

Eyes of the needle

Citation for published version (APA):

Balthasar, A. J. R. (2018). *Eyes of the needle: Spectral tissue sensing, an innovative technology for detecting various tissue types during percutaneous needle-based procedures in locoregional anesthesia and pain medicine*. [Doctoral Thesis, Maastricht University]. Datawyse / Universitaire Pers Maastricht. <https://doi.org/10.26481/dis.20180323ab>

Document status and date:

Published: 01/01/2018

DOI:

[10.26481/dis.20180323ab](https://doi.org/10.26481/dis.20180323ab)

Document Version:

Publisher's PDF, also known as Version of record

Please check the document version of this publication:

- A submitted manuscript is the version of the article upon submission and before peer-review. There can be important differences between the submitted version and the official published version of record. People interested in the research are advised to contact the author for the final version of the publication, or visit the DOI to the publisher's website.
- The final author version and the galley proof are versions of the publication after peer review.
- The final published version features the final layout of the paper including the volume, issue and page numbers.

[Link to publication](#)

General rights

Copyright and moral rights for the publications made accessible in the public portal are retained by the authors and/or other copyright owners and it is a condition of accessing publications that users recognise and abide by the legal requirements associated with these rights.

- Users may download and print one copy of any publication from the public portal for the purpose of private study or research.
- You may not further distribute the material or use it for any profit-making activity or commercial gain
- You may freely distribute the URL identifying the publication in the public portal.

If the publication is distributed under the terms of Article 25fa of the Dutch Copyright Act, indicated by the "Taverne" license above, please follow below link for the End User Agreement:

www.umlib.nl/taverne-license

Take down policy

If you believe that this document breaches copyright please contact us at:

repository@maastrichtuniversity.nl

providing details and we will investigate your claim.



7

Chapter

Summary, General Discussion, and Perspectives

**“Success is not the key to happiness
Happiness is the key to success
If you love what you are doing, you will be successful”**

Albert Schweitzer (1875-1965)
French-German physician, philosopher, humanitarian, organist

7.1 Summary

The aim of this thesis was to determine the value of spectral tissue sensing in percutaneous needle-based procedures. In the introduction the history of needle-based procedures and safety aspects in locoregional anesthesia and pain medicine are described. Also, current maneuvers and tools are discussed with regard to their shortcomings, sensitivity, and specificity. The introduction ends with a brief description of light as an imaging tool and the Spectral tissue sensing (STS) system.

The first chapter explains the ideal method of analyzing optical data that are obtained by STS. The according research question is:

1. *What is the best way to analyze optical spectra with the STS system?*

The second chapter centers on the discovery of intravascular needle position. The according research question is:

2. *Is it possible to detect intravascular needle position with the STS system?*

The third chapter emphasizes the potential of STS to detect nerve structures. The according research question is:

3. *What is the optical signature of nerve tissue?*

The fourth chapter focuses on the detection of tissue transition by STS. The according research question is:

4. *Is it possible to detect tissue transitions with the STS system during peripheral nerve blocks?*

The fifth chapter concentrates on the identification of a correct and safe injection environment during lumbar transforaminal epidural injections with the use of STS. The according research question is:

5. *Can the most appropriate and the safest injection environment be determined with the STS system during lumbar transforaminal epidural injections?*

7.2 Findings

7.2.1 Ad 1: What is the best way to analyze optical spectra with the STS system?

Spectral tissue sensing STS, based on diffuse reflectance spectroscopy (DRS), belongs to the field of biomedical optics. The optical characteristics of various tissues are well de-

scribed. Several challenges must be addressed in developing a technology that is based on DRS—i.e., how to extract the relevant optical data from the spectrum and how to analyze and translate the acquired spectral data into clinically relevant parameters.

In a previous *in vivo* study, we performed partial least-squares discriminant analysis (PLS-DA).¹ PLS-DA was used to classify needle tip locations, and the data were split randomly into training datasets, used to train the PLS-DA model (70% of the data), or validation datasets, used to evaluate the resulting model (the remaining 30%). The evaluation was conducted by applying the PLS-DA model to the validation data and comparing the needle tip locations that it predicted using the locations that were determined by fluoroscopy and DSA. Discriminant analysis was subsequently performed to obtain thresholds for differentiating between values of the response variable. Using this method, the sensitivity and specificity of a technology that is used during lumbar transforaminal epidural injections were described for the first time.

In a subsequent setting, we compared 3 classification methods—PLS-DA, support vector machine (SVM), and classification and regression trees (CARTs)—which were used to examine the difference between *ex vivo* human fascicular and nonfascicular nerve tissue. SVM performed best on this task. The sensitivity and specificity of SVM were comparable or slightly higher compared with PLS-DA (Table 7.1). SVM performed well on multidimensional parameter spaces, because it can ignore features that do not significantly contribute to the discrimination. Dimension reduction by fitting allowed to exclude parameters that are different in an *in vivo* or *ex vivo* setting such as blood oxygenation. In general, the 3 methods had similar accuracies.

Table 7.1 Classification results according to SVM, PLS-DA and CART for discrimination of fascicular tissue of the nerve from the surrounding tissues. For SVM different feature selection methods are used: fit parameters, PCA, segments and a combination of the last three. For PLS-DA, 10 principal components have been used (10PC's). For the CART analysis, the fit parameters have been used as features. Matthews correlation coefficient (MCC see Eq. 2, Chapter 2), accuracy (ACC) sensitivity (SENS), specificity (SPEC).

Classification method	Feature selection	MCC	ACC	SENS (%)	SPEC (%)
SVM	Fit	0.711	0.854	82.6	88.8
SVM	PCA	0.793	0.897	89.9	89.5
SVM	Segments	0.779	0.890	88.6	89.5
SVM	Combined	0.826	0.914	91.3	91.4
PLS-DA	10PC's	0.814	0.907	92.5	89.5
CART	Fit	0.615	0.808	81.2	80.4

7.2.2 Ad 2: Is it possible to detect intravascular needle positions by STS?

During locoregional anesthesia and interventional pain medicine, an intravascular needle position should be avoided. For instance, intravascular injection of local anesthetics can lead to severe complications. Several approaches were used to address this research question in 3 *in vivo* settings. The first setting was in patients for whom interventional pain procedures were planned. In 2 cases, an unintended intravascular needle position was detected by live fluoroscopy²—these 2 situations were clearly detected by STS.

The second observational study was also performed in interventional pain procedures. An intravascular needle position was detected in 1 case by DSA. In a second case, the needle was passively infiltrated by venous blood.¹ Both cases were identified with STS, as evidenced by high blood content. In this study, other needle positions with greater blood content were detected by STS. Due to the study design in this situation, no DSA or aspiration was performed, and the impact of high blood content measured by the STS in this situation is unknown.

Due to the low number of cases in the first 2 studies, we decided to perform a randomized, single-blind, controlled trial with planned intravascular needle insertion,³ in which we inserted a needle subcutaneously in 20 volunteers, who were then randomized for a second subcutaneous or intravascular insertion. The needle position was controlled by aspiration and ultrasound. Based on our results, STS detected an intravascular needle position with high significance. In this setting, the STS data corresponded 100% with the aspiration, compared with 75% between STS and US.

For the latter, in the remaining 25% of cases, the anesthesiologist assumed an intravenous needle position, based on the US image. In these cases, during the insertion, the needle tip positions were judged to be intravenous, but on removal of the stylet, there was no aspiration of blood. The spectra for these subjects suggested a subcutaneous needle position.

Thus, intravascular needle tip positions can't be completely excluded with this study design. Based on aspiration of blood, intravascular needle positioning might fail to be detected. Injection of saline or contrast fluid might have helped ensure the needle position, neither of which was used in this study.

7.2.3 Ad 3: What is the optical signature of nerve tissue?

In addition to the detection of blood vessels, clear identification of nerve tissue is paramount for an anesthesiologist. Despite the use of ultrasound or nerve stimulation, cases of nerve damage are still reported.⁴⁻⁶ The incidence of complications after locoregional anesthesia is 0.4% to 0.79%.^{7,8} However, patients and clinicians fear neurological complications due to nerve damage, such as leg weakness and neuropathic pain.^{9,10} Even temporary nerve damage has a major impact on quality of life.¹¹

We examined nerve detection *in vivo* during ultrasound-guided nerve blocks. In this *in vivo* setup, we failed to discriminate nerve tissue from other adipose tissue,¹² prompting us to revert back to *ex vivo* studies. DRS was acquired from 156 locations in 19 human cadavers in the wavelength range of 400-1710 nm.¹³ Fascicular nerve tissue, muscle, sliding fat, and subcutaneous fat were compared. Fascicular nerve tissue was discriminated from other tissues with a sensitivity and specificity of approximately 90%.

Based on this finding, we decided to perform a second *ex vivo* study to determine the morphological, biological, chemical, and optical characteristics of human nerve tissue and adipose tissue. In addition to conducting DRS and measuring absorption, we performed histology and high-resolution magic-angle spinning nuclear magnetic resonance (HR-MAS NMR) spectroscopy and 2D ¹³C-¹H heteronuclear single-quantum coherence (HSQC). As a result, DRS was able to differentiate nerve fascicles from other adipose tissue. According to the optical absorption measurements in the fascicular nerve tissue, we observed different absorptions of light and a shift in the peak between 900 nm and 1000 nm. With regard to the DRS and HR-MAS NMR measurements, the water percentage of nerve fascicles was higher and the fat percentage was lower compared with all other tissues. The difference in collagen in the DRS measurement was greater in fascicular nerve tissue, as supported by histology. The high scattering parameter (*b*) observed by DRS in fascicular nerve tissue may be related to a larger inhomogeneity in the distribution of the collagen content and higher density of cellular nuclei as seen in histology. Comparing the results between this study and the earlier trial, the differences in collagen, water, light scattering, and fat in fascicular nerve tissue were reproduced.

7.2.4 Ad 4: Is it possible to detect tissue transitions with the STS system during peripheral nerve blocks?

During percutaneous peripheral nerve blocks, the needle will pass various tissues en route to the target nerve. Generally, subcutaneous adipose tissue and muscles will be punctured by the needle before the nerve region is reached. To determine whether STS detects this tissue transition, we made 20 measurements during ultrasound-guided nerve blocks¹²; 15 datasets were ultimately included in the analysis. The lipid parameter declined significantly and the hemoglobin parameter rose significantly when the needle tip transitioned from subcutaneous fat to muscle tissue. When the needle passed from muscle tissue to the nerve environment, the lipid parameter increased significantly, and the hemoglobin parameter fell again. Discrimination between subcutaneous fat and nerve environment was not possible at this time with these parameters.

In a second study, we examined the differences between STS signals obtained at 4 different measurement locations during transforaminal epidural injection (TEI). The 4 measurement points were: M1: in the paraspinal muscle, M2: at the border of the neuroforamen (intended to be extraforaminal), M3: one-third of the distance along the neuroforamen, and M4: in the middle of the neuroforamen at the target location, close

to the segmental nerve. Our data indicated that M1 can be discriminated from M2, M3, and M4 by the significantly lower lipid content ($P = 0.0078$). An earlier study on STS reported that intramuscular needle placement was associated with a higher hemoglobin and lower lipid content, but in the current study, we were able to replicate only the finding of a lower lipid content. The comparison of all intraforaminal locations (M3 + M4) and all extraforaminal locations (M1 + M2) showed a sensitivity and specificity increased to 80% and 71%, respectively. These results suggest that STS can detect the needle transition from extraforaminal to an intraforaminal needle position.

7.2.5 Ad 5: Can the most appropriate and safest injection environment be determined with the STS system during lumbar transforaminal epidural injections?

Transforaminal epidural injection (TEI) is one of the most frequently performed procedures in interventional pain medicine. Nevertheless, case reports have described severe complications, such as spinal cord or brain infarction. Reports on serious adverse events and complications after TEI have recommended more precise needle tip positioning,^{14,15} particularly for the cervical area.¹⁶ Current imaging techniques and orientation aids have limitations, and undetected intravascular uptake of injection fluid can cause such severe complications.¹⁷

We tested STS in lumbar TEIs.¹ A safe injection environment was defined as the spread of contrast fluid along the segmental nerve during DSA without vascular uptake. In this study, with regard to correct needle placement the specificity of STS was 82%, and its sensitivity was 57%. Intraforaminal versus extraforaminal locations were identified with a sensitivity of 80% and a specificity of 71%. In the literature, no comparable studies have been performed that describe the sensitivity or specificity of correct needle placement in lumbar TEIs with other imaging techniques.

7.3 General discussion

This thesis, *Eyes of the needle - Spectral tissue sensing, an innovative technology to detect different types of tissues during needle-based procedures in locoregional anesthesia and pain medicine*, examines the potential of biomedical optics in anesthesiology practice. The basic principle that underlies all optical devices for diagnostic or therapeutic purposes is that the behavior of light of certain wavelengths in various situations is analyzed. Researchers have exploited this phenomenon to develop many devices to characterize tissues, analyze the composition of gases, and destroy tissues. In today's anesthesiology practices, light is used as a diagnostic tool for pulse oximetry and the analysis of the anesthetic gas, for example.

The concept of measuring O₂ saturation with light was first described in 1935 by German physician Karl Matthes (1905–1962).¹⁸ Also, in surgery, several optical technologies are used to discriminate various types of tissue. Fluorescence-guided surgery, using fluorescein sodium, was introduced by Moore et al. in 1948.¹⁹ Near-infrared fluorescence is used in cancer surgery to determine which tissues must be resected or avoided.²⁰

Raman analysis is a well-known technique in biomedical optics that is based on the inelastic scattering of photons on interaction with tissue, measuring the vibrational fingerprint of cells and tissues.¹⁹ For instance, Raman spectra have been used to discriminate between malignant and benign tissue in breast and head and neck cancer patients.^{21,22}

Spectroscopy is another optical technique, using optical probes to determine optical tissue properties to determine tissue composition (based on the absorption characteristics of various chromophores) and tissue architecture (scattering). In contrast to general anesthesia and surgery, no optical technologies have been established in locoregional anesthesia or pain medicine.

Spectral tissue sensing (STS), examined in this thesis, is an optical technique based on diffuse reflectance spectroscopy (DRS). We developed an optical tissue database to render STS a valuable tool for percutaneous needle-based procedures in (locoregional) anesthesia and pain practice. As discussed in the introduction, current techniques have shortcomings, necessitating improvements in their safety and performance.^{4,17,23,24}

To construct a database, we first determined the tissues are most important to be identified, as supported by the literature and ongoing discussion among experts.^{4,25,26} This thesis focuses on the identification of adipose tissue, muscle, blood, and nerve fascicles.

The optical characteristics of the following tissues were described:

- Adipose tissue:
 - Low scattering
 - High absorption of light at 1200 nm
- Muscle tissue:
 - High scattering
 - Some absorption of light 500 nm and little absorption at 1200 nm
- Blood:
 - Low scattering
 - High absorption of light between 500-600 nm
- Nerve fascicles:
 - High scattering
 - Absorption of light at 1300-1600, 1900-2200 nm
 - Peak shift 900 and 1000 nm

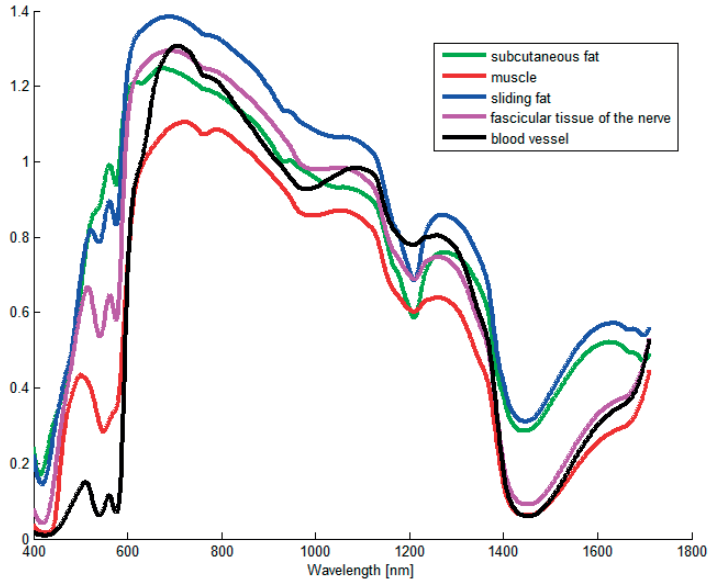


Figure 7.1 Overview of typical absorption characteristics of subcutaneous and sliding fat, muscle, blood, and nerve fascicles. X-axis wavelength in nm, Y-axis intensity in arbitrary units.

With regard to intravascular needle position, nerve stimulators have been unable to identify blood vessels, and aspiration has been needed to test for intravascular needle position. Aspiration has a sensitivity of only 25% to 47%.²⁷ Using X-ray, contrast fluid is needed to test for intravascular needle position. Ultrasound yields more anatomical information, but it is a complex and challenging tool with a steep learning curve. Moreover, the outcome of the procedure depends highly on the experience of and interpretation by the physician.^{4,28} With ultrasound or DSA, intravascular injections continue to encounter complications.^{25,29,30} STS could provide important information on the tissue in front of the needle and detect intravascular needle position reliably, as proven by 3 studies in this thesis.

With the use of ultrasound still unintended subepineural injections occur.³¹⁻³³ Intra-neural needle position does not always lead to a neurological damage one of the most feared complications. There is a clinical need to improve needle tip identification.^{5,34,35} Various technologies are being examined to improve needle tip placement, such as intraneural needle detection with bioimpedance monitoring.³⁶ Further, more advanced ultrasound machines are being designed. Real-time 3-dimensional ultrasound allows for simultaneous visualization of multiple planes of view, permitting longitudinal, cross-sectional, and coronal images to be viewed without probe adjustment, and provides additional information about the spatial relationship between anatomical structures of interest compared with standard imaging.^{34,37}

This thesis describes the optical characteristics of fascicular nerve tissue; such studies in surgery have been published. Schols et al. used DRS in a camera system during thyroid and parathyroid resection and carpal tunnel release surgery, testing 2 hyper-spectral camera technologies (silicon and indium gallium arsenide) for automated discrimination between nerves and surrounding adipose tissue. They reported accuracies of 67% and 100%, respectively.³⁸ In near-infrared fluorescence, myelin-selective fluorescent dyes and nerve-highlighting fluorescent peptides have been developed.^{39,40} Also, a NIR fluorescent dye for use in probes has been described.⁴¹ Many options in biomedical optics are being tested to identify nerve tissue. This thesis concentrates on the identification of nerve fascicles. The optical characteristics of *ex vivo* nerve fascicles are detailed. Next to the supplying blood vessels, nerve fascicles are the most vulnerable structure of the nerve. Damage to these fascicles can result in neurological symptoms, such as dysesthesia and muscle weakness. STS can identify these nerve fascicles.

In addition to that of the tissue itself, information on tissue transition is helpful. These data require a fast STS system that generates user-friendly optical information in real time to the operator without disturbing the workflow. In doing so, the needle placement can be more accurate, and the needle tip identification can be simplified.

Finally, we examined whether STS can detect a safe injection environment during lumbar transforaminal epidural injections (LTEIs).^{1,12} The TEI is one of the most common procedures in interventional pain medicine. Case reports have described severe complications, such as spinal cord and brain infarction.^{14,15} In this setting, it was the first technology to have clear sensitivity and specificity with regard to needle placement during LTEI. Here, we tested the STS system in a clinical setting in actual patients and gathered information on various tissues and the tissue transition.

DRS is not a standalone technique in anesthesiology—other imaging tools, such as ultrasound and X-ray, are needed to determine the anatomical orientation and plan the procedure. STS can identify various tissues, and compared with current clinical tools, this property is unique (see also Table 7.1). The innovation of STS lies in its ability to provide the clinician during needle-based protocols with additional tissue information directly from the needle tip to complete the anatomical profile and track the needle tip position during various procedures.

7.3.1 Validation and reliability

A new technology must meet several criteria to render it a valuable tool. It should:

1. Consistently produce the same results, independent of the user
2. Measure what it claims to assess

This thesis contributes to the validation and reliability of STS. The STS system has clinical potential and can improve current practices in terms of safety. In various settings and patients, STS performed comparably concerning intravascular needle position. These

results were assessed against standard tools (aspiration, live fluoroscopy, and DSA). The optical detection of adipose tissue by STS was also robust and reproduced in ex vivo and in vivo settings. Regarding the identification of fascicular nerve tissue, several important steps were developed, and optical characteristics were described in an ex vivo setting.

In general, no requirements or criteria exist to which new developed technology in locoregional anesthesia should apply. As a consequence, in this thesis, the following questions were frequently raised:

- What are the criteria for an ideal nerve localization tool for procedures in regional anesthesia or pain medicine?
- What is the niche for STS versus other imaging/guidance tools in percutaneous needle-based procedures?

As mentioned, there are no standards with regard to the needs of physicians for safe percutaneous needle-based procedures. The following section describes 14 criteria for an ideal imaging guidance tool and gives an overview of the various techniques and how well they meet each criterion.

7.3.2 Criteria

We have generated a list of criteria for the ideal medical device for percutaneous needle-based procedures, with which current and future techniques and tools can be classified.

These criteria were developed by an expert team at Maastricht University Medical Hospital and St. Radboud University Medical Center, Nijmegen, The Netherlands.

1. Gives a real-time view of the relevant anatomical structures in and along the planned needle trajectory
2. Reliably identifies nerve structures
3. Reliably identifies the subepineural needle position
4. Reliably identifies blood vessels
5. Reliably identifies the intravascular needle position
6. Gives a clear view of the needle tip during the procedure
7. Is primarily independent of the experience and skills of the physician
8. Is primarily independent of the observation and interpretation by the physician
9. Has a short learning curve
10. Does not cause harm to the patient or physician
11. Can be used in various patient categories (e.g. any BMI or age)
12. Does not disturb the regular workflow (no extra injections, no extra sonography, etc.)
13. Gives a real-time display of the needle tip, needle trajectory, and anatomical structures
14. Identifies tissues directly in front of the needle tip in real time during the procedure

Table 7.1 shows the 14 criteria with regard to the main imaging tools and STS. For each imaging tool, an indication is given if it fulfills a certain criterion. The decisions were checked and confirmed by a radiologist. None of these imaging techniques or medical devices meets all of the criteria. Table 7.1 also shows the ideal combinations of various tools that fulfill the most criteria.

STS clearly scores best compared with the other tools and provides the most overlap with the other tools. Thus, STS also provides a double check of information generated by another tool. The combination of ultrasound and STS fulfills 12 of the 14 criteria. For instance, aspiration can be fully replaced by STS and nerve stimulator for most functions at this stage of development of STS. Currently, STS is unable to stimulate nerves. For X-ray-based procedures, the injection of contrast fluid and DSA could be replaced by STS.

Table 7.1 Criteria for the ideal medical device during percutaneous needle-based procedures, the 4 main imaging tools (nerve stimulator, radiography, ultrasonography, and CT), and aspiration used today for these procedures. P means partly.

	Real-time view of anatomy and needle trajectory	Identifies nerves	Identifies intraneural (subepineural) needle position	Identifies vessels	Identifies intravascular needle position	Clear view of needle tip	Independent of physician experience	Independent of the observation / interpretation by the physician	Short learning curve	No extra harm to patient or user	Can be used in multiple patient categories	Does not disturb workflow	Real-time display of the needle tip, needle trajectory, and anatomical structures	Identifies different tissues directly in front of the needle tip
Nerve stimulation	No	p ¹	p ¹	No	No	No	Yes	No	Yes	p ³	Yes	p ⁴	No	No
Radiography with DSA	No	No	No	Yes	Yes	p ²	No	No	No	No	No	p ⁴	No	No
Ultrasound	Yes	Yes	p ²	Yes	p ²	p ²	No	No	No	Yes	No	Yes	Yes	No
CT	No	No	No	Yes	Yes	Yes	No	p ²	No	No	No	p ⁷	No	No
Aspiration	No	No	No	No	p ⁵	No	Yes	p ²	Yes	Yes	Yes	p ⁷	No	No
STS	No	p ⁶	Yes	No	Yes	No	Yes	Yes	Yes	Yes	Yes	p ⁸	No	Yes

¹Insufficient (sensitivity of 74%); ²dependent on physician experience; ³can be painful to the patient; ⁴physician needs extra help from another person or needs to inject an ancillary agent, such as contrast fluid, and take extra images; ⁵insufficient (sensitivity < 47%); ⁶it is not clear whether STS can discover a nerve from the outside; ⁷extra procedures are necessary; ⁸depends on the design of the user interface.

7.3.3 Limitations

More studies are needed in various settings to prove the robustness of existing results and to test STS in a larger, more heterogeneous group of patients.

At this time, several questions remain. In vivo research is needed to confirm the ability of STS to discriminate between nerve fascicles and other adipose tissue. The value of detecting a blood-rich environment by STS is unknown without other proof of the intravascular needle position, which can result from a hematoma or small bleed. A user-friendly interface must be developed and tested for the STS information to be easily understandable and usable.

7.4 Future perspectives

To develop STS into a valuable tool for standard high-quality health care, the database should be generated with all types of tissues. To this end, real-time identification of the tissue directly in front of the needle could provide important data to the physician. We see potential for STS in surgery, diagnostic punctures, needle guidance during any type of percutaneous procedure, and the documentation and quality of care. For instance, documentation of the tissues that are passed during a procedure can be stored. Tissue diagnostics by STS could be also relevant to pain practices. In cases of radiofrequency treatment, the quality of percutaneous radiofrequent lesions can be determined, and the treatment can be individualized, improving the outcome. The combination of STS with tissue-specific fluorescence has not been examined extensively.

Studies have been performed to determine the value of STS in oncology. STS can improve the differentiation of malignant versus benign tissue during surgery or biopsy. STS can be integrated into catheters or sutures to evaluate blood or tissue oxygenation. For instance, the integration of STS into intestinal sutures or central venous catheters can allow one to control tissue oxygenation or ensure venous placement, respectively.

There is some research on the optical stimulation of nerves, which might one day be performed by STS. Nerve stimulation during locoregional anesthesia and surgery has well-known functions.

Finally, an integrated user interface on the ultrasound screen could ease the workflow for the clinician, which would require a fast-acting STS system that does not disturb the workflow.

In summary, STS is a promising technique with potential value in pain and anesthesiology practices. The combination of the STS system with ultrasound or X-ray has the potential to become the new technical standard in percutaneous needle-based procedures.

References

1. Balthasar AJ, Lucassen GW, Sommer M, van der Voort M, Gijbbers G, Arnoldussen CW, et al. The Role of Spectral Tissue Sensing During Lumbar Transforaminal Epidural Injection. *Reg Anesth Pain Med.* 2016;41(4):520-6.
2. Balthasar A, Desjardins AE, van der Voort M, Lucassen GW, Roggeveen S, Wang K, et al. Optical detection of vascular penetration during nerve blocks: an in vivo human study. *Reg Anesth Pain Med.* 2012;37(1):3-7.
3. Balthasar AJ, van Geffen GJ, van der Voort M, Lucassen GW, Roggeveen S, Bruaset IJ, et al. Spectral tissue sensing to identify intra- and extravascular needle placement - A randomized single-blind controlled trial. *PLoS One.* 2017;12(3):e0172662.
4. Neal JM. Ultrasound-guided regional anesthesia and patient safety: An evidence-based analysis. *Reg Anesth Pain Med.* 2010;35(2 Suppl):S59-67.
5. Terkawi AS, Karakitsos D, Elbarbary M, Blaivas M, Durieux ME. Ultrasound for the anesthesiologists: present and future. *ScientificWorldJournal.* 2013;2013:683685.
6. Neuburger M, Schwemmer U, Volk T, Gogarten W, Kessler P, Steinfeldt T. [Localization of peripheral nerves. Success and safety with electrical nerve stimulation]. *Anaesthesist.* 2014;63(5):422-8.
7. Barrington MJ, Watts SA, Gledhill SR, Thomas RD, Said SA, Snyder GL, et al. Preliminary results of the Australasian Regional Anaesthesia Collaboration: a prospective audit of more than 7000 peripheral nerve and plexus blocks for neurologic and other complications. *Reg Anesth Pain Med.* 2009;34(6):534-41.
8. Jacob AK, Mantilla CB, Sviggum HP, Schroeder DR, Pagnano MW, Hebl JR. Perioperative nerve injury after total knee arthroplasty: regional anesthesia risk during a 20-year cohort study. *Anesthesiology.* 2011;114(2):311-7.
9. Barrington MJ, Snyder GL. Neurologic complications of regional anesthesia. *Curr Opin Anaesthesiol.* 2011;24(5):554-60.
10. Houten JK, Errico TJ. Paraplegia after lumbosacral nerve root block: report of three cases. *Spine J.* 2002;2(1):70-5.
11. Helen L, O'Donnell BD, Moore E. Nerve localization techniques for peripheral nerve block and possible future directions. *Acta Anaesthesiol Scand.* 2015;59(8):962-74.
12. Balthasar A, Desjardins AE, van der Voort M, Lucassen GW, Roggeveen S, Wang K, et al. Optical detection of peripheral nerves: an in vivo human study. *Reg Anesth Pain Med.* 2012;37(3):277-82.
13. Hendriks BH, Balthasar AJ, Lucassen GW, van der Voort M, Mueller M, Pully VV, et al. Nerve detection with optical spectroscopy for regional anesthesia procedures. *J Transl Med.* 2015;13:380.
14. Manchikanti L, Malla Y, Wargo BW, Cash KA, Pampati V, Fellows B. A prospective evaluation of complications of 10,000 fluoroscopically directed epidural injections. *Pain physician.* 2012;15(2):131-40.
15. Huntoon MA, Martin DP. Paralysis after transforaminal epidural injection and previous spinal surgery. *Reg Anesth Pain Med.* 2004;29(5):494-5.
16. Van Zundert J, Huntoon MA, van Kleef M. Complications of transforaminal cervical epidural steroid injections. *Spine (Phila Pa 1976).* 2009;34(22):2477; author reply -8.
17. Rathmell JP. Toward improving the safety of transforaminal injection. *Anesth Analg.* 2009;109(1):8-10.
18. Matthes K. Untersuchungen über die Sauerstoffsättigung des menschlichen Arterienblutes. *Naunyn-Schmiedebergs Archiv für experimentelle Pathologie und Pharmakologie.* 179(6):698-711.
19. Valdes PA, Roberts DW, Lu FK, Golby A. Optical technologies for intraoperative neurosurgical guidance. *Neurosurg Focus.* 2016;40(3):E8.
20. Vahrmeijer AL, Hutteman M, van der Vorst JR, van de Velde CJ, Frangioni JV. Image-guided cancer surgery using near-infrared fluorescence. *Nat Rev Clin Oncol.* 2013;10(9):507-18.
21. Hoesli RC, Orringer DA, McHugh JB, Spector ME. Coherent Raman Scattering Microscopy for Evaluation of Head and Neck Carcinoma. *Otolaryngol Head Neck Surg.* 2017:194599817700388.

22. Hu C, Wang J, Zheng C, Xu S, Zhang H, Liang Y, et al. Raman spectra exploring breast tissues: Comparison of principal component analysis and support vector machine-recursive feature elimination. *Med Phys*. 2013;40(6Part1).
23. Rathmell JP, Manion SC. The role of image guidance in improving the safety of pain treatment. *Curr Pain Headache Rep*. 2012;16(1):9-18.
24. Warman P, Nicholls B. Ultrasound-guided nerve blocks: efficacy and safety. *Best Pract Res Clin Anaesthesiol*. 2009;23(3):313-26.
25. Bigeleisen PE. Nerve puncture and apparent intraneural injection during ultrasound-guided axillary block does not invariably result in neurologic injury. *Anesthesiology*. 2006;105(4):779-83.
26. Sites BD, Taenzer AH, Herrick MD, Gilloon C, Antonakakis J, Richins J, et al. Incidence of local anesthetic systemic toxicity and postoperative neurologic symptoms associated with 12,668 ultrasound-guided nerve blocks: an analysis from a prospective clinical registry. *Reg Anesth Pain Med*. 2012;37(5):478-82.
27. Perlas A, Niazi A, McCartney C, Chan V, Xu D, Abbas S. The sensitivity of motor response to nerve stimulation and paresthesia for nerve localization as evaluated by ultrasound. *Reg Anesth Pain Med*. 2006;31(5):445-50.
28. Hadzic A, Sala-Blanch X, Xu D. Ultrasound guidance may reduce but not eliminate complications of peripheral nerve blocks. *Anesthesiology*. 2008;108(4):557-8.
29. Sala Blanch X, Lopez AM, Carazo J, Hadzic A, Carrera A, Pomes J, et al. Intraneural injection during nerve stimulator-guided sciatic nerve block at the popliteal fossa. *Br J Anaesth*. 2009;102(6):855-61.
30. Robards C, Hadzic A, Somasundaram L, Iwata T, Gadsden J, Xu D, et al. Intraneural injection with low-current stimulation during popliteal sciatic nerve block. *Anesth Analg*. 2009;109(2):673-7.
31. Chin KJ, Perlas A, Chan VW, Brull R. Needle visualization in ultrasound-guided regional anesthesia: challenges and solutions. *Reg Anesth Pain Med*. 2008;33(6):532-44.
32. Orebaugh SL, McFadden K, Skorupan H, Bigeleisen PE. Subepineurial injection in ultrasound-guided interscalene needle tip placement. *Reg Anesth Pain Med*. 2010;35(5):450-4.
33. Liu SS, YaDeau JT, Shaw PM, Wilfred S, Shetty T, Gordon M. Incidence of unintentional intraneural injection and postoperative neurological complications with ultrasound-guided interscalene and supraclavicular nerve blocks. *Anaesthesia*. 2011;66(3):168-74.
34. Clendenen NJ, Robards CB, Clendenen SR. A standardized method for 4D ultrasound-guided peripheral nerve blockade and catheter placement. *Biomed Res Int*. 2014;2014:920538.
35. Abdallah FW, Macfarlane AJ, Brull R. The Requisites of Needle-to-Nerve Proximity for Ultrasound-Guided Regional Anesthesia: A Scoping Review of the Evidence. *Reg Anesth Pain Med*. 2016;41(2):221-8.
36. Kalvoy H, Sauter AR. Detection of intraneural needle-placement with multiple frequency bioimpedance monitoring: a novel method. *J Clin Monit Comput*. 2016;30(2):185-92.
37. Chandra A, Eisma R, Felts P, Munirama S, Corner GA, Demore CE, et al. The feasibility of micro-ultrasound as a tool to image peripheral nerves. *Anaesthesia*. 2017;72(2):190-6.
38. Schols RM, ter Laan M, Stassen LP, Bouvy ND, Amelink A, Wieringa FP, et al. Differentiation between nerve and adipose tissue using wide-band (350-1,830 nm) in vivo diffuse reflectance spectroscopy. *Lasers Surg Med*. 2014;46(7):538-45.
39. Gibbs-Strauss SL, Nasr KA, Fish KM, Khullar O, Ashitate Y, Siclovan TM, et al. Nerve-highlighting fluorescent contrast agents for image-guided surgery. *Mol Imaging*. 2011;10(2):91-101.
40. Whitney MA, Crisp JL, Nguyen LT, Friedman B, Gross LA, Steinbach P, et al. Fluorescent peptides highlight peripheral nerves during surgery in mice. *Nat Biotechnol*. 2011;29(4):352-6.
41. Gustafson TP, Yan Y, Newton P, Hunter DA, Achilefu S, Akers WJ, et al. A NIR Dye for Development of Peripheral Nerve Targeted Probes. *Medchemcomm*. 2012;3(6):685-90.