

European consensus-based interdisciplinary guideline for diagnosis, treatment and prevention of actinic keratoses, epithelial UV-induced dysplasia and field cancerization on behalf of European Association of Dermato-Oncology, European Dermatology Forum, European Academy of Dermatology and Venereology and Union of Medical Specialists (Union Européenne des Médecins Spécialistes)

Citation for published version (APA):

Kandolf, L., Peris, K., Malvey, J., Mosterd, K., Heppt, M. V., Fagnoli, M. C., Berking, C., Arenberger, P., Bylaite-Bucinskiene, M., Del Marmol, V., Dirschka, T., Dreno, B., Forsea, A.-M., Harwood, C. A., Hauschild, A., Heerfordt, I. M., Kauffman, R., Kelleners-Smeeths, N., Lallas, A., ... European union of medical specialists (EUMS), (2024). European consensus-based interdisciplinary guideline for diagnosis, treatment and prevention of actinic keratoses, epithelial UV-induced dysplasia and field cancerization on behalf of European Association of Dermato-Oncology, European Dermatology Forum, European Academy of Dermatology and Venereology and Union of Medical Specialists (Union Européenne des Médecins Spécialistes). *Journal of the European Academy of Dermatology and Venereology*, 38(6), 1024-1047. <https://doi.org/10.1111/jdv.19897>

Document status and date:

Published: 01/06/2024

DOI:

[10.1111/jdv.19897](https://doi.org/10.1111/jdv.19897)

Document Version:

Publisher's PDF, also known as Version of record

Document license:

Taverne

Please check the document version of this publication:

- A submitted manuscript is the version of the article upon submission and before peer-review. There can be important differences between the submitted version and the official published version of record. People interested in the research are advised to contact the author for the final version of the publication, or visit the DOI to the publisher's website.
- The final author version and the galley proof are versions of the publication after peer review.
- The final published version features the final layout of the paper including the volume, issue and page numbers.

[Link to publication](#)

General rights

Copyright and moral rights for the publications made accessible in the public portal are retained by the authors and/or other copyright owners and it is a condition of accessing publications that users recognise and abide by the legal requirements associated with these rights.

- Users may download and print one copy of any publication from the public portal for the purpose of private study or research.
- You may not further distribute the material or use it for any profit-making activity or commercial gain
- You may freely distribute the URL identifying the publication in the public portal.

If the publication is distributed under the terms of Article 25fa of the Dutch Copyright Act, indicated by the "Taverne" license above, please follow below link for the End User Agreement:
















www.umlib.nl/taverne-license

Take down policy

If you believe that this document breaches copyright please contact us at:

GUIDELINES

European consensus-based interdisciplinary guideline for diagnosis, treatment and prevention of actinic keratoses, epithelial UV-induced dysplasia and field cancerization on behalf of European Association of Dermato-Oncology, European Dermatology Forum, European Academy of Dermatology and Venereology and Union of Medical Specialists (Union Européenne des Médecins Spécialistes)

Lidija Kandolf¹  | Ketty Peris^{2,3}  | Josep Malvehy⁴ | Klara Mosterd^{5,6}  | Markus V. Heppt^{7,8}  | Maria Concetta Fagnoli⁹  | Carola Berking^{7,8} | Petr Arenberger¹⁰  | Matilda Bylaite-Bučinskiene¹¹ | Veronique del Marmol¹² | Thomas Dirschka^{13,14} | Brigitte Dreno¹⁵  | Ana-Maria Forsea¹⁶  | Catherine A. Harwood¹⁷ | Axel Hauschild¹⁸ | Ida Marie Heerfordt¹⁹  | Roland Kauffman²⁰  | Nicole Kelleners-Smeets^{5,6} | Aimilios Lallas²¹  | Celeste Lebbe²² | Ulrike Leiter²³  | Caterina Longo²⁴  | Željko Mijušković¹ | Giovanni Pellacani²⁵  | Susana Puig⁴  | Philippe Saiag²⁶ | Mirna Šitum²⁷ | Eggert Stockfleth²⁸ | Carmen Salavastru²⁹ | Alexander Stratigos³⁰ | Iris Zalaudek³¹ | Claus Garbe²³ | on behalf of European Association of Dermato-Oncology, European Dermatology Forum, European Academy of Dermatology and Venereology and Union of Medical Specialists (Union Européenne des Médecins Spécialistes)

Correspondence

Lidija Kandolf, Department of Dermatology, Faculty of Medicine, University of Defence, Military Medical Academy, Belgrade, Serbia. Email: lidijkandolf@gmail.com

[Correction added on 8 April 2024, after first online publication: A co-author's name has been corrected to Nicole Kelleners-Smeets.]

Abstract

A collaboration of multidisciplinary experts from the European Association of Dermato-Oncology, the European Dermatology Forum, the European Academy of Dermatology and Venereology, and the European Union of Medical Specialists was formed to develop European recommendations on AK diagnosis and treatment, based on current literature and expert consensus. This guideline addresses the epidemiology, diagnostics, risk stratification and treatments in immunocompetent as well as immunosuppressed patients. Actinic keratoses (AK) are potential precursors of cutaneous squamous cell carcinoma (cSCC) and display typical histopathologic and immunohistochemical features of this malignancy in an early stage. They can develop into cSCC in situ and become invasive in a low percentage of cases. AK is the most frequent neoplasia in white populations, frequently occurring within a cancerous field induced by ultraviolet radiation. Since it cannot be predicted, which lesion will progress to cSCC and when treatment is usually recommended. The diagnosis of

For Affiliation refer page on 18

© 2024 European Academy of Dermatology and Venereology.

AK and field cancerization is made by clinical examination. Dermoscopy, confocal microscopy, optical coherence tomography or line-field confocal-OCT can help in the differential diagnosis of AK and other skin neoplasms. A biopsy is indicated in clinically and/or dermatoscopically suspicious and/or treatment-refractory lesions. The choice of treatment depends on patients' and lesion characteristics. For single non-hyperkeratotic lesions, the treatment can be started upon patient's request with destructive treatments or topical treatments. For multiple lesions, field cancerization treatment is advised with topical treatments and photodynamic therapy. Preventive measures such as sun protection, self-examination and repeated field cancerization treatments of previously affected skin areas in high-risk patients are advised.

INTRODUCTION

Societies in charge

This guideline was developed on behalf of the European Dermatology Forum (EDF). The European Association of Dermato-Oncology (EADO) coordinated the authors' contributions as part of its Guideline Program in Oncology (GPO). The editors and coordinators responsible for the formulation of the guideline were Lidija Kandolf, Claus Garbe, Josep Malvehy, Klara Mosterd, Maria Concetta Fargnoli, Markus Heppt and Carola Berking. To ensure the interdisciplinary quality of the guidelines, they were developed in cooperation with the European Dermatology Forum (EDF) and the European Union of Medical Specialists (Union Européenne des Médecins Spécialistes, UEMS).

Disclaimer

All statements related to the definition, classification, diagnosis and treatment of actinic keratosis (AK) correspond to the current scientific knowledge, based on the data from the literature available at the time of printing the guidelines. The attending physician invoking these guideline recommendations must consider scientific progress since the publication of the guideline. The user remains responsible for all diagnostic and therapeutic applications, medications and doses. Just as adherence to the guidelines may not constitute defence against a claim of negligence (malpractice), deviation from them should not necessarily be deemed negligent. These guidelines will require updating approximately every 2 years but advances in medical sciences may demand an earlier update. Registered trademarks (protected product names) are not specified in these guidelines. This work is protected by copyrights in all its parts. Any utilization outside the provision of the copyright act without the written permission by the GPO of the EADO is prohibited and punishable by law. No part of this work may be reproduced in any way without written permission by the GPO. This applies to duplications, translations, microfilming and the storage, application and utilization in electronic systems, intranets and Internet.

Scope

This guideline was developed to assist clinicians in diagnosing and treating patients with epithelial dysplasia, including AK. In recent years, significant rise of incidence of keratinocyte cancers is evident, leading to the increased burden on the society. Also, advances were made in understanding of keratinocyte dysplasia, and the concept of field cancerization was introduced and adopted by the dermatology community. Different classification schemes of epithelial dysplasia and AK were developed to guide the treatment approach in everyday practice. New insights in the efficacy and safety of different topical treatments and destructive methods for this condition were also developed. It is recognized by the scientific community that these conditions should be treated and monitored to prevent the transformation to invasive cutaneous squamous cell carcinoma. Thus, the use of these guidelines that incorporate the updated scientific knowledge in the field of definition, diagnosis and treatment of epithelial dysplasia, AK and field cancerization in clinical routine should improve patient care.

Target population

The guidelines have been prepared for the clinicians who take care of the patients with AK and keratinocyte carcinomas in general. These are mainly dermatologists.

Objectives and formulation of questions

The guidelines have been developed and organized in clear sections, based on the latest data from the literature, to support clinicians in finding the answers to questions relevant to the everyday practice on: (a) definition of AK and field cancerization and their relation to cutaneous squamous cell carcinoma (cSSC); (b) epidemiology and pathophysiology; (c) which examinations methods are reliable for diagnosis and do we need histopathologic confirmation? (d) is there a rationale for early treatment of AK and which patient should receive which treatment? (e) how we should follow-up patients with AK and (f) what preventive measure can be advised to the patients?

Principles of methodology

The literature search was carried out by the authors using PubMed, and only articles published until September 2022 were included. Search strings were used, which cannot all be listed here. In principle, the search strings are constructed in such a way that the search is primarily carried out in the titles and abstracts of the publication, including the terms AK, keratinocyte dysplasia, field cancerization, prevention, diagnosis and treatment. All diagnostic and treatment recommendations summarized in the respective tables are evaluated on the basis of evidence-based data or formulated as expert consensus if no sufficient evidence is available. The methodology of these updated guidelines is based on the standards of the AGREE II instrument.¹ The levels of evidence are graded according to the Oxford classification (Table 1).²

The grades of recommendation were classified as follows:

- A: Strong recommendation. Syntax: 'shall'.
 - B: Recommendation. Syntax: 'should'.
 - C: Weak recommendation. Syntax: 'may/can'.
 - X: Should not be recommended.
 - 0: Recommendation pending. Currently not available or not sufficient evidence to make a recommendation in favour or against.
- An expert consensus was presented, where there was insufficient evidence.

Source guidelines

Source guidelines for guideline adaptation of recommendations was the German S3 guideline on actinic keratosis and the American Academy of Dermatology guidelines on actinic keratosis,³⁻⁵ since previously published guidelines expired (i.e. published 5 or more years ago).

Consensus building process

The consensus building process was conducted as follows: In a first-round, medical experts who participated in their national guideline development processes were involved in producing an initial draft. A consensus meeting was held in Rome, Italy, on 24 and 25 November with final outcomes: (1) the approval of the text and (2) a consensus rate of agreement of at least 80%, for recommendations provided in structured boxes and the figure. Voting of the recommendations included the selection of 'Agree', 'Disagree' or 'Abstentional' vote, and the possibility of providing comments in case of disagree/abstentional. The consensus vote on the recommendations and the finalization of the draft were conducted among coauthors by email between 1 and 24 December 2022.

Financing

The authors did this work on a voluntary basis and did not receive any honorarium. Travel costs for participation in Consensus Conferences were paid by the authors themselves. Accommodation during the Consensus Conferences was reimbursed in part by EADO.

DEFINITION, EPIDEMIOLOGY, AETIOLOGY AND DIAGNOSIS

Definition

Actinic keratosis (AK) is a common cutaneous keratinocyte dysplasia characterized by the abnormal proliferation of atypical epidermal keratinocytes (keratinocyte intraepidermal neoplasia (KIN)). In World Health Organization (WHO) classification of skin tumours, it is listed as a carcinoma precursor.⁶ Multiple terms have been used in the literature to define this lesion including 'solar keratosis', 'senile keratosis', 'keratosis senilis', 'senile keratoma', 'keratoma senile'⁷ and 'in situ SCC type AK'.⁸ AK is either considered as a precancerous lesion that may possibly 'transform' into invasive SCC (iSCC), or as in situ SCC (intraepidermal proliferation of atypical keratinocytes) that may progress to an invasive stage. This concept is based on the fact that AK is cytologically indistinguishable from in situ SCC and has a number of molecular alterations common to SCC.^{9,10} The term in situ SCC should be used with caution with patients, because the term 'carcinoma' is associated with morbidity that does not correspond to the clinical diagnosis since AKs in most cases do not transform into an iSCC. However, it should be communicated to patients that currently it is not possible to predict the progression of single AK lesions to invasive cSCC (Table 2).

Concept of field cancerization

Field cancerization is defined as an area of subclinical changes in the periphery of clinically visible AKs that displays genetic changes similar to those found in AK lesions.^{11,12} Clinically, a definition of field cancerization has been established by expert opinion consensus and systematic review has been stated as 'the anatomical area with or adjacent to AK and visibly sun-damaged skin characterized by at least two of the following signs: telangiectasia, atrophy, pigmentation abnormalities and a sandpaper like texture'. It is unclear whether a visible AK lesion is required for field cancerization¹³ (Table 2).

Pathophysiology

AKs result from excessive chronic sun exposure and are located mainly on areas with chronically sun-damaged

TABLE 1 Oxford centre for evidence-based medicine 2011 level of evidence.

Question	Step 1 (level 1 ^a)	Step 2 (level 2 ^a)	Step 3 (level 3 ^a)	Step 4 (level 4 ^a)	Step 5 (level 5)
How common is the problem?	Local and current random sample surveys (or censuses)	Systematic review of surveys that allow matching to local circumstances ^b	Local non-random sample ^b	Case-series ^b	N/A
Is this diagnostic or monitoring test accurate? (Diagnosis)	Systematic review of cross-sectional studies with consistently applied reference standard and blinding	Individual cross-sectional studies with consistently applied reference standard and blinding	Non-consecutive studies, or studies without consistently applied reference standards ^b	Case-control studies, or poor or non-independent reference standard ^b	Mechanism-based reasoning
What will happen if we do not add a therapy? (Prognosis)	Systematic review of inception cohort studies	Inception cohort studies	Cohort study or control arm of randomized trial ^a	Case-series or case-control studies, or poor-quality prognostic cohort study ^b	N/A
Does this intervention help? (Treatment benefits)	Systematic review of randomized trials or <i>n</i> -of-1 trials	Randomized trial or observational study with dramatic effect	Non-randomized controlled cohort/follow-up study ^b	Case-series, case-control studies or historically controlled studies ^b	Mechanism-based reasoning
What are the COMMON harms? (Treatment harms)	Systematic review of randomized trials, systematic review of nested case-control studies, <i>n</i> -of-1 trial with the patient you are raising the question about, or observational study with dramatic effect	Individual randomized trial or (exceptionally) observational study with dramatic effect	Non-randomized controlled cohort/follow-up study (post-marketing surveillance) provided there are sufficient numbers to rule out a common harm. (For long-term harms the duration of follow-up must be sufficient) ^b	Case-series, case-control, or historically controlled studies ^b	Mechanism-based reasoning
What are the RARE harms? (Treatment harms)	Systematic review of randomized trials or <i>n</i> -of-1 trial	Randomized trial or (exceptionally) observational study with dramatic effect			
Is this (early detection) test worthwhile? (Screening)	Systematic review of randomized trials	Randomized trial	Non-randomized controlled cohort/follow-up study ^b	Case-series, case-control, or historically controlled studies ^b	Mechanism-based reasoning

^aLevel may be graded down on the basis of study quality, imprecision, in directness (study PICO does not match questions PICO), because of inconsistency between studies, or because the absolute effect size is very small; Level may be graded up if there is a large or very large effect size.

^bAs always, a systematic review is generally better than an individual study.

TABLE 2 Definitions of actinic keratosis and field cancerization.

Definitions of AK and field cancerization	Consensus-based statement
GCP	AK is a precancerous lesion that may progress into invasive SCC. Actinic keratosis shall be used as the preferred term in clinical practice ^{8,9} An area of field cancerization is defined as an area of subclinical changes in the periphery of visible AKs that displays genetic changes similar to those found in AKs ^{11,12}
Expert consensus	Strength of recommendation: 100%

skin.¹⁴⁻¹⁶ UVB radiation can induce mutations and deregulation of tumour suppressor proteins such as p53, p16INK4a and PTEN that are considered a crucial molecular mechanism in the development of AK and cSCC.^{10,17,18} UV radiation and infections with human papillomaviruses (HPV) may act as cofactors in the development of AK, although the role of HPV is still controversial.¹⁹⁻²⁵ Immunosuppression increases the risk of cancers that are associated with viral infection. In particular, the risk of cSCC which has been associated with beta HPV infection is increased by more than 100-fold in immunosuppressed patients.²²⁻²⁴ In a systematic review, 58.5% of AKs were positive for beta HPV, 40.2% for gamma HPV and only a few were positive for alpha subtypes.²⁴ However, it has been found that T-cell immunity against commensal papillomaviruses suppresses skin cancer in immunocompetent hosts, and the loss of this immunity rather than the oncogenic effect of HPVs may contribute to causes the markedly increased risk of cSCC in immunosuppressed patients.²⁵

Development of AK towards cSCC

AKs may undergo spontaneous regression, remain stable or further progress to invasive malignancy. It has been suggested that invasive cSCC may develop in two ways: (1) by transformation of a clinically pre-existing individual AK or (2) de novo, from a subclinical UV-damaged single cell in a field of cancerization. The first way seems to occur in 0.1%–16% in clinically pre-existing AKs, based on the data about the risk of malignant transformation of a single actinic keratosis.²⁶ The second pathway is based on field changes which can be detected in about 80% of histopathologically examined cSCC.²⁷ A meta-analysis found progression rates of AKs to SCC varying from 0% to 0.075% per lesion-year, with a risk of up to 0.53% per lesion-year in patients with prior history of keratinocyte cancer (NMSC).²⁸ Rates of regression of single lesions ranged between 15% and 63% after 1 year, with a recurrence rate of 15%–53% after 1 year follow-up.²⁸

Epidemiology

Since AK are not included in cancer databases or population-based incidence rates and AKs are often not biopsied,

epidemiological data are scarce and often marred by numerous biases. Prevalence varies greatly across countries, depending on study setting, UV radiation level and patient characteristics.²⁹ In the UK, 15.4% of males and 5.9% of females have AK lesions, while in those older than 70 years, the prevalence increases to 34% of whites over 70 years.³⁰ In Australia, up to 60% of people over 40 years old have AK.³¹ In Spain, AK prevalence was observed in 28.6% of the population over 45 years, with higher rates in men than women.³² In Italy, AK prevalence was 27.4% and in Switzerland 25.3%.³³⁻³⁵ Higher rates in men than in women were also observed in all epidemiologic studies in Germany, the overall prevalence of AK was 2.66%, with rates higher in men than in women, and prevalence increasing with age, with the highest rates observed in the 61–70 age group.²⁸

Risk factors for AK

A meta-analysis, including mainly European studies, investigated risk factors in immunocompetent individuals.^{23,29} Factors associated with an increased risk of AK were male sex, age >45 years, fair skin type, light hair colour, light eye colour, freckles on face/arms, positive history of non-melanoma skin cancer (NMSC), sunburns in childhood and adulthood, severe sunburn, chronic occupational and/or recreational sun exposure, baldness, and use of potentially photosensitizing thiazide diuretics or other photosensitizing cardiac drugs. On the contrary, factors associated with a reduced risk of AK were sunscreen use and history of atopy. No association was found between patients' education level and the risk of AK, abnormal body mass index, alcohol consumption and smoking status. Sensitivity analysis yielded consistent results. *IRF4*, *MC1R* and *TYR* genes, that are involved in various kinds of human pigmentation traits as well as in skin cancers, were identified as significant risk factors for AK in the north-western European study population.³³ Chronically immunosuppressed patients especially organ transplant recipients (OTRs) have a higher risk for developing AK and SCC.³⁶ In OTRs, the prevalence of patients with AKs increases with longer duration of immunosuppression.³⁷ A recent study showed that the variability of AKs in a 12-month period was associated with an increased risk of SCC in OTRs.³⁸ In another study, presence of AK patches and their number, as well as the number of AKs and area affected by AKs, was predictive of SCC development in OTR.³⁹ Genetic skin diseases associated with impaired DNA repair mechanisms and disorders with a deficient melanin biosynthesis are associated with a higher risk for the development of AK.^{40,41}

CLINICAL AND NON-INVASIVE DIAGNOSIS OF AKs

Clinical features

AKs typically manifest as rough, scaly skin coloured to red light or dark brown patches, papules or plaques commonly located on chronically sun-damage body sites. The diameter

of AKs generally ranges from a few millimetres to several centimetres.⁴² The clinical features along with the typical anatomical site allow a correct clinical diagnosis in most cases, although the differential diagnosis with basal cell carcinoma (BCC) and inflammatory disorders may be sometimes challenging. Also, lichenoid keratosis (i.e. lichen-planus like keratosis) and Bowen disease have to be considered in differential diagnosis, particularly in solitary lesions. Clinical variants include pigmented, Bowenoid and lichenoid AK.⁴³ While the latter two are usually diagnosed on histopathologic examination, pigmented AK is commonly present in sun-damaged skin, and therefore, differential diagnosis may include lentigo maligna. The number and location of lesions, similar morphology using the comparative approach and rough surface on palpation represent important clues for the diagnosis of AK.^{44,45} Clinical signs suggesting progression to iSCC (iSCC) include lesion induration, bleeding, discomfort, pain and increase in thickness and diameter.⁴³ AKs seldom appear as a solitary lesion; indeed, often an entire region is affected. Individual AK lesions have been clinically graded based on their thickness using the Olsen classification system.⁴⁶ Grade 1 lesions are slightly palpable, more easily felt than seen, grade 2 lesions are moderately thick and easily seen and felt, and grade 3 lesions are very thick and hyperkeratotic. This severity index was combined with the counting of lesions in a limited area for the assessment of clinical trials. However, counting individual lesions is not reproducible even among experts.⁴⁷ Although the Olsen classification failed to reliably correlate with the histological severity of the lesions, it has been shown to be strongly correlated with the risk of cSCC development in a recent study.⁴⁸ Other clinical severity indexes have been proposed considering the entire area affected by AKs.⁴⁹⁻⁵¹ Additionally, a recent practice related approach classified AK based on the overall burden of disease into the following categories⁵²: (1) single AK (less than 5 AKs in a defined field), (2) multiple AKs (6+ lesions in a defined field), (3) field cancerization (6+ lesions associated with sun-damaged skin and hyperkeratosis) and (4) AKs associated with immunosuppression.

Dermatoscopy (Table 3)

Dermatoscopy improves the clinical diagnosis of AK and has been reported to achieve a diagnostic sensitivity and specificity of 98.7% and 95.0%, respectively. Depending on the clinical aspects, dermatoscopy reveals either a red network

TABLE 3 Clinical and dermatoscopic diagnosis of actinic keratosis.

Consensus-based statement	
Grade of recommendation: B	The diagnosis of actinic keratosis and field cancerization is made by clinical examination. Dermatoscopy can help in the differential diagnosis of actinic keratosis and other skin neoplasms
Level of evidence: 1	Strength of consensus: 100%

pattern (grade 1), a 'strawberry pattern', namely background erythema interrupted by white-coloured follicular openings that might be filled with keratin plugs (grade 2), or structureless white to yellow areas (grade 3).^{53,54} Dermatoscopy may help to differentiate solitary AK grade III (with structureless yellow and white colour and erythema with strawberry pattern, focally) and Bowen's disease (with coiled vessels). Moreover, dermatoscopy can aid in the assessment of treatment response and in the differential diagnosis of AK. In the cases of pigmented AK, dermatoscopy may help to rule out lentigo maligna^{44,55} based on the presence of enlarged white follicular openings, double lines between the hair follicles, background erythema and scaly surface in AKs. In AKs located on non-facial skin, the follicular openings are less predominant and dermatoscopy mainly reveals erythema and superficial scales. Dermatoscopy can also help to identify early signs of iSCC due to the presence of coiled/glomerular or polymorphous vessels and white circles, which are rarely observed in AK.⁵⁴

Confocal microscopy and optical coherence tomography (OCT) (Table 4)

In combination with clinical examination and dermatoscopy, reflectance confocal microscopy (RCM) and optical coherence tomography (OCT) can help in the differential diagnosis of AK and SCC, pigmented AK and lentigo maligna. The superficial orientation in the epidermis makes AK suitable for non-invasive imaging tools, but on the other hand, the presence of hyperkeratotic scale may impair image resolution and diagnostic accuracy. RCM and OCT have also been extensively applied to monitor treatment efficacy of AKs.⁵⁶⁻⁶⁰ The RCM terms that describe better diagnostic features of AK include hyperkeratosis, parakeratosis, scale and atypical honeycombed pattern, architectural disarray and targetoid cells.⁶¹⁻⁶³

Line-field confocal optical coherence tomography (LC-OCT)

LC-OCT in vertical and horizontal sections of the lesions have been used in to identify AKs criteria that include an outlined dermo-epidermal junction without broad strands.^{64,65} LC-OCT has also correlated with histological images to evaluate the proliferative pattern of AK that has been associated with resistant to treat AK and the risk of progression.⁶⁶

TABLE 4 Other non-invasive imaging for actinic keratosis.

Consensus-based statement	
GCP	Confocal microscopy, OCT and LC-OCT can help in the differential diagnosis of actinic keratosis and other skin neoplasms
	Strength of consensus: 100%

HISTOPATHOLOGIC DIAGNOSIS

Histopathologic confirmation

Histopathological confirmation is recommended to an equivocal lesions especially in the differential diagnosis of cutaneous SCC (cSCC) or BCC (Table 5). Also, for type III AK and bowenoid AK, differential diagnosis with Bowen's disease can be difficult. The presence of basal cells in palisades along the basement membrane and the dysplasia of the adnexal and follicular epithelium, which is present in BD and absent in AK, can help in differentiating these two entities.⁶⁷ A skin biopsy should be taken if one or more of the following clinical features are present which may indicate cSCC or other types of skin cancer: infiltration, induration, ulceration, pigmentation, rapid enlargement and pain.⁶⁸ A biopsy should also be considered if coiled, dotted, hairpin or polymorphous vessels and/or white circles or whitish homogeneous areas are detected on dermatoscopy or if invasion is suspected on RCM, OCT and LC-OCT. According to their clinico-pathological appearance, various types of AK have been described, including pigmented, atrophic, bowenoid, lichenoid, acantholytic and hyperkeratotic AKs. The Rowert–Hubert histological classification has been suggested to assess the severity degree of single AK lesions⁵²: (1) early in situ cSCC, type AK I corresponds to atypical keratinocytes in the basal and supra-basal layers (the lower third) of the epidermis; (2) early in situ cSCC, type AK II is constituted by atypical keratinocytes extending to the lower two-thirds of the epidermis; (3) in situ cSCC, type AK III consists of atypical keratinocytes extending to more than two-thirds of the full thickness of the epidermis. The classification was suggested to predict the risk of AK to progress to cSCC. However, in a recent study it was demonstrated that AK I are the most frequent lesions associated to cSCC (so-called differentiated pattern) and that Rowert–Hubert classification cannot predict the transformation of AKs.²⁷ Additional evidence suggests that hair follicles may contribute significantly to the development of deeply invasive SCC and that the depth of follicular extension in AK correlates with the depth of invasion of an associated iSCC.^{13,27} Based on these and other findings from the recent studies, the PRO classification of AKs was suggested, which is based on the histological growth pattern. The histological growth pattern of AKs appeared to be associated to treatment resistance and progression to invasive cSCC. Pro I (basal-growth pattern) corresponds to crowding of basal atypical keratinocytes; Pro II to budding of atypical keratinocytes into the upper

papillary dermis and forming round nests of atypical keratinocytes; Pro III (papillary sprouting) to spiky or filiform papillary elongation of atypical keratinocytes protruding into upper dermis and exceeding the thickness of the overlying epidermis.^{69,70} Interestingly, proliferative AKs are not correlated with Olsen grade or KIN criteria.

TREATMENT OF ACTINIC KERATOSES

Rationale for treatment

The most important reason for treatment of AK is to prevent the transformation to invasive cSCC.⁵² The risk of progression varies from 0.025% to 20% per year and is significantly higher in immunosuppressed patients, such as solid organ transplant recipients.⁷¹ Furthermore, if the patient has had previous cSCC in the field, the risk for developing the second cSCC is 40.7% at 5 years.⁷² As there is currently no way to accurately predict which lesion will develop into cSCC or when this might occur, treatment is recommended. Treatment of AK can be lesion-directed or field-directed. Lesion-directed treatments target individual AKs, whereas field-directed treatments have the advantage of treating multiple, widespread and subclinical AKs that may occur within a field of chronically sun-damaged skin, commonly referred to as field cancerization.⁷³ Field-directed treatments are nowadays the focus of AK treatment as most of them are convenient, can be self-administrated and most importantly they target subclinical damage. Weinstock et al.⁷⁴ found that field treatment with 5-fluorouracil (5-FU) reduced the risk of cSCC compared to placebo after 1 year in patients with severe AKs and a history of at least two cSCCs: 1% of patients treated with 5-FU developed a cSCC, compared to 4% in the placebo group. In another study, the total 4-year risk of developing cSCC in a field treated area of AK was 3.7%, but significantly increased to 20.9% in patients with Olsen grade III AK and to 33.5% in patients with Olsen grade II AK patients with an indication for retreatment.⁴⁸ Thus, for multiple severe AKs with a history of previous cSCC, field treatment and retreatments are highly recommended. For mild AKs (Olsen grade I), field treatment can also be recommended, but well-instructed self-examination can be considered.

Field-directed treatments are not suitable for all patients. The long duration of treatment can impact adherence, and they may cause unwanted cosmetic effects. In some patients, lesion-directed treatments are preferred, as they have the benefit of being performed under the supervision of a physician and are less time-consuming. Lesion-directed treatments commonly involve ablative procedures as surgery (shave, excision), cryosurgery/cryotherapy and laser therapy. Surgical treatments are usually reserved for AKs that are unresponsive to other treatments and in cases of uncertain diagnosis.⁷⁵

There is no standard treatment for AKs, and physicians should make decisions considering both lesion (number,

TABLE 5 Biopsy and histopathological examination.

Consensus-based statement	
GCP	Biopsy is not routinely required for the diagnosis of actinic keratosis
	Biopsy shall be done in clinically and/or dermatoscopically suspicious and/or treatment-refractory lesions
Strength of consensus: 100%	

location, histology) and patient characteristics (age, compliance, immune status).⁷⁶ Also, treatment decisions should be made in a patient–physician shared decision process (Table 6).

Surgical procedures (Table 7)

Curettage is the most frequently performed surgical procedure in AK management and particularly suitable for solitary lesions. According to a recent meta-analysis, combinations with destructive treatments such as electrodesiccation or cryosurgery are more effective than photodynamic therapy, 5-fluorouracil or imiquimod in treating in situ SCC or superficially invasive SCCs.⁷⁷ Moreover, curettage is a standard procedure established in photodynamic therapy (PDT) protocols to ablate superficial keratosis, above all in thick hyperkeratotic AK. Deeper shavings or scalpel excisions instead are preferred in suspicious lesions, in which histology of the entire specimen appears justified.⁷⁵ In AK, surgical treatments are usually limited to lesion-directed removal of single or isolated AKs. After primary field-directed treatment, any remaining AK may be effectively treated with a lesion-directed surgical approach.⁷⁸ Surgical interventions, in general, have the advantage to allow for histopathologic examination of the removed tissue specimen. Histology is particularly advised if AKs is refractory to standard therapy, in relapsing AKs, or in those suspicious of cSCCs (e.g. in thickening, painful or bleeding lesions, particularly in immunosuppressed patients).⁷⁹ The drawbacks of surgical techniques are that usually only single lesions will be removed, anaesthesia is needed, and permanent depigmentation or even scarring may develop.⁸⁰

TABLE 6 Indication for treatment of actinic keratosis.

Consensus-based statement	
Expert consensus	Treatment-decision should be made on a case-by-case basis considering patient-related factors and lesion characteristics. For patients with previous cSCC and/or immunosuppression treatment should be considered
Strength of consensus: 100%	

TABLE 7 Surgery and laser ablation for lesion-directed treatment of AK.

Consensus-based statement	
GCP	Curettage, shave or excisional biopsy can be offered for single or few hyperkeratotic lesions. Histological examination is strongly recommended in treatment-resistant cases and in lesions suspicious for iSCC. ⁸¹
Strength of consensus: 100%	

Cryotherapy (Table 8)

Cryosurgery, or cryotherapy, is a lesion-directed treatment, with a focus on treating a single or a limited number of AKs. This procedure is considered to be a standard initial first-line treatment in patients with a limited number of AKs,⁸¹ as it is easy to perform and time-efficient. By using low temperature (liquid nitrogen -196°C), cryotherapy targets and kills precancerous cells directly by inducing cell rupture due to osmotic shock and intracellular formation of ice crystals. In addition, it leads indirectly to a delayed cell termination process by inducing vascular necrosis due to thrombosis and a release of neo-antigens. To attain the effective temperature of at least -40°C on the edge of the lesion, the cycle of freezing and thawing should be repeated.⁸² Sensitive areas such as eyes should be protected.⁸³ AK I-II are subject to a single freeze–thaw cycle with a freezing time between 5 and 20 s.⁸⁴ Two freeze–thaw cycles of 10 s each are indicated for large and hypertrophic lesions.⁸⁵ Prior removal of hyperkeratotic scales is recommended, either by gentle curettage or by application of urea or salicylic acid containing keratolytic agents 2 weeks before cryosurgery.⁸³ Cure rates of cryotherapy as single treatment for AK range from 39% to 83%.⁸⁶ The efficacy depends on the experience of the dermatologist and the protocol used.⁸⁷ Combination of cryosurgery with a topical intervention may be more effective than cryosurgery alone in patients with multiple AKs and field cancerization.⁸⁸

Laser ablation (Table 9)

AK can be treated with laser therapy, either alone or in combination with other treatments like PDT. The most

TABLE 8 Cryosurgery.

Consensus-based statement	
Grade of recommendation: A	Cryosurgery shall be offered as a first-line standard treatment for solitary AK ^{84,85} Cryosurgery in combination with curettage and topical treatments shall be offered in multiple AKs and field cancerization. ^{84,89}
Level of evidence: 1	Systematic review and meta-analysis, ^{84,89} prospective multicentre study ⁹⁰
Strength of consensus: 100%	

TABLE 9 Laser ablation for AKs.

Evidence-based statement	
Grade of recommendation: B	Ablative laser treatment should be offered as one of the options for single or multiple AKs, but it is not superior to cryotherapy or 5-FU treatment.
Level of evidence: 2	Single-centre randomized controlled trials ^{91,92}
Strength of consensus: 100%	

commonly used lasers for ablative treatment in AKs are the CO₂ and Er:YAG lasers, which remove the epidermis and superficial dermis to stimulate re-epithelialization. However, traditional laser treatment can have side effects such as hypopigmentation and scarring, as well as immediate side effects like erythema, oedema, itching, hyperpigmentation and scaling, which usually resolve within 2 weeks but may take longer to heal. Ablative laser treatment appears to be more effective than fractional laser treatment. There are only two randomized controlled trials (RCTs) comparing it to 5-FU cream.⁸⁹⁻⁹¹ Hantash et al. compared CO₂ laser with 5-FU applied twice daily for 3 weeks with no significant difference while Ostertag et al. did find a significant difference in favour of the Er:YAG laser in comparison with 5-FU treatment twice daily for 4–7 weeks. However, after 12 months post-treatment, there was no difference in efficacy, whereas more side effects were noted in the Er:YAG treated group.^{89,90} CO₂ laser was compared to cryosurgery in a single-centre RCT including 200 patients.⁹² In both groups, the cosmetic outcome was good. Complete responses at 3 months were, respectively, 65.3% and 71.1%, respectively, in the laser and cryotherapy groups, but decreased to 14% and 53% at 1 year. Therefore, laser may offer only few advantages over classical and less expensive treatments. No comparative trials are available comparing laser with PDT as a monotherapy. However, fractional laser has been used to improve PDT treatment for AK. It is believed that by creating micro-channels in the skin, the photosensitizer can be delivered deeper, thereby increasing the effect of PDT. Seven RCTs were included in a review where conventional PDT was compared with laser-assisted PDT, which was more effective in short-term clearance rate and not more painful than conventional PDT as a monotherapy.⁹³

Topical agents

5-FU (5%, 4%, 0.5% with or without 10% salicylic acid, 5-FU with calcipotriene) (Table 10)

The fluoropyrimidine 5-fluorouracil (5-FU) is an anti-metabolite drug exerting its anticancer effects through inhibition of thymidylate synthase and incorporation of

its metabolites into RNA and DNA. The benefits of 5-FU treatment for AK were assessed based on five studies with moderate-to-high quality efficacy, four studies with 5% 5-FU once daily and one with 5% 5-FU twice daily.⁹⁴⁻⁹⁶ The largest placebo-controlled randomized trial (VAKCC trial) showed field treatment of AKs on the face with 5% 5-FU, twice daily for 4 weeks, to be more effective than placebo for complete AK clearance at 6 months (38% vs. 17%; $p < 0.01$).⁹⁴ Two placebo-controlled randomized clinical trials evaluating 0.5% 5-FU cream suggested the low concentration of 5-FU to be more effective than placebo in reduction from baseline of AK lesion counts and lesion clearance.^{95,96} The main adverse event, often the primary reason for discontinuation of the treatment with 5-FU, remains local irritation. The number of AK lesions at baseline may predict the severity of local skin reactions.⁹⁷ New formulation of 4% fluorouracil in aqueous cream once daily was compared with twice daily treatment with 5%-FU in a double-blind multicentre study involving 841 subjects. It revealed similar efficacy, but better tolerability of the 4% formulation (30% vs. 60% application site skin reaction). Field treatment of face and scalp area $< 25 \text{ cm}^2$, with 0.5% 5-FU plus 10% salicylic acid solution once daily for 12 weeks led to higher complete clearance rates in 188 subjects in a randomized, vehicle-controlled phase III trial (49.5% vs. 18.2%).⁹⁸ Combination of calcipotriol and 5-FU is an emerging combination recently evaluated by a systematic review of the literature, including studies that assessed treatment of AK and prevention of cSCC.⁹⁹ A secondary exploratory analysis of a previous randomized trial investigated treatment with 0.005% calcipotriol ointment plus 5% 5-FU cream versus baseline plus 5% 5-FU cream (control) twice daily for 4 days in patients with 4–10 AKs in a 25 cm² contiguous area of the face, scalp and upper extremities. It showed a significantly higher complete (62% vs. 8%, $p < 0.0001$) and partial (82% vs. 11%, $p < 0.0001$) AK clearance at all sites than control, also for facial hypertrophic AKs (54.0% vs. 14.7%, $p = 0.002$).¹⁰⁰

Imiquimod 5% and 3.75% cream (Table 11)

Imiquimod is a toll-like receptor-7 agonist that acts as a topical immune response modifier that stimulates the production and release of cytokines, such as tumour necrosis factor- α , interferon- γ , interferon- α and interleukin-12. It plays an important role in the modulation of gene

TABLE 10 5-fluorouracil (5-FU).

	Evidence-based statement
Grade of recommendation: A	Topical 5-fluorouracil shall be offered for the treatment of single or multiple AK and field cancerization. Available are the following 5-FU formulations: 5% 5-FU cream, 4% fluorouracil in aqueous cream, 0.5% fluorouracil in salicylic acid 10% solution, 5% fluorouracil plus calcipotriol 0.005% cream ^{48,94,101}
Level of evidence: 1	Systemic review and meta-analysis Randomized controlled trials ^{48,94,101}
	Strength of consensus: 100%

TABLE 11 Imiquimod.

	Evidence-based statement
Grade of recommendation: B	5% or 3.75% imiquimod should be offered for the treatment of single or multiple AKs and field cancerization treatment. ^{68,91,98,99,100}
Level of evidence: 1–2	Randomized controlled trials ^{68,91,98,99,100}
	Strength of consensus: 100%

expression that regulates macrophages, dendritic cells, cytotoxic T-cells and natural killer cells and has indirect antiviral and antitumoral potency.^{48,101,102} The best candidates for imiquimod treatment are patients with multiple non-hyperkeratotic, non-hypertrophic, palpable AK located on the face and the scalp along with clinical evidence of field cancerization. Other anatomic locations can also be treated with the same treatment schedules, but the clinical outcomes have not been evaluated extensively. Patients taking immunosuppressants or transplant patients should use imiquimod with caution. Treatment with imiquimod is not recommended during summer period.⁷⁵ The 5% concentration is sufficient to cover a skin area of up to 25 cm² of the face and scalp on three times a week schedule over a period of 4 weeks, followed by an additional cycle if partial clearance is obtained. The maximum recommended duration of treatment is 8 weeks. The 3.75% concentration has been approved for the treatment of larger surface area of up to 200 cm². It is applied once daily for two cycles of 2 weeks each, separated by 2-week rest intervals. Overall, imiquimod has a clearance rate ranging from 56.3% for 5% concentration for 4 weeks to 63.3% for 5% concentration for 16 weeks. The 3.75% concentration is associated with a lower clearance rate as two 2-week cycles separated by a 2-week rest resulted in complete clearance rate of 35.6%, while the median percentage of lesion reduction was 81.8% which is comparable to the efficacy of 5% imiquimod.^{103,104} Recurrence rates at 12 months for patients who achieved complete clearance at 2–3 months were 27%–39%.¹⁰⁵ Erythema, crusting, erosions, ulceration and oedema are common local inflammatory reactions that may require increased spacing between applications. In addition to local skin reactions, imiquimod may also produce systemic symptoms such as fever, chills, myalgia and malaise.

Resiquimod

Resiquimod is a TLR7/8 agonist that activates dendritic cells and promotes cytokine release. It is available in four concentrations, with the greatest efficacy observed with application three times weekly for 4 weeks. In a phase II study, higher doses were associated with high rates of adverse events and discontinuation.¹⁰⁶ Complete clinical clearance was obtained in 56%–85% of patients in a large study of 217 patients, with maximal efficacy among patients receiving the 0.03% concentration.¹⁰⁷ From the perspectives of safety and tolerability, the lower concentration and shorter duration were preferable, but there was no significant histological difference from placebo in regimens with fewer gel applications. Further studies are needed to investigate efficacy, safety and tolerability of resiquimod.

Diclofenac (Table 12)

Diclofenac is a nonsteroidal anti-inflammatory drug which acts by inhibition of cyclooxygenase-2 enzyme, thereby

TABLE 12 Diclofenac.

Evidence-based statement	
Grade of recommendation: A	3% diclofenac in 2.5% sodium hyaluronate is less effective than other treatments of single or multiple AKs and field cancerization treatment
Level of evidence: 1	Randomized placebo-controlled trials, ^{110–113} meta-analysis, ¹²⁰ open label single arm trial, ¹¹⁰ trials with active comparator arm ^{111–114}
Strength of consensus: 100%	

causing decreased synthesis of prostaglandin E2 synthesis, and exerting anti-inflammatory, anti-angiogenic and pro-apoptotic effects.^{108,109} Diclofenac 3% gel in 2.5% sodium hyaluronate is approved for clustered AK and field cancerization treatment of AK, at a therapeutic regimen of twice-daily application for 60–90 days. Several studies have evaluated the efficacy and safety of diclofenac 3% gel with sodium hyaluronate in patients with AKs.^{110–113} One study reported a complete clearance response of 41% for patients treated with diclofenac 3% gel twice daily for 90 days.¹¹⁴ Two RCTs comparing diclofenac 3% gel with imiquimod 5% cream did not show a statistically significant difference in efficacy. However, after 24 months, imiquimod had a higher complete clearance rate.¹¹⁵ Additionally, diclofenac 3% gel showed lower lesion complete remission rates compared to methyl-aminolevulinate MAL-PDT for the treatment of multiple AKs on the face and scalp.¹¹⁶ Systematic literature review and network meta-analysis evaluated comparative efficacy and acceptability of different AKs treatment strategies, assessed at least 1 month after end of treatment and within 1-year post-treatment.¹⁰³ The estimated absolute clearance rate for diclofenac 3% gel was 24.7% (95% CI: 12.4–37.0), with diclofenac being superior to placebo only, and the least effective among the treatment strategies (ALA- and MAL-PDT, 5-FU, imiquimod, ingenol mebutate and cryotherapy) included in the study. Another meta-analysis reviewed efficacy and tolerability of different AKs intervention from post-marketing surveillance trials.¹¹⁷ Imiquimod 5% cream and ingenol mebutate 0.015% gel were both more effective compared to diclofenac 3% gel as per patient complete clearance rate in 2 RCTs [(RR: 1.47; 95% CI: 1.19–1.81); (RR: 1.92; 95% CI: 1.48–2.50)].^{118,119} The recurrence rate was also significantly higher for diclofenac 3% gel compared to imiquimod 5% cream (RR: 1.10; 95% CI: 1.02–1.8).

Tirbanibulin (Table 13)

Tirbanibulin is a dual small molecule inhibitor that inhibits tubulin polymerization and indirectly intracellular protein tyrosine kinase Src. Increased Src activity has been observed in both primary tumour growth and metastasis.¹²⁰ As Src is increasingly expressed in AK and

TABLE 13 Tirbanibulin.

Evidence-based statement	
Grade of recommendation: B	Tirbanibulin 1% ointment should be offered for the treatment of single or multiple AKs and field cancerization treatment of the face and scalp
Level of evidence: 1	Randomized placebo-controlled trials ¹²²
	Strength of consensus: 100%

appears to play a role in progression to cSCC,¹²⁰ the efficacy of topical therapy with tirbanibulin in AK has been investigated. An open-label phase II trial was initially conducted in the USA in 168 patients with 4–8 AK over an area of 25 cm² on the face or scalp. Eight weeks after starting treatment with tirbanibulin ointment 1%, the complete patient-related AK clearance rate (100%) was higher in the 5-day treatment cohort (*n* = 84) than in the 3-day treatment cohort (43% vs. 32%).¹²¹ Local skin reactions were mild and mostly included erythema, scaling, crusting and swelling, which resolved quickly. Side effects were rare and mostly mild, including transient itching, tenderness and pain. Based on the results of the phase II study, two identical, multicentre, double-blind, vehicle-controlled trials were conducted. A Phase III trial of the 1% ointment was initiated in a total of 702 patients with AK on the face and scalp, which confirmed the efficacy and safety of tirbanibulin 1% ointment compared to vehicle. The participants received tirbanibulin ointment 1% or vehicle (1:1), which was to be self-applied once daily for 5 consecutive days. After 57 days, the complete (100%) and partial (≥75%) AK clearance rate was significantly higher in both studies in the patients who received tirbanibulin (tirbanibulin vs. vehicle, complete clearance rates: 44%–54% vs. 5%–16%; partial clearance rates: 68%–76% vs. 11%–16%). After 1 year, recurrence occurred in 124 of the 174 (71.26%) patients treated with tirbanibulin who previously had a complete response. The most common local reactions to tirbanibulin were erythema in 91% of patients and scaling in 82%. Most treatment-related adverse events were mild to moderate. The patient-related healing rates achieved with tirbanibulin in the pivotal study are comparable with already approved topical agents. Tirbanibulin was approved for the topical treatment of AK on the face or scalp in adults in the EU in July 2021.

Comparison of efficacy and adverse events

Efficacy and safety of different AK treatment options were compared in several studies. In 2019, Jansen et al. published¹⁰² a prospective randomized trial conducted in four Dutch hospitals. Patients with a clinical diagnosis of five or more AKs lesions on the head, involving one continuous area of 25–100 cm², were enrolled. A total of 624 patients were included, and 5% 5-FU cream, 5% imiquimod cream, MAL-PDT or 0.015% ingenol mebutate gel were randomly

assigned. The primary outcome was the proportion of patients with a reduction of 75% or more in the number of AK lesions from baseline to 12 months after the end of treatment. At 12 months after the end of treatment, the cumulative probability of remaining free from treatment failure was significantly higher among patients who received 5-FU (74.7%; 95% confidence interval [CI], 66.8–81.0) compared with those who received imiquimod (53.9%; 95% CI, 45.4–61.6), MAL-PDT (37.7%; 95% CI, 30.0–45.3) or ingenol mebutate (28.9%; 95% CI, 21.8–36.3). As compared with 5-FU, the hazard ratio for treatment failure was 2.03 (95% CI, 1.36–3.04) with imiquimod, 2.73 (95% CI, 1.87–3.99) with MAL-PDT, and 3.33 (95% CI, 2.29–4.85) with ingenol mebutate (*p* ≤ 0.001 for all comparisons).¹⁰² A secondary analysis of this trial has been recently published,⁴⁸ evaluating the risk of invasive cSCC in a long-term follow-up. Twenty-six invasive cSCC in the target area were diagnosed during follow-up. The total 4-year risk of developing cSCC in a previously treated area of AK was 3.7% (95% CI, 2.4–5.7), varying from 2.2% (95% CI, 0.7–6.6) in patients treated with fluorouracil to 5.8% (95% CI, 2.9–11.3) in patients treated with imiquimod. The risk was 20.9% (95% CI, 10.8–38.1) in patients with severe AK (Olsen grade III), and as high as 33.5% (95% CI, 18.2–56.3) in those patients with severe AK who needed additional treatment. Cheng et al.¹²² recently published a retrospective cohort study to analyse the time to invasive cSCC development after treatment with 5-FU, imiquimod or ALA-PDT beginning 1-year post-treatment. No significant difference in the rate of cSCC development was identified in patients treated with 5-FU compared with imiquimod (0.99; 95% CI, 0.90–1.08) but PDT-ALA was worse than 5-FU (1.27; 95% CI, 1.19–1.36) and imiquimod (HR, 1.29; 95% CI, 1.17–1.43). However, this study is limited by its non-randomized, retrospective design. Finally, Heppt et al.¹²³ conducted a systematic review comparing efficacy of treatments for face and scalp AKs, comprising the 5-day tirbanibulin 1% ointment. The review included 46 studies to inform a Bayesian network meta-analysis of complete clearance against topical placebo or vehicle. The network meta-analysis revealed the lowest odds ratios (with 95% confidence intervals) for diclofenac 3% (2.9, 95% CI 1.9–4.3) and highest for 5%-fluorouracil (35.0, 95% CI 10.2–164.4)^{123,124} (Table 14).

Comparison of adverse events

Most research and guidelines focus on the efficacy of topical interventions while safety and tolerability considerations are less well documented, although they are an integral part of shared decision-making. A standardized and uniform classification of adverse drug reactions in the treatment of AK has not yet been established. Topical therapies differ in their safety profile.¹²⁵ Most treatment options are associated with local adverse events (AE) that are transient in most of the cases. Diclofenac has a very good local tolerability, and the most frequent AEs are mild erythema at

TABLE 14 Review of efficacy and tolerability of actinic keratosis treatments.

Topical agent	Regimen	Localization	Local intervention (L) or field cancerization treatment (F)	Maximum treatable area	Efficacy	Ranking of long-term patient/lesion-specific clearance rates ranking based on network meta-analysis (RR 95% CI) ^a	Provisional grading of application site reactions ^b	Systemic side effects	Ranking of efficacy based on network meta-analysis (OR, 95% CI) ^c
5% 5-FU	Twice daily 4 weeks	Face, scalp neck, extremities	F	500 cm ²	47–94% lesions 38–96% patients	2.80 (0.99–7.86) patient 1.59 (0.82–3.09) lesion	+++	Rarely myelosuppression	35.0 (10.2–164.4)
0.5% 5-FU + 10 salicylic acid%	Once daily 4 weeks	Face, scalp neck, extremities	F + L	25 cm ²	39.4%–98.7% lesions 55.4% patients	NA (patient) 0.92 (0.44–1.93) lesion	++	None	7.6 (4.6–13.5)
4% 5-FU	Once daily 4 weeks	Face and scalp	F	None	80.5% patients	NA (patient) NA (lesion)	+++ (better than 5% 5FU)	Rarely myelosuppression	30.3 (9.1–144.7)
5% imiquimod	3 times a week 4 weeks, for residual lesion another 4 weeks	Face and scalp	F	1 sachet per day	45.1%–93.6% lesions 24%–85% patients	5.98, 2.26–15.84 patient 2.83 (1.00–8.02) lesion	++	Rarely flu-like symptoms	17.9 (9.1–36.6)
3.75% imiquimod	Once daily 2 weeks, 2 weeks break, than again once daily 2 weeks	Face and scalp	F	None	34%–81.8% lesions	0.80 (0.18–3.51) patient NA (lesion)	++	Rarely flu-like symptoms	8.5 (3.5–22.4)
1% tirbanibulin	Once daily 5 days	Face and scalp	F	25 cm ²	44%–54% lesions 76%–82% patients	NA (patient) NA (lesion)	+	None	11.1% (6.2–20.9)
3% diclofenac	Twice daily 60–90 days	Face and scalp	F	200 cm ² or 8 g/day	51.8%–81% lesions 27%–50% patients	1.13 (0.13–9.89) 0.75 (0.38–1.46)	+	None	2.9 (1.9–4.3)

^aAdapted from Steeb et al.¹³⁹^bAdapted from Koch et al.¹²⁵^cAdapted from Heppt et al.¹²³

the site of application followed by scaling, oedema and erosions.^{111,126} Allergic contact dermatitis has been reported in 2.1% of patients.¹¹⁹ Moderate to severe local skin reactions characterize treatment with 5-FU 5%/4% and imiquimod 5%/3.75%. Erythema, itching, crusts, scaling, erosion, pain, swelling and vesicles/bullae often accompany treatment with 5% 5-FU.¹⁰² 4% 5-FU demonstrated a superior tolerability profile compared to 5% 5-FU.¹²⁷ Most AE reported for the lower 0.5% concentration of 5-FU in combination with 10% salicylic acid are mild or moderate.¹²⁸ Erythema, scabbing or crusting, flaking and erosions have been reported frequently with imiquimod 5%/3.75%.^{129,130} The tolerability profile of tirbanibulin has been remarkably good in clinical trials.¹²¹ Most AEs were local and estimated as mild to moderate. Potentially irreversible local side effects might occur, such as persistent hyperpigmentation or scarring after strong local reactions. In a RCT comparing four different field-directed treatments, there were generally no substantial differences in adverse events between the investigated treatments (5-FU, imiquimod, PDT and ingenol mebutate), except for the fact that PDT led to significantly more pain during treatment.⁴⁸ Systemic side effects are rare and are mainly observed with 5-FU (myelosuppression) and imiquimod (flu-like symptoms) and can lead to premature treatment discontinuation.¹²⁵ In most cases, however, they are mild and resolve completely after treatment discontinuation. Diclofenac¹³¹ and 5-FU¹³² appeared safe regarding graft function in OTRs. No allograft rejections or deterioration of allograft function were reported for imiquimod 5% in a multicentre study including 43 OTRs,¹³³ although one patient with a third renal transplant who developed a severe vascular rejection after the use of imiquimod 5% cream was described.¹³⁴ Safety concerns focused mainly on local side effects and less frequently about the severity of long-term or systemic adverse events. The rate of treatment-associated keratinocyte cancers and irreversible adverse drug events warrant investigation in post-marketing surveillance trials with long-term follow-up. In Table 14, comparison of efficacy and safety of different treatment options are adapted from different systemic review and network meta-analyses studies.

Photodynamic therapy (Table 15)

Photosensitizing agents

Photodynamic therapy (PDT) holds a special position in the treatment landscape for AK as it consists of a combination of a topical agent with a procedural method. The principle of PDT relies on the application of light-sensitizing substances ('photosensitizers') such as aminolaevulinate (ALA) or its ester bond methyl-aminolaevulinate (MAL). ALA itself is a precursor (prodrug) of endogenous haem synthesis, which is converted in the skin to photoactive porphyrins such as protoporphyrin IX (PpIX). The photosensitizers accumulate selectively in lesional keratinocytes and are subsequently

TABLE 15 Conventional and daylight photodynamic therapy.

	Evidence-based statement
Grade of recommendation: A	Conventional or daylight photodynamic therapy with 5-aminolaevulinic acid and/or methyl aminolaevulinate should be offered for the treatment of single or multiple AK and field cancerization.
Level of evidence: 1–2	Randomized controlled trials, ^{138,144} systematic review and network meta-analysis ^{142–146}
Strength of consensus: 100%	

activated by illumination with light of a suitable wavelength. In this process, photochemical and photophysical processes generate reactive oxygen species, specifically inducing cell death in atypic keratinocytes. In the USA, a 20% ALA solution is approved in combination with illumination by blue light while in Europe, a nanoemulsion equivalent to a 10% ALA preparation is widely available (BF-200 ALA).^{135,136} In contrast to MAL and conventional ALA formulations, BF-200 ALA is also approved for the treatment of mild to moderate AK on the trunk, extremities and neck. Furthermore, a self-adhesive ALA patch is available enabling direct and highly standardized application without any prior lesion preparation.^{135,136}

Conventional PDT

Multiple PDT regimens using distinct photosensitizers, varying incubation times, illumination protocols and light sources have been established in the last two decades, making PDT a rather heterogeneous intervention. For a more detailed overview of treatment delivery and illumination protocols, we refer to the European Dermatology Forum guidelines on topical PDT^{135,136} and other reviews.¹³⁷ A large body of evidence demonstrates high clearance rates for both photosensitizers for single and multiple lesions, as well as for field cancerization. The clearance rates in randomized controlled trials vary from 50%–94.3% and 31.4%–90.3% for conventional ALA- and MAL-PDT, respectively.³ In a head-to-head trial, ALA-PDT showed slightly higher clearance rates than MAL-PDT.¹³⁸ However, the efficacy may vary according to pre-treatment, light sources and treatment protocols. A recent network meta-analysis suggested the most favourable long-term lesion clearance rates for conventional PDT with BF-200 ALA compared to other interventions, underlining the high efficacy of conventional PDT.¹³⁹ Local skin reactions in the treated areas are almost mandatory and include erythema, crusting, oozing, formation of sterile pustules or scaling. Rare adverse events may include amnestic episodes, contact allergies and post-procedure hyperpigmentation. Painful sensation during illumination is often the limiting factor in the delivery of PDT, requiring pain

control measures such as patient distraction, cooling with cold air or locally infiltrative anaesthesia with nerve blocks.

Daylight-mediated PDT ('daylight' PDT)

Illumination with natural or simulated daylight has been established in recent years as an almost painless alternative to conventional PDT. Daylight continuously activates PpIX, thereby avoiding high peaks of PpIX and minimizing illumination-related pain. ALA or MAL is applied as a thin layer over a large area of the face and scalp after the application of chemical sunscreen and gentle curettage of keratotic lesions. Patients are subsequently exposed to natural daylight for 2 h under suitable weather conditions (March–October, outdoor temperature >10°C, cloudless to overcast sky, no rain). Two pivotal phase III trials conducted in Australia and Europe compared daylight PDT with conventional PDT with MAL in a multicentre, investigator-blinded, controlled intraindividual trial as a non-inferiority analysis.^{140,141} At 12 weeks after a single PDT cycle, the lesion complete clearance rate was not inferior to conventional MAL-PDT (89% vs. 93% in Australia, 70% vs. 74% in Europe), but daylight PDT was significantly less painful in both trials. Dirschka et al.¹⁴² compared daylight PDT with BF-200 ALA versus MAL in a large-scale, multicentre, split-face non-inferiority study. The patient-specific complete clearance rate was 42.9% for ALA versus 38.8% for MAL. The lesion-specific clearance rates were similar for both photosensitizers (79.8% for ALA, 76.5% for MAL). The study reported a significantly higher recurrence rate for MAL (31.6%) compared with ALA (19.9%) after 12 months of follow-up. A similar comparison was performed by Räsänen et al. in 2019 in a multicentre double-blind non-sponsored trial. Both photosensitizers were applied to one side of the face. The lesion-specific clearance rate was 79.7% for ALA versus 73.5% for MAL. The complete clearance rates were 27.5% for both photosensitizers.¹⁴³ From these data, we conclude that ALA and MAL are equally effective when used for daylight PDT. The advantages of daylight PDT over conventional PDT include minimal to no pain, the possibility to treat large fields and the lack of a requirement for artificial light sources.

Field cancerization treatment (Table 16)

Although an exact definition has not yet been agreed upon, the concept of field cancerization is increasingly being acknowledged and considered for treatment selection and prevention of AK. Agents approved for large-field applications such as 5-fluorouracil 5%, 5-fluorouracil 4%, PDT or imiquimod 3.75% are preferable for multiple thin lesions as the field is commonly ill-defined and expands over a larger area. Studies employing RCM provided evidence that subclinical changes are efficiently resolved by topical treatments.¹⁴⁴ Diclofenac sodium is also suitable for large fields but may be less effective for lesion clearance. Patients with multiple hyperkeratotic

TABLE 16 Field cancerization treatment.

Evidence-based statement	
Grade of recommendation: B	5-fluorouracil 5%, 5-fluorouracil 4%, PDT, imiquimod 5% and 3.75%, diclofenac 3% in 2.5% hyaluronic acid gel and tirbanibulin 1% should be offered for field cancerization treatment. ^{71,93,100,101,102,143}
Level of evidence: 1	Randomized placebo-controlled trials ^{93,100,101,102,143}
Strength of consensus: 100%	

TABLE 17 Combination treatment.

Evidence-based statement	
Grade of recommendation: B	Combined treatments should be offered to patients with multiple and/or hyperkeratotic lesions, large treatment fields and treatment resistance to monotherapies.
Level of evidence: 1	Randomized controlled trials, ^{84,90,146} systematic review and meta-analysis. ¹⁴⁹
Strength of consensus: 100%	

lesions may benefit from a sequential use of field- and lesion-directed treatment (see Combination treatment).

Combination treatments: Should it be the rule? (Table 17)

A multitude of interventions for the treatment of AK exists which are often combined either simultaneously or sequentially. The rationale for an upfront combination approach is to take advantage of the strengths and distinct mechanisms of action of different interventions, thereby achieving synergistic effects.¹⁴⁵ The application of a primarily field-directed approach can be focally complemented by lesion-directed modalities such as cryosurgery, laser ablation, or shave excision for hyperkeratotic or treatment-refractory lesions. Pre-treatment with topical agents may even unmask and reveal subclinical lesions within a treatment field which can subsequently be targeted with a lesion-directed treatment. Conversely, following a primarily field-directed therapy, subclinical lesions and field cancerization can be managed by a field-directed treatment which prevents the progression of subclinical lesions to become clinically visible AK.³ Recent analyses have shown that treatment combinations result in significantly higher lesion clearance compared to respective monotherapies. In particular, such efficacy benefits were demonstrated for laser-assisted conventional PDT,⁹³ PDT combined with pre-treatment by microneedling,¹⁴⁶ cryosurgery combined with topical agents⁸⁸ and 0.5% 5-FU followed

by cryosurgery.^{147,148} Furthermore, there is evidence that combining several field-directed treatments can augment their efficacy. A systematic review identified 10 RCTs with a total sample size of $n=277$.¹⁴⁹ Four studies investigated a combination of PDT with imiquimod cream, three with 5-FU and one each with ingenol mebutate, tazarotene gel and calcipotriol ointment. Patients treated with a combination had higher rates of complete and partial lesion clearance,¹⁴⁹ implying that treatment combinations can achieve higher clearance rates compared to monotherapies. Nevertheless, a combination of interventions should always be discussed on a case-by-case basis, and monotherapies will in many cases be sufficient to achieve lesion clearance and disease control. Patients with simultaneous discrete and hyperkeratotic lesions, large treatment fields and treatment resistance to monotherapies may benefit from combinations.

Treatment of AK in immunocompromised patients (Table 18)

Compared to immunocompetent individuals, chronically immunosuppressed patients show significantly increased morbidity and mortality due to the development of iSCC.¹⁵⁰ Important mainstays for secondary prevention are early modification of the immunosuppressive regimens by eliminating of azathioprine and switching to mTOR inhibitor-containing immunosuppression, photoprotection and chemoprevention with retinoids. Although in immunocompetent individuals, dietary supplementation with oral nicotinamide (vitamin B3) was found to be effective in prevention of cSCC, in a recent trial it was found

that it does not reduce the number of new keratinocyte cancers in OTRs.¹⁵¹ For clinically manifest AK, the evidence for active interventions is surprisingly low.¹⁵² A systematic review identified only eight small, randomized trials with 242 OTR, 6 out of 8 which evaluated PDT (but only 2 imiquimod and one each for 5-fluorouracil, diclofenac gel and cryotherapy).¹⁵² Here, field-directed treatments showed higher clearance rates than lesion-directed treatments, underlining the paramount importance of treating the entire field in this high-risk population (see Field-directed treatments). Conventional MAL-PDT showed the most favourable clearance rates (40%–76.4%), followed by imiquimod (27.5%–62.1%), diclofenac sodium (41%) and 5-fluorouracil 5% (11%), while ablative laser treatment showed the lowest lesion clearance (5%–31%). Importantly, there were no graft rejections under topical therapies.¹⁵² In a recent small RCT, treatment with sunscreen, 5-FU and imiquimod was used for prevention of cSCC in OTR, and treatment with 5-FU was found to be superior in AK clearance as a surrogate biomarker of cSCC prevention.¹⁵³ Immunosuppressed patients commonly show multiple and metachronous evolving lesions over large fields. Thus, purely lesion-directed treatments are usually not sufficient to achieve disease control. Due to a more aggressive disease course and a higher portion of treatment-resistant lesions, repeated treatment is often necessary. The threshold to biopsy lesions to rule out progression to cSCC should be lower than in immunocompetent individuals. Most evidence for the subgroup of immunosuppressed patients is available for PDT, imiquimod and diclofenac sodium.³ Dragieva et al. evaluated conventional MAL-PDT in 14 renal and 3 cardiac transplant recipients. The lesion clearance rate assessed 16 weeks after two PDT cycles was 90.3% in the MAL-treated group versus 0% in the vehicle group. Complete response of the entire treatment field was achieved in 75.4% and partial response (>75% of all lesions per field cleared) in 94.1%.¹⁵⁴ A European, multicentre, double-blind, interindividual randomized trial evaluated imiquimod 5% cream versus placebo in 30 kidney, 4 liver and 9 heart transplant patients. The complete response rate was 62.1% for imiquimod (100% in the liver transplant group, 65% in the kidney transplant group and 42.9% in the heart transplant group) versus 0% for placebo.¹⁵⁵ Importantly, anecdotally reported graft rejection or deterioration of the graft function was not observed in this trial.^{133,134,155} Adverse events of imiquimod were local site application reactions, fatigue, headache, diarrhoea, nausea, rash, unspecified skin reactions and leukopenia. Togsverd-Bo et al.¹⁵⁶ investigated MAL-PDT and imiquimod in 35 OTR. PDT resulted in higher lesion clearance at a 3-month follow-up albeit at the cost of more intense local skin reactions. The median patient-specific complete clearance was 78% for PDT versus 61% for imiquimod. Diclofenac sodium was investigated in a double-blind, placebo-controlled, randomized trial in 32 OTR (18 renal, 8 cardiac and 6 liver transplant recipients).¹³¹ The complete clearance of all lesions in the treated field was 41%

TABLE 18 Treatment of AK in immunocompromised patients.

	Evidence-based statement
Grade of recommendation: B	Conventional PDT with illumination by a red-light source, 5-FU 5% cream and diclofenac sodium 3% in hyaluronic acid gel 2.5% should be offered to immunocompromised patients with single and multiple AKs and field cancerization
Grade of recommendation: C	Imiquimod 5% or 3.75% cream may be offered for treatment of single and multiple AKs and field cancerization in selected immunocompromised patients Daylight PDT may be offered to immunocompromised patients with single and multiple AKs and field cancerization Field-directed treatments have higher clearance rates than lesion-directed treatments in this high-risk population
Level of evidence: 2–3	Randomized controlled trials, ¹⁵³ systematic review ¹⁵²
	Strength of consensus: 78.5%

(kidney transplants 30.7%, liver transplants 40%, heart transplants 75%) versus 0% in the placebo group. Partial clearance of at least 75% of lesions was observed in 59% for diclofenac versus 16.7% for placebo. The recurrence after diclofenac treatment was 55% after 9.3 months. Adverse events included mild to moderate erythema, scaling, itching and skin irritation with oedema.¹³¹ Based on the available evidence, Massey and co-workers have developed consensus-based recommendations on the prevention of cSCC in solid organ transplant recipients.¹⁵⁷ The key recommendations for the treatment of AK in OTR patients include cryosurgery for scattered AK, field therapy with 5-fluorouracil for AK grouped in one anatomical area, and for field cancerized skin, and acitretin therapy for patients with a high rate of multiple skin cancers or high-risk cSCC. For thick AKs, a combination of lesion-directed and field therapy with cryotherapy was recommended, and immunosuppression reduction or modification should be discussed with patients with high-risk cSCC.¹⁵⁷ This group of patients should be managed in specialist centres.

Treatment algorithm

Proposed treatment algorithm is presented in [Figure 1](#) (modified from Gupta et al.¹⁵⁸). For single non-hyperkeratotic lesions, destructive or field-directed treatments can be started, although monitoring and self-examination can also be advised. For multiple lesions, field-directed treatments and PDT are advised. For hyperkeratotic lesions, pre-treatment with destructive methods (curettage, cryotherapy or laser) is advised before field-directed treatment. For AKs in immunosuppressed patients, PDT might be preferred, although other topical treatments might be effective and safe, and for AKs in specific high-risk regions and in treatment-resistant cases surgery is indicated. Preventive measures (sun/protection, self/examination), repeated treatments and in patients with previous iSCC chemoprevention are advised ([Figure 1](#)).

PREVENTION OF AK

All patients with AK should be advised to apply the appropriate protective measures against solar UV radiation ([Table 19](#)). The following measures should be recommended: avoidance of intensive intermittent (UV peaks) and chronic sunlight exposure, wearing of appropriate clothing, application of sunscreen with a high sun protection factor (≥ 30) including ear rims and lips, no use of sun beds, and discontinuation or change of light-sensitizing drugs (e.g. hydrochlorothiazide). In more detail, the following UV protection measures should be taken to avoid excessive UV exposure: In case of medium and high UV irradiance (UV index 3–7), shade should be sought during midday. In case of very high UV irradiance (UV index ≥ 8), outdoor activities during

midday should be completely avoided or postponed to the morning and evening hours. Sunburn should be avoided at any time.

In high-risk patients (e.g. OTRs) with multiple AK, field cancerization, or a history of multiple non-melanoma skin cancers regular (e.g. yearly) treatments of previously affected skin areas can be considered with PDT, 5-FU or imiquimod as a preventive topical measure. In the Veterans Affairs Keratinocyte Carcinoma Chemoprevention (VAKCC) trial, one treatment course of 5-FU 5% cream twice daily over 4 weeks effectively reduced AK counts and the need for additional spot treatments for AK for more than 2 years.⁹⁴ Similarly, the formation of new AK was reduced with 5-FU in this trial by prospectively tracking individual lesions over 36 months in this high-risk population having more than 2 keratinocyte carcinomas in the past 5 years.¹⁶⁰ In the LEIDA trials, imiquimod 5% cream was superior to diclofenac 3% gel in preventing histological change to grade III AK or invasive SCC and AK recurrence over 3 years.¹¹⁸ However, this trial did not include a high-risk population as in the VAKCC trial.

There has been long-standing controversy and intense debate on the use of systemic chemoprevention in high-risk situations. Agents investigated for oral chemoprevention include oral retinoids, nonsteroidal anti-inflammatory drugs (NSAID), capecitabine, as well as dietary supplements and vitamins (beta-carotene, nicotinamide). Most of these agents failed to show a clear benefit for prevention and may even be associated with harmful side effects. Oral nicotinamide (vitamin B3) 500 mg twice daily showed a rate reduction for cSCC of 30% in immunocompetent individuals with two or more confirmed keratinocyte carcinomas in the past 5 years.¹⁶¹ However, there was no effect after nicotinamide discontinuation, and it is unclear if the preventive effects also pertain to AK. Also, oral nicotinamide which was found does not reduce the number of new keratinocyte cancers in OTRs.¹⁵¹ Recent consensus-based recommendations on the prevention of cSCC in OTR suggest initiation of acitretin and discussion of immunosuppression reduction or modification for patients who develop multiple skin cancers at a high rate (10 cSCC per year) or develop high-risk cSCC (defined by a tumour with approximately $\geq 20\%$ risk of nodal metastasis). However, no consensus recommendation was achieved for OTR with a first low risk cSCC or multiple AK or field cancerization.¹⁵⁷ Likewise, the German S3 guideline on prevention of skin cancer does not make any recommendations for chemoprevention in AK.^{3,78}

FOLLOW-UP OF AK

The surveillance and follow-up strategies for AK are not standardized and notoriously understudied ([Table 20](#)). The response to any treatment should be assessed 3 months after the end of treatment clinically, dermatoscopically, and if

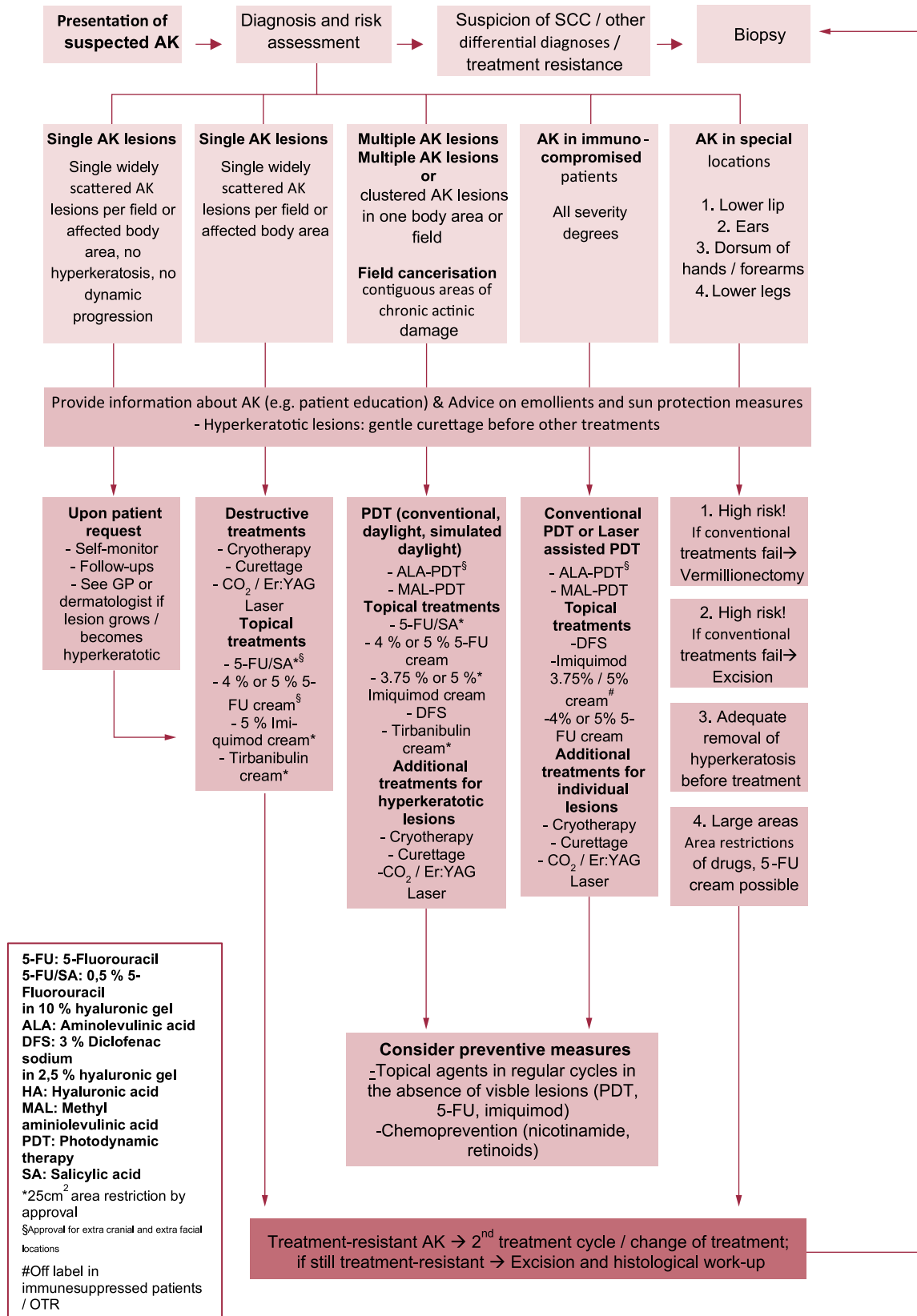


FIGURE 1 Treatment algorithm for actinic keratoses (adapted from Gupta et al. 158).

TABLE 19 Prevention of AKs.

Evidence-based statement	
Grade of recommendation: B	Individuals at high-risk of AKs, including those occupationally exposed to UV irradiation and immunocompromised and all patients with AK should be advised to apply the appropriate protective measures against UV irradiation
Grade of recommendation: C	In high-risk patients (e.g. organ transplant recipients, OTR) with multiple AK, field cancerization, or a history of multiple keratinocyte skin cancers regular (e.g. yearly) treatments of previously affected skin areas with photodynamic therapy, 5-fluorouracil or imiquimod as a preventive topical measure can be considered
Level of evidence: 2–3	Randomized controlled trials, systematic review of randomized controlled trials ^{59,113,159}
Strength of consensus: 100%	

TABLE 20 Follow-up of patients with AK.

Consensus-based statement	
Expert consensus	Patients with AK should be educated for self-skin examination and sun protection and referred for skin examination due to the common risk of recurrences and the development of new lesions as well as of other types of keratinocyte carcinomas
Strength of consensus: 100%	

available, with additional non-invasive imaging techniques. If there is evidence for treatment resistance, retreatment or a biopsy is recommended.

Patients with AK should be educated for self-skin examination and sun protection and referred for skin examination due to the common risk of recurrences and the development of new lesions as well as of other types of keratinocyte carcinomas. In patients with AKs and a history of cSCC, follow-up schedules should follow the guidelines for cSCC. Each follow-up includes a thorough skin check of the chronically sun-exposed body areas at a minimum. The frequency of follow-up should be based on the number and dynamics of previous AKs, the history of previous keratinocyte carcinomas, and the immune status and medication of the patient. In immunosuppressed patients, close follow-up visits with a dermatologist (e.g. every 3–6 months) are recommended.

AFFILIATIONS

¹Department of Dermatology, Faculty of Medicine, University of Defence, Military Medical Academy, Belgrade, Serbia

²UOC di Dermatologia, Dipartimento di Scienze Mediche e Chirurgiche Addominali ed Endrocrino Metaboliche, Fondazione Policlinico Universitario A. Gemelli – IRCCS, Rome, Italy

³Dermatologia, Università Cattolica del Sacro Cuore, Rome, Italy

⁴Dermatology Department of Hospital Clinic of Barcelona, IDIBAPS, CIBER de Enfermedades Raras, Instituto Carlos III, University of Barcelona, Barcelona, Spain

⁵Department of Dermatology, Maastricht University Medical Centre+ Comprehensive Cancer Centre, Maastricht, The Netherlands

⁶GROW-School for Oncology and Reproduction, Maastricht University, Maastricht, The Netherlands

⁷Department of Dermatology, Uniklinikum Erlangen, Friedrich-Alexander-University Erlangen-Nürnberg, Erlangen, Germany

⁸Comprehensive Cancer Center Erlangen-European Metropolitan Area of Nuremberg (CC ER-EMN), Erlangen, Germany

⁹Dermatology, Department of Biotechnological and Applied Clinical Sciences, University of LAquila, LAquila, Italy

¹⁰Department of Dermatovenereology, Third Faculty of Medicine, Charles University and University Hospital of Kralovske Vinohrady, Prague, Czech Republic

¹¹Clinic of Infectious Diseases and Dermatovenereology, Centre of Dermatovenereology, Vilnius University, Vilnius, Lithuania

¹²Department of Dermatology, University Hospital Erasme, Université Libre de Bruxelles, Brussels, Belgium

¹³Faculty of Health, University Witten-Herdecke, Witten, Germany

¹⁴CentroDerm Clinic, Wuppertal, Germany

¹⁵Nantes Université, INSERM, CNRS, Immunology and New Concepts in ImmunoTherapy, INCIT, UMR 1302/EMR6001, Nantes, France

¹⁶Department of Oncologic Dermatology, Elias University Hospital Bucharest, Carol Davila University of Medicine and Pharmacy, Bucharest, Romania

¹⁷Centre for Cell Biology and Cutaneous Research, Blizard Institute, Barts and The London School of Medicine and Dentistry, Queen Mary University of London, London, UK

¹⁸Department of Dermatology, University Hospital (UKSH), Kiel, Germany

¹⁹Department of Dermatology, Copenhagen University Hospital – Bispebjerg and Frederiksberg, Copenhagen, Denmark

²⁰Department of Dermatology, Venereology and Allergology, Frankfurt University Hospital, Frankfurt, Germany

²¹First Department of Dermatology, Aristotle University, Thessaloniki, Greece

²²Université Paris Cite, AP-HP Dermato-oncology, Cancer institute APHP, Nord Paris cité, INSERM U976, Saint Louis Hospital, Paris, France

²³Centre for Dermatoooncology, Department of Dermatology, Eberhard Karls University, Tuebingen, Germany

²⁴Skin Cancer Center, Azienda Unità Sanitaria Locale – IRCCS di Reggio Emilia, Reggio Emilia, Italy

²⁵Department of Dermatology, University of Modena and Reggio Emilia, Modena, Italy

²⁶Department of General and Oncologic Dermatology, Ambroise Paré Hospital, APHP, & EA 4340 “Biomarkers in Cancerology and Hemato-Oncology”, UVSQ, Université Paris-Saclay, Boulogne-Billancourt, France

²⁷Department of Dermatology and Venereology, Sestre Milosrdnice University Hospital Center, Zagreb, Croatia

²⁸Skin Cancer Center, Department of Dermatology, Ruhr-University Bochum, Bochum, Germany

²⁹Department of Pediatric Dermatology, Colentina Clinical Hospital, Carol Davila University of Medicine and Pharmacy, Bucharest, Romania

³⁰1st Department of Dermatology-Venereology, National and Kapodistrian University of Athens, Andreas Sygros Hospital, Athens, Greece

³¹Dermatology Clinic, Maggiore Hospital, Department of Medical Sciences, University of Trieste, Trieste, Italy

FUNDING INFORMATION

The development of the current set of guidelines was supported solely by funds of the EADO which were used to mainly support the consensus meeting without honoraria and without reimbursement of travel costs.

CONFLICT OF INTEREST STATEMENT

LK: None for the present manuscript. Consulting fees from MSD, Merck, Abbvie, Janssen and honoraria for lectures and educational events by BMS, MSD, Novartis, Merck, Roche, Abbvie and Janssen. KP: None for the present manuscript. Grants from Sanofi, Novartis, Abbvie and Almirall. Consulting fees from Sanofi, honoraria for lectures and educational events from Lilly, Sanofi and Sun Pharma,

participation in advisory boards Abbvie and Almirall. Leo Pharma, Lilly, Janssen, Sanofi, Pierre Fabre, Sun Pharma, Biogen, Galderma and Philogen. JM: None for the present manuscript. Honoraria for lectures and educational events from Almirall, Pierre Fabre, ISDIN, BMS, MSD and Sunpharma, support for attending meetings and/or travel Almirall, ISDIN, Sunpharma, participation in advisory boards Pierre Fabre, Almirall, stock options Athena tech and Dermavision. KM: None for the present manuscript. Grants from institution, Health Foundation Limburg, ZonMW. Consulting fees from Sunpharma, Almirall, honoraria for lectures and educational events from Leopharma, Sanofi, Pierre Fabre, Novartis and Galderma, support for attending meetings Pierre Fabre, participation in Advisory boards Michelson Diagnostics. MH: None for the present manuscript. Grants from Almirall Hermal, BMS, InflaRx, Kartos Therapeutics, Pfizer, Immatics, IO Biotech and MSD. Consulting fees from Almirall Hermal, BMS, Immunocore, MSD, Novartis, Pierre Fabre and Sanofi, honoraria for lectures and educational events from Almirall Hermal, Biofrontera, MSD. MCF: None for the present manuscript Consulting fees from Almirall honoraria for lectures and educational events from Almirall, Galderma, Pierre Fabre, advisory board participation Almirall and Pierre Fabre. CB: None for the present manuscript. Grants from Almirall Hermal, BMS, InflaRx, Kartos Therapeutics, Pfizer, Immatics and IO Biotech. Consulting fees from Almirall Hermal, BMS, Immunocore, InflaRx, MSD, Novartis, Pierre Fabre, Regeneron and Sanofi, honoraria for lectures and educational events from Almirall Hermal, BMS, MSD, LeoPharma, Novartis, Sanofi, advisory board participation Miltenyl Biotech. PA: None for the present manuscript. Grants from AbbVie, BMS, MSD, Novartis and Pfizer. MB-B, IMH, AL, CL, MS, ES, CS: None. VM: None for the present manuscript; Grants to my institution by Pierre Fabre, BMS, MSD, Almirall and Sanofi; consulting fees from BMS, MSD, Novartis, Pierre Fabre, Merck, Sanofi, Almirall, Abbvie and LeoPharma, honoraria for lectures and educational events from BMS, MSD, Sanofi, SunPharma, Pierre Fabre and Novartis, support for attending meetings/travel BMS, MSD, Pierre Fabre and Novartis. TD: None for the present manuscript. Honoraria for lectures and educational events from Almirall Hermal, Biofrontera, Galderma, Pierre Fabre, Neracare, Leo, Novartis and Pfizer, support for attending meetings Janssen Cilag, Abbvie, Advisory board participation Almirall Hermal, Galderma, Neracare, Biofrontera, Leo and Pierre Fabre. BD: None for the present manuscript. Consulting fees from Almirall. AMF: None for the present manuscript. Honoraria for lectures and educational events from Novartis. CH: None for the present manuscript. Grants from Medical research Council, UK, British Skin Foundation, National Institute for Health Research, Wellcome Trust, consulting fees from Incanthera, Almirall and AMLo Biosciences. Honoraria for lectures and educational events from Merck, Saofi/Regeneron, medical writing Novartis and Sanofi. AH: None for the

present manuscript. Grants to institution from MSD/Merck, Philogen, Pierre Fabre, Regeneron, Roche, Sanofi-Genzyme, Novartis Pharma, Eisai. Honoraria for lectures and educational events from MSD/Merck, Pierre Fabre, Regeneron, Roche, Sanofi-Genzyme, Novartis Pharma, Eisai, participation in Advisory boards MSD/Merck, Pierre Fabre, Regeneron, Roche, Sanofi-Genzyme, Novartis Pharma, Eisai, Immunocore, Replimune and Seagen. RK: None for the present manuscript. Grants to institution from AbbVie, Amgen, Biontech, BMS, Celgene, Galderma, Janssen, Leo, Lilly, Merck, MSD, Novartis, Pierre Fabre, Pfizer, Regeneron, Roche and Wyeth. NKS: None for the present manuscript. Honoraria for lectures and educational events from Sanofi, Novartis, participation in Advisory boards Sanofi, MSD and SunPharma. CL: None for the present manuscript. Grants to my institution BMS and Roche, consulting fees from BMS, MSD, Novartis, Amgen, Roche, Merck Serono, Sanofi and Pierre Fabre, honoraria for lectures and educational events from Roche, BMS, Novartis, Amgen, MSD, Pierre Fabre, pfizer, Incyte, support for attending meetings/travel BMS, MSD, Novartis, Sanofi and Pierre Fabre, participation in advisory boards BMS, MSD, Novartis, Sanofi, Pierre Fabre, Roche, Novartis, Amgen, Merck Serono, InflaRx, Avantis and Jazz Pharmaceuticals. Ulrike Leiter: None for the present manuscript. Honoraria for lectures and educational events from Almirall Hermal, Biofrontera, Galderma, Pierre Fabre, Neracare, Leo, Novartis and Pfizer, support for attending meetings Janssen Cilag and Abbvie, participation in advisory boards Almirall hermal, Galderma, Neracare, Biofrontera, Leo and Pierre Fabre. ZM: None for the present manuscript. Honoraria for lectures and educational events from MSD, Janssen, Novartis, Roche, advisory board participation Beiersdorf and BMS. GP: None for the present manuscript. Grants to institution from AbbVie, Almirall, Galderma, Leo, Lilly, Novartis, Pierre Fabre and Pfizer. SP: None for the present manuscript. Grants from La Roche Posay, Almirall and Pierre Fabre, consulting fees from Almirall, ISDIN and La Roche Posay, honoraria for lectures and educational events from Almirall, Sanofi, Sanpharma, Novartis, MSD and La Roche Posay, Support for attending meetings/travel Almirall, La Roche Posay, participation in advisory boards Almirall Sanofi, SunPharma, Novartis and MSD. PS: None for the present manuscript. Honoraria for lectures and educational event from Novartis, Pierre Fabre, Merck Serono, BMS and MSD. AS: None for the present manuscript. Grants to institution from Novartis, Abbvie and Regeneron, honoraria for lectures and educational events from BMS, Janssen Cilag, Sanofi, genesis Pharma and Regeneron. IZ: None for the present manuscript. Honoraria for lectures and educational events from Almirall Hermal, Difa Cooper, Sanofi, Philogen, Sun Pharma, Novartis, MSD and La Roche Posay. Participation on Advisory Boards Almirall Hermal, Philogen, Sanofi, Sun Pharma, Novartis and MSD. CG: None for the present manuscript. Grants from Novartis and Neracare.

DATA AVAILABILITY STATEMENT

Data sharing is not applicable to this article as no datasets were generated or analysed during the current study.

ORCID

Lidija Kandolf  <https://orcid.org/0000-0002-5221-5068>
 Kitty Peris  <https://orcid.org/0000-0003-1957-6600>
 Klara Mosterd  <https://orcid.org/0000-0002-9065-3050>
 Markus V. Heppt  <https://orcid.org/0000-0003-4603-1825>
 Maria Concetta Fargnoli  <https://orcid.org/0000-0002-7249-2556>
 Petr Arenberger  <https://orcid.org/0000-0002-4800-5877>
 Brigitte Dreno  <https://orcid.org/0000-0001-5574-5825>
 Ana-Maria Forsea  <https://orcid.org/0000-0002-1007-7883>
 Ida Marie Heerfordt  <https://orcid.org/0000-0002-6130-875X>
 Roland Kauffman  <https://orcid.org/0000-0002-1614-694X>
 Aimilios Lallas  <https://orcid.org/0000-0002-7193-0964>
 Ulrike Leiter  <https://orcid.org/0000-0002-8019-1577>
 Caterina Longo  <https://orcid.org/0000-0002-8218-3896>
 Giovanni Pellacani  <https://orcid.org/0000-0002-7222-2951>
 Susana Puig  <https://orcid.org/0000-0003-1337-9745>

REFERENCES

- Brouwers MC, Kho ME, Browman GP, Burgers JS, Cluzeau F, Feder G, et al. AGREE II: advancing guideline development, reporting and evaluation in health care. *CMAJ*. 2010;182:E839–E842.
- Howick J, Chalmers I, Glasziou P, Greenhalgh T, Heneghan C, Liberati S, et al. The 2011 Oxford CEBM Levels of Evidence (Introductory Document). Oxford Centre for Evidence-Based Medicine. 2011. <https://www.cebm.ox.ac.uk/resources/levels-of-evidence/ocebml-levels-of-evidence>
- Heppt MV, Leiter U, Steeb T, Amaral T, Bauer A, Becker JC, et al. S3 Guideline for actinic keratosis and cutaneous squamous cell carcinoma—short version, part 1: diagnosis, interventions for actinic keratoses, care structures and quality-of-care indicators. *J Dtsch Dermatol Ges*. 2020;18:275–94.
- Eisen DB, Asgari MM, Bennett DD, Connolly SM, Dellavalle RP, Freeman EE, et al. Guidelines of care for the management of actinic keratosis. *J Am Acad Dermatol*. 2021;85:e209–e233.
- Eisen DB, Dellavalle RP, Frazer-Green L, Schlesinger TE, Shive M, Wu PA. Focused update: guidelines of care for the management of actinic keratosis. *J Am Acad Dermatol*. 2022;87:373–4.e5.
- World Health Organization. WHO Classification of tumours online. 2023.
- Heaphy MR, Ackerman AB. The nature of solar keratosis: a critical review in historical perspective. *J Am Acad Dermatol*. 2000;43:138–50.
- Röwert-Huber J, Patel M, Forschner T, Ulrich C, Eberle J, Kerl H, et al. Actinic keratosis is an early in situ squamous cell carcinoma: a proposal for reclassification. *Br J Dermatol*. 2007;156:8–12.
- Ackerman A, Mones J. Solar (actinic) keratosis is squamous cell carcinoma. *Br J Dermatol*. 2006;155:9–22.
- Padilla RS, Sebastian S, Jiang Z, Nindl I, Larson R. Gene expression patterns of normal human skin, actinic keratosis, and squamous cell carcinoma: a spectrum of disease progression. *Arch Dermatol*. 2010;146:288–93.
- Jetter N, Chandan N, Wang S, Tsoukas M. Field cancerization therapies for management of actinic keratosis: a narrative review. *Am J Clin Dermatol*. 2018;19:543–57.
- Siegel J, Korgavkar K, Weinstock M. Current perspective on actinic keratosis: a review. *Br J Dermatol*. 2017;177:350–8.
- Figueras Nart I, Cerio R, Dirschka T, Dréno B, Lear J, Pellacani G, et al. Defining the actinic keratosis field: a literature review and discussion. *J Eur Acad Dermatol Venereol*. 2018;32:544–63.
- Kennedy C, Willemze R, de Grujil FR, Bavinck JNB, Bajdik CD. The influence of painful sunburns and lifetime sun exposure on the risk of actinic keratoses, seborrheic warts, melanocytic nevi, atypical nevi, and skin cancer. *J Invest Dermatol*. 2003;120:1087–93.
- Karagas MR, Zens MS, Nelson HH, Mabuchi K, Perry AE, Stukel TA, et al. Measures of cumulative exposure from a standardized sun exposure history questionnaire: a comparison with histologic assessment of solar skin damage. *Am J Epidemiol*. 2007;165:719–26.
- Harvey I, Frankel S, Marks R, Shalom D, Nolan-Farrell M. Non-melanoma skin cancer and solar keratoses II analytical results of the South Wales Skin Cancer Study. *Br J Cancer*. 1996;74:1308–12.
- Ming M, Han W, Maddox J, Soltani K, Shea CR, Freeman DM, et al. UVB-induced ERK/AKT-dependent PTEN suppression promotes survival of epidermal keratinocytes. *Oncogene*. 2010;29:492–502.
- Kanellou P, Zaravinos A, Zioga M, Stratigos A, Baritaki S, Soufla G, et al. Genomic instability, mutations and expression analysis of the tumour suppressor genes p14ARF, p15INK4b, p16INK4a and p53 in actinic keratosis. *Cancer Lett*. 2008;264:145–61.
- Harwood CA, Proby CM. Human papillomaviruses and non-melanoma skin cancer. *Curr Opin Infect Dis*. 2002;15:101–14.
- Lebwohl MG, Rosen T, Stockfleth E. The role of human papillomavirus in common skin conditions: current viewpoints and therapeutic options. *Cutis*. 2010;86(suppl):1–11; quiz suppl 2.
- Queille S, Luron L, Spatz A, Avril MF, Ribrag V, Duvillard P, et al. Analysis of skin cancer risk factors in immunosuppressed renal transplant patients shows high levels of UV-specific tandem CC to TT mutations of the p53 gene. *Carcinogenesis*. 2007;28:724–31.
- Nehal KS, Bichakjian CK. Update on keratinocyte carcinomas. *N Engl J Med*. 2018;379:363–74.
- Wang J, Aldabagh B, Yu J, Arron ST. Role of human papillomavirus in cutaneous squamous cell carcinoma: a meta-analysis. *J Am Acad Dermatol*. 2014;70:621–9.
- Chockalingam R, Downing C, Tyring SK. Cutaneous squamous cell carcinomas in organ transplant recipients. *J Clin Med*. 2015;4:1229–39.
- Strickley JD, Messerschmidt JL, Awad ME, Li T, Hasegawa T, Ha DT, et al. Immunity to commensal papillomaviruses protects against skin cancer. *Nature*. 2019;575:519–22.
- Reinehr CPH, Bakos RM. Actinic keratoses: review of clinical, dermoscopic, and therapeutic aspects. *An Bras Dermatol*. 2019;94:637–57.
- Fernandez-Figueras M, Carrato C, Sáenz X, Puig L, Musulen E, Ferrándiz C, et al. Actinic keratosis with atypical basal cells (AK I) is the most common lesion associated with invasive squamous cell carcinoma of the skin. *J Eur Acad Dermatol Venereol*. 2015;29:991–7.
- Werner R, Sammain A, Erdmann R, Hartmann V, Stockfleth E, Nast A. The natural history of actinic keratosis: a systematic review. *Br J Dermatol*. 2013;169:502–18.
- Flohil SC, Van Der Leest RJ, Dowlatshahi EA, Hofman A, De Vries E, Nijsten T. Prevalence of actinic keratosis and its risk factors in the general population: the Rotterdam Study. *J Invest Dermatol*. 2013;133:1971–8.
- Memon AA, Tomenson JA, Bothwell J, Friedmann PS. Prevalence of solar damage and actinic keratosis in a Merseyside population. *Br J Dermatol*. 2000;142:1154–9.
- Frost C, Green A, Williams G. The prevalence and determinants of solar keratoses at a subtropical latitude (Queensland, Australia). *Br J Dermatol*. 1998;139:1033–9.
- Ferrándiz C, Plazas M, Sabaté M, Palomino R, EPIQA Study Group. Prevalence of actinic keratosis among dermatology outpatients in Spain. *Actas Dermosifiliogr*. 2016;107:674–80.

33. Jacobs LC, Liu F, Pardo LM, Hofman A, Uitterlinden AG, Kayser M, et al. IRF4, MC1R and TYR genes are risk factors for actinic keratosis independent of skin color. *Hum Mol Genet.* 2015;24:3296–303.
34. Fargnoli MC, Altomare G, Benati E, Borgia F, Broganelli P, Carbone A, et al. Prevalence and risk factors of actinic keratosis in patients attending Italian dermatology clinics. *Eur J Dermatol.* 2017;27:599–608.
35. Dziunycz PJ, Schuller E, Hofbauer GF. Prevalence of actinic keratosis in patients attending general practitioners in Switzerland. *Dermatology.* 2018;234:214–9.
36. Roewert-Huber J, Stockfleth E, Kerl H. Pathology and pathobiology of actinic (solar) keratosis—an update. *Br J Dermatol.* 2007;157:18–20.
37. Ramsay HM, Fryer AA, Reece S, Smith AG, Harden PN. Clinical risk factors associated with nonmelanoma skin cancer in renal transplant recipients. *Am J Kidney Dis.* 2000;36:167–76.
38. Jiyad Z, Marquart L, O'Rourke P, Green AC. The natural history of actinic keratoses in organ transplant recipients. *J Am Acad Dermatol.* 2017;76:162–4.
39. Jiyad Z, O'Rourke P, Soyer H, Green AC. Actinic keratosis-related signs predictive of squamous cell carcinoma in renal transplant recipients: a nested case–control study. *Br J Dermatol.* 2017;176:965–70.
40. DiGiovanna JJ, Kraemer KH. Shining a light on xeroderma pigmentosum. *J Invest Dermatol.* 2012;132:785–96.
41. Marçon CR, Moraes JC, de Olivas Ferreira MAM, Oliari CB. Dermatological and epidemiological profiles of patients with albinism in São Paulo, Brazil, between 2010 and 2017: a cross-sectional study. *Dermatology.* 2020;236:219–27.
42. Zalaudek I, Piana S, Moscarella E, Longo C, Zendri E, Castagnetti F, et al. Morphologic grading and treatment of facial actinic keratosis. *Clin Dermatol.* 2014;32:80–7.
43. Dirschka T, Gupta G, Micali G, Stockfleth E, Basset-Séguin N, Del Marmol V, et al. Real-world approach to actinic keratosis management: practical treatment algorithm for office-based dermatology. *J Dermatolog Treat.* 2017;28:431–42.
44. Lallas A, Tschandl P, Kyrgidis A, Stolz W, Rabinovitz H, Cameron A, et al. Dermoscopic clues to differentiate facial lentigo maligna from pigmented actinic keratosis. *Br J Dermatol.* 2016;174:1079–85.
45. Tschandl P, Rosendahl C, Kittler H. Dermatoscopy of flat pigmented facial lesions. *J Eur Acad Dermatol Venereol.* 2015;29:120–7.
46. Olsen EA, Abernethy ML, Kulp-Shorten C, Callen JP, Glazer SD, Huntley A, et al. A double-blind, vehicle-controlled study evaluating masoprocol cream in the treatment of actinic keratoses on the head and neck. *J Am Acad Dermatol.* 1991;24:738–43.
47. Weinstock MA, Bingham SF, Cole GW, Eilers D, Naylor MF, Kalivas J, et al. Reliability of counting actinic keratoses before and after brief consensus discussion: the VA topical tretinoin chemoprevention (VATTC) trial. *Arch Dermatol.* 2001;137:1055–8.
48. Ahmady S, Jansen MHE, Nelemans PJ, Kessels J, Arits A, de Rooij MJM, et al. Risk of invasive cutaneous squamous cell carcinoma after different treatments for actinic keratosis: a secondary analysis of a randomized clinical trial. *JAMA Dermatol.* 2022;158:634–40.
49. Dreno B, Cerio R, Dirschka T, Figueras Nart I, Lear JT, Peris K, et al. A novel actinic keratosis field assessment scale for grading actinic keratosis disease severity. *Acta Derm Venereol.* 2017;97:1108–13.
50. Dirschka T, Pellacani G, Micali G, Malvey J, Stratigos A, Casari A, et al. A proposed scoring system for assessing the severity of actinic keratosis on the head: actinic keratosis area and severity index. *J Eur Acad Dermatol Venereol.* 2017;31:1295–302.
51. Baker C, James A, Supranowicz M, Spelman L, Shumack S, Cole J, et al. Method of Assessing Skin Cancerization and Keratoses™ (MASCK): development and photographic validation in multiple anatomical sites of a novel assessment tool intended for clinical evaluation of patients with extensive skin field cancerization. *Clin Exp Dermatol.* 2022;47:1144–53.
52. Werner R, Stockfleth E, Connolly S, Correia O, Erdmann R, Foley P, et al. Evidence-and consensus-based (S3) guidelines for the treatment of actinic keratosis—International League of Dermatological Societies in cooperation with the European Dermatology Forum—short version. *J Eur Acad Dermatol Venereol.* 2015;29:2069–79.
53. Huerta-Brogeras M, Olmos O, Borbujo J, Hernández-Núñez A, Castano E, Romero-Maté A, et al. Validation of dermoscopy as a real-time noninvasive diagnostic imaging technique for actinic keratosis. *Arch Dermatol.* 2012;148:1159–64.
54. Zalaudek I, Giacomel J, Schmid K, Bondino S, Rosendahl C, Cavicchini S, et al. Dermatoscopy of facial actinic keratosis, intraepidermal carcinoma, and invasive squamous cell carcinoma: a progression model. *J Am Acad Dermatol.* 2012;66:589–97.
55. Valdés-Morales KL, Peralta-Pedrero ML, Jurado-Santa Cruz F, Morales-Sánchez MA. Diagnostic accuracy of dermoscopy of actinic keratosis: a systematic review. *Dermatol Pract Concept.* 2020;10:e2020121.
56. Pampena R, Condorelli A, Cornacchia L, Guiducci L, Raucci M, Benati E, et al. Treatment monitoring of 5-fluorouracil 0.5%/salicylic acid 10% lesion-directed therapy for actinic keratosis using dermoscopy and in-vivo reflectance confocal microscopy. *Dermatol Ther.* 2020;33:e13744.
57. Benati E, Longhitano S, Pampena R, Mirra M, Raucci M, Pellacani G, et al. Digital follow-up by means of dermoscopy and reflectance confocal microscopy of actinic keratosis treated with imiquimod 3.75% cream. *J Eur Acad Dermatol Venereol.* 2020;34:1471–7.
58. Longo C, Borsari S, Benati E, Moscarella E, Alfano R, Argenziano G. Dermoscopy and reflectance confocal microscopy for monitoring the treatment of actinic keratosis with ingenol mebutate gel: report of two cases. *Dermatol Ther.* 2016;6:81–7.
59. Ulrich M, Alarcon I, Malvey J, Puig S. In vivo reflectance confocal microscopy characterization of field-directed 5-fluorouracil 0.5%/salicylic acid 10% in actinic keratosis. *Dermatology.* 2015;230:193–8.
60. Malvey J, Roldán-Marín R, Iglesias-García P, Díaz Lorca MA, Puig i Sardà S. Monitoring treatment of field cancerisation with 3% diclofenac sodium 2.5% hyaluronic acid by reflectance confocal microscopy: a histologic correlation. *Acta Derm Venereol.* 2014;95(1):45–50.
61. Navarrete-Dechent C, DeRosa AP, Longo C, Liopyris K, Oliviero M, Rabinovitz H, et al. Reflectance confocal microscopy terminology glossary for nonmelanocytic skin lesions: a systematic review. *J Am Acad Dermatol.* 2019;80:1414–27.e3.
62. Pellacani G, Ulrich M, Casari A, Prow TW, Cannillo F, Benati E, et al. Grading keratinocyte atypia in actinic keratosis: a correlation of reflectance confocal microscopy and histopathology. *J Eur Acad Dermatol Venereol.* 2015;29:2216–21.
63. Tang Z, Kang L, Zhang Y, Huang J, Tong X, Zhou L, et al. The diagnostic value of in vivo reflectance confocal microscopy in actinic keratosis. *Skin Res Technol.* 2021;27:80–5.
64. Cinotti E, Tognetti L, Cartocci A, Lamberti A, Gherbassi S, Orte Cano C, et al. Line-field confocal optical coherence tomography for actinic keratosis and squamous cell carcinoma: a descriptive study. *Clin Exp Dermatol.* 2021;46:1530–41.
65. Ruini C, Schuh S, Gust C, Kendziora B, Frommherz L, French LE, et al. Line-field confocal optical coherence tomography for the in vivo real-time diagnosis of different stages of keratinocyte skin cancer: a preliminary study. *J Eur Acad Dermatol Venereol.* 2021;35:2388–97.
66. Ruini C, Schuh S, Gust C, Hartmann D, French LE, Sattler EC, et al. In-vivo LC-OCT evaluation of the downward proliferation pattern of keratinocytes in actinic keratosis in comparison with histology: first impressions from a pilot study. *Cancers.* 2021;13:2856.
67. Bagazgoitia L, Cuevas J, Juarranz A. Expression of p53 and p16 in actinic keratosis, Bowenoid actinic keratosis and Bowen's disease. *J Eur Acad Dermatol Venereol.* 2010;24:228–30.
68. Askari SK, Schram SE, Wenner RA, Bowers S, Liu A, Bangerter AK, et al. Evaluation of prospectively collected presenting signs/symptoms of biopsy-proven melanoma, basal cell carcinoma, squamous cell carcinoma, and seborrheic keratosis in an elderly male population. *J Am Acad Dermatol.* 2007;56:739–47.

69. Schmitz L, Gambichler T, Kost C, Gupta G, Stucker M, Stockfleth E, et al. Cutaneous squamous cell carcinomas are associated with basal proliferating actinic keratoses. *Br J Dermatol*. 2019;180:916–21.
70. Schmitz L, Brehmer A, Falkenberg C, Gambichler T, Heppt MV, Steeb T, et al. Treatment-resistant actinic keratoses are characterized by distinct clinical and histological features. *Ital J Dermatol Venerol*. 2021;156:213–9.
71. Stockfleth E, Ferrandiz C, Grob JJ, Leigh I, Pehamberger H, Kerl H, et al. Development of a treatment algorithm for actinic keratoses: a European consensus. *Eur J Dermatol*. 2008;18:651–9.
72. Wehner MR, Linos E, Parvataneni R, Stuart SE, Boscardin WJ, Chren MM. Timing of subsequent new tumors in patients who present with basal cell carcinoma or cutaneous squamous cell carcinoma. *JAMA Dermatol*. 2015;151:382–8.
73. Marques E, Chen TM. Actinic keratosis. In: StatPearls. Treasure Island, FL: StatPearls Publishing; 2022.
74. Weinstock MA, Thwin SS, Siegel JA, Marcolivio K, Means AD, Leader NF, et al. Chemoprevention of basal and squamous cell carcinoma with a single course of fluorouracil, 5%, cream: a randomized clinical trial. *JAMA Dermatol*. 2018;154:167–74.
75. Del Regno L, Catapano S, Di Stefani A, Cappilli S, Peris K. A review of existing therapies for actinic keratosis: current status and future directions. *Am J Clin Dermatol*. 2022;23:339–52.
76. Dianzani C, Conforti C, Giuffrida R, Corneli P, di Meo N, Farinazzo E, et al. Current therapies for actinic keratosis. *Int J Dermatol*. 2020;59:677–84.
77. Stewart JR, Lang ME, Brewer JD. Efficacy of nonexcisional treatment modalities for superficially invasive and in situ squamous cell carcinoma: a systematic review and meta-analysis. *J Am Acad Dermatol*. 2022;87:131–7.
78. Leiter U, Heppt MV, Steeb T, Amaral T, Bauer A, Becker JC, et al. S3 Guideline for actinic keratosis and cutaneous squamous cell carcinoma (cSCC) - short version, part 2: epidemiology, surgical and systemic treatment of cSCC, follow-up, prevention and occupational disease. *J Dtsch Dermatol Ges*. 2020;18:400–13.
79. de Berker D, McGregor JM, Mohd Mustapa MF, Exton LS, Hughes BR. British Association of Dermatologists' guidelines for the care of patients with actinic keratosis 2017. *Br J Dermatol*. 2017;176:20–43.
80. Poulin Y, Lynde CW, Barber K, Vender R, Claveau J, Bourcier M, et al. Non-melanoma skin cancer in Canada chapter 3: management of actinic keratoses. *J Cutan Med Surg*. 2015;19:227–38.
81. Chetty P, Choi F, Mitchell T. Primary care review of actinic keratosis and its therapeutic options: a global perspective. *Dermatol Ther*. 2015;5:19–35.
82. Dermatological cryosurgery and cryotherapy. *Anticancer Res*. 2016;36:4979–80.
83. Guidelines of care for cryosurgery. American Academy of Dermatology Committee on guidelines of care. *J Am Acad Dermatol*. 1994;31:648–53.
84. Nashan D, Meiss F, Muller M. Therapeutic strategies for actinic keratoses—a systematic review. *Eur J Dermatol*. 2013;23:14–32.
85. Mota A, De Carvalho N, Pellacani G, de Faria PCP, Melo DF, Pineiro-Maceira JM, et al. Reflectance confocal microscopy in actinic keratosis-comparison of efficacy between cryotherapy protocols. *Skin Res Technol*. 2020;26:876–82.
86. Gage AA. Experimental cryogenic injury of the palate: observations pertinent to cryosurgical destruction of tumors. *Cryobiology*. 1978;15:415–25.
87. Arisi M, Guasco Pisani E, Calzavara-Pinton P, Zane C. Cryotherapy for actinic keratosis: basic principles and literature review. *Clin Cosmet Investig Dermatol*. 2022;15:357–65.
88. Heppt MV, Steeb T, Ruzicka T, Berking C. Cryosurgery combined with topical interventions for actinic keratosis: a systematic review and meta-analysis. *Br J Dermatol*. 2019;180:740–8.
89. Hantash BM, Stewart DB, Cooper ZA, Rehmus WE, Koch RJ, Swetter SM. Facial resurfacing for nonmelanoma skin cancer prophylaxis. *Arch Dermatol*. 2006;142:976–82.
90. Ostertag JU, Quaedvlieg PJ, van der Geer S, Nelemans P, Christianen ME, Neumann MH, et al. A clinical comparison and long-term follow-up of topical 5-fluorouracil versus laser resurfacing in the treatment of widespread actinic keratoses. *Lasers Surg Med*. 2006;38:731–9.
91. Tai F, Shah M, Pon K, Alavi A. Laser resurfacing monotherapy for the treatment of actinic keratosis. *J Cutan Med Surg*. 2021;25:634–42.
92. Zane C, Facchinetti E, Rossi MT, Specchia C, Ortel B, Calzavara-Pinton P. Cryotherapy is preferable to ablative CO2 laser for the treatment of isolated actinic keratoses of the face and scalp: a randomized clinical trial. *Br J Dermatol*. 2014;170:1114–21.
93. Steeb T, Schlager JG, Kohl C, Ruzicka T, Heppt MV, Berking C. Laser-assisted photodynamic therapy for actinic keratosis: a systematic review and meta-analysis. *J Am Acad Dermatol*. 2019;80:947–56.
94. Pomerantz H, Hogan D, Eilers D, Swetter SM, Chen SC, Jacob SE, et al. Long-term efficacy of topical fluorouracil cream, 5%, for treating actinic keratosis: a randomized clinical trial. *JAMA Dermatol*. 2015;151:952–60.
95. Jorizzo J, Stewart D, Bucko A, Davis SA, Espy P, Hino P, et al. Randomized trial evaluating a new 0.5% fluorouracil formulation demonstrates efficacy after 1-, 2-, or 4-week treatment in patients with actinic keratosis. *Cutis*. 2002;70:335–9.
96. Weiss J, Menter A, Hevia O, Jones T, Ling M, Rist T, et al. Effective treatment of actinic keratosis with 0.5% fluorouracil cream for 1, 2, or 4 weeks. *Cutis*. 2002;70:22–9.
97. Stockfleth E, Begeault N, Delarue A. Intensity of local skin reactions during 5-fluorouracil treatment related to the number of actinic keratosis lesions: a post hoc, exploratory analysis. *Dermatol Ther*. 2022;12:467–79.
98. Stockfleth E, von Kiedrowski R, Dominicus R, Ryan J, Ellery A, Falques M, et al. Efficacy and safety of 5-fluorouracil 0.5%/salicylic acid 10% in the field-directed treatment of actinic keratosis: a phase III, randomized, double-blind, vehicle-controlled trial. *Dermatol Ther*. 2017;7:81–96.
99. Mohney L, Singh R, Grada A, Feldman S. Use of topical calcipotriol plus 5-fluorouracil in the treatment of actinic keratosis: a systematic review. *J Drugs Dermatol*. 2022;21:60–5.
100. Azin M, Mahon AB, Isaacman S, Seaman JE, Allen IE, Szarek M, et al. Topical calcipotriol plus 5-fluorouracil immunotherapy for actinic keratosis treatment. *JID Innov*. 2022;2:100104.
101. Samrao A, Cockerell CJ. Pharmacotherapeutic management of actinic keratosis: focus on newer topical agents. *Am J Clin Dermatol*. 2013;14:273–7.
102. Jansen MHE, Kessels J, Nelemans PJ, Kouloubis N, Arits A, van Pelt HPA, et al. Randomized trial of four treatment approaches for actinic keratosis. *N Engl J Med*. 2019;380:935–46.
103. Vegter S, Tolley K. A network meta-analysis of the relative efficacy of treatments for actinic keratosis of the face or scalp in Europe. *PLoS One*. 2014;9:e96829.
104. Swanson N, Smith CC, Kaur M, Goldenberg G. Imiquimod 2.5% and 3.75% for the treatment of actinic keratoses: two phase 3 multicenter, randomized, double-blind, placebo-controlled studies. *J Drugs Dermatol*. 2013;12:1278–82.
105. Jorizzo J, Dinehart S, Matheson R, Moore JK, Ling M, Fox TL, et al. Vehicle-controlled, double-blind, randomized study of imiquimod 5% cream applied 3 days per week in one or two courses of treatment for actinic keratoses on the head. *J Am Acad Dermatol*. 2007;57:265–8.
106. Szeimies RM, Bichel J, Ortonne JP, Stockfleth E, Lee J, Meng TC. A phase II dose-ranging study of topical resiquimod to treat actinic keratosis. *Br J Dermatol*. 2008;159:205–10.
107. Stockfleth E, Hofbauer GFL, Reinhold U, Popp G, Hengge UR, Szeimies RM, et al. Topical resiquimod dosing regimens in patients with multiple actinic keratoses: a multicentre, partly placebo-controlled, double-blind clinical trial. *Br J Dermatol*. 2019;180:297–305.
108. Gan TJ. Diclofenac: an update on its mechanism of action and safety profile. *Curr Med Res Opin*. 2010;26:1715–31.

109. Johnsen JI, Lindskog M, Ponthan F, Pettersen I, Elfman L, Orrego A, et al. Cyclooxygenase-2 is expressed in neuroblastoma, and non-steroidal anti-inflammatory drugs induce apoptosis and inhibit tumor growth in vivo. *Cancer Res*. 2004;64:7210–5.
110. Gebauer K, Brown P, Varigos G. Topical diclofenac in hyaluronan gel for the treatment of solar keratoses. *Australas J Dermatol*. 2003;44:40–3.
111. Rivers JK, Arlette J, Shear N, Guenther L, Carey W, Poulin Y. Topical treatment of actinic keratoses with 3.0% diclofenac in 2.5% hyaluronan gel. *Br J Dermatol*. 2002;146:94–100.
112. Wolf JE Jr, Taylor JR, Tschen E, Kang S. Topical 3.0% diclofenac in 2.5% hyaluronan gel in the treatment of actinic keratoses. *Int J Dermatol*. 2001;40:709–13.
113. McEwan LE, Smith JG. Topical diclofenac/hyaluronic acid gel in the treatment of solar keratoses. *Australas J Dermatol*. 1997;38:187–9.
114. Nelson C, Rigel D, Smith S, Swanson N, Wolf J. Phase IV, open-label assessment of the treatment of actinic keratosis with 3.0% diclofenac sodium topical gel (Solaraze). *J Drugs Dermatol*. 2004;3:401–7.
115. Kose O, Koc E, Erbil AH, Caliskan E, Kurumlu Z. Comparison of the efficacy and tolerability of 3% diclofenac sodium gel and 5% imiquimod cream in the treatment of actinic keratosis. *J Dermatolog Treat*. 2008;19:159–63.
116. Zane C, Facchinetti E, Rossi MT, Specchia C, Calzavara-Pinton PG. A randomized clinical trial of photodynamic therapy with methyl aminolaevulinate vs. diclofenac 3% plus hyaluronic acid gel for the treatment of multiple actinic keratoses of the face and scalp. *Br J Dermatol*. 2014;170:1143–50.
117. Steeb T, Wessely A, Harlass M, Heppt F, Koch EAT, Leiter U, et al. A systematic review and meta-analysis of interventions for actinic keratosis from post-marketing surveillance trials. *J Clin Med*. 2020;9:2253.
118. Gollnick H, Dirschka T, Ostendorf R, Kerl H, Kunstfeld R. Long-term clinical outcomes of imiquimod 5% cream vs. diclofenac 3% gel for actinic keratosis on the face or scalp: a pooled analysis of two randomized controlled trials. *J Eur Acad Dermatol Venereol*. 2020;34:82–9.
119. Stockfleth E, Harwood CA, Serra-Guillen C, Larsson T, Osterdal ML, Skov T. Phase IV head-to-head randomized controlled trial comparing ingenol mebutate 0.015% gel with diclofenac sodium 3% gel for the treatment of actinic keratosis on the face or scalp. *Br J Dermatol*. 2018;178:433–42.
120. Smolinski MP, Bu Y, Clements J, Gelman IH, Hegab T, Cutler DL, et al. Discovery of novel dual mechanism of action Src signaling and tubulin polymerization inhibitors (KX2-391 and KX2-361). *J Med Chem*. 2018;61:4704–19.
121. Blauvelt A, Kempers S, Lain E, Schlesinger T, Tyring S, Forman S, et al. Phase 3 trials of tirbanibulin ointment for actinic keratosis. *N Engl J Med*. 2021;384:512–20.
122. Cheng B, Veerabagu S, Miller CJ, Sobanko JF, Shin TM, Higgins HW 2nd, et al. A comparison of invasive squamous cell carcinoma greater than 1 year after treatment with 5-fluorouracil, imiquimod, or photodynamic therapy with aminolevulinic acid. *J Am Acad Dermatol*. 2022;87:592–6.
123. Heppt MV, Dykukha I, Graziadio S, Salido-Vallejo R, Chapman-Rounds M, Edwards M. Comparative efficacy and safety of tirbanibulin for actinic keratosis of the face and scalp in Europe: a systematic review and network meta-analysis of randomized controlled trials. *J Clin Med*. 2022;11:1654.
124. Mpourazanis G, Kunschake W, Vogiatzis R, Papalexis P, Georgakopoulou VE, Ntritsos G, et al. The role and effectiveness of photodynamic therapy on patients with actinic keratosis: a systematic review and meta-analysis. *Cureus*. 2022;14:e26390.
125. Koch EAT, Wessely A, Steeb T, Berking C, Heppt MV. Safety of topical interventions for the treatment of actinic keratosis. *Expert Opin Drug Saf*. 2021;20:801–14.
126. Pflugfelder A, Welter AK, Leiter U, Weide B, Held L, Eigentler TK, et al. Open label randomized study comparing 3 months vs. 6 months treatment of actinic keratoses with 3% diclofenac in 2.5% hyaluronic acid gel: a trial of the German Dermatologic Cooperative Oncology Group. *J Eur Acad Dermatol Venereol*. 2012;26:48–53.
127. Dohil MA. Efficacy, safety, and tolerability of 4% 5-fluorouracil cream in a novel patented aqueous cream containing peanut oil once daily compared with 5% 5-fluorouracil cream twice daily: meeting the challenge in the treatment of actinic keratosis. *J Drugs Dermatol*. 2016;15:1218–24.
128. Stockfleth E. The importance of treating the field in actinic keratosis. *J Eur Acad Dermatol Venereol*. 2017;31(Suppl 2):8–11.
129. Hadley G, Derry S, Moore RA. Imiquimod for actinic keratosis: systematic review and meta-analysis. *J Invest Dermatol*. 2006;126:1251–5.
130. Hanke CW, Beer KR, Stockfleth E, Wu J, Rosen T, Levy S. Imiquimod 2.5% and 3.75% for the treatment of actinic keratoses: results of two placebo-controlled studies of daily application to the face and balding scalp for two 3-week cycles. *J Am Acad Dermatol*. 2010;62:573–81.
131. Ulrich C, Johannsen A, Rowert-Huber J, Ulrich M, Sterry W, Stockfleth E. Results of a randomized, placebo-controlled safety and efficacy study of topical diclofenac 3% gel in organ transplant patients with multiple actinic keratoses. *Eur J Dermatol*. 2010;20:482–8.
132. Perrett CM, McGregor JM, Warwick J, Karran P, Leigh IM, Proby CM, et al. Treatment of post-transplant premalignant skin disease: a randomized inpatient comparative study of 5-fluorouracil cream and topical photodynamic therapy. *Br J Dermatol*. 2007;156:320–8.
133. Ulrich C, Bichel J, Euvrard S, Guidi B, Proby CM, van de Kerkhof PC, et al. Topical immunomodulation under systemic immunosuppression: results of a multicentre, randomized, placebo-controlled safety and efficacy study of imiquimod 5% cream for the treatment of actinic keratoses in kidney, heart, and liver transplant patients. *Br J Dermatol*. 2007;157(Suppl 2):25–31.
134. Santos-Juanes J, Esteve A, Mas-Vidal A, Coto-Segura P, Salgueiro E, Gomez E, et al. Acute renal failure caused by imiquimod 5% cream in a renal transplant patient: review of the literature on side effects of imiquimod. *Dermatology*. 2011;222:109–12.
135. Morton CA, Szeimies RM, Basset-Seguín N, Calzavara-Pinton P, Gilaberte Y, Haedersdal M, et al. European dermatology forum guidelines on topical photodynamic therapy 2019 part 1: treatment delivery and established indications - actinic keratoses, Bowen's disease and basal cell carcinomas. *J Eur Acad Dermatol Venereol*. 2019;33:2225–38.
136. Morton CA, Szeimies RM, Basset-Seguín N, Calzavara-Pinton PG, Gilaberte Y, Haedersdal M, et al. European Dermatology Forum guidelines on topical photodynamic therapy 2019 part 2: emerging indications - field cancerization, photorejuvenation and inflammatory/infective dermatoses. *J Eur Acad Dermatol Venereol*. 2020;34:17–29.
137. Heerfordt IM, Philipsen PA, Wulf HC. Bringing the gentle properties of daylight photodynamic therapy indoors: a systematic review of efficacy and safety. *Photodiagnosis Photodyn Ther*. 2022;39:102858.
138. Dirschka T, Radny P, Dominicus R, Mensing H, Bruning H, Jenne L, et al. Photodynamic therapy with BF-200 ALA for the treatment of actinic keratosis: results of a multicentre, randomized, observer-blind phase III study in comparison with a registered methyl-5-aminolaevulinate cream and placebo. *Br J Dermatol*. 2012;166:137–46.
139. Steeb T, Wessely A, Petzold A, Brinker TJ, Schmitz L, Leiter U, et al. Evaluation of long-term clearance rates of interventions for actinic keratosis: a systematic review and network meta-analysis. *JAMA Dermatol*. 2021;157:1066–77.
140. Lacour JP, Ulrich C, Gilaberte Y, Von Felbert V, Basset-Seguín N, Dreno B, et al. Daylight photodynamic therapy with methyl aminolevulinic acid is effective and nearly painless in treating actinic keratoses: a randomised, investigator-blinded, controlled, phase III study throughout Europe. *J Eur Acad Dermatol Venereol*. 2015;29:2342–8.

141. Rubel DM, Spelman L, Murrell DF, See JA, Hewitt D, Foley P, et al. Daylight photodynamic therapy with methyl aminolevulinate cream as a convenient, similarly effective, nearly painless alternative to conventional photodynamic therapy in actinic keratosis treatment: a randomized controlled trial. *Br J Dermatol*. 2014;171:1164–71.
142. Dirschka T, Ekanayake-Bohlig S, Dominicus R, Aschoff R, Herrera-Ceballos E, Botella-Estrada R, et al. A randomized, intraindividual, non-inferiority, phase III study comparing daylight photodynamic therapy with BF-200 ALA gel and MAL cream for the treatment of actinic keratosis. *J Eur Acad Dermatol Venereol*. 2019;33:288–97.
143. Rasanen JE, Neittaanmaki N, Ylitalo L, Hagman J, Rissanen P, Ylianttila L, et al. 5-aminolaevulinic acid nanoemulsion is more effective than methyl-5-aminolaevulinate in daylight photodynamic therapy for actinic keratosis: a nonsponsored randomized double-blind multicentre trial. *Br J Dermatol*. 2019;181:265–74.
144. Malvey J. A new vision of actinic keratosis beyond visible clinical lesions. *J Eur Acad Dermatol Venereol*. 2015;29(Suppl 1):3–8.
145. Steeb T, Wessely A, Leiter U, French LE, Berking C, Heppt MV. The more the better? An appraisal of combination therapies for actinic keratosis. *J Eur Acad Dermatol Venereol*. 2020;34:727–32.
146. Steeb T, Niesert AC, French LE, Berking C, Heppt MV. Microneedling-assisted photodynamic therapy for the treatment of actinic keratosis: results from a systematic review and meta-analysis. *J Am Acad Dermatol*. 2020;82:515–9.
147. Jorizzo J, Weiss J, Furst K, VandePol C, Levy SF. Effect of a 1-week treatment with 0.5% topical fluorouracil on occurrence of actinic keratosis after cryosurgery: a randomized, vehicle-controlled clinical trial. *Arch Dermatol*. 2004;140:813–6.
148. Jorizzo J, Weiss J, Vamvakias G. One-week treatment with 0.5% fluorouracil cream prior to cryosurgery in patients with actinic keratoses: a double-blind, vehicle-controlled, long-term study. *J Drugs Dermatol*. 2006;5:133–9.
149. Heppt MV, Steeb T, Leiter U, Berking C. Efficacy of photodynamic therapy combined with topical interventions for the treatment of actinic keratosis: a meta-analysis. *J Eur Acad Dermatol Venereol*. 2019;33:863–73.
150. Dahle DO, Grotmol T, Leivestad T, Hartmann A, Midtvedt K, Reisaeter AV, et al. Association between pretransplant cancer and survival in kidney transplant recipients. *Transplantation*. 2017;101:2599–605.
151. Allen NC, Martin AJ, Snaird VA, Eggins R, Chong AH, Fernandez-Penas P, et al. Nicotinamide for skin-cancer chemoprevention in transplant recipients. *N Engl J Med*. 2023;388:804–12.
152. Heppt MV, Steeb T, Niesert AC, Zacher M, Leiter U, Garbe C, et al. Local interventions for actinic keratosis in organ transplant recipients: a systematic review. *Br J Dermatol*. 2019;180:43–50.
153. Hasan ZU, Ahmed I, Matin RN, Homer V, Lear JT, Ismail F, et al. Topical treatment of actinic keratoses in organ transplant recipients: a feasibility study for SPOT (squamous cell carcinoma prevention in organ transplant recipients using topical treatments). *Br J Dermatol*. 2022;187:324–37.
154. Dragieva G, Prinz BM, Hafner J, Dummer R, Burg G, Binswanger U, et al. A randomized controlled clinical trial of topical photodynamic therapy with methyl aminolaevulinate in the treatment of actinic keratoses in transplant recipients. *Br J Dermatol*. 2004;151:196–200.
155. Ulrich C, Busch JO, Meyer T, Nindl I, Schmook T, Sterry W, et al. Successful treatment of multiple actinic keratoses in organ transplant patients with topical 5% imiquimod: a report of six cases. *Br J Dermatol*. 2006;155:451–4.
156. Togsverd-Bo K, Halldin C, Sandberg C, Gonzalez H, Wennberg AM, Sorensen SS, et al. Photodynamic therapy is more effective than imiquimod for actinic keratosis in organ transplant recipients: a randomized intraindividual controlled trial. *Br J Dermatol*. 2018;178:903–9.
157. Massey PR, Schmults CD, Li SJ, Arron ST, Asgari MM, Bouwes Bavinck JN, et al. Consensus-based recommendations on the prevention of squamous cell carcinoma in solid organ transplant recipients: a Delphi consensus statement. *JAMA Dermatol*. 2021;157:1219–26.
158. Gupta G, Dirschka T. Squamous cell carcinoma and its precursors. *Rook's Textbook of Dermatology*, Chapter 142. 10th ed., 2024, in press.
159. Griffiths CEM, Barker J, Bleiker TO, Hussain W, Simpson RC, editors. Chapter 142: Squamous cell carcinoma and its precursors. In: *Rooks textbook of dermatology*. 10th ed. Hoboken, NJ: Wiley; 2024.
160. Walker JL, Siegel JA, Sachar M, Pomerantz H, Chen SC, Swetter SM, et al. 5-fluorouracil for actinic keratosis treatment and chemoprevention: a randomized controlled trial. *J Invest Dermatol*. 2017;137:1367–70.
161. Chen AC, Martin AJ, Choy B, Fernandez-Penas P, Dalziel RA, McKenzie CA, et al. A phase 3 randomized trial of nicotinamide for skin-cancer chemoprevention. *N Engl J Med*. 2015;373:1618–26.

How to cite this article: Kandolf L, Peris K, Malvey J, Mosterd K, Heppt MV, Fargnoli MC, et al. European consensus-based interdisciplinary guideline for diagnosis, treatment and prevention of actinic keratoses, epithelial UV-induced dysplasia and field cancerization on behalf of European Association of Dermato-Oncology, European Dermatology Forum, European Academy of Dermatology and Venereology and Union of Medical Specialists (Union Européenne des Médecins Spécialistes). *J Eur Acad Dermatol Venereol*. 2024;00:1–24. <https://doi.org/10.1111/jdv.19897>