

Treatment of cefuroxime-induced neurotoxicity with continuous venovenous haemofiltration

Citation for published version (APA):

van Dam, D. G. H. A., Burgers, D. M. T., Foudraïne, N., Janssen, P. K. C., Neef, C., & le Noble, J. L. M. L. (2017). Treatment of cefuroxime-induced neurotoxicity with continuous venovenous haemofiltration. *Netherlands Journal of Medicine*, 75(1), 32-34. <http://www.njmonline.nl/getpdf.php?id=1801>

Document status and date:

Published: 01/01/2017

Document Version:

Publisher's PDF, also known as Version of record

Document license:

Taverne

Please check the document version of this publication:

- A submitted manuscript is the version of the article upon submission and before peer-review. There can be important differences between the submitted version and the official published version of record. People interested in the research are advised to contact the author for the final version of the publication, or visit the DOI to the publisher's website.
- The final author version and the galley proof are versions of the publication after peer review.
- The final published version features the final layout of the paper including the volume, issue and page numbers.

[Link to publication](#)

General rights

Copyright and moral rights for the publications made accessible in the public portal are retained by the authors and/or other copyright owners and it is a condition of accessing publications that users recognise and abide by the legal requirements associated with these rights.

- Users may download and print one copy of any publication from the public portal for the purpose of private study or research.
- You may not further distribute the material or use it for any profit-making activity or commercial gain
- You may freely distribute the URL identifying the publication in the public portal.

If the publication is distributed under the terms of Article 25fa of the Dutch Copyright Act, indicated by the "Taverne" license above, please follow below link for the End User Agreement:

www.umlib.nl/taverne-license

Take down policy

If you believe that this document breaches copyright please contact us at:

repository@maastrichtuniversity.nl

providing details and we will investigate your claim.

Treatment of cefuroxime-induced neurotoxicity with continuous venovenous haemofiltration

D.G.H.A. van Dam^{1*}, D.M.T. Burgers², N. Foudraïne¹, P.K.C. Janssen^{2,3}, C. Neef^{3,4}, J.L.M.L. le Noble^{1,4}

Department of ¹Intensive Care, ²Clinical Pharmacy, VieCuri Medical Centre, the Netherlands, Department of ³Clinical Pharmacy, ⁴Pharmacology and Toxicology, Maastricht University Medical Centre, Maastricht, the Netherlands, *corresponding author: tel.: + 31 (0)77-3205555, fax: + 31 (0)77-3206514, email: ddam@viecuri.nl

ABSTRACT

A 61-year-old woman with decreased consciousness, myoclonus, tremors, nystagmus and bradypnoea, due to cefuroxime-induced neurotoxicity, was admitted to the intensive care unit. Continuous venovenous haemofiltration (CVVH) rapidly reduced plasma cefuroxime concentrations and improved neurological manifestations within the next few hours. Retrospective pharmacokinetic assessment showed a total cefuroxime clearance of 166 ml/min during the CVVH.

KEYWORDS

Cefuroxime, haemofiltration, intoxication, neurotoxicity, toxicokinetics

INTRODUCTION

Cefuroxime is a semi-synthetic second-generation cephalosporin. It has a molecular weight of 446 D, a volume of distribution (V_d) of 9.3-12.8 l, and an elimination half-life ranging between 61.6-80 minutes. It is 33-41% protein bound and predominantly (95%) excreted unchanged in the urine.^{1,2}

Cephalosporins, especially cefepime, ceftazidime, and cefuroxime, are associated with neurological disturbances such as mild encephalopathy, status epilepticus, and coma.^{3,4} Elderly patients with renal insufficiency and prior neurological disease are prone to the development of cephalosporin-induced neurotoxicity (CIN). Management of CIN comprises cessation of cephalosporin use, initiation of anticonvulsive therapy if indicated, and intermittent haemodialysis in those with compromised renal function.⁴

What was known on this topic?

Cephalosporin-induced neurotoxicity (CIN) is a rare complication characterised by multiple neurological disturbances ranging from mild encephalopathy to coma. CIN predominantly occurs in elderly patients with compromised renal function and prior neurological disease. In general, CIN can be managed with supportive therapy. However, in case of severe intoxication, renal replacement therapy may be necessary to ensure a rapid decline in serum cefuroxime levels.

What does this add?

This report describes a case of cefuroxime-induced neurotoxicity that was successfully treated with continuous venovenous haemofiltration (CVVH) in an intensive care unit. Furthermore, we performed pharmacokinetic modelling to show that the cefuroxime was effectively cleared due to the CVVH. We obtained a total cefuroxime clearance of 166 ml/min. This case is the first to describe CVVH as a practical, technically feasible and beneficial therapy for CIN.

In general, in haemodynamically unstable ICU patients with oliguric/anuric acute kidney injury, continuous venovenous haemofiltration (CVVH) is the preferred method of renal replacement therapy.⁵ Due to its low molecular weight, low protein binding and low V_d , cefuroxime has a high removal rate; therefore, it is expected that serum cefuroxime levels will normalise rapidly to prevent severe neurotoxicity.⁶

We describe a patient with cefuroxime-induced neurotoxicity who was successfully treated with CVVH and regional citrate anticoagulation. Pharmacokinetic

parameters were calculated using MwPharm 3.86 software (MwPharm BV, Zuidhorn, Netherlands).

CASE REPORT

A 61-year-old woman (height 174 cm; weight 80 kg) with a history of chronic obstructive pulmonary disease (Gold IV), type II diabetes mellitus, seronegative rheumatoid arthritis and contracted kidneys was admitted to our hospital. She had suffered a 14-day fever, right flank pain and acute-on-chronic renal insufficiency (serum creatinine 199 $\mu\text{mol/l}$). She had rose-coloured, cloudy urine.

Abdominal computed tomography scan showed right-sided urolithiasis with urethral obstruction and pelvic dilatation; therefore, a nephrostomy catheter was placed in her right kidney. Intravenous cefuroxime (1500 mg, 3 times daily) and a single dose of gentamicin (400 mg) were administered for suspected urinary tract infection. After four days with clinical improvement, her urine production decreased and the serum creatinine increased (316 $\mu\text{mol/l}$). Pus (*P. mirabilis*) was observed in the catheter; therefore, two more nephrostomy catheters were placed to drain a suspected pyonephrosis.

Nine days after admission, neurological examination showed a decline in the Glasgow Coma Scale score ($E_3M_5V_4$), horizontal nystagmus, myoclonus and tremors, which necessitated ICU admission. Laboratory examinations showed the following: serum creatinine 440 $\mu\text{mol/l}$; C-reactive protein, 95 mg/l; leucocyte count, $15.8 \times 10^9/l$; and serum albumin level, 17 g/l. CIN was suspected and, therefore, cefuroxime was discontinued and CVVH (Prismaflex[®]) with citrate anticoagulation was started with an AN69ST filter. Blood flow and net ultrafiltration were set at 180 ml/min and 0 ml, respectively. Prismocitrate[®] and Priskasol[®] were delivered prefilter and postfilter (2640 and 400 ml/hour, respectively). Plasma cefuroxime concentration at CVVH initiation was 173 mg/l and rapidly declined over the next few hours (*figure 1*). The next day, her general condition improved and all the neurological symptoms resolved completely. Before and after CVVH initiation, total cefuroxime clearance was 11 and 166 ml/min, respectively (*figure 2*). Elimination half-life was 16.8 and 2.6 hours, respectively. V_d of the central compartment was 9.4 l/kg and total V_d was estimated to be 15-20 litres.

DISCUSSION

We report the case of a critically ill patient with cefuroxime-induced neurotoxicity due to acute-on-chronic renal insufficiency, who was successfully treated with CVVH. CVVH was preferred over intermittent haemodialysis because of haemodynamic instability and

Figure 1. Pharmacokinetic simulation of plasma cefuroxime concentration following intravenous administration of cefuroxime (1500 mg, 3 times daily). Intravenous administration was stopped after nine days and CVVH was initiated. The diamond symbols represent the actual/measured plasma cefuroxime concentrations

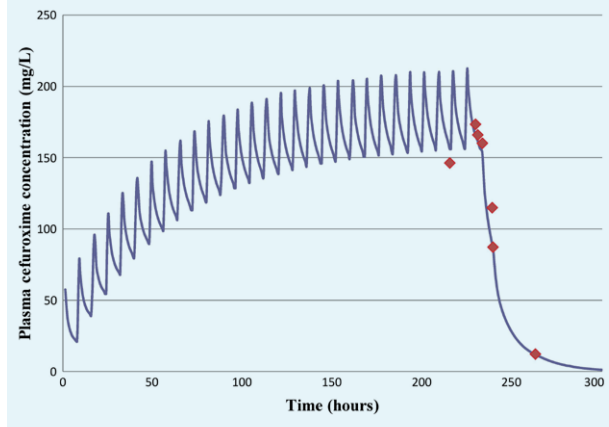
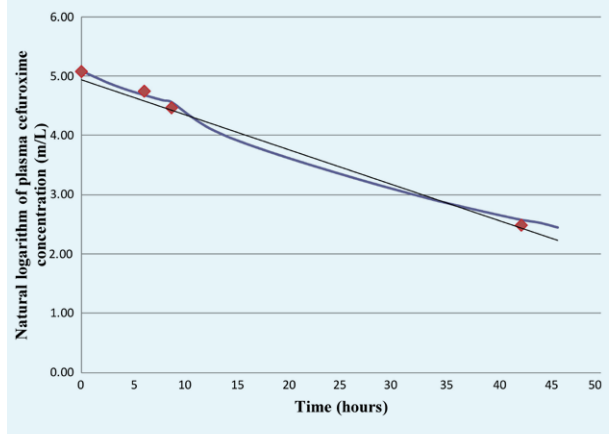


Figure 2. Natural logarithm of plasma cefuroxime concentration following the initiation of CVVH. The diamond symbols represent the actual/measured plasma cefuroxime concentrations. The natural log transformed plasma cefuroxime concentration was calculated as $Lc(C) = -0.059 \cdot \text{time (hours)} + 4.94$ and R^2 was 0.980



practical feasibility. As this type of renal replacement therapy is frequently used in the ICU, it is important to show proof of principle in ICU patients. This is because most published reports describe only intermittent haemodialysis as the rescue therapy for CIN.⁷

The most remarkable finding from toxicokinetic assessments was a rapid decrease in plasma cefuroxime levels to non-toxic levels as a result of the CVVH, which led to a full clinical recovery. We also found that 100% of the 1500-mg single dose of cefuroxime was removed within 2.5

hours following the initiation of CVVH indicating effective cefuroxime removal during neurotoxicity.

There are several possible explanations for the results of the pharmacokinetic assessment. Firstly, the pharmacokinetic characteristics of cefuroxime, including its low molecular weight, hydrophilicity, low V_d and low protein binding, made cefuroxime easily accessible for its clearance during CVVH. Secondly, changes in the protein binding of cefuroxime and thus cefuroxime displacement favours convective clearance during CVVH. The displacement can be caused by acidosis or the levels of bilirubin, uraemic inhibitors, free fatty acids or other displacing drugs in the blood.⁶ Thirdly, we observed an increase in total V_d , which is frequently observed in critically ill patients due to capillary leak and oedema. These might have contributed to cefuroxime removal.⁸ Because of persistent anuria, clearance by the native kidneys was nil. Furthermore, in a previous study adsorption of cefuroxime by the haemofilter was found insignificant in a similar cohort of patients.⁹

Other possible factors that might have contributed to the total body clearance of cefuroxime during the CVVH were the use of a haemofilter with a larger membrane surface area, a higher blood flow and a higher effluent rate than those used in previous studies. Reports on CIN are uncommon and our finding of an extremely high cefuroxime peak level of 173 mg/l is unique. A previous study reported that, immediately after a 1.0-g bolus injection of cefuroxime was administered to healthy adults, the mean peak plasma concentration of cefuroxime was 99.2 ± 9.6 mg/l. The study also reported that the peak concentrations were not associated with any adverse effects. However, exposure to high concentrations of cefuroxime for a prolonged time might increase the susceptibility to neurotoxicity as was observed in our patient.¹⁰ Dose adjustments are not necessary in a steady state, especially when cefuroxime is administered continuously. It is advised to measure the serum concentration once to be sure that the concentration is in the effective but not in the toxic range. However, changes in renal function may mandate adjustments.⁹

A limitation of the present case is that we did not measure the pre- and post-filter cefuroxime levels; therefore, we could not calculate the sieving coefficient of the haemofilter employed. This also makes it unfeasible to calculate the endogenous and extracorporeal cefuroxime

clearances. Finally, we did not correct for protein-bound cefuroxime in plasma.

CONCLUSION

This is the first case to describe CVVH as a practical, technically feasible, safe and effective alternative to acute haemodialysis in cefuroxime-induced neurotoxicity concomitant with anuric renal failure. We showed that the central (vascular) compartment acts as a reservoir of cefuroxime due to the high cefuroxime fraction that is unbound. In addition, the pharmacokinetic analysis was useful in monitoring the concentration and effective clearance of cefuroxime.

DISCLOSURES

The authors declare no conflicts of interest.

REFERENCES

1. Smith BR, LeFrock JL. Cefuroxime: antimicrobial activity, pharmacology, and clinical efficacy. *Ther Drug Monit.* 1983;5:149-60.
2. Gower PE, Dash CH. The pharmacokinetics of cefuroxime after intravenous injection. *Eur J Clin Pharmacol.* 1977;12:221-7.
3. Snavely SR, Hodges GR. The neurotoxicity of antibacterial agents. *Ann Intern Med.* 1984;101:92-104.
4. Grill MF, Maganti R. Cephalosporin-induced neurotoxicity: clinical manifestations, potential pathogenic mechanisms, and the role of electroencephalographic monitoring. *Ann Pharmacother.* 2008;42:1843-50.
5. Ricci Z, Ronco C, D'Amico G, et al. Practice patterns in the management of acute renal failure in the critically ill patient: an international survey. *Nephrol Dial Transplant.* 2006;21:690-6.
6. Bouman CS. Antimicrobial dosing strategies in critically ill patients with acute kidney injury and high-dose continuous veno-venous hemofiltration. *Curr Opin Crit Care.* 2008;14:654-9.
7. Chatellier D, Jourdain M, Mangalaboyi J, et al. Cefepime-induced neurotoxicity: an underestimated complication of antibiotherapy in patients with acute renal failure. *Intensive Care Med.* 2002;28:214-7.
8. Carlier M, Noe M, Roberts JA, et al. Population pharmacokinetics and dosing simulations of cefuroxime in critically ill patients: non-standard dosing approaches are required to achieve therapeutic exposures. *J Antimicrob Chemother.* 2014;69:2797-803.
9. Janssen PK, Foudraïne NA, Burgers DM, et al. Population pharmacokinetics of cefuroxime in critically ill patients receiving continuous venovenous hemofiltration with regional citrate anticoagulation and a phosphate-containing replacement fluid. *Ther Drug Monit.* 2016.
10. Foord RD. Cefuroxime: human pharmacokinetics. *Antimicrob Agents Chemother.* 1976;9:741-7.