

Staging procedures in patients with mucinous borderline tumors of the ovary do not reveal peritoneal or omental disease

Citation for published version (APA):

De Decker, K., Speth, S., ter Brugge, H. G., Bart, J., Massuger, L. F. A. G., Kleppe, M., Kooreman, L. F. S., Kruitwagen, R. F. P. M., & Kruse, A-J. (2017). Staging procedures in patients with mucinous borderline tumors of the ovary do not reveal peritoneal or omental disease. *Gynecologic Oncology*, 144(2), 285-289. <https://doi.org/10.1016/j.ygyno.2016.11.035>

Document status and date:

Published: 01/02/2017

DOI:

[10.1016/j.ygyno.2016.11.035](https://doi.org/10.1016/j.ygyno.2016.11.035)

Document Version:

Publisher's PDF, also known as Version of record

Document license:

Taverne

Please check the document version of this publication:

- A submitted manuscript is the version of the article upon submission and before peer-review. There can be important differences between the submitted version and the official published version of record. People interested in the research are advised to contact the author for the final version of the publication, or visit the DOI to the publisher's website.
- The final author version and the galley proof are versions of the publication after peer review.
- The final published version features the final layout of the paper including the volume, issue and page numbers.

[Link to publication](#)

General rights

Copyright and moral rights for the publications made accessible in the public portal are retained by the authors and/or other copyright owners and it is a condition of accessing publications that users recognise and abide by the legal requirements associated with these rights.

- Users may download and print one copy of any publication from the public portal for the purpose of private study or research.
- You may not further distribute the material or use it for any profit-making activity or commercial gain
- You may freely distribute the URL identifying the publication in the public portal.

If the publication is distributed under the terms of Article 25fa of the Dutch Copyright Act, indicated by the "Taverne" license above, please follow below link for the End User Agreement:

www.umlib.nl/taverne-license

Take down policy

If you believe that this document breaches copyright please contact us at:

repository@maastrichtuniversity.nl

providing details and we will investigate your claim.



Staging procedures in patients with mucinous borderline tumors of the ovary do not reveal peritoneal or omental disease



Koen De Decker^{a,*}, Stephanie Speth^b, Henk G. ter Brugge^a, Joost Bart^c, Leon F.A.G. Massuger^d, Marjolein Kleppe^b, Loes F.S. Kooreman^e, Roy F.P.M. Kruitwagen^{b,f}, Arnold-Jan Kruse^{a,b,f}

^a Isala Hospital, Department of Obstetrics and Gynecology, Zwolle, The Netherlands

^b Maastricht University Medical Center, Department of Obstetrics and Gynecology, Maastricht, The Netherlands

^c Isala Hospital, Department of Pathology, Zwolle, The Netherlands

^d Radboud University Nijmegen Medical Centre, Department of Obstetrics and Gynecology, Nijmegen, The Netherlands

^e Maastricht University Medical Center, Department of Pathology, Maastricht, The Netherlands

^f GROW, School for Oncology and Developmental Biology, Maastricht University Medical Center, Maastricht, The Netherlands

HIGHLIGHTS

- No peritoneal and omental implantations were identified in case of mBOTs.
- Staging in case of mucinous borderline tumours of the ovary may be omitted.
- Recurrence with malignant disease is rare after mBOT.
- The value of posttreatment surveillance seems limited in patients with mBOT.

ARTICLE INFO

Article history:

Received 4 September 2016

Received in revised form 11 November 2016

Accepted 21 November 2016

Available online 23 November 2016

Keywords:

Mucinous

Borderline tumors of the ovary

Staging procedure

Review

ABSTRACT

Objectives. Staging in case of a borderline tumor of the ovary (BOT) is a controversial issue. Upstaging is not uncommon, but this occurs especially with presumed stage I serous borderline tumors. There are only a few documented cases of BOTs of non-serous histology that were not confined to the ovary. The aim of this study was to assess the incidence of non-invasive and invasive implants in the omentum and other (extra)pelvic peritoneal surfaces in patients with a mucinous BOT (mBOT).

Methods. A retrospective cohort study was performed in three hospitals in the Netherlands. All patients with a histopathological diagnosis of mBOT diagnosed from January 1st 1990 to December 1st 2015 were identified and included when the inclusion criteria were met.

Results. In total, 74 patients were included. Of these 74 patients, 46 (62.2%) underwent a staging procedure. In 12 (26.1%) patients, only omental tissue was obtained, in 32 (69.6%) patients, omental tissue and peritoneal biopsies were obtained and in two (4.3%) patients, only peritoneal biopsies were obtained. No implants were seen upon microscopic examination in any of the patients. Two patients (3%) developed a recurrence.

Conclusions. Because no extra-ovarian disease was found, staging procedures in the case of an mBOT may be omitted. However, the actual perioperative decision for staging or not should be taken in the context of a frozen section diagnosis, which is not always accurate and straightforward. Recurrence with malignant disease is rare after mBOT. The value of post-treatment surveillance seems limited after bilateral salpingo-oophorectomy.

© 2016 Elsevier Inc. All rights reserved.

1. Introduction

Borderline ovarian tumors (BOTs) are non-invasive tumors that display greater epithelial proliferation and cytological atypia than benign

tumors of the ovary, but less than their malignant counterparts [1]. There is no agreement on a single, unifying concept for BOTs, as borderline serous tumors comprise a unique group of tumors that is biologically distinct from borderline tumors of other histological types. Borderline serous tumors can present at an advanced stage (FIGO ovarian cancer staging), whereas borderline ovarian tumors of non-serous histology (e.g. endometrioid, mucinous, clear cell, or Brenner) are usually confined to the ovary [2–4]. Patients with early stage disease who are

* Corresponding author at: Isala Clinics, Department of Obstetrics and Gynecology, PO Box 10400, 8000 GK Zwolle, The Netherlands.

E-mail address: k.de.decker@isala.nl (K. De Decker).

finished childbearing and patients with advanced stage disease are treated with radical surgery, consisting of bilateral salpingo-oophorectomy and resection of macroscopically visible peritoneal lesions. Some recommend total abdominal hysterectomy and lymphadenectomy as well. In addition, appendectomy is often performed in case of mucinous BOT [3,5], whereas others limit this to patients in which the appendix has an abnormal appearance macroscopically [6,7]. For patients who want to preserve their fertility, conservative surgery consisting of unilateral salpingo-oophorectomy or cystectomy in cases of bilateral ovarian involvement or when the disease develops in the only remaining ovary may be a valuable alternative. Furthermore, a proper staging procedure for BOT is recommended for the detection of peritoneal implants and is defined as an exploration of the entire abdominal cavity with peritoneal washings, infracolic omentectomy, and multiple peritoneal biopsies [5, 8]. This is based on the fact that 14.8–27.0% of patients with BOTs are upstaged, mostly because of positive peritoneal cytology, the discovery of non-invasive peritoneal implants, or in rare instances because of invasive peritoneal implants [9–11]. In these studies, upstaging because of peritoneal implants only involved patients with serous BOTs (sBOTs). There are only a few documented cases of BOTs of non-serous histology that were not confined to the ovary [12–14]. Thus far, guidelines for the staging procedures for BOT do not take into account the differences between the different histological types of BOTs.

To understand the value of a staging procedure in patients with an mBOT, it would be interesting to know the incidence of patients with biopsies positive for extra-ovarian disease. Therefore, the aim of the present study was to evaluate the histopathology of the peritoneal biopsies and/or omentum in patients with mucinous ovarian tumors with borderline features.

2. Patients and methods

The present retrospective cohort study was performed in three hospitals in the Netherlands (Isala Hospital, Zwolle, Radboud University Nijmegen Medical Centre, Nijmegen, and Maastricht University Medical Centre in Maastricht). Patients with an mBOT diagnosed from January 1st 1990 to December 1st 2015 were identified using the Dutch nationwide histo- and cytopathology data network and archive (PALGA data registration system) with the search terms “mucinous”, “borderline”, “ovarian”, “staging”, “peritoneum”, and “omentum” [15]. Patients diagnosed with a mucinous borderline tumor of the ovary in which it could be determined whether a staging procedure was performed during surgery were included in the study. Patients with a proven secondary tumor of the ovary (i.e. a metastasis from a primary mucinous appendiceal carcinoma) were excluded.

After inclusion, the following variables were retrieved from the patient files and the pathology and surgery reports: the macroscopic appearance of the omentum and (extra)pelvic peritoneal surface, whether or not an omentectomy was performed or omental biopsies were obtained, whether or not peritoneal biopsies were obtained, the number of anatomic sites where peritoneal biopsies were collected, the results of the pathological examination of the peritoneal biopsies and omentum, whether or not intra-epithelial carcinoma was seen in the tumor, whether or not there was a recurrence, the location(s) of recurrences, and the duration of follow-up. The macroscopic appearance of the omentum and (extra)pelvic peritoneal surface was classified as abnormal when there was adhesion to the tumor of the ovary or when tumor-like structures were palpable.

In case of an mBOT with intra-epithelial carcinoma, or a recurrent tumor, the number of samples per cm of tumor, assessed by the pathologist, was also recorded in the database.

3. Results

In total, 83 patients with an mBOT were identified (Fig. 1). Nine of them were excluded because patient files and pathology reports were

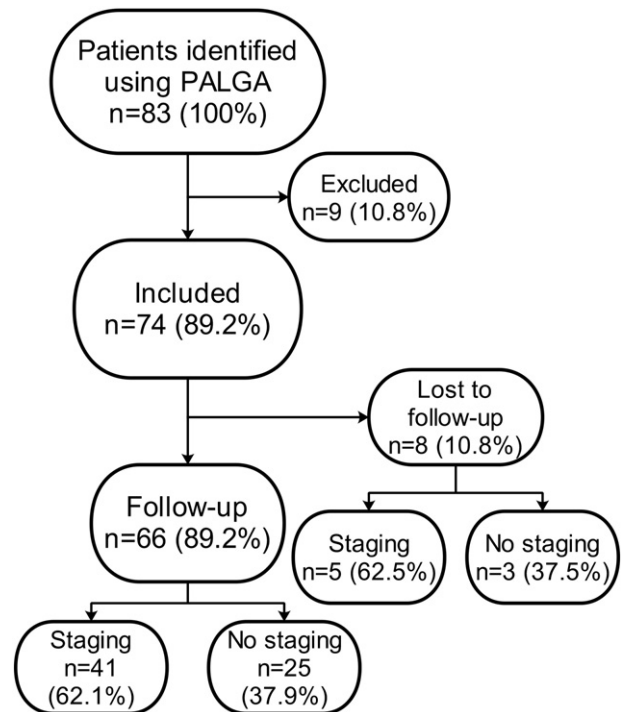


Fig. 1. The total number of patients identified with PALGA, the number of in- and exclusions and the number of patients that had follow-up visitations, as well as the number of patients that was lost to follow-up.

not available, or did not contain any information about the surgical procedure. Most often, this was because they were treated at another hospital and only pathology specimens of the primary tumor were revised by the pathologist at one of the included centers. The remaining 74 patients (mean age of 52 years) with an mBOT were included in the study. Of these 74 patients, eight patients (10.8%) were recorded as lost to follow-up. For instance, this was because only pathology reports and no follow-up data were available (only the revision of specimens obtained after surgery at another hospital), no follow-up visits were scheduled because of the patient's characteristics (i.e. age, health status), or because patients had their follow-up visits at another hospital.

In 54 of 74 patients (73.0%), a bilateral salpingo-oophorectomy was performed. A unilateral salpingo-oophorectomy was performed in 17 patients (23.0%) and a cystectomy in three patients (4.1%). Microscopic evaluation of the tumors revealed intra-epithelial carcinoma in 11 of the 74 patients (14.9%). In one patient (1.4%), it could not be determined whether there was intra-epithelial carcinoma or not. The mean number of histologic samples in these 11 cases was 0.9 (range 0.3–1.5) per cm tumor.

There was some degree of staging in 46 of 74 patients (62.2%), which means that there was at least an infracolic omentectomy, collection of omental biopsies, or collection of peritoneal biopsies during surgery (Fig. 2). For these 46 patients, the macroscopic appearance of the omentum and (extra)pelvic peritoneal surface was described in the surgery report in 31 (67.4%) and 33 (71.1%) patients, respectively. Macroscopic abnormalities of the omentum were described in 5 patients and macroscopic abnormalities of the (extra)pelvic peritoneal surfaces were described in 7 patients. In 28 of 74 patients (37.8%), no staging procedure was performed. The most common reasons for not performing a staging procedure were either a discordant (benign) frozen section (13 of 28 patients) or a less aggressive approach to surgery (11 of 28 patients). In the latter, no frozen sections were obtained and the diagnosis of mBOT was made after pathological examination of the ovary. In one patient, no staging procedure was performed because of an inconclusive frozen section, and in another because of the patient's cardiac and hematological condition. In two patients, it was unclear

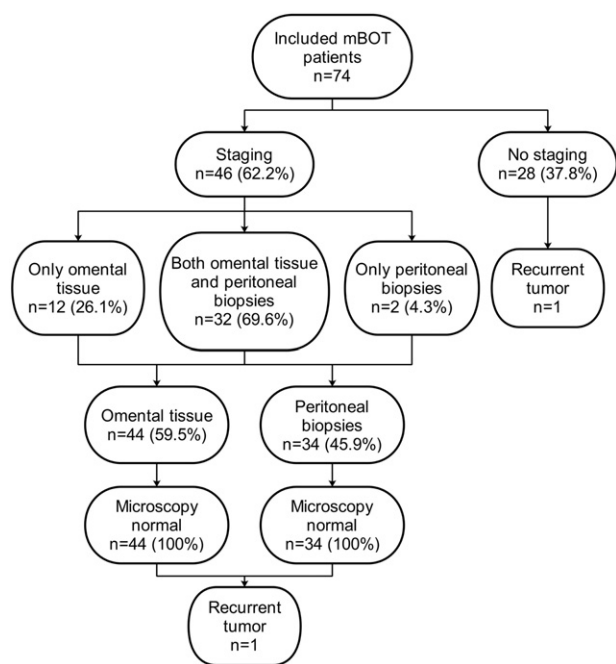


Fig. 2. Graphical representation of the total number of mBOT patients included in the study, as well as the frequency of staging, the frequency of omentectomies/omental biopsies, the frequency of peritoneal biopsies, the results of microscopic examination and the number of recurrences.

why no staging procedure had been performed. In 16 of the 28 patients (57.1%), in whom no staging procedure was performed, the macroscopic appearance of the omentum and (extra)pelvic peritoneal surface was described in the surgery report and no macroscopic abnormalities were seen. With respect to the 46 patients with some degree of staging, 32 patients (69.6%) had both omentectomy/omental biopsies and collection of peritoneal biopsies. In 12 patients (26.1%), only an omentectomy was performed/omental biopsies were obtained, and in two patients (4.3%), only peritoneal biopsies were obtained. The median number of peritoneal biopsies was three with a range from one to eight. The anatomic sites where biopsies were collected included both paracolic gutters, the recto- and vesico-uterine pouch, the small bowel mesentery, both ovarian fossa and the diaphragm, both left and right. Pathological examination of the omental and (extra)pelvic peritoneal specimens of 44 (59.6%) and 34 (45.9%) patients, respectively, showed no microscopic abnormalities, even in the patients in whom the omentum and/or (extra)pelvic peritoneal surface was described as macroscopically abnormal.

With respect to the patients who were recorded as lost to follow-up ($n = 8$, 10.8%), five patients (63.5%) were in the “staging group” and three patients (37.5%) were in the “non-staging group” (Fig. 1). The median follow-up duration for the remaining 66 patients, of which 41 (62.1%) were staged, was 3 years and 10 months (range 1 month to 12 years and 9 months). With respect to the duration of follow-up, there was no significant difference between the “staging” and “non-staging group” ($p = 0.776$, Mann-Whitney U test).

Two patients (3.0%) had a recurrence in the vaginal vault (Fig. 2). The first patient (mBOT with the presence of intra-epithelial carcinoma) underwent complete staging during initial surgery and no abnormalities were seen in the omentum and peritoneal biopsies (at the location of both pelvic side walls and both paracolic gutters). A total of 16 samples was taken from the primary tumor with a diameter of 15 cm. Surgical spill was reported during the procedure. The recurrence was detected 5 years, 8 months after the primary procedure. Pathological examination of the obtained biopsies showed a mucinous invasive adenocarcinoma of the intestinal type. The treatment consisted of chemotherapy (six cycles of paclitaxel and carboplatin). Eleven months

later, a second recurrence at the same location was discovered and treated with whole abdominal radiation therapy. Two and half years later, the patient underwent a lung lobe resection because of a metastasis of the mucinous invasive adenocarcinoma and now (7 years later) is still alive without evidence of another recurrence or metastasis.

The recurrence of the second patient was detected 8 years after a bilateral salpingo-oophorectomy (mBOT with the presence of intra-epithelial carcinoma) without a staging procedure, and was resected via laparotomy. In this patient, a total abdominal hysterectomy had been performed 9 years previously. The pathological examination showed a recurrence of the mBOT. One year and eleven months later, there was a second recurrence. Biopsies of the vaginal vault were obtained and pathological examination this time showed a mucinous invasive adenocarcinoma of the intestinal type. Despite four cycles of paclitaxel and carboplatin, there was tumor progression and eventually sonographic suspicion of liver metastasis. The patient died within a few months after discovery of the second recurrence. It was unknown how many samples were taken for each cm of the primary tumor.

4. Discussion

Staging in cases of a borderline tumor of the ovary (BOT) is a controversial issue. Some advocate proper staging procedures, because it has been shown that 14.8–27.0% of BOTs will be upstaged [5,9–11]. Others may argue that the outcomes of staging procedures do not have any consequences for treatment, and staging is therefore not indicated. Moreover, upstaging most often involves tumors with a serous type histology [1,3–5,11]. Only a few cases of mBOTs with extra-ovarian disease are known [14]. However, the literature is scarce. The current study evaluated the incidence of non-invasive and invasive implants in the omentum and other (extra)pelvic peritoneal surfaces in 74 patients with an mBOT. None of the patients with a final histopathological diagnosis of mBOT who underwent any kind of surgical staging procedure ($n = 46$) had disease in the omentum and/or peritoneal biopsies. This indicates the limited value of performing a staging procedure in case of an mBOT. This is also supported by the fact that only one out of 28 patients in the present study in whom no staging procedure was performed developed a recurrence.

It is very important to underscore that the results of our study account for patients with a final histopathological diagnosis of mBOT. Unfortunately, in daily practice, one has to deal with frozen section diagnosis. It has been shown that, in 10% of patients with a borderline ovarian tumor diagnosis based on a frozen section, a definitive diagnosis has been adapted into a histopathological diagnosis of invasive ovarian cancer [16]. In these cases, a subsequent relaparotomy is needed for adequate staging purposes. Besides this discrepancy between frozen sections and the final histopathological diagnosis, in daily practice, one has to deal with a frozen section diagnosis that is not always straightforward. For example, one has to cope with diagnoses like minimum borderline tumor of the ovary, borderline tumor of the ovary, but cannot exclude invasive cancer or borderline ovarian tumor and strong suspicion of invasive disease. In this scenario, staging may be recommended in view of the considerable chance of invasive cancer as the final histopathological diagnosis, with the goal of preventing a second procedure. This scenario should be discussed of course with the patient to obtain informed consent before the procedure. It is clear that surgeons and pathologists experienced in frozen section diagnosis, their nuances, and consequences for further treatment are very important to minimize over- and under treatment.

The finding of no extra-ovarian disease in cases of mBOT in our study is supported by others. Camatte et al. found no peritoneal or omental implants in their own series of patients with an mBOT, as well as in the series of patients of the studies they reviewed ($n = 65$) [11,17,18]. A more recent study by Kristensen et al. investigated the role of omentectomy and peritoneal biopsies with respect to BOTs in 75 patients who were completely staged [9]. Twenty-three patients had an

mBOT and, again, peritoneal or omental implants were not found in the specimens obtained during surgery. Karlsen et al. recently found invasive implants in five of 535 patients with an mBOT [14]. However, in these cases, it was not specified whether there was upstaging of presumed stage I disease or presumed advanced stage disease and, furthermore, the location of the implants and the macroscopic appearance of the tissue resected during surgery was unknown. Thus, in all studies so far, extra-ovarian lesions were found in staging procedures for mBOTs in only a few patients. This indicates the limited value of performing a staging procedure in case of a presumed stage I mBOT. This is also supported by the fact that only one out of 28 patients in the present study, in whom no staging procedure was performed, developed a recurrence.

Recommendations for follow-up in cases with an mBOT differ. Some do recommend follow-up only in patients in whom a cystectomy was performed or when the contralateral ovary is still present, while others recommend long-term follow-up irrespective of the presence of a contralateral ovary, as recurrences can develop years after initial treatment [4,5,19]. Moreover, some extrapolate guidelines for the post-treatment surveillance of patients with ovarian cancer to patients with mBOTs [20]. In the present study, two patients (3.0%) developed recurrent disease during follow-up, one patient with an additional complete staging procedure but with spill during operation, and one without a staging procedure. These patients developed a recurrence in the vaginal vault within a period of 6–8 years. In the literature, recurrence rates of mBOTs vary between 4.2 and 13% [21,22]. In a study by Khunamornpong et al., six patients (4.2%) developed a recurrent tumor, of whom two patients underwent a bilateral salpingo-oophorectomy. All of them were completely staged, five were diagnosed with a stage IC mBOT (surface growth with or without positive cytology, positive cytology alone or earlier rupture of the tumor), and in one patient it was uncertain whether there was stage IA, IB or IC disease [22]. Koskas et al. found 13 recurrences (13%), of whom only three patients underwent a bilateral salpingo-oophorectomy. Four patients were completely staged at initial surgery (two patients with stage IA disease and two patients with stage IC disease) [21]. Therefore, follow-up may be limited to patients with positive ascites or peritoneal washings and/or spill during surgery. This could be supplemented with patients after conservative surgery (only cystectomy or one ovary remaining in situ) or mBOTs with intra-epithelial carcinoma [21,23,24]. As shown in the literature and in the present study, recurrent tumors of mBOTs are rare after treatment with bilateral salpingo-oophorectomy.

In the present study, in both patients presenting with a recurrence, an invasive component was eventually found. In general, recurrent tumors after a borderline tumor of the ovary are more likely to present as borderline tumors instead of invasive carcinomas [19,20,23]. However, Koskas et al. and Khunamornpong et al. have shown that 6 of 13 (46.2%) and 4 of 6 (66.7%) recurrent tumors presented as malignant disease, respectively, so it seems that mBOTs are more prone to recur as invasive adenocarcinomas than serous borderline tumors of the ovary [21, 22]. Overall, it has been shown that about 1.6% of patients presenting with an mBOT develop a recurrent tumor presenting as invasive carcinoma [19]. There are several possible explanations for the finding of recurrent invasive disease during follow-up. Firstly, a diagnostic or sampling error may have occurred, in which case the mucinous adenocarcinoma was misdiagnosed as an mBOT during the initial procedure. However, because all tissue samples of both patients obtained during the initial surgery were revised, in which again no malignant components were found during the microscopic examination, this theory seems unlikely. Surgical spill might have been an additional risk factor for the recurrence as well in case of a primary mucinous adenocarcinoma. Secondly, the mucinous adenocarcinoma may have developed from a distinct area with endocervicosis or a transitional-type epithelium at the fallopian tube-peritoneal junction. In this scenario, the finding of a mucinous adenocarcinoma during follow-up may not be directly related to the previous mBOT. Endocervicosis and a transitional-type

epithelium at the fallopian tube-peritoneal junction seem to be site of origin in cases of mucinous ovarian tumors, apart from metastasis of malignancies of the gastro-intestinal tract [25–28]. As shown by Kruse et al., primary extra-ovarian mucinous carcinomas of the endocervical-like type, without ovarian involvement, can develop from endocervicosis [25].

The current study has some limitations. Because mBOTs are rare tumors, the number of patients included in the study is relatively small. Therefore, it would be an added value to include more hospitals in future studies concerning mBOTs to enlarge the study population. A considerable number of patients (37.8%) underwent no staging procedure. Theoretically, extra-ovarian disease could have been missed. However, there was only one recurrence in the unstaged group, which did not significantly differ from the staged group, considering the duration of follow-up. In four patients, omental biopsies were obtained, instead of performing an omentectomy. One may argue that implants could have been missed by not removing at least the infracolic omentum. However, Arie et al. critically appraised the role of omentectomy in the staging of apparent early stage epithelial ovarian carcinoma. In their review, they cite a study by Usubutun et al., which states that a thorough macroscopic examination of the omentum and collection of three to five random omental samples may be sufficient for appropriate staging [29,30]. Also, with respect to the peritoneal biopsies, the degree of staging differed among the patients, with the number of biopsies ranging from one to eight. Thus, although in a considerable number of patients there was no staging procedure or a suboptimal staging procedure, the overall low number of recurrences confirms that the majority of cases of mBOT are confined to the ovary. Furthermore, given the current guidelines, the number of samples taken for each cm tumor might be considered as less adequate. Unfortunately, these guidelines were not common practice in the past. So, in theory, bigger portions of expansile or invasive adenocarcinoma might have been missed. Still, the majority of patients with an intra-epithelial carcinoma did not develop a recurrence (9 of 11 patients; 81.8%) Finally, the present study had a retrospective design, and thus one must accept missing data (i.e. follow-up, information regarding the staging procedure, macroscopic appearance during inspection of the abdominal cavity), which weakens the conclusions of the study.

In patients with final histopathological diagnosis of mBOT, no extra-ovarian disease was found. Staging procedures in cases of mBOT may be omitted, but the actual perioperative decision to perform staging or not should be made considering that frozen section diagnosis is not always accurate and straightforward. Recurrence with malignant disease is rare after an mBOT. The value of post-treatment surveillance seems limited in patients with mBOT after bilateral salpingo-oophorectomy.

Conflict of interest statement

All of the authors of this manuscript certify that there are no conflicts of interest.

References

- [1] R.J. Kurman, International Agency for Research on Cancer (IARC), WHO Classification of Tumours of Female Reproductive Organs, fourth ed. IARC, Lyon, 2014.
- [2] Denny L. Quinn M. FIGO cancer report 2015. *Int. J. Gynaecol. Obstet.* 2015; 131 Suppl 2:S75.
- [3] W.R. Hart, Borderline epithelial tumors of the ovary. *Mod. Pathol.* 18 (Suppl. 2) (2005) S33–S50.
- [4] M. Akeson, B.M. Zetterqvist, K. Dahllof, A.M. Jakobsen, M. Brannstrom, G. Horvath, Population-based cohort follow-up study of all patients operated for borderline ovarian tumor in western Sweden during an 11-year period. *Int. J. Gynecol. Cancer* 18 (3) (2008) 453–459.
- [5] I. Cadron, K. Leunen, T. Van Gorp, F. Amant, P. Neven, I. Vergote, Management of borderline ovarian neoplasms. *J. Clin. Oncol.* 25 (2007) 2928–2937.
- [6] M. Kleppe, J. Bruls, T. Van Gorp, L. Massuger, B.F. Slangen, K.K. Van de Vijver, et al., Mucinous borderline tumours of the ovary and the appendix: a retrospective study and overview of the literature. *Gynecol. Oncol.* 133 (2) (2014) 155–158.
- [7] A. Ozcan, E. Toz, V. Turan, C. Sahin, A. Kopuz, C. Ata, et al., Should we remove the normal-looking appendix during operations for borderline mucinous ovarian neoplasms?: a retrospective study of 129 cases. *Int. J. Surg.* 18 (2015) 99–103.
- [8] J.S. Berek, C. Crum, M. Friedlander, Cancer of the ovary, fallopian tube, and peritoneum. *Int. J. Gynaecol. Obstet.* 131 (Suppl. 2) (2015 Oct) S111–S122.

- [9] G.S. Kristensen, D. Schledermann, O. Mogensen, K.M. Jochumsen, The value of random biopsies, omentectomy, and hysterectomy in operations for borderline ovarian tumors, *Int. J. Gynecol. Cancer* 24 (5) (2014) 874–879.
- [10] R. Fauvet, J. Boccara, C. Dufournet, E. David-Montefiore, C. Poncelet, E. Darai, Restaging surgery for women with borderline ovarian tumors: results of a French multicenter study, *Cancer* 100 (6) (2004) 1145–1151.
- [11] S. Camatte, P. Morice, A. Thoury, V. Fourchette, P. Pautier, C. Lhomme, et al., Impact of surgical staging in patients with macroscopic “stage I” ovarian borderline tumors: analysis of a continuous series of 101 cases, *Eur. J. Cancer* 40 (12) (2004) 1842–1849.
- [12] K.R. Kim, H.I. Lee, S.K. Lee, J.Y. Ro, S.J. Robboy, Is stromal microinvasion in primary mucinous ovarian tumors with “mucin granuloma” true invasion? *Am. J. Surg. Pathol.* 31 (4) (2007) 546–554.
- [13] K.R. Lee, R.H. Young, The distinction between primary and metastatic mucinous carcinomas of the ovary: gross and histologic findings in 50 cases, *Am. J. Surg. Pathol.* 27 (3) (2003) 281–292.
- [14] N.M. Karlsen, M.A. Karlsen, E. Hogdall, L. Nedergaard, I.J. Christensen, C. Hogdall, Relapse and disease specific survival in 1143 Danish women diagnosed with borderline ovarian tumours (BOT), *Gynecol. Oncol.* 142 (1) (2016 Jul) 50–53.
- [15] M. Casparie, A.T. Tiebosch, G. Burger, H. Blauwgeers, A. van de Pol, J.H. van Krieken, et al., Pathology databanking and biobanking in The Netherlands, a central role for PALGA, the nationwide histopathology and cytopathology data network and archive, *Cell. Oncol.* 29 (1) (2007) 19–24.
- [16] T. Pongsuvareeyakul, S. Khunamornpong, J. Settakorn, K. Sukpan, P. Suprasert, S. Siriaunkgul, Accuracy of frozen-section diagnosis of ovarian mucinous tumors, *Int. J. Gynecol. Cancer* 22 (3) (2012) 400–406.
- [17] D.D. Snider, G.C. Stuart, J.G. Nation, D.I. Robertson, Evaluation of surgical staging in stage I low malignant potential ovarian tumors, *Gynecol. Oncol.* 40 (2) (1991) 129–132.
- [18] R. Land, L. Perrin, J. Nicklin, Evaluation of restaging in clinical stage 1A low malignant potential ovarian tumours, *Aust. N. Z. J. Obstet. Gynaecol.* 42 (4) (2002) 379–382.
- [19] G. Zanetta, S. Rota, S. Chiari, C. Bonazzi, G. Bratina, C. Mangioni, Behavior of borderline tumors with particular interest to persistence, recurrence, and progression to invasive carcinoma: a prospective study, *J. Clin. Oncol.* 19 (10) (2001) 2658–2664.
- [20] UpToDate: Borderline Ovarian Tumors http://www.uptodate.com/contents/borderline-ovarian-tumors?source=search_result&search=borderline+ovarian+tumors&selectedTitle=1-9.
- [21] M. Koskas, C. Uzan, S. Gouy, P. Pautier, C. Lhomme, C. Haie-Meder, et al., Prognostic factors of a large retrospective series of mucinous borderline tumors of the ovary (excluding peritoneal pseudomyxoma), *Ann. Surg. Oncol.* 18 (1) (2011) 40–48.
- [22] S. Khunamornpong, J. Settakorn, K. Sukpan, P. Suprasert, S. Siriaunkgul, Mucinous tumor of low malignant potential (“borderline” or “atypical proliferative” tumor) of the ovary: a study of 171 cases with the assessment of intraepithelial carcinoma and microinvasion, *Int. J. Gynecol. Pathol.* 30 (3) (2011) 218–230.
- [23] P. Morice, C. Uzan, R. Fauvet, S. Gouy, P. Duvillard, E. Darai, Borderline ovarian tumour: pathological diagnostic dilemma and risk factors for invasive or lethal recurrence, *Lancet Oncol.* 13 (3) (2012) e103–e115.
- [24] Y. Yokoyama, T. Moriya, T. Takano, T. Shoji, O. Takahashi, K. Nakahara, et al., Clinical outcome and risk factors for recurrence in borderline ovarian tumours, *Br. J. Cancer* 94 (11) (2006) 1586–1591.
- [25] A.J. Kruse, B. Slangen, G.A. Dunselman, T. Pirens, F.C. Bakers, J.P. Baak, et al., Neoplastic transformation of endocervicosis into an extraovarian mucinous cystadenocarcinoma, *Hum. Pathol.* 42 (5) (2011) 743–748.
- [26] J.D. Seidman, A. Yemelyanova, R.J. Zaino, R.J. Kurman, The fallopian tube-peritoneal junction: a potential site of carcinogenesis, *Int. J. Gynecol. Pathol.* 30 (1) (2011) 4–11.
- [27] K.R. Cho, Ovarian cancer update: lessons from morphology, molecules, and mice, *Arch. Pathol. Lab. Med.* 133 (11) (2009) 1775–1781.
- [28] R.J. Kurman, I. Shih, Molecular pathogenesis and extraovarian origin of epithelial ovarian cancer—shifting the paradigm, *Hum. Pathol.* 42 (7) (2011) 918–931.
- [29] A.B. Arie, L. McNally, D.S. Kapp, N.N. Teng, The omentum and omentectomy in epithelial ovarian cancer: a reappraisal: part II—the role of omentectomy in the staging and treatment of apparent early stage epithelial ovarian cancer, *Gynecol. Oncol.* 131 (3) (2013) 784–790.
- [30] A. Usabutun, H.S. Ozseker, C. Himmetoglu, S. Balci, A. Ayhan, Omentectomy for gynecologic cancer: how much sampling is adequate for microscopic examination? *Arch. Pathol. Lab. Med.* 131 (10) (2007) 1578–1581.