

Definition of the Rectum

Citation for published version (APA):

D'Souza, N., Babberich, M. P. M. D. N. T., d'Hooe, A., Turet, E., Xynos, E., Beets-Tan, R. G. H., Nagtegaal, I. D., Blomqvist, L., Holm, T., Glimelius, B., Lacy, A., Cervantes, A., Glynne-Jones, R., West, N. P., Perez, R. O., Quadros, C., Lee, K. Y., Madiba, T. E., Wexner, S. D., ... Brown, G. (2019). Definition of the Rectum: An International, Expert-based Delphi Consensus. *Annals of Surgery*, 270(6), 955-959. <https://doi.org/10.1097/SLA.0000000000003251>

Document status and date:

Published: 01/12/2019

DOI:

[10.1097/SLA.0000000000003251](https://doi.org/10.1097/SLA.0000000000003251)

Document Version:

Publisher's PDF, also known as Version of record

Document license:

Taverne

Please check the document version of this publication:

- A submitted manuscript is the version of the article upon submission and before peer-review. There can be important differences between the submitted version and the official published version of record. People interested in the research are advised to contact the author for the final version of the publication, or visit the DOI to the publisher's website.
- The final author version and the galley proof are versions of the publication after peer review.
- The final published version features the final layout of the paper including the volume, issue and page numbers.

[Link to publication](#)

General rights

Copyright and moral rights for the publications made accessible in the public portal are retained by the authors and/or other copyright owners and it is a condition of accessing publications that users recognise and abide by the legal requirements associated with these rights.

- Users may download and print one copy of any publication from the public portal for the purpose of private study or research.
- You may not further distribute the material or use it for any profit-making activity or commercial gain
- You may freely distribute the URL identifying the publication in the public portal.

If the publication is distributed under the terms of Article 25fa of the Dutch Copyright Act, indicated by the "Taverne" license above, please follow below link for the End User Agreement:

www.umlib.nl/taverne-license

Take down policy

If you believe that this document breaches copyright please contact us at:

repository@maastrichtuniversity.nl

providing details and we will investigate your claim.

Definition of the Rectum

An International, Expert-based Delphi Consensus

Nigel D'Souza, MBBS, MRCS, *†‡ Michael P. M. de Neree tot Babberich, MD, § Andre d'Hoore, MD, PhD, ¶
 Emmanuel Tiret, MD, || Evaghelos Xynos, MD, PhD, ** Regina G. H. Beets-Tan, MD, PhD, ††
 Iris D. Nagtegaal, MD, PhD, ‡‡ Lennart Blomqvist, MD, PhD, §§ Torbjorn Holm, MD, PhD, §§
 Bengt Glimelius, MD, PhD, ¶¶ Antonio Lacy, MD, PhD, |||| Andres Cervantes, MD, PhD, ***
 Robert Glynne-Jones, MBBS, FRCR, ††† Nicholas P. West, PhD, FRCPath, †††† Rodrigo O. Perez, MD, PhD, §§§
 Claudio Quadros, MD, PhD, ¶¶¶ Kil Yeon Lee, MD, PhD, ||||| Thandinkosi E. Madiba, MBChB, PhD, ****
 Steven D. Wexner, MD, PhD, †††† Julio Garcia-Aguilar, MD, PhD, ††††† Dushyant Sahani, MBBS, MD, §§§§
 Brendan Moran, MCh, FRCSI, ¶¶¶¶ Paris Tekkis, MD, FRCS, †‡ Harm J. Rutten, MD, PhD, ||||| *****
 Pieter J. Tanis, MD, PhD, § Theo Wiggers, MD, PhD, †††††
 and Gina Brown, MD, FRCR †‡

Background: The wide global variation in the definition of the rectum has led to significant inconsistencies in trial recruitment, clinical management, and outcomes. Surgical technique and use of preoperative treatment for a cancer of the rectum and sigmoid colon are radically different and dependent on the local definitions employed by the clinical team. A consensus definition of the rectum is needed to standardise treatment.

Methods: The consensus was conducted using the Delphi technique with multidisciplinary colorectal experts from October, 2017 to April, 2018.

Results: Eleven different definitions for the rectum were used by participants in the consensus. Magnetic resonance imaging (MRI) was the most frequent modality used to define the rectum (67%), and the preferred modality for 72% of participants. The most agreed consensus landmark (56%) was "the sigmoid take-off," an anatomic, image-based definition of the junction of the mesorectum and mesocolon. In the second round, 81% of participants agreed that the sigmoid take-off as seen on computed tomography or MRI achieved consensus, and that it could be implemented in their institution. Also, 87% were satisfied with the sigmoid take-off as the consensus landmark.

Conclusion: An international consensus definition for the rectum is the point of the sigmoid take-off as visualized on imaging. The sigmoid take-off can be identified as the mesocolon elongates as the ventral and horizontal course of the sigmoid on axial and sagittal views respectively on cross-sectional imaging. Routine application of this landmark during multidisciplinary team discussion for all patients will enable greater consistency in tumour localisation.

Keywords: anatomy, MRI, rectum, sigmoid

(Ann Surg 2019;270:955–959)

From the *Croydon University Hospital, London, UK; †Royal Marsden NHS Foundation Trust, London, UK; ‡Imperial College, London, UK; §Amsterdam University Medical Centers, University of Amsterdam, the Netherlands; ¶University Clinic Leuven, Belgium; ||Hospital Saint Antoine, Paris, France; **Interclinic Hospital of Heraklion, Greece; ††The Netherlands Cancer Institute, Amsterdam, the Netherlands; ‡‡Radboud Medical Centre, Nijmegen, the Netherlands; §§Karolinska University Hospital, Stockholm, Sweden; ¶¶Uppsala University, Sweden; ||||Hospital Clinic, Barcelona, Spain; ***CIBERONC, Biomedical Research Institute INCLIVA, University of Valencia; †††Mount Vernon Hospital, London, UK; ††††University of Leeds, UK; §§§University of Sao Paulo School of Medicine, Brazil; ¶¶¶Aristides Maltez Hospital, Salvador, Brazil; |||||Kyung Hee University Medical Centre, Seoul, South Korea; ****University of Kwa-Zulu Natal, South Africa; ††††Cleveland Clinic Florida, FL; †††††Memorial Sloan-Kettering Cancer Center, New York, USA; §§§§Massachusetts General Hospital, Boston, MA; ¶¶¶¶Basingstoke Hospital, UK; |||||Catherina Ziekenhuis, Eindhoven, the Netherlands; *****GROW: School of Developmental Biology and Oncology, University of Maastricht, the Netherlands; and †††††University Medical Center Groningen, Groningen, The Netherlands.

Author contributions: N.D.'S., M.D.N.B., T.W., and G.B. designed and conducted the study. N.D.'S. and M.D.N.B. acquired and analyzed the data, produced the figures and tables, and wrote the manuscript. N.D.'S. and M.D.N.B. were equal contributors. All authors contributed to data interpretation, revision of the manuscript and approval of the final draft. G.B. is guarantor of the work.

Funding: G.B.: National Institute for Health Research (NIHR) Biomedical Research Centre at the Royal Marsden, the Institute of Cancer Research and grant funding from the Pelican Cancer Foundation; N.D.'S.: As per G.B., and Croydon Colorectal Research Fellowship; N.W.: Yorkshire Cancer Research; A.C.: Grant PI15/02180 to Andrés Cervantes from Fondo de Investigaciones Sanitarias (Instituto de Salud Carlos III) from the Spanish Government and CIBERONC; B.G.: Swedish Cancer Society.

The authors declare no conflict of interests.

Supplemental digital content is available for this article. Direct URL citations appear in the printed text and are provided in the HTML and PDF versions of this article on the journal's Web site (www.annalsofsurgery.com).

Reprints: Nigel D'Souza, MBBS, MRCS, Department of Gastrointestinal Imaging, Royal Marsden NHS Foundation Trust, Downs Road, Sutton SM2 5PT, UK. E-mail: Nigel.D'Souza@nhs.net.

Copyright © 2019 Wolters Kluwer Health, Inc. All rights reserved.

ISSN: 0003-4932/19/27006-0955

DOI: 10.1097/SLA.0000000000003251

The variation in the definition of the rectum poses a problem for researchers, clinicians, and patients. A number of different landmarks have been used globally in trials^{1–5} and clinical practice guidelines^{6–11} to distinguish the rectum from the sigmoid. Understanding the optimal treatment for cancers of the upper rectum or distal sigmoid cannot be accomplished without an unambiguous, accurate, and reproducible landmark to which the location of the tumor can be related. From a practical viewpoint, distinguishing the sigmoid colon from the rectum is important in planning preoperative staging techniques, neo-adjuvant treatment strategies, and surgical approaches which differ substantially between sigmoid cancer and rectal cancer. As a consequence of important advances in diagnostic and staging techniques over the past decades and the emergence of neoadjuvant therapeutic options, it is timely to focus on an updated and uniform definition of the rectum. Therefore, the primary aim of this study was to achieve an international consensus on the modern definition of the rectum from the sigmoid colon. The secondary aim was to establish the variation in the existing definition of the rectum.

METHODS

On the basis of definitions of the rectum currently used in the literature, a Delphi consensus survey was conducted using an online tool (surveymonkey.com). The Delphi technique is a widely used

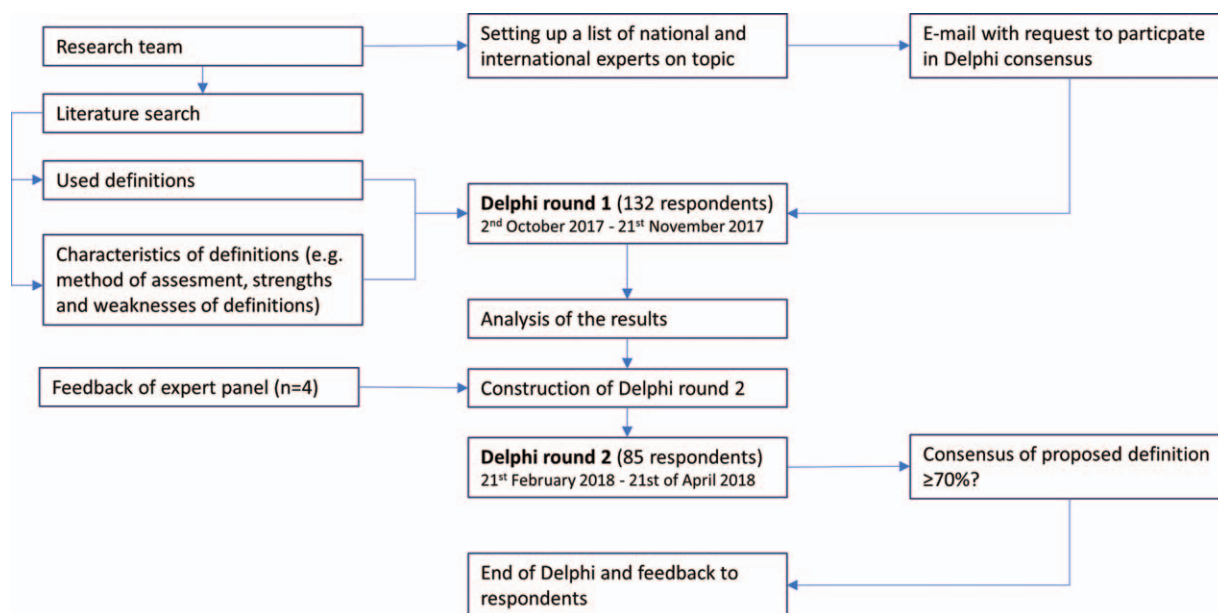


FIGURE 1. Delphi consensus flowchart.

consensus method that allows a large group of individuals to achieve consensus on a complex problem effectively by structuring the group communication process.¹² The survey was disseminated to leading academics and practitioners in all colorectal multidisciplinary team (MDT) specialties (surgery, radiology, medical oncology, clinical oncology, and pathology) on all continents via e-mail. Participants were encouraged to invite further specialists on this topic to join the Delphi survey. Members of the national associations of colorectal surgeons in Great Britain and the Netherlands were also invited to participate in the survey. The Delphi technique was to be repeated for 3 rounds or until a consensus of over 70% of participants was reached (see Fig. 1, and online addendum for further details, <http://links.lww.com/SLA/B598>). Logistic regression analysis was used to investigate whether participant specialty or country affected voting with STATA (StataCorp. 2017; *Stata Statistical Software: Release 15*. College Station, TX: StataCorp LLC).

RESULTS

Round 1

There were 132 experts who responded to the invitation to take part in the survey. The majority (60%) were colorectal surgeons. All members of the MDT responded including surgeons (specialist rectal, general, surgical oncologist, or retired), gastroenterologists, radiologists (specialist colorectal or general), medical oncologists, radiation therapists (clinical oncologists), and pathologists. All 6 continents were represented in the survey, with the majority of participants from the countries of the survey authors (36% UK, 31% Netherlands).

Over 90% of clinicians thought it was important to define the proximal extent of the rectum. The most common reasons were to determine eligibility for neoadjuvant therapy (75%), to counsel patients about their functional and oncological prognosis (43%), and to ensure adequate volumes of rectal cancer surgery (27%).

Magnetic resonance imaging (MRI) was the most commonly available modality to define the rectum (98%), followed

by flexible endoscopy (86%) and computed tomography (CT) (80%). Pragmatically, MRI was used in over 67% of institutions to define the rectum, followed by rigid endoscopy (10%) and flexible endoscopy (8%).

Over 11 different pragmatic definitions were used in every day clinical practice (Fig. 2). The most commonly employed definitions were 15 cm from the anal verge (36%), the anterior peritoneal reflection (15%), and the sacral promontory (12%).

After a summary of published evidence for and against different landmarks, the preferred modality to define the rectum was MRI (73%), followed by intraoperative findings (13%) and rigid endoscopy (6%).

The most commonly chosen imaging-based definition was junction of mesorectum and mesocolon seen as the “sigmoid take-off” (56%), followed by 15 cm from the anal verge (14%) and the sacral promontory (10%).

Round 2

Eighty-five participants from round 1 took part in round 2, with representation of all members of the colorectal MDT, although the majority were still colorectal surgeons (62%).

The Delphi consensus definition of the rectum was agreed by 81% of participants to be the sigmoid take-off. A further 87% of participants were satisfied the sigmoid take-off could define the rectum. In total, 81% of participants believed the sigmoid take-off could be used within their own institution. No association between participant specialty, or country, with regard to their choice of definition was found (Fig. 3).

DISCUSSION

From a plethora of definitions for the rectum used globally, the sigmoid take-off—an anatomically based definition identifying the junction of the mesorectum and mesocolon—emerged as the consensus of international experts.

While experts overwhelmingly (>90%) agree it is important to define the rectum, over 11 different definitions are employed in their daily practice. No single landmark was used by 40% of

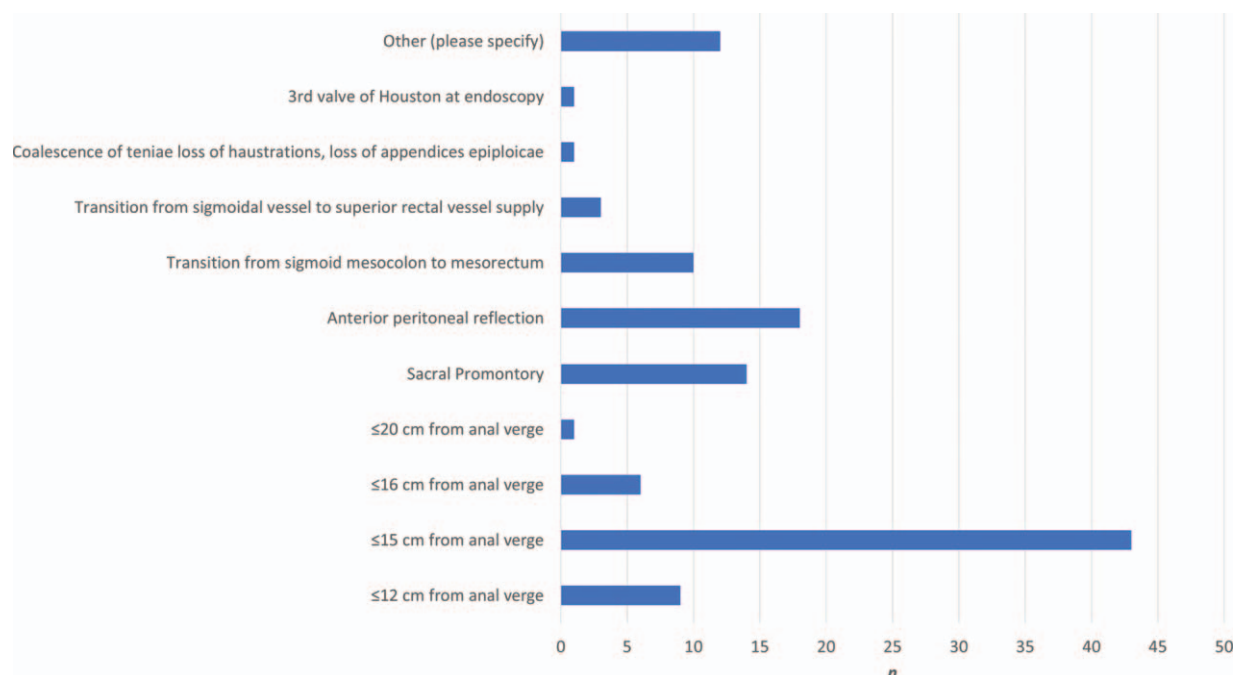
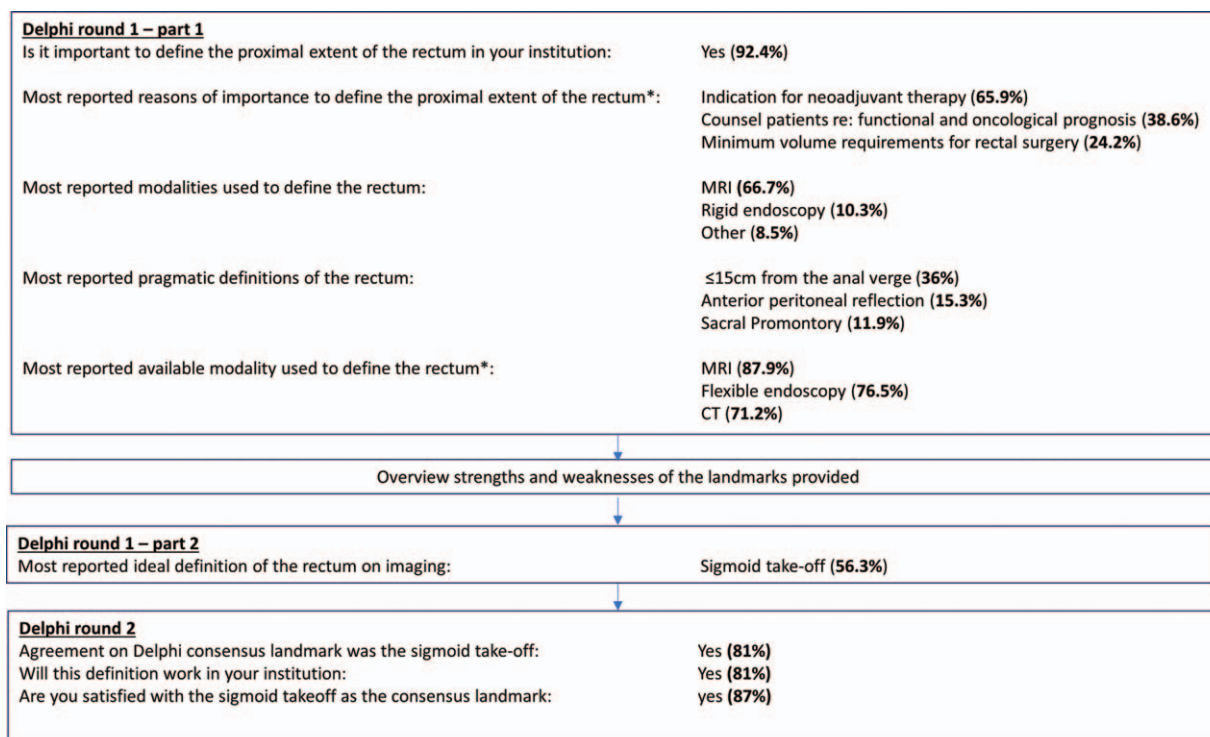


FIGURE 2. Pragmatic definitions (in daily use by experts) for the rectum.



*multiple answers possible

FIGURE 3. Summary of results.

participants. Despite metric measurements being the most commonly employed definitions, MRI was the most common modality used in clinical practice to define the rectum and available in 98% of participant institutions. The preference for an anatomical-based definition of the rectum was evident from the Delphi process as the sigmoid take-off emerged from the 11 definitions to become the consensus landmark.

Colorectal clinical practice has been based on rectal cancer trials that had different definitions of the rectum,^{1–5} and will have included varying numbers of patients with sigmoid cancer, particularly if metric measurements were used to define the rectum. Consequently, we do not know which patients benefit from neoadjuvant therapy. Inclusion of patients with sigmoid cancer in these studies may dilute the benefits of preoperative radiotherapy in rectal cancer, but it is also possible that the benefits of radiotherapy may also extend to tumors above the peritoneal reflection in the distal sigmoid.

An imaging-based anatomic definition has shown its benefits in low rectal cancer research, clinical management, and outcomes.¹³ Consistent classification of distal sigmoid and upper rectal tumors using an anatomic definition will standardize future research from trials of neoadjuvant therapy, and also local or national registries, and for MDT clinical management. The documentation of an anatomical location of the tumor could be used in the audit and accreditation of colorectal units, and reduce further inconsistencies in the use of chemoradiotherapy, or failure to adhere to treatment guidelines more generally for rectal or colon cancer.⁹

The Sigmoid Take-off

The “sigmoid take-off” is the radiological landmark that identifies the junction of the sigmoid mesocolon with the mesorectum, and therefore the sigmoid colon with the rectum. On cross-sectional imaging (CT or MRI), the sigmoid take-off can be identified on 2 views (Fig. 4).

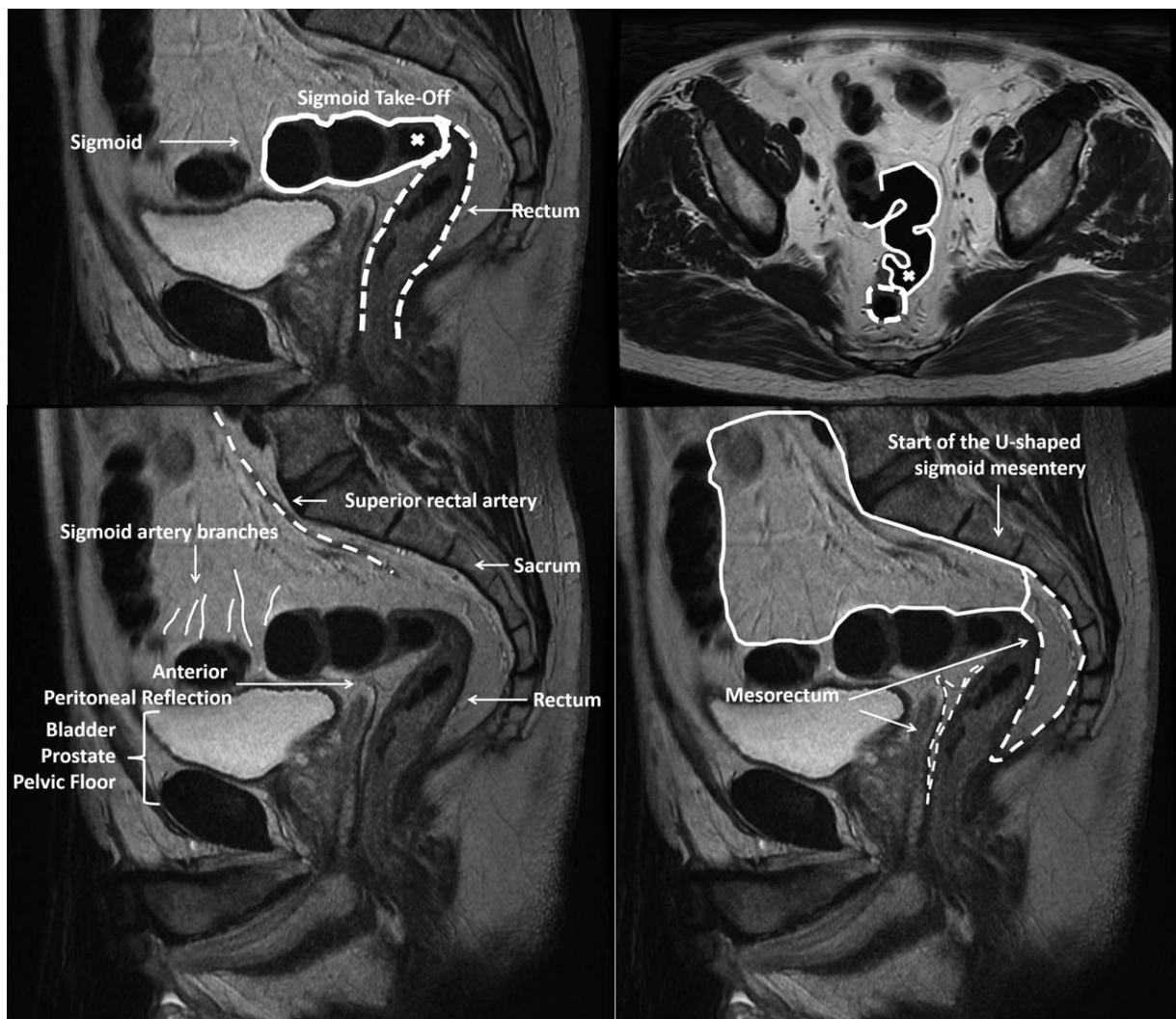


FIGURE 4. Clockwise from top left. (1) Sagittal view of the sigmoid and rectum (dashed outline): horizontal sweep of sigmoid. (2) Axial views of the sigmoid and rectum (dashed outline): ventral projection of sigmoid, when the upper mesorectum, tethered to the sacrum by the rectosacral/presacral fascia, transitions to the mesocolon. (3) U-shaped sigmoid mesocolon. (4) Spidery sigmoid arteries supply the sigmoid through its fan-shaped mesocolon. Larger caliber superior rectal artery (dashed) bifurcates and supplies the rectum through its cylindrical fatty envelope.

The sigmoid take-off has been described previously, in studies of intraoperative anatomy, and specimen analysis of the rectum. Memon et al¹⁴ identified the mesorectal-mesocolic transition as “the point that the surgeon felt there was mobility of the colon away from the vertebral column.” In a series of 109 total colectomies, Culligan et al¹⁵ found that the transition from the sigmoid mesocolon to the mesorectum corresponded to the transition from the sigmoid colon to the rectum, and the coalescence of the taenia coli.

Limitations of the Sigmoid Take-off and Future Research

The online Delphi technique enabled a global consensus to be achieved, with representation from all continents and from all members of the colorectal MDT. There was some over-representation from colorectal surgeons, and also from the UK and the Netherlands, but the consensus remained consistent in participants in all countries and across different MDT specialties on logistic regression analysis. The method was not constructed to lead to any specific outcome or definition.

An attrition rate is expected with a Delphi consensus, particularly with the larger sample size needed to sufficiently represent experts, in all specialties of the MDT, from all parts of the world. Our attrition rate of 36% to reach consensus was notably lower than other Delphi studies with smaller numbers of participants.

Implementation of this definition should occur on a routine basis for every patient during their evaluation in the colorectal MDT. Classification of tumors would be based on their anatomical location:

1. Sigmoid: distal sigmoid tumors that arise above the take-off.
2. Rectosigmoid: tumors that straddle the take-off.
3. Rectal: high/upper third rectal tumors which are located below the take-off, but above the peritoneal reflection.

Previously, each of these tumors may have been classified as “rectosigmoid,” or as rectal or sigmoid without consistency. A more consistent and accurate classification of rectal versus sigmoid cancers will be achieved using a landmark specific to each patient’s anatomy.

Optimal clinical management of these tumors could then be investigated, particularly with regards to neoadjuvant therapy, but also other strategies such as partial mesorectal excision. The sigmoid take-off offers a definition with an anatomical basis to harmonise efforts to investigate and improve outcomes.

CONCLUSIONS

An international panel of experts agreed that the sigmoid take-off as seen on CT or MRI defined the rectum. Colorectal practitioners are urged to use this intuitive, anatomical definition within their MDT to correctly localize tumors.

ACKNOWLEDGMENTS

We would like to thank the following experts for participating in both rounds of the consensus: Africa—T. Madiba; Asia—KY Lee; Europe—A. D’Hoore (Belgium), S. Laurberg (Denmark), E. Turet, JP Gerard (both France), S. Stelzner (Germany), S. Goursoyanni, G.

Pechlivanidis, J. Souglakos, C. Triantopoulou, E. Xynos, (all Greece), V. Valenti (Italy), A. Albers, R. Beets-Tan, WA Bemelman, S. Breukink, JWT. Dekker, P. Doorenbosch, TM Karsten, J. Merijerink, I. Nagtegaal, C. Punt, H. Rutten, T. Wiggers, CJH Van de Velde (all Netherlands), F. Pfeffer (Norway), A. Lacy, A. Cervantes (both Spain), T. Folm, P. Nilsson, L. Blomqvist, B. Glimelius (all Sweden), A. Acheson, A. Baxter, R. Beable, C. Beadsmoore, G. Branagan, K. Chapple, J. Conti, N. Francis, N. Gouvas, R. Glynne-Jones, SJ Holtham, I. Jenkins, S. Karandikar, S. Kapur, A. Mirnezami, B. Moran, S. Moug, J. Murphy, H. Narula, G. Nash, D. Nicol, D. O’Leary, R. Rahaman, V. Sams, I. Shaikh, Sharawdwani, O. Shihab, B Singh, J. Singleton, C. Speakman, A. Stearns, N. Stylianides, P. Tekkis, O. Warren, NP West, J. Wheeler, S. Wijeyekoon (all UK); North America—S. Wexner, D. Sahani, P. Sylla, J.A. Garcia; South America—C. Quadros, R. Perez, C. Ortega.

REFERENCES

1. Swedish Rectal Cancer Trial. Improved survival with preoperative radiotherapy in resectable rectal cancer. *N Engl J Med*. 1997;336:980–987.
2. Kapiteijn E, Marijnen CAM, Nagtegaal ID, et al. Preoperative radiotherapy combined with total mesorectal excision for resectable rectal cancer. *N Engl J Med*. 2001;345:638–646.
3. Sauer R, Becker H, Hohenberger W, et al. Preoperative versus postoperative chemoradiotherapy for rectal cancer. *N Engl J Med*. 2004;351:1731–1740.
4. Sebag-Montefiore D, Stephens RJ, Steele R, et al. Preoperative radiotherapy versus selective postoperative chemoradiotherapy in patients with rectal cancer (MRC CR07 and NCIC-CTG C016): a multicentre, randomised trial. *Lancet*. 2009;373:811–820.
5. Fleshman J, Branda M, Sargent DJ, et al. Effect of laparoscopic-assisted resection vs open resection of stage ii or iii rectal cancer on pathologic outcomes: the ACOSOG z6051 randomized clinical trial. *JAMA*. 2015;314:1346–1355.
6. Dennosuke J. General rules for clinical and pathological studies on cancer of the colon, rectum and anus. *Jpn J Surg*. 1983;13:557–573.
7. Monson J, Weiser M, Buie W, et al. Practice parameters for the management of rectal cancer (revised). *Dis Colon Rectum*. 2013;56:535–550.
8. Wagner G, Hermanek P. Organspezifische Tumordokumentation: Prinzipien und Verschlüsselungsanweisungen für Klinik und Praxis. Springer-Verlag; 2013 Apr 18.
9. Cunningham C, Leong K, Clark S, et al. Association of Coloproctology of Great Britain & Ireland (ACPGBI): Guidelines for the management of cancer of the colon, rectum and anus (2017) – Diagnosis, Investigations and Screening. *Colorectal Dis*. 2017;19:9–17.
10. Grávalos Castro C, Maurel Santasusana J, Rivera Herrero F, et al. SEOM clinical guidelines for the adjuvant treatment of colorectal cancer. *Clin Transl Oncol*. 2010;12:724–728.
11. Hwang MR, Park JW, Park S, et al. Prognostic impact of circumferential resection margin in rectal cancer treated with preoperative chemoradiotherapy. *Ann Surg Oncol*. 2014;21:1345–1351.
12. Hsu C-C, Sandford BA. The Delphi technique: making sense of consensus. *Pract Assess Res Eval*. 2007;12:1–8.
13. Battersby NJHP, Moran BJ, Stelzner S, et al., on behalf of the MERCURY II study group. Prospective validation of a low rectal cancer mri staging system and development of a local recurrence risk stratification model: the MERCURY II study. *Ann Surg*. 2016;63:751–760.
14. Memon S, Keating JP, Cooke HS, et al. A study into external rectal anatomy: improving patient selection for radiotherapy for rectal cancer. *Dis Colon Rectum*. 2009;52:87–90.
15. Culligan K, Coffey J, Kiran R, et al. The mesocolon: a prospective observational study. *Colorectal Dis*. 2012;14:421–428.