Maastricht University

New observations on the role of accessory pathways in tachycardias in man

Citation for published version (APA):

Atie, J. (1990). *New observations on the role of accessory pathways in tachycardias in man*. [Doctoral Thesis, Maastricht University]. Maastricht University. https://doi.org/10.26481/dis.19900511ja

Document status and date:
Published: 01/01/1990

DOI:
10.26481/dis.19900511ja

Document Version:
Publisher's PDF, also known as Version of record

Please check the document version of this publication:

• A submitted manuscript is the version of the article upon submission and before peer-review. There can be important differences between the submitted version and the official published version of record. People interested in the research are advised to contact the author for the final version of the publication, or visit the DOI to the publisher's website.
• The final author version and the galley proof are versions of the publication after peer review.
• The final published version features the final layout of the paper including the volume, issue and page numbers.

Link to publication

General rights
Copyright and moral rights for the publications made accessible in the public portal are retained by the authors and/or other copyright owners and it is a condition of accessing publications that users recognise and abide by the legal requirements associated with these rights.

• Users may download and print one copy of any publication from the public portal for the purpose of private study or research.
• You may not further distribute the material or use it for any profit-making activity or commercial gain
• You may freely distribute the URL identifying the publication in the public portal.

If the publication is distributed under the terms of Article 25fa of the Dutch Copyright Act, indicated by the “Taverne” license above, please follow below link for the End User Agreement:

www.umlib.nl/taverne-license

Take down policy
If you believe that this document breaches copyright please contact us at:

repository@maastrichtuniversity.nl

providing details and we will investigate your claim.

Download date: 25 Apr. 2024

New observations on the role of accessory pathways in tachycardias in man

New observations on the role of accessory pathways in tachycardias in man

PROEFSCHRIFT

ter verkrijging van de graad van doctor
aan de Rijksuniversiteit Limburg te Maastricht,
op gezag van de Rector Magnificus, Prof. Dr. F.I.M. Bonke,
volgens het besluit van het College van Dekanen,
in het openbaar te verdedigen
op vrijdag, 11 mei 1990 om 16.00 uur

door Jacob Atié

geboren te Tel-Aviv, Israel,
28 Januari 1953

Promotores	Prof. Dr. P. Brugada Prof. Dr. H.J.J. Wellens
Beoordelingscommissie	Prof. Dr. R.S. Reneman (voorzitter) Prof. Dr. M.A. Allessie Prof. Dr. M.J. Janse Prof. Dr. F.L. Meijler Prof. Dr. O.C.K.M. Penn
Foreign Referees	Prof. Dr. Edson A. Saad Dr. Jéronimo Farré

CIP-DATA KONINKLIJKE BIBLIOTHEEK, DEN HAAG

Atié, Jacob

New observations on the role of accessory pathways in tachycardias in man / Jacob Atié. - Maastricht : Datawyse. - Ill.
Thesis Maastricht. - With ref. - With summary in Dutch.
ISBN 90-5291-023-5
SISO 605.12 UDC 616.12-072(043.3)
Subject headings: Wolf -Parkinson-White syndrome / Antidromic tachycardia / Multiple accessory pathways.

Produktie en layout: Datawyse Maastricht, Ruud Leliveld
Illustraties: Adri Van den Dool
Druk: Krips Repro Meppel

Publikatie van dit proefschrift werd mede mogelijk gemaakt door financiele steun van CNPq, Rescar, Nederlandse Hartstichting, Sanofi, Ciba, 3M Riker en Knoll b.v.

À Angela, Hélène e Mauricio
Ao meu pai e minha saudosa mãe
Às paixões da vida
Às grandes velejadas
Ao samba e canção
Ao sol e mar e
À terra carioca

Foreword

In Cardiology, and particularly in Rhythmology, orthodromic is an electric impulse in the heart which follows the normal, expected way. Contrarily the term antidromic refers to an electric stimulus which follows an unexpected, unusual or reversed way.

This thesis deals with several aspects of antidromic tachycardia, an arrhythmia where impulses follow a route which differs from the common one.

Initially, I did not know why I chose this topic, but suddenly I realized I was surrounded by antidromic people and antidromic facts.

The first antidromic way I took was many years ago when, at the age of 6 years, my family and I emigrated from Israel to Brazil. The orthodromic way for Jewish people has been the opposite, the emigration to Israel.

In the Middle Ages people followed the orthodromic way to discovery and adventure from Europe to South America. However, I took a couple of years ago the antidromic way and came to Europe for discovery, adventure and science.

I was received by Pedro Brugada, antidromic in his way of living, doing and teaching. Being with him provided me inspiration, stimulus and the necessary energy to undertake the realization of this thesis, which is the first by a Research Fellow in Electrophysiology in the University of Limburg. Without the antidromic initiatives of Pedro this thesis would not have been possible. Without any doubt the help, discussions and comments of Prof. Wellens (an antidromic scientist) were essential in the achievement of this goal.

Only with the company of another antidromic person could my life move in an appropriate antidromic way. It is always difficult to move against the orthodromic current. I would certainly have been drowned if Angela did not come to help me against the water. Since then, we moved up like the trouts, trying to reach the highest hills where the river starts. We searched, and found fulfillment in our lifes an created new ones. Like the trouts, we went back towards the sea with a small Hélène and a just born Mauricio. And there, Angela accepted the antidromic challenge to cross the Atlantic, of course,.... by other means ! The experience in Maastricht was unique for all of us. Angela was more than support and understanding. She is a real co-author of this thesis.

Contents

Chapter I Cardiac preexcitation
Introduction 10
Historical Overview 10
The anatomic and electrophysiologic basis 13
The electrocardiogram during sinus rhythm 17
Tachyarrhythmias 20
Localization of the accessory pathway on the ECG 28
Multiple accessory pathways 41
Clinical consequences of accessory pathways 43

Chapter II Further support of the atrio-ventricular localization of so-called "Mahaim fibers" 53

Chapter III Clinical and electrophysiological characteristics of patients with antidromic circus movement tachycardia in the Wolff-Parkinson-White syndrome 65

Chapter IV The diagnosis of multiple accessory pathways in the Wolff-Parkinson-White syndrome from the surface electrocardiogram in sinus rhythm 91

Chapter V The electrocardiogram in multiple accessory pathways 107

Chapter VI Clinical and electrophysiological characteristics of patients with multiple accessory pathways 121

Chapter VII Surgical treatment of multiple accessory pathways in the Wolff-Parkinson-White syndrome 141

Chapter VIII Longitudinal dissociation of atrio-ventricular accessory pathways 157

Chapter IX General conclusions, recommendations and implications for daily practice 171

Summary 175

Samenvatting 177

Acknowledgments 179

Curriculum Vitae 181

Chapter I

Cardiac preexcitation

Cardiac preexcitation

INTRODUCTION

The Wolff-Parkinson-White syndrome, the most common type of preexcitation caused by an accessory pathway between the atrium and ventricle (1), can lead to a variety of cardiac arrhythmias. Among them, orthodromic circus movement tachycardia, atrial fibrillation, and less commonly, antidromic circus movement tachycardia.

Circus movement tachycardia in the Wolff-Parkinson-White syndrome is the classical model of reentry. The arrhythmia is easily reproduced in the catheterization laboratory by means of programmed electrical stimulation (2). It is not surprising, therefore, that the Wolff-Parkinson-White syndrome has been the subject of extensive study by cardiologists. Adequate understanding of this model of reentry may give answers to fundamental questions in relation to mechanisms and treatment of many other cardiac arrhythmias.

This doctoral thesis analyzes new aspects of the preexcitation syndromes. These include the diagnosis and mechanisms of antidromic circus movement tachycardia, multiple accessory pathways and accessory pathways with unusual electrophysiological properties. It also describes the results of treatment in these patients. Although the emphasis is on the use of invasive electrophysiologic techniques, new information is also presented concerning the 12-lead electrocardiogram. This is done by applying to the ECG data derived from the electrophysiologic study. It will be shown that this further increases the diagnostic power of the ECG, a simple and inexpensive tool.

HISTORICAL OVERVIEW

The first reported case of preexcitation goes back to 1915 when Wilson made his observation in a single patient (3). Wedd (4) in 1921 and Bach (5) and Hamburger (6) in 1929 described patients in whom the diagnosis of preexcitation was, in retrospect, quite certain. These investigators, however, gave a variety of explanations for the broad QRS complex which they considered to be a form of atypical bundle branch block.

It were Wolff, Parkinson and White (7), who in 1930, described the clinico-electrocardiographic syndrome that now carries their names. In a series of 11 healthy young patients with intermittent QRS aberrancy and a short PR interval, they noticed a high incidence of attacks of paroxysmal

palpitations. Interestingly, they made no reference to the possibility of accessory pathways, although these muscular connections had been described more than 50 years before by Paladino (8).

In 1893, Kent (9) identified muscular connections between atria and ventricles considering them, however, parts of the normal AV conduction system. In 1914, Mines (10) suggested that "bundles of Kent" could represent a pathway for re-entrant tachycardias. In 1929 de Boer (11) proposed that the narrow QRS complex tachycardia could result from the presence of an anomalous pathway connecting atria and ventricles.

Holzmann and Scherf in 1932 (12) and Wolferth and Wood in 1934 (13) were the first to combine the presence of preexcitation with circus movement tachycardia (fig. 1). In 1943, Wood et al (14) reported for the first time the anatomopathological correlation between the clinical finding of a short P-R interval and broad QRS complex with an anomalous A-V connection in the heart. This finding was supported by the description of Ohnell (15) one year later.

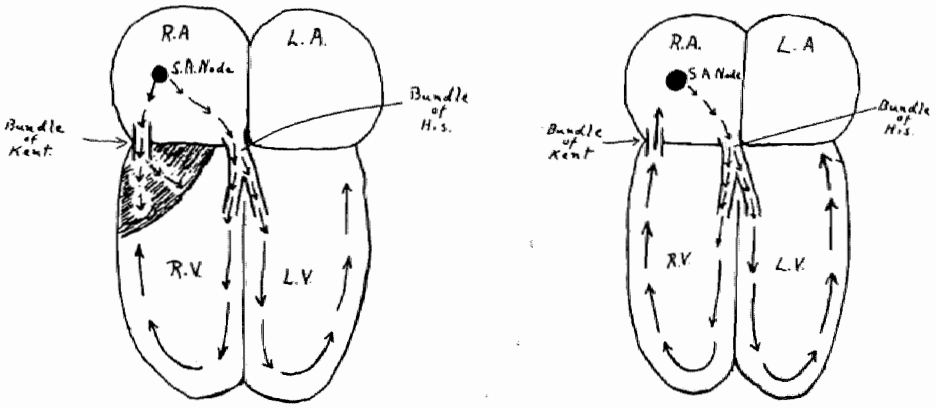

Figure 1. Diagrams drawn in 1933, reproduced from the paper of Wolferth and Wood (13), showing possible mechanisms of pre-excitation and of circus movement tachycardia. By permission of the Am. Heart J.

In 1945 Rosenbaum (16) classified the WPW syndrome in types A and B based on the precordial leads of the surface electrocardiogram. In 1948 Sodi Pallares (17) supported Rosenbaum's classification by recording potentials within the heart. Later on, Hecht (18) also supported this classification.

Definitive proof for the mechanism of preexcitation and the circus movement tachycardias occurring in patients with this anomaly was provided by Durrer and his coworkers when they first documented pre-excitation by

epicardial mapping and then demonstrated the initiation and termination of the circus movement tachycardia during programmed electrical stimulation of the heart (2).

In 1971 Wellens described the electrophysiologic characteristics of the different accessory pathways leading to preexcitation (19). Thereafter many electrophysiology laboratories around the world further defined the various mechanisms of reciprocating tachycardias in patients with pre-excitation.

New types of accessory pathways were described in the mid 1970's, such as concealed accessory pathways, capable of only retrograde conduction (from ventricle to atrium), and therefore not showing anterograde pre-excitation (20,21,22). In 1978, Gallagher (23) and thereafter Farré (24), described patients with circus movement tachycardia retrogradely using a concealed accessory pathway with a very long conduction time. The tachycardia was of the type previously described by Coumel (25) as the "permanent" or "incessant" form of A-V junctional reciprocating tachycardia.

The better understanding of the various preexcitation syndromes was inevitably followed by the recognition of its possible consequences. An anomaly which frequently causes paroxysmal palpitations, incessant tachycardias or even sudden arrhythmic death could not be considered anymore an electrocardiographic curiosity (26-27).

During many years, the therapeutic armamentarium to manage these problems was limited. Decisions had to be made on an empirical basis. However, the ability to reproduce the arrhythmias during electrical stimulation studies opened the way to study the effects of antiarrhythmic drugs on the arrhythmia mechanisms (28-30).

An important breakthrough in the treatment of the Wolff-Parkinson-White syndrome was the successful first surgical division of an accessory pathway by Sealy (31). Surgical treatment rapidly became a reality and is now a fully accepted form of treatment (32,33).

Nowadays, other types of treatment for the Wolff-Parkinson-White syndrome like electrical or radiofrequency percutaneous ablation are being applied or investigated (34,35). In spite of the many advances in understanding and treatment of the Wolff-Parkinson-White syndrome, there are still questions to be answered.

Recently Jackman et al (36) suggested that accessory pathway potentials may be recorded during electrical mapping. In spite of discussions as to the validity of their interpretations this has resulted in a renewed interest in the pathophysiologic aspects of conduction over an accessory pathway. Also, we are still far from understanding why antiarrhythmic drugs affect (or fail to affect) conduction over an accessory pathway.

It is clear, therefore, that the Wolff-Parkinson-White syndrome will continue to puzzle and fascinate us for many years to come. Especially because it is such a beautiful model to study and understand arrhythmias occurring in other sites of the heart.

THE ANATOMIC AND ELECTROPHYSIOLOGIC BASIS OF THE PREEXCITATION SYNDROMES

Normally, ventricular excitation follows conduction of a supraventricular impulse over the atrioventricular node, the bundle of His and the bundle branch-Purkinje system. When apart from the normal atrio-ventricular system another pathway for conduction is present, this pathway is called an accessory pathway. The normal atrioventricular node can be bypassed by a number of potentially different types of accessory pathways. It is believed that these accessory pathways are composed of normal myocytes. These cells can be arranged and localized in different ways causing a variety of anatomical and electrophysiological types of accessory pathways (37,38) (fig. 2).

The type of accessory pathway found in 345 consecutive patients studied in our institution is shown in table I.

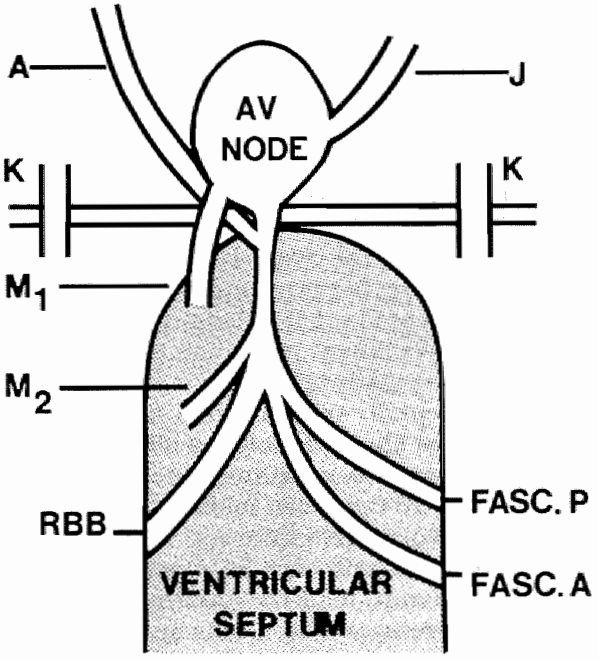

Figure 2. Scheme of the atrioventricular conduction system and possible accessory connection(s) partially or totally bypassing that system. A, indicates an atriofascicular bypass tract; J, an atrionodal bypass tract; K, an accessory atrioventricular pathway; M1, a nodoventricular pathway; M2, a fasciculoventricular pathway; Fasc P, the posterior fascicle of the left bundle branch; and fasc A, the anterior fascicle of the left bundle branch; RBB, the right bundle branch. (Reproduced from ref. 1, by permission)

Table I. Type of accessory pathways in 345 patients

A-V AP "Kent"	194 pts
A-V AP slow CT	3 pts (anterogradely)
A-V AP slow CT	20 pts (retrogradely)
Nodoventricular AP	4 pts
Concealed AP	124 pts

Abbreviations:A-V= atrioventricular; AP= accessory pathway; CT= conduction time; pts= patients.

a. Accessory atrioventricular pathways

The most common type of accessory atrioventricular connection is the so-called Kent bundle, which is found in patients with the typical Wolff-Parkinson-White syndrome (14) (fig. 2). The bundles of Kent originate and insert into the myocardium (from atrium to ventricle) and can be located endocardially or epicardially (38).

In the few anatomic descriptions available, the accessory pathway consisted of a thin strand of morphologically normal myocardium bridging the fibro-fatty epicardial gap between atrium and ventricle (38). This type of accessory pathway can be located at any site along the atrioventricular junction, including the area of aortic-mitral valve fibrous continuity (38) (fig. 3).

The initial classification of the Wolff-Parkinson-White syndrome separated the electrocardiographic patterns into types A and B (16). In this classification, type A represented a left-sided accessory pathway and type B a right-sided connection. We know now that there are different possible localizations of the accessory pathways. They can be infero-septal (postero-septal), para-hisian (mid-septal), supero-septal (antero-septal), left or right paraseptal or localized in the left or right free wall (39).

The dimensions of an accessory pathway seem to vary. They can be as short as 1 mm or as long as 10 mm. Also the diameter may vary, and the way they branch out into the myocardium (38).

Atrioventricular accessory pathways in symptomatic patients are frequently capable of conduction in both the anterograde and retrograde direction (40). However, there are accessory pathways capable of conduction in only one direction. If only retrograde conduction is possible, the electrocardiogram during sinus rhythm does not show preexcitation. However, paroxysmal supraventricular tachycardia due to a reentry circus movement tachycardia using such a concealed accessory pathway retrogradely (orthodromic circus movement tachycardia) is possible (20,21). Similarly, there are accessory atrio-ventricular pathways capable of only anterograde conduction. In those patients orthodromic circus movement tachycardia cannot occur. An

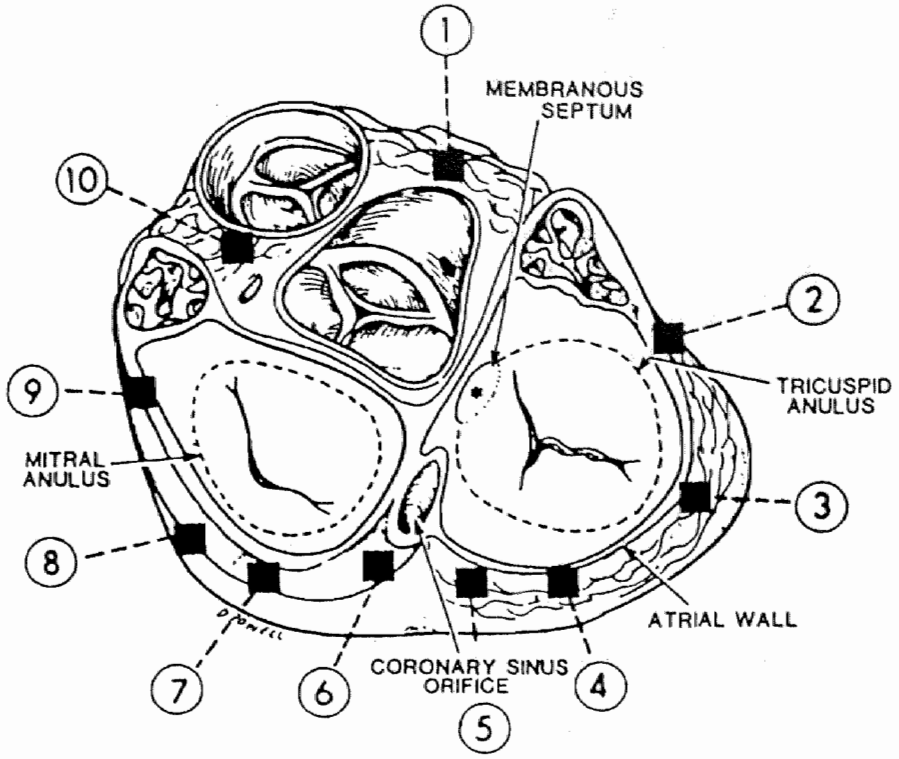

Figure 3. Possible localizations of accessory atrio-ventricular pathways as suggested by Gallagher (39). Ten representative sites are depicted on a schematic cross-section of the ventricles at the level of the atrioventricular ring.

antidromic circus movement tachycardia with the accessory pathway conducting anterogradely and the normal atrio-ventricular conduction system conducting retrogradely is possible, however.

Usually, the accessory atrioventricular pathway conducts the impulse with a short conduction time, from atrium to ventricle and vice-versa. However, there are accessory pathways with long conduction times. These accessory pathways with long conduction times are also capable to conduct retrogradely or anterogradely, or in both directions (23-24).

Patients with retrogradely conducting atrio-ventricular accessory pathways with long conduction times, generally, have incessant circus movement tachycardia (23-25).

Atrio-ventricular accessory pathways with long conduction times capable of anterograde conduction have electrophysiological properties very similar to nodo-ventricular accessory pathways (19,42,43). Actually it has been

demonstrated that in some patients in whom a nodo-ventricular accessory pathway was suspected, an accessory atrio-ventricular pathway with long anterograde conduction times was present (44-46) (Chapter II).

One of the most important properties of the accessory pathways is their capacity to conduct an impulse. The ability to do so is determined by the refractory period of the pathway. The effective refractory period of these structures is generally different in anterograde and retrograde direction.

The ventricular response during atrial fibrillation is determined by the electrophysiological properties of both AV (normal and accessory) conduction pathways. If the accessory atrioventricular pathway has a very short anterograde refractory period, an extremely rapid ventricular rate can develop during atrial fibrillation, which in some instances may degenerate into ventricular fibrillation (27,47).

b. Nodoventricular and Fasciculo-Ventricular Accessory Pathways

Nodo-ventricular accessory pathways go directly from the AV node into the ventricle. Fasciculo-ventricular accessory pathways connect the common bundle of His to the ventricles (fig. 2). A nodo-ventricular accessory pathway was first described by Mahaim in 1941 (42). They are less common than true atrioventricular accessory pathways (39). At least that is true in symptomatic patients studied electrophysiologically because of a variety of preexcitation syndromes (table I).

Some concepts about nodo-ventricular accessory pathways have recently been revised (44-46). It seems that in selected patients, features suggestive of a nodo-ventricular accessory pathway are in reality caused by an accessory atrio-ventricular pathway with slow anterograde conduction. Further support of this hypothesis will be given in chapter II.

c. Other Variants of The Preexcitation Syndromes

In 1961, James (48) described an accessory pathway connecting the atrium with the distal fibers of the AV node (atrionodal) or the common bundle (atriofascicular) (fig. 2). This type of accessory pathway should result in a short PR interval, a normal QRS complex without preexcitation and circus movement tachycardia (Lown-Ganong-Levine syndrome) (49). Definite proof on the existence and role of such an accessory pathway is missing. Some of the reported cases can also be explained by a short atrio-ventricular nodal conduction time and dual atrio-ventricular nodal pathways (50).

THE ELECTROCARDIOGRAM DURING SINUS RHYTHM IN THE PREEXCITATION SYNDROMES

The incidence of ventricular preexcitation in patients with accessory pathways is estimated to be 1 to 3 per 1000 persons (51). However, it has to be realized that studies based on the electrocardiogram during sinus rhythm can only recognize patients with accessory pathways capable of anterograde conduction. Concealed accessory pathways cannot be recognized in the electrocardiogram during sinus rhythm. Also, preexcitation may be unapparent or intermittent on the electrocardiogram. The true incidence of accessory pathways in the general population therefore must certainly be underestimated.

The electrocardiogram in the preexcitation syndromes, may lead to 4 different patterns:

1. Short PR interval with a delta wave.
2. Short PR interval without delta wave.
3. Normal PR interval with delta wave.
4. Normal PR interval without delta wave.

a. Atrio-ventricular accessory pathways with fast conduction times

The most common variety of preexcitation is that associated with an atrioventricular accessory pathway of the so-called "Kent" type. The electrocardiogram during sinus rhythm shows a short PR interval, a delta wave and a wide QRS complex, when the accessory pathway is capable of anterograde conduction. These findings are the result of ventricular activation over both the normal atrioventricular conduction system and the accessory pathway (14). As pointed out by Wellens (1), the pattern of ventricular activation and therefore the degree of preexcitation is determined by several factors, as illustrated in figure 4. Among them, the localization of the accessory pathway, the intra-atrial conduction times and the conduction times over the accessory pathway and the AV nodal-His-Purkinje pathway.

When we take these factors into consideration, the electrocardiogram can vary from a normal electrocardiogram to an electrocardiogram with a pattern of maximal preexcitation (fig. 4). It has to be realized that the degree of preexcitation on the 12 lead electrocardiogram during sinus rhythm does not indicate the electrophysiologic properties of the accessory pathway. Accessory pathways with very short refractory periods can produce minimal preexcitation on the electrocardiogram during sinus rhythm. This is particularly common in left lateral accessory pathways because of their distance from the sinus node (fig. 4). On the contrary, a right-sided or septal accessory pathway with a long refractory period may give rise to a very preexcited QRS complex simply because of its proximity to the sinus node.

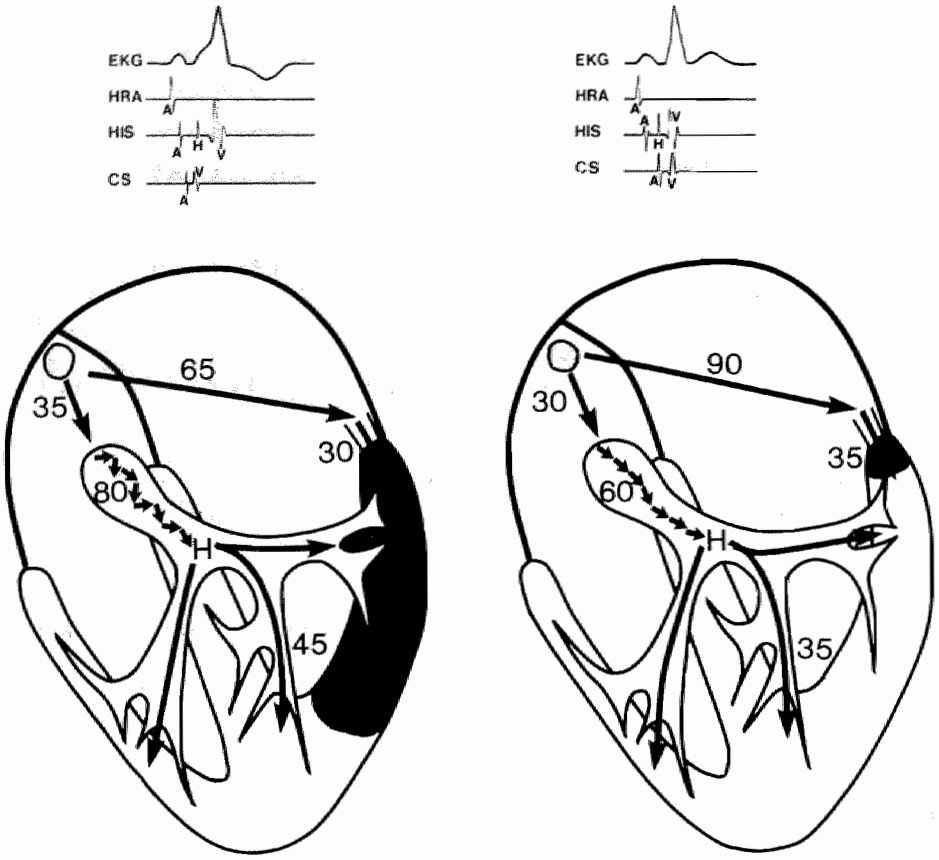

Figure 4. Schematic representation of factors determining the degree of ventricular preexcitation in the Wolff-Parkinson-White patient during sinus rhythm. The corresponding electrocardiogram and intracavitary recordings from the high right atrium (HRA), His bundle region (HIS), and coronary sinus (CS) are shown in the upper part of the figure.
(Left) The atrioventricular conduction time from the sinus node region over the normal AV pathway measures 160 ms (the time required to travel from the sinus node to the AV node, PA interval, of 35 msec; the transnodal conduction time, AH interval, of 80 msec; and the time needed to travel through the bundle of His and the bundle branches to the ventricular myocardium, HV interval, of 45 msec). The time required to travel from the sinus node to the atrial insertion of the AP measures 65 msec, and the conduction time over the AP measures 30 msec. The total AV conduction time to travel from the sinus node to the ventricle using the AP measures 95 msec. Under these circumstances, the corresponding electrogram will show a P-delta interval of 95 msec and a wide QRS complex with ventricular excitation starting 160-95=65 msec earlier than expected.
(Right) In this example, as compared to the left panel, there is (1) a longer conduction time from sinus node to the atrial insertion of the AP, (2) a longer conduction time over the accessory pathway, and (3) a shorter conduction time over the normal AV conduction system (shorter PA, AH and HV times). As a result of these differences, the AV conduction times over either the normal or the accessory pathway are identical (both 125 msec). Now the electrocardiogram shows a PR interval of 125 msec and a QRS complex without evident preexcitation. (reproduced from ref 1, by permission)

Sudden and unexpected loss of the delta wave (normalization of the QRS complex) has been observed already a long time ago in the preexcitation syndromes (15). Loss of the delta wave can be related to a critical rapid (or slow) heart rate, although, most often, loss of delta wave occurs unexpectedly (52). These patients have an accessory pathway with a long anterograde refractory period and are not at risk for rapid ventricular rates when atrial fibrillation occurs (53).

Patients with an accessory atrio-ventricular pathway that conducts only retrogradely, have a normal P-R interval without delta wave on the electrocardiogram during sinus rhythm. However, they often suffer from circus movement tachycardia, depending upon the electrophysiological properties of the AV nodal and accessory pathway (54).

The presence of a normal PR interval without delta wave, can also be present in patients with inapparent preexcitation. In these patients a delta wave may appear during sinus tachycardia or bradycardia (53).

b. Nodoventricular and fasciculoventricular accessory pathways

Patients with "Mahaim fibers" may have a normal ECG or a normal PR interval with a delta wave at the beginning of the QRS complex (19,53). This occurs because there are two varieties of nodoventricular accessory pathways, those which arise from the transitional zone of the AV junction and those which arise from the deep, compact nodal portion of the AV junction (37).

Nodoventricular fibers, depending on the level of takeoff relative to the area of physiologic AV nodal delay, can be associated with either a short or a normal PR interval. Ventricular activation results from fusion of impulse conduction via the nodoventricular and the normal conduction system, resulting in a QRS complex of variable morphology depending upon the degree of anomalous ventricular activation.

Fasciculoventricular fibers, arising from the His bundle or bundle branches, result in minor abbreviations of the H-V interval and some degree of anomalous QRS morphology. The PR interval, however, is usually normal in the absence of other abnormalities of AV conduction (55).

c. "James" fibers

Patients with "James fibers", present a short PR interval with a normal QRS complex (19,49). These findings, when associated with paroxysmal tachycardia, are known as the Lown-Ganong-Levine syndrome.

d. Accessory pathways with long conduction time

The electrocardiogram of patients having an atrioventricular accessory pathway with long conduction times able to conduct anterogradely is similar to the ECG in nodo-ventricular accessory pathways (44,45).

Patients having atrioventricular accessory pathway with long conduction times only conducting retrogradely, frequently suffer from incessant tachycardias. During tachycardia the PR interval is much shorter than the R-P interval because of slow retrograde conduction over the accessory pathway. Usually these accessory pathways are not able to conduct anterogradely and the electrocardiogram during sinus rhythm has a normal PR interval without a delta wave (24).

In summary, the electrocardiogram during sinus rhythm in patients with the preexcitation syndromes may differ, depending upon the type, localization and electrophysiologic characteristics of the accessory pathway.

TACHYARRHYTHMIAS IN THE PREEXCITATION SYNDROMES

A variety of tachyarrhythmias may occur in patients with accessory pathways. Some of those tachyarrhythmias are well tolerated (39), however, other patients may suffer from incapacitating or even life threatening arrhythmias (26). Treatment is therefore necessary in many patients with an accessory pathway. The best therapy will depend upon the type of arrhythmia, their impact on quality of life, its prognosis and the ease of treatment.

1. Orthodromic circus movement tachycardia

The most common type of tachycardia in patients with an accessory pathway is orthodromic circus movement tachycardia (fig. 5). This tachycardia utilizes the AV node as the anterograde limb and the accessory pathway as the retrograde limb of the circuit. The atria, the ventricles, the normal conduction system of the heart and the accessory pathway are all necessary links in the circuit.

Orthodromic circus movement tachycardia may occur with any type of accessory pathway. The only necessary condition is that the accessory pathway must be able to conduct impulses retrogradely. That may be possible with rather short ("fast" type of accessory pathway) or rather long conduction times ("slow" type of accessory pathway).

The anterograde and retrograde conduction properties of the accessory pathway determine the mode of spontaneous or electrically induced initiation of circus movement tachycardia. These aspects will be discussed later.

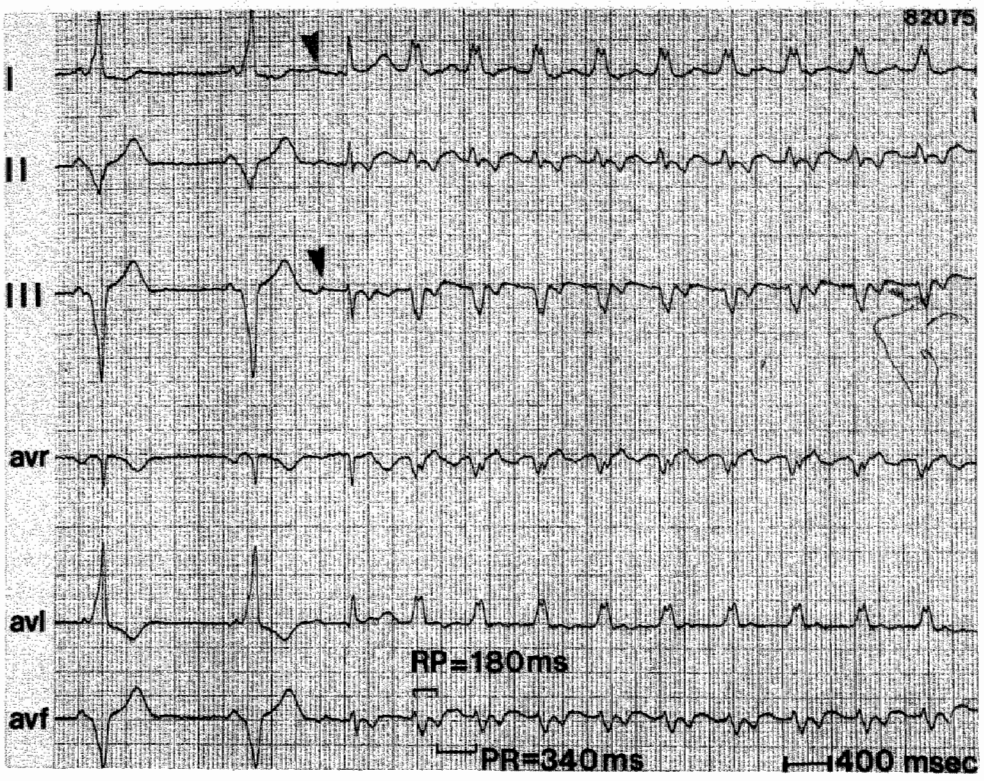

Figure 5. Six simultaneous electrocardiographic leads from a patient with the Wolff-Parkinson-White syndrome and a left postero-septal accessory pathway. The first two beats show sinus rhythm. An atrial premature beat (arrow) blocks in the accessory pathway and is conducted to the ventricle with a long PR interval only over the AV node pathway. Retrograde conduction occurs over the accessory pathway followed by orthodromic circus movement tachycardia with left bundle brunch block. The RP interval is 180 ms and is shorter than the PR interval (340 ms).

In orthodromic circus movement tachycardia, ventricular activation occurs by way of the AV node-His-Purkinje system only. The QRS complex is normal. Bundle branch block may occur and can be the result from a variety of mechanisms. This will lead to a wide QRS complex with the typical features of aberrant conduction (56).

During orthodromic circus movement tachycardia, the RP interval is usually shorter than the PR interval when the pathway is of the "fast" type (most common) (fig. 5). The RP interval is longer than the PR interval when during orthodromic tachycardia retrogradely an accessory pathway with long conduction times is used (57) (fig. 6). This type of accessory pathway is usually septally located, does not conduct anterogradely during sinus rhythm

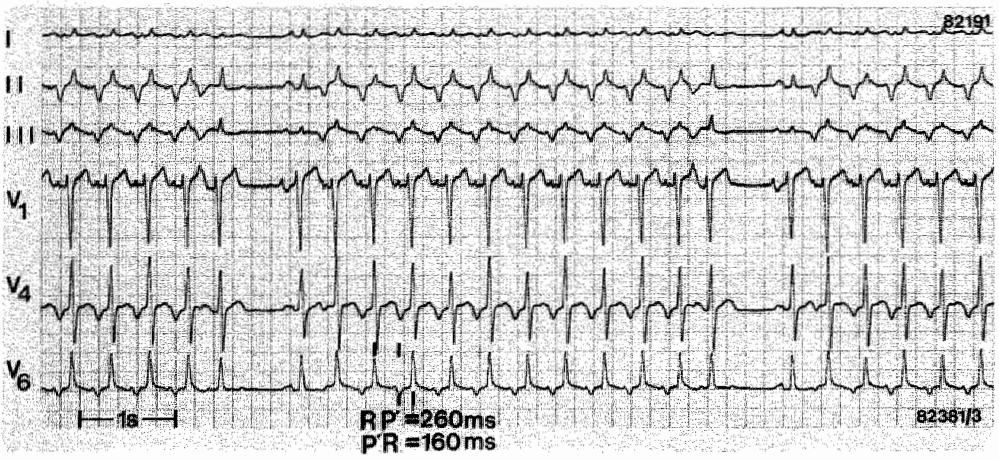

Figure 6. Six simultaneous electrocardiographic leads from a patient with incessant supraventricular tachycardia caused by a retrogradely conducting accessory pathway with long conduction times. The RP interval is 260 ms and the PR 160 ms. Orthodromic circus movement tachycardia is interrupted twice by an atrial premature beat. The first beat following termination of tachycardia is a sinus beat after which tachycardia initiates spontaneously.

(when atrio-ventricular conduction over the normal pathway is intact) and causes the "incessant" or permanent tachycardia as described by Coumel (25).

The value of the relation of the RP/PR interval during tachycardia to distinguish between different mechanisms of tachycardia is relative. Most patients with a fast accessory pathway have indeed a shorter RP than PR interval during orthodromic circus movement tachycardia. However, if atrio-ventricular nodal conduction time shortens while the RP interval remains the same, the RP interval can become longer than the PR interval. That is particularly the case in children and is responsible for the poor value of the RP/PR relation to determine the mechanism of a supraventricular tachycardia in children. Therefore, it is much better to measure the RP interval on the 12 lead electrocardiogram. This is usually in between 120 to 180 ms during an orthodromic circus movement tachycardia using an accessory pathway with fast conduction times and above 200 ms in accessory pathways with long conduction times.

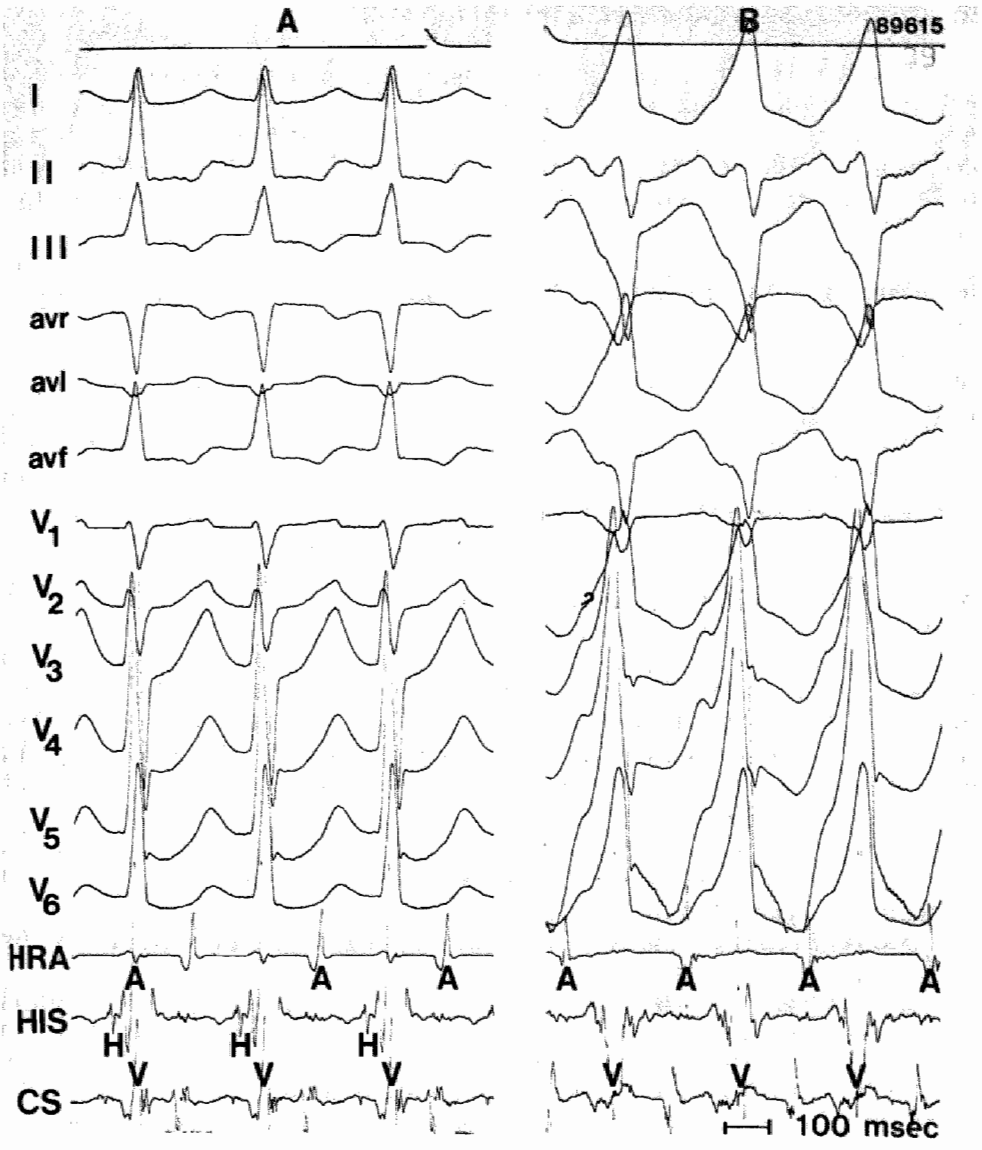

Figure 7. Panel A shows orthodromic circus movement tachycardia with activation of the bundle of His before the QRS complex. Panel B shows antidromic circus movement tachycardia with a wide QRS complex (140 msec). In each panel, 12 electrocardiographic leads are shown with 3 intracardiac leads, high right atrium (RA), bundle of His (HIS) and coronary sinus (CS).

2. Antidromic circus movement tachycardia

A second type of tachycardia in patients with atrioventricular accessory pathways is antidromic circus movement tachycardia. This tachycardia utilizes the accessory pathway in the anterograde direction and the AV node or a second accessory pathway as the retrograde limb (56,58) (fig. 7). This type of tachycardia occurs less frequently than orthodromic circus movement tachycardia.

In antidromic tachycardia, ventricular activation occurs solely via the accessory pathway, resulting in a wide QRS complex with maximal preexcitation.

There is a wide spectrum of regular tachycardias with wide QRS complexes in patients with atrio-ventricular accessory pathways (56). Programmed electrical stimulation with intracardiac recordings is usually necessary to avoid misdiagnosis. The difficulties to recognize the retrograde P wave during a wide QRS complex tachycardia make the 12-lead electrocardiogram frequently unreliable in diagnosing the exact tachycardia pathways.

3. Atrial fibrillation and atrial flutter

The incidence of atrial fibrillation in patients with an accessory pathway varies from 11.5% to 32% in different series (59). It is not clear whether the incidence of atrial fibrillation in patients with an accessory pathway is higher than in the general population or that the arrhythmia in the presence of an accessory pathway leads to more serious consequences and therefore earlier and easier recognition.

The accessory pathway may play a role in the initiation of this arrhythmia. As pointed out by Wellens (60), atrial fibrillation may be initiated by an atrial premature beat, by a retrogradely conducted premature ventricular beat, by deterioration of an orthodromic circus movement tachycardia and even by rapid pacing of the ventricle because of the ventriculo-atrial conduction.

The incidence of atrial fibrillation in patients with overt preexcitation is higher than in patients with a "concealed" accessory pathway (61). It seems therefore that the electrophysiologic properties of the accessory pathway may be important to determine whether atrial fibrillation will occur.

The ventricular rate during atrial fibrillation in patients with an accessory pathway is primarily determined by the refractory period of the accessory pathway but other factors like effective refractory period of the ventricle and adrenergic tone by changing the properties of the accessory pathway and ventricle do play a role (62). An increase in sympathetic tone, as during exercise, may cause the accessory pathway to conduct more impulses to the ventricle. If conduction during atrial fibrillation occurs over an accessory pathway with a very short refractory period, the ventricular rate can become so high that degeneration into ventricular fibrillation occurs (27).

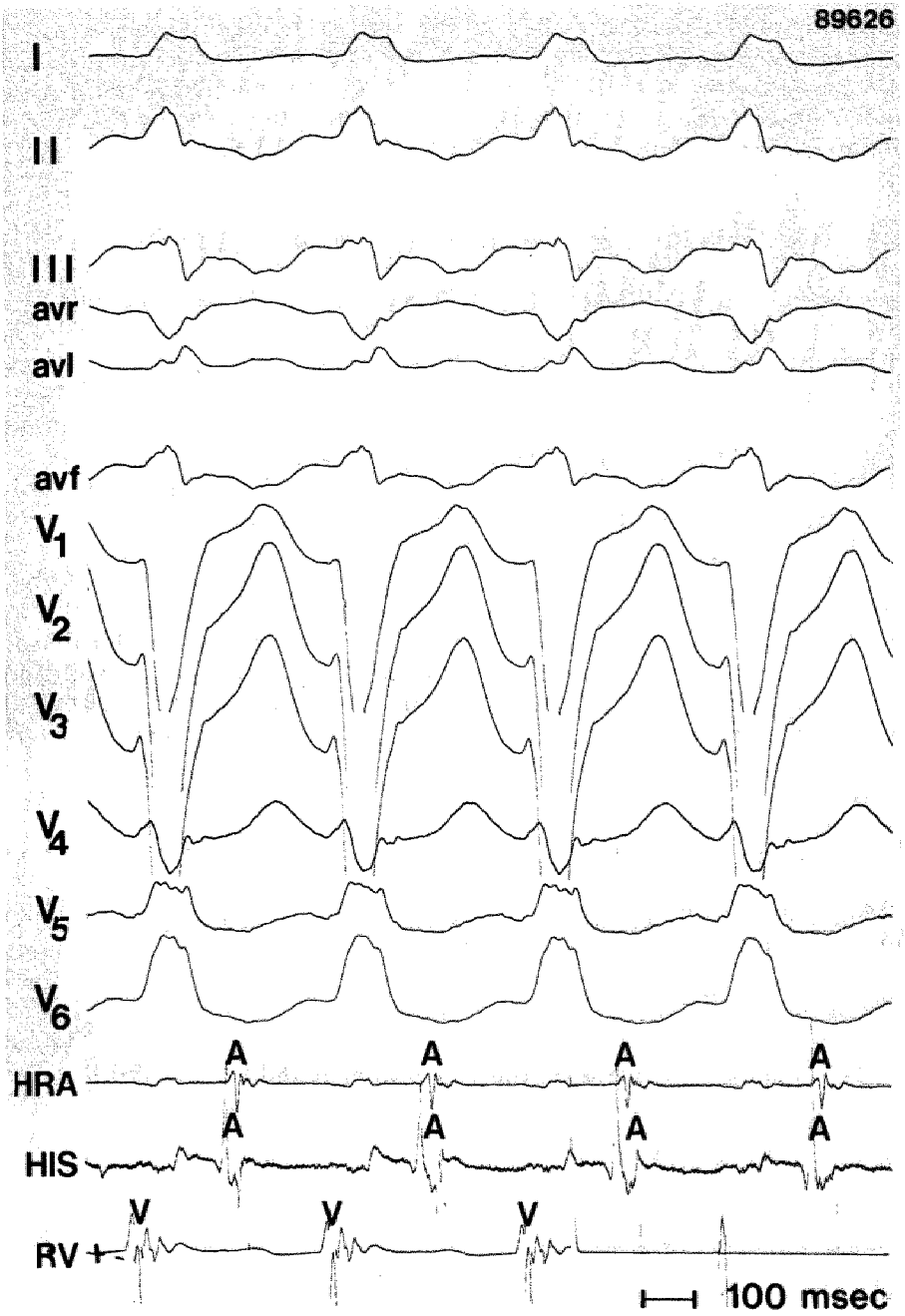

Figure 8. Example of a circus movement tachycardia with left bundle branch block morphology using anterogradely a nodoventricular accessory pathway. The A-V interval is longer than the V-A interval. Twelve electrocardiographic leads are shown and 3 intracardiac leads, high right atrium (RA), bundle of His (HIS) and right ventricle (RV).

Spontaneous atrial flutter in patients with an accessory pathway is rare (63). During electrophysiological study, however, it is frequently possible to induce atrial flutter. One-to-one conduction over the accessory pathway may cause diagnostic problems such as the differential diagnosis with antidromic circus movement tachycardia and ventricular tachycardia.

4. Circus movement tachycardia using a Mahaim fiber

A variety of arrhythmias have been described in patients with nodo-ventricular accessory pathways. The fiber may participate as a component of a tachycardia circuit, where anterograde conduction occurs over the nodo-ventricular fiber and retrograde conduction is via the His-Purkinje- AV node (19,55). Alternatively, the fiber may function as an "innocent bystander" during AV nodal tachycardia, atrial flutter or atrial fibrillation (64).

Invasive electrophysiological study is necessary to document the presence of a nodoventricular connection and its participation in the observed arrhythmias (43).

Patients with nodoventricular pathways have tachycardias with left bundle branch block morphology resulting from preexcitation of the right ventricle via the nodo-ventricular fiber (43) (fig. 8). Atrioventricular dissociation during tachycardia provides the diagnostic clue of a nodo-ventricular accessory pathway. This is, however, a rare observation (65). Recent studies suggest that nodo-ventricular fiber may in fact be an accessory atrio-ventricular pathway with long anterograde conduction times (44-47).

5. Ventricular fibrillation

Ventricular fibrillation is the most serious arrhythmia in patients with the Wolff-Parkinson-White syndrome (27,47). Although the exact incidence of this complication in this population remains unknown, it is likely to be low (66,67).

Several studies have recognized that the risk of ventricular fibrillation in the Wolff-Parkinson-White syndrome is primarily determined by the occurrence of atrial fibrillation in the presence of a very short anterograde refractory period of one or more accessory pathways (27,47) (fig. 9).

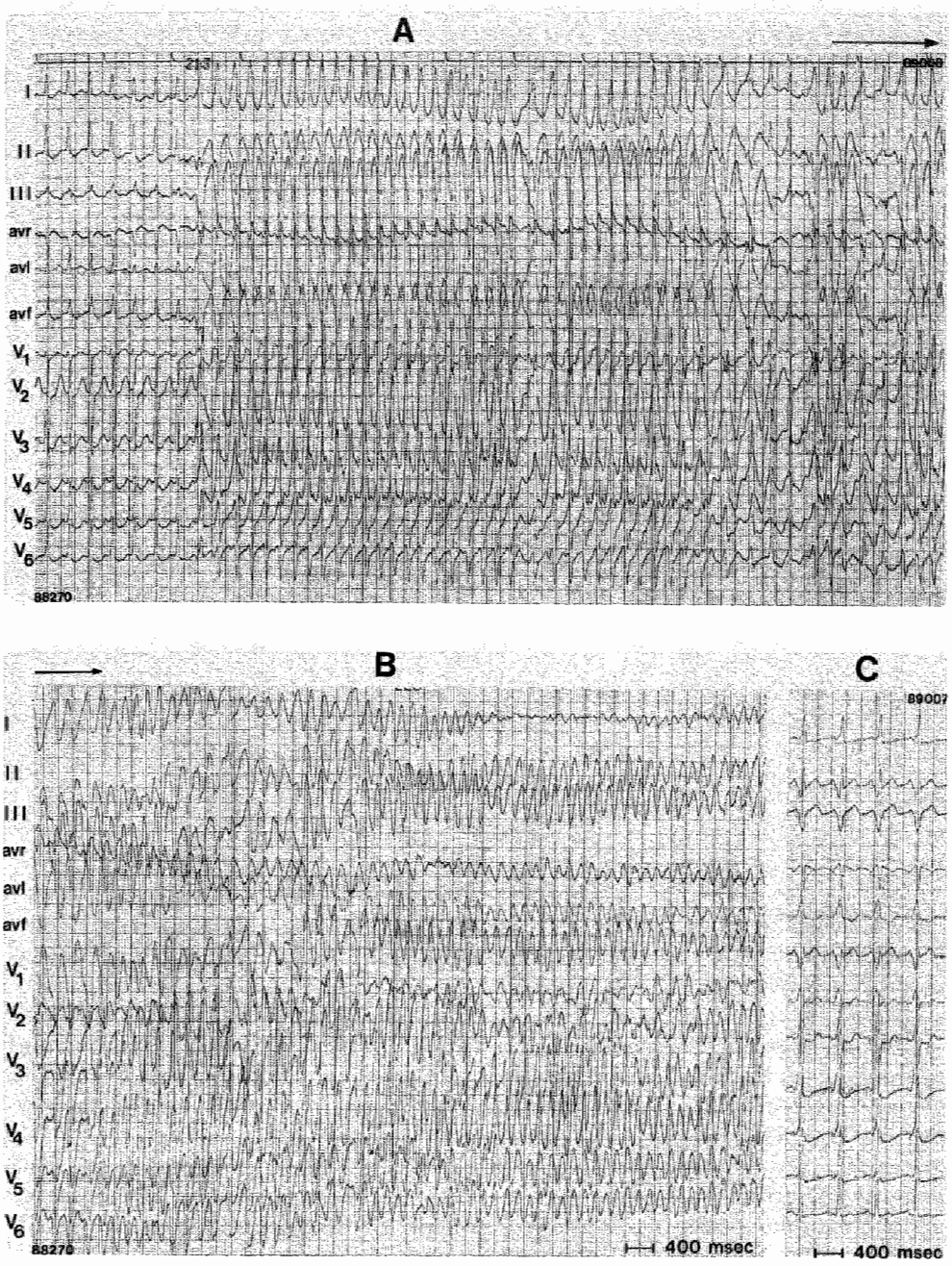

Figure 9. Twelve lead electrocardiogram showing during orthodromic circus movement tachycardia the development of atrial fibrillation (upper panel) degenerating into ventricular fibrillation (bottom panel). Both recordings are continuous. The electrocardiogram of the same patient during sinus rhythm is shown in panel C.

LOCALIZATION OF THE ACCESSORY PATHWAY ON THE 12 LEAD ELECTROCARDIOGRAM

1. During sinus rhythm

Localization of the site of the accessory pathway is not difficult in the Wolff-Parkinson-White syndrome when preexcitation is evident in the electrocardiogram during sinus rhythm (1,67-70). Accurate localization of the accessory pathway when the preexcitation is minimal is usually impossible (1).

Different authors have studied the value of the polarity of the delta wave (first 40 ms) on the 12 lead ECG during sinus rhythm to localize the accessory pathway. These data have usually been correlated with the localization of the accessory pathway by epicardial mapping during surgery (68-70) (table II).

Table II. The polarity of delta wave in the different possible localizations of accessory atrio-ventricular pathways.

LEADS	LL	PS	RL	AS
I	-i	+	+	+
II	+	-i+	+	+
III	+	-	+i-	+
aVL	-	+	+	+
aVF	+	-	+	+
V1	+	+-i	-i	-
V2	+	+	-i	-
V6	-i+	i-+	+	+

Abbreviations: LL= left lateral; PS= postero septal; RL= right lateral; AS= anteroseptal; i= polarity of delta wave isoelectric; - = polarity of delta wave negative; + = polarity of delta wave positive. From reference 39.

For the purpose of localization of the accessory pathway, it is important to have an electrocardiogram showing sufficient preexcitation, and to obtain several electrocardiographic simultaneous leads to identify isoelectric portions of the delta wave (fig. 10-13).

Reddy and Schamroth (71) recently described the importance of the QRS axis in the frontal plane to localize the site of implantation of accessory atrioventricular pathways. The mechanisms leading to a different axis of the QRS complex following AV conduction over accessory pathway are simple: Normal ventricular activation occurs transversely and synchronously through the free wall of both ventricles, from endocardial to epicardial surfaces.

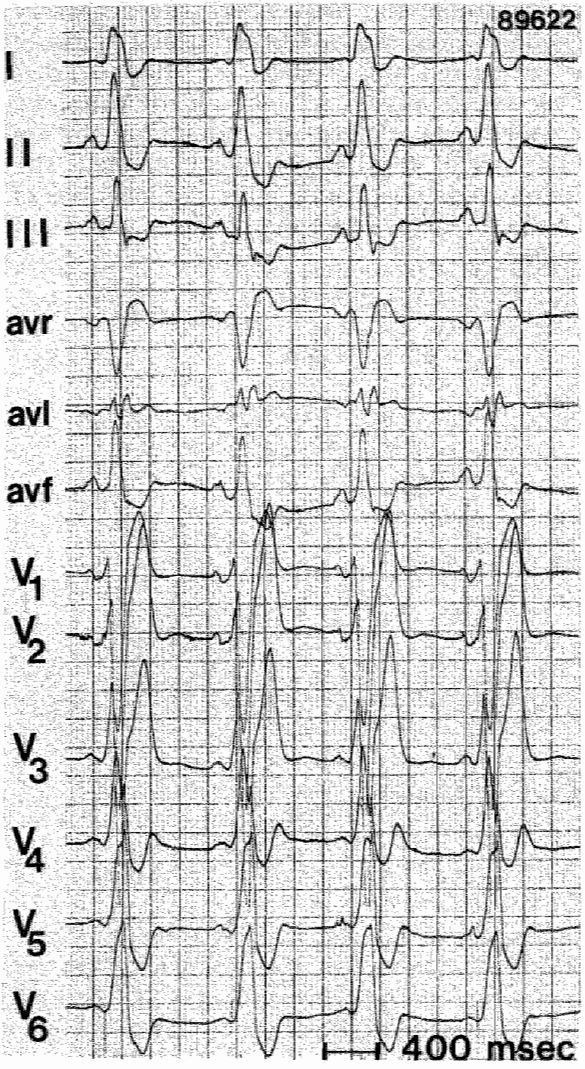

Figure 10. Twelve lead electrocardiogram during sinus rhythm of a patient with preexcitation caused by an anteroseptal accessory pathway. The delta wave is positive in leads I, II, III, aVL, aVF and V1. The QRS axis in the frontal plane is +60°.

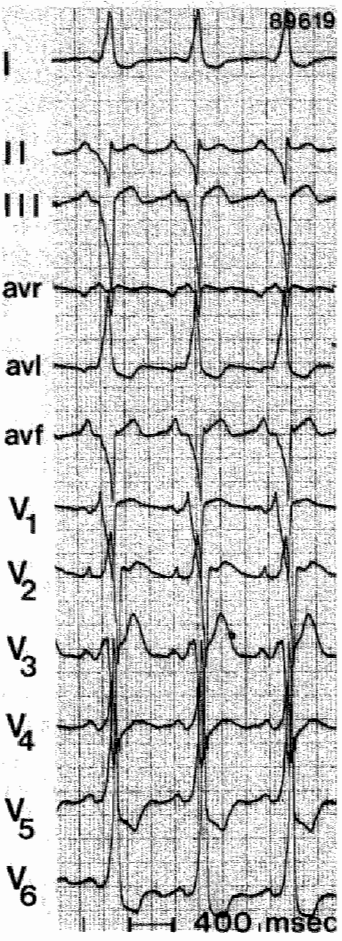

Figure 11. Twelve lead electrocardiogram of a patient with a posteroseptal accessory pathway. The delta wave is positive in leads I, aVL and V1, negative in leads II, III and aVF. The QRS axis in the frontal plane is -60°.

In the Wolff-Parkinson-White syndrome the area where the accessory pathway enters the ventricle is excited before arrival of the normal impulse. The direction of excitation in the preexcited area is therefore changed, disturbing the normal balance of electrical forces. A right sided accessory pathway, preempts the right free wall forces, resulting in a dominant role of the forces leading to deviation of the axis of the QRS complex to the left. The same mechanism explains the different axis observed in different locations of accessory pathways. Each site of insertion of an accessory pathway will result in a different axis of the QRS complex (fig. 14).

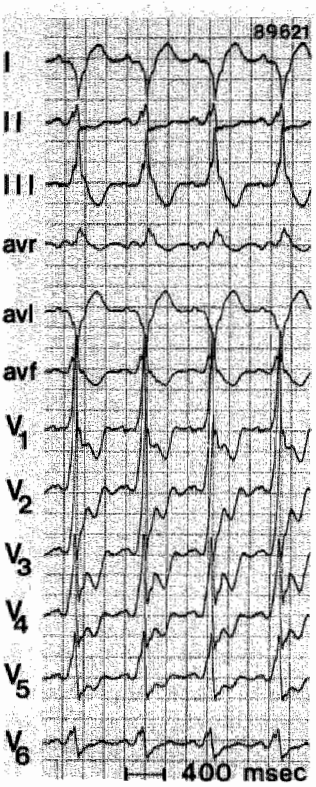

Figure 12. Electrocardiogram of a patient with a left lateral accessory pathway. The delta wave is positive in leads II, III, aVF and V1, negative in leads I and aVL. The QRS axis in the frontal plane is +120°.

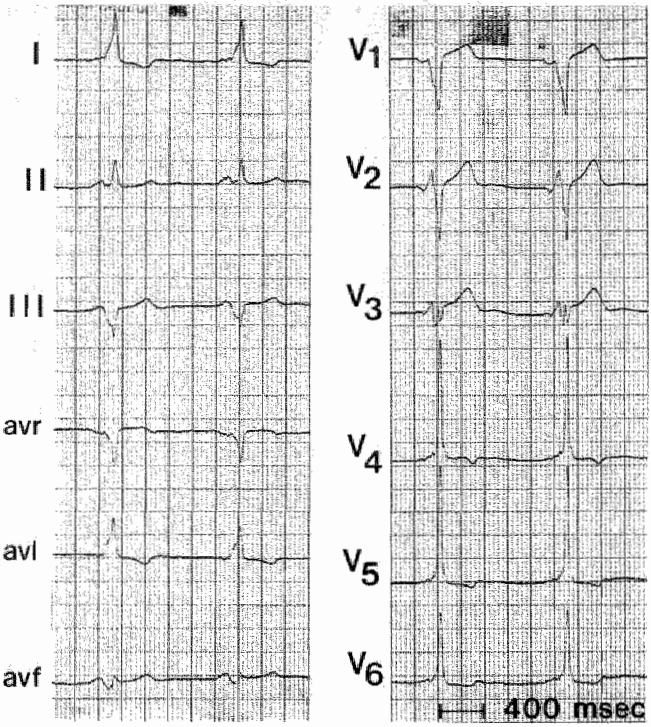

Figure 13. Electrocardiogram of a patient with a right lateral accessory pathway. The delta wave is positive in leads I and aVL, negative in leads III, aVF and V1. The QRS axis in the frontal plane is -10°.

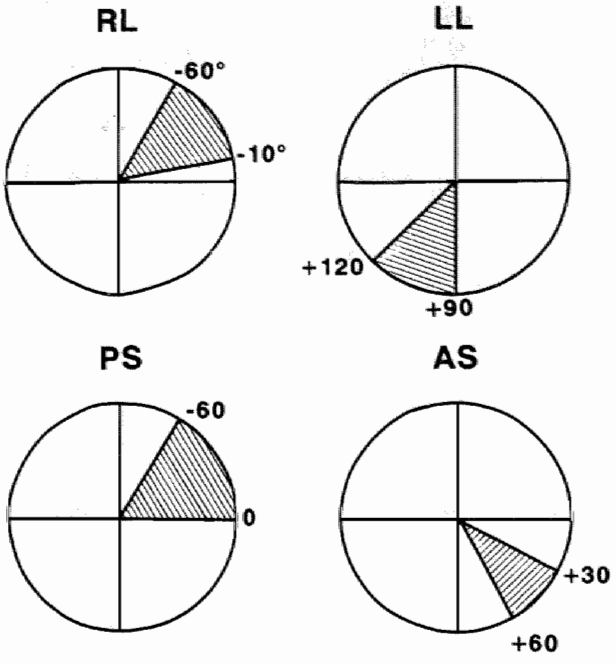

Figure 14. Diagrams illustrating the QRS axis in the frontal plane in the different locations of accessory pathways. RL = right lateral; LL = left lateral; PS = posteroseptal; AS = anteroseptal. (adapted from Reddy and Schamroth (71).

2. During orthodromic tachycardia

Examination of the electrocardiogram during tachycardia provides important additional information to localize the site of an accessory pathway (72). During orthodromic circus movement tachycardia the atria are retrogradely activated over the accessory pathway. That results in a specific axis, morphology and duration of the P wave on the 12 lead electrocardiogram depending upon the localization of the atrial insertion of the accessory pathway (56,72,73).

It has been reported that in patients with orthodromic circus movement tachycardia utilizing a left lateral accessory pathway, the P wave is usually negative in leads I and aVL (fig. 15). In contrast, when orthodromic circus movement tachycardia utilizes a right sided accessory pathway, the P wave is usually positive in those leads (fig. 16). In inferoseptal accessory pathways the P wave is negative in leads II, III and aVF (fig. 5). Table III shows the morphologies of the retrograde P wave in different localizations of the accessory pathway.

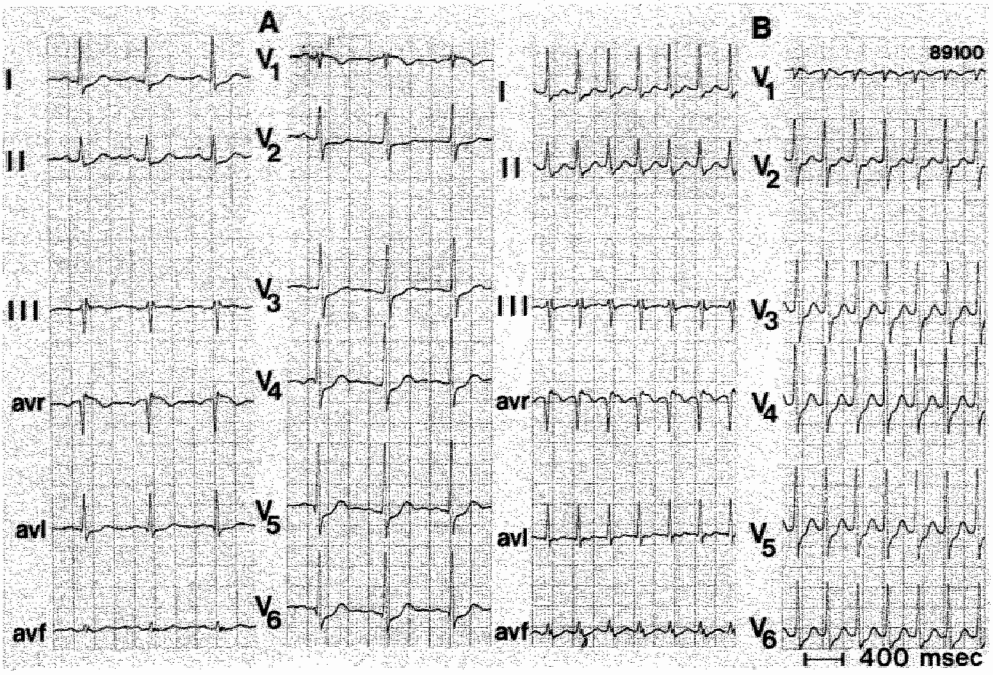

Figure 15. A patient with a left lateral concealed accessory atrioventricular pathway. In the left panel the electrocardiogram during sinus rhythm shows a normal PR interval and no preexcitation. In the right panel orthodromic circus movement tachycardia is present with a P wave 140 ms after the onset of the QRS. The P wave is negative in leads I, aVL which is very suggestive of a left lateral accessory pathway.

During orthodromic circus movement tachycardia using a left or right lateral accessory pathway, the duration of the P wave will be longer than in a septally located accessory pathway. That occurs because in septally located accessory pathways the two atria are simultaneously activated, while they are sequentially activated in right or left sided accessory pathways.
Localization of the accessory pathway by means of the retrograde atrial activation pattern is important in:

a. Confirming that the same accessory pathway is used retrogradely during orthodromic circus movement tachycardia and anterogradely during sinus rhythm.
b. Recognizing the presence of multiple accessory pathways when different pathways are used anterogradely during sinus rhythm, antidromic circus movement tachycardia, or atrial fibrillation and retrogradely during orthodromic circus movement tachycardia (see Chapter V).
c. Identifying the use of a concealed accessory pathway during orthodromic circus movement tachycardia.

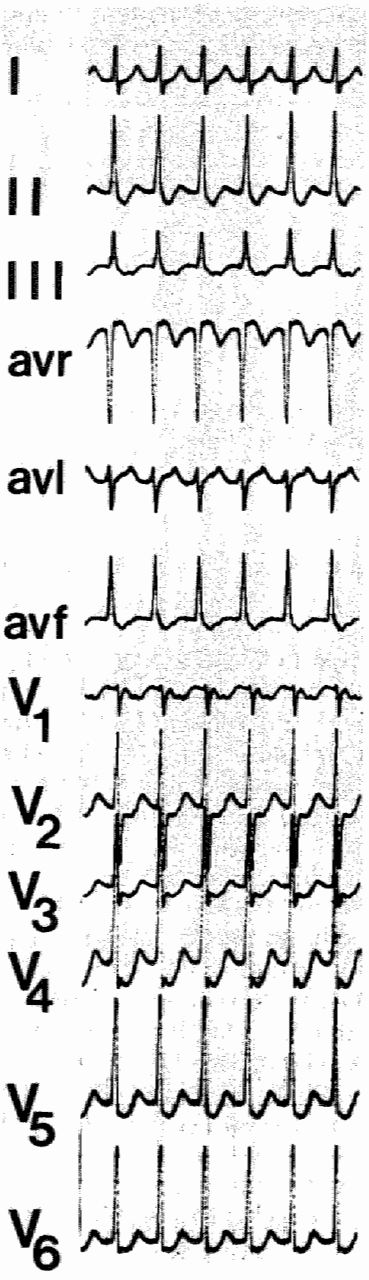

Figure 16. Electrocardiogram during orthodromic circus movement tachycardia, in a patient with a right sided accessory pathway. The P wave during orthodromic tachycardia which is seen 140 ms after the onset of the QRS and is positive in leads I and aVL and negative bimodal in lead III and V1.

Table III. Polarity of the P wave during orthodromic circus movement tachycardia in the different possible localizations of the accessory atrio-ventricular pathways

LEADS	LL	PS	RL	AS
I	-	i	+	+ - i
II	+	-	+	+
III	++	- -	-	+
aVL	-	i	+	+ - i
aVF	+	-	+	+
V1	+	+ i	-	- +

Abbreviations: LL= left lateral; PS= postero septal; RL= right lateral; AS= anteroseptal; i= polarity of delta wave isoelectric; - = polarity of delta wave negative; + = polarity of delta wave positive.

During orthodromic circus movement tachycardia there are several additional clues to help in localization the accessory pathway:

a. The occurrence of bundle branch block during orthodromic circus movement tachycardia can give additional information to localize the accessory pathway during tachycardia (74). Functional bundle branch block during tachycardia, may result in slowing in rate of the tachycardia, if the tachycardia utilizes an accessory pathway ipsilateral to the bundle branch where conduction block occur (74). The mechanisms leading to slowing of tachycardia are illustrated in figures 17-19. Bundle branch block ipsilateral to the accessory pathway forces the stimulus to follow a longer route and to cross the septum in order to activate the accessory pathway. Transseptal conduction takes ± 40 msec (75), and such an increase in ventriculo-atrial conduction time will minimally develop when ipsilateral bundle branch block occurs during orthodromic tachycardia. This prolongation in ventriculo-atrial interval (R-P interval on the surface electrocardiogram) may not lead to a change in cycle length of the tachycardia if the prolongation of the R-P interval is accompanied by a shortening of the PR interval (76). Bundle branch block does not affect the ventriculo-atrial conduction time or rate of the tachycardia, in truly septal accessory pathways.
b. Orthodromic tachycardia may have at times an alternation pattern of long RR cycles. This usually indicates alternation between two different anterograde limbs of the reentry circuit. For example, in patients with dual AV nodal pathways and an accessory pathway, orthodromic circus movement tachycardia may utilize alternately the fast and the slow AV nodal pathway as the anterograde limb of the tachycardia circuit (fig. 20,21).

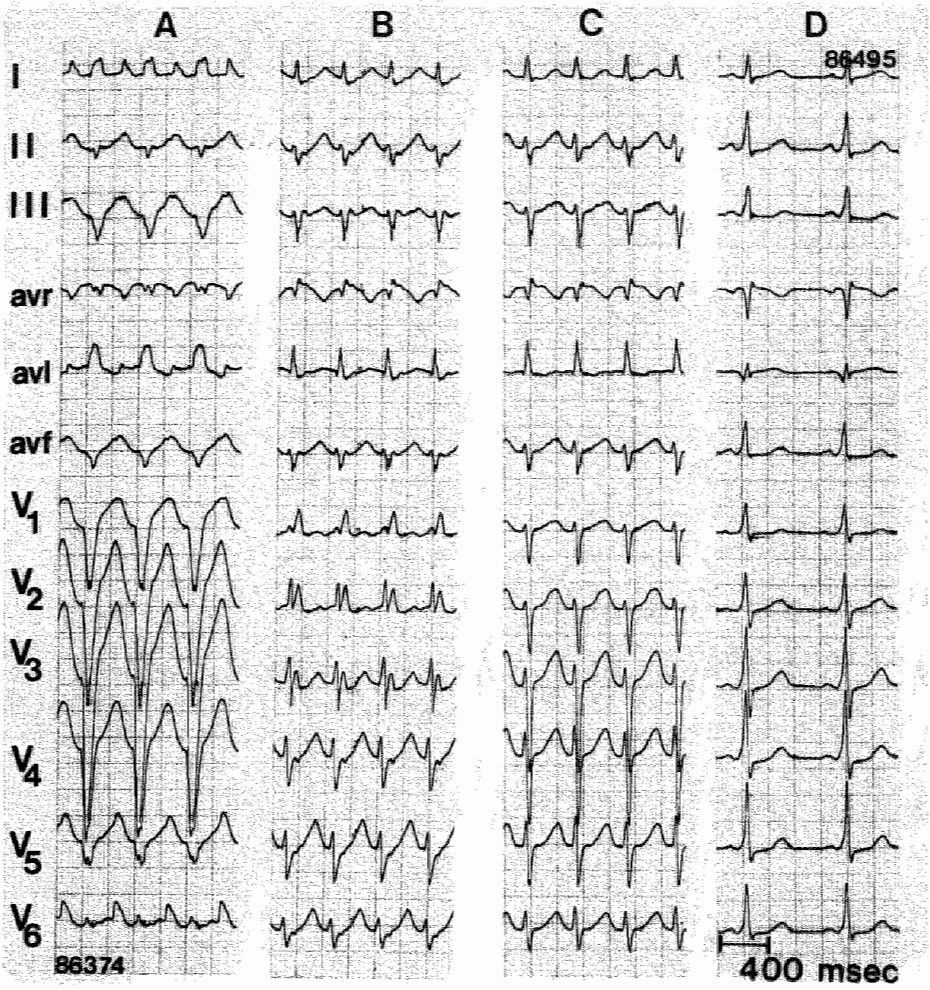

Figure 17. Four electrocardiograms from the same patient having a left sided accessory atrioventricular pathway. In panel D, sinus rhythm shows a negative delta wave in aVL. In panel C, orthodromic circus movement tachycardia with normal intraventricular conduction is observed. In panel B, orthodromic circus movement tachycardia with right bundle branch block is present. Panel A shows orthodromic circus movement tachycardia with left bundle branch block. The cycle length of the tachycardia during right bundle branch block is the same as the tachycardia with normal intraventricular conduction. The cycle length of the tachycardia during left bundle branch block is 40 ms longer then during non-aberrant conduction or right bundle branch block.. This is typical of a left sided located accessory atrioventricular pathway (see text).

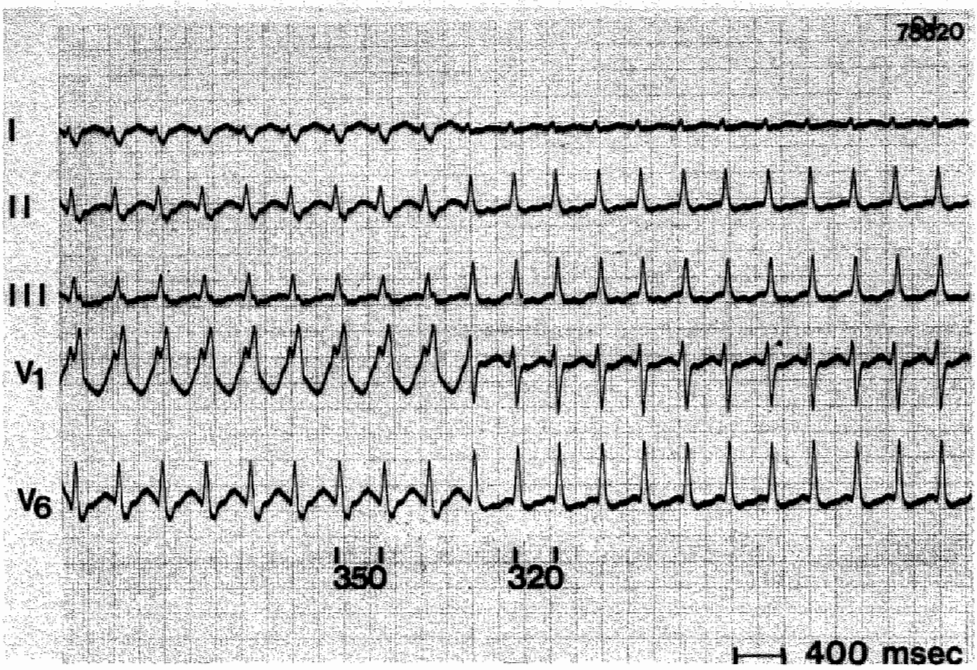

Figure 18. Five simultaneous electrocardiographic leads showing a change from an orthodromic circus movement tachycardia with right bundle branch block aberrant conduction into a tachycardia with non-aberrant conduction. The cycle length of the tachycardia during right bundle branch block is 30 ms longer than during non-aberrant conduction indicating a right lateral accessory pathway. (see text).

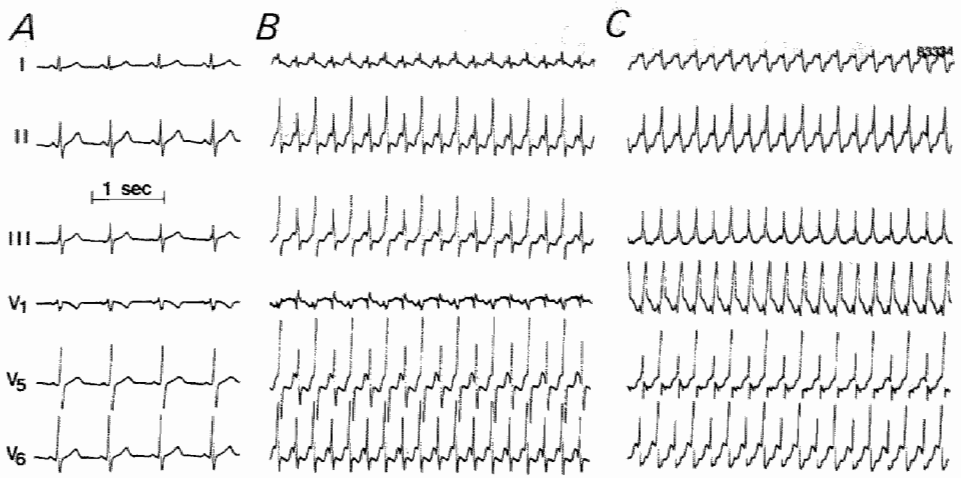

Figure 19. Three recordings from the same patient. In panel A sinus rhythm without preexcitation is present. In panel B orthodromic circus movement tachycardia with electrical alternans and in panel C an orthodromic tachycardia with right bundle branch block and electrical alternans are shown. The cycle length does not change with and without bundle branch block, thereby excluding the use of a right sided accessory pathway.

c. A right ventricular premature beat given during a narrow QRS orthodromic circus movement tachycardia using a left lateral accessory pathway in the retrograde direction, will have a longer V-A interval (R-P interval in the surface electrocardiogram) than during tachycardia with normal intraventricular conduction (fig. 22). The R-P interval will decrease after a right ventricular premature beat during orthodromic circus movement tachycardia using a right lateral accessory pathway (paradoxical capture) (fig. 23), and will not change in patients with a truly septal accessory pathway (exact capture) (75) (fig. 24).

3. During antidromic tachycardia

In the case of this less frequent type of circus movement tachycardia, resulting from conduction over the accessory pathway in the anterograde direction and the AV node or another accessory pathway in the retrograde direction (antidromic circus movement tachycardia), it is easy to localize the anterogradely conducting accessory pathway, because during tachycardia there is maximal preexcitation of the QRS complex.

The incidence of multiple accessory pathways in patients presenting antidromic circus movement tachycardia is high (Chapter III).

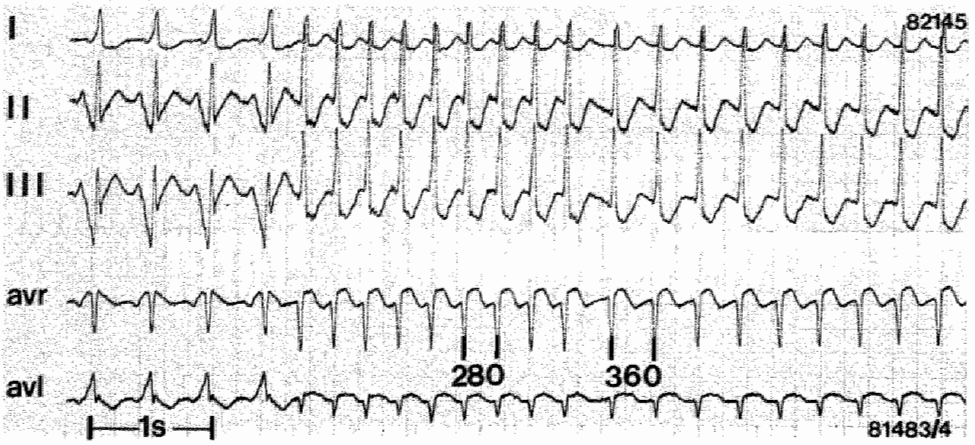

Figure 20. Five simultaneous electrocardiographic leads from a patient with a posteroseptal accessory pathway and dual AV nodal pathways. The first 4 beats are sinus beats and show preexcitation. One atrial premature beat initiates orthodromic circus movement tachycardia. This tachycardia shows a sudden slowing in rate without change in RP interval. The change in cycle length is caused by a shift in anterograde conduction from a fast to a slow intranodal pathways.

The electrophysiologic mechanisms leading to tachycardias in the Wolff-Parkinson-White syndrome have been extensively studied (1,19). However, there are relatively few studies on antidromic circus movement tachycardia (77,78).

4. During atrial fibrillation

During atrial fibrillation, three types of AV conduction pattern can be observed:

a. Exclusive conduction over the accessory pathway with a maximally preexcited QRS complex.
b. Exclusive conduction over the normal AV conduction pathway with a normal QRS complex or typical bundle branch block.
c. Fusion complexes resulting from conduction over both (the normal and accessory) pathways.

The ventricular rate during atrial fibrillation is determined by the electrophysiologic properties of both, normal AV conduction system and accessory pathway (60).

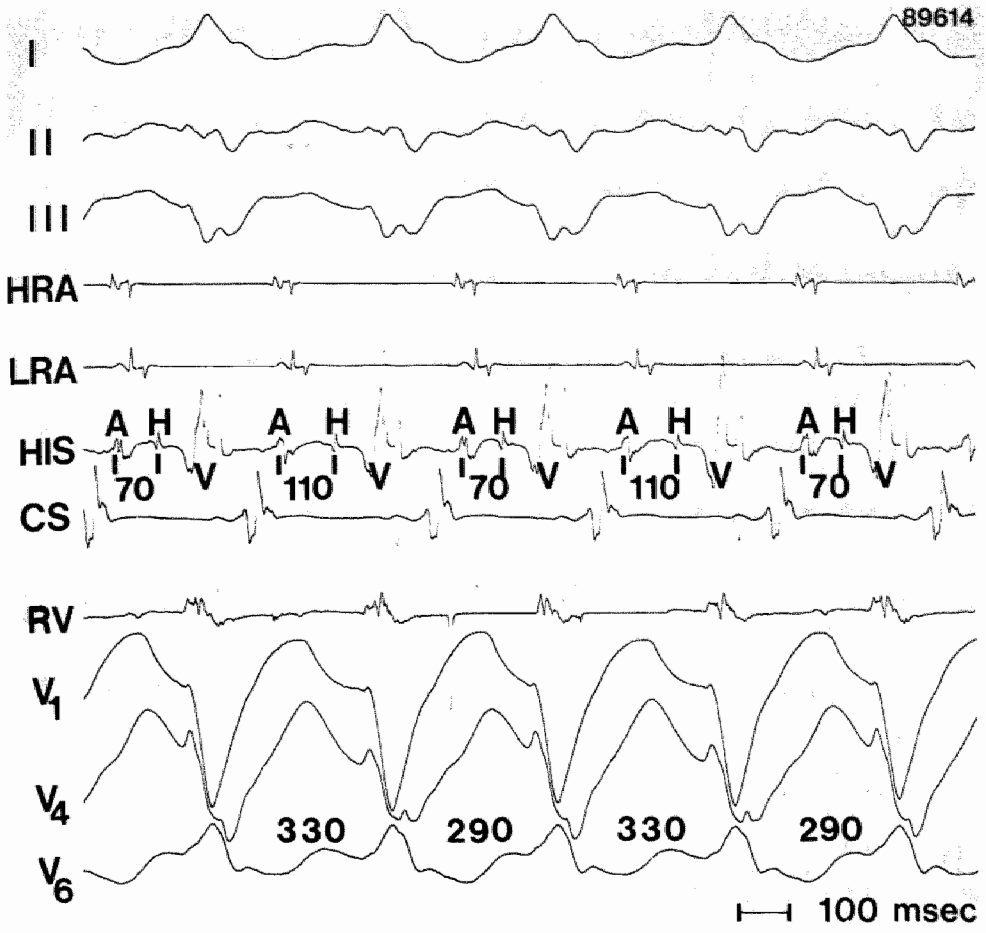

Figure 21. Cycle length alternation by 40 ms due to a change in the A-H interval (from 110 to 70 ms) in a patient with orthodromic circus movement tachycardia with left bundle branch block. Six simultaneous electrocardiographic leads and five intracardiac leads are shown, high right atrium (HRA), low right atrium (LRA), bundle of His (HIS) and coronary sinus (CS).

The QRS configuration during atrial fibrillation can give important clues to diagnose multiple accessory pathways. When two different accessory pathways capable of anterograde conduction are present, it is very likely to observe in the 12 lead electrocardiogram two different patterns of preexcitation during atrial fibrillation (Chapters V, VI).

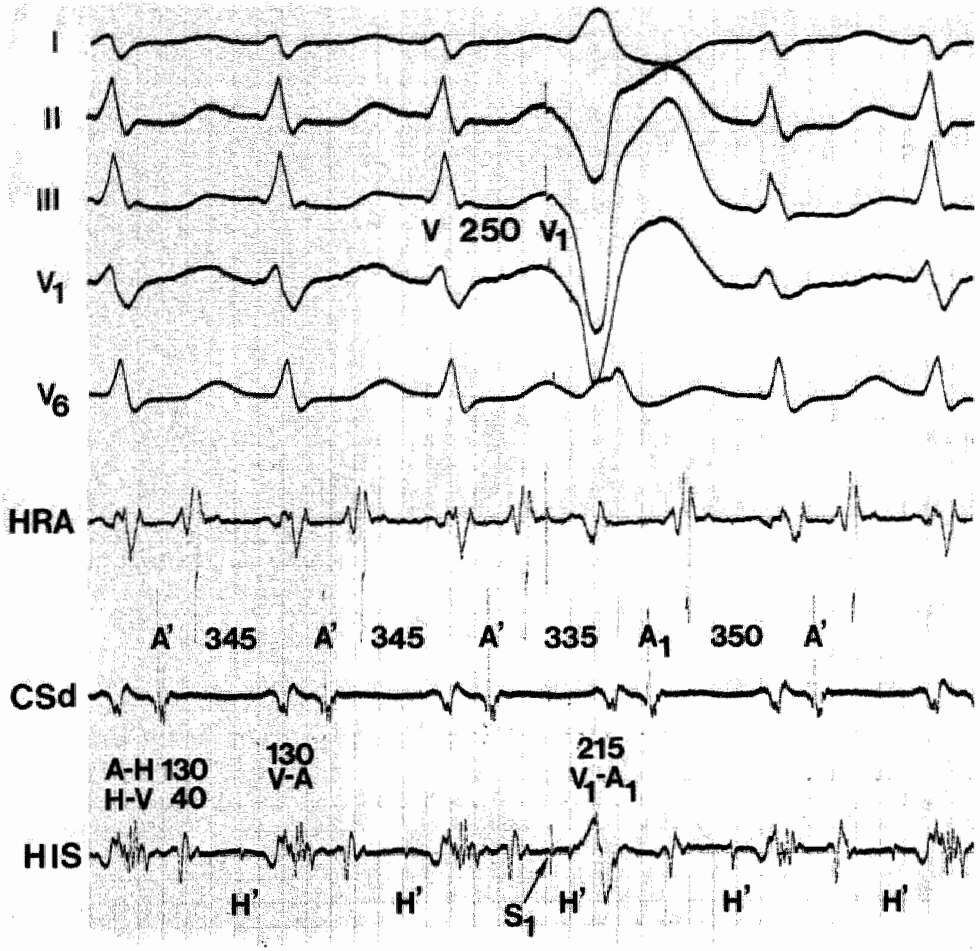

Figure 22. Five simultaneous recorded electrocardiographic leads and 3 intracardiac leads, high right atrium (HRA), distal coronary sinus (CSd) and bundle of His (HIS), showing the effect of a right ventricular apical premature beat given during orthodromic circus movement tachycardia. As shown this premature beat given at the time when the bundle of His is refractory, advances atrial activation. The V-A interval of the premature beat increases by 85 ms as compared to the V-A interval during tachycardia. This occurs because of the left lateral localization of the accessory pathway.

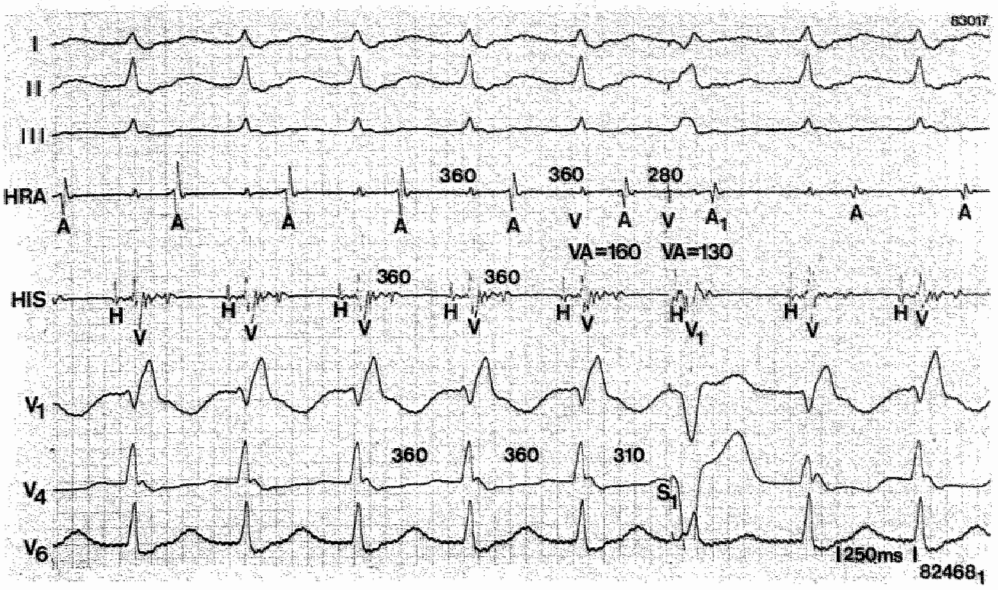

Figure 23. Example of paradoxical capture in a patient with a right lateral accessory pathway. During orthodromic circus movement tachycardia with a cycle length of 360 msec, a premature beat is given at the right ventricle (S1), at the time when the bundle of His is refractory. Subsequent atrial activation is advanced. The V-A interval following the ventricular premature beat measures 130 ms as compared to 160 ms during tachycardia.

MULTIPLE ACCESSORY PATHWAYS

The existence of multiple accessory pathways in the same patient, was first suggested in 1964 by the electrocardiographic observation of alternating type A and B of preexcitation in the same patient (79). Subsequently, the existence of multiple pathways has been confirmed during electrophysiological study and intraoperative mapping (77,78). The prevalence of multiple accessory pathways ranges between 3.7 and 15% in different studies (77,78).

Different drugs can demonstrate the presence of multiple accessory pathways on the 12 lead electrocardiogram during sinus rhythm (30) (fig. 25,26).

Failure to recognize the presence of multiple accessory pathways is a common cause for failure of surgical therapy in patients with the Wolff-Parkinson-White syndrome (80) (Chapter VII). Therefore, the presence and exact localization of accessory pathways must be clearly defined during electrophysiological study. As it will be described in Chapters IV and V, however, there are certain clues on the 12 lead electrocardiogram that should make the physician suspicious of the presence of more than one accessory pathway.

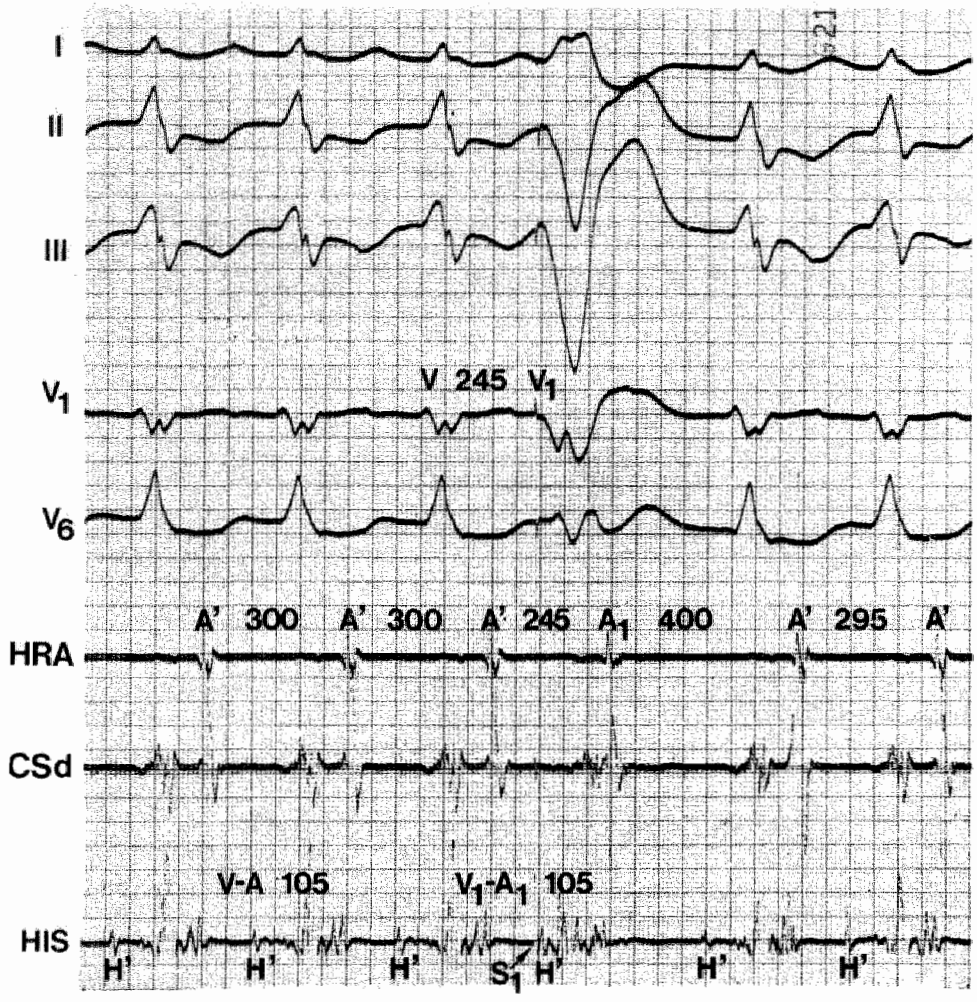

Figure 24. Five surface electrocardiographic leads and 3 intracardiac leads are shown, high right atrium (HRA), distal coronary sinus (CSd) and bundle of His (HIS). As shown, the ventricular premature beat has the same V-A interval as the V-A interval during tachycardia. Behaviour of the V-A interval following a right ventricular apical premature beat in septally located accessory pathway (exact capture).

CLINICAL CONSEQUENCES OF ACCESSORY PATHWAYS

The clinical significance of accessory pathways depends upon the type of arrhythmias the patient suffers from. This may vary from palpitations, dizziness, syncope or result on sudden cardiac death. In the symptomatic patient these arrhythmias do affect quality of life and may influence prognosis.

Quality of life is affected by the complaints, but also the recognition of preexcitation may result in social, job and insurance problems (1).

If the tachycardia occurs very frequently it may lead to a "tachycardiomyopathy" with progressive dilatation of the heart eventually resulting in congestive heart failure (81).

While a symptomatic patient will suffer from these problems, the asymptomatic patient with the Wolff-Parkinson-White syndrome is not without risks. Asymptomatic patients with the Wolff-Parkinson-White syndrome, may have a very short anterograde refractory period of the accessory pathway, and the first symptom may be sudden cardiac death. In a multicenter study from 7 european centers (67), ventricular fibrillation was the first manifestation of the Wolff-Parkinson-White syndrome in 7 out of 23 patients (30%).

At present diagnostical and therapeutical possibilities for patients with the Wolff-Parkinson-White syndrome are extensive. By making the correct diagnosis and prescribing the appropriate treatment it is possible to return them to a fully normal life.

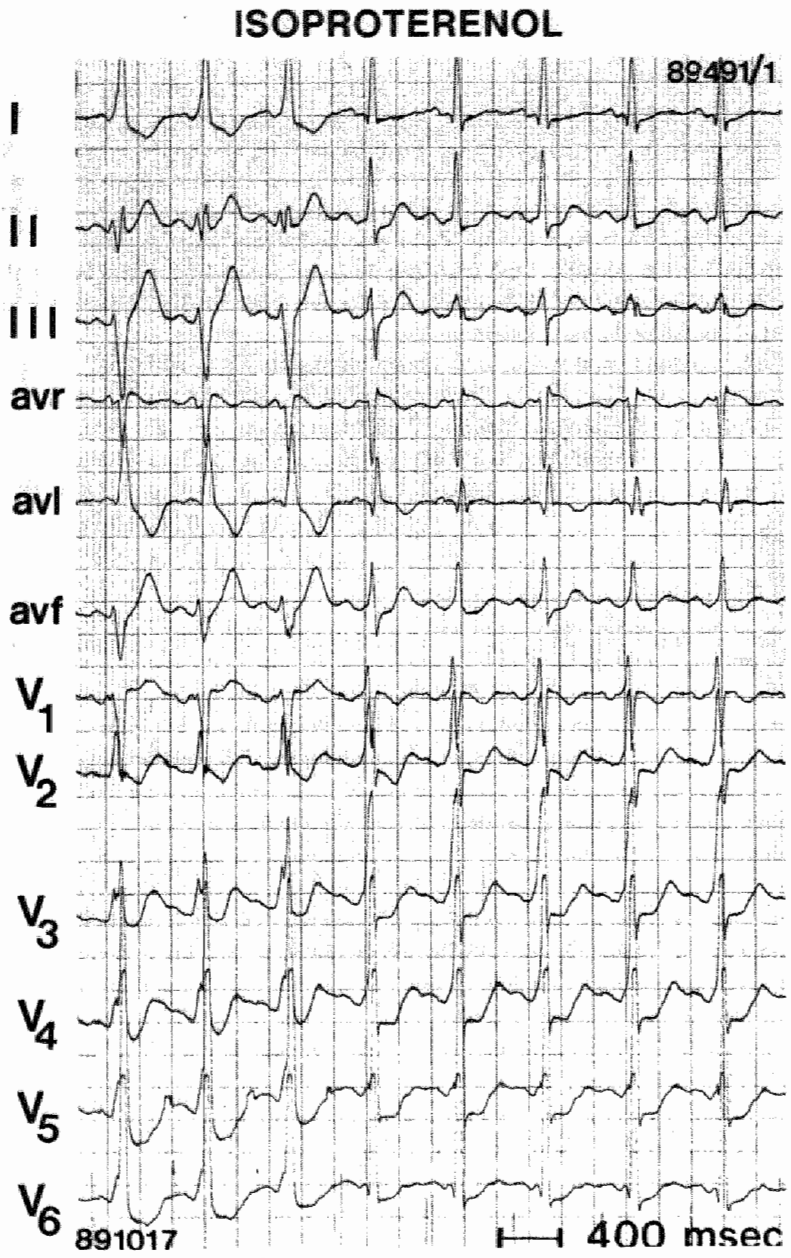

Figure 25. Exposure of two accessory atrioventricular pathways by isoproterenol in a patient with the Wolff-Parkinson-White syndrome. A change in preexcitation pattern is shown after the third QRS complex. The figure illustrates how, because of different electrophysiologic properties, the presence of two accessory atrioventricular pathways can be exposed during the administration of isoproterenol.

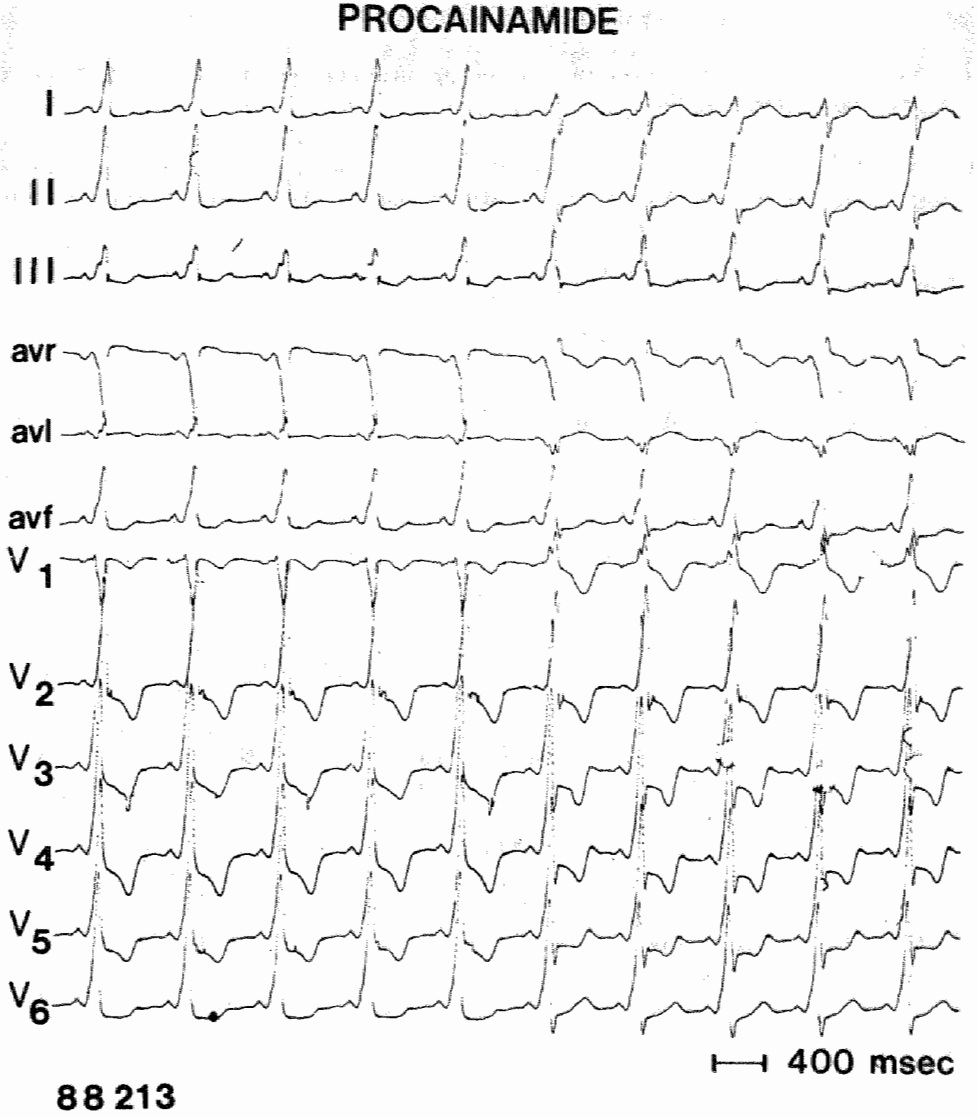

Figure 26. Exposure of two accessory atrioventricular pathways by procainamide in a patient with the Wolff-Parkinson-White syndrome. The left part of figure shows a different preexcitation pattern from the right side.

REFERENCES

1. Wellens HJJ, Brugada P, Penn OC: The management of preexcitation syndromes. JAMA 257: 2325, 1987.

2. Durrer D, Schoo L, Schuilenburg RM, Wellens HJJ: The role of premature beats in the initiation and termination of supraventricular tachycardia in Wolff-Parkinson-White syndrome. Circulation 36: 644, 1967.

3. Wilson FN: A case in which the vagus influenced the form of ventricular complex of the electrocardiogram. Arch Intern Med 16: 1008, 1915.

4. Weed AM: Paroxysmal tachycardia. With reference to nomotopic tachycardia and the role of the extrinsic cardiac nerves. Arch Intern Med 27: 571, 1921.

5. Bach R: Paroxysmal tachycardia of 48 years duration and right bundle branch block. Proc Royal Soc Med 22: 314, 1929.

6. Hamburger WW: Bundle branch block. Four cases of intraventricular blocks showing some interesting and unusual clinical features. Med Clin North Am. 13: 343, 1929.

7. Wolff L, Parkinson J, White PD: Bundle branch block with short P-R interval in healthy young people prone to paroxysmal tachycardia. Am Heart J 5: 685, 1930.

8. Paladino G: Contribuzione a l'anatomia, istologia e fisiologia del cuore. Moiv Med Chir (Napoli) 8: 428, 1876.

9. Kent AFS: Researches on structure and function of mammalian heart. J Physiol 14: 233, 1876.

10. Mines GR: On circulating excitation in heart muscles and their possible relation to tachycardia and fibrillation. Trans R Soc Can Ser 8: 43, 1914.

11. de Boer S. Herzwuhlen, Flimmern, Flattern: Gehaufte extrasystolie, parozysmale tachykardie. Pflugers Arch 187: 193, 1921.

12. Holzman M and Scherf D: Uber elektrokardiogramme mit vorkurzten vorhol Kanner-Distanz and positiven P-Zacken. Z Klin Med 121: 404, 1932.

13. Wolferth CC and Wood FC: The mechanism of production of short P-R intervals and prolonged QRS complexes in patients with presumably undamaged hearts. Hypothesis of an accessory pathway of auriculoventricular conduction (bundle of Kent). Am Heart J 8:297, 1933.

14. Wood FC, Wolferth CC, and Geckele GD: Histological demonstration of accessory muscular connections between auricle and ventricle in a case of short P-R interval and prolonged QRS complex. Am Heart J 252: 454, 1943.

15. Ohnell RF: Preexcitation, a cardiac abnormality. Acta Med Scand 152: 74, 1944.

16. Rosenbaum FF, Hecht HH, Wilson FN, Johnson FD: The potential variation of the thorax and the esophagus in anomalous atrioventricular excitation. Am Heart J 19: 281, 1945.

17. Sodi Pallares D, Soberon J, Thomsen P, Fishleder BL, Estandia A: Contribucion al estudio del Sindrome de WPW por las derivaciones intracavitarias. Arch Instit Cardiol Mex 8: 1, 1948.

18. Hecht HH: Further observations on the spread of ventricular excitation. Anomalous atrioventricular excitation. The electrophysiology of the heart. Ann N Y Acad Sci 65:841, 1957.

19. Wellens HJJ: Electrical stimulation of the heart in the study and treatment of tachycardias. University Park Press, Baltimore, Maryland, 1971.

20. Slama R, Coumel P, Bouvrain Y: Les syndromes de Wolff-Parkinson-White de type A inapparents ou latent en rhythm sinusal. Arch Mal Coeur 66: 639, 1974.

21. Zipes DP, De Joseph RL, Rothbaum DA: Unususal properties of accessory pathways. Circulation 49: 1200, 1974.

22. Wellens HJJ Durrer D: The role of an accessory atrioventricular pathway in reciprocal tachycardia. Observations in patients with and without the Wolff-Parkinson-White syndrome. Circulation 52: 58, 1978.

23. Gallagher JJ, Sealy WC: The permanent form of junctional reciprocating tachycardia: further elucidation of the underlying mechanism. Eur J Cardiol 8: 413, 1978.

24. Farré J, Ross D, Wiener I, Bar FW, Vanagt EJ, Wellens HJJ: Reciprocal tachycardias using accessory pathways with long conduction times. Am J Cardiol 44: 1099, 1979.

25. Coumel P, Attuel P, Mujica J: Junctional reciprocating tachycardia. The permanent form. In: Re-entrant Arrhythmias, Mechanisms and Treatment, edited by Kubertus HE. England, Lancaster, MTP Press; 1977: p 170.

26. Dreifus LS, Haiat R, Watanabe Y et al: Ventricular fibrillation, a possible mechanism of sudden death in patients with the Wolff-Parkinson-White syndrome. Circulation 43: 520, 1971.

27. Klein GJ, Bashore TM, Seller TD et al: Ventricular fibrillation in the Wolff-Parkinson-White syndrome. N Engl J Med 301: 1080, 1979.

28. Wellens HJJ, Durrer D: Effect of digitalis on atrio-ventricular conduction and circus movement tachycardia in patients with the Wolff-Parkinson-White syndrome. Circulation 47: 1229, 1973.

29. Rosen KM, Barwolf C, Ehsari A, Rahimtoola SM: Efect of lidocaine and propranolol on the normal and anomalous pathways in patients with preexcitation. Am J Cardiol 30: 801, 1972.

30. Wellens HJJ, Durrer D: Effect of procainamide, quinidine and ajmaline on the Wolff-Parkinson-White syndrome. Circulation 50: 114, 1974.

31. Cobb FR, Blumenschein SD, Sealy WC, Boineau JP, Wagner GS, Wallace AG: Successful surgical interruption of the bundle of Kent in a patient with Wolff-Parkinson-White syndrome. Circulation 38: 1018, 1968.

32. Gallagher JJ, Sealy WC, Cox JL, Kasell JH: Results of surgery for pre-excitation in 200 cases. Circulation 64: 146, 1981.

33. Guiraudon GM, Klein GJ, Sharma AD, Milstein S, McLellan DG: Close-Heart technique for the Wolff-Parkinson-White syndrome: Further experience and potential limitations. Ann Thorac Surg 42: 651, 1986.

34. Morady F, Scheinman MM, Kou WH, Griffin JV, Dick M, Herre J, Kadish AH, Langberg J: Long-term results of catheter ablation of a posteroseptal accessory atrioventricular connection in 48 patients. Circulation 79: 1160, 1989.

35. Hindricks G, Borggrefe M, Haverkamp W, Rubio AM, Karbenn U, Budde T, Rissel U, Gulker H, Breithardt G: Significant of monitoring catheter tip temperature during radiofrequency ablation in patients with supraventricular tachyarrhythmias. Am Heart J 10: 165, 1989. (Abstr)

36. Jackman WM, Friday KJ, Scherlag BJ: Direct endocardial recording from an accessory pathway: localization of the site of block, effect of antiaarrhythmic drugs, and attemp of non surgical ablation. Circulation 68: 906, 1983.

37. Anderson RH, Becker AE, Brechenmacher C, Davies MJ, Rossi: Ventricular preexcitation: A proposed nomenclature for its substrates. Eur J Cardiol 31: 27, 1975.

38. Becker AG, Anderson RW, Durrer D, Wellens HJJ: The anatomical substrates of Wolff-Parkinson-White syndrome. A clinicopathologic correlation in seven patients. Circulation 57: 870, 1978.

39. Gallagher JJ, Pritchett ELC, Sealy WC, Kasell J, Wallace AG: The preexcitation syndromes. Prog Cardiovasc Dis 20: 285, 1978.

40. Wellens HJJ: Contribution of cardiac pacing to our understanding of the Wolff-Parkinson-White syndrome. Br Heart J 37: 231, 1975.

41. Critelli G, Gallagher JJ, Thiene G, Perticone F, Coltorti F, Rossi L: Electrophysiologic and histopathologic correlations in a case of permanent form of reciprocating tachycardia. Eur Heart J 6: 130, 1985.

42. Mahaim I, Winston MR: Recherchers d'anatomie comparée et de pathologie expérimentale sur les connexions hautes de His-Tawara. Cardiologia 5: 189, 1941.

43. Ellenbogen KA, Ramirez NM, Packer DL, O'Callaghan WG, Greer GS, Sintetos AL, Gilbert MR, German LD: Accessory nodoventricular (Mahaim) fibers: A clinical review. PACE 9: 868, 1986.

44. Tchou P, Lehmann MH, Jazayeri M, Akhtar M: Atriofascicular connection or a nodoventricular Mahaim fiber? Electrophysiologic elucidation of the pathway and associated reentrant circuit. Circulation 77: 837, 1988.

45. Klein GJ, Guiraudon GM, Kerr CR, Sharma AD, Yee R, Szabo T, Yeung Laiwah JAY. "Nodoventricular" accessory pathway: Evidence for a distinct accessory atrioventricular pathway with atrioventricular node-like properties. J Am Coll Cardiol 11: 1035, 1988.

46. Atié J, Brugada P, Smeets JLRM, Cruz FES, Penn OCKM, Wellens HJJ: Further support of the atrio-ventricular localization of so-called "Mahaim Fibers". J Am Coll Cardiol 13: 232, 1989. (Abstr).

47. Kaplan MA, Cohen KL: Ventricular fibrillation in the Wolff-Parkinson-White syndrome. Am J Cardiol 24: 259, 1969.

48. James TN: Morphology of the human AV node, with remarks pertinent to its electrophysiology. Am Heart J 62: 756, 1961.

49. Lown B, Ganong WF, Levine SA: The syndrome of short PR interval, normal QRS complex and paroxysmal rapid heart action. Circulation 5: 593, 1952.

50. Brechenmacher C: Atrio-His bundle tracts. Brit Heart J 37: 853, 1975.

51. Chung KY, Walsh TI, Massie E: Wolff-Parkinson-White syndrome. Am Heart J 69: 116, 1965.

52. Klein GJ, Gulamhusein SS: Intermitent pre-excitation in the Wolff-Parkinson-White syndrome. Am J Cardiol 52: 292, 1983.

53. Wellens HJJ, Farré J, Bär FW. The Wolff-Parkinson-White syndrome. In: Cardiac arrhythmias, WJ Mandel (Ed). Lippicott, Pliladelphya, 1980 p 342.

54. Sung RJ, Gelband H, Castellanos A, Aranda JM, Myerburg RJ: Clinical and electrophysiological observations in patients with concealed accessory bypass tracts. Am J Cariol 40: 839, 1977.

55. Gallagher JJ, Smith WM, Kasell JH et al: Role of Mahaim fibers in cardiac arrhythmias in man. Circulation 64: 176, 1981.

56. Benditt DG, Pritchett ELC, Gallagher JJ: Spectrum of regular tachycardias with wide QRS complexes in patients with accessory atrioventricular pathways. Am J Cardiol 42: 828, 1978.

57. Bär FW, Brugada P, Dassen WRM, Wellens HJJ: Differential diagnosis of tachycardia with narrow QRS complex (shorter than 0.12 second). Am J Cardiol 54: 455, 1984.

58. Fontaine G, Frank R, Coutte R, Vedel JP, Grosgogeat Y: Rhythme reciproqué antidromique dans un syndrome de Wolff-Parkinson-White de type A. Ann Cardiol Angeiol 24: 59, 1975.

59. Laham J: Les syndrome de Wolff-Parkinson-White. Paris, Librarie Maloine SA 1969: p 102.

60. Wellens HJJ: The electrophysiologic properties of the accessory pathway in the Wolff-Parkinson-Whote syndrome. In: The conduction system of the heart. Wellens HJJ, Lie KI, Janse MJ (Eds), Lea and Febiger. Philadelphia 1976, p 567.

61. Della Bella P, Brugada P, Talajic M, Torner P, Lemery R, Dugernier T, Wellens HJJ: Atrial fibrillation in patients with accessory pathways: differences between patients with the Wolff-Parkinson-White syndrome and those with concealed accessory pathways. J Am Coll Cardiol 9: 12A, 1987. (Abstr)

62. Wellens HJJ, Durre D: Wolff-Parkinson-White syndrome and atrial fibrillation. Relation between refractory period of accessory pathway and ventricular rate during atrial fibrillation. Am J Cardiol 34: 771, 1974.

63. Stevens RH, Miller HC, Gallagher JJ et al: Electrophysiological evaluation of the Wolff-Parkinson-White syndrome. Problems in assessing anterograde and retrograde conduction over the accessory pathway. Circulation 52: 552, 1975.

64. Sung RJ, Styperek JL: Electrophysiologic identification of dual atrioventricular nodal pathways conduction in patients with reciprocating tachycardia using anomalous bypass tracts. Circulation 60: 1464, 1979.

65. Saulnier JP, Nouvialfe R, Aliot E, et al: Reentry tachycardia with complete atrioventricular dissociation probably connected with the right Mahaim bundle. Arch Mal Coeur 72: 1259, 1979.

66. Milstein S, Sharma AD, Klein GJ: Electrophysiologicic profile of asymptomatic Wolff-Parkinson-White pattern. Am J Cardiol 57: 1097, 1986.

67. Torner PM, on behalf of the European Registry on Sudden Death in the Wolff-Parkinson-White syndrome: Ventricular fibrillation in the Wolff-Parkinson-White syndrome. PACE 11: 46, 1988.

68. Tonkin AM, Wagner GS, Gallagher JJ, Cope CD, Kasell J, Wallace AG: Initial forces of ventricular depolarization in the Wolff-Parkinson-White syndrome. Circulation 52: 1030, 1975.

69. Lindsay BD, Crossen KJ, Cain ME: Concordance of distinguishing electrocardiographic features during sinus rhythm with the location of accessory pathways in the Wolff-Parkinson-White syndrome. Am J Cardiol 59: 1093, 1987.

70. Milstein S, Sharma AD, Guiraudon GM, Klein GJ: An algorithm for the electrocardiographic localization of accessory pathways in the Wolff-Parkinson-White syndrome. PACE 10: 555, 1987.

71. Reddy GV, Schamroth L: The localization of bypass tracts in the Wolff-Parkinson-White syndrome from the surface electrocardiogram. Am Heart J 113: 984, 1987.

72. Civera RC, Ferrero JA, Sanjuan R, Insa L, Rodrigues M, Segui J, Merino VL, Llavador J: Retrograde P wave polarity in reciprocating tachycardia utilizing lateral bypass tracts. Eur Heart J 1: 137, 1980.

73. Puech P, Grolleau R, Cinca J: Reciprocating tachycardia using a latent left-sided accessory pathway. Diagnostic approach by conventional ECG. In: Re Entrant Arrhythmias, edited by Kulbertus H. Lancaster, England: MTP Press 1977: p 117.

74. Kerr CR, Gallagher JJ, German LD: Changes in ventriculoatrial intervals with bundle branch block aberration during reciprocating tachycardia in patients with accessory pathways. Circulation 66: 196, 1982.

75. Weiss J, Brugada P, Roy D, Bar FWHM, Wellens HJJ: Localization of the accessory pathway in the Wolff-Parkinson-White syndrome from the ventriculo-atrial conduction time of right ventricular apical extrasystoles. PACE 6: 260, 1983.

76. Wellens HJJ, Ross DL, Farré J, Brugada P: Functional bundle branch block during supraventricular tachycardia in man. Observations on mechanisms and their incidence. In: Cardiac Electrophysiology and Arhythmias. Zipes D and Jaliffi J (Eds), Grune and Stratton, Orlando, 1985, p 435.

77. Gallagher JJ, Sealy WC, Kasell J, Wallace AG: Multiple accessory pathways in patients with the pre-excitation syndrome. Circulation 54: 571, 1976.

78. Colavita PG, Packer DL, Pressley JC, Ellenbogen KA, O'Callaghan WG, Gilbert MR, German LD: Frequency, diagnosis and clinical characteristics of patients with multiple accessory atrioventricular pathways. Am J Cardiol 59: 601, 1987.

79. Matter BJ, Hayes WL: Wolff-Parkinson-White syndrome, report of a case with both type A and type B preexcitation. Am J Cardiol 13: 284, 1964.

80. Sealy WC, Gallagher JJ: Surgical problems with multiple accessory pathways of atrioventricular conduction. J Thorac Cardiovasc Surg 81: 707, 1981.

81. Cruz F, Brugada P, Smeets J, Atié J, Duque M, Cheriex E, Mackelenberg B, Penn O, Wellens HJJ: Reversibility of tachycardia induced cardiomyopathy after surgical cure of incessant supraventricular tachycardia. Eur Heart J 10: 226, 1989. (Abstr).

Chapter II

Further support of the atrio-ventricular localization of so-called "Mahaim Fibers"

Jacob Atié
Pedro Brugada
Joep L.R.M. Smeets
Fernando E.S. Cruz
Olaf C.K.M. Penn
Marie P. Roukens
Hein J.J. Wellens

Further support of the atrio-ventricular localization of so-called "Mahaim Fibers"

SUMMARY

To further characterize the type of pathway of apparently nodo-ventricular accessory pathways, data of 7 patients suggesting the diagnosis of a Mahaim accessory pathway were analyzed. In 2 patients, ventricular activation could be advanced during tachycardia by a right atrial premature beat given simultaneously with the onset of retrograde atrial activation suggesting a direct atrio-ventricular connection of the accessory pathway. In one of these patients the atrio-ventricular localization of the accessory pathway was confirmed during surgery. In a third patient epicardial dissection of the right lateral atrio-ventricular groove interrupted anterograde pre-excitation and tachycardia, demonstrating a direct atrio-ventricular connection of the accessory pathway. In the other 4 patients, analysis of the electrophysiological studies suggested a classical nodo-ventricular accessory pathway. However, an atrio-ventricular accessory pathway with anterograde decremental conduction properties could not be excluded. In conclusion, 3 of our 7 patients suspected to have nodo-ventricular accessory pathways had an atrio-ventricular accessory pathway with decremental conduction.

Presented at the American College of Cardiology. J Am Coll Cardiol 1989;13:232, and at the European Society of Cardiology. Eur Heart J 1989;10:382.
Submitted for publication

INTRODUCTION

In 1941 Mahaim described the existence of islands of conducting tissue running from atrio-ventricular node into the ventricular myocardium (1). In 1971, one of us reported the results of a electrophysiologic study in a patient with such connection (2). Since then, several authors have analyzed the electrocardiographic and electrophysiological features attributed to these fibers (3-9). Hallmark of the diagnosis of a nodo-ventricular fiber was: 1) Lengthening of the stimulus-delta interval on shortening the atrial pacing rate or atrial premature beat interval and 2) The demonstration that the atrium was not participating in the reentry circuit (2,3). In 1979 however Farré et al (10) reported a patient with an atrioventricular accessory pathway that showed anterograde decremental conduction properties (10). In 1985 Critelli et al (11) reported a patient presenting with a concealed accessory atrio-ventricular pathway having retrograde decremental conduction in whom the accessory pathway conducted anterogradely with a long conduction time after ablation of the bundle of His. Recently, observations during electrophysiologic study and surgery in patients with an accessory pathway that behaved as a typical nodo-ventricular fiber demonstrated that the accessory pathway was truly atrio-ventricular with slow anterograde conduction (12,13).

This study, reports our findings in 7 patients initially considered as having a nodo-ventricular accessory pathway.

PATIENTS AND METHODS

Patients

The seven patients in our study were selected from 314 consecutive studied in our hospital between 1979 and April 1988 for evaluation and treatment of various preexcitation syndromes. Three patients were studied after publication of the articles by Tchou (12) and Klein (13). In the other 4 patients the data were analyzed retrospectively. Six patients were male and one female. The mean age was 25 years (18 to 41 years). All patients had a complete electrophysiological study using previously described techniques (14). Two patients underwent surgery for ablation of the accessory pathway.

Electrophysiological study

The criterium for the diagnosis of the nodo-ventricular accessory pathway was: Progressive prolongation of the A-H and A-delta interval during incremental right atrial pacing and atrial premature beats with progressively shorter premature beat intervals. During the prolongation of the A-H interval the QRS morphology showed progressive preexcitation because the A-H interval prolonged more than the A-delta interval (fig. 1).

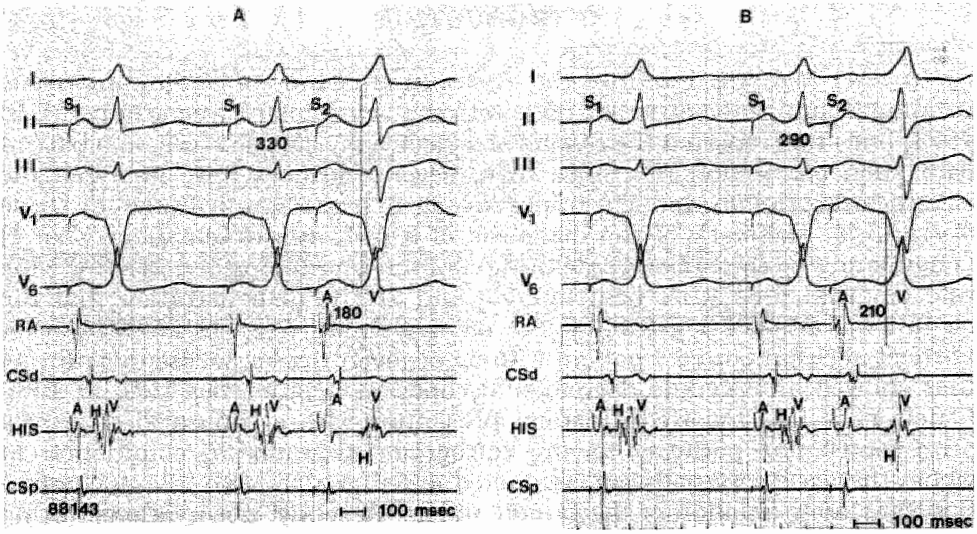

Figure 1. Five surface electrocardiographic leads and intracardiac electrograms from the high right atrium (RA), bundle of His (His), right ventricle (RV), proximal (CSp) and distal (CSd) coronary sinus. During atrial pacing with a cycle length of 500 ms the QRS complex is slightly preexcited. Maximal preexcitation occurs following the atrial premature beat given after an S1-S2 interval of 330 ms (panel A). The AV conduction time is 180 ms. After a further decrease in the S1-S2 interval by 40 ms, the AH and AV conduction time continues to prolong, with displacement of the His deflection into the ventricular electrogram and maximal preexcitation (panel B).

The criteria for the diagnosis of an atrio-ventricular accessory pathway with slow anterograde conduction were all the criteria described for the nodo-ventricular accessory pathway, associated with: (1) Advancement of ventricular activation during tachycardia by an atrial premature beat delivered just at the onset of retrograde atrial activation (time of A-V nodal refractoriness) (fig. 2,3), demonstrating dissociation at the atrial level of the two pathways involved in tachycardia. (2) Successful ablation of the accessory pathway after epicardial surgical dissection and mobilization of the right atrio-ventricular fat pad with exposure and cryoablation of the atrio-ventricular junction at the right free wall (15).

Surgery

Operative therapy was carried out using the close-heart technique described by Guiraudon et al (15). A ventricular ring map was obtained during sinus rhythm, atrial pacing and tachycardia, and an atrial ring map during ventricular pacing and tachycardia.

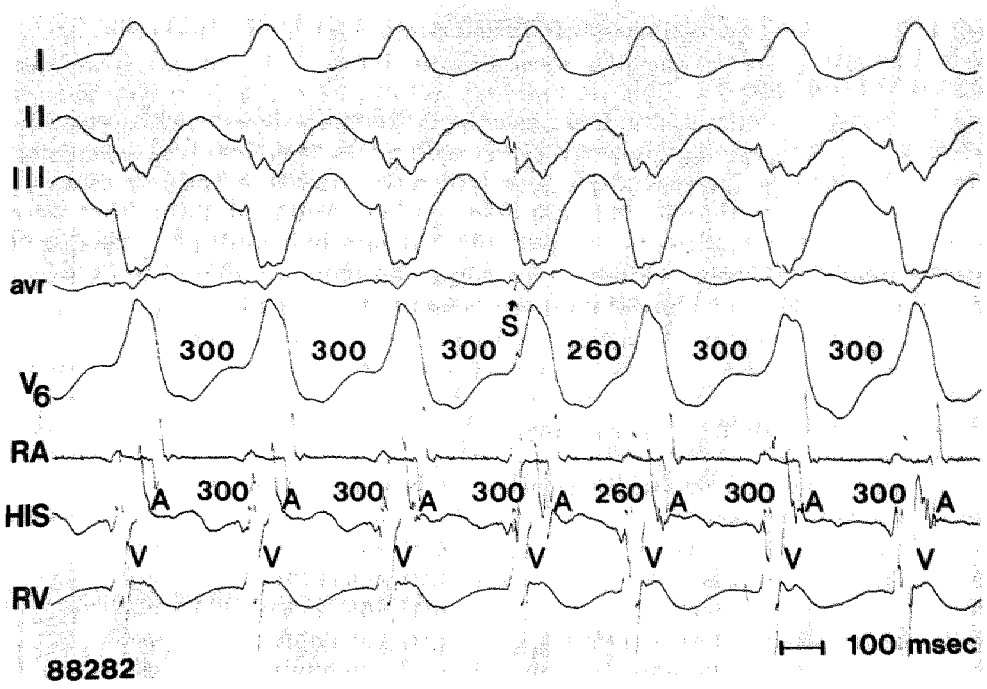

Figure 2. Surface and intracardiac electrograms recorded during reciprocating tachycardia from a patient with an atrio-ventricular accessory pathway with decremental conduction. Five surface leads and three endocavitary bipolar electrograms are shown. An atrial premature beat given in the low right atrium (S) advances ventricular activation by 40 ms, without modifying retrograde atrial activation.

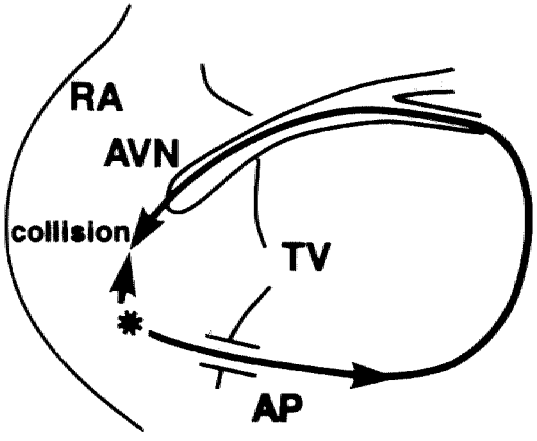

Figure 3. Schematic representation of how an atrial premature beat given at the time of onset of retrograde atrial activation can advance ventricular activation and show proximal dissociation of the two pathways. (AP = accessory pathway; AVN = atrio-ventricular node; RA = right atrium; TV = tricuspide valve).

RESULTS

Clinical Findings

From our 7 patients, one had associated Ebstein's disease with ventricular septal defect, another hypertrophic cardiomyopathy. Two had associated dual atrio-ventricular pathways. Two had also another accessory pathway than the nodo-ventricular "Mahaim fiber". Other cardiac abnormalities were not found in these patients. All patients but one had multiple episodes of circus movement tachycardia and syncope, one patient suffered from incessant tachycardia. The clinical data are presented in table I.

Table I. Clinical data

Pt	Age	sex	Associated anomalies	Presenting arrhythmia	Syncope
1	18	M	none	CMT with LBBB	yes
2	41	F	none	CMT with LBBB	yes
3	24	M	none	CMT with LBBB	no
4	18	M	Ebstein + VSD	CMT with LBBB	yes
5	16	M	Hypertrophic CMP	CMT with RBBB V.F.	yes
6	18	M	none	CMT with LBBB Atrial fibrillation	yes
7	40	M	none	CMT with LBBB	yes

Abbreviations: CMT = circus movement tachycardia; CMP = cardiomyopathy; VSD = ventricular septal defect; VF = ventricular fibrillation; LBBB = left bundle branch block morphology; RBBB = right bundle branch block morphology.

Electrocardiographic findings

At rest, the surface electrocardiogram showed a short PR interval in three patients and a normal PR interval in the remaining four. In two patients a delta wave was present, one of them had also a Kent type atrio-ventricular pathway. During tachycardia all patients had a QRS duration of.12 seconds or more, 6 patients had a left bundle branch block morphology with an axis between 0 and -60° in the frontal plane and one a right bundle branch block morphology with a QRS axis of +120°.

Electrophysiological findings

All patients fulfilled the criteria for a nodo-ventricular accessory pathway, six had the classical left bundle branch morphology during incremental atrial pacing and tachycardia, and one had a right bundle branch morphology.

In three patients atrial stimuli were introduced during tachycardia at the low right atrium. The atrial stimuli were delivered just at the onset of retrograde atrial activation. In two patients an atrial premature beat advanced subsequent ventricular activation (fig. 2,3). The ability to preexcite the ventricle during tachycardia at the time of A-V nodal refractoriness, indicated that the accessory pathway originated directly from the atrium (fig. 3).

Surgery

Surgical dissection of the accessory pathway was carried out in the normothermic beating heart in two patients. Epicardial mapping during both atrial pacing and antidromic tachycardia showed earliest epicardial activation at the right free wall (fig. 4) in both patients. Earliest retrograde activation during ventricular pacing and tachycardia was observed in the septal area. Epicardial dissection performed at the right atrio-ventricular groove, followed

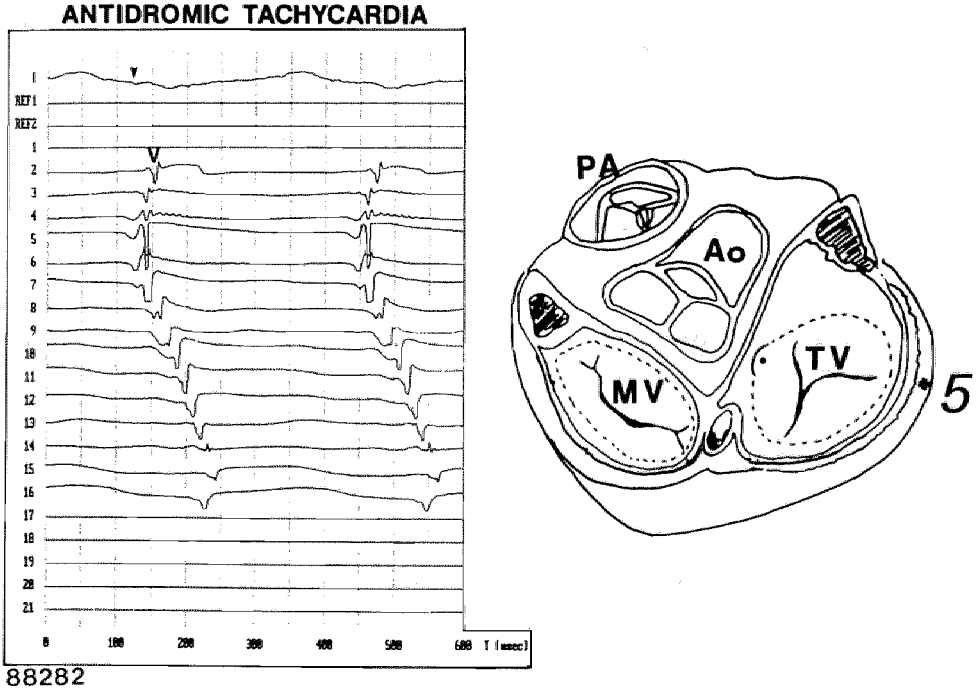

Figure 4. Peroperative epicardial ventricular mapping during antidromic tachycardia. The earliest epicardial activation is recorded in electrode 5, corresponding to the right free wall as showed in the diagram of the superior view of the heart. (MV = mitral valve, PA = pulmonary artery, TV = tricuspid valve, Ao = Aorta).

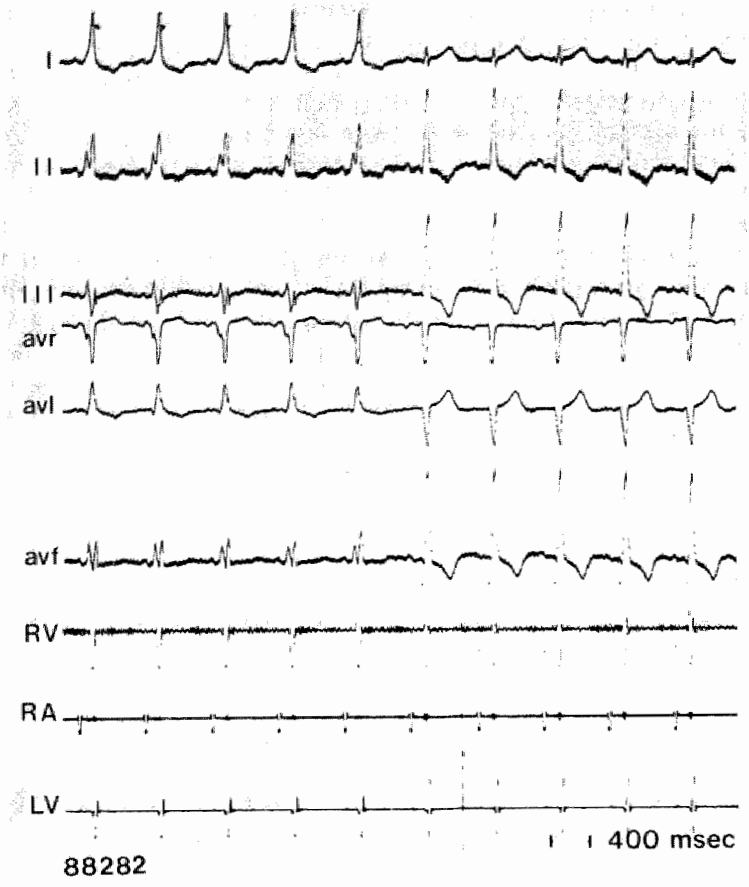

Figure 5. Surface ECG and epicardial leads at the very moment of interruption of preexcitation during surgery performed in the right A-V groove. In the left part a preexcited QRS complex is observed, which disappears in the right part after a single cycle.

by cryoablation, abolished pre-excitation and no tachycardia could be induced in both patients (fig. 5). After a follow-up of four and seven months these patients remain free of arrhythmias.

In the other 4 patients no sufficient data were available to exclude an accessory atrio-ventricular pathway with slow anterograde conduction. Late atrial premature beats had not been given during tachycardia in these patients in whom data were analyzed retrospectively.

DISCUSSION

The data from this partially prospective and partially retrospective study come to further support an atrio-ventricular localization of accessory pathways presenting with electrocardiographic and electrophysiologic features suggestive of a nodo-ventricular accessory pathway. Like in the previous reports by Tchou et al (12) and Klein et al (13), only detailed electrophysiologic studies along with data from surgery allowed the exact localization of the implantation of the accessory pathway. This is confirmed by the impossibility to exactly localize the accessory pathway implantation in the 4 retrospectively analyzed patients. In them very late atrial premature beats (at the time of onset of retrograde atrial activation) were not given and made it impossible to exclude an atrio-ventricular implantation of the accessory pathway. One has to realize however, that even the inability to advance subsequent ventricular activation by a very late atrial premature beat not influencing onset of retrograde atrial activation does not allow the positive diagnosis of a nodo-ventricular accessory pathway. The decremental anterograde conduction properties of the accessory pathway may make it impossible to advance subsequent ventricular activation even when the accessory pathway is truly atrio-ventricular. The only criterium which positively can demonstrate a nodo-ventricular accessory pathway is the presence of atrio-ventricular dissociation during tachycardia (16,17).

Data from this and previous studies (12,13) demonstrating the existence of atrio-ventricular accessory pathways with anterograde slow decremental conduction are of importance when surgery is considered. Epicardial dissection at the right atrio-ventricular groove cured our two patients undergoing surgery and definitely proved the atrio-ventricular localization of the accessory pathway. Because of their possible nodo-ventricular implantation, patients with findings suggestive of a Mahaim accessory pathway have been considered a separate problem as compared to patients with the classic Wolf-Parkinson-White syndrome. The results of this and previous (12,13) studies show that the only difference may be the electrophysiologic properties and not the localization of the accessory pathway.

In patients with features suggesting a Mahaim accessory pathway a slowly conducting atrio-ventricular accessory pathway has to be considered. Detailed electrophysiologic study is necessary to prove this hypothesis, because accessory atrio-ventricular pathways can be easily dissected surgically resulting in permanent cure of the arrhythmia.

REFERENCES

1. Mahaim I, Winston MR. Recherches d'anatomic comparee et du pathologie experimentale sur les connections hautes du faisceau et du pathologie experimentale sur les connexions hautes du faisceau de His-Tawara. Cardiologia 1941;5: 189-260.

2. Wellens HJJ. Electrical Stimulation of the Heart in the Study and Treatment of Tachycardias. Baltimore:University Park Press 1971; 97-109.

3. Bardi GH, German LD, Packer DL, Coltorti F, Gallagher JJ. Mechanism of tachycardia using a nodofascicular Mahaim fiber. Am J Cardiol 1984;1: 1140-1141.

4. Lerman BB, Waxman HL, Proclemer A, Josephson ME. Supraventricular tachycardia associated with nodoventricular and concealed atrioventricular bypass tracts. Am Heart J 1982;104: 1097-1102.

5. Gmeiner R, Keung N C, Hammer I, Becker AE. Tachycardia caused by an accessory nodoventricular tract: a clinic-pathologic correlation. Eur Heart J 1984;5: 233-242.

6. Ellenbogen KA, Ramirez NM, Packer DL, O'Callaghan WG, Greer GS, Sintetos AL, Gilbert MR, German LD. Accessory nodoventricular (Mahaim fibers: a clinical review. Pace 1986;9: 868-884.

7. Gallagher JJ, Smith WM, Kassell JH, Benson DWJ, Sterba R, Grant AO. Role of Mahaim fibers in cardiac arrhythmias in man. Circulation 1981;64: 176-189.

8. Motté G, Brechenmacher C, Davy JM, Belhassen B. Association des fibres nodo-ventriculaires et atrio-ventriculaires à l'origine de tachycardies réciproques. Arch Mal Coeur 1980;6: 737-746.

9. Smith WS, Broughton A, Reiter MJ, Benson DWJ, Grant AO, Gallagher JJ. Bystander accessory pathway during AV node re-entrant tachycardia. Pace 1983;6: 537-547.

10. Farré J, Ross D, Wiener I, Bar FW, Vanagt EJ, Wellens HJJ. Reciprocal tachycardias using accessory pathways with long conduction times. Am J Cardiol 1979;44: 1098-1109.

11. Critelli G, Gallagher JJ, Thiene G, Perticone F, Coltorti F, Rossi L. Electrophysiologic and histopathologic correlations in a case of permanent form of reciprocating tachycardia. Eur Heart J 1985; 6(2): 130-137.

12. Tchou P, Lehmann H, Jazayeri M, Akhtar M. Atriofascicular connection or a nodoventricular Mahaim fiber? Electrophysiologic elucidation of the pathway and associated reentrant circuit. Circulation 1988;77: 837-848.

13. Klein GJ, Guiraudon GM, Kerr CR, Sharma AD, Yee R, Szabo T, Yeung Laiwah JAY. "Nodoventricular" accessory pathway: Evidence for a distinct accessory atrioventricular pathway with atrioventricular node-like properties. J Am Coll Cardiol 1988;11: 1035-1040.

14. Wellens HJJ, Durrer D. The role of an accessory atrioventricular pathway in reciprocal tachycardia. Observations in patients with and without the Wolf-Parkinson-White syndrome. Circulation 1975;52: 58-64

15. Guiraudon GM, Klein GJ, Sharma AD, Miltsein S, MsLellan DG. Closed-heart technique for Wolff-Parkinson-White syndrome: Further experience and potential limitations. Ann Thorac Surg 1986;42:651-657.

16. Morady F, Scheinman MM, Gonzalez R, Hess D. His-ventricular dissociation in a patient with reciprocating tachycardia and a nodoventricular bypass tract. Circulation 1981;64: 839-852.

17. Shimizu A, Ohe T, Takaki H, Kamakura S, Matsuhisa M, Sato I, Shimomura K. Narrow QRS complex tachycardia with atrioventricular dissociation. Pace 1988;11: 384-393.

18. Guiraudon GM, Klein GJ, Sharma AD, Jones DL, McLellan DG. Surgical ablation of posterior septal accessory pathways in the Wolff-Parkinson-White syndrome by a close heart technique. J Thorac Cardiovasc Surg 1986;92: 406-413.

Chapter III

Clinical and electrophysiological characteristics of patients with antidromic circus movement tachycardia in the Wolff-Parkinson-White syndrome

Jacob Atié
Pedro Brugada
Joep L.R.M. Smeets
Marie P. Roukens
Fernando E.S. Cruz
Ayrton Peres
Josep Brugada
Hein J.J. Wellens

Clinical and electrophysiological characteristics of patients with antidromic circus movement tachycardia in the Wolff-Parkinson-White syndrome

SUMMARY

Antidromic circus movement tachycardia was documented in 36 out of 345 consecutive patients with the Wolff-Parkinson-White syndrome undergoing detailed electrophysiologic evaluation. Twenty six patients were male and 10 female, the mean age was 26 ± 12 years (12-45). Multiple accessory pathways were identified in 12 of these 36 patients (33%). Of patients withclinically documented antidromic tachycardia, 10 (67%) had multiple accessory pathways. Dizziness and syncope occurred in 61 and 50% of patients with antidromic circus movement tachycardia. Six patients had clinical documentation of atrial fibrillation, and 4 patients (11%) were resuscitated from ventricular fibrillation. In the 36 patients, 56 distinct antidromic tachycardias were recorded and several different pathways were observed. Orthodromic tachycardia was the most frequently associated arrhythmia (72%). Dual A-V nodal pathways were present in 12 patients (33%), however in only 2 of them A-V nodal tachycardia could be initiated. Interruption of the accessory pathway was successfully performed in all 20 patients undergoing surgery.

Accepted for presentation at the North American Society of Pacing and Electrophysiology in 1990
Submitted for publication

INTRODUCTION

Accessory atrioventricular connections in patients with Wolff-Parkinson-White syndrome may participate in a variety of paroxysmal tachycardias (1-4). The most commonly observed arrhythmia is orthodromic circus movement tachycardia in which the reentrant circuit utilizes the normal A-V conducting system in the anterograde direction and the accessory pathway in the retrograde direction. The resulting QRS complex during tachycardia is, therefore, normal or shows the typical intraventricular features of aberrant conduction (5,6). In 1975, Fontaine (7) used the term antidromic to define a tachycardia using the accessory pathway in the anterograde direction and the AV node in retrograde direction. The resulting tachycardia has a wide QRS complex with maximal preexcitation. A variant of true antidromic circus movement tachycardia was also described in which the retrograde limb of the circuit was a second accessory pathway (8,9). Furthermore, tachycardia due to reentry within the A-V node and anterograde conduction over the accessory pathway has been reported to occur in patients with Wolff-Parkinson-White syndrome. That may result in a paroxysmal regular tachycardia with preexcited QRS complexes that mimics antidromic tachycardia (10,11). The electrophysiologic mechanisms leading to tachycardias in the Wolff-Parkinson-White syndrome has been extensively studied (12,13). However, there are relatively few studies on antidromic circus movement tachycardia (14-15) and consequently little is known about the clinical characteristics and the electrophysiological substrate necessary for its occurrence.

This report reviews the clinical and electrophysiologic characteristics and results of treatment in patients with the Wolff-Parkinson-White syndrome presenting antidromic circus movement tachycardia.

PATIENTS AND METHODS

The 36 patients of this study were selected from 345 consecutive patients seen between 1979 and august 1989 in our institution for evaluation and treatment of various pre-excitation syndromes.

Definition of antidromic tachycardia

Antidromic circus movement tachycardia was defined as a tachycardia that used an accessory pathway in the anterograde direction and the His/AV node or a different accessory pathway in retrograde direction.

Criteria for diagnosis of antidromic tachycardia in patients with a single accessory pathway:

1. The QRS configuration during tachycardia was essentially identical with that obtained during atrial pacing with maximal preexcitation.
2. *Participation of the ventricles in the reentry circuit:*
   Demonstration of participation of the ventricles in the tachycardia mechanism was obtained by observing that: 1) Ventricular premature beats terminated tachycardia, without depolarizing either the His bundle or the atria (this criteria excludes atrial flutter, and atrial tachycardias with 1:1 conduction over the accessory pathway), 2) Atrial premature beat advanced the tachycardia with the same pattern of ventricular activation during tachycardia. This criterium excludes ventricular tachycardia, and 3) Atrial premature beats could advance the tachycardia, with the next atrial activation occurring after the same V-A interval and with the same sequence of retrograde atrial activation. This criterium excludes A-V nodal tachycardia with 1:1 conduction over a bystander accessory pathway.
3. *Participation of the atria in the reentry circuit:*
   Demonstrated by the following: 1) An atrial premature beat terminated tachycardia without conduction to the ventricles. This observation excludes ventricular tachycardia, 2) Ventricular premature beats conducted to the atrium with the same retrograde atrial activation sequence, advancing tachycardia. This phenomenon also excludes ventricular tachycardia, 3) Ventricular premature beats, conducting to the atrium, could advance tachycardia with the next ventricular activation having the same A-V interval as during the tachycardia. This criterium excludes A-V nodal tachycardia with 1:1 conduction over a bystander accessory pathway).
4. Atrial and ventricular pacing showed that the conduction properties of each limb of the reentrant circuit were capable of sustaining the tachycardia.
5. Atrial flutter, atrial tachycardia and dual A-V nodal tachycardia using the accessory pathway as a "bystander", were excluded by at least one of the above criterium.
6. Circus movement tachycardia using a nodoventricular fiber in the anterograde conduction were also excluded.

Criteria for diagnosis of antidromic tachycardia in the presence of multiple accessory pathways

The criteria discussed above, were also used for the diagnosis of antidromic tachycardia in patients with multiple accessory pathways. However, configuration of the QRS complex during tachycardia could be different from that obtained during atrial pacing, depending upon the accessory pathway(s) used for anterograde conduction. Also, a second accessory pathway could sometimes be used as the retrograde limb of the tachycardia circuit. In one case fusion between both accessory pathways occurred during anterograde conduction over both pathways.

Electrophysiological study

After informed consent all patients underwent a complete electrophysiologic study in the nonsedated state. At the time of study, 16 of the 36 patients were taking different antiarrhythmics drugs.

Catheters were passed through both femoral veins using the Seldinger technique and positioned in the heart under fluoroscopic guidance. Multiple electrode catheters were used to record and pace from the right atrium, coronary sinus and right ventricular apex. His bundle electrograms were obtained with a bipolar electrode catheter positioned over the septal leaflet of the tricuspid valve. The methods for stimulation and recording used in our laboratory and the definitions used have been previously described in detail (16). All patients underwent a complete electrophysiologic investigation.

Surgery

Twenty of the 36 patients underwent surgery. In these patients, intraoperative mapping was used to confirm the location(s) of the accessory pathway(s) determined before surgery.

RESULTS

Clinical characteristics

Of the 345 patients studied, 36 patients (11%) had antidromic circus movement tachycardia induced during the electrophysiologic study. Twenty four of them (67%) had a single accessory pathway and 12 patients (33%) had two or more accessory pathways (three patients had 3 different accessory pathways).

The clinical data of these patients are listed in table I. The age of the patients ranged from 12 to 45 years (mean 26 ± 12), 26 patients were male (72%) and 10 (28%) female. The mean duration of symptoms before electrophysiologic study was 8 years. The mean age at onset of symptoms was 16 ± 6 years (in 6 patients the first symptoms of arrhythmia occurred less than 6 months before electrophysiologic study). The mean number of attacks was 4.5 ± 3 a month, in the last 6 months before the electrophysiologic study. Clinical symptoms included palpitations (34 patients - 94%), dizziness (22 patients 61%) and syncope (18 patients - 50%). Fifteen patients (42%) had exercise-induced tachycardia.

Table I. Clinical data of the 36 patients studied

Pts	Sex	Age	Onset of arrhythmia	Incidence of attacks per month (last 6 m)	Symptoms	Exercise induced tachycardia	Clinical documented arrhythmia
1	F	40	20	1	PL/DZ/SN	YES	O
2	M	23	13	30	PL/DZ/SN	YES	A/AF
3	F	27	26	1	PL/SN	NO	O/AF/VF
4	M	21	12	6	PL/DZ/SN	YES	A/O
5	M	45	30	4	PL	NO	A
6	M	12	10	1	PL	NO	A/O/AVN
7	M	28	28	0	ASYMPT.	NO	NAD
8	F	22	13	1	PL/DZ/SN	YES	A/O/F
9	M	28	28	1	PL	NO	A
10	M	19	19	5	PL/DZ/SN	YES	A/O/VF
11	F	41	41	1	PL/DZ/SN	YES	O/AF
12	M	15	10	5	PL/DZ	YES	A
13	M	17	14	1	PL/DZ/SN	YES	NAD
14	M	17	14	1	PL/DZ/SN	YES	A/O/AVN
15	F	12	8	2	PL/DZ/SN	YES	A/O
16	M	12	12	1	PL	NO	A
17	M	48	19	1	PL	NO	NAD
18	M	28	24	2	PL/DZ/SN	YES	O
19	M	42	14	1	PL/DZ/SN	YES	O
20	M	15	13	30	PL/DZ/SN	YES	A
21	F	45	12	3	PL/DZ/SN	YES	A
22	F	17	7	4	PL	NO	O
23	M	32	22	1	PL/DZ	YES	A
24	M	18	18	1	ASYMPT.	NO	NAD
25	M	23	15	1	PL/DZ/SN	YES	A/O/VF
26	M	38	30	1	PL	NO	NAD
27	M	28	20	5	PL/DZ/SN	YES	O
28	M	16	14	1	PL/DZ/SN	YES	A/O
29	F	28	20	1	PL	NO	A
30	F	30	20	5	PL/DZ	YES	AF
31	M	32	28	4	PL	NO	O
32	M	42	30	1	PL/DZ	YES	O
33	M	31	20	4	PL/DZ/SN	YES	A/VF
34	M	20	10	10	PL/DZ	YES	O/AF
35	F	29	20	0	PL	NO	NAD
36	M	28	20	4	PL	NO	NAD

Abbreviations: A=antidromic circus movement tachycardia; AF=atrial fibrillation; ASYMPT.= asymptomatic; AVN=AV nodal tachycardia; DZ=dizziness; NAD=no arrhythmia documented; O=orthodromic circus movement tachycardia; PL=palpitation; SD=standard deviation; SN= syncope; VF=ventricular fibrillation; m= months.; Pts = patient number

Eighteen of the 36 patients (50%) had clinically documented antidromic circus movement tachycardia, 18 patients (50%) had documented orthodromic circus movement tachycardia, 7 patients (19%) had both tachycardias clinically. A history of atrial fibrillation was present in 6 patients (16%). Four patients (11%) had a previous history of ventricular fibrillation.

Electrophysiological characteristics

The location of the accessory pathways is presented in table II. The most common location was left lateral (15 accessory pathways 29%) and left posteroseptal (15 accessory pathways 29%).

The mean atrial refractory period was 212 ± 28 ms, the mean ventricular effective refractory period was 198 ± 23 ms. The anterograde effective refractory period of the AV node was 227 ± 25 ms and the retrograde effective refractory period of the AV conduction system 222 ± 21 ms. The mean shortest measured anterograde refractory period of the accessory pathway was 238 ± 35 ms (range from ≤ 190 ms to 410 ms). In patients with more than one accessory pathway only the value of the accessory pathway with the shortest refractory period was considered. The atrial, ventricular, A-V node and accessory pathway refractory periods are shown in Table III.

Antidromic tachycardia

Antidromic circus movement tachycardia was the only inducible arrhythmia in 10 patients (28%). In the remaining 26 patients (72%) both antidromic and orthodromic tachycardia could be initiated.

Nine patients had 2 different types of antidromic tachycardias, 4 patients presented 3 different types, and 1 patient 4 different types of tachycardia. The remaining 22 patients presented only one type of antidromic circus movement tachycardia. The different types of antidromic tachycardias were based upon: 1) Differences in cycle length because of differences in the retrograde pathway, as shown by different retrograde atrial activation patterns. 2) Different patterns of preexcitation, because of anterograde conduction over different accessory pathways (fig. 1). 3) Differences in cycle length because of an increase in the V-A interval as a result of V-H prolongation due to a change in bundle branch used for retrograde conduction during tachycardia (fig. 2) (14). 4) Differences in cycle length because of an increase in the VA interval as a result of H-A prolongation, caused by the presence of retrograde dual AV nodal pathways (fig. 3). 5) Differences in cycle length because of an increase in the AV interval due to anterograde longitudinal dissociation in the accessory pathway or alternating conduction over two very closely located accessory pathways (fig. 4) (17).

Table II. Localization of the accessory pathway and cycle length during antidromic tachycardia.

Patient N°	Localization of AP	Cycle length (ms)	VA interval (ms)	AV interval (ms)	QRS duration (ms)
1	RL	370	170	200	130
		330	130	200	130
2	RL	360	180	180	140
		400	180	220	140
3	LPS	360	230	130	140
4	AS, LL, RPS	260	70	190	130
		300	230	70	130
		290	200	90	140
5	LPS	340	210	130	140
6	RPS	250	150	100	130
7	RPS	380	280	100	150
8	LL, LPS	260	200	60	160
		300	220	80	140
9	LL	300	180	120	160
		240	130	110	160
10	LL, LPS	290	200	90	140
		270	150	120	140
		320	170	150	120
11	LL	330	210	120	130
12	RPS	320	200	120	140
13	RL	280	180	100	160
14	LPS	250	120	130	130
15	RL, LL	380	220	160	160
		300	170	130	160
16	RL, LPS	270	190	80	130
		280	160	120	130
		270	140	130	140
17	LL	280	180	100	160
18	LL	280	150	130	140
19	LL	380	220	160	130
20	LPS, NV	440	290	150	140
		430	210	130	140
		370	200	170	140
21	RL	320	170	150	130
22	LL	360	230	130	140
23	LL	340	210	130	140
24	RL, NV	320	180	140	140
25	RPS, LPS	340	170	170	150
		320	220	110	130
26	LL	250	150	100	130

Continuation table II

Patient N°	Localization of AP	Cycle length (ms)	VA interval (ms)	AV interval (ms)	QRS duration (ms)
27	LL	330	210	120	130
28	RL, PS	310	170	140	140
29	LPS	270	150	120	140
		300	230	70	130
30	RL, LL, LPS	380	240	140	140
		320	200	120	130
		280	160	120	130
		240	140	100	140
31	LPS	250	120	130	130
32	LPS	250	120	130	130
		300	170	130	140
33	LL	400	240	160	160
34	LPS, RPS	310	180	130	140
35	PS, LPS, RL	280	140	140	140
		250	160	90	150
36	LPS	280	180	100	140

Abbreviations: AP=accessory pathway; AS=anteroseptal; LL=left lateral; LPS=left posteroseptal; NV=nodoventricular; PS=posteroseptal; RL=right lateral; RPS=right posteroseptal

In the 36 patients, 56 distinct antidromic tachycardias were recorded with different mechanisms. In figure 5 the mechanisms are shown. Representative recordings of antidromic circus movement tachycardia are illustrated in figs 1-4, 6-9.

The cycle length of antidromic tachycardia ranged between 240 and 440 ms (mean= 317 ± 38). The mean VA interval was 188 ± 32 ms (range from 120-290). The mean AV interval was 129 ± 29 ms (range 60-200).

During antidromic tachycardia a sudden increase in cycle length was observed in 10 patients (28%). In 6 patients (17%) it was caused by a change in retrograde conduction over a bundle branch (14) (sudden increase of the V-H interval) (fig. 2). In 4 patients (11%) it was caused by a shift from a fast to a slow retrograde A-V nodal pathway (prolongation of H-A interval) (fig. 3).

The retrograde limb of antidromic tachycardia was the AV node in 28 patients (78%) and a second accessory pathway in the remaining 8 patients.

During antidromic tachycardia the mean duration of the QRS complex was 138 ms ± 8 ms (130-160) in patients who were on antiarrhythmic drugs, and 142 ms ± 8 ms (130-160) in patients off drugs. There were no differences in the duration of the QRS complex in relation to the localization of the accessory pathway. The narrowest (130 ms) and the widest (160 ms) QRS complexes were found in two different patients both having a right lateral

Table III. Refractory periods of atrium, ventricles, av node and accessory pathway

Pts	AERP (PCL) (ms)	VERP (PCL) (ms)	AV-AERP (PCL) (ms)	AV-RERP (PCL) (ms)	AP-AERP (PCL) (ms)	AP-RERP (PCL) (ms)
1.	250 (428)	220 (500)	≤ 250 (428)	310 (248)	≤ 250 (428)	380 (428)
2.	210 (428)	170 (428)	240 (428)	180 (428)	240 (428)	250 (428)
3.	160 (500)	190 (500)	190 (500)	NA	≤ 160 (500)	280 (500)
4.	220 (428)	180 (428)	≤ 220 (428)	≤ 180 (428)	280 (500)	≤ 180 (428)
5.	270 (500)	210 (428)	NA	≤ 210 (428)	≤ 270 (500)	300 (428)
6.	NA	180 (428)	NA	210 (428)	120 (428)	≤ 180 (428)
7.	220 (428)	220 (500)	280 (428)	250 (600)	280 (428)	400 (600)
8.	190 (600)	210 (428)	≤ 190 (600)	250 (428)	260 (500)	≤ 210 (428)
9.	260 (600)	190 (428)	280 (500)	≤ 190 (428)	280 (600)	270 (428)
10.	190 (428)	220 (428)	200 (428)	≤ 220 (428)	≤ 190 (500)	240 (428)
11.	190 (428)	200 (500)	≤ 190 (428)	≤ 200 (500)	≤ 190 (428)	≤ 200 (500)
12.	220 (428)	220 (428)	280 (428)	≤ 220 (428)	270 (428)	NA
13.	230 (428)	190 (428)	≤ 230 (600)	220 (428)	280 (500)	NA
14.	200 (428)	210 (500)	≤ 200 (428)	NA	240 (428)	NA
15.	210 (428)	200 (428)	350 (600)	NA	330 (500)	≤ 200 (428)
16.	200 (428)	200 (428)	250 (500)	230 (428)	230 (500)	NA
17.	220 (500)	190 (428)	≤ 220 (500)	≤ 210 (500)	250 (500)	240 (428)
18.	210 (428)	220 (428)	260 (428)	240 (428)	240 (428)	240 (428)
19.	270 (600)	210 (428)	NA	320 (428)	400 (500)	NA
20.	250 (428)	250 (600)	NA	320 (500)	310 (500)	460 (500)
21.	240 (500)	260 (500)	260 (500)	280 (500)	300 (500)	270 (500)
22.	170 (500)	190 (428)	200 (600)	210 (428)	210 (500)	250 (500)
23.	220 (428)	210 (428)	250 (600)	NA	230 (510)	280 (500)
24.	230 (428)	280 (500)	≤ 230 (428)	≤ 280 (500)	≤ 230 (428)	NA
25.	180 (428)	180 (500)	190 (428)	≤ 180 (428)	≤ 180 (428)	≤ 180 (428)
26.	190 (600)	180 (428)	220 (500)	≤ 180 (428)	210 (500)	≤ 180 (428)
27.	190 (428)	200 (500)	≤ 190 (428)	CNM	≤ 190 (428)	≤ 200 (500)
28.	220 (428)	210 (428)	230 (500)	≤ 210 (428)	240 (428)	≤ 210 (428)
29.	220 (428)	220 (428)	280 (428)	≤ 220 (428)	270 (428)	290 (500)
30.	200 (428)	200 (500)	≤ 200 (428)	≤ 200 (500)	≤ 200 (428)	NA
31.	230 (428)	190 (428)	250 (500)	210 (428)	≤ 230 (600)	220 (428)
32.	200 (428)	210 (600)	≤ 200 (428)	240 (600)	240 (600)	≤ 210 (600)
33.	200 (600)	220 (600)	NA	≤ 220 (600)	≤ 200 (600)	≤ 220 (600)
34.	200 (600)	200 (500)	210 (428)	NA	260 (428)	NA
35.	190 (428)	160 (428)	270 (428)	≤ 160 (428)	270 (428)	≤ 160 (428)
36.	220 (500)	200 (500)	230 (500)	≤ 200 (500)	NA	

Abbreviations: AERP= atrial effective refractory period; VERP= ventricular effective refractory period; AV-AERP= atrio-ventricular nodal anterograde effective refractory period; AV-RERP= His AV-nodal retrograde effective refractory period; AP-AERP= accessory pathway anterograde effective refractory period; AP-RERP= accessory pathway retrograde effective refractory period; PCL= pacing cycle length.

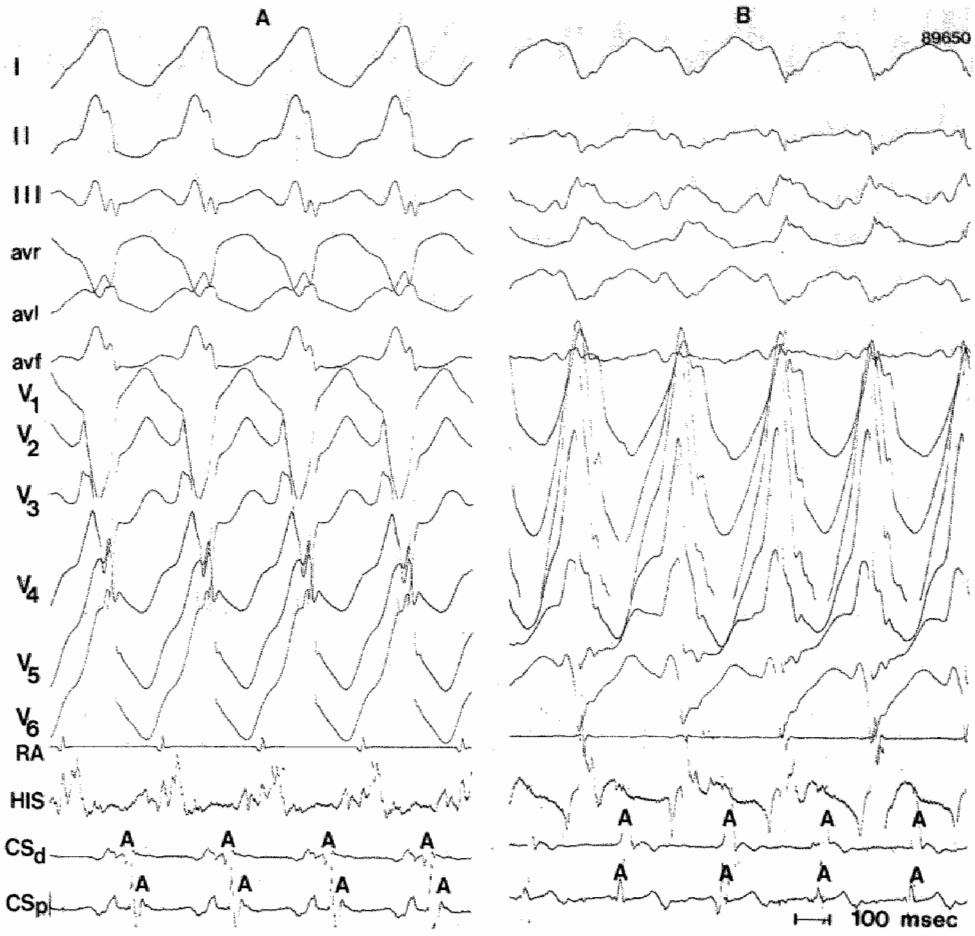

Figure 1. In panels A and B a 12 lead electrocardiogram, bipolar electrograms from the high right atrium (RA),bundle of His, coronary sinus distal (CSd) and proximal (CSp) during antidromic tachycardia are shown from the same patient. In panel A an antidromic circus movement tachycardia using anterogradely a right-sided accessory pathway and retrogradely a left-sided accessory pathway is present. Panel B shows antidromic circus movement tachycardia using anterogradely a left-sided accessory pathway and retrogradely the normal A-V conduction system.

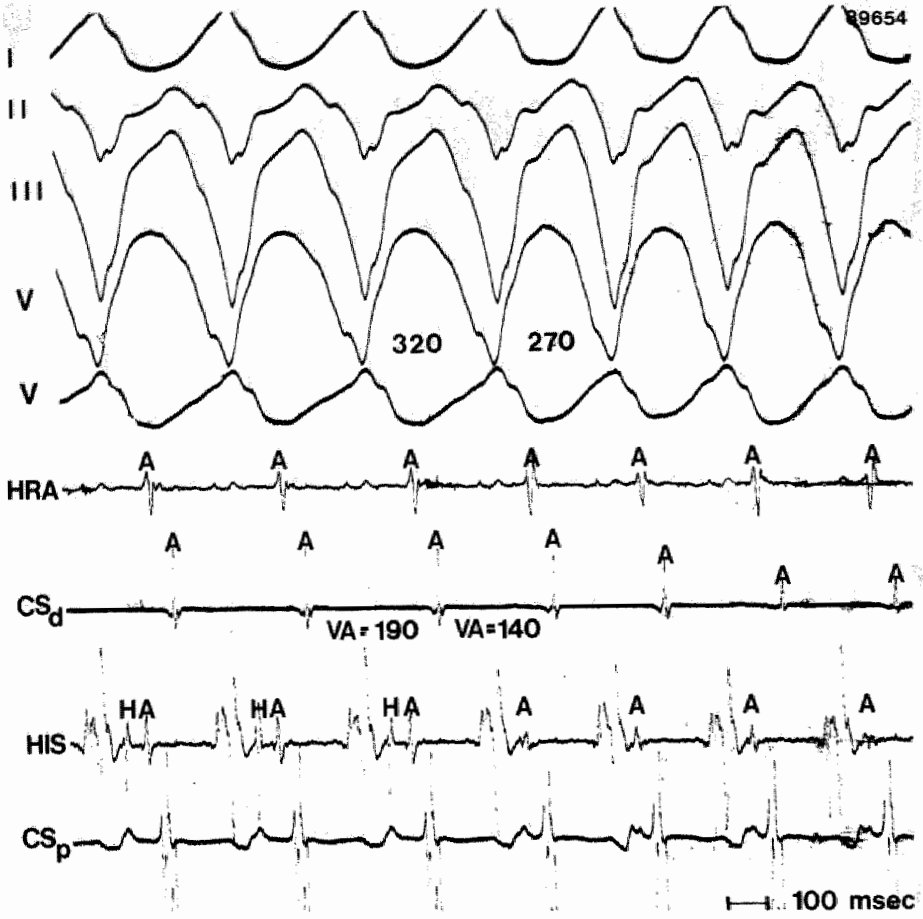

Figure 2. An antidromic tachycardia using a right-sided accessory pathway in the anterograde direction and the AV node in the retrograde direction is shown. During the first three beats the cycle length is 320 ms with a V-A interval of 190 ms. The H-A interval is 50 ms. The cycle length decreases suddenly to 270 ms with a shortening of the V-A interval to 140 ms, because of a sudden shortening in the V-H interval. That is caused by disappearence of retrograde block in the bundle branch. Five surface electrocardiographic leads and four intracardiac leads are shown. High right atrium (RA), distal coronary sinus (CSd), bundle of His (HIS) and proximal coronary sinus (CSp).

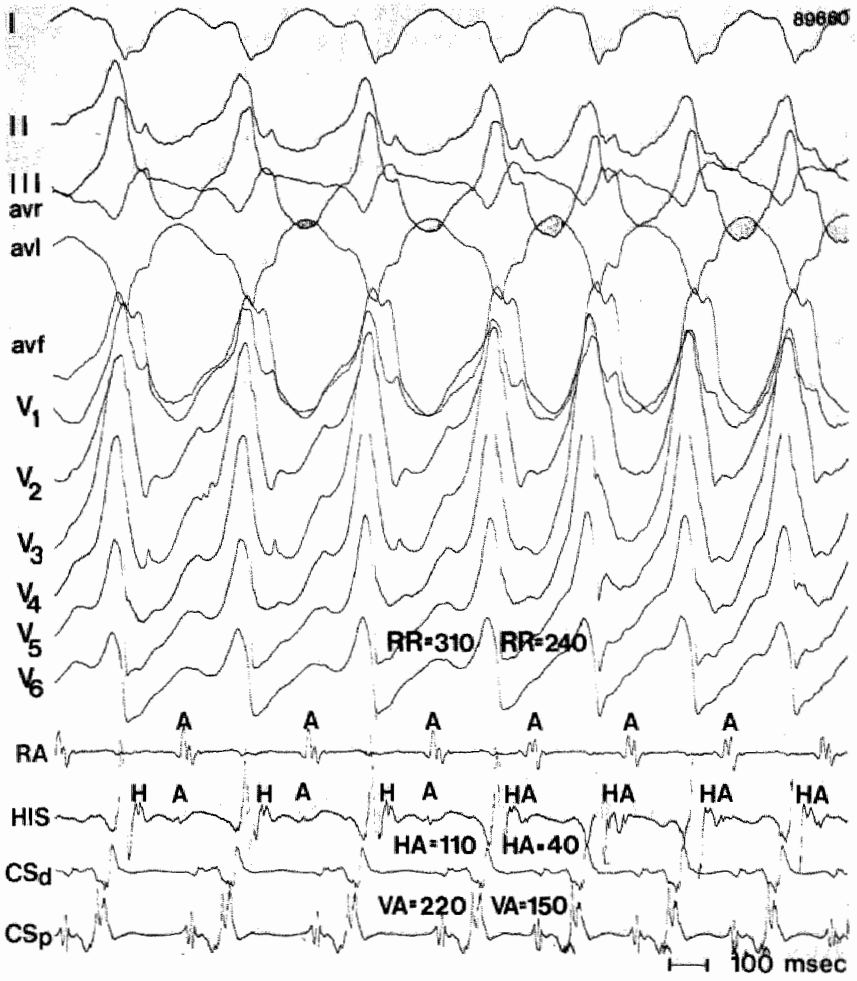

Figure 3. Twelve lead electrocardiogram and intracardiac electrograms from the high right atrium (RA), bundle of His (HIS), distal coronary sinus (CSd) and proximal coronary sinus (CSp) are shown. Antidromic circus movement tachycardia initially having a cycle length of 310 ms showing shortening to 240 ms because of shortening in the H-A interval. Duringtachycardia with the longer cycle length, retrograde conduction occured over a slowly conducting retrograde atrio-ventricular nodal pathway. Tachycardia accelerated when retrograde conduction shifted to a faster conducting retrograde atrio-ventricular nodal pathway.

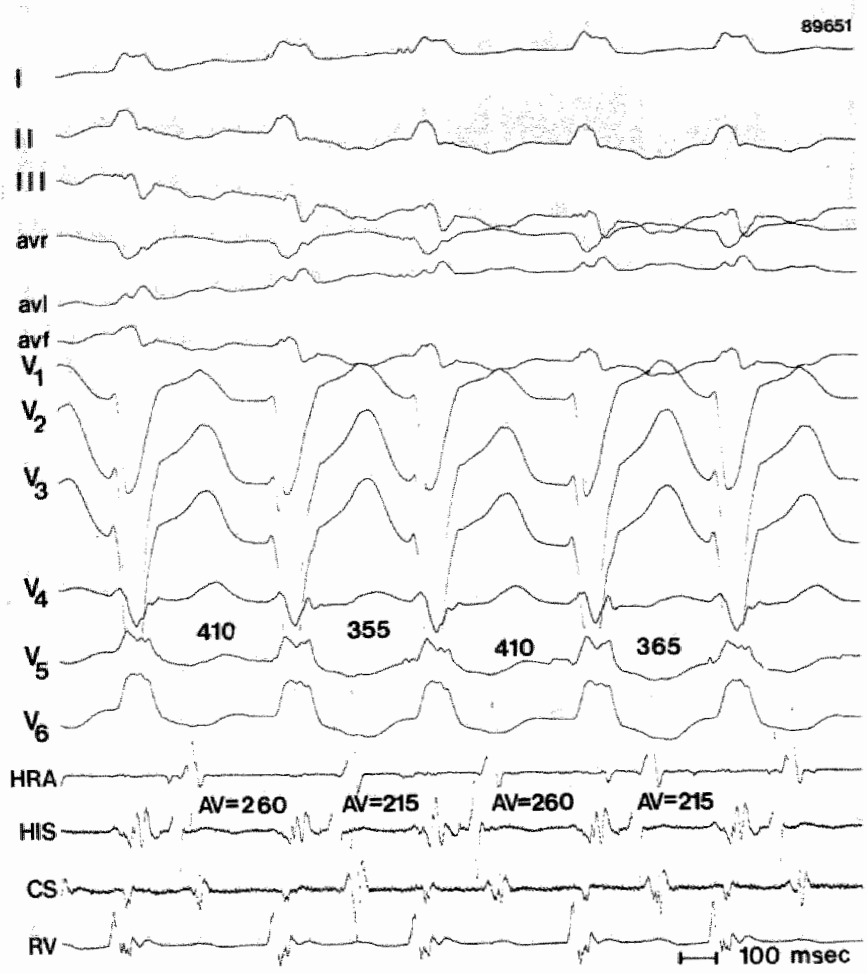

Figure 4. Twelve surface electrocardiographic leads and four intracardiac electrograms are shown. Antidromic circus movement tachycardia using anterogradely a right sided accessory pathway with long conduction time and retrogradely the AV node is shown. There is alternation in cycle length of the tachycardia of 45 ms because of changes in the A-V interval, without significant changes in the morphology of the QRS complex and V-A interval. This phenomenon can be explained by either functional longitudinal dissociation in anterograde conduction over the accessory pathway or alternating anterograde conduction over two closely adjacent located accessory pathways.

accessory pathway. One has to realize, however, that exact measurement of the duration of the QRS complex during antidromic tachycardia is difficult, particularly in fast tachycardias.

Initiation of antidromic tachycardia

Atrial premature beat(s) initiated antidromic tachycardia in 30 patients (83%), and ventricular premature beat(s) initiated the arrhythmia in 16 patients (45%). In 10 patients (28%) both atrial and ventricular premature beat(s) initiated antidromic tachycardia. There were no statistical differences in induction of antidromic tachycardia from the atrial level between patients with one or multiple accessory pathways. Ventricular premature beat (s), however, initiated the antidromic tachycardia in 67% of patients with multiple accessory pathways and in 33% of patients with a single accessory pathway ($p< 0.01$) (table IV). In one patient orthodromic circus movement tachycardia changed spontaneously into antidromic tachycardia (fig. 8). In three patients this phenomenon was observed after atrial or ventricular premature beats (fig. 7). In 3 patients with multiple accessory pathways, one type of antidromic tachycardia changed spontaneously to a second type of antidromic tachycardia (fig. 9). That was also observed after induced atrial or ventricular premature beats, in two patients.

Table IV. Modes of initiation of antidromic tachycardia

Mode of initiation	One accessory pathway (24 pts)	Multiple accessory pathways (12 pts)
1 APB	20 pts (83%)	8 pts (67%)
2 APB	1 pt (4%)	1 pt (8%)
1 VPB	6 pts (25%)	6 pts (50%)
2 VPB	2 pts (8%)	2 pts (17%)
RAP	9 pts (37%)	2 pts (17%)

Abbreviations: APB= atrial premature beat; RAP= rapid atrial pacing; pts= patients; VPB= ventricular premature beat.

Termination of antidromic tachycardia

Termination of antidromic tachycardia occurred spontaneously in 8 patients (22%). Atrial premature beats terminated tachycardia in 23 patients and ventricular premature beats in 19 patients. In one patient antidromic tachycardia changed spontaneously into orthodromic tachycardia. Three patients showed this phenomenon following atrial or ventricular premature beats (fig. 8). In 17 patients (47%) termination of tachycardia occurred because of block in the retrograde pathway. In 14 in the AV conduction system and in 3 in a second accessory pathway. In 19 patients (53%) termination of tachycardia occurred because of block in the accessory pathway conducting anterogradely.

Figure 5. Diagrams illustrating the different types of antidromic circus movement tachycardias. A= atrium; AVN= A-V node; AP= accessory atrioventricular pathway; FAVN= fast A-V nodal pathway; SAVN= slow A-V nodal pathway; 1. Antidromic circus movement tachycardia with anterograde conduction over an accessory atrioventricular pathway and retrograde conduction over a fast A-V nodal pathway. 2. Antidromic circus movement tachycardia with anterograde conduction over an accessory atrioventricular pathway and retrograde conduction over a slow A-V nodal pathway; 3. Antidromic circus movement tachycardia with anterograde conduction over an atrioventricular accessory pathway with long conduction times and retrograde conduction over the A-V node; 4. Antidromic circus movement tachycardia with anterograde conduction via an accessory atrioventricular pathway and retrogradely over the AV node, with ipsilateral retrograde bundle branch block; 5. Antidromic circus movement tachycardia with anterograde conduction over an accessory atrioventricular accessory pathway and retrograde conduction over a second accessory pathway; 6. Antidromic circus movement tachycardia with anterograde conduction over an accessory atrioventricular pathway with long conduction times and retrograde conduction via a second accessory pathway; 7. Antidromic circus movement tachycardia with anterograde conduction over two accessory atrioventricular pathways with fusion at the ventricular level and retrograde conduction over the A-V node; 8. Antidromic circus movement tachycardia with anterograde conduction over both an accessory atrioventricular pathway and the AV node His-Purkinje system and retrograde conduction by way of a second accessory pathway; 9. Antidromic circus movement tachycardia with anterograde conduction over an accessory atrioventricular pathway and retrograde conduction over both the AV node and a second accessory pathway; 10. Preexcited reciprocating tachycardia with anterograde conduction over a nodoventricular accessory pathway and retrograde over the AV node; 11. Preexcited reciprocating tachycardia with anterograde conduction over a nodoventricular accessory pathway and retrograde conduction via an accessory atrioventricular pathway; Types 10 and 11 are antidromic circus movement tachycardias using nodo-ventricular fibers and are not included in the patients described in this article.

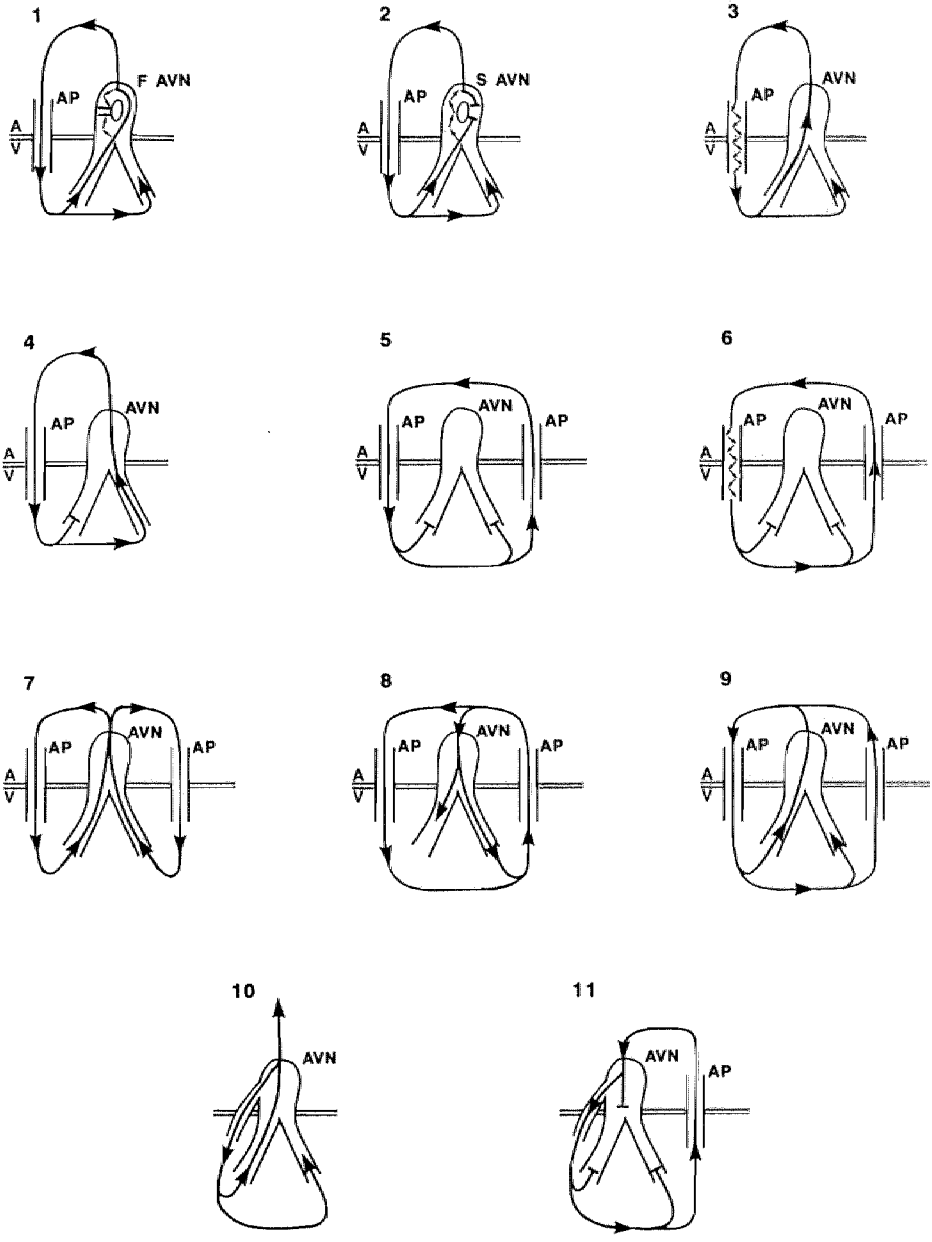
1
AP
F AVN
A
V
2
AP
S AVN
A
V
3
AP
AVN
A
V
4
AP
AVN
A
V
5
AP
AVN
AP
A
V
6
AP
AVN
AP
A
V
7
AP
AVN
AP
A
V
8
AP
AVN
AP
A
V
9
AP
AVN
AP
A
V
10
AVN
11
AVN
AP

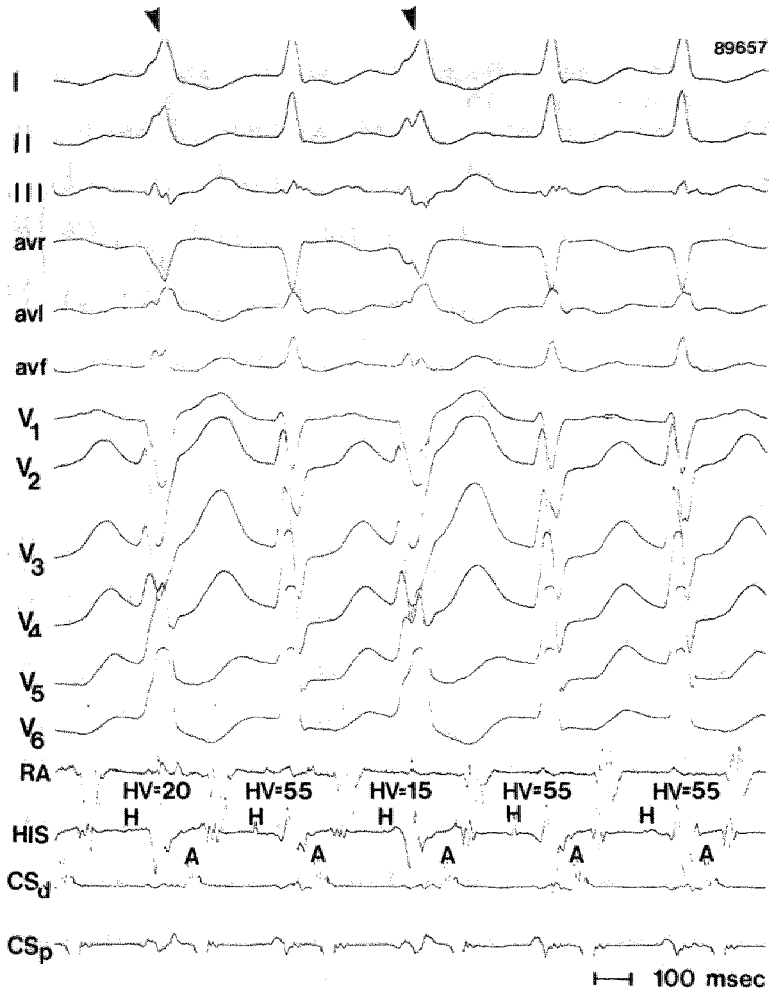

Figure 6. Twelve lead electrocardiogram and 4 intracardiac leads are shown. Orthodromic circus movement tachycardia conducting retrogradely over a left-sided accessory pathway is illustrated. The first and third complexes (arrows) are fusion beats because of anterograde conduction over a second accessory pathway. Note the shortening in the H-V interval preceding these fusion beats.

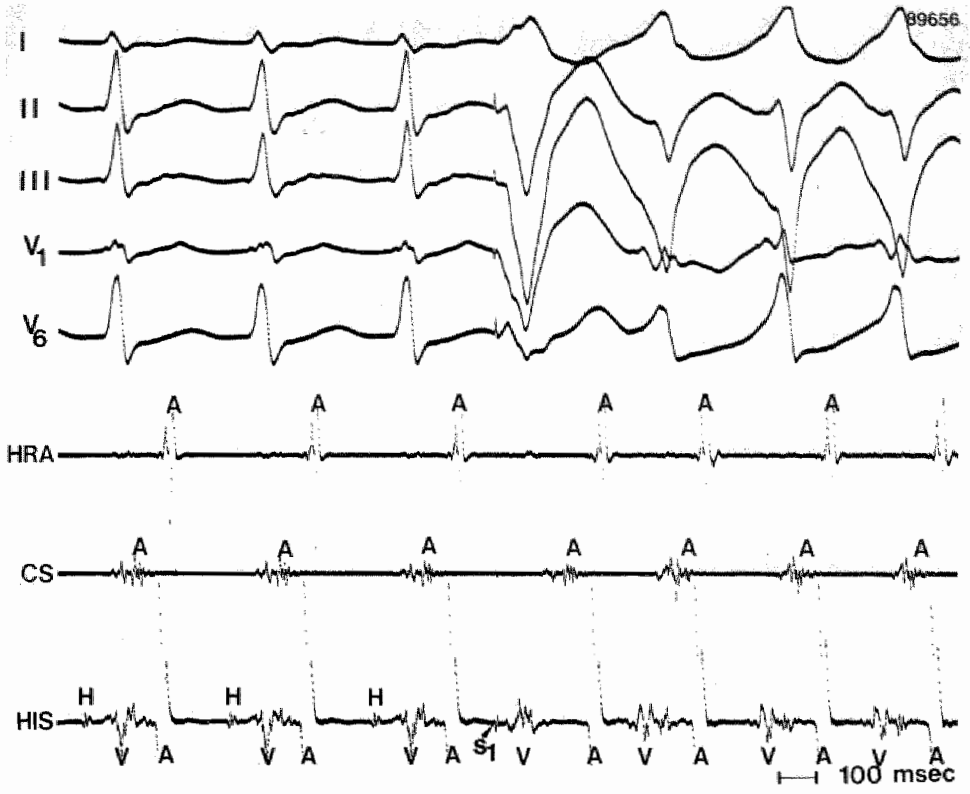

Figure 7. Five surface electrocardiographic leads and three intracardiac leads from a patient with two accessory atrioventricular pathways, one left lateral and the other left posteroseptal. One ventricular premature beat changes orthodromic circus movement tachycardia conducting retrogradely over the left lateral accessory pathway into antidromic circus movement tachycardia with anterograde conduction over the left posteroseptal accessory pathway.

Associated arrhythmias

In 26 patients (72%) orthodromic tachycardia was also induced during the study, 18 of them also having clinical documentation of orthodromic tachycardia. The mean cycle length (334 ± 42 ms) was longer than the cycle length of antidromic tachycardia (317 ± 38 ms), however, without reaching statistical significance.

No differences were found between patients with one or multiple accessory pathways concerning the cycle length of orthodromic and antidromic tachycardia in the same patient.

Dual AV nodal pathways were diagnosed in 12 patients (33%). In 2 patients (5%) A-V nodal tachycardia of the slow-fast type could be initiated.

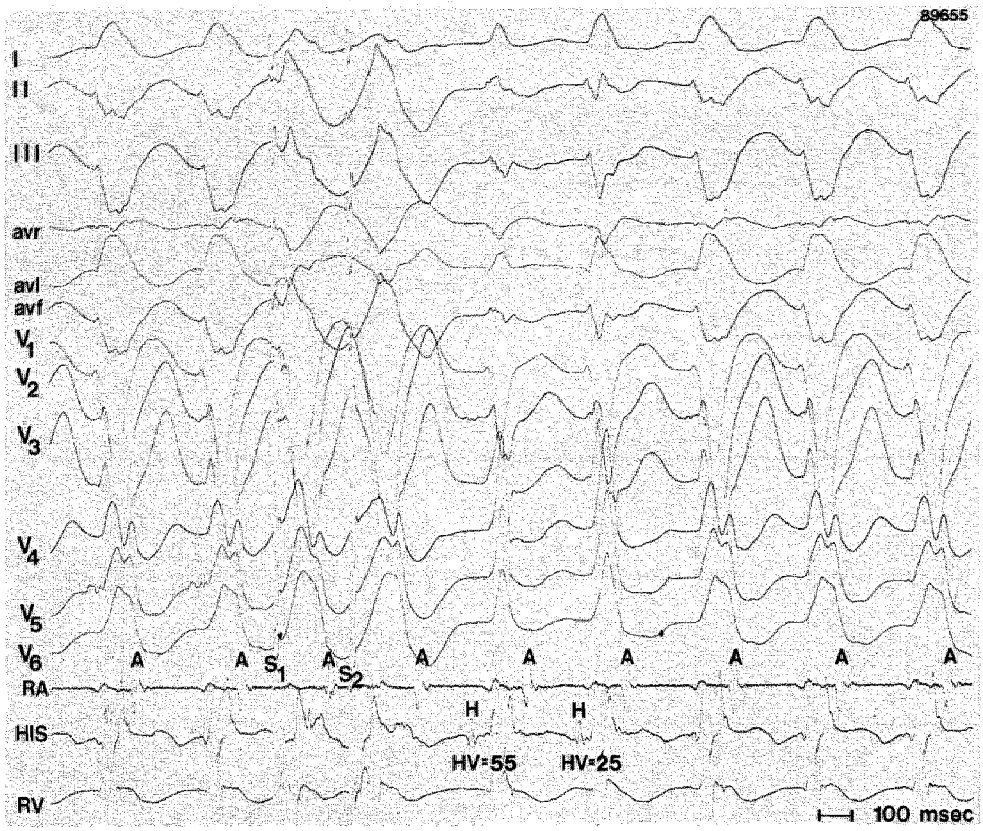

Figure 8. Twelve lead electrocardiogram and three intracardiac leads from a patient with multiple accessory pathways. Two ventricular premature beats change an antidromic circus movement tachycardia, conducting anterogradely over a right sided accessory pathway with long conduction times into orthodromic circus movement tachycardia. The second beat of the orthodromic circus movement tachycardia is a fusion beat resulting from conduction over the AV node and a second accessory pathway. Orthodromic tachycardia shifts spontaneously to antidromic circus movement tachycardia.

Atrial fibrillation was induced in 17 patients (47%), and the shortest RR interval during atrial fibrillation ranged from 160 ms to 400 ms (mean 225 ± 35 ms). Initiation of atrial fibrillation was possible by one or two atrial premature beats in 4 patients (27%) and by pacing the atria at high rates (± 200 beats/min) in 13 patients (73%). In one patient one ventricular premature beat during sinus rhythm induced atrial fibrillation. Spontaneous termination of atrial fibrillation was observed in 8/17 patients (47%), the remaining 9 patients (53%) had to be cardioverted.

Four patients developed atrial flutter and one patient atrial tachycardia during the electrophysiological study.

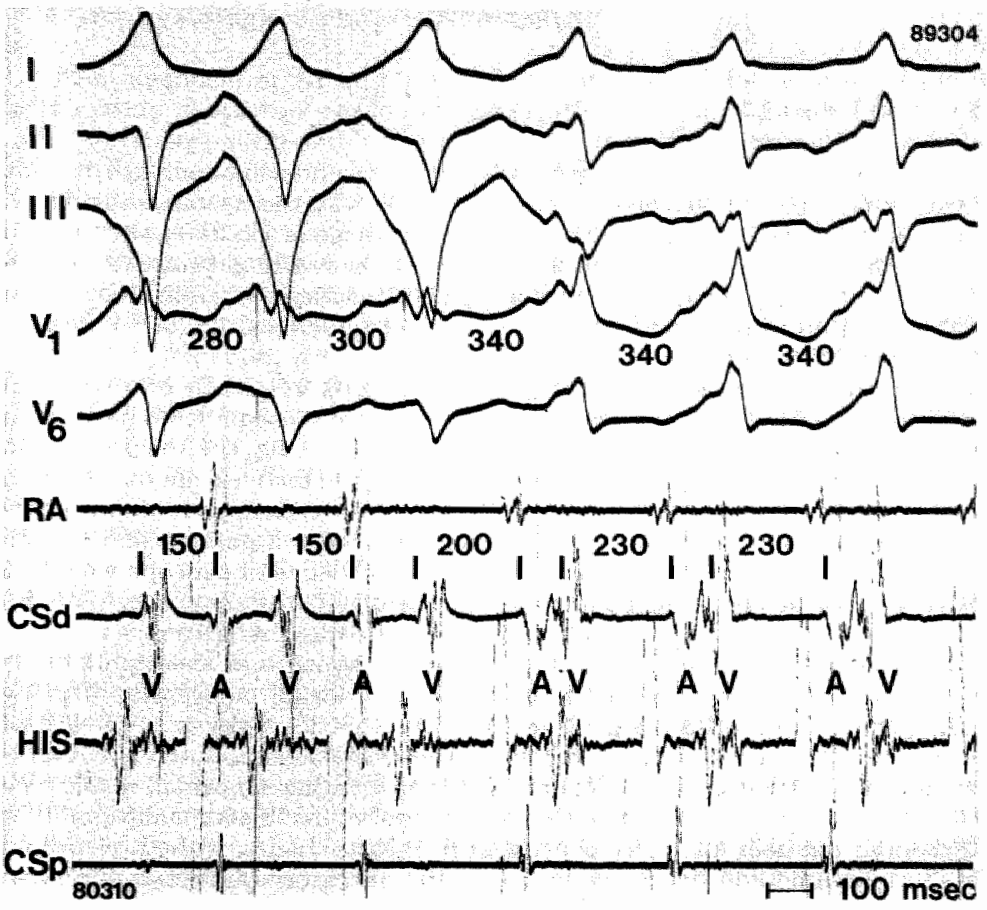

Figure 9. Five surface electrocardiographic leads and four intracardiac leads showing a spontaneous change from one antidromic circus movement tachycardia into another antidromic circus movement tachycardia. The first three beats show anterograde conduction over a left posterior accessory pathway, and the last 3 beats over a left lateral accessory pathway.

Surgery

Twenty patients were submitted to surgical ablation of the accessory pathway. Eleven of them had a single accessory pathway, 7 two accessory pathways and 2 three accessory pathways. Three patients had to be re-operated within the first week because of a recurrence of a delta wave or tachycardia. Two patients had a reoperation 6 and 8 months after the first surgery, because of a recurrence of tachycardia. After a mean follow up of 14 ± 6 months, one patient had a recurrence of a delta wave but did not suffer from spontaneous tachycardias.

DISCUSSION

Clinical findings

The age (26 ± 12 years) of our patients with antidromic tachycardia was lower but not statistically different from that of patients only having an orthodromic tachycardia. In our series the mean age of the 319 patients with only orthodromic tachycardia in the Wolff-Parkinson-White syndrome was 35 ± 14 years. The prevalence of male patients (72%) with antidromic tachycardia is higher than in patients with only orthodromic tachycardia (60%). Similar findings have been previously published (18).

The onset of complaints in the antidromic group frequently occurred at a very young age (table I). Also with medical treatment these patients had a high number of tachycardia recurrences per month (4.5 ± 3). The most common symptom was palpitations. Patients with antidromic tachycardia had a much higher incidence of dizziness (61%) and syncope (50%) than patients with only orthodromic tachycardia (19). In the 18 patients who clinically suffered from antidromic circus movement tachycardia the incidence of syncope was 67% (12 patients), a much higher prevalence, compared with our own patients with only orthodromic tachycardia (7%) and the literature (20).

One may suggest that one of the reasons for syncope in these patients is the abnormal pattern of ventricular contraction during tachycardia. During antidromic tachycardia the contraction of the ventricles starts at the site of insertion of the accessory pathway in the ventricle and consequently contraction of the ventricles occurs like in ventricular tachycardia, which may cause significant hemodynamic changes in some patients. Theoretically, another reason for the high incidence of syncope in these patients, is the presence of a short anterograde refractory period of the accessory pathway which can result in high ventricular rates during atrial fibrillation. However, some patients that developed syncope, had a relatively long anterograde refractory period of the accessory pathway, and most of them did not have clinical documentation of atrial fibrillation or induction of this arrhythmia during electrophysiologic study.

There was a high incidence of ventricular fibrillation in our group of patients (11%) compared to the occurrence of this arrhythmia in the general population of Wolff-Parkinson-White syndrome (21,22). Spontaneous occurrence of atrial fibrillation during antidromic tachycardia with the development of excessively rapid ventricular rates has been demonstrated (23). Although this is the most frequent mechanism of ventricular fibrillation in the Wolff-Parkinson-White syndrome, some patients with Wolff-Parkinson-White syndrome can have ventricular fibrillation secondary to other causes (coronary artery disease or long QT due to medication) (22). In our study, all four patients who suffered from ventricular fibrillation had a very short anterograde refractory period of their accessory pathway, 2 of them having multiple accessory pathways. None had other cardiac abnormalities.

Electrophysiological characteristics

The diagnosis of an antidromic circus movement tachycardia requires information about the cardiac activation sequence during tachycardia and proof of participation of the accessory pathway in the reentrant circuit to be able to distinguish that type of tachycardia from other arrhythmias.

The incidence of antidromic tachycardia in patients with Wolff-Parkinson-White syndrome, varies from 7% to 15% in different studies (18,25). In our series, the incidence was 11%. The presence of multiple accessory pathways in patients with antidromic tachycardia was 33% (12/36 patients). However when we consider patients who had clinically documented antidromic tachycardia (18 patients), the incidence of multiple accessory pathways in this group rose to 61% (11 patients). Thus, the observation of a spontaneously occurring antidromic tachycardia strongly suggests the presence of multiple accessory pathways.

Antidromic tachycardia

During electrophysiological study antidromic circus movement tachycardia was generally well tolerated hemodynamically, no patient required cardioversion because of associated hypotension. The high incidence of a previous history of syncope in these patients, in spite of a low incidence of atrial fibrillation, suggests that the antidromic tachycardia might be poorly tolerated in circumstances other than in the supine position in the laboratory. We also wonder about the possibility of deterioration of an antidromic tachycardia into ventricular fibrillation. While it is generally believed that ventricular fibrillation usually occurs secondary to atrial fibrillation with a high ventricular rate because of a short anterograde refractory period of the accessory pathway, we cannot exclude that antidromic tachycardia which hemodynamically behaves like ventricular tachycardia, may deteriorate into ventricular fibrillation.

We observed 9 different pathways during antidromic tachycardia in the 56 different antidromic tachycardias induced.

A spontaneous change from orthodromic to antidromic tachycardia or one induced by atrial or ventricular premature beat occurred in 4 patients. One should realize that this type of change can only occur in the presence of three different atrioventricular pathways. All our 4 patients showing this phenomenon had multiple atrioventricular accessory pathways.

A-V nodal tachycardia with "bystander" participation of the accessory pathway can occur in patients with the Wolff-Parkinson-White syndrome (10,11) and the differential diagnosis between antidromic tachycardia can be difficult. In our study no patient with antidromic tachycardia fulfilled the criteria for A-V nodal tachycardia using the accessory pathway as a "bystander". Also none of the 20 patients in whom the accessory pathway(s) was interrupted surgically developed A-V nodal tachycardia during follow-up.

Another consideration, is that antidromic tachycardia was induced by ventricular premature beat(s) in 16 patients, which is an uncommon mechanism of initiation of an A-V nodal tachycardia.

In 2 patients A-V nodal tachycardia with a narrow QRS complex could be induced during programmed electrical stimulation. During the antidromic tachycardia in these 2 patients, we were able to prove participation of both atria and ventricles in the tachycardia circuit, confirming the antidromic nature of the circus movement.

Three patients presented electrophysiologic features initially suggesting a "Mahaim" type of accessory pathway. However, all three had an accessory atrioventricular pathway with long conduction times. This was demonstrated at the time of surgery or during the electrophysiologic study, by advancing ventricular activation during tachycardia by an atrial premature beat given at the time of onset of retrograde atrial activation (26).

In conclusion, antidromic circus movement tachycardia occurred in 11% of our patients with the Wolff-Parkinson-White syndrome. Clinical documentation of antidromic tachycardia occurred less frequently (6%) and was associated with a high incidence of syncope. There is a high incidence (33%) of multiple accessory pathways in patients in whom antidromic tachycardia can be induced, and even higher in patients with clinically documented antidromic tachycardia (61%). Palpitations were the most common symptom, however dizziness and syncope occurred in a high percentage of patients with antidromic circus movement tachycardia. There was also a high incidence of previous ventricular fibrillation (11%) in these patients.

Many different pathways are possible during antidromic tachycardia. Like others, we found that surgery has a high success rate in the treatment of these patients.

REFERENCES

1. Wellens HJJ. Electrical stimulation of the heart in the study and treatment of tachycardias. Baltimore, University Park Press 1971; pp 74-121.

2. Gallagher JJ, Pritchett ELC, Sealy WC, Kasell J, Wallace AG. The preexcitation syndromes. Prog Cardiovasc Dis 1978; 20: 285-327.

3. Cosio FG, Benson DW, Anderson RW, Hession WT, Pritzker MR, Kriett JM, Benditt DG. Onset of atrial fibrillation during antidromic tachycardia: association with sudden cardiac arrest and ventricular fibrillation in a patient with Wolff-Parkinson-White syndrome. Am J Cardiol 1982; 50: 353-359.

4. Heddle WF, Brugada P, Wellens HJJ. Multiple circus movement tachycardias with multiple accessory pathways. J Am Coll Cardiol 1984; 4: 168-175.

5. Chung EK, Walsh TJ, Massie E. Wolff-Parkinson-White syndrome. Am Heart J 1965; 69: 116-133.

6. Wellens HJJ, Durrer D. Patterns of ventriculo-atrial conduction in the Wolff-Parkinson-White syndrome. Circulation 1974; 49: 22-41.

7. Fontaine G, Frank R, Coutte R, Vedel JP Grosgogeat Y. Rhythme reciproque antidromique dans un syndrome de Wolff-Parkinson-White de Type A. Ann Cardiol Angeiol 1975; 24: 59-66.

8. Benditt DG, Pritchett ELC, Gallagher JJ. Spectrum of regular tachycardias with wide QRS complexes in patients with accessory atrioventricular pathways. Am J Cardiol 1978; 42: 828-838.

9. Akhtar M. Electrophysiologic bases for wide QRS complex tachycardia. Pace 1983; 6: 81-98.

10. Smith WM, Broughton A, Reiter MJ, Benson DW, Grant AO, Gallagher JJ. Bystander accessory pathway during AV node re-entrant tachycardia. Pace 1983; 6: 537-547.

11. Zipes DP, DeJoseph RL, Rothbaum DA. Unusual properties of accessory pathways. Circulation 1974; 49: 1200-1214.

12. Wellens HJJ. Modes of initiation of circus movement tachycardia in 139 patients with the Wolff-Parkinson-White syndrome studied by programmed electrical stimulation. In, Reentrant Arrhythmias. Mechanisms and Treatment (Kulbertus HE, ed). Lancaster, MTP Press, 1977, p 153-169.

13. Grolleau R, Dufoix R, Puech P, Latoue H. Les tachycardies par rhythme reciproque dans le syndrome de Wolff-Parkinson-White. Arch Mal Coeur 1970; 63: 74-96.

14. Kuck KH, Brugada P, Wellens HJJ. Observations on the antidromic circus movement tachycardia in the Wolff-Parkinson-White syndrome. J Am Coll Cardiol 1983; 2: 1003-1010.

15. Sung RJ, Castellanos A, Mallon SM, Bloom MG, Gelband H, Myerburg RJ. Mechanisms of spontaneous alternation between reciprocating tachycardia and atrial flutter fibrillation in the Wolff-Parkinson-White syndrome. Circulation 1977; 56: 409-417.

16. Wellens HJJ, Durrer D. The role of an accessory atrioventricular pathway in reciprocal tachycardia. Observation in patients with and without Wolff-Parkinson-White syndrome. Circulation 1975; 52: 58-64.

17. Belhassen B, Misrahi D, Shapira I, Laniado S. Longitudinal dissociation in an anomalous accessory atrioventricular pathway. Am Heart J 1983; 106: 1441-1443.

18. Bardy GH, Packer DL, Lawrence DG, Gallagher JJ. Preexcited reciprocating tachycardia in patients with Wolff-Parkinson-White syndrome: incidence and mechanisms. Circulation 1984; 70: 377- 391.

19. Klein GJ, Sharma AD, Milstein S. Initial evaluation of the patient with the Wolff-Parkinson-White syndrome. In Benditt DG, Benson DW, eds: Cardiac Preexcitation Syndromes: Origin, Evaluation and Treatment. Martinus Nijhoff Publishing, Boston, 1986; p 305-320.

20. Sherf L, Neufeld HN: General consideration. In Sherf L. Neufeld HN, eds: The pre-excitation syndrome: facts and theories. Yorke Medical Books, New York 1978; p 1-35.

21. Papa LA, Saia JA, Chung EK et al: Ventricular fibrillation in Wolff-Parkinson-White type A. Heart Lung 1978; 7: 1015-1019.

22. Klein GJ, Bashre JM, Seller TD. Ventricular fibrillation in the Wolff-Parkinson-White syndrome. N Engl J Med 1979; 301: 1080-1085.

23. Dreifus LS, Haia R, Watanabe Y et al. Ventricular fibrillation: a possible method of sudden death in patients with Wolff-Parkinson-White syndrome. Circulation 1971; 43: 520-527.

24. Colavita PG, Packer DL, Pressley JC, Ellenbogen KA, O'Callaghan WG, Gilbert MR, German LD. Frequency, diagnosis and clinical characteristics of patients with multiple accessory atrioventricular pathways. Am J Cardiol 1987; 59: 601-606.

25. Wellens HJJ, Brugada P. Value of programmed stimulation of the heart in patients with Wolff-Parkinson-White syndrome. In Josephson ME, Wellens HJJ (eds): Tachycardias Philadelphia- Lea & Febiger, 1984, p 189-222.

26. Atié, J, Brugada P, Smeets JLRM, Cruz FES, Penn OCKM, Wellens HJJ. Further support of the atrio-ventricular localization of so-called "Mahaim Fibers". J Am Coll Cardiol 1989; 13: 232 (Abst).

Chapter IV

The diagnosis of multiple accessory pathways in the Wolff-Parkinson-White syndrome from the surface electrocardiogram in sinus rhythm

Jacob Atié
Pedro Brugada
Fernando E.S. Cruz
Joep L.R.M. Smeets
Ayrton Peres
Mauricio Duque
Hein JJ Wellens

The diagnosis of multiple accessory pathways in the Wolff-Parkinson-White syndrome from the surface electrocardiogram in sinus rhythm

SUMMARY

Multiple accessory pathways are present in 5-15% of patients with pre-excitation syndrome. The diagnosis of multiple accessory pathways is rarely made on the resting 12 lead electrocardiogram during sinus rhythm. We analyzed the 12 lead electrocardiograms of 18 patients with two or more accessory pathways and compared them with the electrocardiograms of 50 patients having only one accessory pathway. All patients had an electrophysiological study and 9 patients a peroperative epicardial mapping. In 5 of the 18 patients with multiple accessory pathways only one accessory pathway showed anterograde conduction. Comparing the polarity of the delta wave with the main frontal QRS axis, we observed that 9/13 patients (69%) having A-V conduction over more than one accessory pathway had a discordant pattern between axis of the QRS and delta wave morphology, while only 4 patients (8%) with one accessory pathway had this discordant pattern. A qrS or qRS morphology in lead V1 was seen in 6/13 patients (46%) with A-V conduction over more than one accessory pathway and in only 2 patients (4%) with one accessory pathway. We conclude that the presence in the electrocardiogram during sinus rhythm of a discordant pattern between QRS axis and delta wave morphology or a qRS or qrS configuration in V1 is suggestive of multiple accessory pathways.

Accepted for presentation at the American College of Cardiology in 1990
Submitted for publication

INTRODUCTION

The accessory pathway of the Wolff-Parkinson-White syndrome may be situated anywhere around the atrio-ventricular ring (1). Knowledge of the anatomic location of the accessory atrioventricular pathway became relevant to the clinician with the advent of operative and ablative therapies (2,3). Localization of such tracts on the 12 lead electrocardiogram has been facilitated by application of the knowledge derived from electrophysiologic studies (4-8). Multiple accessory pathways are present in 5-15% of patients with pre-excitation syndromes (9,10). The diagnosis of multiple accessory pathways is rarely made on the resting 12 lead electrocardiogram (6-8). The purpose of our study was to identify criteria for the diagnosis of multiple accessory pathways on the 12 lead electrocardiogram during sinus rhythm.

PATIENTS AND METHODS

The study population consisted of 18 patients with multiple atrioventricular accessory pathways and 50 consecutive patients having one atrioventricular accessory pathway. There were 57 men and 11 women, aged 26 ± 13 years.

A 12 lead electrocardiogram with simultaneous recording of three, six or 12 leads was obtained for each patient during spontaneous sinus rhythm.

All patients were submitted to a complete electrophysiological study using previously described techniques (11). All patients with one accessory pathway and nine with multiple accessory pathways underwent surgical ablation of their accessory pathway(s).

Electrocardiographic Classification

We grouped accessory pathways into one of four anatomic locations (fig. 1). Anteroseptal, left free wall, right free wall and posteroseptal accessory pathway. The right and left paraseptal accessory pathways were included in the posteroseptal location.

Criteria for localization

To localize an accessory pathway on the 12 lead electrocardiogram, we required a short P-delta interval and a width of the ventricular complex of at least 0.12 sec to ensure a sufficient degree of pre-excitation of the ventricles. Thereafter the following steps were taken:

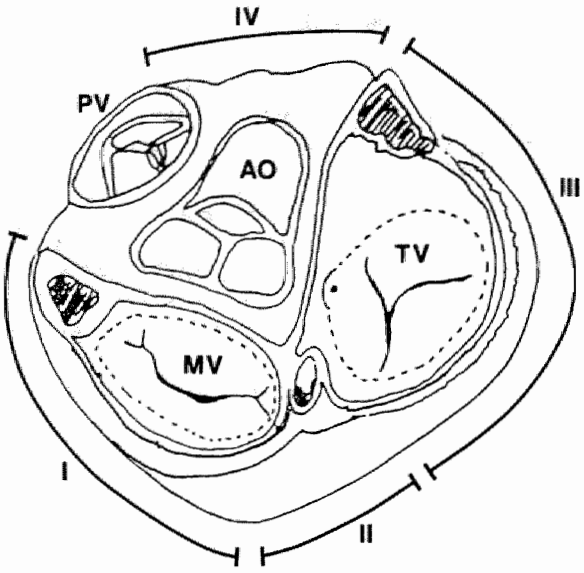

Figure 1. Cross-sectional diagram of the heart at the level of the annulus fibrosus showing the 4 anatomic regions: left lateral (I), posteroseptal (II), right free wall (III) anteroseptal (IV). Abbreviations: AO=aorta; MV=mitral valve; PV=pulmonare valve; TV=tricuspide valve

1. *Analysis of the delta wave*: In the literature (7) the polarity of the delta waves in the presence of a single accessory pathway has been suggested to be as described in table I. *A right lateral* accessory pathway (region III) is expected to give a delta wave which is positive in leads I, aVL, II, aVF, V6, negative or isoelectric in leads V1 and V2 and positive, isoelectric or negative in lead III. *A left lateral* accessory pathway (region I) should give a delta wave which is negative in lead aVL, negative or isoelectric in lead I, positive in lead, III and aVF, and isoelectric or negative in lead V6. *An anteroseptal* accessory pathway (region IV) is expected to show a delta wave positive in leads II, III, aVF, V6 and negative in leads V1 and V2. With *a posteroseptal* accessory pathway (region II), the delta wave is expected to be negative in leads III, aVF and negative, isoelectric or positive in leads II, V1 and V6 (7).
2. *Analysis of the frontal QRS axis*: The polarity of the QRS axis in the frontal plane is illustrated in fig 2, and may help in the localization of the accessory pathway. With *a right lateral* accessory pathway the axis is located between -30° and -60°. With *a left lateral* accessory pathway between +60° and +120°. With an *anteroseptal* accessory pathway inbetween 0° and +60° and with *posteroseptal* accessory pathways between 0° and -45°.

Table I. The polarity of delta wave in the different possible localizations of accessory atrio-ventricular pathways.

LEADS	LL	PS	RL	AS
I	-i	+	+	+
II	+	-i+	+	+
III	+	-	+i-	+
aVL	-	+	+	+
aVF	+	-	+	+
V1	+	+-i	-i	-
V2	+	+	-i	-
V6	-i+	i-+	+	+

Abbreviations: LL= left lateral; PS= postero septal; RL= right lateral; AS= anteroseptal; i= polarity of delta wave isoelectric; - = polarity of delta wave negative; + = polarity of delta wave positive. From reference 5.

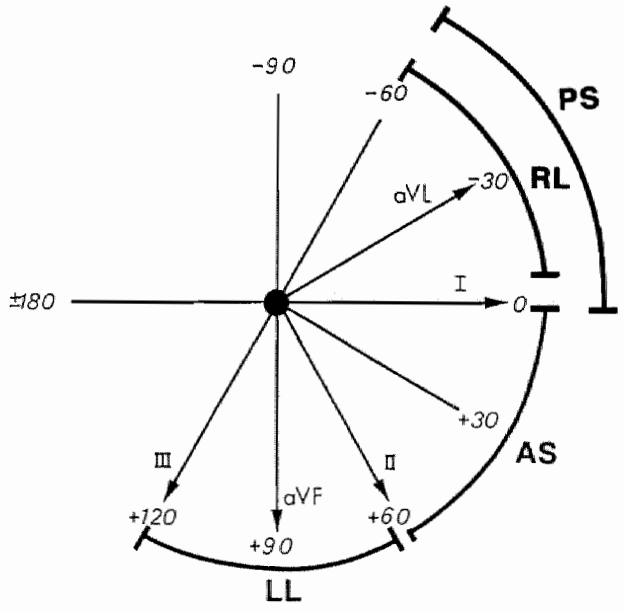

Figure 2. Diagram illustrating the frontal plane QRS axis in the different locations of accessory pathways in the Wolff-Parkinson-White syndrome. Abbreviations: AS= antero-septal; LL= left lateral; PS= posteroseptal; RL= right lateral.

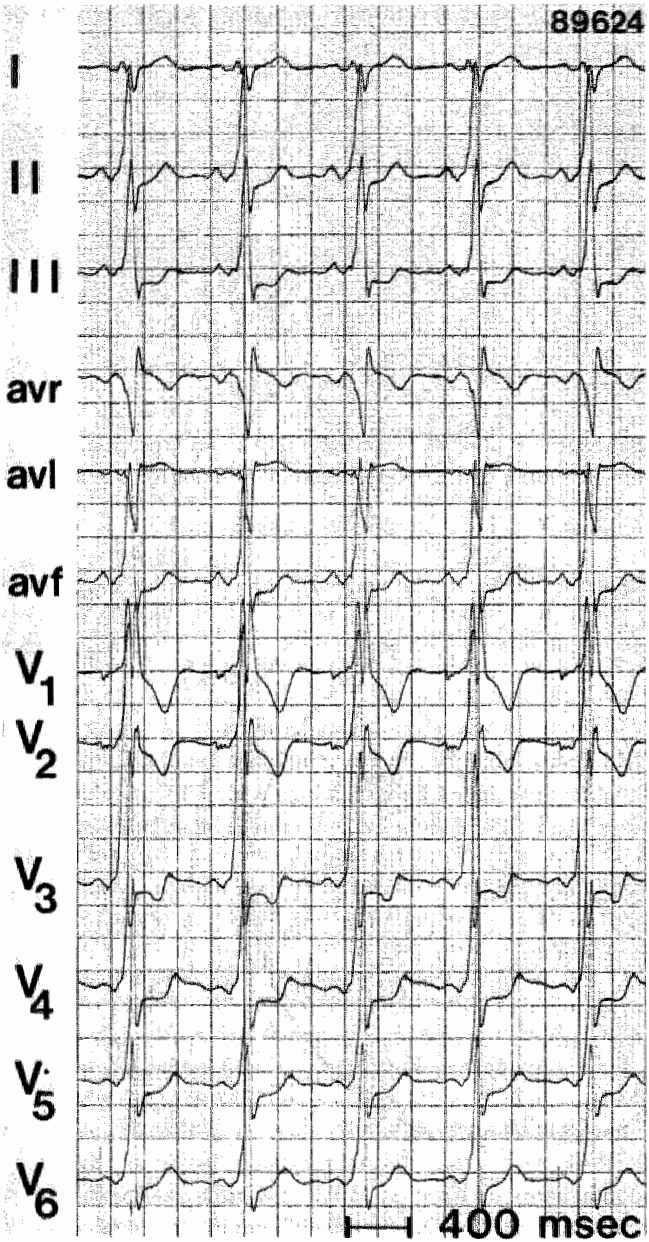

Figure 3. Electrocardiogram of the Wolff-Parkinson-White syndrome in a patient with a left lateral accessory pathway. The QRS axis is +100°. A concordant pattern between delta wave and the QRS axis is present (see text).

Concordant Pattern

Concordance between delta wave polarity and axis of the QRS complex in the frontal plane was diagnosed when they had the same direction (fig. 3,4).

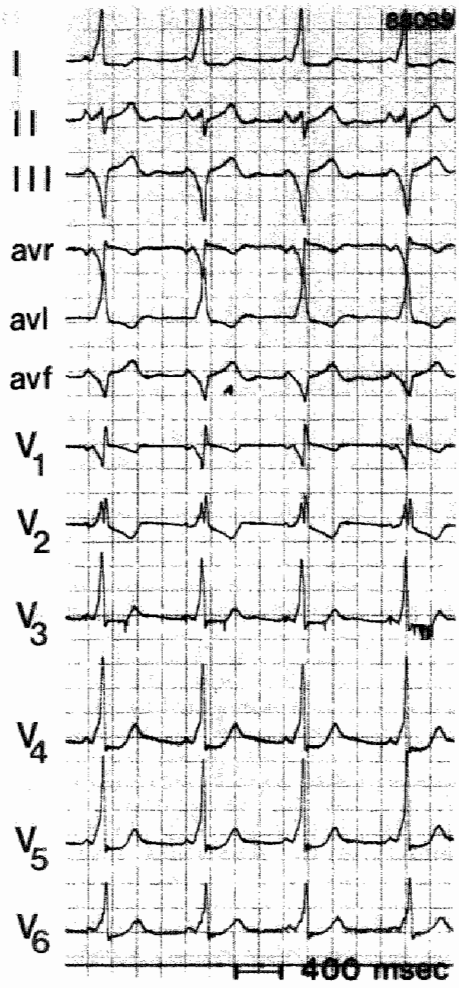

Figure 4. Electrocardiogram of a Wolff-Parkinson-White syndrome due to a right posteroseptal accessory pathway. The QRS axis is -30°. There is a concordant pattern between the delta wave and the QRS axis.

Discordant Pattern

We classified pre-excitation as having a discordant pattern when the axis of the QRS complex was located in an area different from the area where the accessory pathway was localized as assessed from the polarity of the delta wave. For instance, in figure 5 the delta wave indicates a right-sided accessory pathway, however, the QRS axis is +15° which would fit with an anteroseptal accessory pathway. Thus, axis of QRS and delta wave polarity are discordant. Another example is given in figure 6.

The true location the accessory pathway(s) was confirmed at surgery (59 patients) or by electrophysiologic study (all patients). That location was compared with the predicted localization of the accessory pathway (s) using

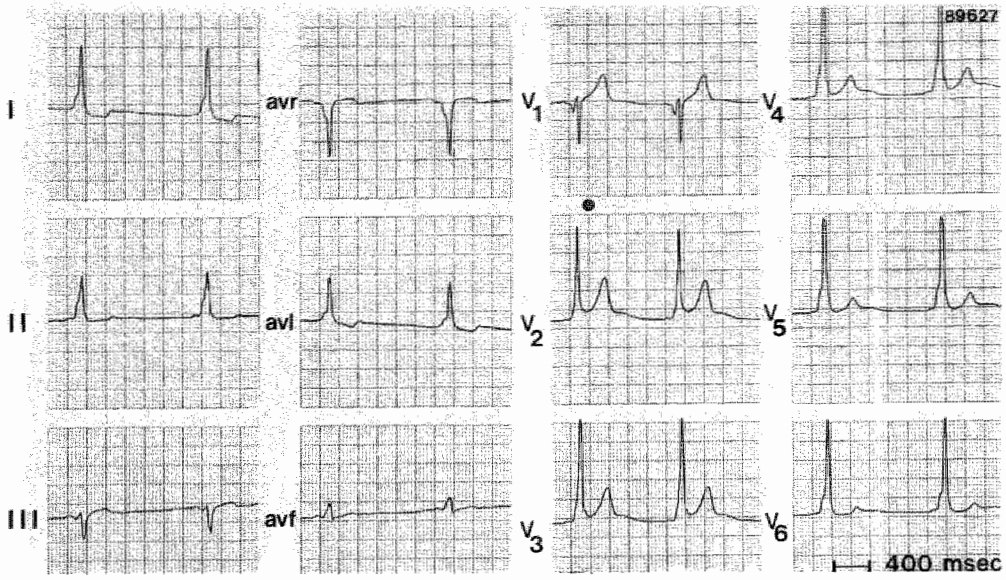

Figure 5. Electrocardiogram of Wolff-Parkinson-White with 2 different accessory pathways (right lateral and left paraseptal). The delta wave polarity fits with a right sided accessory pathway, however the QRS axis is +15°. Therefore a discordant pattern is present. Lead V1 shows the QRS morphology which is suggestive for two different accessory pathways.

the above mentioned criteria. Thereafter the 12 lead electrocardiogram during sinus rhythm was carefully studied comparing the 50 patients having one accessory pathway with the 18 patients having multiple accessory pathways.

RESULTS

The true location of the accessory pathway (s) of all patients are shown in the table II and III. Left free wall was the most prevalent location in patients with a single accessory pathway (48%).

Analyzing the 12 lead electrocardiogram from the 18 patients with two or more accessory pathways we found a discordant pattern between delta wave and QRS axis in 9 patients (50%), while only 4 patients (8%) out of 50 patients with a single accessory pathway had a discordant pattern between the QRS axis and the polarity of the delta wave. When we correct for the fact that in only 13 patients more than one of the multiple accessory pathways was able to conduct in A-V direction, we come to 9/13 patients (69%) with a discordant pattern.

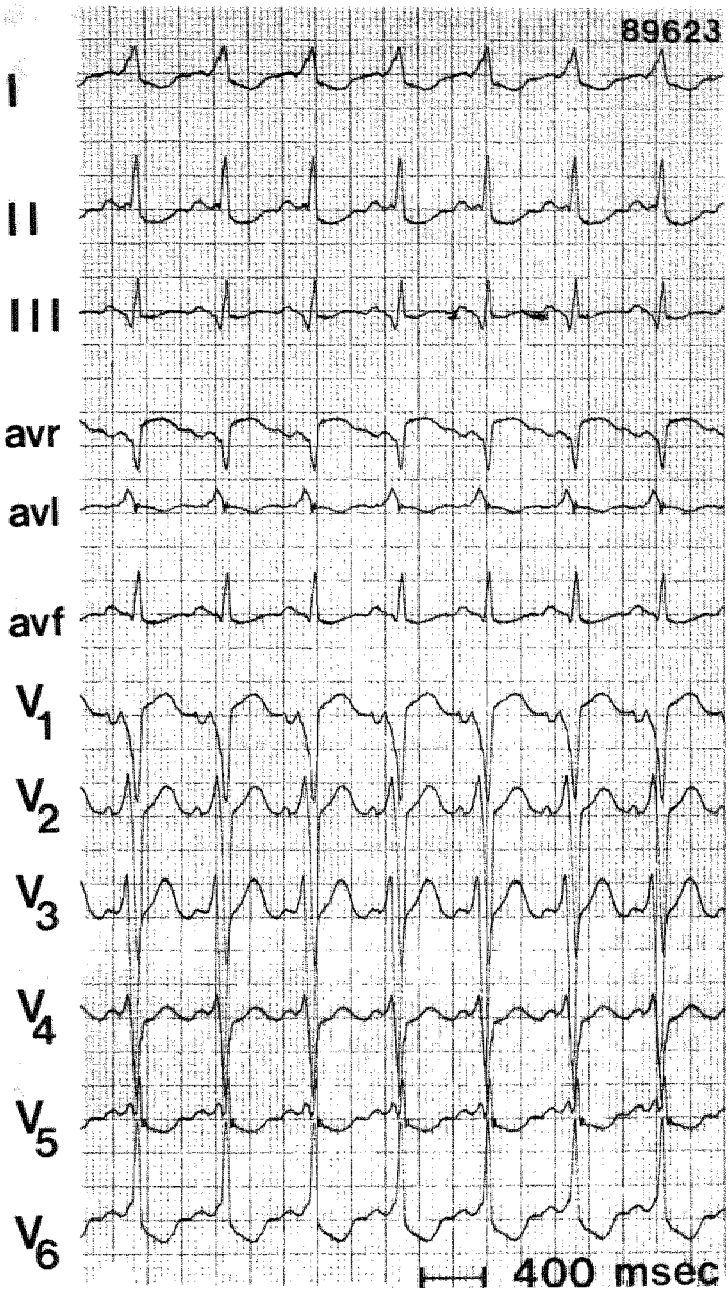

Figure 6. Electrocardiogram from a patient with anterograde conduction over 2 different accessory pathways (left and right free wall). The delta wave fits with a left posteroseptal accessory pathway, however the QRS axis is +45, indicating a discordant pattern.

Table II. Localization of the accessory pathway in the patients with a single accessory pathway (intracardiac mapping and mapping during surgery).

Left lateral	23 patients
Posteroseptal	23 patients
Right lateral	3 patients
Anteroseptal	1 patient

Table III. Location of the accessory pathway in the patients with multiple accessory pathways (intracardiac mapping and mapping during surgery).

LL + RL	3 patients
LL + LPS	3 patients
LL + RPS	2 patients
LL + AS	1 patient
LPS + RPS	3 patients
LPS + RNV	1 patient
LPS + RL	1 patient
LL + LPS + RPS	2 patients
LL + RL + LPS	2 patient

On studying the delta QRS morphology on the 12 lead electrocardiogram in all patients, we found that 6 of the 13 patients (46%) with A-V conduction over multiple accessory pathways had a qrS or qRS pattern in lead V1 (fig. 5,7), while only 2 patients (4%) from the group with a single accessory pathway showed that pattern.

Eleven of the 13 patients (84%) in the group with multiple accessory pathways able to conduct anterogradely had either a discordant pattern or a qRS morphology in lead V1. This was found in only 6 patients (12%) having a single accessory pathway. A discordant pattern plus a qRS or qrS morphology in V1 was present in 4 patients (22%) with multiple accessory pathways and in one patient (2%) in the group with a single accessory pathway.

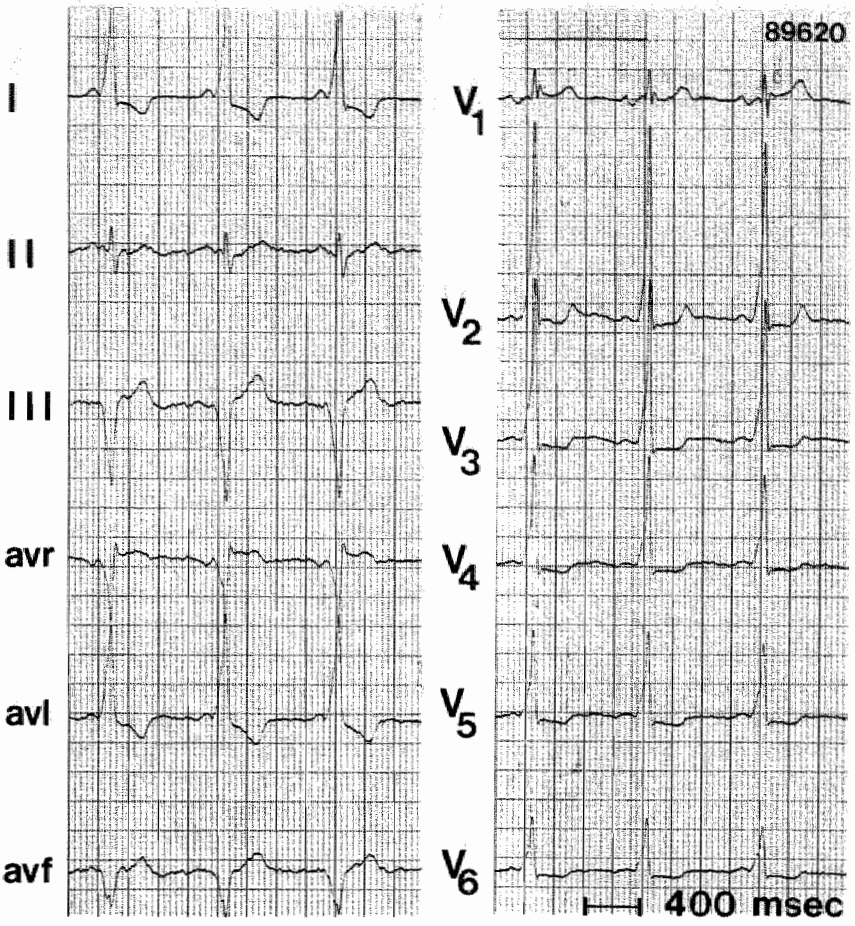

Figure 7. Electrocardiogram of a patient with anterograde conduction over 2 different accessory pathways (left lateral and right posteroseptal). The delta wave fits with a right posteroseptal accessory pathway, the QRS axis is -30°. Concordant pattern is present. The morphology of lead V1 however is very suggestive of multiple accessory pathways.

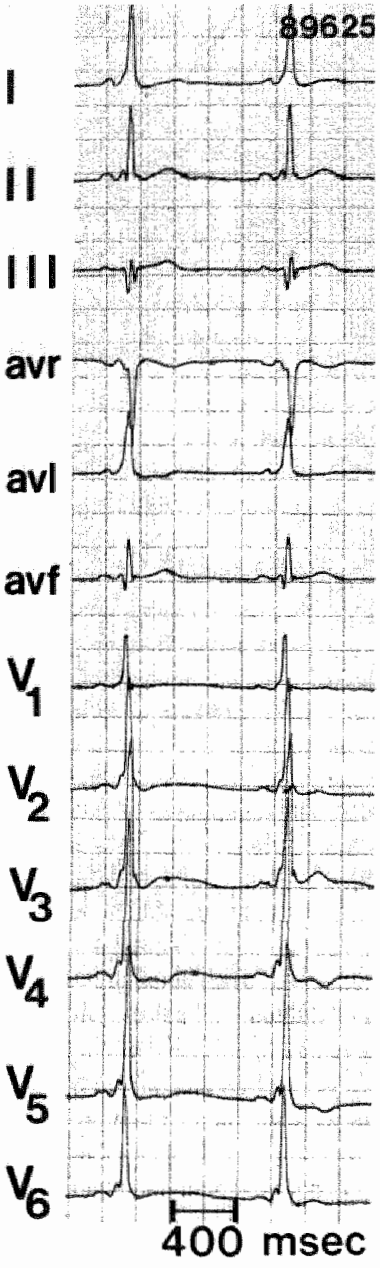

Figure 8. Electrocardiogram of a patient with anterograde conduction over 2 different accessory pathways (left lateral and left posteroseptal). The delta wave fits with a left posteroseptal accessory pathway, however the QRS axis is +30° indicating a discordant pattern.

DISCUSSION

The stimulus to localize the site of an accessory pathway on the ECG comes from our ability to treat Wolff-Parkinson-White patients by surgical or electrical ablation of the accessory atrioventricular pathways (12-14). In those patients it would be very helpful to recognize or suspect multiple accessory pathways.

In 1945 Rosenbaum et al (15) classified electrocardiograms from patients with ventricular pre-excitation into type A and B. The type A pattern was attributed to a left sided and type B to a right sided accessory pathway. This classification did not account for a more precise localization of accessory pathways. Following the introduction of catheter and operation mapping a wide spectrum of electrocardiographic patterns from patients with Wolff-Parkinson-White syndrome and their association with the anatomic location of the accessory pathway was reported (16.17). More recently other studies have reported different criteria to localize the anatomic position of the accessory pathway by using the 12 lead electrocardiogram (5-8).

The importance of the delta wave polarity to localize an accessory pathway in Wolff-Parkinson-White syndrome is well known (6,7). The analysis of the main QRS deflection is also helpful when the mechanism of axis deviation is understood in relation to the different possible localizations of accessory pathways. During normal ventricular activation spread of activation occurs transversely and synchronously through the free walls of both ventricles from the endocardial to the epicardial surfaces. The larger QRS forces of the anatomically larger free wall tend to counteract the smaller QRS forces of the smaller free right wall. Thus the main resultant QRS vectors are directed to the left. In the Wolff-Parkinson-White syndrome apart from activation over the A-V node His-axis, the ventricle is excited eccentrically over the accessory pathway changing the mode and direction of excitation and disturbing the normal balance. Thus, with right lateral pre-excitation, the right free wall forces are preempted so that the left free wall forces become even more dominant leading to left axis deviation. With left lateral pre-excitation, the left free wall forces are preempted, therefore the right free wall forces tend to be less opposed, and the main QRS axis will deviate to the right. The degree of shift in frontal plane axis will be more or less marked depending upon the degree of pre-excitation. In patients with a normal PR interval and minimal pre-excitation the axis will be normal in contrast to patients with marked pre-excitation.

The analysis of axis deviation can only be used in patients who do not have conduction disturbances or underlying heart disease which produces an abnormal axis on the electrocardiogram.

Using both criteria, the delta wave polarity and the QRS axis, more precise localization of the accessory pathway should be possible. Prediction of accessory pathway localization was found to be possible in 44 out of 50 patients with a single accessory pathway (88%). However, when anterograde conduction occurs over more than one accessory pathway, there is competition

between pre-excitation from two or three different positions and the concordance between the polarity of the delta wave and the QRS axis is likely to disappear. In our study, from the 18 patients with more than one accessory pathway 9 patients (50%) presented a discordant pattern between the polarity of delta wave and the QRS axis. From those 18 patients with multiple accessory pathways, 5 patients had only one accessory pathway conducting anterogradely, the other accessory pathway was conducting only in the retrograde direction. Therefore, 9 of the 13 patients (69%) using more than one accessory pathway for A-V conduction showed a discordant pattern. It is possible that in the remaining 4 patients the pre-excited area over one of the accessory pathways was not large enough to produce the expected changes in the electrocardiogram during sinus rhythm.

A qRS or qrS pattern in lead V1 is very seldom seen in the electrocardiogram of patients with Wolff-Parkinson-White syndrome. In the 50 patients with a single accessory pathway this pattern was present in only 2 patients (4%). However 6 of the 18 patients (33%) with multiple accessory pathways and 6 of the 13 (46%) having anterograde conduction over more than one accessory pathway showed this pattern.

From our study we conclude that the presence in the 12 lead electrocardiogram of a qRS or qrS pattern in lead V1 and discordance between the delta wave polarity and the QRS axis is suggestive of multiple accessory atrioventricular pathways. Such a finding should be an extra stimulus to look for more than one accessory pathway during the electrophysiologic study and during cardiac mapping.

REFERENCES

1. Cox JL. The surgical mannagement of cardiac arrhythmias. In: Sabiston DC, Spencer FC (eds). Gibbon's Surgery of the Chest, Philadelphia, WB Saunders. 1983; 1552-1584.

2. Guiraudon GM, Klein GJ, Sharma AD, Milstein S, McLellan DG. Closed-heart technique for Wolff-Parkinson-White syndrome: Further experience and potential limitations. Annals of Thoracic Surgery 1986; 42: 651-657.

3. Wellens HJJ, Janse MJ, van Dam RTh, van Capelle FJL, Meijne NG, Mellink HM, Durrer D. Epicardial mapping and surgical treatment in Wolff-Parkinson-White syndrome type A. Am Heart J 1974; 88: 69-78.

4. Wellens HJJ, Farré J, Ross D, Vanagt EJ, Bär FW. Preoperative localization of bypass tract(s) in the Wolff-Parkinson-White syndrome. Springer Verlag 1980: 94-105.

5. Gallagher JJ, Pritchett ELC, Sealy WC, Kassell J, Wallace AG. The pre-excitation syndrome. Prog. Cardiovasc. Dis. 1978; 20: 285-296.

6. Reddy GV, Schamroth L. The localization of bypass tracts in the Wolff-Parkinson-White syndrome from the surface electrocardiogram. Am Heart J 1987; 113: 984-993.

7. Lindsay BD, Crossen KJ, Cain ME. Concordance of distinguishing electrocardiographic features during sinus rhythm with the location of accessory pathways in the Wolff-Parkinson-White syndrome. Am Heart J 1987; 59: 1093-1102.

8. Milstein S, Sharma AD, Guiraudon GM, Klein GJ. An algorithm for the electrocardiographic localization of accessory pathways in the Wolff-Parkinson-White syndrome. PACE 1987; 10: 555-563.

9. Bardy GH, Packer DL, German LD, Gallagher JJ. Preexcited reciprocating tachycardia in patients with Wolff-Parkinson-White syndrome: Incidence and mechanisms. Circulation 1984; 70: 377-391.

10. Colavita PG, Packer DL, Pressley JC, Ellenbogen KA, O'Callaghan WG, Gilbert MR, German LD. Frequency, diagnosis and clinical characteristics of patients with multiple accessory atrioventricular pathways. Am J Cardiol 1987; 59: 601-606.

11. Wellens HJJ, Durrer D. The role of an accessory atrioventricular pathway in reciprocal tachycardia. Observations in patients with and without the Wolff-Parkinson-White syndrome. Circulation 1975; 52: 58-64.

12. Cox JL, Gallagher JJ, Cain ME. Experience with 118 consecutive patients undergoing operation for the Wolff-Parkinson-White syndrome. J Thorac Cardiovasc Surg 1985; 90: 490-501.

13. Scheinman MM, Davis JC. Catheter ablation for treatment of tachyarrhythmias: present role and potential promise. Circulation 1986; 73: 10-13.

14. Morady F, Scheinman MM, DiCarlo LA, Winston SA, Davis JC, Baerman JM, Krol RB, Crevey BJ. Coexistent posteroseptal and right-sided atrioventricular bypass tracts. JACC 1985; 5: 640-646.

15. Rosenbaum FF, Hecht HH, Wilson FN, Johnson FD. The potential variations of the thorax and esophagus in anomalous atrioventricular excitation Wolff-Parkinson-White syndrome. Am Heart J 1945; 29: 281-326.

16. Boineau JP, Moore EN, Spear JF, Sealy WC. Basis of static and dynamic electrocardiographic variations in Wolff-Parkinson-White syndrome. Anatomic and electrophysiologic observations in right and left ventricular pre-excitation. Am J Cardiol 1973; 32: 32-45.

17. Tonkin AM, Wagner GS, Gallagher JJ, Cope CD, Kasell J, Wallace AG. Initial forces of ventricular depolarization in the Wolff-Parkinson-White syndrome. Circulation 1975; 52: 1030-1036.

Chapter V

The electrocardiogram in multiple accessory pathways

Hein J.J. Wellens
Jacob Atié
Joep Smeets
Fernando E. S. Cruz
Anton P.Gorgels
Pedro Brugada

The electrocardiogram in multiple accessory pathways

SUMMARY

Twelve lead ECG findings were reviewed in 17 patients having two or more accessory pathways as documented during electrocardiophysiologic study (17 patients) and intra-operative mapping (8 patients).

Findings arguing for the presence of more than one AV pathway were present in 12 patients. These were: 1) More than one P wave configuration during orthodromic circus movement tachycardia (4 patients); 2) A "mismatch" between the location of the ventricular and the atrial end of the accessory pathway when comparing in the same patient exclusive atrioventricular and ventriculo-atrial conduction over the accessory pathway during antidromic and orthodromic circus movement tachycardia respectively (7 patients); 3) Atrial fibrillation showing more than one pre-excitation pattern (6 patients); 4) A spontaneous change from orthodromic into antidromic circus movement tachycardia and vice-versa (2 patients); 5) a spontaneous change from one type of antidromic tachycardia to another (2 patients); 6) A change in pre-excitation pattern following the administration of drugs prolonging the anterograde refractory period of the accessory pathway (3 patients). The retrospective nature of our study does not allow conclusions as to the true value of the electrocardiogram to predict the presence of more than one accessory pathway. That has to be evaluated in a prospective study.

Accepted for publication in the Journal of the American College of Cardiology, in press

INTRODUCTION

Multiple accessory pathways are present in 5-15% of patients with pre-excitation syndromes (1,2). The possibility of therapies like surgery and electrical ablation to definitely interrupt conduction over accessory atrio-ventricular (AV) pathways requires the exact localization of these connections. It is essential under those circumstances to recognize patients having more than one accessory atrio-ventricular pathway. The purpose of this article is to present electrocardiographic clues which should make the physician suspicious of that situation.

MATERIAL AND METHODS

From February 1977 to May 1989, 314 patients with accessory AV connections underwent detailed electrophysiologic evaluation in our institution. Methods used have been described elsewhere (3). Studies were performed after informed consent and approved by our instutional committee on research. Seventeen patients were found to have more than one accessory pathway during electrophysiologic study and or intracardiac mapping. We carefully reviewed their 12 lead electrocardiograms during sinus rhythm, regular narrow QRS tachycardia, regular wide QRS tachycardia, atrial fibrillation and following the intravenous injection of drugs prolonging the refractory period of the accessory AV pathway, like ajmaline and procainamide.

RESULTS

The following electrocardiographic findings were found to be of value in recognizing more than one accessory pathway:

1. The ECG during orthodromic tachycardia

Four patients presented orthodromic circus movement tachycardia (CMT) with two different P wave configurations. Such a finding indicates that two accessory AV pathways can be used during CMT to conduct the impulse in ventriculo-atrial (V-A) direction (fig. 1).

2. "Mismatch" between the atrial and ventricular end of the accessory pathway by comparing antidromic and orthodromic CMT

When comparing in the same patient the ECG during orthodromic and antidromic CMT we discovered in 7 patients a "mismatch" between the location of the atrial and the ventricular end of the accessory pathway. The

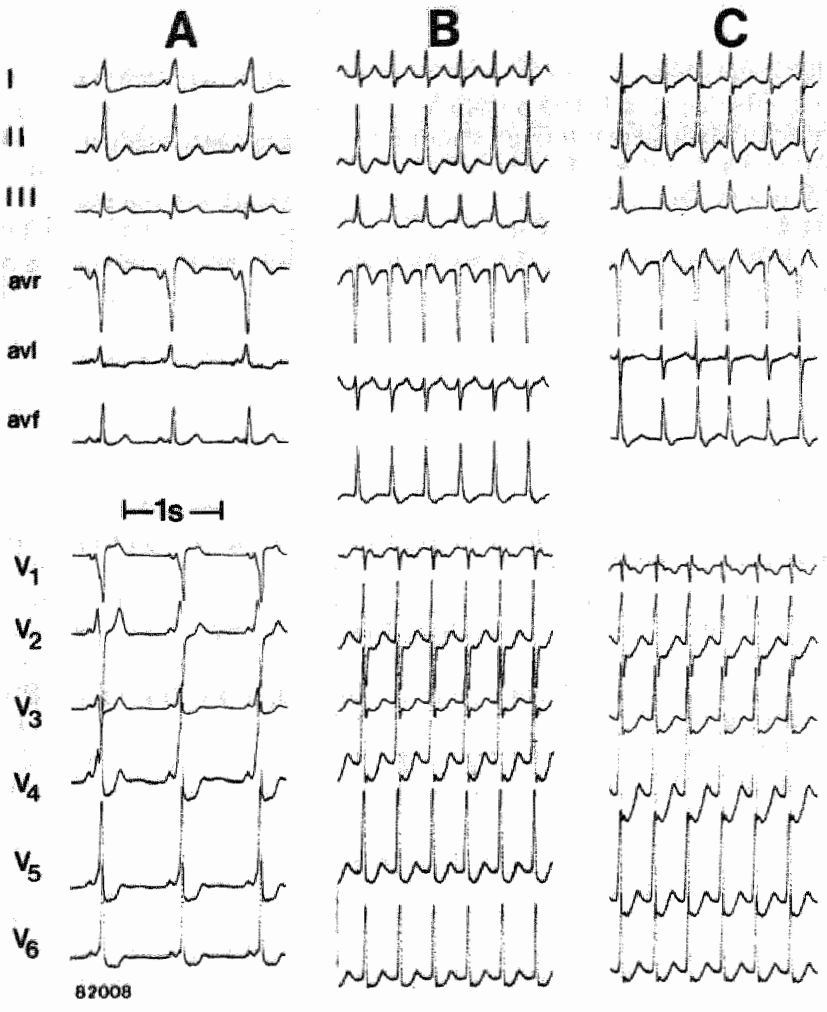

Figure 1. A patient with a right and a left free wall accessory pathway. Panel B shows orthodromic CMT using a right free wall accessory pathway. Note the positive P wave in leads I and AVL. In panel C a left sided free wall (neg P in lead I) is used during orthodromic CMT. Panel A shows the ECG during sinus rhythm.

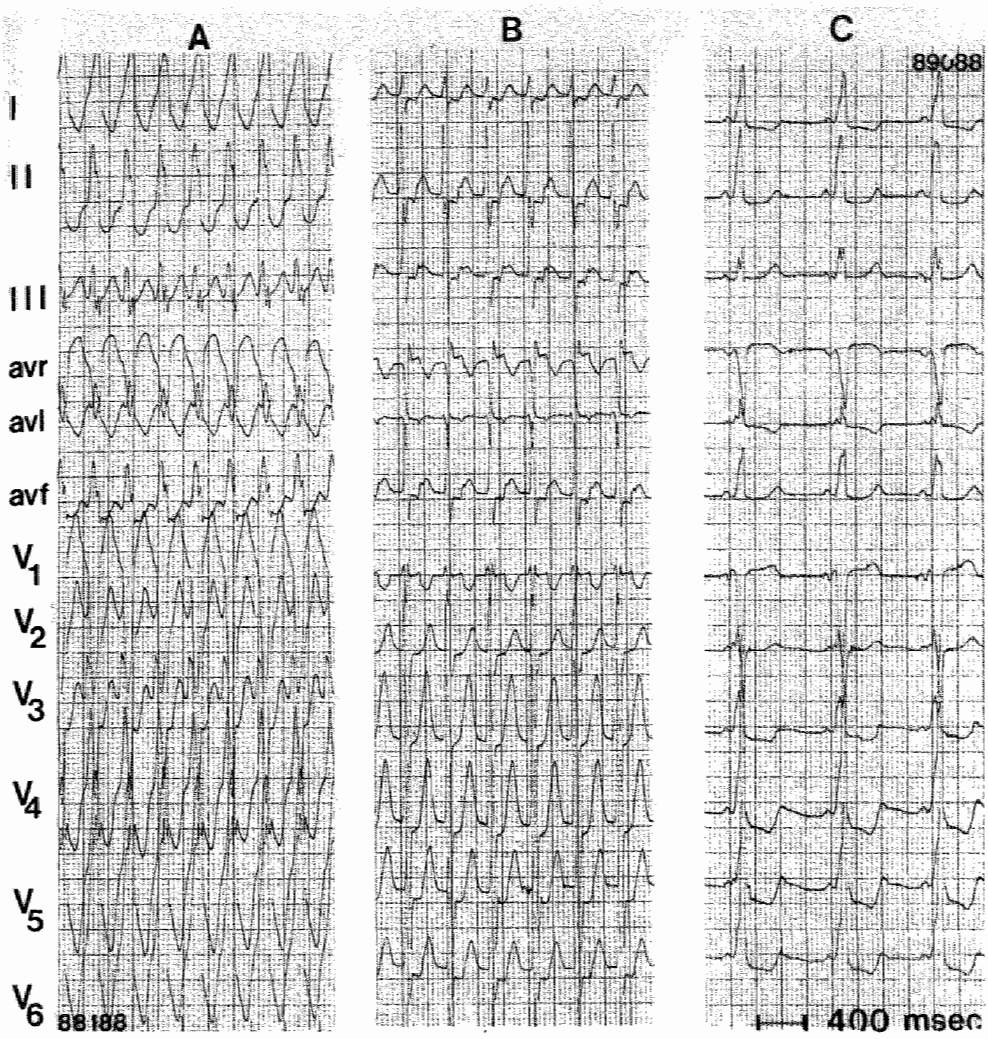

Figure 2. A patient with a right and a left free wall accessory pathway. The first one is used anterogradely during antidromic CMT (panel A). The second one is used retrogradely during orthodromic CMT (panel B). As shown the P wave is negative in leads I and aVL and positive in lead aVR. Panel C shows the ECG during sinus rhythm.

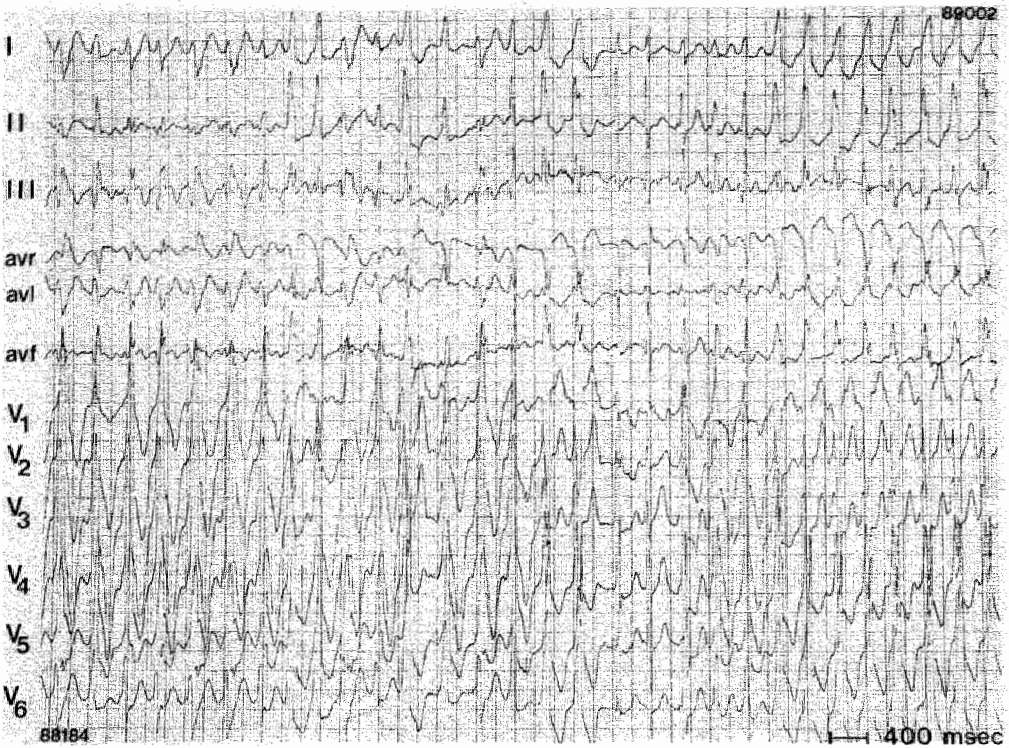

Figure 3. Atrial fibrillation with AV conduction over a left free wall (left part of figure) and right free wall accessory pathway (right part of figure). Also fusion complexes indicating anterograde conduction over both pathways can be seen.

location of the ventricular end of the accessory pathway was derived from the configuration of the delta wave during exclusive AV conduction over the accessory pathway (antidromic CMT) and the location of the atrial end from the configuration of the P wave during exclusive V-A conduction over the accessory pathway (orthodromic CMT) (fig. 2).

3. The ECG during atrial fibrillation

When analyzing the ECG during atrial fibrillation, 6 patients presented QRS complexes showing more than one pattern of pre-excitation suggesting the presence of more than one accessory AV pathway (fig. 3).

4. Spontaneous change from orthodromic to antidromic CMT or vice-versa

A spontaneous change from orthodromic into antidromic CMT (or vice-versa) was seen in 2 patients (fig. 4). This phenomenon can only be explained by the presence of at least 2 different accessory AV pathways (fig. 5A).

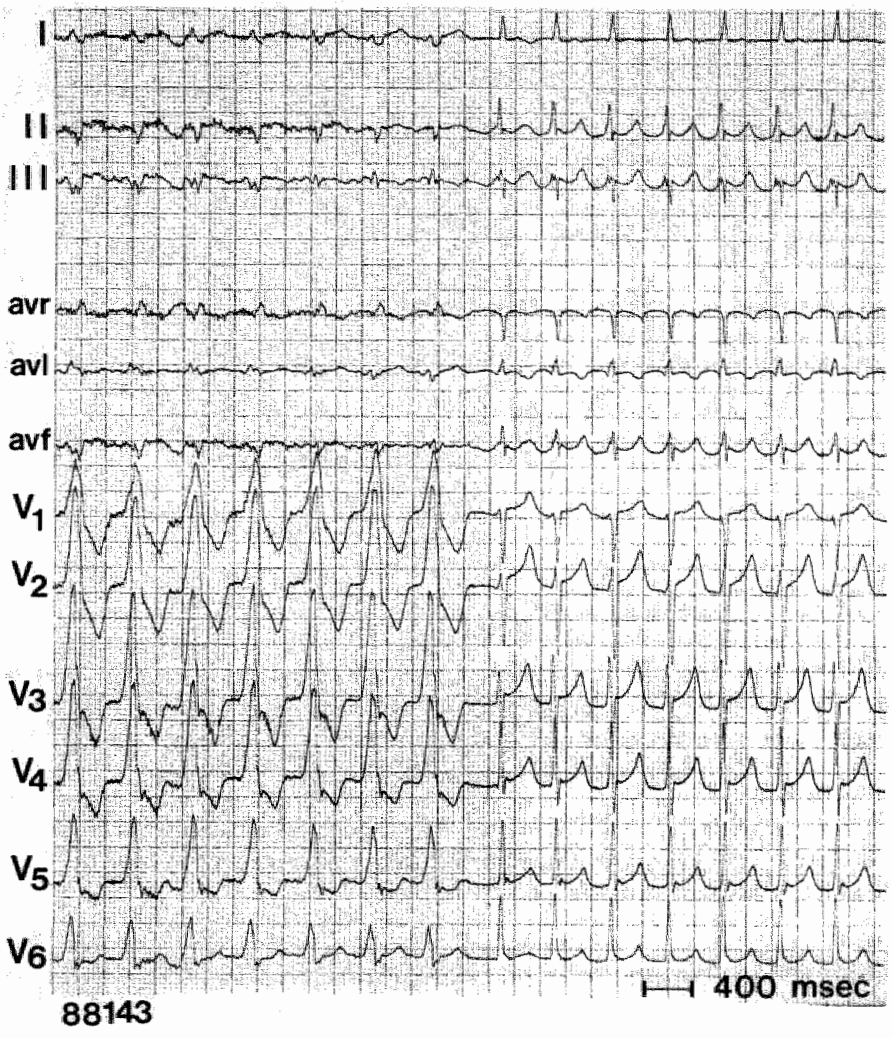

Figure 4. Spontaneous change from an antidromic CMT into an orthodromic CMT. In this patient AV conduction during antidromic CMT occurred over a left free wall pathway and V-A conduction during both antidromic and orthodromic CMT over a right sided accessory AV pathway.

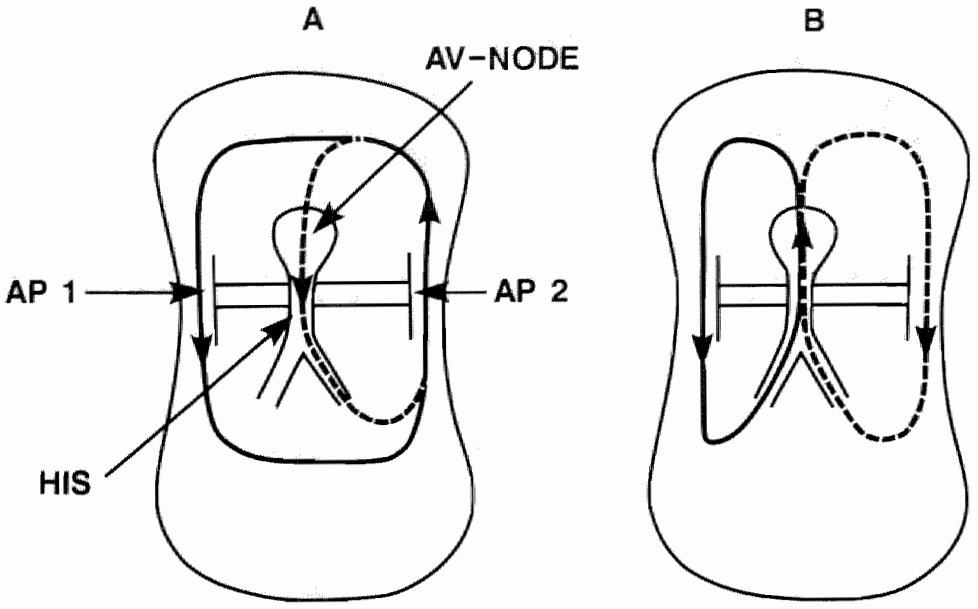

Figure 5. Scheme, illustrating a spontaneous change from an antidromic (solid line) into an orthodromic CMT (interrupted line) (panel A) or from one type of antidromic CMT (solid line) into another one (stippled line) (panel B). As shown, both situations require the presence of at least two accessory AV pathways. In panel B ventriculo-atrial conduction occurs over the His-AV node pathway. In the presence of a third accessory AV pathway that structure can also be used for retrograde conduction during the change from one antidromic CMT into another. Abbreviations: AP 1 = Accessory AV pathway 1; AP 2 = Accessory AV pathway 2; AV node = Atrioventricular node; His = His bundle.

5. *Spontaneous change from one type of antidromic tachycardia to another*

This was observed in 2 patients and as shown in fig. 5B can only occur in the presence of at least 2 different accessory pathways (fig. 6).

6. *Demonstration of more than one accessory AV pathway during administration of an agent prolonging the anterograde refractory period of the accessory pathway.*

Three patients showed during intravenous injection of ajmaline or procainamide a sudden change from one pre-excitation pattern to another. Depending upon the location of the accessoray pathways the change may be major (8) or minor (fig. 7). Fig. 7 stresses the necessity to record several ECG leads simultaneously to recognize the change in pre-excitation pattern. As shown in figure 7 continuation of drug administration eventually resulted in block of AV conduction in both accessory AV pathways.

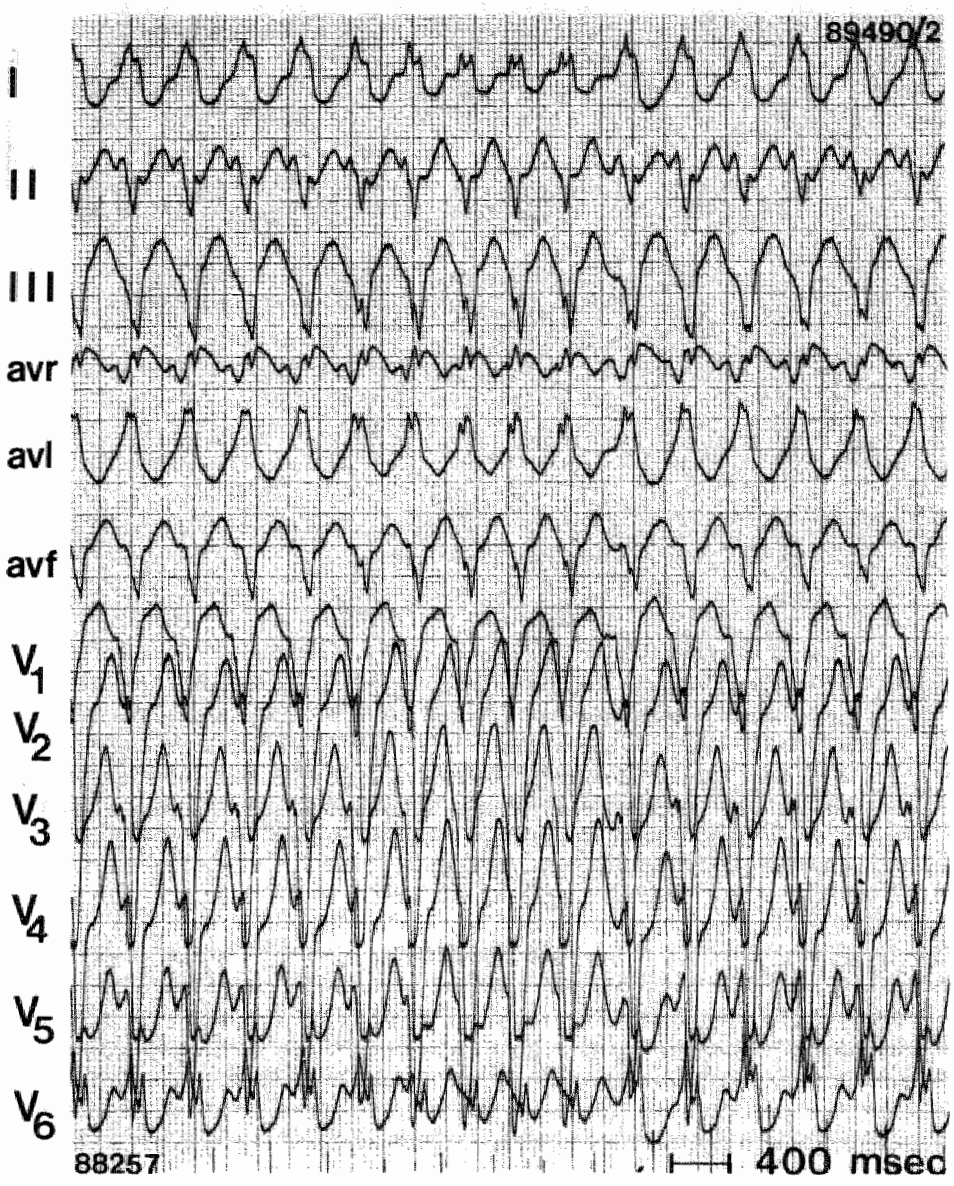

Figure 6. Example of the spontaneous change of one antidromic circus movement tachycardia to another. As shown in the middle of the figure, the QRS complex indicates a more right anterior location of the accessory pathway as during the antidromic tachycardia in the beginning and end of the figure. Note that the cycle length of the 2 tachycardias differs by 50 ms and fusion complexes are present when the tachycardia changes from one to another. Twelve electrocardiographic leads were recorded simultaneously.

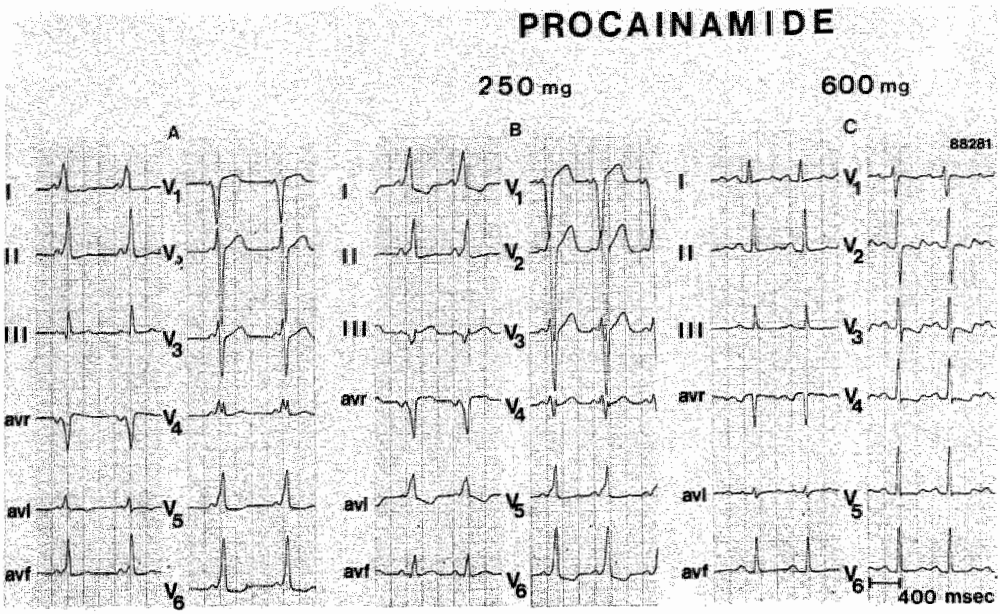

Figure 7. Exposure of two accessory AV pathways by procainamide in a patient with the Wolff-Parkinson-White syndrome. Panel A shows preexcitation pattern which in panel B after 250 mg of procainamide changes into another preexcitation pattern (most marked in lead III). Panel C shows disappearance of pre-excitation after a total of 600 mg of procainamide. The figure illustrates how, because of different electrophysiologic properties, the presence of two accessory atrio-ventricular pathways can be exposed during the administration of procainamide. Subsequent epicardial mapping studies during surgery showed one pathway to be located posteroseptally and the other on the right free wall.

DISCUSSION

Programmed electrical stimulation of the heart in patients with accessory AV pathways reveals that in 10-15% of patients studied in the catheterization laboratory more than one accessory AV pathway is present (1,2).

Their recognition is of obvious importance when surgical or electrical ablation of pre-excitation is considered. Colavita et al (1) in a large series of patients with multiple accessory AV pathways indicated the importance to look during the electrophysiologic study for: 1) Different patterns of ventricular pre-excitation during induced atrial fibrillation, flutter or atrial pacing; 2) Different sites of atrial activation during right ventricular pacing or orthodromic reciprocating tachycardia, and 3) Pre-excited reciprocating tachycardia using a second pathway as the retrograde limb of the tachycardia. We decided to carefully evaluate the 12 lead electrocardiogram in patients with multiple accessory AV pathways to pick up clues to the presence of more than one accessory AV pathway.

In reviewing that electrocardiographic information we found that the ECG should be studied during orthodromic and antidromic CMT, atrial fibrillation and during the injection of drugs prolonging the anterograde refractory period of the accessory AV pathway. Several investigators have reported on the use of the ECG during sinus rhythm to locate the accessory AV pathway in patients with pre-excitation (4-7). To be able to locate the accessory AV pathway on the 12 lead ECG sufficient pre-excitation of the ventricle over the accessory pathway should be present. This is indicated by a P-delta interval of less than 100 msec, a clear delta wave and a QRS width of at least 120 msec. Theoretically, if the ECG pattern during an ECG showing pre-excitation does not fit with one of the described patterns more than one accessory AV pathway may be suspected. The ECG, however may be affected by a congenital cardiac defect, ventricular hypertrophy, or muscle loss as in myocardial infarction. Prediction of anterograde AV conduction over more than one accessory AV pathway on the ECG during sinus rhythm is therefore difficult. A more useful finding indicating ventriculo-atrial conduction over more than one accessory pathway is the presence of two different types of P waves during orthodromic CMT. In order to have different P waves the site of atrial insertion of the accessory pathways must differ. We believe that major differences in the location of the atrial insertion site are required to lead to sufficient differences in P wave configuration to recognize the presence of more than one accessory AV pathway during ortodromic CMT.

It is likely that accessory AV pathways cross the AV ring in such a way that the atrial and the ventricular end are not far from one another. That leads to the assumption that the site of origin of ventricular activation during exclusive anterograde conduction over the accessory AV pathway and of the origin of atrial activation during exclusive retrograde conduction over the accessory pathway are located close together. The site of origin of the QRS during antidromic CMT and the site of origin of the P wave during orthodromic CMT should therefore "match". The findings shown in fig. 2 clearly indicate a large distance between the origin of ventricular activation and atrial activation during antidromic and orthodromic CMT respectively. Even if the accessory AV pathway would cross the AV ring obliguely one would not expect the major differences shown in fig. 2.

During atrial fibrillation rapid impulse formation is present in both atria. That allows the beginning of ventricular activation at different sites when multiple accessory AV pathways having anterograde conduction properties are present. To recognize anterograde AV conduction over more than one accessory AV pathway during atrial fibrillation sufficient spatial separation between the ventricular insertion of the accessory pathways should be present. Only under those circumstances the differences in patterns of ventricular activation can be recognized. It should be realized that AV conduction over the AV node-His pathway may result in fusion complexes falsely suggesting the presence of more than one accessory AV pathway.

A sudden change from an antidromic to an orthodromic CMT or vice versa can only be explained by the presence of two accessory pathways. By definition the orthodromic CMT uses an accessory AV pathway for V-A conduction. A sudden change to or from an antidromic CMT requires therefore that also the antidromic CMT uses an accessory AV pathway for retrograde conduction.

Similarly, the spontaneous change from one type of antidromic tachycardia into another can only be explained by the presence of at least 2 accessory pathways (see fig. 5,6).

We (8) have previously reported on the use of antiarrhythmic drugs that prolong the anterograde refractory period of the accessory AV pathway to diagnose the presence of more than one accessory AV pathway. Requirements to expose the presence of more than one accessory pathway by drugs like ajmaline or procainamide include: 1) A difference in duration of the anterograde refractory period of the two accessory AV pathways.: 2) A relatively long anterograde refractory period of at least one of the accessory AV pathways (9,10); 3) The recording of several ECG leads simultaneously to recognize small changes in pre-excitation pattern; 4) Changes should occur in the initial portion of the QRS complex (the delta wave). Antiarrhythmic drugs may induce bundle branch block and thereby change the QRS after the delta wave. Those changes should not be interpreted as pointing to the presence of more than one accessory AV pathway.

Limitations of the study

The findings reported were obtained during a retrospective analysis in patients shown to have more than one accessory AV pathway during electrophysiologic study or intraoperative mapping. The true value of the 12 lead ECG in recognizing the presence of more than one accessory AV pathway can only be established by performing a prospective study.

REFERENCES

1. Colavita PG, Packer DL, Pressley JC, et al: Frequency, diagnosis and clinical characteristics of patients with multiple accessory atrio-ventricular pathways. Am J Cardiol 1987; 59: 601-606.

2. Prystowsky EN: Diagnosis and management of the preexcitation syndromes. In: Current problems in Cardiology 1988; 13: 277-310.

3. Wellens HJJ, Brugada P: Value of programmed stimulation of the heart in patients with the Wolff-Parkinson-White syndrome. In: Tachycardias, Josephson ME and Wellens HJJ (Eds); Philadelphia, Lea and Febiger, 1984; 199-221.

4. Gallagher JJ, Pritchett ELC, Sealy WC, Kasell J, Wallace AG: The pre-excitation syndromes. Prog Cardiovasc Dis 1978; 20: 285-327.

5. Milstein S, Sharma AD, Guiraudon GM, Klein GJ: An algorithm for the electrocardiographic localization of accessory pathways in the Wolff-Parkinson-White syndrome. PACE 1987; 10: 555-563.

6. Lemery R, Hammill SC, Wood DL et al: Value of the resting 12 lead electrocardiogram and vectorcardiogram for locating the accessory pathway in patients with the Wolff-Pakrinson-White syndrome. Brit Heart J 1987; 58: 324-332.

7. Lindsay BD, Crossen KJ, Cain ME: Concordance of distinguishing electrocardiographic features during sinus rhythm with the locatgion of accessory pathways in the Wolff-Parkinson-White syndrome. Am J Cardiol 1987; 59: 1093-1102.

8. Wellens HJJ, Brugada P, Penn OC: The management of pre-excitation syndromes. JAMA 1987; 257 no. 17: 2325-2333.

9. Wellens HJJ, Bär FW, Gorgels AP, Vanagt EJ: Use of ajmaline in identifying patients with the Wolff-Parkinson-White syndrome and a short refractory period of their accessory pathway. Am J Cardiol 1980; 45: 130-133.

10. Wellens HJJ, Braat SH, Brugada P, Gorgels AP, Bär FW: Use of procainamide in patients with the Wolff-Parkinson-White syndrome to disclose a short refractory period of the accessory pathway. Am J Cardiol 1982; 50: 921-925.

Chapter VI

Clinical and electrophysiological characteristics of patients with multiple accessory pathways

Jacob Atié
Pedro Brugada
Joep L.R.M. Smeets
Fernando E.S. Cruz
Ayrton Peres
Mauricio Duque
Marie P. Roukens
Hein J.J. Wellens

Clinical and electrophysiological characteristics of patients with multiple accessory pathways

SUMMARY

Multiple accessory atrioventricular pathways were documented in 18 of 345 patients (5,2%) with Wolff-Parkinson-White syndrome undergoing detailed electrophysiologic evaluation. Multiple accessory pathways were identified during intraoperative mapping or electrophysiologic study by: 1) Different patterns of preexcitation during antidromic circus movement tachycardia, atrial fibrillation or atrial pacing (12 patients); 2) Different patterns of retrograde atrial activation during right ventricular pacing or orthodromic circus movement tachycardia (10 patients); 3) Antidromic circus movement tachycardia using a second accessory pathway as the retrograde limb of the tachycardia (5 patients); 4) A spontaneous or induced change from antidromic circus movement tachycardia to orthodromic circus movement tachycardia or vice-versa, using different accessory pathways (4 patients); 5) Change in pre-excitation pattern following administration of drugs (4 patients). Fourteen patients (78%) had 2 accessory pathways and 4 patients (22%) had 3 accessory pathways. Right free wall and left posteroseptal accessory pathways were most commonly associated. In 12 out of 18 patients (67%) with multiple accessory pathways an antidromic circus movement tachycardia could be initiated. This was possible in only 24/325 patients (7.6%) with one accessory pathway. Nine patients (50%) had one or more episodes of syncope and 2 patients (11%) had ventricular fibrillation, compared to an incidence of 12% and 2% in patients with only one accessory pathway. Ten patients had surgery, 3 patients (30%) had to be reoperated, compared to 9/115 pts (8%) with only one accessory pathway. Conclusions: 1) There is a wide spectrum of findings during spontaneous or induced arrhythmias pointing to the likelihood of more than one accessory pathway in patients with multiple pathways. 2) Patients with multiple accessory pathways have more frequently syncope, antidromic tachycardia and ventricular fibrillation than patients with a single accessory pathway. 3) Reoperation rate is higher in pts with multiple accessory pathways.

Presented at the European Society of Cardiology. Eur Heart J 1989; 10:381
Submitted for publication

INTRODUCTION

The existence of multiple accessory atrioventricular pathways in a single patient was first demonstrated by Matter et al [1] in 1964, from the electrocardiographic observation of alternating types A and B preexcitation in the same patient. Afterwards multiple accessory atrioventricular pathways have been documented in an increasing number of patients during electrophysiological study and intraoperative mapping (2-7). The reported incidence of multiple accessory pathways ranges between 3.7 and 13% in different studies (7-9).

One of the reasons for failure of surgical dissection in patients with Wolff-Parkinson-White syndrome is the presence of multiple accessory pathways that were not recognized during preoperative electrophysiological study (3,9).

This report reviews our experience and the clinical and electrophysiological characteristics of patients with multiple accessory pathways.

PATIENTS AND METHODS

The 18 patients in this study were selected from 345 patients seen at our institution between 1979 and august 1989, for evaluation and treatment of various pre-excitation syndromes.

The localization of the accessory pathway(s) was based on findings from endocardial catheter mapping during electrophysiologic study, and on information from intraoperative mapping in those patients who underwent surgical correction of the accessory pathway(s).

Electrophysiological study

After informed consent an electrophysiological study was performed in the resting, nonsedated state.

Four multipolar electrode catheters were inserted percutaneously and positioned under fluoroscopic guidance in the right atrium, coronary sinus, right ventricular apex, and bundle of His region. Methods of stimulation and recording used at our laboratory and the definitions used have been described in detail [10]. All patients underwent a complete electrophysiologic investigation.

Definitions

Multiple accessory pathways were considered to be present when more than one accessory pathway was found during electrophysiological study or epicardial mapping during surgery.

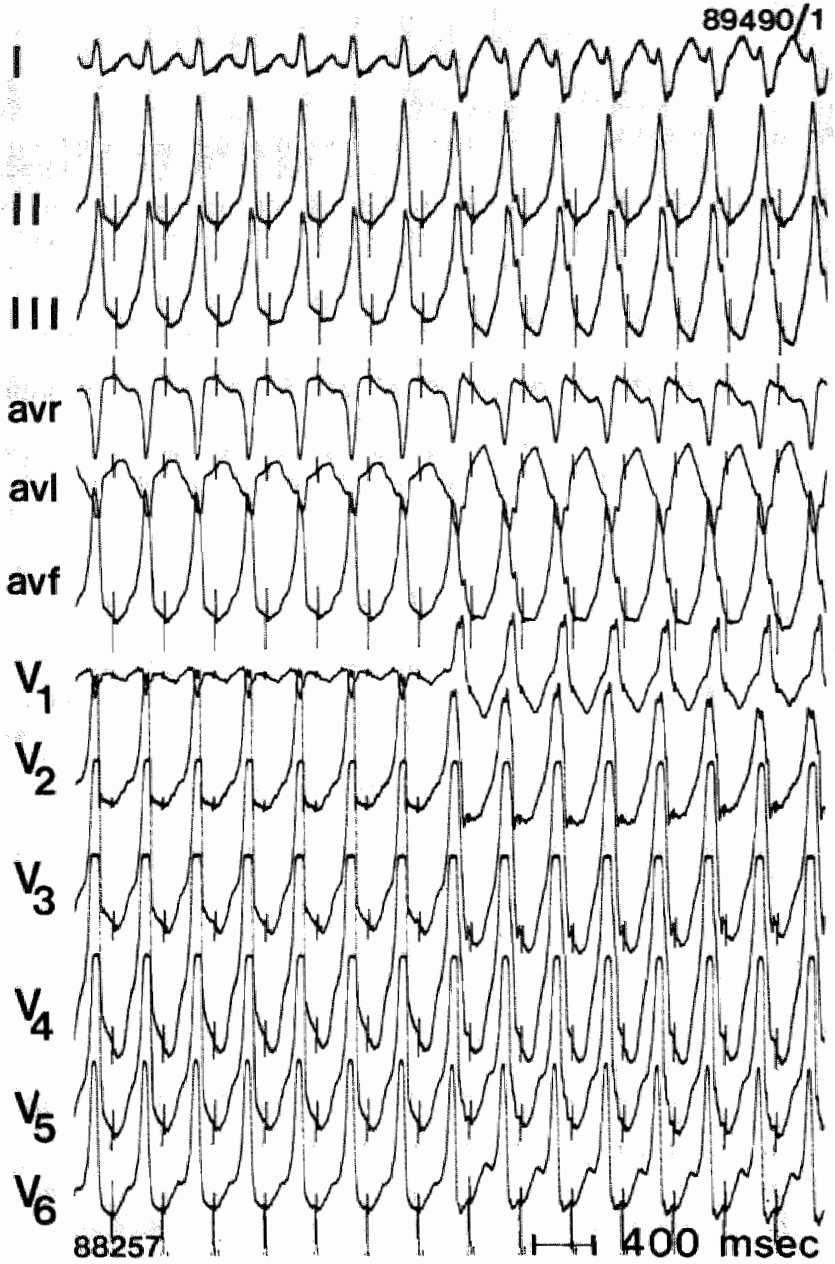

Figure 1. The 12 lead electrocardiogram during atrial pacing in a patient with the Wolff-Parkinson-White syndrome. Two different patterns of pre-excitation, one from A-V conduction over an anteroseptal accessory pathway (left part) and another with A-V conduction over a left lateral accessory pathway (right part) are shown.

Criteria

The following criteria were used to recognize multiple accessory pathways during electrophysiological study:

1. Two or more different patterns of preexcitation during atrial pacing (fig. 1).
2. Two or more different patterns of preexcitation during antidromic circus movement tachycardia (fig. 2). Antidromic tachycardia was defined as a reentrant tachycardia that used anterogradely an accessory atrioventricular pathway and retrogradely the A-V node system or a second accessory pathway. In all patients with antidromic circus movement tachycardia we were able to exclude atrial flutter, atrial tachycardia and dual A-V nodal tachycardia using the accessory pathway as a "bystander".
3. Two or more different patterns of preexcitation during atrial fibrillation (fig. 3).

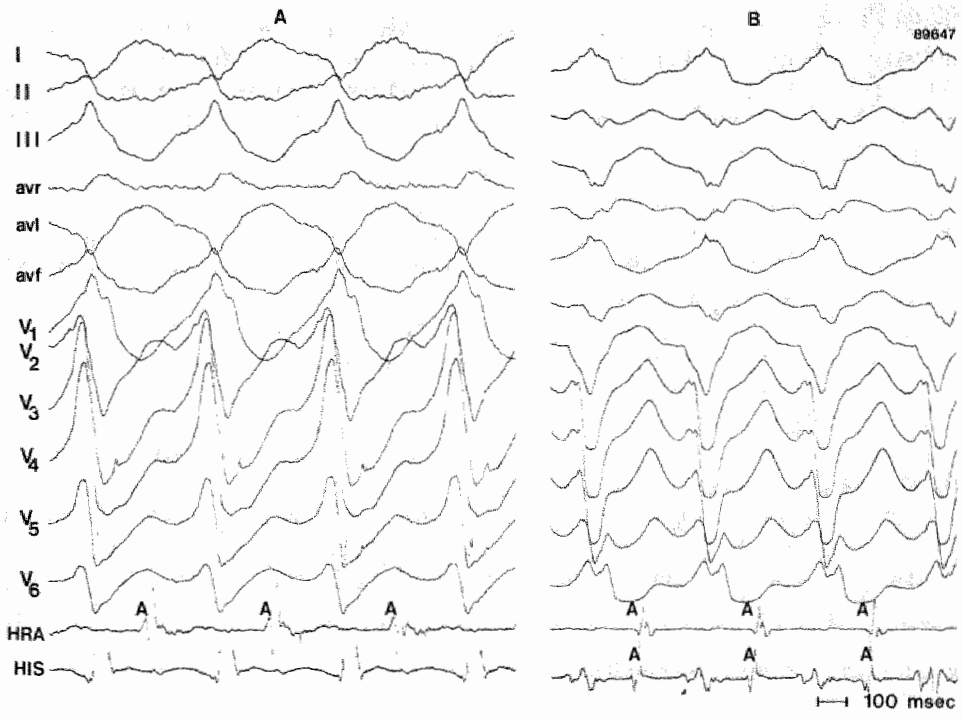

Figure 2. Two types of antidromic circus movement tachycardia in the same patient. Panel A shows an antidromic circus movement tachycardia with anterograde conduction over a left lateral accessory pathway. Panel B an antidromic circus movement tachycardia with anterograde conduction over a right sided accessory pathway. Twelve surface electrocardiographic leads and 2 intracardiac leads from the high right atrium (RA) and bundle of His (HIS).

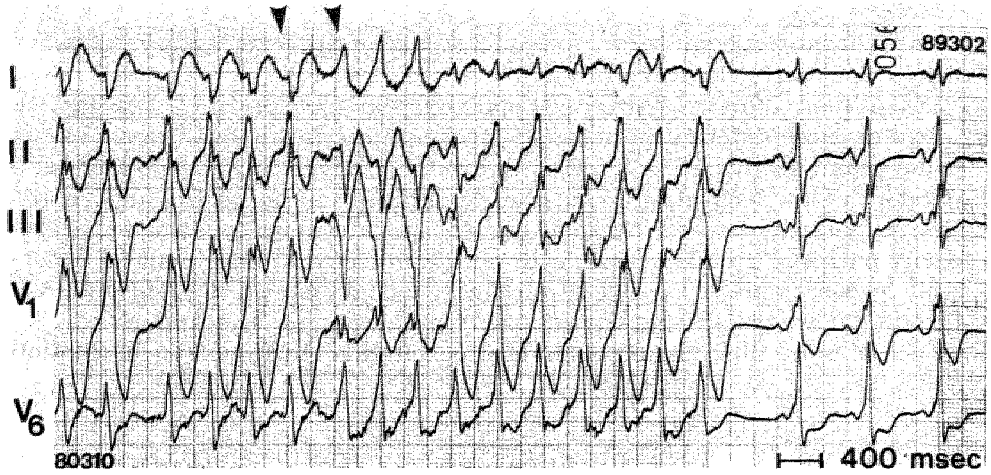

Figure 3. Five simultaneous electrocardiographic leads showing two different patterns of pre-excitation, left lateral and posteroseptal (arrows), during atrial fibrillation. Also fusion complexes resulting from anterograde conduction over both accessory pathways are present. The atrial fibrilation stopped spontaneously and sinus rythm is seen in the right part of the figure.

4. Two or more different patterns of retrograde atrial activation during ventricular pacing, different from that of the AV node and confirmed to be over accessory pathways (fig. 4).
5. Two or more different patterns of retrograde atrial activation during orthodromic circus movement tachycardia over different accessory pathways (fig. 5). Orthodromic tachycardia was defined as a reentrant tachycardia that used the normal AV conduction system as the anterograde limb and an accessory pathway as the retrograde limb of the circuit.
6. A "mismatch" between the site of origin of atrial activation following retrograde activation over the accessory pathway during ventricular pacing or orthodromic tachycardia and the site of earliest ventricular activation during atrial pacing or antidromic tachycardia. Such a finding suggests that different accessory pathways were used in retrograde and anterograde direction (fig. 6).
7. A spontaneous change from an orthodromic circus movement tachycardia to an antidromic circus movement tachycardia, or viceversa (fig. 7). This can only be explained by the presence of two accessory pathways.
8. A change from an orthodromic circus movement tachycardia to antidromic circus movement tachycardia or viceversa after a single atrial or ventricular premature beat. It is impossible to use the same accessory pathway retrogradely and immediately thereafter anterogradely or viceversa.
9. A change from one antidromic tachycardia into another (fig. 8).

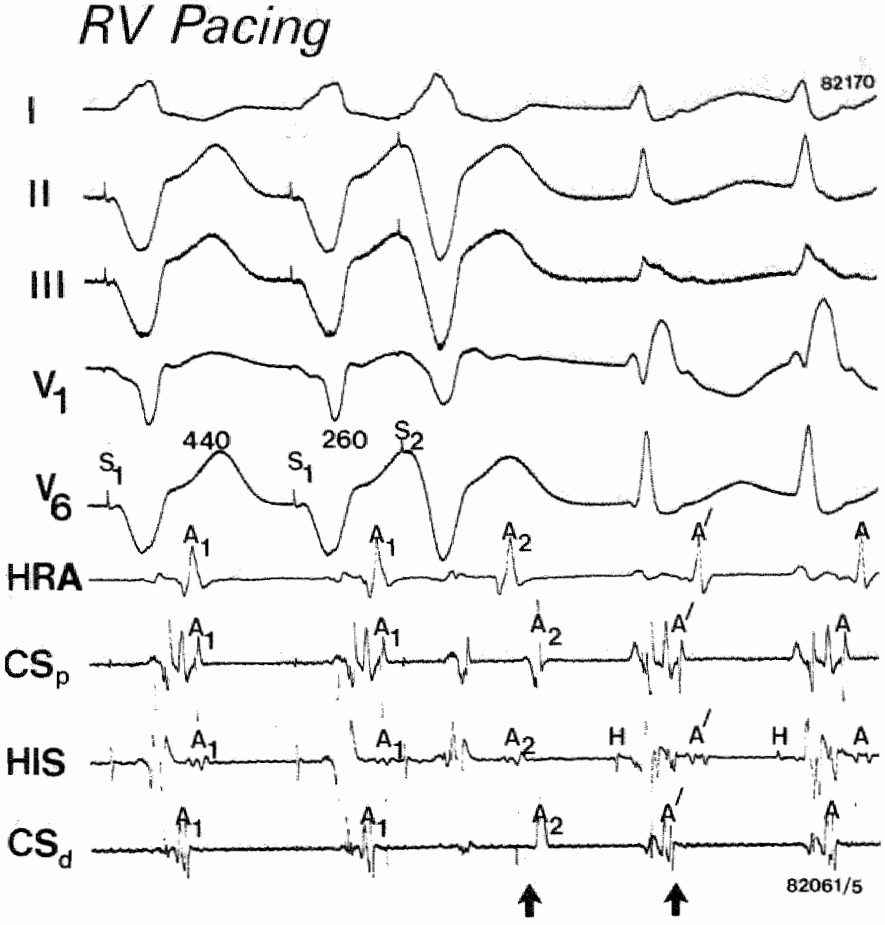

Figure 4. Initiation of orthodromic circus movement tachycardia showing the presence of two retrogradely conducting accessory pathways. Five electrocardiographic leads and four intracardiac leads recording from the high right atrium (HRA), proximal coronary sinus (CSp), bundle of His (HIS) and distal coronary sinus (CSd) are shown. During ventricular pacing with a cycle length of 440 ms, atrial activation occurs almost simultaneously in all intracardiac recordings. After a ventricular premature beat given after 260 ms, the first retrograde atrial activation occurs in the high right atrium by way of a right sided accessory pathway. Thereafter orthodromic circus movement tachycardia starts, with earliest retrograde atrial activation being recorded in the coronary sinus indicating left-sided accessory pathway.

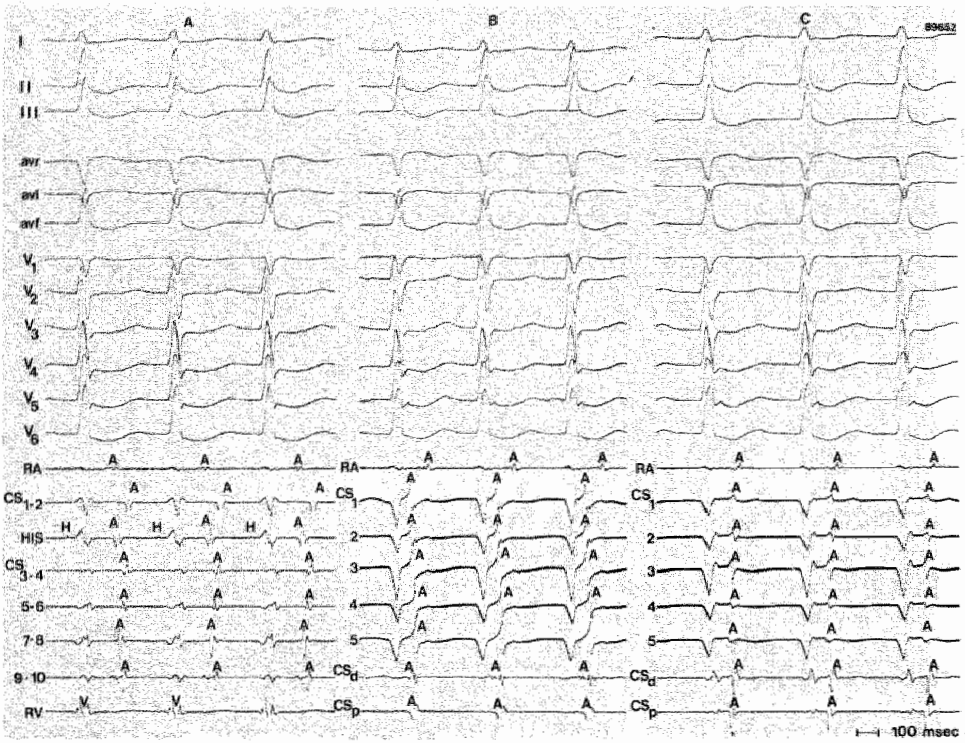

Figure 5. Orthodromic circus movement tachycardia showing retrograde conduction over 2 accessory pathways. In panel A orthodromic circus movement tachycardia is observed, with the onset of retrograde atrial activation occurring in the right atrium (right lateral accessory pathway). In panel B, orthodromic circus movement tachycardia shows earliest atrial activation in the distal (CS_1) coronary sinus (left lateral accessory pathway). In panel C there is almost simultaneous retrograde atrial activation in all recordings (retrograde fusion over both accessory pathways). Apart from the 12 extracardiac leads, intracardiac recordings are shown from the high right atrium (RA), the bundle of His (HIS), the coronary sinus (CS) and the right ventricle (RV). Panel A shows bipolar and panel B and C unipolar recordings from the coronary sinus.

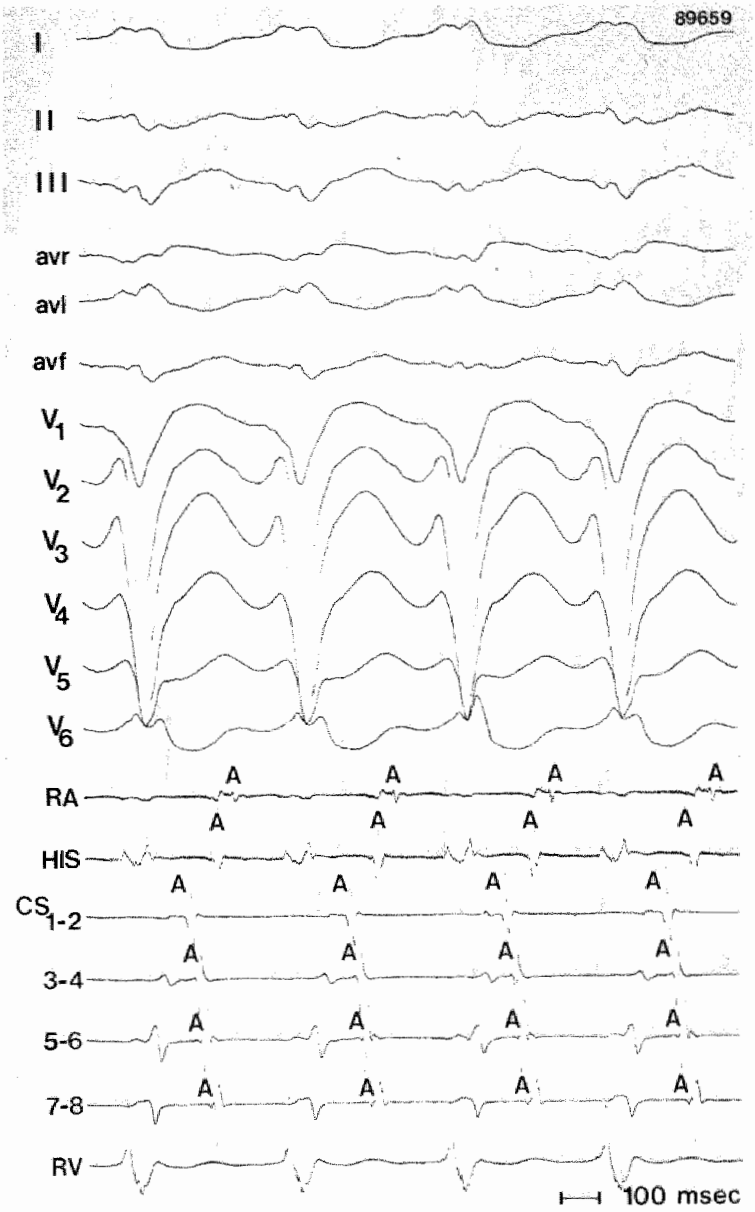

Figure 6. Example of antidromic circus movement tachycardia, using a right sided accessory pathway in the anterograde direction and a left sided accessory pathway in the retrograde direction. As shown, earliest retrograde atrial activation occurs in the distal coronary sinus (CS 1-2). Twelve surface electrocardiographic leads and 7 intracardiac leads are shown, high right atrium (RA), bundle of His (HIS), four bipolar recording from the coronary sinus, from the more distal (CS 1-2) to proximal (CS 7-8) and right ventricle (RV).

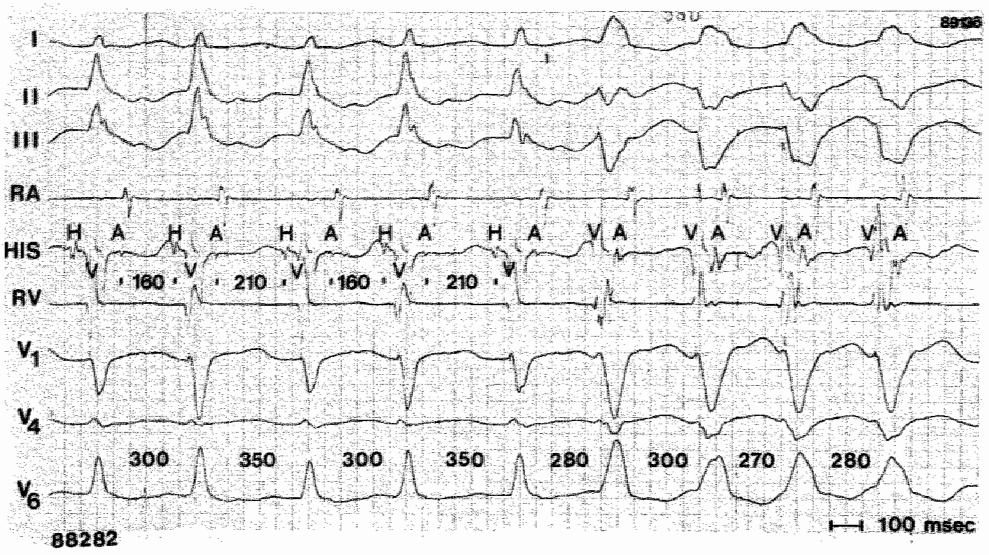

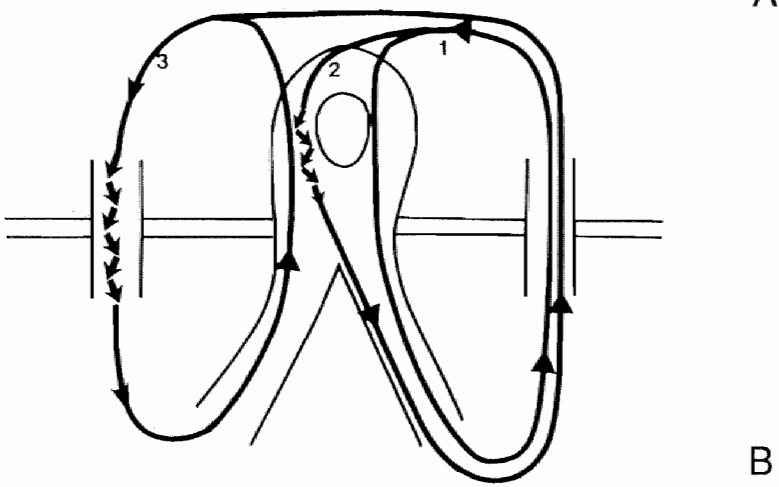

Figure 7. Example of a spontaneous change from orthodromic to antidromic tachycardia. The first 5 QRS complex are from an orthodromic circus movement tachycardia showing cycle length alternation of 50 ms. Alternation is caused by alternating conduction over a fast and a slow A-V nodal pathway. Thereafter, tachycardia changes spontaneously to antidromic circus movement tachycardia using a second atrio-ventricular accessory pathway with long anterograde conduction times. In panel B a schematic representation of the tachycardias is given. Number 1 represents orthodromic tachycardia with anterograde conduction over the fast A-V nodal pathway. Number 2 represents orthodromic tachycardia with anterograde conduction over the slow A-V nodal pathway. In both 1 and 2 the retrograde conduction is over the left sided accessory pathway. Number 3 represents the antidromic tachycardia conducting anterogradely over an right sided accessory pathway with long conduction times.

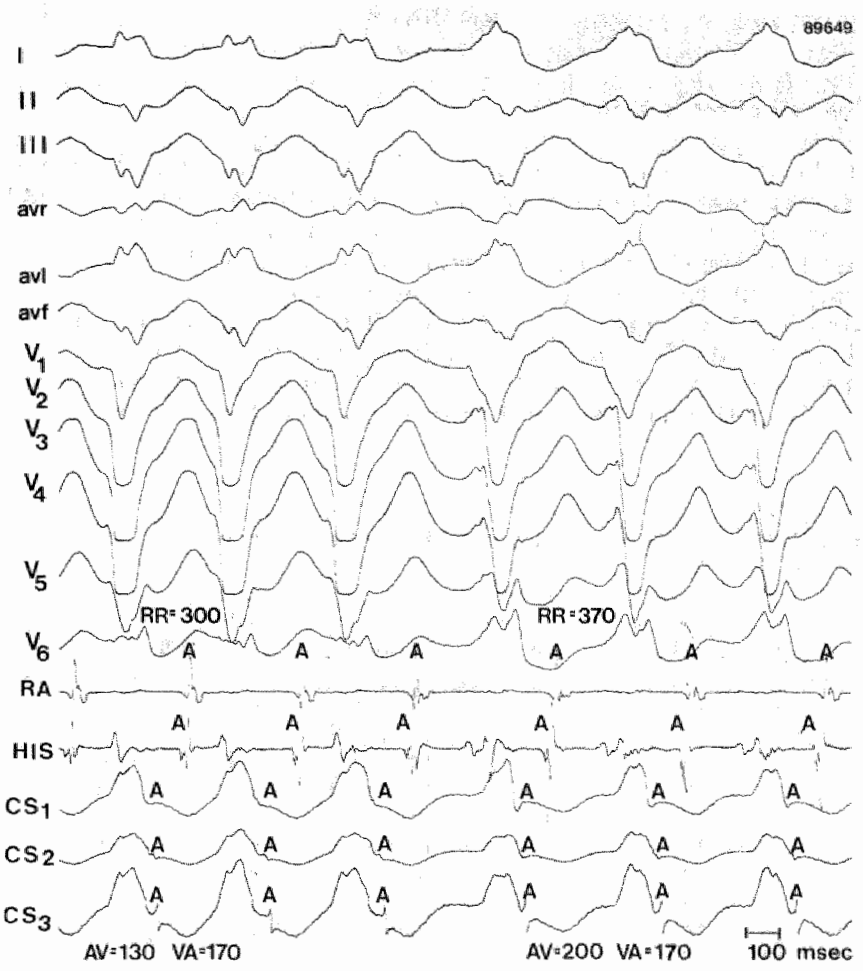

Figure 8. Spontaneous change from one antidromic tachycardia to another. The first three QRS complexes are the result of anterograde conduction over a right posteroseptal pathway. Thereafter a right free wall accessory pathway is used for anterograde conduction. Note that: 1) A left lateral accessory pathway is used for retrograde conduction during both tachycardias and 2) A difference of 70 ms in the cycle length between the 2 tachycardias. The 12 lead electrocardiogram was simultaneous recorded with 5 intracardiac leads.

RESULTS

Clinical Characteristics

Of the 345 patients studied, 18 (5.2%) were found to have multiple accessory pathways. Fourteen patients had 2 pathways and 4 patients had 3 pathways. The clinical data of the 18 patients are listed in table I. The age of the patients ranged from 12 to 56 years (mean 25 ± 8), 14 were male and 4 female. The clinical history revealed that the first episode of an arrhythmia occurred at a mean age of 15 ± 7 years. The mean number of attacks per month in the last 6 month before referred was 5 ± 3. The most common symptom was palpitations (94%), followed by dizziness (66%) and syncope (50%). Nine patients (50%) had their tachycardia induced by exercise.

Table I. Clinical Data of 18 patients with multiple accessory pathways

Pts	Sex	Age	Age at onset of arrhythmia	Frequency of attacks (month)	Symptoms	Exercise induced tachycardia	Clinical arrhythmia
1	M	21	12	6	PL/DZ/SN	yes	A/O
2	F	22	13	1	PL/DZ/SN	yes	A/O/AF
3	M	19	19	5	PL/DZ/SN	yes	A/O/VF
4	F	12	8	2	PL/DZ/SN	yes	A/O
5	M	12	12	1	PL	no	A
6	M	15	13	30	PL/DZ/SN	yes	A
7	M	18	18	1	ASYMPT.	no	NAD
8	M	23	15	1	PL/DZ/SN	yes	A/O
9	M	16	14	1	PL/DZ/SN	yes	A/O/VF
10	F	30	20	5	PL/DZ	yes	AF
11	M	20	10	10	PL/DZ	yes	O/AF
12	F	29	20	0	PL	no	NAD
13	M	39	20	4	PL	no	O
14	M	56	30	2	PL	no	O
15	M	29	12	7	PL/DZ/SN	no	O
16	M	31	15	3	PL/DZ/SN	no	O
17	M	28	19	4	PL/DZ	no	O
18	M	30	15	1	PL	no	O

Abbreviations: PTS= patient number; PL= palpitations; DZ= dizziness; SN= syncope; Asympt= asymptomatic; A= antidromic circus movement tachycardia; O= orthodromic circus movement tachycardia; AF= atrial fibrillation; VF= ventricular fibrillation; NAD = no arrhythmia documented; M= male; F= female.

Thirteen patients (72%) had clinical documentation of orthodromic tachycardia and 8 patients (44%) had a clinically documented episode of antidromic tachycardia. Seven patients (39%) suffered from both orthodromic and antidromic tachycardia. Atrial fibrillation was documented clinically in 3 patients (17%). Two patients (11%) had a history of ventricular fibrillation.

Electrophysiological Characteristics

The location of the accessory pathways is presented in table II. The most common location was left posteroseptal (33%), followed by right lateral (25%). The most frequent association was right lateral with left posteroseptal (5 patients).

Table II. Location of the accessory pathways and types of induced tachycardias

Pt	Localization	Arrhythmias induced
1	AS, LL, RPS	AT/OT/AFT
2	LL, LPS	AT/OT/AF/AFT
3	LL, LPS	AT/OT/AF/AFT/VF
4	RL, LL	AT/OT/AF/AFT
5	RL, LPS	AT/OT/AF
6	LPS, NV	AT
7	RL, NV	AT/OT
8	RPS, LPS	AT/OT/AF
9	RL, PS	AT/OT/AF/VF
10	RL, LL, LPS	AT/OT/AF/AFT
11	LPS, RPS	AT/OT/AF/AFT
12	PS, LPS, RL	AT/OT/AF
13	LPS, PS	OT/AF/AFT
14	LL, LPS	OT/AFT
15	LL, RL	OT/AF/AFT
16	LPS, RL, PS	OT
17	LPS, RL	OT/AF
18	LPS, RL	OT/AF

Abbreviation: AS= anteroseptal; PS= posteroseptal; LL= left lateral; RL= right lateral; LPS= left posteroseptal; RPS= right posteroseptal; NV= nodoventricular; OT= orthodromic circus movement tachycardia; AT= antidromic circus movement tachycardia; AF= atrial fibrillation; AFT= atrial flutter; VF= ventricular fibrillation.

The mean atrial refractory period was 205 ± 24 ms and the mean ventricular refractory period was 198 ± 25 ms. The mean refractory period of the AV node measured was 215 ± 38 ms anterogradely and 220 ± 32 ms retrogradely. It has to be realized that the exact measurement of this values could not be obtained in all patients. The mean anterograde refractory period of the accessory pathway was 232 ± 32 ms, when only the accessory pathway having the shortest refractory period was considered. The atrial, ventricular, and accessory pathways refractory periods are listed in table III.

In 17 patients (94%) orthodromic circus movement tachycardia could be induced and in 12 patients (67%) antidromic circus movement tachycardia. Ability to induced antidromic circus movement tachycardia was significatively higher ($p<0.0001$) in patients with multiple accessory pathways (12/18) as compared to patients (24/327) with a single accessory pathway. In 11/18 patients (61%) both an antidromic and an orthodromic tachycardia could be

Table III. Refractory periods of atrium, ventricle and accessory pathway in the 18 patients studied

Pts	AERP (ms) (PCL)	VERP (ms) (PCL)	AP AERP (ms) (PCL)	AP RERP (ms) (PCL)
1	220 (428)	180 (428)	280 (500)	≤180 (428)
2	190 (600)	210 (428)	260 (500)	≤210 (428)
3	190 (428)	220 (428)	≤190 (500)	240 (428)
4	210 (428)	200 (428)	330 (500)	≤200 (428)
5	200 (428)	200 (428)	230 (500)	NA
6	250 (428)	250 (600)	310 (500)	460 (500)
7	230 (428)	280 (500)	≤230 (428)	NA
8	180 (428)	180 (500)	≤180 (428)	≤180 (428)
9	220 (428)	210 (428)	240 (428)	≤210 (428)
10	200 (428)	200 (500)	≤200 (428)	NA
11	200 (600)	200 (500)	260 (428)	NA
12	190 (428)	160 (428)	270 (428)	≤160 (428)
13	NA	200 (428)	280 (428)	≤200 (428)
14	210 (600)	240 (600)	270 (428)	260 (500)
15	200 (500)	NA	250 (500)	NA
16	210 (428)	190 (428)	250 (428)	≤190 (428)
17	230 (500)	210 (600)	260 (500)	≤210 (600)
18	NA	NA	250 (500)	NA

Abbreviations: AERP = atrial effective refractory period; VERP = ventricular effective refractory period; AP AERP = accessory pathway anterograde effective refractory period; AP RERP = accessory pathway retrograde effective refractory period; NA = not available. PCL = paced cycle length. Only the shortest refractory period is present in this table.

initiated (table II). The mean cycle length of the orthodromic tachycardia was longer than that of the antidromic tachycardia (349 ± 24 ms and 309 ± 31 ms respectively).

Of the 40 accessory pathways documented in our 18 patients, 28 were able to conduct both in anterograde and in retrograde direction. Twelve conducted in one direction only, 6 anterogradely and 6 retrogradely. In the 12 patients having more than one accessory pathway able to conduct anterogradely, 2 delta wave morphologies were seen during atrial flutter, atrial fibrillation (fig. 3) or atrial pacing (fig. 1). Two different patterns of preexcitation during antidromic circus movement tachycardia was observed in 7 patients (fig. 2).

In two patients, with retrograde conduction over an accessory pathway during orthodromic circus movement tachycardia, evidence of a second accessory pathway conducting anterogradely was obtained by observing fusion QRS complexes during tachycardia (fig. 9).

In one patient with antidromic circus movement tachycardia, using a second accessory pathway for retrograde conduction, evidence of a third accessory pathway was obtained because of a sudden change in the QRS morphology during antidromic tachycardia without changes in the retrograde atrial activation sequence (fig. 8).

In one patient the presence of two accessory pathways conducting anterogradely could only be demonstrated after the infusion of isoproterenol.

Clinical Outcome

Antiarrhythmic drug treatment was prescribed in 8 patients and surgical ablation attempted in the remaining 9. One patient is asymptomatic without treatment. Because of a recurrence of preexcitation and tachycardias, 3 patients had to be reoperated, two during the same hospitalization and one a few months later. Two of the 3 patients had a third accessory pathway that had not been diagnosed neither during the first pre-operative electrophysiologic study nor during the first surgery.

No patient died during or after operation.

accessory pathway. Also, a septally located accessory pathway can be missed because retrograde conduction over the AV node is assumed. Other reasons to fail to recognize an accessory pathway are its electrophysiologic properties. If the anterograde or retrograde refractory period is longer than the refractory period of the other pathway, conduction may not be observed under normal circumstances.

In conclusion, patients with multiple accessory pathways have a higher incidence of syncope and ventricular fibrillation. There are several findings both during the spontaneously occurring and induced tachycardias that help in recognition the presence of more than one accessory pathway. The incidence of failure of surgical treatment is higher than in patients with a single accessory pathway.

REFERENCES

1. Matter BJ, Hayes WL. Wolff-Parkinson-White syndrome, report of a case with both type A and B preexcitation. Am J Cardiol 1964; 13: 284-286.

2. Portillo B, Portillo-Leon N, Zaman L, Castelyanos A. Quintuple pathways participating in three distinct types of atrioventricular reciprocating tachycardia in a patient with Wolff-Parkinson-White syndrome. Am J Cardiol 1982; 50: 347-352.

3. Sealy WC, Gallagher JJ. Surgical problems with multiple accessory pathways of atrioventricular conduction. J Thorac Cardiovasc Surg 1981;81: 707-712.

4. Morady F, Scheinman ZMM, DiCarlo LA, Winston SA, Davis JC, Baerman JM, Krol RB, Crevey BJ. Coexistent posteroseptal and right-sided atrioventricular accessory tracts. J Am Coll Cardiol 1985; 5: 540-646.

5. Heddle WF, Brugada P, Wellens HJJ. Multiple circus movement tachycardia with multiple accessory pathways. J Am Coll Cardiol 1984; 1: 168-175.

6. Cinca J, Valle V, Gutierrez L, Figueras J, Ruiz J. Reciprocating tachycardia using bilateral accessory pathways: electrophysiological and clinical implications. Circulation 1980; 62: 657-61.

7. Gallagher JJ, Sealy WC, Kasel J, Wallace AG. Multiple accessory pathways in patients with the pre-excitation syndrome. Circulation 1976; 54: 571-91.

8. Colavita PG, Packer DL, Pressley JC, Ellenbogen KA, O'Callaghan WG, Gilbert MR, German LD. Frequency, diagnosis and clinical characteristics of patients with multiple accessory atrioventricular pathways. Am J Cardiol 1987; 59: 601-606.

9. Iwa T, Kawasuji M, Misaki T, Iwase T, Magara T. Localization and interruption of acessory conduction pathway in the Wolff-Parkinson-White syndrome. J Thorac Cardiovasc Surg 1980; 80: 271- 279.

10. Wellens HJJ, Durrer D. The role of an accessory atrioventricular pathway in reciprocal tachycardia. Observation in patients with and without Wolff-Parkinson-White syndrome. Circulation 1975; 52: 58-64.

11. Benditt DG, Pritchet ELC, Gallagher JJ. Spectrum of regular tachycardias with wide QRS complexes in patients with accessory atrioventricular pathways. Am J Cardiol 1978; 42: 826-838.

12. Bardy GH, Packer DL, German LD, Gallagher JJ. Preexcited reciprocating tachycardia in patients with Wolff-Parkinson-White syndrome: incidence and mechanisms. Circulation 1984; 70: 377-391.

13. Klein GJ, Bashore TM, Sellers TD, Pritchet ELC, Smith WM, Gallagher JJ. Ventricular fibrillation in the Wolff-Parkinson-White syndrome. N Engl J Med 1979; 301: 1080-1085.

14. Torner PM, on behalf of the European Registry on Sudden Death in the Wolff-Parkinson-White syndrome. Ventricular fibrillation in the Wolff-Parkinson-White syndrome. PACE 1988; 11: 46 (Abstr)

15. Gallagher JJ, Pritchet ELC, Sealy WC, Kasell J, Wallace AG. The preexcitation syndromes. Prog Cardiovasc Dis 1978; 20: 285-327.

Chapter VII

Surgical treatment of multiple accessory pathways in the Wolff-Parkinson-White syndrome

Jacob Atié
Pedro Brugada
Joep L.R.M. Smeets
Fernando E.S. Cruz
Olaf C.K.M. Penn MD
Hein J.J. Wellens

Surgical treatment of multiple accessory pathways in the Wolff-Parkinson-White syndrome

SUMMARY

Eight out of 134 patients who underwent surgery for the Wolff-Parkinson-White syndrome had multiple accessory pathways. Four were male and 4 female, the mean age was 23 ± 9 years (12-61). Six patients had 2 accessory pathways and 2 patients 3. A complete preoperative electrophysiological study was performed in all patients. Surgical dissection of the accessory pathways was done using an epicardial approach with the normothermic beating heart followed by cryoablation in 6 patients and using an endocardial approach with cardiopulmonary bypass and cross-clamping of the aorta with cold cardioplegia in 2 patients. Three patients (37%) had to be reoperated because of a recurrence of preexcitation or tachycardia. The incidence of reoperation in this group of patients was significantly higher as compared to 126 operated patients with a single accessory pathway. In this last group only 9 patients (7%) had to be reoperated. Two patients with multiple accessory pathways that required repeat surgery had 3 accessory pathways, and the third accessory pathway was not diagnosed during the preoperative electrophysiological study nor during epicardial mapping. All the 8 patients had 2 accessory pathway diagnosed in the preoperative study. We conclude that patients with multiple accessory pathways can be successfully operated on, but they frequently require reoperation when the diagnosis of the second or third pathway cannot be made during the preoperative electrophysiological study.

Submitted for publication

INTRODUCTION

In 1967, during an epicardial mapping study, Durrer demonstrated ventricular preexcitation in a patient with a right-sided atrio-ventricular accessory (1). In the same year, Burchell et al (2) tried to surgically interrupt conduction over an atrioventricular accessory pathway in a patient with the Wolff-Parkinson-White syndrome undergoing surgical correction of an atrial septal defect. Successful surgical interruption of an atrioventricular accessory pathway was achieved in 1968 by Sealy and coworkers (3). Since that time, the endocardial approach for division of accessory pathways has undergone further refinement with excellent results (4-8). In 1984, Guiraudon et al (9) reported a closed heart approach for interruption of left free wall accessory pathways. Cryoablation of the A-V junction at the site of the atrioventricular accessory pathway was thereafter included in the procedure to ensure accessory pathway interruption (10). Most of the patients submitted to surgery have a single accessory pathway (7,11-14). However, all series reported on some patients having multiple accessory pathways. In those series the incidence of multiple accessory pathways varies from 3 to 20%. However, there are few reports in the literature confined to surgery of patients with multiple accessory pathways in the Wolff-Parkinson-White syndrome (13,15).

The purpose of this report is to describe our surgical experience in patients with multiple accessory pathways.

PATIENTS AND METHODS

Patients

One hundred and thirty four patients underwent surgical ablation of their accessory pathway at our institution from 1986 to august 1989. Eight of them had multiple accessory pathways.

Methods

Electrophysiologic study

After informed consent all patients underwent a complete pre operative electrophysiological study in the nonsedated state. Multiple electrode catheters were used to record and pace from the right atrium, the left atrium via the coronary sinus, and the right ventricle. A bipolar catheter was placed across the tricuspid valve to record a His bundle electrogram. Our techniques and protocols during an electrophysiologic study have been reported previously (16).

Surgery

The heart was exposed via a median sternotomy in all patients. Intraoperative epicardial mapping using a 21 electrode belt placed over the atrioventricular annulus was performed during sinus rhythm, atrial pacing, ventricular pacing and orthodromic circus movement tachycardia (fig. 1). Fixed left atrial, right atrial and ventricular epicardial electrodes were used to record and pace before and after dissection of the accessory pathway(s).

Accessory pathway ablation was carried out using an epicardial approach in the normothermic beating heart with or without cardiopulmonary bypass, or by an endocardial approach with cardiopulmonary bypass and cross-clamping of the aorta associated with cold cardioplegia (6), depending upon the location of the accessory pathway (10).

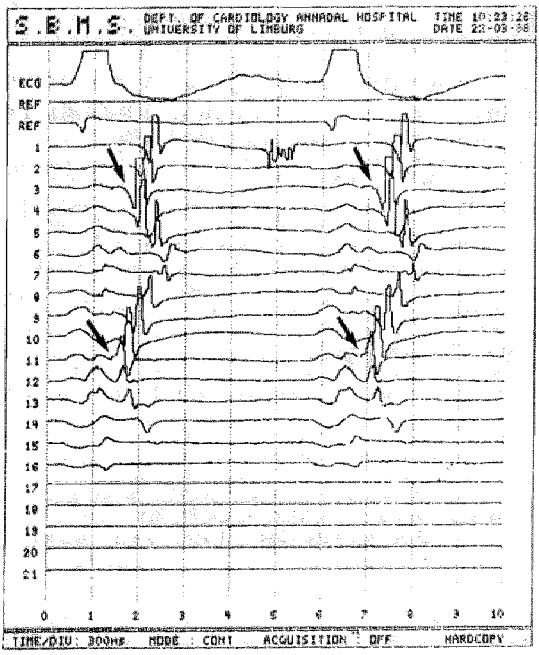

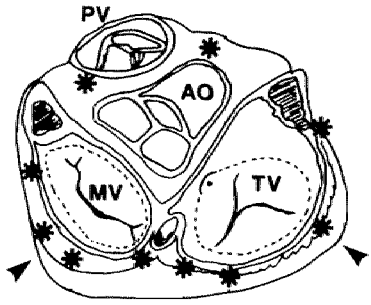

Figure 1. In the left panel, epicardial mapping during surgery is shown. The band with multiple electrodes has been located over the atrioventricular groove at the atrial level. During orthodromic circus movement tachycardia two different patterns of atrial activation are present simultaneously. Earliest atrial activation is recorded on electrodes 3 and 11 (arrows).
In the right panel a schematic cross-section of the ventricles at the level of the atrioventricular ring is shown. The arrows show the location of the accessory pathways where electrodes 3 and 11 were located. Abbreviation: MV = mitral valve; TV = tricuspid valve; Ao = aortic valve; PV = pulmonary valve.

RESULTS

From the 18 patients with multiple accessory pathways diagnosed at electrophysiological study, 8 patients underwent surgery. Six patients had 2 and 2 patients 3 accessory pathways. The third accessory pathway was diagnosed in the post operative electrophysiological study. All 8 patients had 2 accessory pathways diagnosed during the preoperative electrophysiological study.

The clinical data of the 8 patients are shown in table I. The mean age was 23 ± 9 years (range 13-61). There were 4 male and 4 female.

All patients had several episodes of tachycardia before surgery, and 4 patients had a history of syncopal episodes.

Table I. Clinical findings of 8 patients operated upon with multiple accessory pathways

Patient	Sex	Age	Fp	Clinical Arrhythmia	Syncope
1.	M	21	6	ORT/ANT	+
2.	F	23	3	ORT/ANT/VF	+
3.	F	16	5	ORT/AF	+
4.	M	28	4	ORT	-
5.	F	15	2	ORT/ANT	-
6.	M	13	2	ORT/ANT	+
7.	M	61	4	ORT/AF	-
8.	F	14	1	ORT	-

Abbreviations: AF= atrial fibrillation; ANT= antidromic circus movement tachycardia; FP= frequency of attacks of rapid palpitations a month; ORT= orthodromic circus movement tachycardia; VF= ventricular fibrillation; (+) = present; (-) = absent.

Electrophysiological study

The location of the accessory pathways as diagnosed during the electrophysiological study, and the electrophysiological properties of these pathways are shown in table II. The diagnosis of two accessory pathways was made by: 1) More than one sequence of atrial activation indicating retrograde conduction over different accessory pathways during ventricular pacing and/or orthodromic circus movement tachycardia (fig. 2), 2) More than one pattern of ventricular preexcitation during atrial pacing and/or antidromic circus movement tachycardia (fig. 3,4), 3) Atrial fibrillation showing more than one pattern of ventricular preexcitation (fig. 5). In one patient, the presence of a second accessory pathway was exposed after the infusion of isoproterenol.

Table II. Location and electrophysiological properties of the accessory pathways

Patient	Location	RAERP	VERP	APAERP	APAERP
1	RL	190	200	≤ 190	≤ 200
	RPS	250	NA		
	LL *	200	210	330	280
2	RL	250	250	≤ 250	NA
	LL	NA	NA		
	LPS *	NA	210	320	270
3	LPS	200	200	260	NA
	RPS **	NA	NA		
4	LL	230	190	≤ 230	220
	LPS				
5	RL	200	210	240	≤ 210
	LL				
6	LL	220	180	280	≤ 180
	RL				
7	LL	200	210	240	≤ 210
	RPS				
8	LL	220	200	≤ 220	NA
	RPS				

* = diagnosis during post-operative electrophysiologic study; ** = recurrence after first surgery. Abbreviations: RAERP= right atrial effective refractory period; VERP= ventricle effective refractory period; APAERP= accessory pathway anterograde effective refractory period; APRERP= accessory pathway retrograde effective refractory period; LL= left lateral; RL= right lateral; LPS= left posteroseptal; RPS= right posteroseptal; NA= not available. All values in ms.

The isoproterenol was given to the patient because during the study only non-sustained orthodromic circus movement tachycardia occurred because of retrograde block in the accessory pathway. In none of our 8 patients 3 accessory pathways were diagnosed during the electrophysiological study.

Surgery

The surgical technique followed in our 8 patients is shown in table III. In six patients an epicardial approach with a normothermic beating heart followed by cryoablation was used, in 2 patients an endocardial approach was used to divide the accessory pathway. One patient had both epicardial and endocardial procedure.

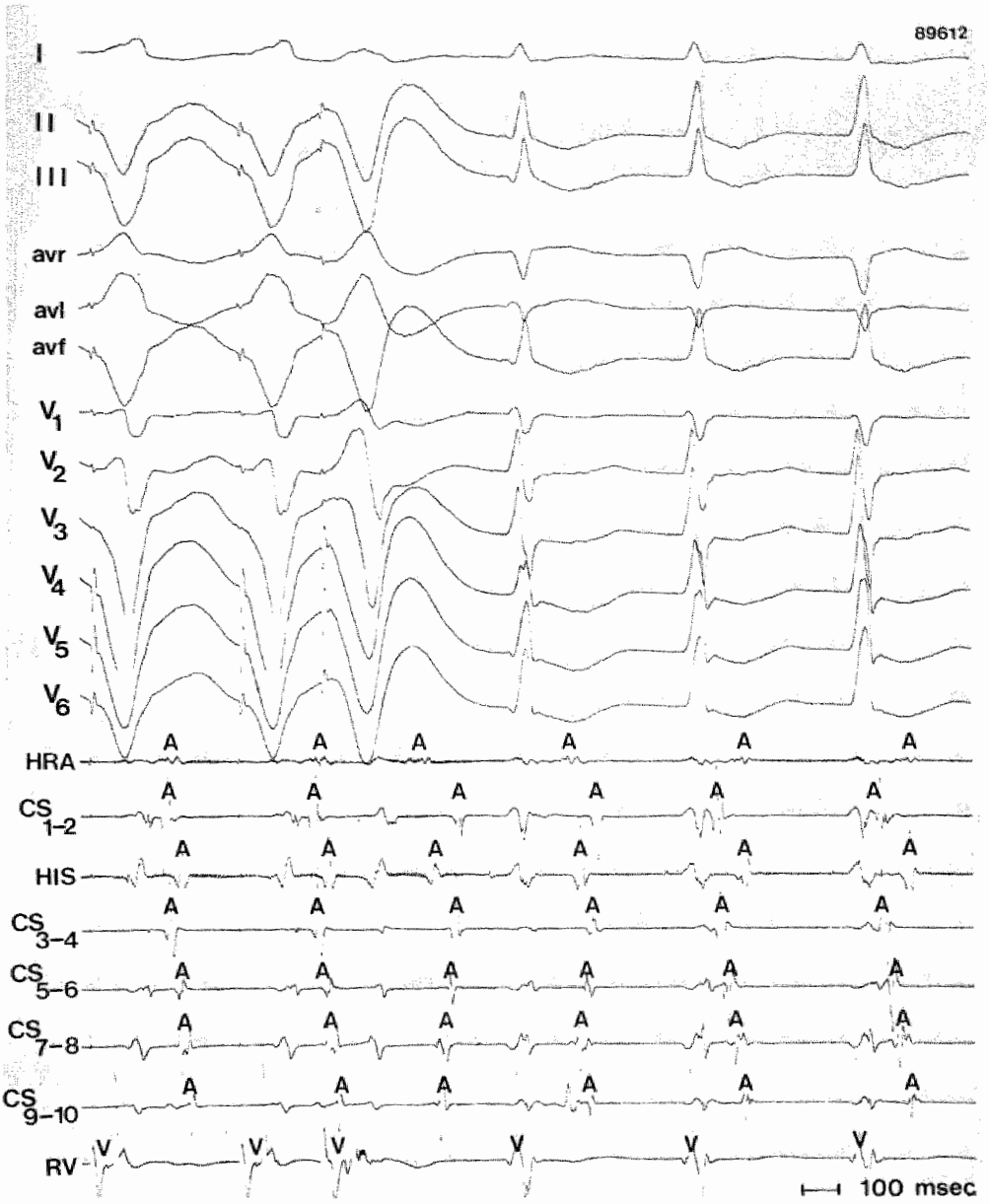

Figure 2. Twelve lead electrocardiogram and intracardiac electrograms from the high right atrium (RA), bundle of His (His), 5 bipolar electrograms from the coronary sinus and the right ventricle (RV) are shown in a patient with 2 accessory pathways. During ventricular pacing with a cycle length of 400 ms atrial activation starts almost simultaneously from the right atrium and the distal coronary sinus. Right atrial activation occurs first following a ventricular premature beat given after an interval of 200 ms. Orthodromic circus movement tachycardia is initiated showing that the sequence of retrograde atrial activation changes after the first beat from high right atrium to distal coronary sinus.

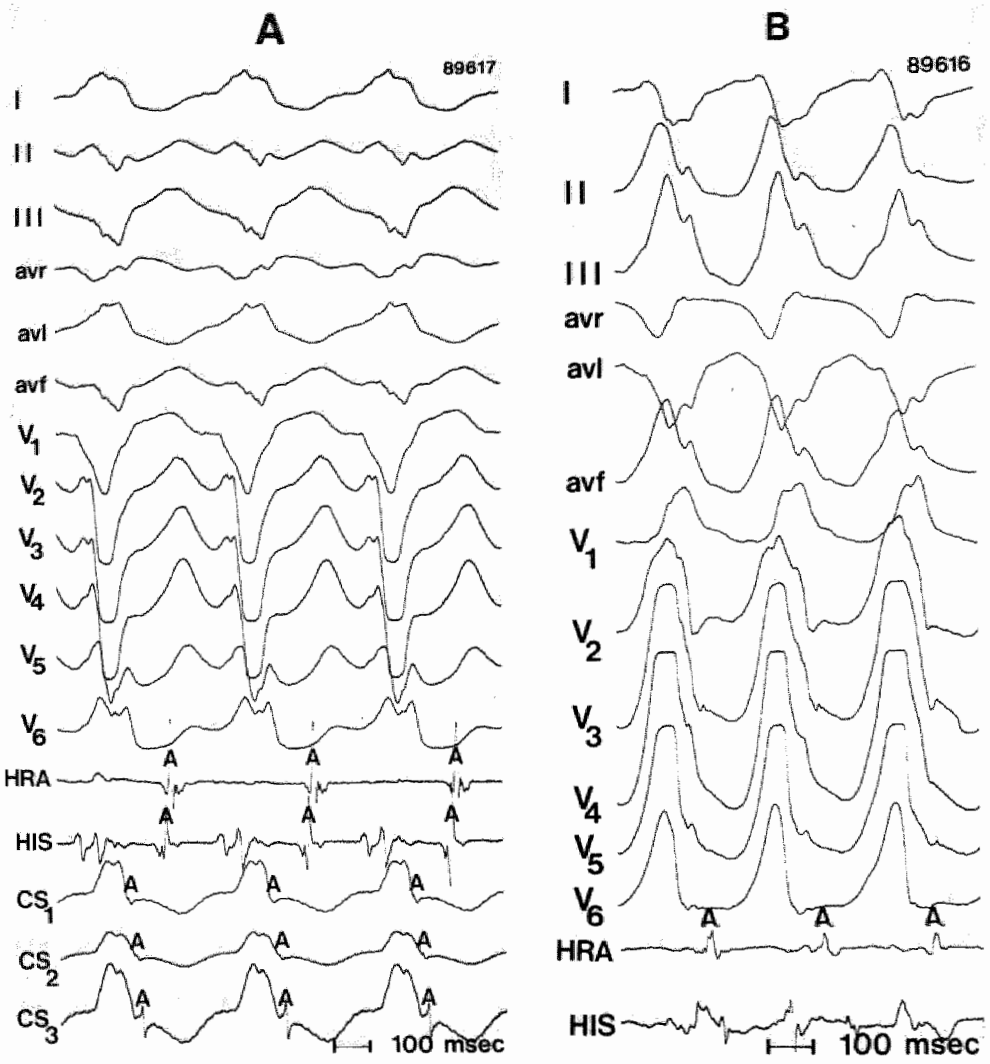

Figure 3. Panel A shows antidromic circus movement tachycardia using for anterograde conduction a right-sided accessory pathway and for retrograde atrial activation a left-sided accessory pathway (starting in the distal coronary sinus lead). In panel B, antidromic circus movement tachycardia using anterogradely the left sided accessory pathway is shown in the same patient. Simultaneous recordings of the 12 lead electrocardiogram and intracardiac electrograms from the high right atrium (RA), bundle of His (His) and 3 unipolar electrograms from the coronary sinus are shown

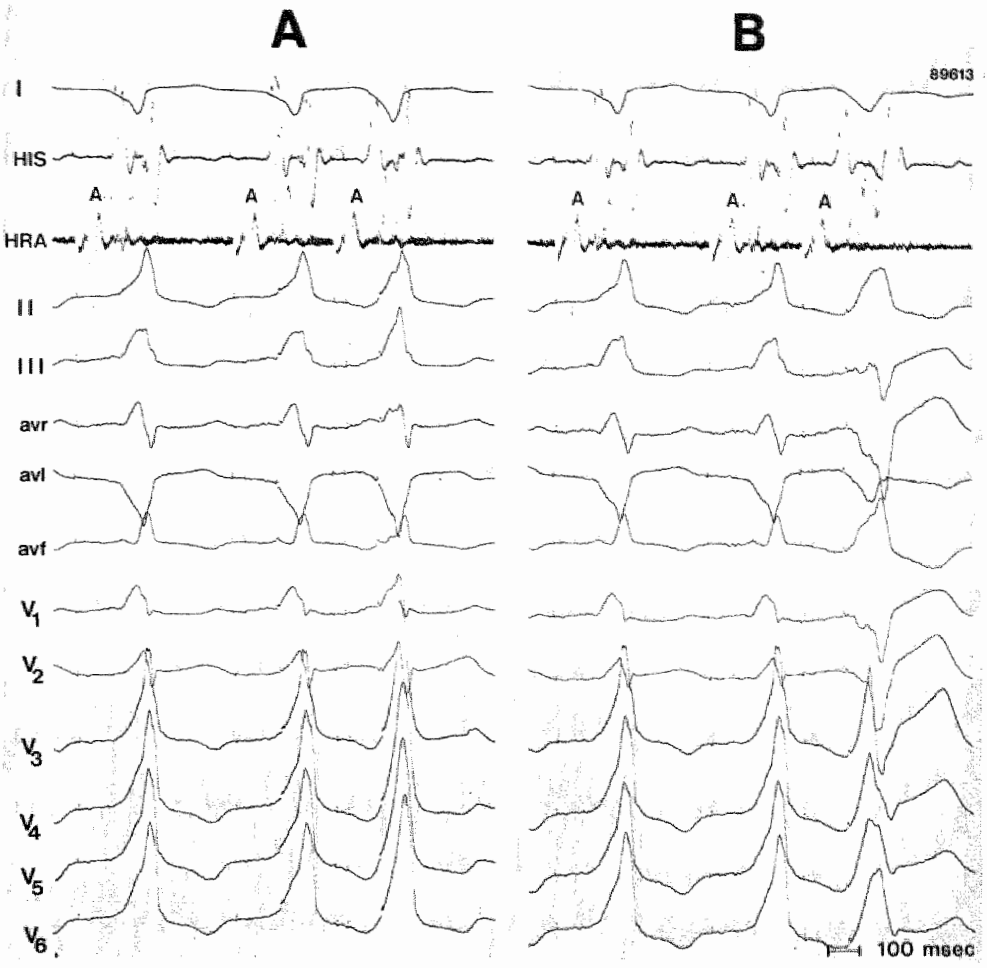

Figure 4. Atrial pacing showing anterograde conduction over two different accessory pathways in the same patient. During atrial pacing with a cycle length of 500 ms the QRS complex shows maximal pre-excitation with anterograde conduction over a left-sided accessory pathway. In panel A the same pre-excitation pattern is observed following anterograde conduction of an atrial premature beat given after an interval of 300 ms. In panel B a different pattern of pre-excitation occurs following an atrial premature beat given after an interval of 290 ms. The effective refractory period of the left sided accessory pathway was 290 ms. Therefore, a premature beat with intervals of 290 ms or less, exclusive conduction over the right-sided accessory pathway was observed.

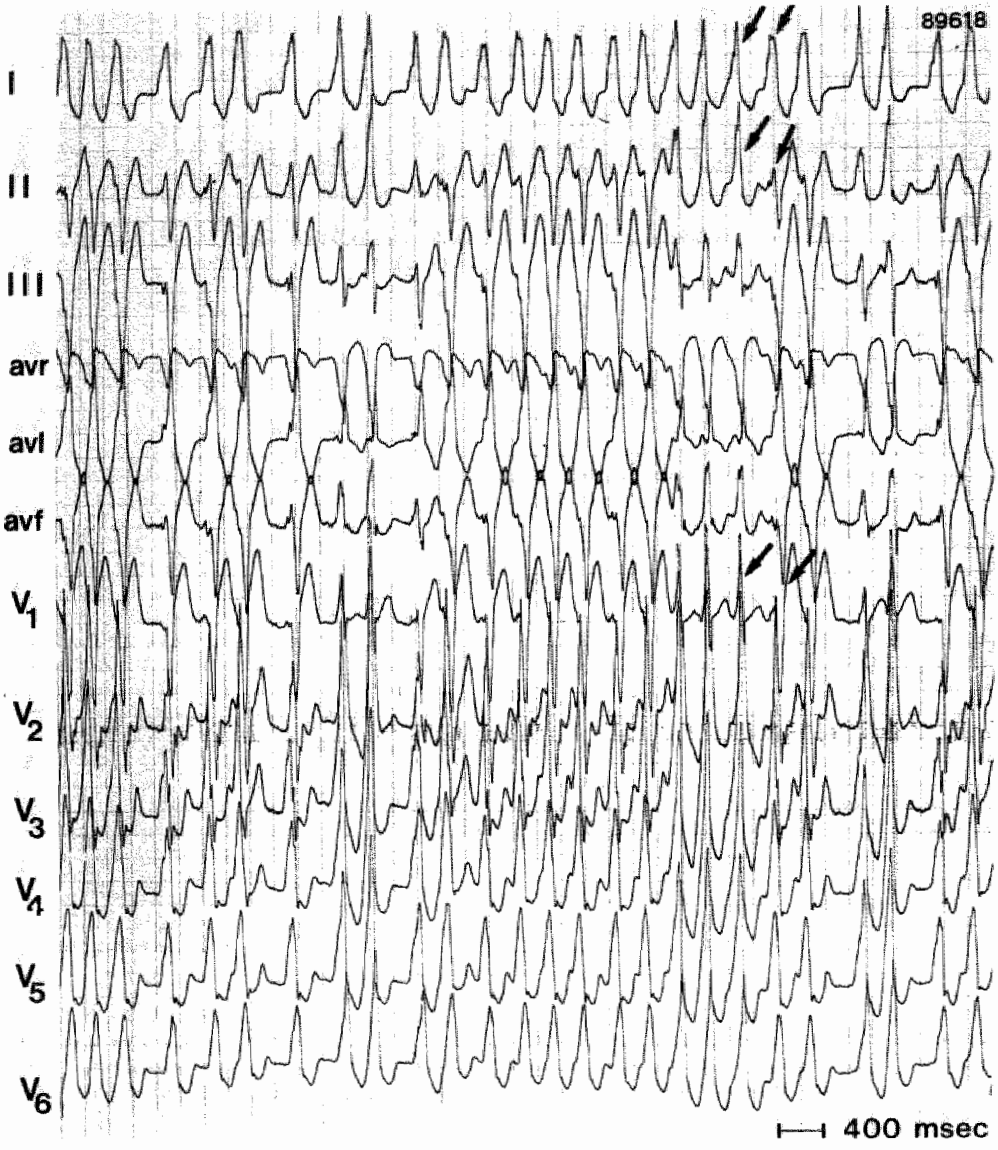

Figure 5. Twelve lead electrocardiogram during atrial fibrillation. Two patterns of ventricular pre-excitation can be seen. This example illustrates the importance of the simultaneous recording of multiple electrocardiographic leads. While some leads do not show different patterns of ventricular excitation, it is very clear in other leads (II, aVF, V1).

Table III. Location of accessory pathways and surgical technique

Patient	Location	First surgery	Second surgery
1	RL/RPS	EPICARDIAL	
		LL *	ENDOCARDIAL
2	RL/LL	EPICARDIAL	
		LPS *	ENDOCARDIAL
3	LPS/RPS	EPICARDIAL	
		RPS **	ENDOCARDIAL
4	LL/LPS	EPICARDIAL + ENDO	
5	RL/LL	EPICARDIAL	
6	LL/RL	EPICARDIAL	
7	LL/RPS	ENDOCARDIAL	
8	LL/RPS	EPICARDIAL	

* Diagnosis during post-operative electrophysiologic study; ** recurrence after first surgery
Abbreviations: RL= right lateral; LL= left lateral; RPS= right posteroseptal; LPS= left posteroseptal;

Three patients (37%) had to be reoperated. Two patients during the same hospitalization and one a few months later because of a recurrence of preexcitation and tachycardia. During reoperation the endocardial approach was used in all 3 patients. Two of the reoperated patients had a third pathway that had not been diagnosed during the first pre-operative electrophysiological study nor during the first surgery. The third patient had recurrence of conduction over an accessory pathway a few months after the first surgery. Following reoperation all three patients are cured without preexcitation or tachycardias.

In the patient in whom isoproterenol had to be given during the preoperative electrophysiologic study, only one accessory pathway could initially be identified during intraoperative epicardial mapping. After infusion of isoproterenol the second pathway could also be located.

No patient developed A-V block, and there were no deaths during surgery or during the follow-up.

Of 126 patients with a single accessory pathway operated in our institution, 9 patients (7%) had to be reoperated because of recurrence of preexcitation or tachycardia. Six of them were reoperated during the same hospitalization for the first surgery. After a mean follow-up of 15 ± 6 months, only one patient showed recurrence of preexcitation. However there was no retrograde conduction over the accessory pathway and the patient remains asymptomatic without drugs.

DISCUSSION

In the past, only few patients with Wolff-Parkinson-White syndrome who did not respond to medical treatment or who had a high risk of ventricular fibrillation underwent surgery. However, in recent years surgical techniques have been developed having a high success rate and a low operative risk (6-13). This has influenced indications for surgery, making it more an attractive option for patients who have to be treated medically for the rest of their lives, or for patients who have professional problems because of the presence of an accessory pathway.

Multiple accessory pathways are found in 3 to 20% of patients who undergo surgery for the Wolff-Parkinson-White syndrome (11-14). In our series 8 out of 135 patients (6.7%) who underwent surgery had multiple accessory pathways. The incidence of failure or reoperation varies from 2 to 15% in the different series (10-15). In our own series, 12 patients (9%) needed reoperation. However, when we look at patients with multiple accessory pathways, 3 out of 8 patients (37%) had to be reoperated. In 2 patients a third pathway was found only during the post-operative electrophysiological study.

These observations indicate that it is very difficult to identify the presence of a third accessory pathway during an electrophysiologic study. Several possible causes have to be mentioned: 1) The location of the accessory pathway may be such that it contributes little to ventricular activation during anterograde conduction, or atrial activation during retrograde conduction. 2) The accessory pathway may be septally located resulting in confusion with retrograde conduction over the AV node. 3) The dynamic nature of the electrophysiologic properties of the accessory pathway may results in absence of conduction during the electrophysiologic study or during surgery. In one patient the third pathway was located in the left posteroseptal region. In another patient the third accessory pathway was located in the left lateral region but because it had a longer anterograde and retrograde refractory period than the other 2 pathways, contributed little to anterograde or retrograde preexcitation. The third patient who was reoperated, had a very late recurrence of conduction over a right posteroseptal accessory pathway.

It is important that in one patient, a second pathway could only be demonstrated in the preoperative electrophysiologic study during the infusion of isoproterenol. Also during surgery only during isoproterenol administration, epicardial mapping revealed the second pathway. One can argue whether it is necessary to give isoproterenol to all patients during the electrophysiological study to uncover a possible second accessory pathway. We believe that this should be done in patients who have clinical findings that suggest the presence of multiple accessory pathways, like a history of syncope or clinical documentation of antidromic tachycardia (17).

We conclude that patients with multiple accessory pathways more often need reoperation because the diagnosis of one of the pathways is missed during the preoperative electrophysiological study and during the first operation.

The findings of this study answer in part the question of Dr. Jatene "Is a second or third bundle identified mainly during the preoperative electrophysiological study or during operation?" (14). It seems that even with very detailed electrophysiological study, a second and particularly a third accessory pathway can be missed because of the electrophysiologic properties and location of the pathway.

REFERENCES

1. Durrer D, Roos JP. Epicardial excitation of the ventricles in a patient with Wolff-Parkinson-White syndrome (type B). Circulation 1967; 35: 15-21.

2. Burchell HB, Frye RL, Anderson MW, McGoon DC. Atrioventricular and ventriculoatrial excitation in Wolff-Parkinson-White syndrome (type B). Circulation 1967; 36: 663-672.

3. Cobb FR, Blumenschein SD, Sealy WC, Boineau JP, Wagner GS, Wallace AG. Successful surgical interruption of the bundle of Kent in a patient with Wolff-Parkinson-White syndrome. Circulation 1968; 38: 1018-1029.

4. Sealy WC, Hattler BG Jr, Blumenschein SD, Cobb FR. Surgical treatment of Wolff-Parkinson-White syndrome. Ann Thorac Surg 1969; 8: 1-11.

5. Iwa T, Mitsui T, Misaki T, Mukai K, Magara T, Kamata E. Radical cure of Wolff-Parkinson-White syndrome: The Kanazawa experience. J Thorac Cardiovasc Surg 1986; 91: 225-233.

6. Sealy WC, Gallagher JJ, Wallace A. The surgical treatment of Wolff-Parkinson-White syndrome. Evolution of improved methods for identification and interruption of Kent bundle. Ann Thorac Surg 1976; 22: 443-457.

7. Uther JW, Johnson DC, Baird DK, et al. Surgical section of accessory atrioventricular electrical connections in 108 patients. Am J Cardiol 1982; 49: 995. (Abstr).

8. Gallagher JJ, Kasell J, Cox JL, et al. Techniques of intraoperative electrophysiologic mapping. Am J Cardiol 1982; 49: 221-233.

9. Guiraudon GM, Klein GJ, Gulamhusein S, et al. Surgical repair of Wolff-Parkinson-White syndrome: a new closed heart technique. Ann Thorac Surg 1984; 37: 67-74.

10. Klein GJ, Guiraudon GM, Perkins DG, et al. Surgical correction of the Wolff-Parkinson-White syndrome in closed heart using cryosurgery: a simplified approach. J Amm Coll Cardiol 1984; 3: 405-428.

11. Gallagher JJ, Sealy WC, Cox JL, et al. Results of surgery for preexcitation in 200 consecutive cases. In Levy S, Scheinman MM (eds): Cardiac Arrhythmias from Diagnosis to Therapy. Mt. Kisco, NY, Futura, 1984, chap 18.

12. Bredikis J, Bukauskas F, Zebraustas R, et al. Cryosurgical ablation of right parietal and septal accessory atrioventricular connections without the use of extracorporeal circulation. J Thorac Cardiovasc Surg 1985; 90: 206-222.

13. Cox JL, Gallagher JJ, Cain ME: Experience with 118 consecutive patients undergoing operation for the Wolff-Parkinson-White syndrome. J Thorac Cardiovasc Surg 1985; 90: 490-501.

14. Jatene AD: Discussion of Cox et al (13).

15. Selle JG, Sealy WC, Gallagher JJ, Fedor JM, Svenson RH, Zimmern SH. Technical considerations in the surgical approach to multiple accessory pathways in the Wolff-Parkinson-White syndrome. Ann Thorac Surg 1987; 43: 579-584.

16. Ross DL, Farre J, Bar FWHM, Vanagt EJ, Brugada P, Wiener I, Wellens HJJ: Spontaneous termination of circus movement tachycardia utilizing an atrioventricular accessory pathway: incidence, sites of block and mechanisms. Circulation 1981: 63: 1129-1137.

17. Atié J, Brugada P, Smeets JLM, Cruz F, Wellens HJJ. Incidence of multiple accessory pathways in patients with antidromic circus movement tachycardia. Eur Heart J 1989; 10: 381 (abstr).

Chapter VIII

Longitudinal dissociation of atrio-ventricular accessory pathways

Jacob Atié
Pedro Brugada
Joep L.R.M. Smeets
Fernando E.S. Cruz
Ayrton Peres
Mauricio Duque
Hein J.J. Wellens

Longitudinal dissociation of atrio-ventricular accessory pathways

SUMMARY

Unusual properties of atrio-ventricular accessory pathways were found during electrophysiologic investigations in four patients, 3 male and 1 female. Anterograde longitudinal dissociation of the accessory pathway was observed in 2 patients and retrograde longitudinal dissociation in two others. Two patients had accessory pathways with slow conduction times, one in anterograde direction and one in retrograde direction. These observations further expand our knowledge on the spectrum of electrophysiologic properties of accessory atrio-ventricular pathways.

INTRODUCTION

The electrophysiologic properties of the atrio-ventricular node and atrio-ventricular accessory pathways have been studied extensively (1-3).

Decremental conduction and functional longitudinal dissociation of the AV node is a well known phenomenon (4-8).

The classical fastly conducting accessory pathway of patients with the Wolf-Parkinson-White syndrome usually shows no or only minimal decremental conduction properties (9), in contrast to concealed pathways with long conduction times who frequently show decremental properties in ventriculo-atrial direction (10-11). Recently, anterograde slow and decremental conduction has also been demonstrated in accessory atrio-ventricular pathways simulating nodo-ventricular connections (12-13). These observations suggest that decremental conduction can occur in accessory pathways. Longitudinal dissociation of accessory atrio-ventricular pathways, however, has been reported only rarely (14-15).

In this article, four patients are described showing functional longitudinal dissociation of their accessory pathway. In two patients in retrograde direction and in anterograde direction in the other two patients.

Submitted for publication

PATIENTS AND METHODS

The four patients in this study were selected from 314 patients seen between 1979 and May 1989 at our institution for evaluation and treatment of various preexcitation syndromes. The four patients were studied retrospectively. Three patients were male and one female. The mean age was 41 (22-72) years. Clinical data are summarized in table I.

Electrophysiologic study

Following informed consent, an electrophysiological study was performed in all patients in the resting, postabsortive non-sedated state. Using the femoral approach, catheters were placed for stimulation and recording of intracardiac electrograms, at the right ventricular apex, tricuspid valve ring, high lateral right atrium and coronary sinus. Our methods of recording, stimulation and analysis of tracings have been described previously (16).

The criteria for the diagnosis of *anterograde longitudinal dissociation* in the accessory pathway were as follows: 1) Cycle length alternation, caused by a sudden change in the A-V interval with a constant V-A interval, without changes in QRS complex or retrograde atrial activation pattern during antidromic circus movement tachycardia (fig. 1). 2) Sudden lengthening of the cycle length of antidromic tachycardia because of prolongation of the A-V interval without changes in V-A interval, the sequence of retrograde atrial activation or the QRS complex.

The criteria for the diagnosis of *retrograde longitudinal dissociation* in the accessory pathway were: 1) Cycle length alternation because of changes in V-A interval with the same sequence of retrograde atrial activation and the same A-V interval during orthodromic circus movement tachycardia, using the normal atrio-ventricular node in the anterograde direction and the accessory pathway in the retrograde direction (fig. 2). 2) During ventricular pacing, a sudden prolongation in the V-A interval over the accessory pathway after minimal changes in pacing rate or premature beat interval without a change in retrograde atrial activation sequence (fig. 3).

RESULTS

Patient 1

During electrophysiological study, incremental atrial pacing performed from the right atrium, showed 1:1 atrio-ventricular conduction with progressive prolongation of the A-H and A-V intervals and increasing pre-excitation. Antidromic tachycardia with left bundle branch block morphology was induced by a single ventricular or atrial extrastimulus. Retrograde conduction

Table I. Age, sex and information of clinical complaints and arrhythmias in the four patients studied.

Patient	Age	Sex	Syncope	Type of Arrhythmias	Additional abnormalities
1	24	M	yes	atrial fibrillation antidromic CMT incessant tachycardia	DAVNP
2	22	M	yes	antidromic CMT orthodromic CMT atrial fibrillation	DAVNP
3	48	M	yes	orthodromic CMT	
4	72	F	no	orthodromic CMT atrial fibrillation	coronary artery disease DAVNP

Abbreviations: CMT = circus movement tachycardia; DAVNP= dual AV nodal pathways; M= male; F= female.

to the atria occurred over the A-V node with a pattern of retrograde atrial activation showing the beginning of atrial activation in the His electrogram, thereafter followed by activation in the proximal coronary sinus, high right atrium and distal coronary sinus.

The tachycardia which had a cycle length of 365 ms changed suddenly to a cycle length of 410 ms. During tachycardia, alternation in cycle length between 365 ms to 410 ms was observed. The V-A interval was constant and the 45 ms alternation was caused by a change in the A-V interval from 220 ms to 265 ms. No change in the retrograde atrial activation or the morphology of the QRS complex was seen (fig. 1). Atrial pacing from the low right atrium showed more pre-excitation as compared to pacing from the high right atrium. This confirmed the diagnosis of an atrio-ventricular accessory pathway with decremental conduction, instead of a nodo-ventricular "Mahaim" fiber. This diagnosis was confirmed later during surgery. The accessory pathway was localized in the free wall of the right AV groove.

Patient 2

The electrophysiological study showed dual AV nodal pathways and two accessory pathways, one left-sided and another located postero-septally. Both pathways were able to conduct anterogradely when atrial pacing was performed. During right ventricular pacing conduction to the atria took place over the left-sided accessory pathway. Atrial activation was first recorded in the distal coronary sinus, thereafter followed by activation in the proximal coronary sinus, His bundle electrogram and high right atrium. Retrograde conduction over the AV node was also observed, but never over the postero-septal accessory pathway.

Both pathways were able to conduct anterogradely when atrial pacing was performed.

Four different types of circus movement tachycardia could be induced: 1) Orthodromic tachycardia with retrograde conduction over the left-sided accessory pathway; 2) Antidromic tachycardia using the postero-septal accessory pathway in the anterograde direction and the left-sided accessory pathway in the retrograde direction; 3) Antidromic tachycardia using the postero-

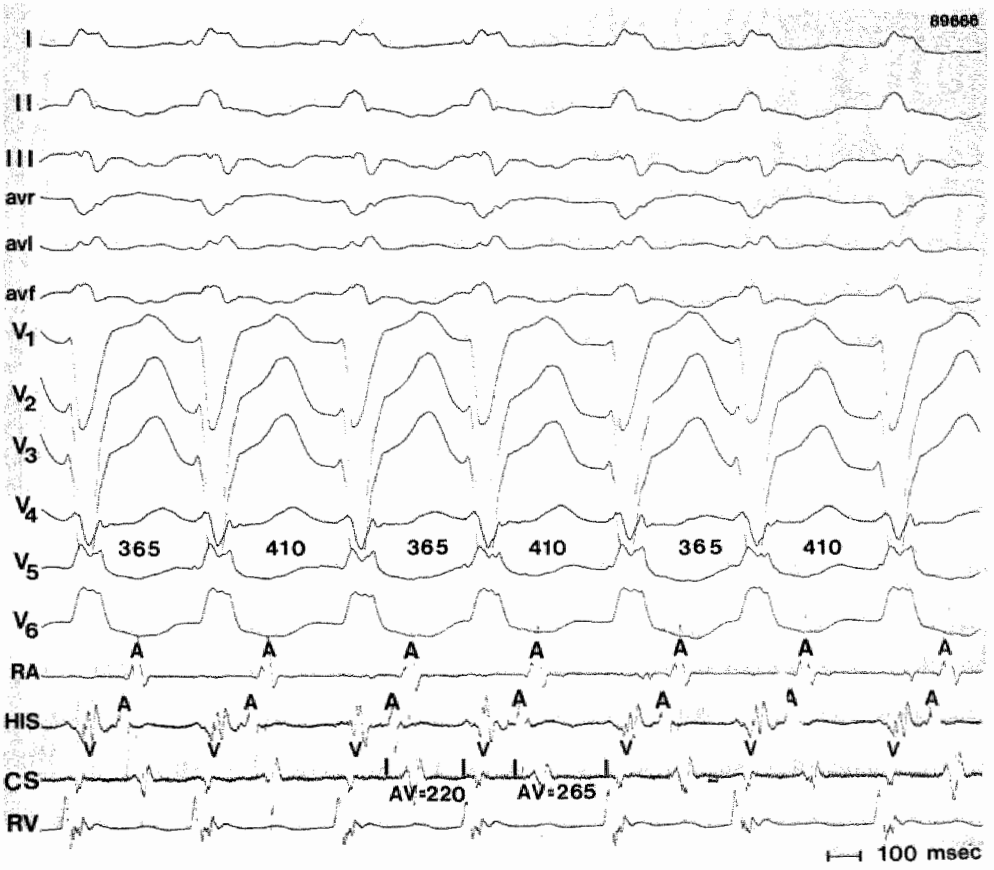

Figure 1. *Patient 1.* Example of antidromic circus movement tachycardia using anterogradely a right-sided accessory pathway with a long conduction time and retrogradely the normal AV node, showing cycle length alternation. Cycle length alternation from 365 to 410 ms is caused by alternation in the A-V interval from 220 to 265 ms, without changes in QRS configuration or V-A interval. Twelve electrocardiographic leads and four intracardiac electrograms from the high right atrium (RA), bundle of His (HIS), distal coronary sinus (CSd) and right ventricle (RV) were recorded simultaneously.

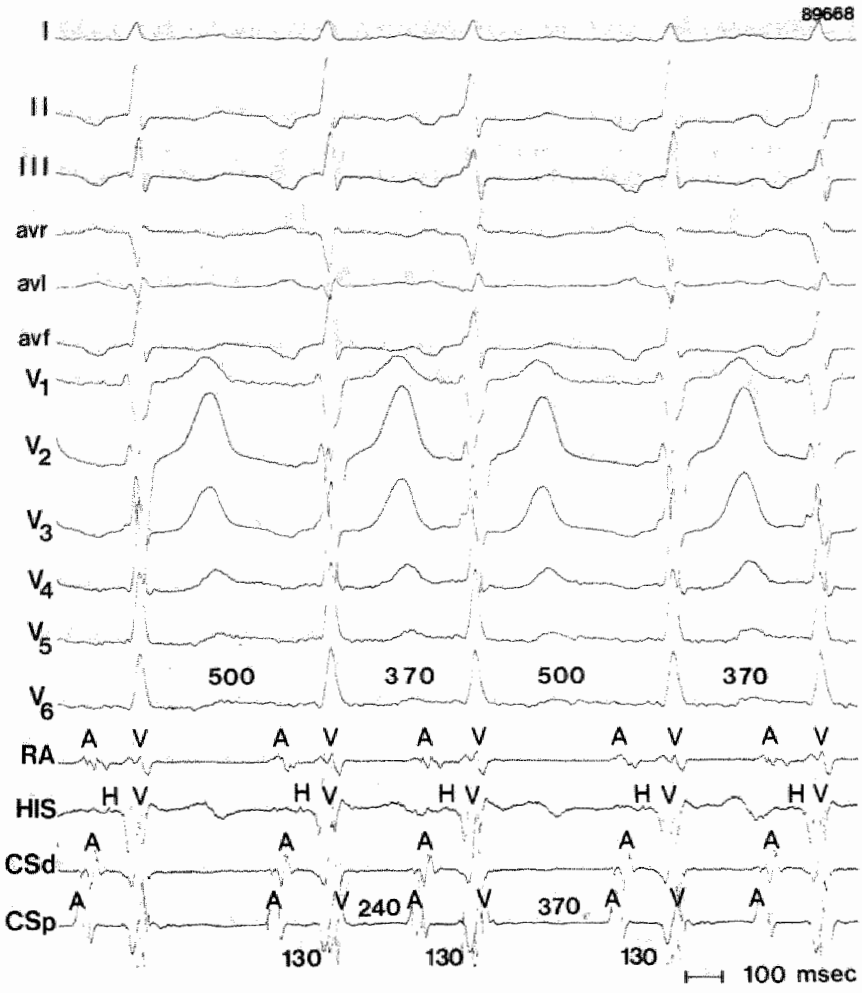

Figure 2. *Patient 3.* Orthodromic circus movement tachycardia using the normal AV node in the anterograde direction and a posteroseptal accessory pathway with long conduction times in the retrograde direction showing cycle length alternation. Cycle length alternation from 500 to 370 ms is caused by alternation in the V-A interval from 370 to 240 ms, without changes in A-V interval and atrial activation pattern. Twelve surface electrocardiographic leads and four intracardiac electrograms are shown.

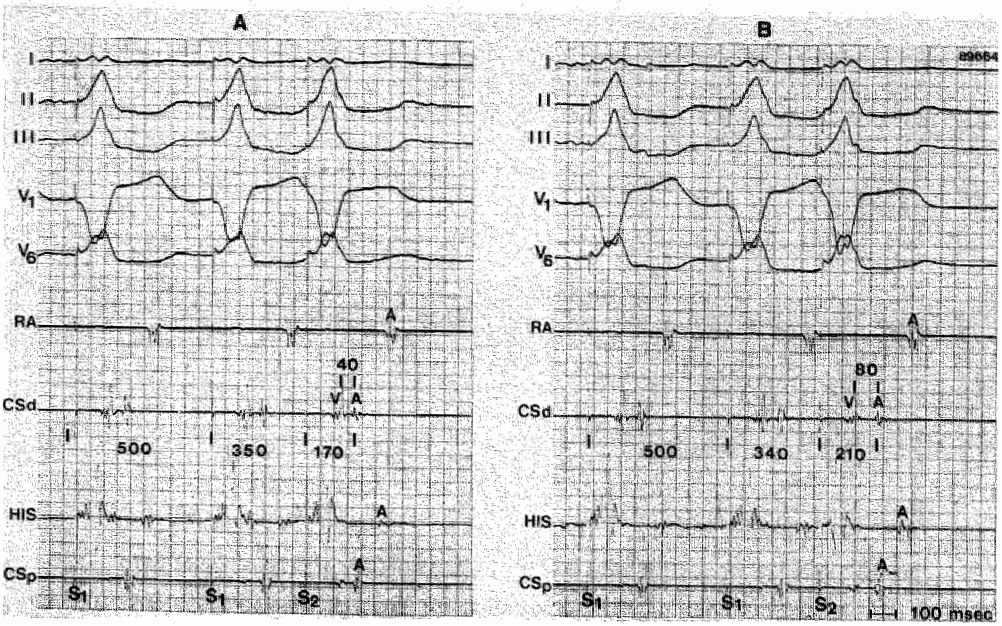

Figure 3. *Patient 4.* Example of longitudinal dissociation in retrograde conduction over an accessory pathway. In panel A, a ventricular premature beat given after 350 ms is followed by atrial activation with a V-A interval of 170 ms. In panel B, on shortening the premature beat by 10 ms, the V-A interval suddenly prolongs by 40 ms, with the same sequence of retrograde atrial activation. Five surface electrocardiographic leads were simultaneously recorded with four intracardiac electrograms.

septal accessory pathway in the anterograde direction and the normal His Purkinje system in the retrograde direction; 4) Antidromic tachycardia using the left-sided accessory pathway in the anterograde direction and the normal His Purkinje system in the retrograde direction. During the last type of tachycardia, alternation in cycle length was observed. Alternation in cycle length measured 70 ms. Alternation was seen both in the anterograde pathway (50 ms) and retrograde pathway (20 ms) (fig. 4).

Patient 3

This patient had a concealed septally located accessory pathway with long conduction times and decremental conduction. During ventricular pacing conduction to the atria took place over the accessory pathway, with earliest atrial activation being recorded in the proximal coronary sinus, thereafter followed by His, distal coronary sinus and high right atrium. Retrograde conduction was also seen over the AV node. Regular ventricular pacing at increasing rates resulted in Wenckebach type V-A conduction over the accessory pathway. Premature ventricular beats given during ventricular pacing also showed decremental conduction over the accessory pathway.

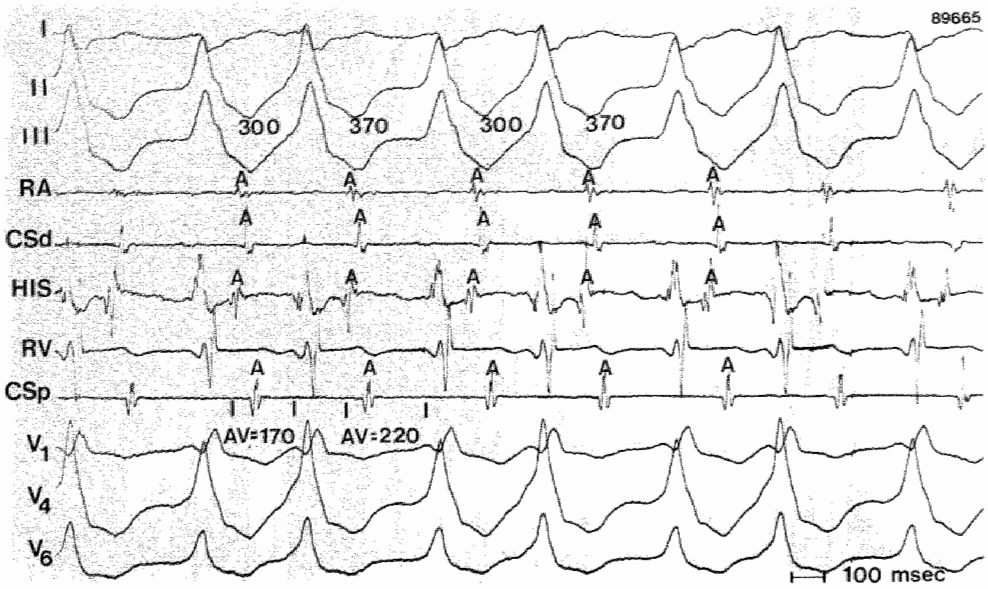

Figure 4. *Patient 2.* An example of antidromic tachycardia using a left-sided accessory pathway for anterograde conduction and the normal conduction system retrogradely, showing alternation in both the A-V (50 ms) and V-A (20 ms) interval. As discussed in the text the alternation in A-V conduction can be explained by two closely located accessory pathways or longitudinal dissociation in a single accessory pathway. Six surface electrocardiographic leads and 5 bipolar endocavitary recordings are shown.

During the electrophysiological study, narrow QRS complex tachycardias occurred both spontaneously and after induced atrial and ventricular premature beats. During tachycardia the PR interval was shorter than the R-P interval. Several episodes of tachycardia with alternation in cycle length were observed from 500 to 370 ms, with VA intervals varying between 370 ms and 240 ms, the A-V interval remaining constant (fig. 2).

Patient 4

During the electrophysiological study, this patient was found to have a left-sided accessory pathway and dual AV nodal pathways. Orthodromic circus movement tachycardia, atrial tachycardia, atrial fibrillation, and atrial flutter could be induced.

During sinus rhythm (cycle length 950 ms) His bundle recordings, revealed an A-H interval of 90 ms and an H-V interval of 20 ms. During ventricular stimulation an increase in V-A time of 40 ms over the accessory pathway was observed on slowing the premature beat interval by 10 ms (fig. 3). The retrograde atrial activation sequence was identical before and after the jump in retrograde conduction.

Orthodromic circus movement tachycardia could be initiated by a single ventricular premature beat. The cycle length of tachycardia alternated from 430 to 390 ms as a result of changes by 65 ms in the A-V and 25 ms in the V-A intervals (fig. 5). Changes in A-V intervals were caused by the dual AV nodal pathways. But changes in V-A intervals could only be explained by longitudinal dissociation of the accessory pathway.

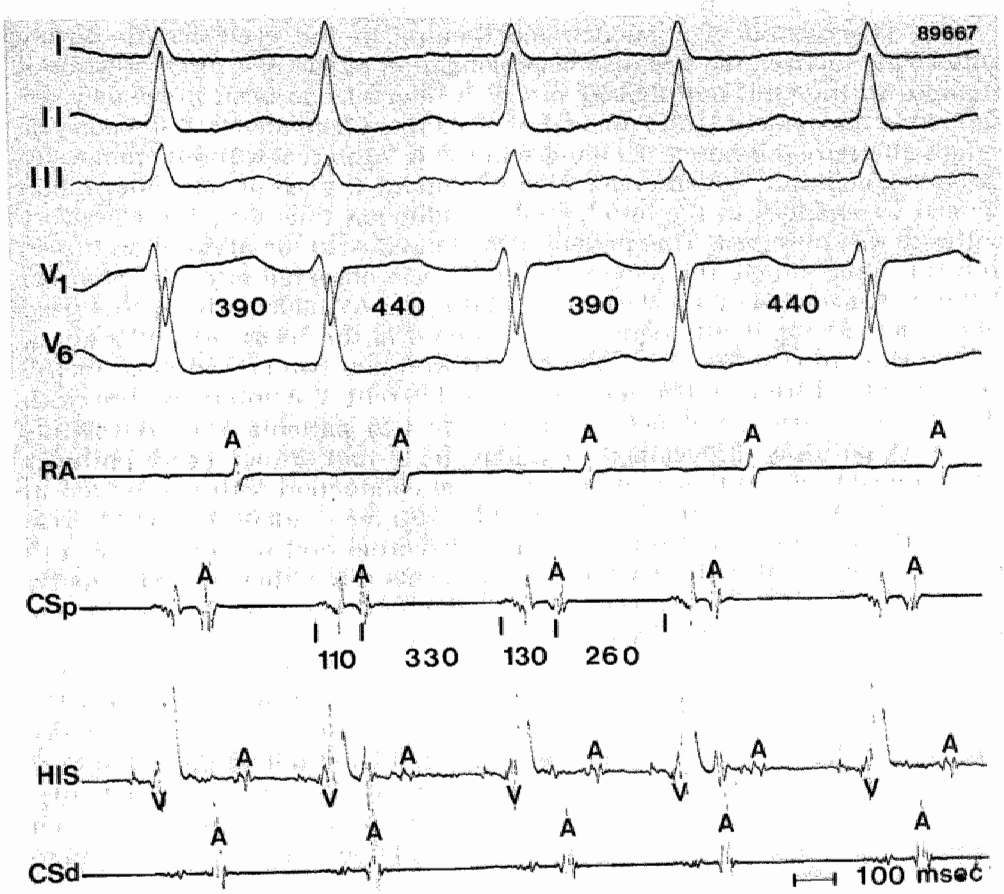

Figure 5. *Patient 4.* Alternation of anterograde and retrograde conduction times during orthodromic circus movement tachycardia. As discussed in the text, this can be explained by dual pathways in the AV node and longitudinal dissociation of the slowly conducting accessory pathway. That cannot be explained by the conduction curves of an accessory pathway with decremental conduction, where long cycles should result in short V-A intervals and short cycles in long V-A intervals. Five surface leads and 4 bipolar endocavitary electrograms are shown.

DISCUSSION

Functional dissociation of conduction in accessory pathways has been reported only rarely during reciprocating tachycardia (17) or pacing (18). Recently Tai (14) described one patient who presented an accessory pathway with retrograde longitudinal dissociation during treatment with re ainam. In our four patients the findings strongly suggest that they had functional dissociation of their accessory pathways. All were without antiarrhythmics drugs at the time of study.

The observation of a sudden lengthening in the cycle length during antidromic tachycardia because of prolongation of the A-V interval without changes in the QRS morphology and V-A interval has been previously described in one patient (15). Patient 1 showed this phenomenon but also cycle length alternation because of changes in the A-V interval without changes in QRS complex and V-A interval. Also in patient 2 cycle length alternation caused by changes in the anterograde conduction time over the accessory pathway was observed. This patient also showed a 20 ms alternation in V-A interval. Interestingly the longest V-A time was observed after the shortest A-V time suggesting that a slower conducting His-AV node pathway was used following more rapid anterograde conduction over the accessory pathway.

Denes et al (18) described one patient who had two orthodromic tachycardias with distinct rates and with two different V-A intervals, but with identical eccentric atrial activation. In our two patients with retrograde accessory pathway dissociation, one (patient 3) had an accessory pathway with long conduction times and decremental conduction with alternation in the cycle length and in the V-A interval by 130 ms. Patient 4 showed cycle length alternation during orthodromic tachycardia and a jump in the V-A interval during ventricular pacing. This suggests that either two very closely located accessory pathways with long conduction time were present or one pathway with longitudinal dissociation.

Our data support findings from previous studies suggesting that longitudinal functional dissociation may occur in accessory atrio-ventricular pathways. Given the complex anatomy of the few carefully studied accessory pathways (19), this is not a surprising finding. If longitudinal dissociation of the atrio-ventricular node can be observed in approximately 20% of patients, the question is why longitudinal dissociation of accessory pathways is not observed more frequently. As already indicated, an alternative explanation to longitudinal dissociation of a single accessory pathway is the possibility of two very closely located accessory pathways. Although anatomically two closely located accessory pathways are different from a single functionally dissociated accessory pathway, their functional consequences will be the same. Two accessory pathways located very close to one another should not result in changes in the QRS complex (as during anterograde longitudinal dissociation) or the retrograde atrial activation sequence (as during retrograde longitudinal dissociation).

Our findings further extend our knowledge on the electrophysiologic properties of accessory atrio-ventricular pathways. They suggest that not only decremental conduction, but also longitudinal dissociation are not restricted to the atrio-ventricular node.

REFERENCES

1. Wellens HJJ. Electrical stimulation of the heart. In the study and treatment of tachycardias. Baltimore, University Park Press, 1971.

2. Rosen KM, Mehta A, Miller RA. Demonstration of dual atrioventricular nodal pathways in man. Am J Cardiol 1974; 33: 291-294.

3. Coumel P, Attuel P, Motte G, Slama R, Bouvrain Y. Les tachycardies jonctionelles paroxystiques. Evaluation du point de jonction inferieur du circuit de reentrée. Demembrement des "rhythmes" réciproques intra-nodaux. Arch Mal Coeur 1975; 68: 1255-1277.

4. Critelli G, Gallagher JJ, Monda V, Coltorti F, Scherillo M, Rossi L. Anatomic and Electrophysiologic substrate of the permanent form of junctional reciprocating tachycardia. J Am Coll Cardiol 1984; 4: 601-610.

5. Brugada P, Vanagt E, Dassen WR, Gorgels AP, Bär FW, Wellens HJJ. Atrioventricular nodal tachycardia with and without discontinuous anterograde and retrograde atrioventricular nodal conduction curves: a reappraisal of the dual pathway concept. Eur Heart J 1980; 1: 399-407.

6. Akhtar M, Damato AN, Ruskin JN, et al. Anterograde and retrograde conduction characteristics in three patterns of paroxysmal atrioventricular junctional reentrant tachycardia. Am Heart J 1978; 95: 22-42.

7. Denes P, Wu D, Amat-y-Leon F, Dhingra R, Wyndham CR, Rosen KM. The determinants of atrioventricular nodal reentry with premature atrial stimulation in patients with dual A-V nodal pathways. Circulation 1977; 56: 253-259.

8. Brugada P, Bar FW, Vanagt EJ, Friedman PL, Wellens HJJ. Observations on patients showing AV junctional echoes with a shorter P-R than R-P interval. Distinction between intranodal reentry or reentry using an accessory pathway with long conduction time. Am J Cardiol 1981; 48: 611-622.

9. Wellens HJJ, Durrer D. Combined conduction disturbances in two AV pathways in patients with Wolf-Parkinson-White syndrome. Eur Heart J 1973; 1: 23-28.

10. Coumel P, Attuel P, Mugica J. Junctional reciprocating tachycardia. The permanent form. In: Kulbertus HE, ed: Reentrant Arrhythmias. Lancaster: MTP Press. 1977; 170-183.

11. Gallagher JJ, Sealy WC. The permanent form of reciprocating tachycardia: Further elucidation of the underlying mechanism. Eur J Cardiol 1978; 8: 413-430.

12. Atié J, Brugada P, Smeets JLRM, Cruz ESF, Penn OCKM, Wellens HJJ. Further support of the atrio-ventricular localization of so-called Mahaim fibers. J Am Coll Cardiol 1989; 13: 232 [abstr].

13. Klein GJ, Guiraudon GM, Kerr CR, Sharma AD, Yee R, Szabo T, Yeung Laiwah JAY. Nodo-ventricular accessory pathway: Evidence for a distinct accessory atrioventricular pathway with atrioventricular node-like properties. J Am Coll Cardiol 1988; 11: 1035-1040.

14. Tai YT, Campbell RWF, McComb JM. Latent functional duality in an accessory pathway. Eur Heart J 1989; 10: 380-384.

15. Belhassen B, Misrahi D, Shapira I, Laniado S. Longitudinal dissociation in an anomalous accessory atrioventricular pathway. Am Heart J 1983; 106: 1441-1443.

16. Ross DL, Farre J, Bar FWHM, Vanagt EJ, Brugada P, Wiener I, Wellens HJJ: Spontaneous termination of circus movement tachycardia utilizing an atrioventricular accessory pathway: incidence, sites of block and mechanisms. Circulation 1981; 63: 1129-1138.

17. Klein GJ, Prystowsky EN, Pritchett ELC, Davis D, Gallagher JJ. Atypical patterns of retrograde conduction over accessory atrioventricular pathways in Wolf-Parkinson-White syndrome. Circulation 1979; 60: 1477-1486.

18. Denes P, Kehoe R, Rosen KM. Multiple reentrant tachycardias due to retrograde conduction of dual atrioventricular bundles with atrioventricular nodal-like properties. Am J Cardiol 1979; 44: 162-170.

19. Becker AE. Morphologic characteristics of arrhythmias. In Brugada P, Wellens HJJ (eds): Cardiac Arrhythmias: Where to Go From Here? Mount Kisco, NY, Futura Publishing Co, 1987, pp 435-456.

Chapter IX

General conclusions, recommendations and implications for daily practice

General conclusions, recommendations and implications for daily practice

This thesis addresses particular problems encountered in patients with accessory pathways. The Wolff-Parkinson-White syndrome was for years considered some sort of electrocardiographic curiosity. Recognition of its clinical relevance, the complications which it could produce and the impact of the arrhythmia episodes on quality of life has required many years of study.

Nowadays all these factors are well understood and extremely successful therapies have become available. Among them, surgical interruption of an accessory pathway offers a definitive solution to the problem. However, before surgical correction is undertaken an accurate diagnosis is required. This diagnosis must include not only the exact localization and properties of the accessory pathway but also understanding of the different types of tachycardias present in one patient and most important, whether more than one accessory pathway is present.

As described in this thesis, multiple accessory pathways are not a rarity and an important cause of reoperation. We found multiple accessory pathways in 5.2% of our patients initially diagnosed as having at least one accessory pathway. Of importance, these were the patients who presented the most severe symptoms and a high incidence (11%) of spontaneous ventricular fibrillation. They also suffered more often from antidromic circus movement tachycardia. The reverse was also true, that is, patients with antidromic circus movement tachycardia, particularly when spontaneous, had a high incidence of multiple accessory pathways. The electrocardiogram during sinus rhythm offered also some clues to the diagnosis of multiple accessory pathways. A discordance in the axis in the frontal plane of the delta wave and the main QRS complex and a qRS or qrS pattern in lead V1 should suggest that diagnosis.

In the electrophysiology laboratory, but also in the electrocardiogram, other clues to the diagnosis of multiple accessory pathway were: 1) more than one P wave configuration during orthodromic circus movement tachycardia; 2) A "mismatch" between the location of the atrial and ventricular end of the accessory pathway as determined from the P wave during circus movement tachycardia and the preexcitation pattern during sinus rhythm or antidromic tachycardia; 3) More than one preexcitation pattern during atrial fibrillation, atrial pacing or antidromic circus movement tachycardia; 4) A spontaneous change from antidromic tachycardia to another with a different preexcitation pattern; 5) A spontaneous change from antidromic to orthodromic circus movement tachycardia or vice-versa within one cycle; 6) Demonstration of two patterns of preexcitation during administration of an agent prolonging or

shortening the anterograde refractory period of the accessory pathway; 7) More than one pattern of retrograde atrial activation over different accessory pathways during ventricular pacing or orthodromic circus movement tachycardia.

A group of patients of particular interest were patients with a "Mahaim" accessory pathway. It has been considered that "Mahaim" fibers were nodo-ventricular accessory pathways. Physicians were reluctant to indicate surgical correction of these accessory pathways which were thought difficult to accurately localize. Previous studies and data presented in this thesis indicate that "Mahaim" fibers are accessory atrio-ventricular pathways localized in the right ventricular free wall. They behave similarly to nodo-ventricular fibers because they have special electrophysiology properties suggesting implantation of their proximal part in the atrio-ventricular node. Frequently it has been stated that they implanted in a "slow" atrioventricular nodal pathway. In reality, they are accessory atrioventricular pathways with simply slow anterograde conduction. This slow anterograde conduction is similar to what is found in certain types of concealed accessory pathways which conduct slowly in retrograde direction. These new insights have completely changed the therapeutic approach to "Mahaim" fibers. These accessory pathways can be operated on as easily as any type of accessory atrioventricular pathway.

The last problems addressed in this thesis were some unusual electrophysiologic properties of accessory pathways as observed during electrophysiologic examination. Longitudinal dissociation of an accessory pathway should be recognized by the electrophysiologist and differentiated from multiple accessory pathways.

Our findings have several important implications for daily practice:

1. Multiple accessory pathways are not a rarity. The physician looking after a patient with an accessory pathway has always to think of the possibility of multiple accessory pathways if the patient has symptoms such as syncope, spontaneous ventricular fibrillation, antidromic tachycardia or electrocardiographic clues as here described.
2. Multiple accessory pathways are not a contraindication to surgery. On the contrary, because of the severe symptoms they may cause, surgery should be the treatment of choice.
3. "Nodo-ventricular fibers" (Mahaim) are accessory atrioventricular pathways with slow anterograde conduction. They can be operated on as easily and successfully as any other type of accessory atrio-ventricular pathway.

Summary

The aim of this thesis was to analyze new aspects of the preexcitation syndromes. These include the diagnosis and mechanisms of antidromic circus movement tachycardia, incidence, diagnosis and mechanisms of tachycardias in patients with multiple accessory pathways and observations in patients with accessory pathways with unusual electrophysiologic properties. It also described the results of treatment in these patients. Although emphasis was on invasive electrophysiologic techniques, necessary for the correct diagnosis, attention was also given to the value of the 12-lead electrocardiogram in diagnosing these abnormalities. This resulted in a further increase in the diagnostic power of this simple and inexpensive tool.

In Chapter I, the anatomic, electrocardiographic and electrophysiologic aspects of cardiac preexcitation were reviewed.

Chapter II described findings in patients with atrioventricular accessory pathways with long anterograde conduction times. These accessory pathways behave similarly to nodo-ventricular ("Mahaim") accessory pathways.

In Chapter III the clinical and electrophysiologic characteristics of 36 patients with antidromic circus movement tachycardia were presented. These patients had a high incidence of multiple accessory pathways and ventricular fibrillation.

In Chapter IV the 12-lead electrocardiogram during sinus rhythm was studied in patients with multiple accessory pathways. We concluded that the presence of a qRS or qrS pattern in lead V1 and a discordance between delta wave polarity and the QRS axis in the frontal plane is suggestive of the presence of multiple accessory pathways.

In Chapter V several findings were reported on the 12-lead electrocardiogram during tachycardias or after antiarrhythmic drug administration that indicated the presence of multiple accessory pathways.

In Chapter VI the clinical and electrophysiologic characteristics of 18 patients with multiple accessory pathways were presented.

In Chapter VII the results of surgical treatment in patients with multiple accessory pathways were presented. Patients with multiple accessory pathways could be operated on successfully, but they more often required reoperation because the diagnosis of a third pathway could not be made during the preoperative electrophysiological study.

In Chapter VIII evidences for functional longitudinal dissociation of the accessory pathway were presented. This very unusual finding was observed in 2 patients in anterograde and in 2 patients in retrograde direction.

Samenvatting

Dit proefschrift beschrijft nieuwe bevindingen bij patiënten met pre-excitatie. Het gaat over de diagnose en mechanismen van antidrome cirkeltachycardie; de incidentie, de diagnose en mechanismen van tachycardieën bij patiënten met meerdere extraverbindingen en patiënten met extraverbindingen met bijzondere electrofysiologische eigenschappen. Ook worden tevens de resultaten beschreven van de behandeling van deze patiënten. Hoewel de nadruk ligt op invasieve electrofysiologische technieken, wordt ook aandacht besteed aan de waarde van het 12-kanaals ECG bij het diagnostiseren van deze afwijkingen. Het laatste omdat dit leidt tot een verdere toename van de diagnostische waarde van deze eenvoudige en goedkope techniek.

In hoofdstuk I wordt een overzicht gegeven van de anatomische, electrocardiografische en electrofysiologische aspecten van cardiale preexcitatie.

Hoofdstuk II beschrijft bevindingen bij patiënten met atrio-ventriculaire extraverbindingen met lange anterograde geleidingstijden. Het blijkt dat deze extraverbindingen zich hetzelfde gedragen als nodo-ventriculaire ("Mahaim") extraverbindingen.

In hoofdstuk III worden de klinische en electrofysiologische karakteristieken van 36 patiënten met antidrome cirkeltachycardieën gepresenteerd. Bij deze patiënten is er een hoge incidentie van multipele extraverbindingen en kamerfibrilleren.

Hoofdstuk IV geeft de bevindingen van het 12-kanaals electrocardiogram gedurende sinusritme bij patiënten met multipele extraverbindingen. Hieruit blijkt dat de aanwezigheid van een qRS of qrS patroon in afleiding V1 en een discordantie tussen deltagolf polariteit en de QRS-as in het frontale vlak suggestief is voor de aanwezigheid van multipele extraverbindingen.

Hoofdstuk V beschrijft de waarde van het 12-kanaals electrocardiogram gedurende tachycardie of ná administratie van antiaritmische medicatie om de aanwezigheid van multipele extraverbindingen vast te stellen.

Hoofdstuk VI beschrijft de klinische en electrofysiologische karakteristieken van 18 patiënten met meerdere extraverbindingen.

In hoofdstuk VII worden de resultaten van chirurgische behandeling van patiënten met meerdere extraverbindingen gegeven. Het blijkt hierbij dat bij deze patiënten vaker dan bij patiënten met een enkel extraverbinding een heroperatie noodzakelijk is geweest omdat het moeilijk is de diagnose van een derde extra-verbinding vast te stellen tijdens het pre-operatieve electrofysiologisch onderzoek.

In hoofdstuk VIII worden 4 patiënten gepresenteerd met functionele dissociatie van een extraverbinding.

Acknowledgment

Many people supported and continue to support me during the work preceding, involving and following the publication of this thesis.

It is fantastic to have that many friends. The disadvantage is that one cannot mention them all in such a limited space.

I thank my parents, my dear "pais" who from the beginning lead me in all those apparently irrelevant things, which, however, determine one's personality and approach to life. They lead me to study and to interest in every little detail of my work. Without that excellent leadership my life could have been a completely different one.

Angela, please, just keep being the same way you are.

I thank my teachers Pedro Brugada who since my arrival in Maastricht stimulated me and showed me the ways to Rhythmology and Electrophysiology, and Prof. Wellens who with his dynamic and scientific personality contributed a lot to my learning process.

Also Joep Smeets, who with his excellent work, his patience and good feelings, always had that "second" to teach and help me.

Also Simon Braat, that together with Joep are my "Paraninfs" in this thesis.

I thank the members of the "Committee", Prof. Reneman, Prof. Allessie, Prof. Penn, Prof. Meijler and Prof. Janse, and the "Foreign Referees", Prof. Saad and Dr. Farré.

My colleagues in Maastricht, the Research Fellows of the Clinical Electrophysiology Laboratory contributed as much to my scientific as to my social life. Fernando Cruz, Ayrton Peres, Josep Brugada, Tamer Seixas, Mauricio Duque, the "president" Shi, Rodolfo Oyarzun, Lluis Mont, Luz Maria Rodrigues, I also thank you for your help with this thesis.

Rodolpho Rocco, master of masters, and friend who guided me since early days in Medicine. I express you all my gratitude.

Edson Saad, I thank you for all the stimulus and the extra "kick" you gave me.

Adalberto Lorga and Ivan Maia contributed in different and unexpected ways to my life. Adalberto, fax up, fax down, looked with microscope to every single word in this thesis. Ivan did the same with a telescope, because of the distance. I am looking forward to be again face to face next to each other and provide the best of our care to the many patients we have in Brazil.

Louis Peters and Heloisa Castelo Branco, for all the support and help they gave me.

Anton Gorgels and Marc Vos who directly and indirectly contributed a lot to this thesis.

I thank also Marie Pauline Roukens, that help me not only in this thesis, but also in other investigations.

Rob Mulleneers has indirectly introduced the informatics in our Department in Brazil. You may not know that, but you started in someway, a little revolution. We count on you to continue our computerized work from a far distance.

I thank also Patricia Krekels, not only for the secretarial help, but also for her perpetual smile.

Also Adri Van den Dool and all members of the Photographic Department of the Hospital for their help with the illustrations.

I thank the CNPq and UFRJ for their support in my endeavour. Certainly without their support I would not have been able to perform this doctoral thesis in the Netherlands.

Curriculum vitae

JACOB ATIÉ

Born	Tel-Aviv, Israel, January 28, 1953
Nationality	Brazilian
1971-1976	Medical School, Federal University of Rio de Janeiro, Brazil.
1978-1980	Master in Cardiology, Pontificia Universidade Católica, Rio de Janeiro, Brazil.
1981	Specialist in Cardiology (Brazil).
1982-1990	Staff Member, Hospital Clementino Fraga Filho, Federal University of Rio de Janeiro, Brazil.
1988-1990	Research Fellow in Clinical Cardiac Electrophysiology, University of Limburg, Maastricht, The Netherlands.