Psoas hitch ureteral reimplantation after surgery for locally advanced and locally recurrent colorectal cancer

Available online at www.sciencedirect.com

ScienceDirect

EJSO 43 (2017) 1869–1875

EJSO the Journal of Cancer Surgery

www.ejso.com

Psoas hitch ureteral reimplantation after surgery for locally advanced and locally recurrent colorectal cancer: Complications and oncological outcome

F. van den Heijkant [a,*,d], T.A. Vermeer [b,d], E.J.E.J. Vrijhof [a], G.A.P. Nieuwenhuijzen [b], E.L. Koldewijn [a], H.J.T. Rutten [b,c]

[a] *Department of Urology, Catharina Hospital, Michelangelolaan 2, 5623 EJ, Eindhoven, The Netherlands*
[b] *Department of Surgery, Catharina Hospital, Michelangelolaan 2, 5623 EJ, Eindhoven, The Netherlands*
[c] *GROW: School of Oncology and Developmental Biology, Maastricht University Medical Centre, P.O. Box 616, 6200 MD, Maastricht, The Netherlands*

Accepted 15 May 2017
Available online 26 May 2017

Abstract

Introduction: The most important prognostic factor for oncological outcome of rectal cancer is radical surgical resection. In patients with locally advanced T4 rectal cancer (LARC) or locally recurrent rectal cancer (LRRC) (partial) resection of the urinary tract is frequently required to achieve radical resection. The psoas bladder hitch (PBH) technique is the first choice for reconstruction of the ureter after partial resection and this bladder-preserving technique should not influence the oncological outcome.
Methods: Demographic and clinical data were collected prospectively for all patients operated on for LARC or LRRC between 1996 and 2014 who also underwent a psoas hitch ureter reconstruction. Urological complications and oncological outcome were assessed.
Results: The sample comprised 70 patients, 30 with LARC and 40 with LRRC. The mean age was 62 years (range: 39–86). Postoperative complications occurred in 38.6% of patients, the most frequent were urinary leakage (22.9%), ureteral stricture with hydronephrosis (8.6%) and urosepsis (4.3%).

Surgical re-intervention was required in 4 cases (5.7%), resulting in permanent loss of bladder function and construction of a ureter-ileo-cutaneostomy in 3 cases (4.3%). Oncological outcome was not influenced by postoperative complications.
Conclusion: The rate of complications associated with the PBH procedure was higher in our sample than in previous samples with benign conditions, but most complications were temporary and did not require surgical intervention. We conclude that the bladder-sparing PBH technique of ureter reconstruction is feasible in locally advanced and recurrent rectal cancer with invasion of the urinary tract after pelvic radiotherapy.

Keywords: Psoas hitch; Ureter reconstruction; Rectal cancer; Bladder-sparing surgery

Introduction

The main objective of surgery for locally advanced T4 rectal cancer (LARC) and locally recurrent rectal cancer (LRRC) is to achieve a radical resection with negative tumour margins.[1] It has been shown that a clear surgical margin is the most important prognostic factor with respect to oncological outcome of rectal cancer surgery.[1,2] In LARC and LRRC the tumour invades adjacent organs or pelvic structures. The urinary tract is one of the most frequently invaded organs due to its anatomical position, anterolateral to the rectum.[3,4] Surgical margins are more prone to tumour invasion in LRRC than in primary cases, because the natural anatomical borders were breached during primary resection. Complete or partial resection of the urinary tract is often required to achieve a radical resection. This means that urologists play an increasingly important role in treatment of advanced tumours, as reconstruction

* Corresponding author.
E-mail address: fleurvdheijkant@gmail.com (F. van den Heijkant).
[d] Both authors equally contributed to the manuscript.

http://dx.doi.org/10.1016/j.ejso.2017.05.018

of the urinary tract is often necessary after surgery for LARC or LRRC.[4–6]

Recent studies show that if adequate clear surgical margins can be achieved using bladder-preserving surgery, then rates of local and distant recurrence are no higher than when more radical surgery is used.[4,6,7] Because total cystectomy and urinary diversion are associated with substantial chronic morbidity, bladder-preserving procedures for urinary tract reconstruction should be used when possible.[7]

In cases where the tumour has invaded the ureter, partial resection of the ureter is necessary to achieve a radical resection. In most cases neither uretero-ureterostomy nor direct reimplantation are possible due to the length of the ureteral defect and under these circumstances European and American guidelines on ureteral trauma specify that the psoas bladder hitch (PBH) is the technique of choice for bridging ureteral gaps.[8]

The primary aim of this study was to describe the outcome of bladder-preserving ureter reconstruction with a PBH after surgery for LARC or LRRC invading the ureter in patients who underwent radiotherapy as part of their treatment. In this study we assessed oncological outcome and postoperative complications of PBH in a cohort of patients who underwent PBH for LARC or LRRC invading the urinary tract, during curative surgery. Use of a bladder-preserving strategy in surgery for LARC and LRRC should not interfere with the oncological resection, therefore our secondary aim was to evaluate oncological outcome after PBH in this particular population. We also investigated the effects of neo-adjuvant and intra-operative radiotherapy on complication rates. Our assessment of the time course of complications may serve as the basis for a follow-up guideline, as there is still no such guideline for PBH.[9] To our knowledge this is the first study of short and long-term outcomes in PBH patients in this specific oncological population.

Methods

Patients and methods

The Catharina Hospital is a national referral centre for patients with LRRC and LARC. We included all patients operated on for LARC or LRRC from January 1996 to December 2014, who also underwent PBH. Since the design of our study was retrospective, ethical approval was not required. All data were available from historical patient files and regular follow-up *visits*.

Surgical technique and postoperative urological care

In all LARC and LRRC cases with possible invasion of the urinary tract, bilateral ureter double-J-stents are placed before surgery to facilitate identification of the ureter during tumour resection. During the data collection period for this study tumour resections were performed by two experienced gastro-intestinal surgeons and PBH ureter reconstructions by four experienced urologists.

The PBH technique was first described by Turner Warwick and Worth.[10] In brief, the procedure starts with mobilisation and opening of the bladder. Then the bladder is pushed upwards towards the psoas muscle on the side of the transected ureter and subsequently fixed to the muscle using 2 vicryl 1.0 sutures. The site of the uretero-neocystotomy at the top of the bladder is selected after suturing. The ureter is pulled through a submucosal tunnel in the bladder wall in a 'non-kinking' manner, after spatulation of the ureter, a uretero-neocystotomy is performed. Finally, the ureteral adventitia is attached to the exterior bladder wall (Fig. 1).

After the procedure a 5Fr-infant feeding tube is placed in the ureter and passed through the bladder and the abdominal wall. This tube allows urine drainage to be monitored directly. A Foley catheter is left in place to maximise drainage of the bladder. A cysto-ureterogram is performed 7–14 days postoperatively to determine whether the anastomosis has healed; if it has the feeding tube is removed. The Foley catheter is removed one day after the feeding tube and voiding (frequency, presence of urgency, incontinence and residual volume) is observed.

Neo-adjuvant therapy and intra-operative radiotherapy

Neo-adjuvant (chemo)-radiation therapy is currently standard for LARC and LRRC patients. The neo-adjuvant treatment protocols changed during the study period. At

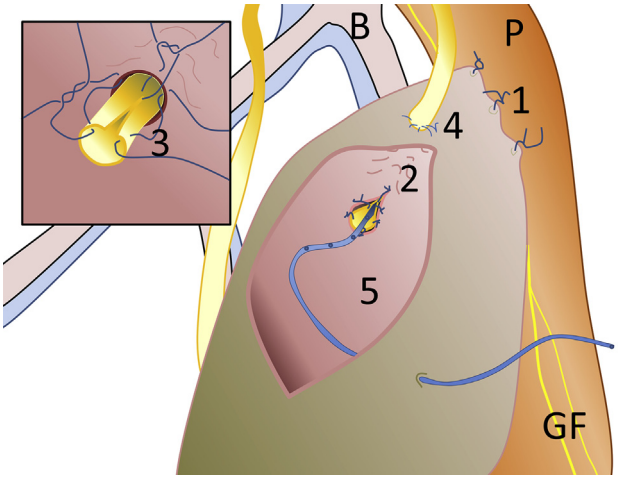

Figure 1. Illustration of the psoas hitch technique. Subsequent steps in a psoas hitch uretero-neo-cystostomy procedure: 1. After mobilizing the bladder by transection of the antero-lateral peritoneal attachments and blunt opening of Retzii's space, a cystostomy is performed and the bladder is stretched upward and fixed with some sutures to the psoas muscle(P), avoiding the genitofemoral nerve (GF). 2. The shortened ureter is led through a submucosal tunnel into the bladder. 3. The opening at the end of the ureter is widened by a longitudinal incision before suturing it to the mucosal layer of the bladder in order to avoid stenosis (3). At the outer entrance site the ureter is also fixed to the bladder wall (4). Before closure of the cystostomy, a double J catheter is placed as a temporary stent. (B is the aorta bifurcation).

the beginning of the study period patients with LARC received 50.4 Gy (5 × 1.8 Gy per week) radiotherapy with concomitant chemotherapy. In 2008 this was changed to 50 Gy (5 × 2 Gy per week). In the 1990s the concomitant chemotherapy was a 5-FU-based regimen, but in 2000 this changed to a capecitabine regimen. A more extensive overview of the changes in our neo-adjuvant treatment protocols is given elsewhere.[11] Some patients were not treated according to these protocols and received 25 Gy (5 × 5 Gy per week) prior to referral to our hospital.[12]

Neo-adjuvant therapy in LRRC cases varies, since the doses of chemo- and radiotherapy depend on what the previous regimes were. In the early part of the study period re-irradiation was not common, but after 1998 all recurrent cases received re-irradiation. Only two LRRC patients who had undergone radiotherapy for their primary tumour were not re-irradiated. In all cases intra-operative analysis of frozen sections of the margin with the highest risk of tumour involvement was performed after LARC or LRRC resection. In addition to the external beam pelvic radiotherapy, most patients with threatened surgical margins received supplementary intra-operative radiotherapy (IORT) (10–17.5 Gy) at the area with close or microscopically involved margins, where the risk of local recurrence was greatest.

Outcomes

The incidence and management of urological complications during follow-up were determined by retrospective review of all patient charts and follow-up data from referring hospitals. Only severe urological complications requiring invasive intervention and/or re-admission to hospital (Clavien–Dindo grade III–V) were included in the analysis.[13] Mild urinary tract infections, temporary retention of urine and mild hydronephrosis without renal failure were therefore not included.

Length of follow-up was recorded as the number of months between surgery and death, or between surgery and the last follow-up appointment, whether this was with a urologist or surgeon. Patients whose last hospital visit was more than one year before the research began were interviewed by phone in order to complete the follow-up for this study.

Statistical analysis

Statistical analysis was performed using SPSS 19.0 for Windows. Patient-, tumour- and treatment-related variables were assessed to determine their association with urological complications. Group comparisons were carried out using chi-squared or Fischer's exact tests when appropriate. All tests were two-tailed and results were considered significant if $p \leq 0.05$. Finally, Kaplan–Meier survival analysis was used to analyse survival curves and comparisons were made using the log rank test. A multivariate Cox regression analysis was performed to assess the clinicopathological variables from the Kaplan–Meier univariate analysis.

Results

Between January 1996 and December 2014 a total of 1591 patients were operated on for LARC or LRRC. We identified 221 patients who underwent some kind of reconstruction of the urinary tract: ileo-uretero-cutaneostomy (103/221), psoas bladder hitch procedure (70/221), partial cystectomy with primary closure (29/221), ileum interposition (8/221), uretero-ureterostomy (3/221), bladder augmentation (3/221), trans-uretero-ureterostomy (2/221), direct ureteral reimplantation (1/221), nephrectomy (1/221). In one patient the ureter was spatulated and sutured into the peritoneum, because of a non-functional kidney.

In this study we only report results for the 70 PBH patients. The indication for PBH was lateral sidewall involvement of a primary cT4 or locally recurrent rectal cancer without invasion into the bladder. The resulting gap after removement of the pelvic ureter was too large to close with direct end to end anastomosis or a tension free direct insertion to the (mobilized) bladder. Their mean age was 62 years (range 39–86); 36 were women and 34 were men. Forty-three percent (30/70) of the patients were operated on for primary T4 rectal cancer and 57% (40/70) of procedures were performed on patients with LRRC. IORT was administered to 54/70 patients: 70% and 83% respectively of the T4 and LRRC groups. The mean duration of follow-up was 78 months patients alive (range 27–177) (Table 1).

Complications

Urological complications were observed in 27/70 patients (38.6%) during follow-up. Twenty-eight complications were detected in 27 patients. Half of the urological complications occurred within the first three months after surgery. A large majority of the urological complications (85%) occurred in the first two years after surgery. Fig. 2 provides an overview of the observed urological complications. The rate of urological complications did not vary by

Table 1
Patient characteristics and complications. RTH = radiotherapy. PBH = psoas bladder hitch procedure. FU = follow-up.

	All	T4 primary rectal cancer	Locally recurrent rectal cancer	p-Value
Patients	70	30	40	
Male	34	9	25	0.007
Mean age	62	63	61	n.s.
Preoperative RTH	64 (91%)[1]	27 (93%)	33 (89%)	n.s.
Intra-operative RTH	54 (77%)	21 (70%)	33 (83%)	n.s.
R0 resections	41 (60%)[2]	26 (87%)	15 (40%)	<0.0001
Mean FU	81 months	117 months	55 months	0.006
Men FU patients alive	78 months	83 months	68 months	n.s.

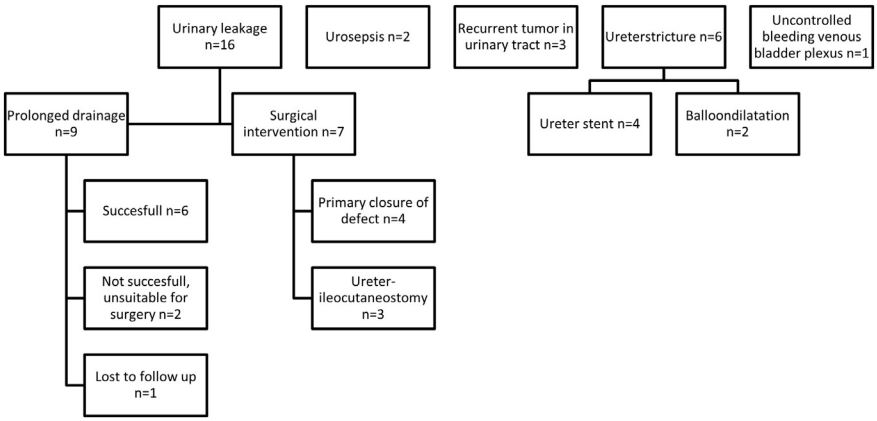

Figure 2. Occurrence and treatment of postoperative complications.

gender ($p = 0.23$) or age (groups: >60 years, ≤60 years; $p = 0.80$). Patients operated on for LRRC were marginally more likely ($p = 0.063$) to develop urological complications (48%) than those who underwent a resection for LARC (27%). In the LRRC patients the majority was re-irradiated after having had radiotherapy for their primary tumour. These patients developed significantly more urologic complications than patients who had had full course radiotherapy for their primary tumour only, or had only full course radiotherapy for their recurrence and not for their primary rectal cancer (70% versus 25% $p = 0.004$).

Urinary leakage and incidence of fistulas

The most common urological complication seen after PBH was prolonged urinary leakage, which occurred in 16/70 patients (22.9%). Leakage of urine was defined as complication if urinary leakage was detected on a cystoureterograph and/or by urinary production of the wound drains, at ≥10 days after surgery. Initially these cases were treated with prolonged drainage of the urinary tract by Foley catheter and ureter stent and in 6/16 patients the leak resolved with these conservative measures. In 8/9 patients with persisting urinary leakage imaging revealed the formation of some sort of fistula. Five patients developed a recto-vesical fistula; two patients developed a fistula between the ureter and vagina and one uretero-enteral fistula was observed. One patient with persistent urinary leakage on the first ureterogram was lost to follow up and further therapy is unknown.

In cases where conservative therapy failed and a fistula was observed surgical repair options were considered. In 4/9 patients with persisting leakage a surgical repair of the fistula was performed to close the defect; the surgical re-intervention rate was thus 5.7% (4/70). Unfortunately, in 3/9 cases reconstruction of the PBH was technically impossible and a ureter-ileo-cutaneostomy (Bricker) for urinary deviation had to be performed. Hence, the total failure rate for the PBH procedure was 4.2% (3/70). The two remaining patients (2/9) in this group were not re-operated because of severe co-morbidities.

One patient died after developing a fistula. This patient had a history of a recto-vesical fistula that had been surgically closed, but developed a fistula between the bladder and iliac vein, followed by a lethal haemorrhage.

Hydronephrosis and ureteral stricture

Postoperative hydronephrosis at the side of the PBH procedure, due to a ureteral stricture at the level of bladder-ureter anastomosis, was the second most frequent complication, observed in 6/70 (8.6%) patients. The timing of development of hydronephrosis in the sample was as follows: within one month of surgery ($n = 2$), 1–3 months later ($n = 2$), 3–5 months later ($n = 1$) and 24 months later ($n = 1$). All strictures were managed conservatively by placement of a temporary double-J-ureter stent for at least 6 weeks. In 4 patients the stricture and additional hydronephrosis resolved after removal of the stent. The other 2 patients required additional balloon dilatation of the ureter to solve the problem.

Infection

Three patients developed urosepsis in the first month after surgery; all were treated successfully with intravenous antibiotics. The specific causes of urosepsis in these patients were unknown and urosepsis was not related to other complications, such as hydronephrosis.

Renal failure

Blood levels of creatinine were checked routinely in all patients, but because creatinine clearance reflects combined functioning of both kidneys it is not an accurate index of kidney function at the PBH site. No patient was diagnosed with renal failure during follow up.

Pathology and oncological outcome

In 33/70 (47.1%) patients pathology reports revealed that the ureter was fibrotic or normal; in 11/70 (15.7%) patients the ureter had been invaded by malignant cells and in

6 of these 11 patients the margins of the resected ureter had also been invaded by malignant cells. In 26/70 (37.1%) patients the ureteric resection margin was not mentioned specifically in the pathology report.

In three PBH patients (3/70) recurrence of rectal cancer within the urinary tract was observed during follow-up. All of these patients underwent a R1 resection of the ureter. In one patient recurrent disease was found to be obstructing the remaining ureter, so a ureter stent was placed; in another patient the recurrent tumour was resected transurethrally and the third patient was treated with palliative therapy. Recurrence of malignancy was detected at 32, 36 and 66 months postoperatively, respectively.

The Kaplan–Meier survival analysis comparing survival of patients with and without complications showed that complications did not interfere with survival (Fig. 3). The median survival time was similar for patients with and without and with complications, 43 (CI 12.9–73.1) and 50 (CI 0.1–102.0) months respectively (Fig. 3). The only variables predictive of overall survival were having a T4 tumour (median survival not reached yet) or a local recurrence (median survival 34 months, CI 21.8–46.2) (Fig. 4) and radicality of resection (median survival clear margins was 137 months, CI 31.5–242.5 versus surgically involved margins 33 months, CI 21.8–46.2) (Fig. 5). After multivariate Cox regression analysis only radicality of resection remained significant (Hazard ratio 0.424 CI 0.2011–0.897, $p = 0.025$).

Discussion

In this study we have presented the long-term follow-up of a unique series of 70 patients who underwent PBH after resection of LARC or LRRC invading the ureter. The majority of patients in the sample had a successful outcome. To our knowledge, this study is the first to describe the results of PBH in this specific group of oncological patients, which was subjected to neo-adjuvant and/or intra-operative chemo- and radiotherapy for LARC and LRRC.

In our sample the overall complication rate was 38.6% (27/70). Previous studies of PBH for benign indications (e.g. endometriosis, lithiasis) have described success rates between 93.9% and 100%.[14–17] These studies describe small cohorts: the largest sample was 26 patients, but all had had no radiotherapy as part of their treatment.

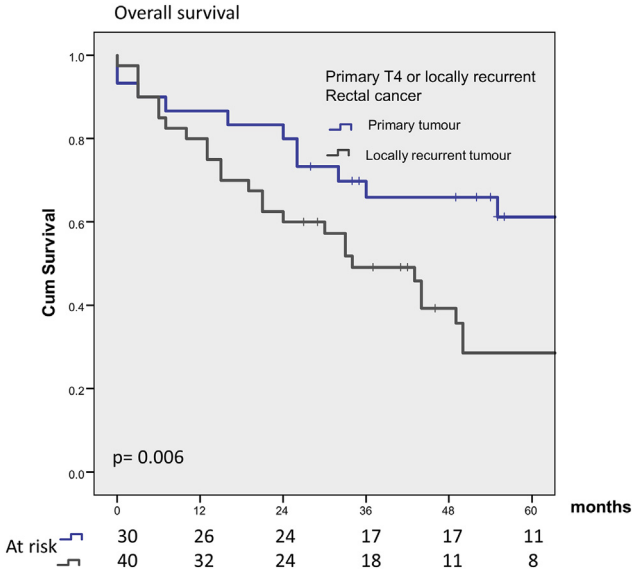

Figure 4. Kaplan–Meier overall survival curve of primary cT4 and locally recurrent rectal cancer patients.

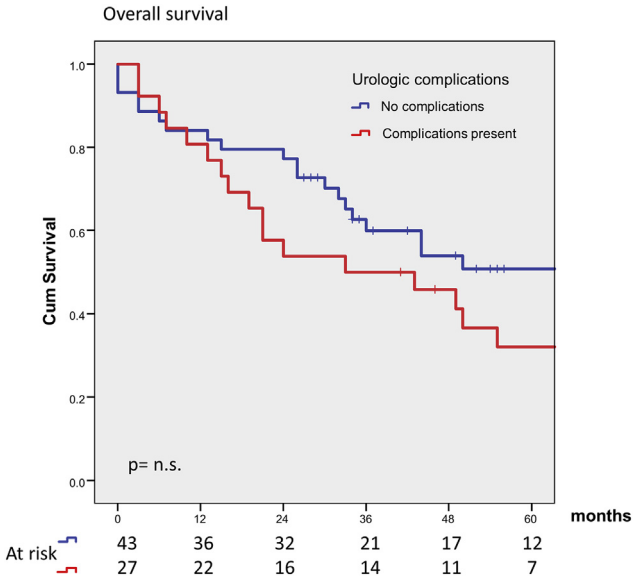

Figure 3. Kaplan–Meier overall survival curve of patients with and without complications of the PBH.

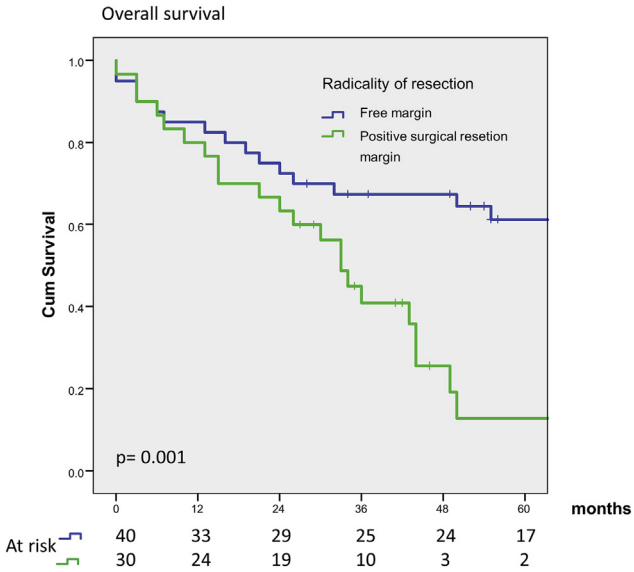

Figure 5. Kaplan–Meier overall survival curve of patients who had a free surgical resection margin and those having involved resection margins at final pathology.

Urinary tract infection and ureteric strictures were the most commonly described complications in these studies[15,16,18,19] whereas in our sample the most frequently encountered complication was urinary leakage. One possible explanation for the higher incidence of complications in our sample is impaired tissue healing because of intensive preoperative chemo- and radiotherapy. Preoperative chemoradiation therapy generally impairs wound healing, but the exact pathogenesis of this complex biochemical process remains unknown.[20,21] The prevailing impression amongst urologists is, therefore, that preoperative (chemo)radiotherapy is associated with increased ureteral leak rates but this has not been confirmed.[22] As all patients in this study underwent some kind of radiotherapy we could not analyse the specific impact of radiotherapy on healing of the ureteral anastomosis. However, it was noticed that the patients, who were re-irradiated and therefore had an accumulated total dose exceeding the fractionated biological equivalent of 80 Gy had significantly more complications, which had to bet treated.

It is important to note that all patients underwent surgery for their rectal cancer simultaneously with the PBH procedure. Rectal cancer surgery is associated with its own surgical complications, such as anastomotic leakage and sacral cavity abscess formation. Healing of the PBH anastomosis might be influenced by these surgical complications. The complication rate was higher in the LRRC group than the LARC group, which may be because the ureter was more devitalised in the LRRC group due to previous surgery and higher doses of radiotherapy in the preoperative radiotherapy regimen. A reduction in blood supply to the ureter might impair tissue healing. Although the complication rate in our sample was much higher than in studies of PBH for benign conditions, it is difficult to compare outcomes, because of the heterogeneity of the samples. In three patients (4.3%) complications resulted in permanent loss of bladder function and a construction of an ileo-cutaneostomy. Still, in all patients renal function was preserved.

In the majority of resected ureters that were invaded by tumour the pathology reports revealed fibrosis. It is notable that in all of the patients with recurrence of malignancy in the urinary tract (3/70), the margin of the resected ureter was invaded by malignant cells. It has been shown that radical resection is the most important prognostic factor for LARC and LRRC patients, so every effort must be made to achieve this.[2] In view of this inspection of fresh frozen biopsy of the ureter before construction of a PBH would have been useful.

The length of follow-up varied according to the urologist's preference. As our results show that the majority complications (85%) occurred within the first two years after surgery, we advise a follow-up of at least two years, including regular ultrasounds of the kidney and monitoring of blood levels of creatinine.

Our study has strengths and limitations. The main strength is that it is the first long-term follow-up of PBH patients in this specific oncological population. We contacted all surviving patients and also studied the records of the referring hospitals, so we believe that our follow-up is as complete as possible. A limitation of the study is its retrospective design. Furthermore, the length of follow-up was limited due to the limited survival of patients with LARC and LRRC. Although survival of LARC patients is relatively good, early disease recurrence and subsequent death is not uncommon in LRRC patients.[23,24] Our study captured standard practice and the actual incidence and course of complications in surviving patients.

We conclude that bladder-preserving PBH is feasible in LARC and LRRC patients, even after neo-adjuvant (chemo)radiotherapy and intra-operative radiotherapy, and that the associated complication rate is acceptable. Close follow-up for early management of stenosis and stricture formation is advisable. Future research should focus on functional outcome (voiding disabilities, renal failure and sexual dysfunction) of PBH and health related quality of life in PBH patients. In the earlier years of the study period we were more aggressive and performed more total excenterations in LARC and LRRC. In the last decade we have performed less extended resections of the urinary tract with comparable or better clinical and oncological outcomes.[4,22] Further research should be carried out on effect of the different types of urological reconstruction (e.g. ureter reconstruction, cystectomy, neobladders, and partial cystectomy) on functional outcome and quality of life in patients undergoing surgery for rectal cancer invading the urinary tract.

In conclusion, our bladder-preserving strategy for LARC and LRRC invading the ureter by PBH resulted in a relatively high incidence of complications, but these were temporary and relatively easily solved using a conservative approach and in the majority cases the oncological outcome was good.

Conflicts of interest

None.

Funding sources

None.

References

1. Dresen RC, Gosens MJ, Martijn H, et al. Radical resection after IORT-containing multimodality treatment is the most important determinant for outcome in patients treated for locally recurrent rectal cancer. *Ann Surg Oncol* 2008;**15**:1937–47.
2. Gosens MG, Klaassen RA, Tan-Go I, et al. Circumferential margin involvement is the crucial prognostic factor after multimodality

treatment in patients with locally advanced rectal carcinoma. *Clin Cancer Res* 2007;**13**(22):6617–23.
3. Kusters M, Marijnen CA, van de Velde CJ, et al. Patterns of local recurrence in rectal cancer; a study of the Dutch TME Trial. *Eur J Surg Oncol* 2010;**36**:470–6.
4. Carne PWG, Frye JNR, Kennedy-Smith A, et al. Local invasion of the bladder with colorectal cancers: surgical management and patterns of local recurrence. *Dis Colon Rectum* 2004;**47**:44–7.
5. Harada K, Sakai I, Muramaki M, et al. Reconstruction of urinary tract combined with surgical management of locally advanced non-urological cancer involving the genitourinary organs. *Urol Int* 2006; **76**:82–6.
6. Delacroix SE, Winters JC. Bladder reconstruction and diversion during colorectal surgery. *Clin Colon Rectal Surg* 2010;**23**:113–8.
7. Balbay MD, Slaton JW, Trane N, Skibber J, Dinney CPN. Rationale for bladder-sparing surgery in patients with locally advanced colorectal carcinoma. *Cancer* 1999;**86**:2212–6.
8. Bryk DJ, Zhao LC. Guideline of guidelines: a review of urological trauma guidelines. *Br J Urol Int* 2015;**117**:1–9.
9. Wenske S, Olsson CA, Benson MC. Outcomes of distal ureteral reconstruction through reimplantation with psoas hitch, boari flap, or ureteroneocystostomy for benign or malignant ureteral obstruction or injury. *Urology* 2013;**1**:231–6.
10. Warwick RT, Worth PH. The psoas bladder-hitch procedure for the replacement of the lower third of the ureter. *Br J Urol* 1969;**41**:701–9.
11. Bosman SJ, Holman FA, Nieuwenhuijzen GAP, Martijn H, Creemers G-J, Rutten HJT. Feasibility of reirradiation in the treatment of locally recurrent rectal cancer. *Br J Surg* 2014;**101**:1280–9.
12. van de Velde CJ, Boelens PG, Tanis PJ, et al. Experts' reviews of the multidisciplinary consensus conference colon and rectal cancer 2012: science, opinions and experiences from the experts of surgery. *Eur J Surg Oncol* 2013;**4**:454–68.
13. Dindo D, Demartines N, Clavien PA. Classification of surgical complications: a new proposal with evaluation in a cohort of 6336 patients and results of a survey. *Ann Surg* 2004;**240**:205–13.
14. Riedmiller H, Becht E, Hertle L, Jacobi G, Hohenfellner R. Psoas hitch ureteroneocystostomy. *Eur Urol* 1984;**3**:145–50.
15. Carmignani L, Ronchetti A, Amicarelli F, Vercellini P, Spinelli M, Fedele L. Bladder psoas hitch in hydronephrosis due to pelvic endometriosis: outcome of urodynamic parameters. *Fertil Steril* 2009;**92**: 35–40.
16. Manassero F, Mogorovich A, Fiorini G, Di Paola G, De Maria M, Selli C. Ureteral reimplantation with psoas bladder hitch in adults: a contemporary series with long-term followup. *Sci World J* 2012; **2012**:1–4.
17. Duijvesz D, Lock MTWT, Kraak R, Verhagen PCMS, Bosch JLHR. De psoas hitch met re-implantatie van de ureter is een betrouwbare procedure voor distale ureterpathologie. *Ned Tijdchrift Urol* 2011;**1**:2–6.
18. Ahn M, Loughlin KR. Psoas hitch ureteral reimplantation in adults − analysis of a modified technique and timing of repair. *Adult Urol* 2001; **58**:184–7.
19. Mathews R, Marshall FF. Versatility of the adult psoas hitch ureteral reimplantation. *J Urol* 1997;**158**:2078–82.
20. Wang J, Boerma M, Fu Q, Hauer-Jensen M. Radiation responses in skin and connective tissues: effect on wound healing and surgical outcome. *Hernia* 2006;**10**:502–6.
21. Straub JM, New J, Hamilton CD, Lominska C, Shnayder Y, Thomas SM. Radiation-induced fibrosis: mechanisms and implications for therapy. *J Cancer Res Clin Oncol* 2015;**141**(11):1985–94.
22. Stotland PK, Moozar K, Cardella JA, et al. Urologic complications of composite resection following combined modality treatment of colorectal cancer. *Ann Surg Oncol* 2009;**16**:2759–64.
23. van Gijn VV, Marijnen CA, Nagtegaal ID, et al. Preoperative radiotherapy combined with total mesorectal excision for resectable rectal cancer. 12-year follow-up of the multicentre, randomised controlled TME trial. *Lancet Oncol* 2011;**6**:575–82.
24. Kusters M, Valentini V, Calvo FA, et al. Results of European pooled analysis of IORT-containing multimodality treatment for locally advanced rectal cancer: adjuvant chemotherapy prevents local recurrence rather than distant metastasis. *Ann Oncol* 2010;**21**:1279–364.