Safe laparoscopic cholecystectomy: A systematic review of bile duct injury prevention

International Journal of Surgery 60 (2018) 164–172

Contents lists available at ScienceDirect

International Journal of Surgery

journal homepage: www.elsevier.com/locate/ijsu

Review

Safe laparoscopic cholecystectomy: A systematic review of bile duct injury prevention

Floyd W. van de Graaf[a,*], Ina Zaïmi[a], Laurents P.S. Stassen[b], Johan F. Lange[a]

[a] Department of Surgery, Erasmus MC - University Medical Center Rotterdam, Rotterdam, the Netherlands
[b] Department of Surgery, Maastricht University Medical Center+, Maastricht, the Netherlands

ARTICLE INFO

Keywords:
Laparoscopic cholecystectomy
Bile duct injury
Critical view of safety
Dissection technique
Peroperative imaging techniques

ABSTRACT

Background: Since the introduction of laparoscopic cholecystectomy (LC), a substantial increase in bile duct injury (BDI) incidence was noted. Multiple methods to prevent this complication have been developed and investigated. The most suitable method however is subject to debate. In this systematic review, the different modalities to aid in the safe performance of LC and prevent BDI are delineated.

Materials and methods: A systematic search for articles describing methods for the prevention of BDI in LC was conducted using EMBASE, Medline, Web of science, Cochrane CENTRAL and Google scholar databases from inception to 11 June 2018.

Results: 90 studies were included in this systematic review. Overall, BDI preventive techniques can be categorized as dedicated surgical approaches (Critical View of Safety (CVS), fundus first, partial laparoscopic cholecystectomy), supporting imaging techniques (intraoperative radiologic cholangiography, intraoperative ultrasonography, fluorescence imaging) and others. Dedicated surgical approaches demonstrate promising results, yet limited research is provided. Intraoperative radiologic cholangiography and ultrasonography demonstrate beneficial effects in BDI prevention, however the available evidence is low. Fluorescence imaging is in its infancy, yet this technique is demonstrated to be feasible and larger trials are in preparation.

Conclusion: Given the low sample sizes and suboptimal study designs of the studies available, it is not possible to recommend a preferred method to prevent BDI. Surgeons should primarily focus on proper dissection techniques, of which CVS is most suitable. Additionally, recognition of hazardous circumstances and knowledge of alternative techniques is critical to complete surgery with minimal risk of injury to the patient.

1. Introduction

With a number of 150–200 procedures per 100,000 inhabitants in Europe and the United States each year, cholecystectomy is one of the most common abdominal surgical procedures today, of which over 80% is performed laparoscopically [1,2]. Since the introduction of laparoscopic cholecystectomy (LC) its superiority compared to open cholecystectomy (OC), e.g. decreased postoperative pain and shorter length of stay, was cause of its rapid and widespread implementation. Accompanying this however, was an upsurge in the occurrence of bile duct injury (BDI), a potentially life threatening complication. Compared to an average of 0.2% in OC [3,4], the incidence of BDI encountered a drastic increase after the introduction of LC, with reported rates of up to 1.5% [5–11]. At first, this aggravation was attributed to the learning curve surgeons had to deal with [10]. Yet, higher patient numbers and operator experience did not significantly decrease the incidence of BDI [12]. Since then, considerable effort has been made to improve safety in LC with a variety of methods described in literature, reducing the incidence of BDI to around 0.23% and 0.30% [13,14]. To date however, it is unclear what contribution the different methods make in the prevention of BDI, therefore rendering it difficult to identify the most suitable method.

In this systematic review, the different modalities that might aid in the realization of safe LC are outlined with emphasis on the available evidence with regard to the prevention of BDI.

2. Material and methods

2.1. Search strategy

EMBASE, Medline, Web of science, Cochrane CENTRAL and Google scholar databases were systematically searched from inception up to 11

* Corresponding author. Department of Surgery, Erasmus MC - University Medical Center Rotterdam P.O. Box 2040, 3000 CA Rotterdam, H-822k, the Netherlands.
E-mail address: f.vandegraaf@erasmusmc.nl (F.W. van de Graaf).

https://doi.org/10.1016/j.ijsu.2018.11.006
Received 15 July 2018; Received in revised form 14 October 2018; Accepted 4 November 2018
Available online 12 November 2018

June 2018 for articles describing possible methods to avoid BDI in LC. With the assistance of an information specialist, the search was conducted in accordance with the Preferred Reporting Items for Systematic Reviews and Meta-Analyses (PRISMA) guidelines and limited to manuscripts written in the English language. The complete search strategy can be found in Appendix 1.

The work has been reported in line with AMSTAR (Assessing the methodological quality of systematic reviews) Guidelines.

2.2. Article selection and data extraction

Potentially eligible articles were reviewed by two investigators independently (IZ and FvdG). Exclusion criteria included: no description of role in BDI prevention, technical reports without study population, no full text available, non-original articles, surveys, case reports, animal or cadaveric studies, guidelines or protocols, no distinction between OC and LC, and other hepatopancreaticobiliary surgery. Discrepancies between the two investigators were resolved through consensus.

The following data were extracted from the included articles:

- Study period
- Study type
- Described method of BDI prevention
- Number of included cases
- BDI rate (number of BDIs per total number of cases)
- Bile leak rate (number of bile leaks per total number of cases)
- Success rate (successful execution of the described method per total number of cases)
- Conversion rate (the number cases converted top open resection per total number of cases)
- Authors' conclusion
- Authors' viewpoint regarding the described method

The level of evidence (according to the Oxford Centre of Evidence-Based Medicine [15]) was appraised for each inclusion. Articles were categorized according to the following BDI prevention methods:

1 Dedicated surgical approaches
- *Critical view of safety (CVS)*; the technique proposed by Strasberg et al., in 1995 to conclusively identify the cystic duct and the cystic artery and minimize misidentification [16].
- *Fundus first laparoscopic cholecystectomy (FFLC)*; The act of clamping the gallbladder at the fundus to facilitate traction during dissection alongside the liver bed towards the liver hilum. Through the natural course of dissection, the cystic duct emerges from the infundibulum and is thereby identified.
- *Laparoscopic subtotal cholecystectomy (LSC)*; Partial resection of the gallbladder, most often by transection proximal to the cystic duct. This technique makes it possible to avoid dissection in Calot's hepatobiliary triangle in case of precarious conditions.

2 Supporting imaging techniques
- *Intraoperative radiologic cholangiography (IOC)*; The practice in which a radiographic image of the biliary tree is acquired during surgical intervention by cannulating a bile duct and subsequently administering a radiographic contrast agent. In general, three different policies towards the use of IOC can be distinguished: *routine* use, *selective* use or *total omission*. Routine IOC implies that all patients planned for LC are expected to have IOC performed during the procedure. In selective use, IOC is only performed in certain circumstances, according to protocol or upon surgeons' request.
- *Intraoperative ultrasonography (IOUS)*; The visualization of transverse and longitudinal planes of not only biliary structures, but also other critical structures, such as the portal and caval veins, and the hepatic arteries by introducing a linear ultrasonography probe.
- *Fluorescence cholangiography*; The method of using a fluorescence agent to illuminate the biliary system. The best known fluorescence agent currently used is Indocyanine green (ICG), which becomes fluorescent once excited with specific wavelength light in the near infra-red (NIR) spectrum (approximately 800–825 nm) [17]. Once injected into the blood stream, ICG is excreted via the liver into bile almost exclusively [18].

3 *Other BDI prevention methods*

2.3. Data analysis

Due to the presence of conceptual heterogeneity among the included studies a quantitative synthesis is not realized. Therefore, a narrative synthesis is performed. Microsoft Excel (Microsoft Corp., Redmond, WA, USA) was used for the analysis of data. Values are represented as median and interquartile range (IQR) or mean and range.

3. Results

The initial database search resulted in 2309 articles. After removal of duplicate studies, 1429 potentially relevant articles were screened based on title and abstract, resulting in 318 records eligible for full-text review. After thorough assessment, an additional 228 articles were excluded, resulting in 90 studies to be included in this systematic review. The PRISMA flowchart presented in Fig. 1 depicts the detailed selection of studies.

Among the 90 studies, 20 covered dedicated surgical approaches (CVS in 7 studies [19–25], FFLC in 6 [26–31], LSC in 7 [32–38]). Supporting imaging techniques were investigated in 69 (IOC in 45 studies, [39–83] IOUS in 8 studies [76–78,84–88], fluorescence imaging in 16 studies [79,89–103]). Other methods were described in 5 studies [104–108]. Detailed characteristics of these studies are represented in supplemental Table 1 through 5 (Appendix 2). Overall, the results of 203,368 patients in total were presented in the included articles (with an average per article of 2285 patients (range 12–51,041). 68 studies reported BDI rates, a total of 1104 incidents. The mean reported BDI rate was 0.23% (range 0%–3.1%).

Supplemental Figure 1 depicts the studies included in this systematic review in order of publication date and the time periods of inclusion. Note that the primary method investigated before the turn of the century was IOC. Thereafter, other modalities of BDI prevention were starting to be explored.

4. Dedicated surgical approaches

A summary of findings of the articles covering dedicated surgical approaches is presented in Table 1.

4.1. Critical view of safety

Seven studies were included in this systematic review covering the use of CVS [19–25]. Within these articles, encompassing over 5000 cases in total (average of 818 patients per study; range 54–3042), one BDI was reported by Yegiyants et al. among 3042 cases (incidence 0.03%) [25]. Overall, the median reported success rate of CVS was 95.8% (IQR 95.4%–100%). The median reported conversion rate was 0.95% (IQR 0–2.4%).

4.2. Fundus first laparoscopic cholecystectomy

Six studies described FFLC [26–31]. A median of 32 FFLC procedures were performed (IQR 22–46). The conversion rate in these series was lower than the general conversion rate in LC, with a median of 0.3% (IQR 0–1.2%). Mahmud et al. described a conversion rate of 1.2% among 710 LCs, of which 35 by way of FFLC [27]. The authors also reported that, without the use of FFLC in this study, conversion would have been necessary in 28 cases having received FFLC, what would have resulted in a potential conversion rate of 5.2%. Tuveri et al.

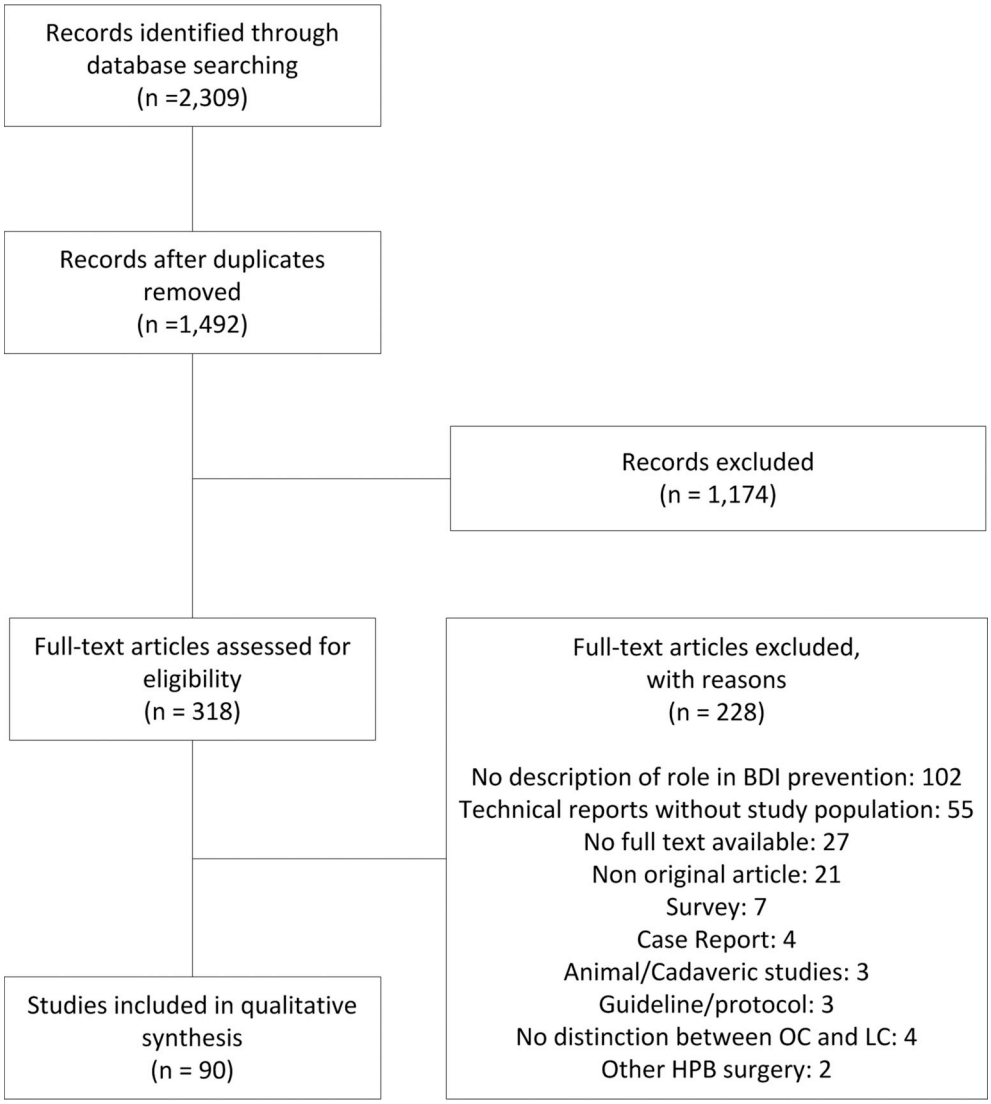

Fig. 1. Prisma flow-chart.

conducted a large retrospective study (1965 LCs; 29 FFLCs), in which two BDIs occurred (none in the FFLCS group) [31]. It was also noted that a significantly larger amount of complications occurred in the FFLC group than in the conventional LC group (20% vs. 1.4% respectively). Both the studies by Mahmud et al. and Tuveri et al. respectively reported dense adhesions (40% and 51%), followed by impacted stones in Hartmann's pouch (29% and 17%) and a short dilated CD (17% and 14%) as most common indications of resorting to FFLC.

4.3. Laparoscopic subtotal cholecystectomy

7 articles covered LSC [32–38]. A median of 39 LSC procedures have been performed (IQR 26–47), accounting for a median of 9.1% of LC cases in these articles (IQR 6.3%–10.3%). The median reported number of bile leaks was 6.3% (IQR 0.85%–12.5%). Beldi et al. compared their institution's experience in LSC with a national database, reporting a significantly lower conversion rate in cases with acute cholecystitis (9.7%–23.2% respectively) [32]. LSC was attempted in 46 of 345 cases (13.3%) with subsequent conversion deemed necessary in approximately one fifth of the patients. The posterior wall was left in situ in all LSC patients and the infundibulum in 26.1% of the cases. No bile duct injury was reported. Nakajima et al. compared two periods: before and after the introduction of LSC in their institution [35]. Before introduction, the BDI incidence was reported to be 1.6% with a conversion rate of 2.5%. after introduction LSC was performed in 10.3% of the LC cases with both BDI incidence and conversion rate significantly

Table 1
Dedicated surgical approaches – summary of findings.

BDI prevention technique	*N* Studies	N Cases		Median Success rate
		Total	Average per study	
Critical View of Safety	7	5728	818 (54–3042)	95.8% (95.4–100)
Fundus First Laparoscopic Cholecystectomy	6	3094	516 (16–53)	89% (84.5–93.5)
Subtotal Laparoscopic Cholecystectomy	7	6196	885 (23–60)	90.2% (85.3–95.1)

Values represent total, average (range) or median (interquartile range) of reported outcomes among included studies

Table 2
Intraoperative Radiologic Cholangiography and Intraoperative Ultrasonography – summary of findings.

BDI prevention technique		*N* Studies	N Cases	Average per study	Median success rate	Median BDI Incidence
			Total			
Intraoperative Radiologic Cholangiography	*Overall*	45	155,105	4432 (50–51,041)	89% (78.5–94)	0.18% (0–0.38)
	Routine	15	76,894	5126 (100–51,041)	94% (88.5–96.3)	0.025% (0–0.29)
	Selective	4	33,455	8364 (75–31,838)	76.3% (75.7–85.2)	0.15% (0–0.3)
	Omission	10	9935	994 (82–2038)	X	0.28% (0.02–0.53)
Intraoperative Ultrasonography		8	3360	420 (43–1381)	88.8% (78.5–94)	0% (0–0.6)

Values represent total, average (range) or median (interquartile range) of reported outcomes among included studies.

dropping to 0.3% each.

5. Supporting imaging techniques

5.1. Intraoperative radiologic cholangiography

The key findings of articles covering IOC are summarized in Table 2.

One RCT was included in this systematic review [41]. The authors of this study randomized 404 patients to either conventional LC or LC combined with routine IOC. No significant differences were reported between the two groups in regards to BDI rate, conversion rate or bile leaks. Therefore the authors concluded that IOC as an adjunctive to LC had no significant effect on the reported success rates of LC or BDIs. In a retrospective study performed by Flum et al. covering 30,630 LCs, a significant reduction in BDI rate was observed with concurrent IOC use, about 40% less (2.0 vs. 3.3 per 1000 cases) [43]. It was thereby noted that the majority of BDIs occurred in earlier parts of the learning curve. Fletcher et al. reviewed cases of BDI to assess possible risk factors [42]. The authors concluded that approximately one third of BDI cases could be prevented by performing IOC.

5.1.1. Routine and selective use of IOC

Fifteen articles primarily addressed the *routine* use of IOC [44–58]. Among an average of 5126 patients per study (range 100–51,041), the median reported BDI incidence was 0.025% (IQR 0–0.285%).

Tornqvist et al. obtained the data of 51,041 patients operated between 2005 and 2010 from the national Swedish Registry for Gallstone Surgery (GallRiks) [56]. In this retrospective cohort study, 747 BDIs – graded according to the Hannover criteria (109) – were identified (incidence 1.5%). In patients suffering from concurrent cholecystitis, a significant protective effect was demonstrated by applying IOC. Alvarez et al. retrospectively evaluated the routine use of IOC (successfully performing cholangiography in over 95% of the cases) in 11,423 consecutive LCs [44]. Twenty patients suffered from BDI (0.17%) of which 18 were diagnosed and managed peroperatively. The sensitivity and specificity for the detection of BDI in this study was 79% and 100% respectively.

Four articles addressed the *selective* use of IOC [59–62]. With an average of 8364 patients per study, the median reported BDI incidence was 0.15% (IQR 0–0.3%). IOC was attempted in a median of 29% of the cases (IQR 11.8%–34.6%). Giger et al. performed a retrospective analysis of 31,838 LC cases entered in a prospectively maintained nationwide database [59]. 101 BDIs (0.3%) were observed among these cases. IOC was performed in 36.6% of LCs, among which 39.6% of BDIs were observed. IOC did not seem to reduce the amount of BDIs in this study, as no significant differences were found between the groups. The amount of BDIs that were missed during surgery also did not show a significant difference (10% and 8% - IOC and no IOC respectively).

Three other studies directly compared a routine IOC policy with selective use of IOC [63–65]. One of these studies (n = 835) concluded that routine IOC was superior in comparison with a selective approach [64], while two studies (n = 334 and 319 respectively) found no superiority in a routine policy considering BDI rates [63,65].

5.1.2. Omission of IOC

Ten studies were included in this systematic review that evaluated the safety of LC *without* the use of IOC [66–75]. In these studies any specific surgical techniques as described above were not mentioned. The median reported BDI incidence without the use of IOC was 0.28% (IQR 0.02–0.53%). Comparing the reported rates of conversion among the included studies in this review, the median conversion rate of the articles without IOC was 3.1% (IQR 2.5%–5.1%), versus a median of 3.5% (IQR 1.8%–5.8%) reported by studies employing either *routine* or *selective* IOC. The prospective study by Mir et al. demonstrated that, in rural hospitals in a developing country, where a minimalistic setting applies and costly interventions like IOC are undesirable or even unavailable, safe LC was also possible [70]. Despite their restrictions, the authors report a BDI incidence of 0.08% and conversion rates of 1.8%, all having been acquired through application of safe dissection techniques. In 1993, Barkun et al. reported a BDI incidence of 0.38% while employing a very low IOC rate (4.2%), achieving a rate similar as has been reported elsewhere in literature [66]. Taylor et al. reported the outcomes of 2038 LC cases without the use of IOC after retrospective review [73]. BDI was reported in 1.1%, of which 18.2% required additional surgery postoperatively. Zacharakis et al. reported a BDI rate of 0.37% in 1851 patients who underwent LC without an IOC, which were found to be comparable with the reported rates after an LC with routine use of an IOC [75].

5.1.3. Other applications of IOC

Three articles reported results of performing IOC through the gallbladder (cholecystocholangiography) [80–82]. All three studies agreed that cholecystocholangiography is a simpler method of employing IOC compared to the CD method. Noji et al. and Liyanage et al. addressed a method of preoperative endoscopic placement of an endo-nasal biliary drainage tube (ENBD), through which cholangiography could be performed, avoiding the chance of BDI as a consequence of the cannulation process [52,83]. Both recommended the use of ENBD, particularly in cases in which the patient is to undergo preoperative ERCP.

6. Intraoperative ultrasonography

A summary of findings regarding IOUS are delineated in Table 2.

The largest study was performed by Machi et al., investigating 1381 LC cases with routine IOUS [86]. In this article, successful imaging using IOUS was reported in 98% of the cases. Overall, the reported accuracy among the studies was similarly high, with a median reported overall identification rate of biliary structures of 97% (IQR 95.9%–97%) [76–78,85–88]. Five studies reported BDI incidence [76,84–87]. Of these five, the studies of Biffl et al. and Hakamada et al. had occurrences of BDI (0.6% and 1.1% respectively) [84,85]. The other three reported none. When explored in more detail, the reported BDIs in these two articles all occurred in the group in which IOUS was not used.

Table 3
Fluorescence Cholangiography - summary of findings.

N Studies on Fluorescence Cholangiography	N Cases		Median identification rate			
	Total	Average per study	*CHD*	*CD-CHD Confluence*	*CD*	*CBD*
16	863	54 (12–184)	75.7% (62.4–93.8)	87.8% (77.8–97.8)	100% (97.8–100)	87.3% (83–98.5)

Values represent total, average (range) or median (interquartile range) of reported outcomes among included studies. *CHD* common hepatic duct, *CD* cystic duct, *CBD*

7. Fluorescence imaging

The main findings of fluorescence imaging are summarized in Table 3.

The primary focus of the studies covering fluorescence cholangiography is the evaluation of feasibility and the biliary detection rates. No BDIs were reported in any of these studies. For the extrahepatic biliary system, the studies investigating ICG-NIR reported the following median detection rates of biliary structures: 75.7% for the CHD (IQR 62.4%–93.8%); 87.8% for the CD-CHD confluence (IQR 77.8%–97.8%); 100% for the CD (range 97.8%–100%); 87.3% for the CBD (83%–98.5%). While the majority of the articles utilize ICG-NIR to map the biliary tree, Mohsen et al. achieved fluorescence imaging of biliary structures through administration of a fluorescein solution and subsequent exposure to UV-A, visualizing the bile ducts in 82.5% of the time whilst demonstrating true negative results for other tissue in all cases [98].

8. Comparison of techniques and other preventive measures

8.1. Comparison of techniques

Three articles compared IOC with the use of IOUS [76–78]. IOUS was favored over IOC in all, on account of technical availability, success rate in the examination of the biliary tree and the absence of radiation and contrast solution. In the study by Osayi et al. both ICG-NIR and routine IOC were performed during the same procedure, comparing their measurements [79]. The main study focus was safety and the role of ICG-NIR in the identification of biliary anatomy. CD detection rates were superior compared to IOC (95.1% vs. 72.0% respectively). Furthermore, IOC was unobtainable in 24.4% of the IOC cases compared to an inability to visualize biliary structures in 4.9% using the ICG-NIR technique.

8.2. Other preventive measures

Apart from the main techniques mentioned above, several other methods have been investigated. Cai et al. reported over a decade's experience with hydrodissection combined with blunt dissection using the suction tube to expose Calot's hepatobiliary triangle, having applied this technique in 21,497 patients [104]. In this series BDI incidence was reported to be 0.09%, with a conversion rate of 1.1%. Li et al. introduced a 4-point grading system to evaluate intraoperative unfavorable factors (IUF) as a decision aid for the use of IOC and/or conversion to OC [105]. The purpose of this study was to validate this tool by comparing safety of LC before (n = 384) and after introduction (n = 396). After implementation, a significant increase in conversion rate was observed (1.6%–5.4%), while the BDI rate dropped from 1.3% to zero. No significant differences in postoperative morbidity and mortality were observed.

Three articles reported alternative methods to directly visualize the biliary system, either by way of methylene blue dye injection or light cholangiography [106–108]. Xu et al. compared methylene blue cholangiography with light cholangiography, favoring the latter, demonstrating clear images of the biliary tree using an optic fiber introduced via duodenoscopy [108].

9. Discussion

As a much dreaded complication of LC, BDI has been widely researched. In this systematic review, the largest to date within this topic, we have provided a critical analysis of the different modalities currently employed for its prevention. We have noted however that research yielding a high level of evidence is difficult to perform and consequently scarce. In a recent perspective written by Strasberg and Brunt it was emphasized that, despite the numerous major BDIs that still occur, the amount of injuries per number of LCs is relatively low [110]. This makes it incredibly difficult to organize a proper RCT. Therefore, low sample size is a recurrent problem in the search for valid literature. A different problem we encountered is the inconsistency of BDI reporting. For instance, different BDI classification systems are currently in use [111]. Some studies report BDI according to one of these classification systems, for instance Tornqvist et al. [56] employing the Hannover classification [109], whilst others report terms like ‘major BDI’ or ‘common bile duct injury’. The nature of these unclassified injuries are frequently unclear, making the true incidence of BDI caused by iatrogenic damage difficult to estimate.

Despite the aforementioned problem involving low power among studies, the articles describing CVS report just one BDI in over 5000 cases, the lowest reported incidence of BDI in literature with regard to a specific technique for prevention of BDI. This might suggest that CVS would be a capable method to conduct safe LC. However, CVS requires a thorough knowledge of biliary surgical anatomy with special reference that Calot's hepatobiliary triangle has to be unfolded completely and overseen correctly after mobilization of the gallbladder neck from the liver. A recent survey has demonstrated that, despite the fact that CVS was well-known overall, many respondents, senior surgeons in particular, were not able to adequately discern the essential steps of this technique [112]. In an effort to create awareness among the practicing surgeons, the Society of American Gastrointestinal and Endoscopic Surgeons (SAGES) has implemented CVS in its SAGES Safe Cholecystectomy Program, as part of their general culture of safety program [113].

CVS is more likely to function well in uncomplicated LCs, while in case of acute inflammation, fibrosis, or adhesions, a safe dissection within Calot's hepatobiliary triangle is often impeded. In these cases a different approach should be considered. Conversion to open cholecystectomy might come to mind in these situations. Conversion does not necessarily facilitate easier operation however, as conditions do not change and visibility might be equally poor. FFLC or LSC are techniques that could be employed in these circumstances instead of conversion.

Bile leak rates were higher among LSC cases in this review. The median reported number of bile leaks was 6.3%, compared to the 0.35% reported in standard LC [114]. This could probably be attributed to the incomplete resection of the gallbladder and incomplete closure of the residual infundibulum. The morbidity associated with these bile leaks however is moderate: only 1.4%–15% of bile leaks require an (endoscopic) intervention [32,115].

IOC has been a comprehensively investigated, yet highly debated method in both conventional and laparoscopic cholecystectomy. Ever since the moment it was first described by Mirizzi in 1931 [116]. IOC has demonstrated to be a helpful tool in both prevention and intraoperative recognition of BDI. However, definitive recommendation

to employ this technique routinely, selectively or not at all cannot be given because of the low evidence available studies are coping with. Due to the same reason, a review by Ford et al. made a similar conclusion: no robust evidence currently exists to either support or abandon the use of IOC in the prevention of BDI [117]. Also, IOC use is highly variable across the world. For example, IOC use is customary in the UK and the USA; two surveys among surgeons demonstrated mass use of IOC in these countries, with 93%–99% of surgeons reported to use IOC – among which 24%–27% used the technique routinely [118,119]. In contrast, IOC is rarely used outside these parts of the world [120,121]. Moreover, since the wide availability of endoscopic retrograde cholangiopancreatography (ERCP) and magnetic resonance cholangiopancreatography (MRCP), the necessity to perform IOC has been diminished greatly [122]. This development has already led to surgical trainees lacking exposure to IOC, which is unfavorable if this technique is to be incorporated in surgical practice [112]. Furthermore, IOC is prone to failure. The median reported success rate was 89% among the included studies and none established a perfect record. Even if a successful IOC is achieved, i.e. successful cannulation and mapping of the biliary tree on a radiological image, this does not equal correct interpretation. Advocates for omission of IOC also state that proper dissection techniques in favorable circumstances do not necessarily call for IOC and this technique might even be harmful to the patients due to the additional operative time and the risk of iatrogenic major BDI [50,61,66].

IOUS is another method to identify biliary structures, yet less invasive than IOC. It has the potential to achieve high accuracy, with reports of completely visualizing the biliary tract in 92%–100% of cases, with a failure rate that is lower than IOC [123]. Furthermore, in theory IOUS could be repeated an infinite amount of times with negligible harm to the patient on account of its non-invasive nature, without the need of radiologic contrast solutions or cannulation of a ductal structure. An apparent disadvantage is the learning curve in the performance and interpretation of the ultrasonogram, which has previously been described as ten or even up to thirty cases [124,125]. Despite these advantages, the evidence in support of IOUS as a preventive measure of BDI is scarce and therefore decisive recommendation cannot be given.

Upcoming modalities such as fluorescence imaging could function as a minimally invasive and easy to perform extension to conventional LC. ICG-NIR allows for repeatable and real time exploration of the biliary system, something that is not possible with radiological IOC due to safety limits in radiation exposure and iodine contrast administration and that is difficult to achieve with IOUS. ICG-NIR provides good detection rates of biliary structures, with specifically high detection rates of the cystic duct. Furthermore, new methods within the field of fluorescence cholangiography are currently being developed, of which in particular direct intragallbladder injection of ICG is promising, providing higher contrast due to the reduced ICG accumulation in the liver as seen after systemic administration [126].

A limitation to the articles evaluating fluorescence cholangiography is that the moments when biliary structures are detected are quite inconsistent; some measurements are made before dissection of Calot's hepatobiliary triangle, whilst some are made thereafter. A recent review evaluating the utility of ICG-NIR cholangiography reported similar results in terms of for the intraoperative visualization of the biliary system [127]. Important deficiencies of the technique however were also noted. Mainly, the limited tissue penetration of light prohibited the deeper intrahepatic ducts, as well as extrahepatic ducts obscured by (inflamed) tissue to be adequately visualized.

In the current systematic review, the primary aim of the studies investigating fluorescence imaging was to obtain information regarding the feasibility and safety. From the results provided it can be concluded that the technique of ICG-NIR imaging is indeed feasible and safe. The following step is to properly study the benefits of fluorescence imaging on a larger scale. Hence a multicenter randomized controlled trial comparing LC assisted by ICG-NIR cholangiography with conventional LC is initiated in the Netherlands [128].

10. Conclusion

Many methods used in the prevention of BDI have demonstrated promising results, yet lack sufficient power. To execute a high volume multicenter study providing the high level of evidence necessary however is very challenging. Furthermore, there is great need for consensus regarding a systematic reporting system of BDI to adequately determine the true incidence of BDI and, not in the least, discern between the severity of injuries. For the time being, it is advisable to focus on proper dissection techniques while following the basic principles of biliary surgery, of which CVS seems arguably the preferred method. Moreover, when conventional dissection proves to be too hazardous, a sufficient attention to alternative techniques should be apprehended.

Disclosures

The authors have no conflicts of interest or financial ties to disclose.

Provenance and peer review

Not commissioned, externally peer-reviewed.

Conflicts of interest

FW van de Graaf: None.
I Zaïmi: None.
LPS Stassen: Stortz GmbH (financial support of PhD project not related to the present study/manuscript).
JF Lange: None.

Sources of funding

None.

Ethical approval

N/A.

Research registration unique identifying number (UIN)

Open Science Framework (OSF) DOI 10.17605/osf.io/pqjuw https://osf.io/pqjuw/

Author contribution

FW van de Graaf: Study design, data collections, data analysis, writing.
I Zaïmi: Study design, data collections, data analysis, writing.
LPS Stassen: Study design, data analysis, writing.
JF Lange: Study design, data analysis, writing.

Acknowledgements

We would like to thank Mr. W.M. Bramer for his assistance in formulating and executing the search strategy.

Appendix A. Supplementary data

Supplementary data to this article can be found online at https://doi.org/10.1016/j.ijsu.2018.11.006.

References

[1] Eurostat, Surgical Operations and Procedures Statistics. Eurostat; October 2016, (22 February 2017) http://ec.europa.eu/eurostat/statistics-explained/index.php/Surgical_operations_and_procedures_statistics.
[2] Healthcare Cost and Utilization Project (HCUP). Surgeries in Hospital-based Ambulatory Surgery and Hospital Inpatient Settings, Agency for Healthcare Research and Quality, Rockville, MD, USA, 2014.
[3] H.R. Bernard, T.W. Hartman, Complications after laparoscopic cholecystectomy, Am. J. Surg. 165 (4) (1993) 533–535 1993/04/01/.
[4] R.M. Girard, M. Morin, Open cholecystectomy: its morbidity and mortality as a reference standard, Can. J. Surg. 36 (1) (1993 Feb) 75–80 PubMed PMID: 8443723.
[5] A prospective analysis of 1518 laparoscopic cholecystectomies. The Southern Surgeons Club, N. Engl. J. Med. 324 (16) (1991 Apr 18) 1073–1078 PubMed PMID: 1826143. Epub 1991/04/18.
[6] L. Caputo, D.R. Aitken, M.C. Mackett, A.E. Robles, Iatrogenic bile duct injuries. The real incidence and contributing factors–implications for laparoscopic cholecystectomy, Am. Surg. 58 (12) (1992 Dec) 766–771 PubMed PMID: 1456604. Epub 1992/12/01.
[7] D.R. Fletcher, M.S. Hobbs, P. Tan, et al., Complications of cholecystectomy: risks of the laparoscopic approach and protective effects of operative cholangiography: a population-based study, Ann. Surg. 229 (4) (1999 Apr) 449–457 PubMed PMID: 10203075. Pubmed Central PMCID: 1191728. Epub 1999/04/15.
[8] B. Tornqvist, C. Stromberg, G. Persson, M. Nilsson, Effect of intended intraoperative cholangiography and early detection of bile duct injury on survival after cholecystectomy: population based cohort study, BMJ (2012 Oct 11) 345 e6457. PubMed PMID: 23060654.
[9] X. Huang, Y. Feng, Z. Huang, Complications of laparoscopic cholecystectomy in China: an analysis of 39,238 cases, Chinese Med J 110 (9) (1997 Sep) 704–706 PubMed PMID: 9642330. Epub 1998/06/27.
[10] L. Morgenstern, M.F. McGrath, B.J. Carroll, et al., Continuing hazards of the learning curve in laparoscopic cholecystectomy, Am. Surg. 61 (10) (1995) 914–918.
[11] A. Waage, M. Nilsson, Iatrogenic bile duct injury: a population-based study of 152 776 cholecystectomies in the Swedish inpatient registry, Arch. Surg. 141 (12) (2006) 1207–1213.
[12] S.B. Archer, D.W. Brown, C.D. Smith, et al., Bile duct injury during laparoscopic cholecystectomy: results of a national survey, Ann. Surg. 234 (4) (2001) 549–559 PubMed PMID: PMC1422078.
[13] M. Barrett, H.J. Asbun, H.-L. Chien, L.M. Brunt, D.A. Telem, Bile duct injury and morbidity following cholecystectomy: a need for improvement, Surg. Endosc. 32 (4) (2018 Apr) 1683–1688, https://doi.org/10.1007/s00464-017-5847-8 Epub 2017 Sep 15. PubMed PMID: 28916877.
[14] J. Rystedt, G. Lindell, A. Montgomery, Bile duct injuries associated with 55,134 cholecystectomies: treatment and outcome from a national perspective, World J. Surg. 40 (1) (2016 January 01) 73–80.
[15] OCEBM Levels of Evidence Working Group, The Oxford Levels of Evidence 2. Oxford Centre for Evidence-based Medicine, University of Oxford, 2011.
[16] S.M. Strasberg, M. Hertl, N.J. Soper, An analysis of the problem of biliary injury during laparoscopic cholecystectomy, J. Am. Coll. Surg. 180 (1) (1995) 101–125.
[17] M.L. Landsman, G. Kwant, G.A. Mook, W.G. Zijlstra, Light-absorbing properties, stability, and spectral stabilization of indocyanine green, J. Appl. Physiol. 40 (4) (1976 Apr) 575–583 PubMed PMID: 776922.
[18] J.T. Alander, I. Kaartinen, A. Laakso, et al., A review of indocyanine green fluorescent imaging in surgery, Int. J. Biomed. Imag. 2012 (2012) 940585 PubMed PMID: 22577366.
[19] C. Avgerinos, D. Kelgiorgi, Z. Touloumis, et al., One thousand laparoscopic cholecystectomies in a single surgical unit using the "critical view of safety" technique, J. Gastrointest. Surg. 13 (3) (2009) 498–503.
[20] B. Kaya, M.M. Fersahoglu, F. Kilic, et al., Importance of critical view of safety in laparoscopic cholecystectomy: a survey of 120 serial patients, with no incidence of complications, Ann Hepato Biliary pancreat surg 21 (1) (2017 Feb) 17–20 PubMed PMID: 28317041.
[21] A. Rawlings, S.E. Hodgett, B.D. Matthews, et al., Single-Incision laparoscopic cholecystectomy: initial experience with critical view of safety dissection and routine intraoperative cholangiography, J. Am. Coll. Surg. 211 (1) (2010) 1–7.
[22] K. Tsalis, N. Antoniou, Z. Koukouritaki, et al., Open-access technique and "critical view of safety" as the safest way to perform laparoscopic cholecystectomy, Surg. Laparosc. Endosc. Percutaneous Tech. 25 (2) (2015) 119–124.
[23] N. Vettoretto, C. Saronni, A. Harbi, et al., Critical view of safety during laparoscopic cholecystectomy, J. Soc. Laparoendosc. Surg. 15 (3) (2011) 322–325.
[24] P. Sanjay, J.L. Fulke, D.J. Exon, 'Critical view of safety' as an alternative to routine intraoperative cholangiography during laparoscopic cholecystectomy for acute biliary pathology, J. Gastrointest. Surg. 14 (8) (2010) 1280–1284.
[25] S. Yegiyants, J.C. Collins, Operative strategy can reduce the incidence of major bile duct injury in laparoscopic cholecystectomy, Am. Surg. 74 (10) (2008) 985–987.
[26] H. Cui, J.J. Kelly, D.E.M. Litwin, Single-incision laparoscopic cholecystectomy using a modified dome-down approach with conventional laparoscopic instruments, Surg Endosc Interv Tech 26 (4) (2012) 1153–1159.
[27] S. Mahmud, M. Masaud, K. Canna, A.H.M. Nassar, Fundus-first laparoscopic cholecystectomy: a safe means of reducing the conversion rate, Surg Endosc Interv Tech 16 (4) (2002) 581–584.
[28] I.G. Martin, S.P. Dexter, J. Marton, et al., Fundus-first laparoscopic cholecystectomy, Surg. Endosc. 9 (2) (1995) 203–206.
[29] P.K. Raj, G. Castillo, L. Urban, Laparoscopic cholecystectomy: fundus-down approach, J. Laparoendosc. Adv. Surg. Tech. Part A 11 (2) (2001) 95–100.
[30] J. Rosenberg, T. Leinskold, Dome down laparosonic cholecystectomy, Scand. J. Surg. 93 (1) (2004) 48–51.
[31] M. Tuveri, P.G. Calo, F. Medas, et al., Limits and advantages of fundus-first laparoscopic cholecystectomy: lessons learned, J. Laparoendosc. Adv. Surg. Tech. 18 (1) (2008 Feb) 69–75 PubMed PMID: 18266578.
[32] G. Beldi, A. Glättli, Laparoscopic subtotal cholecystectomy for severe cholecystitis: a follow-up study, Surg. Endosc. 17 (9) (2003) 1437–1439.
[33] C. Hubert, L. Annet, B.E. Van Beers, J.F. Gigot, The "inside approach of the gallbladder" is an alternative to the classic Calot's triangle dissection for a safe operation in severe cholecystitis, Surg Endosc Interv Tech 24 (10) (2010) 2626–2632.
[34] J. Kuwabara, Y. Watanabe, K. Kameoka, et al., Usefulness of laparoscopic subtotal cholecystectomy with operative cholangiography for severe cholecystitis, Surg. Today 44 (3) (2014) 462–465.
[35] J. Nakajima, A. Sasaki, T. Obuchi, et al., Laparoscopic subtotal cholecystectomy for severe cholecystitis, Surg. Today 39 (10) (2009) 870–875.
[36] J.A.E. Philips, D.A. Lawes, A.J. Cook, et al., The use of laparoscopic subtotal cholecystectomy for complicated cholelithiasis, Surg Endosc Interv Tech 22 (7) (2008) 1697–1700.
[37] Y. Tian, S.D. Wu, Y. Su, et al., Laparoscopic subtotal cholecystectomy as an alternative procedure designed to prevent bile duct injury: experience of a hospital in Northern China, Surg. Today 39 (6) (2009) 510–513.
[38] P.D. Yoon, T. Pang, M. Siriwardhane, et al., Laparoscopic partial cholecystectomy: a way of getting out of trouble, Int. J. Hepatobiliary Pancreat. Dis. 6 (2016 Aug) 68–75 PubMed PMID: WOS:000384378500001. English.
[39] D. Akolekar, S.J. Nixon, R.W. Parks, Intraoperative cholangiography in modern surgical practice, Dig. Surg. 26 (2) (2009) 130–134.
[40] E. Caratozzolo, M. Massani, A. Recordare, et al., Usefulness of both operative cholangiography and conversion to decrease major bile duct injuries during laparoscopic cholecystectomy, J. Hepato-Biliary-Pancreatic Surg. 11 (3) (2004) 171–175.
[41] G.Q. Ding, W. Cai, M.F. Qin, Is intraoperative cholangiography necessary during laparoscopic cholecystectomy for cholelithiasis? World J. Gastroenterol. 21 (7) (2015) 2147–2151.
[42] D.R. Fletcher, M.S.T. Hobbs, P. Tan, et al., Complications of cholecystectomy: risks of the laparoscopic approach and protective effects of operative cholangiography: a population-based study, Ann. Surg. 229 (4) (1999) 449–457.
[43] D.R. Flum, T. Koepsell, P. Heagerty, et al., Common bile duct injury during laparoscopic cholecystectomy and the use of intraoperative cholangiography: adverse outcome or preventable error? Arch. Surg. 136 (11) (2001) 1287–1292.
[44] F.A. Alvarez, M. De Santibañes, M. Palavecino, et al., Impact of routine intraoperative cholangiography during laparoscopic cholecystectomy on bile duct injury, Br. J. Surg. 101 (6) (2014) 677–684.
[45] B.J. Carroll, R.L. Friedman, M.A. Liberman, E.H. Phillips, Routine cholangiography reduces sequelae of common bile duct injuries, Surg. Endosc. 10 (12) (1996) 1194–1197.
[46] M.R. Cox, T.G. Wilson, P.L. Jeans, et al., Minimizing the risk of bile duct injury at laparoscopic cholecystectomy, World J. Surg. 18 (3) (1994) 422–427.
[47] K. Ido, N. Isoda, C. Kawamoto, et al., Confirmation of a "safety zone" by intraoperative cholangiography during laparoscopic cholecystectomy, Surg. Endosc. 10 (8) (1996 Aug) 798–800 PubMed PMID: 8694940.
[48] D.B. Jones, D.L. Dunnegan, N.J. Soper, et al., Results of a change to routine fluorocholangiography during laparoscopic cholecystectomy, Surgery 118 (4) (1995) 693–702.
[49] E. Kullman, K. Borch, E. Lindström, et al., Value of routine intraoperative cholangiography in detecting aberrant bile ducts and bile duct injuries during laparoscopic cholecystectomy, Br. J. Surg. 83 (2) (1996) 171–175.
[50] A. Kumar, U. Kumar, A. Munghate, A. Bawa, Role of routine intraoperative cholangiography during laparoscopic cholecystectomy, Surg Endosc Interv Tech 29 (9) (2015) 2837–2840.
[51] A.H.M. Nassar, A. Mirza, H. Qandeel, et al., Fluorocholangiography: reincarnation in the laparoscopic era—evaluation of intra-operative cholangiography in 3635 laparoscopic cholecystectomies, Surg Endosc Interv Tech 30 (5) (2016) 1804–1811.
[52] T. Noji, F. Nakamura, T. Nakamura, et al., ENBD tube placement prior to laparoscopic cholecystectomy may reduce the rate of complications in cases with predictably complicating biliary anomalies, J. Gastroenterol. 46 (1) (2011) 73–77.
[53] O.N.M. Panton, A.G. Nagy, C.H. Scudamore, R.J. Panton, Laparoscopic cholecystectomy: a continuing plea for routine cholangiography, Surg. Laparosc. Endosc. 5 (1) (1995) 43–49.
[54] E.S. Photi, A. El-Hadi, S. Brown, et al., The routine use of cholangiography for laparoscopic cholecystectomy in the modern era, J. Soc. Laparoendosc. Surg. : J. Soc. Laparoendosc. Surg. 21 (3) (2017) (English).
[55] S.A. Stuart, T.I.G. Simpson, L.A. Alvord, M.D. Williams, Routine intraoperative laparoscopic cholangiography, Am. J. Surg. 176 (6) (1998) 632–637.
[56] B. Tornqvist, C. Stromberg, O. Akre, et al., Selective intraoperative cholangiography and risk of bile duct injury during cholecystectomy, Br. J. Surg. 102 (8) (2015 Jul) 952–958 PubMed PMID: WOS:000356516400012. English.
[57] I. Van Campenhout, O. Prosmanne, M. Gagner, et al., Routine operative cholangiography during laparoscopic cholecystectomy: feasibility and value in 107 patients, AJR Am. J. Roentgenol. 160 (6) (1993 Jun) 1209–1211 PubMed PMID: 8498217.
[58] A. Vezakis, D. Davides, B.J. Ammori, et al., Intraoperative cholangiography during

laparoscopic cholecystectomy, Surg. Endosc. 14 (12) (2000) 1118–1122.
[59] U. Giger, M. Ouaissi, S.F. Schmitz, et al., Bile duct injury and use of cholangiography during laparoscopic cholecystectomy, Br. J. Surg. 98 (3) (2011 Mar) 391–396 PubMed PMID: 21254014.
[60] A. Hawasli, Does routine cystic duct cholangiogram during laparoscopic cholecystectomy prevent common bile duct injury? Surg. Laparosc. Endosc. 3 (4) (1993) 290–295.
[61] B.L. Robinson, J.H. Donohue, S. Gunes, et al., Selective operative cholangiography: appropriate management for laparoscopic cholecystectomy, Arch. Surg. 130 (6) (1995) 625–631.
[62] S. Verma, M.W. Wichmann, T. Gunning, et al., Intraoperative cholangiogram during laparoscopic cholecystectomy: a clinical trial in rural setting, Aust. J. Rural Health 24 (6) (2016 Dec) 415–421 PubMed PMID: 27087573.
[63] D. Amott, A. Webb, B. Tulloh, Prospective comparison of routine and selective operative cholangiography, ANZ J. Surg. 75 (6) (2005) 378–382.
[64] K.T. Buddingh, R.K. Weersma, R.A. Savenije, et al., Lower rate of major bile duct injury and increased intraoperative management of common bile duct stones after implementation of routine intraoperative cholangiography, J. Am. Coll. Surg. 213 (2) (2011 Aug) 267–274 PubMed PMID: 21459631.
[65] M.A. Carlson, K.A. Ludwig, C.T. Frantzides, et al., Routine or selective intraoperative cholangiography in laparoscopic cholecystectomy, J. Laparoendosc. Surg. 3 (1) (1993) 27–33.
[66] J.S. Barkun, G.M. Fried, A.N. Barkun, et al., Cholecystectomy without operative cholangiography: implications for common bile duct injury and retained common bile duct stones, Ann. Surg. 218 (3) (1993) 371–379.
[67] U. Lepner, V. Grünthal, Intraoperative cholangiography can be safely omitted during laparoscopic cholecystectomy: a prospective study of 413 consecutive patients, Scand. J. Surg. 94 (3) (2005) 197–200.
[68] J.W. Lorimer, R.J. Fairfull-Smith, Intraoperative cholangiography is not essential to avoid duct injuries laparoscopic cholecystectomy, Am. J. Surg. 169 (3) (1995) 344–347.
[69] M.E.C. McFarlane, C.A.L. Thomas, T. McCartney, et al., Selective operative cholangiography in the performance of laparoscopic cholecystectomy, Int. J. Clin. Pract. 59 (11) (2005) 1301–1303.
[70] I.S. Mir, M. Mohsin, O. Kirmani, et al., Is intra-operative cholangiography necessary during laparoscopic cholecystectomy? A multicentre rural experience from a developing world country, World J. Gastroenterol. 13 (33) (2007) 4493–4497.
[71] J.B. Morris, R. Margolis, E.F. Rosato, Safe laparoscopic cholecystectomy without intraoperative cholangiography, Surg. Laparosc. Endosc. 3 (1) (1993) 17–20.
[72] A. Pesce, T.R. Portale, V. Minutolo, R. Scilletta, G. Li Destri, S. Puleo, Bile duct injury during laparoscopic cholecystectomy without intraoperative cholangiography: a retrospective study on 1,100 selected patients, Dig. Surg. 29 (4) (2012) 310–314, https://doi.org/10.1159/000341660 Epub 2012 Sep 6. PubMed PMID: 22986956.
[73] O.M. Taylor, P.C. Sedman, B. Mancey Jones, et al., Laparoscopic cholecystectomy without operative cholangiogram: 2038 cases over a 5-year period in two district general hospitals, Ann. R. Coll. Surg. Engl. 79 (5) (1997) 376–380.
[74] K.D. Wright, J.M. Wellwood, Bile duct injury during laparoscopic cholecystectomy without operative cholangiography, Br. J. Surg. 85 (2) (1998) 191–194.
[75] E. Zacharakis, S. Angelopoulos, D. Kanellos, et al., Laparoscopic cholecystectomy without intraoperative cholangiography, J. Laparoendosc. Adv. Surg. Tech. 17 (5) (2007) 620–625.
[76] T. Ohtani, C. Kawai, Y. Shirai, et al., Intraoperative ultrasonography versus cholangiography during laparoscopic cholecystectomy: a prospective comparative study, J. Am. Coll. Surg. 185 (3) (1997) 274–282.
[77] H. Rijna, Q.A.J. Eijsbouts, F. Barkhof, et al., Assessment of the biliary tract by ultrasonography and cholangiography during laparoscopic cholecystectomy: a prospective study, Eur. J. Ultrasound 9 (2) (1999) 127–133.
[78] S.E. Tranter, M.H. Thompson, A prospective single-blinded controlled study comparing laparoscopic ultrasound of the common bile duct with operative cholangiography, Surg. Endosc. 17 (2) (2003) 216–219.
[79] S.N. Osayi, M.R. Wendling, J.M. Drosdeck, et al., Near-infrared fluorescent cholangiography facilitates identification of biliary anatomy during laparoscopic cholecystectomy, Surg Endosc Interv Tech 29 (2) (2015) 368–375.
[80] W.M. Duff, Avoiding misidentification injuries in laparoscopic cholecystectomy: use of cystic duct marking technique in intraoperative cholangiography, J. Am. Coll. Surg. 203 (2) (2006) 257–261.
[81] A.D. Fox, R.J. Baigrie, R.A. Cobb, B.L. Dowling, Peroperative cholangiography through the gallbladder (cholecystocholangiography) during laparoscopic cholecystectomy, Surg. Laparosc. Endosc. 6 (1) (1996) 22–25.
[82] G.G.R. Kuster, S.B.C. Gilroy, Intraoperative trans-gallbladder cholangiography intended to delineate bile duct anatomy, J. Laparoendosc. Surg. 5 (6) (1995) 377–384.
[83] C.A.H. Liyanage, Y. Sadakari, H. Kitada, et al., Prevention of iatrogenic bile duct injuries in difficult laparoscopic cholecystectomies: is the naso-biliary drain the answer? J. Hepato-Biliary-Pancreatic Surg. 16 (4) (2009) 458–462.
[84] W.L. Biffl, E.E. Moore, P.J. Offner, et al., Routine intraoperative laparoscopic ultrasonography with selective cholangiography reduces bile duct complications during laparoscopic cholecystectomy, J. Am. Coll. Surg. 193 (3) (2001) 272–280.
[85] K. Hakamada, S. Narumi, Y. Toyoki, et al., Intraoperative ultrasound as an educational guide for laparoscopic biliary surgery, World J. Gastroenterol. 14 (15) (2008) 2370–2376.
[86] J. MacHi, J.O. Johnson, D.J. Deziel, et al., The routine use of laparoscopic ultrasound decreases bile duct injury: a multicenter study, Surg Endosc Interv Tech 23 (2) (2009) 384–388.
[87] J. Machi, A.J. Oishi, T. Tajiri, et al., Routine laparoscopic ultrasound can significantly reduce the need for selective intraoperative cholangiography during cholecystectomy, Surg Endosc Interv Tech 21 (2) (2007) 270–274.
[88] T. Tomonaga, C.J. Filipi, A. Lowham, T. Martinez, Laparoscopic intracorporeal ultrasound cystic duct length measurement: a new technique to prevent common bile duct injuries, Surg. Endosc. 13 (2) (1999) 183–185.
[89] M. Ankersmit, D.A. van Dam, A.S. van Rijswijk, B. van den Heuvel, J.B. Tuynman, W.J.H.J. Meijerink, Fluorescent imaging with indocyanine green during laparoscopic cholecystectomy in patients at increased risk of bile duct injury, Surg. Innovat. 24 (3) (2017 Jun) 245–252 Epub 2017 Feb 8. PubMed PMID: 28178882; PubMed Central PMCID: PMC5431362.
[90] L. Boni, G. David, A. Mangano, et al., Clinical applications of indocyanine green (ICG) enhanced fluorescence in laparoscopic surgery, Surg Endosc Interv Tech 29 (7) (2015) 2046–2055.
[91] D. Daskalaki, E. Fernandes, X. Wang, et al., Indocyanine green (ICG) fluorescent cholangiography during robotic cholecystectomy: results of 184 consecutive cases in a single institution, Surg. Innovat. 21 (6) (2014) 615–621.
[92] F. Dip, D. Nguyen, L. Montorfano, et al., Accuracy of near infrared-guided surgery in morbidly obese subjects undergoing laparoscopic cholecystectomy, Obes. Surg. 26 (3) (2016) 525–530.
[93] F. Dip, M. Roy, E.L. Menzo, et al., Routine use of fluorescent incisionless cholangiography as a new imaging modality during laparoscopic cholecystectomy, Surg Endosc Interv Tech 29 (6) (2015) 1621–1626.
[94] F.D. Dip, M. Nahmod, L. Alle, et al., Fluorescence cholangiography in laparoscopic cholecystectomy experience in Argentina, Front Gastrointest Res (2013) 80–85.
[95] T. Igami, M. Nojiri, K. Shinohara, et al., Clinical value and pitfalls of fluorescent cholangiography during single-incision laparoscopic cholecystectomy, Surg. Today 46 (12) (2016) 1443–1450.
[96] T. Ishizawa, Y. Bandai, M. Ijichi, et al., Fluorescent cholangiography illuminating the biliary tree during laparoscopic cholecystectomy, Br. J. Surg. 97 (9) (2010) 1369–1377.
[97] Y. Kono, T. Ishizawa, K. Tani, et al., Techniques of fluorescence cholangiography during laparoscopic cholecystectomy for better delineation of the bile duct anatomy, Medicine 94 (25) (2015) e1005.
[98] A. Mohsen, M.S. Elbasiouny, M. El-Shazli, et al., Evaluation of the effectiveness of fluorescent visualization of bile ducts using fluorescein and ultraviolet a at laparoscopic cholecystectomy, Surg. Innovat. 23 (3) (2015) 261–265.
[99] F. Prevot, L. Rebibo, C. Cosse, et al., Effectiveness of intraoperative cholangiography using indocyanine green (versus contrast fluid) for the correct assessment of extrahepatic bile ducts during day-case laparoscopic cholecystectomy, J. Gastrointest. Surg. 18 (8) (2014 Aug) 1462–1468 PubMed PMID: 24916587.
[100] R.M. Schols, N.D. Bouvy, A.A.M. Masclee, et al., Fluorescence cholangiography during laparoscopic cholecystectomy: a feasibility study on early biliary tract delineation, Surg Endosc Interv Tech 27 (5) (2013) 1530–1536.
[101] R.M. Schols, N.D. Bouvy, R.M. Van Dam, et al., Combined vascular and biliary fluorescence imaging in laparoscopic cholecystectomy, Surg Endosc Interv Tech 27 (12) (2013) 4511–4517.
[102] G. Spinoglio, F. Priora, P.P. Bianchi, et al., Real-time near-infrared (NIR) fluorescent cholangiography in single-site robotic cholecystectomy (SSRC): a single-institutional prospective study, Surg. Endosc. 27 (6) (2013 Jun) 2156–2162 PubMed PMID: 23271272.
[103] C. Zroback, G. Chow, A. Meneghetti, et al., Fluorescent cholangiography in laparoscopic cholecystectomy: the initial Canadian experience, Am. J. Surg. 211 (5) (2016) 933–937.
[104] X.J. Cai, H.N. Ying, H. Yu, et al., Blunt dissection: a solution to prevent bile duct injury in laparoscopic cholecystectomy, Chin. Med. J. 128 (23) (2015) 3153–3157.
[105] X. Li, K.X. Ai, Y.Q. Bai, et al., Strategies to decrease bile duct injuries during laparoscopic cholecystectomy, J. Laparoendosc. Adv. Surg. Tech. 24 (11) (2014) 770–776.
[106] Y.S. Sari, V. Tunali, K. Tomaoglu, et al., Can bile duct injuries be prevented? "A new technique in laparoscopic cholecystectomy, BMC Surg. 5 (2005 Jun 17) 14 PubMed PMID: 15963227.
[107] Z.Y. Wang, F. Xu, Y.D. Liu, et al., Prevention of biliary duct injury in laparoscopic cholecystectomy using optical fiber illumination in common bile duct, Gastroenterol. Res. 3 (5) (2010 Oct) 207–212 PubMed PMID: 27956998.
[108] F. Xu, C.G. Xu, D.Z. Xu, A new method of preventing bile duct injury in laparoscopic cholecystectomy, World J. Gastroenterol. 10 (19) (2004) 2916–2918.
[109] H. Bektas, H. Schrem, M. Winny, J. Klempnauer, Surgical treatment and outcome of iatrogenic bile duct lesions after cholecystectomy and the impact of different clinical classification systems, Br. J. Surg. 94 (9) (2007 Sep) 1119–1127 PubMed PMID: 17497652.
[110] S.M. Strasberg, L.M. Brunt, The critical view of safety: why it is not the only method of ductal identification within the standard of care in laparoscopic cholecystectomy, Ann. Surg. 265 (3) (2017 Mar) 464–465 PubMed PMID: 27763898.
[111] M.A. Mercado, I. Domínguez, Classification and management of bile duct injuries, World J. Gastrointest. Surg. 3 (4) (2011) 43–48 PubMed PMID: PMC3083499.
[112] F.W. van de Graaf, J. van den Bos, L.P.S. Stassen, J.F. Lange, Lacunar implementation of the critical view of safety technique for laparoscopic cholecystectomy: results of a nationwide survey, Surgery (2018 Mar 7) pii: S0039-6060(18)30032-1. doi: 10.1016/j.surg.2018.01.016. [Epub ahead of print] PubMed PMID: 29525733.
[113] Society of American Gastrointestinal and Endoscopic Surgeons (SAGES), The SAGES safe cholecystectomy program. Strategies for minimizing bile duct injuries: adopting a universal culture of safety in cholecystectomy, Available from: https://www.sages.org/safe-cholecystectomy-program/.
[114] R. Vecchio, B.V. MacFadyen, S. Latteri, Laparoscopic cholecystectomy: an analysis on 114,005 cases of United States series, Int. Surg. 83 (3) (1998 Jul-Sep) 215–219

PubMed PMID: 9870777.
[115] C. Palanivelu, P.S. Rajan, K. Jani, et al., Laparoscopic cholecystectomy in cirrhotic patients: the role of subtotal cholecystectomy and its variants, J. Am. Coll. Surg. 203 (2) (2006 Aug) 145–151 PubMed PMID: 16864026.
[116] P.L. Mirizzi, [Calculi of the common bile duct (520 cases under the control of surgical cholangiography)] La lithiase de la voie biliaire principale (a propos de 520 cas sous le controle de la cholangiographie operatoire), Mem. Acad. Chir. 81 (27–28) (1955 Oct 26-Nov 9) 834–841 discussion, 41-2. PubMed PMID: 13287835. Epub 1955/10/26. fre.
[117] J.A. Ford, M. Soop, J. Du, et al., Systematic review of intraoperative cholangiography in cholecystectomy, Br. J. Surg. 99 (2) (2012) 160–167.
[118] N.N. Massarweh, A. Devlin, J.A. Elrod, et al., Surgeon knowledge, behavior, and opinions regarding intraoperative cholangiography, J. Am. Coll. Surg. 207 (6) (2008 Dec) 821–830 PubMed PMID: 19183527.
[119] P. Sanjay, C. Kulli, F.M. Polignano, I.S. Tait, Optimal surgical technique, use of intra-operative cholangiography (IOC), and management of acute gallbladder disease: the results of a nation-wide survey in the UK and Ireland, Ann. R. Coll. Surg. Engl. 92 (4) (2010) 302–306.
[120] K.T. Buddingh, H.S. Hofker, H.O. ten Cate Hoedemaker, et al., Safety measures during cholecystectomy: results of a nationwide survey, World J. Surg. 35 (6) (2011) 1235–1241 discussion 42-43.
[121] T. Hibi, Y. Iwashita, T. Ohyama, et al., The "right" way is not always popular: comparison of surgeons' perceptions during laparoscopic cholecystectomy for acute cholecystitis among experts from Japan, Korea and Taiwan, J Hepatobiliary Pancreat Sci 24 (1) (2017 Jan) 24–32 PubMed PMID: 28026137.
[122] K.S. Gurusamy, V. Giljaca, Y. Takwoingi, et al., Endoscopic retrograde cholangiopancreatography versus intraoperative cholangiography for diagnosis of common bile duct stones, Cochrane Database Syst. Rev. (2) (2015 Feb 26) CD010339 PubMed PMID: 25719222.
[123] A. Dili, C. Bertrand, Laparoscopic ultrasonography as an alternative to intraoperative cholangiography during laparoscopic cholecystectomy, World J. Gastroenterol. 23 (29) (2017 Aug 7) 5438–5450 PubMed PMID: 28839445.
[124] R.A. Falcone Jr., E.J. Fegelman, M.S. Nussbaum, et al., A prospective comparison of laparoscopic ultrasound vs intraoperative cholangiogram during laparoscopic cholecystectomy, Surg. Endosc. 13 (8) (1999) 784–788.
[125] N.J. Soper, Intraoperative detection: intraoperative cholangiography vs. intraoperative ultrasonography, J. Gastrointest. Surg. 4 (4) (2000) 334–335 2000/07/01/.
[126] Y.Y. Liu, C.H. Liao, M. Diana, et al., Near-infrared cholecystocholangiography with direct intragallbladder indocyanine green injection: preliminary clinical results, Surg. Endosc. 32 (3) (2018 Mar) 1506–1514 PubMed PMID: 28916859.
[127] A. Pesce, G. Piccolo, G. La Greca, S. Puleo, Utility of fluorescent cholangiography during laparoscopic cholecystectomy: a systematic review, World J. Gastroenterol. : WJG 21 (25) (2015) 7877–7883 PubMed PMID: PMC4491975.
[128] J. van den Bos, R.M. Schols, M.D. Luyer, et al., Near-infrared fluorescence cholangiography assisted laparoscopic cholecystectomy versus conventional laparoscopic cholecystectomy (FALCON trial): study protocol for a multicentre randomised controlled trial, BMJ Open 6 (8) (2016).