

# Ultrasonography of the Cervical Spine: An In Vitro Anatomical Validation Model

Citation for published version (APA):

van Eerd, M., Patijn, J., Sieben, J. M., Sommer, M., van Zundert, J., van Kleef, M., & Lataster, A. (2014). Ultrasonography of the Cervical Spine: An In Vitro Anatomical Validation Model. *Anesthesiology*, *120*(1), 86-96. <https://doi.org/10.1097/ALN.0000000000000006>

## Document status and date:

Published: 01/01/2014

## DOI:

[10.1097/ALN.0000000000000006](https://doi.org/10.1097/ALN.0000000000000006)

## Document Version:

Publisher's PDF, also known as Version of record

## Document license:

Taverne

## Please check the document version of this publication:

- A submitted manuscript is the version of the article upon submission and before peer-review. There can be important differences between the submitted version and the official published version of record. People interested in the research are advised to contact the author for the final version of the publication, or visit the DOI to the publisher's website.
- The final author version and the galley proof are versions of the publication after peer review.
- The final published version features the final layout of the paper including the volume, issue and page numbers.

[Link to publication](#)

## General rights

Copyright and moral rights for the publications made accessible in the public portal are retained by the authors and/or other copyright owners and it is a condition of accessing publications that users recognise and abide by the legal requirements associated with these rights.

- Users may download and print one copy of any publication from the public portal for the purpose of private study or research.
- You may not further distribute the material or use it for any profit-making activity or commercial gain
- You may freely distribute the URL identifying the publication in the public portal.

If the publication is distributed under the terms of Article 25fa of the Dutch Copyright Act, indicated by the "Taverne" license above, please follow below link for the End User Agreement:

[www.umlib.nl/taverne-license](http://www.umlib.nl/taverne-license)

## Take down policy

If you believe that this document breaches copyright please contact us at:

[repository@maastrichtuniversity.nl](mailto:repository@maastrichtuniversity.nl)

providing details and we will investigate your claim.

# Ultrasonography of the Cervical Spine

## *An In Vitro Anatomical Validation Model*

Maarten van Eerd, M.D., F.I.P.P., Jacob Patijn, M.D., Ph.D., Judith M. Sieben, Ph.D., Mischa Sommer, M.D., Ph.D., Jan Van Zundert, M.D., Ph.D., F.I.P.P., Maarten van Kleef, M.D., Ph.D., F.I.P.P., Arno Lataster, M.Sc.

### ABSTRACT

**Background:** Anatomical validation studies of cervical ultrasound images are sparse. Validation is crucial to ensure accurate interpretation of cervical ultrasound images and to develop standardized reliable ultrasound procedures to identify cervical anatomical structures. The aim of this study was to acquire validated ultrasound images of cervical bony structures and to develop a reliable method to detect and count the cervical segmental levels.

**Methods:** An anatomical model of a cervical spine, embedded in gelatin, was inserted in a specially developed measurement device. This provided ultrasound images of cervical bony structures. Anatomical validation was achieved by laser light beams projecting the center of the ultrasound image on the cervical bony structures through a transparent gelatin.

**Results:** Anatomically validated ultrasound images of different cervical bony structures were taken from dorsal, ventral, and lateral perspectives. Potentially relevant anatomical landmarks were defined and validated. Test/retest analysis for positioning showed a reproducibility with an intraclass correlation coefficient for single measures of 0.99. Besides providing validated ultrasound images of bony structures, this model helped to develop a method to detect and count the cervical segmental levels *in vivo* at long-axis position, in a dorsolateral (paramedian) view at the level of the laminae, starting from the base of the skull and sliding the ultrasound probe caudally.

**Conclusions:** Ultrasound bony images of the cervical vertebrae were validated with an *in vitro* model. Anatomical bony landmarks are the mastoid process, the transverse process of C1, the tubercles of C6 and C7, and the cervical laminae. Especially, the cervical dorsal laminae serve best as anatomical bony landmarks to reliably detect the cervical segmental levels *in vivo*. (**ANESTHESIOLOGY 2014; 120:86-96**)

**E**XACT anatomical localization of target structures is essential for interventional pain management procedures of the cervical spine. These are usually fluoroscopy-guided interventional procedures. Ultrasound is a noninvasive, radiation-free method that depicts cervical bony structures and soft-tissue components. Ultrasound can help localize different targets for interventional pain treatment and could possibly replace fluoroscopy for some indications.<sup>1-4</sup> Precise identification of the cervical vertebral level on ultrasound images is difficult; it requires experience and takes considerable time to learn. Therefore, recognizing the bony structures in ultrasound images and defining bony landmarks can be helpful.

Only few ultrasound studies have tried to validate ultrasound images of cervical bony structures anatomically, such

#### What We Already Know about This Topic

- Interventional pain management and regional anesthesia procedures of the cervical spine are aided by visualization, either by fluoroscopy or ultrasound
- Validated approaches to ultrasound imaging of the cervical spine are not available

#### What This Article Tells Us That Is New

- An *in vitro* model was constructed to validate ultrasound imaging of the cervical spine
- Validated ultrasound images are provided for the key landmarks: mastoid process, transverse process of C1, tubercles of C6 and C7, and cervical laminae

This article is featured in "This Month in Anesthesiology," page 1A. Corresponding article on page 10. Supplemental Digital Content is available for this article. Direct URL citations appear in the printed text and are available in both the HTML and PDF versions of this article. Links to the digital files are provided in the HTML text of this article on the Journal's Web site ([www.anesthesiology.org](http://www.anesthesiology.org)).

Submitted for publication November 15, 2012. Accepted for publication August 23, 2013. From the Department of Anesthesiology and Pain Management (M.v.E., J.P., M.S., M.v.K., J.V.Z.), University Medical Center Maastricht, Maastricht, The Netherlands; Department of Anesthesiology and Pain Management (M.v.E.), Amphia Hospital, Breda, The Netherlands; Department of Anatomy and Embryology (J.M.S., A.L.), Maastricht University, Maastricht, The Netherlands; CAPHRI School for Public Health and Primary Care (J.M.S., A.L.), Maastricht, The Netherlands; Department of Anesthesiology and Multidisciplinary Pain Center (J.V.Z.), Ziekenhuis Oost-Limburg, Genk, Belgium.

Copyright © 2013, the American Society of Anesthesiologists, Inc. Lippincott Williams & Wilkins. Anesthesiology 2014; 120:86-96

as the sixth and seventh cervical vertebra<sup>5</sup> or the cervical facet joints.<sup>6</sup> To validate these ultrasound images, different definitive standards or reference tests have been used, such as cross-sectional gross anatomy and histology of cadavers, fluoroscopy, and computerized tomography scan.<sup>6-9</sup> None of these studies, however, validated the ultrasound images of bony cervical structures of all the different cervical levels.

One study used bony cervical landmarks to locate the brachial plexus.<sup>5</sup> In that study, a cervical spine of a human cadaver embedded in gelatin was used to localize the seventh cervical vertebra as a bony landmark. Under ultrasound guidance, a needle was placed at the C7 level by an investigator who was unaware of the orientation of the embedded spine. After removal of the gelatin, the actual needle position was verified. Ultrasound images of the sixth and seventh cervical vertebra of a single cervical spine were validated in that study. Therefore, those findings cannot be generalized to other cervical levels. Precise identification of the different cervical segments to be treated is indispensable.<sup>2</sup>

The aim of this study was to perform an *in vitro* ultrasound study of all cervical segments to acquire anatomically validated ultrasound images of the cervical vertebrae. In addition, clinically useful anatomical bony landmarks were defined in order to develop a method to reliably identify the segmental levels *in vivo*.

## Materials and Methods

In this study, the cranial base and the cervical spine of one cadaver were used. A handwritten and signed codicil from the donor, posed when still alive and well, is kept at the Department of Anatomy and Embryology Faculty of Health, Medicine and Life Sciences, Maastricht University, Maastricht, The Netherlands. This is required by Dutch law for the use of cadavers for scientific research and education. Medical ethics board approval was obtained for the acquisition of the *in vivo* ultrasound images from human volunteers (Institutional review board METC azM/UM Maastricht, Maastricht, The Netherlands, METC nr.13-4-066). All healthy volunteers gave informed consent.

### Anatomical Model of the Cervical Spine

The cranial base (C0) and seven cervical vertebrae (C1–C7) of a cadaver (woman, 52 yr) were used to reconstruct the cervical spine. C0 and the different cervical vertebrae were reassembled and affixed with beeswax that was heated to a malleable consistency. Beeswax was used because of its ultrasound properties (we used toy clay in a previous attempt to reconstruct a cervical spine. However, the toy clay produced ultrasound reflections on the images that could not be distinguished from the adjacent bony structures). Beeswax was used in the cervical anatomical model to fill the intervertebral spaces in order to distinguish the intervertebral disc spaces from the adjacent bony vertebral bodies. The facet joints were also filled with beeswax with an approximate distance to the corresponding joint surfaces between 1 and

2 mm. In order to reconstruct the curve of the anatomical cervical spine, lateral radiographs of two nondegenerative *in vivo* cervical spines were used. After completing the construction of the anatomical cervical spine, a radiograph of it was taken. This radiograph was compared with the previously mentioned *in vivo* radiographs, and the curve of our anatomical cervical spine was adjusted until it matched.

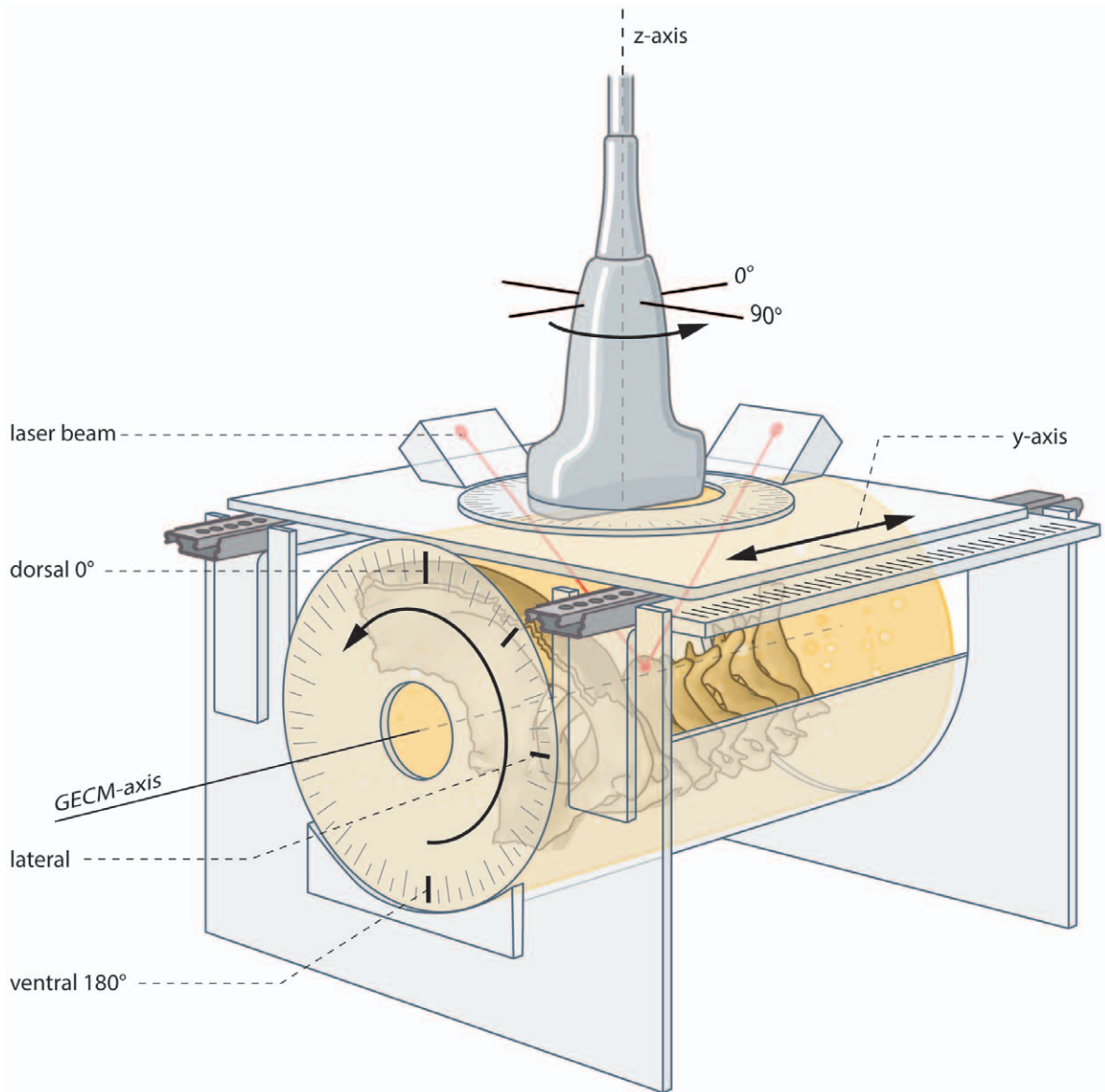
Next, the anatomical cervical spine was placed upside down on a transparent polycarbonate bottom plate in which a circular groove was made to hold a polycarbonate cylinder (diameter 19 cm and height 30 cm). The cranial base was affixed to the bottom plate with beeswax at a distance of 2 cm from the bottom plate in such a way that the tip of the dens was pointing to the center of the circle. The inside of the polycarbonate cylinder was covered with a thin layer of white petroleum jelly to prevent the gelatin from adhering to the inner surface of the cylinder. The cylinder was placed in the groove of the bottom plate and sealed from the outside with beeswax. The cylinder was filled with a 20% gelatin solution. After solidification of the gelatin, the cylinder was removed and the gelatin-embedded cervical model (GECM) was ready to use for measurements (see figure, Supplemental Digital Content 1, <http://links.lww.com/ALN/A994>, this figure shows the anatomical model of the cervical spine embedded in gelatin solution).

### Measurement Device

The GECM was placed horizontally in a transparent half cylinder. This half cylinder was placed in a transparent polycarbonate box (fig. 1). Within the half cylinder, the model could be rotated along the longitudinal axis of the model (GECM-axis). This allows ultrasound scanning from the dorsal, ventral, and lateral sides and all view angles in between. The degree of rotation could be read from a protractor fixed to the cranial end of the polycarbonate box. The position of the external occipital protuberance, visible through the gelatin, was used as a reference mark for rotation.

A movable carriage was mounted on the top of the transparent polycarbonate box. The carriage, containing the ultrasound probe holder, could be moved to both sides in a horizontal plane (y-axis), parallel to the GECM-axis. This construction allowed cranial to caudal ultrasound scanning. The horizontal translation position could be read from a ruler fixed at the top of the box (fig. 1).

On the movable carriage, a rotatable circular holder was mounted to hold the ultrasound probe. This allowed rotation of the probe along a z-axis through the center of the probe, perpendicular to the GECM-axis. This construction made it possible to use the ultrasound probe in all possible rotation positions. The degree of rotation of the ultrasound probe could be read from a protractor fixed to the probe holder (fig. 1). Two laser lights were mounted on the movable carriage, next to the ultrasound probe, at 12 and 9 o'clock position. These two laser lights, with an angle of 45 degrees, produced two perpendicularly crossing laser beams into the polycarbonate



**Fig. 1.** Measurement device. Measurement device with ultrasound probe in probeholder. The ultrasound probe can rotate around the z-axis and slide horizontally (craniocaudal) along the y-axis. The gelatin-embedded cervical spine can be rotated around the gelatin-embedded cervical model (GECM) axis. Two crossing laserbeams project the center of the ultrasound image on the cervical spinal model.

box with their junction in the z-axis of the ultrasound probe. Laser light positioning was calibrated with correction for the refractive index of the gelatin. The two crossing laser beams were projected on the cervical spine through the transparent gelatin. In this way, the precise position of the center of the ultrasound beam with respect to the cervical spine could be confirmed. Thus, the bony structure at the cross of the two perpendicular laser beams was seen at the center of the ultrasound image. This method was used to anatomically validate the ultrasound images of the cervical spine.

#### **Ultrasound-equipment Specifications**

An Esaote (Mylab 25) ultrasound scanner was used for ultrasound imaging, in combination with a 5-cm (7.5–12 MHz)

linear array probe (Esaote Worldwide, Milan, Italy, Europe). Ultrasound transmission gel (Aquasonic 100; Parker Lab, Fairfield, NJ) was used as an interface between the model and the transducer to optimize signal transduction. To protect the gelatin cylinder against fungal growth in the ultrasound transmission gel, the gelatin was wrapped in a plastic cling film.

#### **Ultrasound-measurement Conditions**

Ultrasound measurements were collected from the following positions: dorsal view, ventral view, left lateral, and right lateral view (series 1–4). Ultrasound images were made with two probe rotation positions (0° and 90° z-axis rotation, comparable with long-axis and short-axis view).

This resulted in eight different subconditions: two dorsal views ( $0^\circ$  = sagittal and  $90^\circ$  = transverse), two ventral views ( $0^\circ$  = sagittal and  $90^\circ$  = transverse), and two left and two right lateral views ( $0^\circ$  = coronal and  $90^\circ$  = transverse).

### Anatomical Reference Points and Target Structures

The cranial base and all cervical levels were scanned from cranial to caudal in a standardized way. For each view, a predefined anatomical reference point (ARP), localized as cranially as possible (at C0 or C1 level), was selected. The ultrasound probe was centered (verified by the laser beams cross) at this ARP. This ARP was defined as the zero position (y-axis) for this view. For the ventral view, the anterior arch of C1 was used as ARP. For the dorsal view, the posterior arch of C1 was used as ARP. For both lateral views, the caudal tip of the mastoid process was used as ARP. From this zero position, the ultrasound probe was translated caudally, taking ultrasound images of relevant bony target structures at each subsequent cervical level. In dorsal view, the spinal processes were scanned; in ventral view, the vertebral bodies were scanned; in left and right lateral view, the transverse processes and facet joints were scanned (table, Supplemental Digital Content 2, <http://links.lww.com/ALN/A995>, which is a table listing an overview of the ARPs and bony cervical targets from dorsal, ventral, and lateral views).

### Data Collection and Image Documentation

For each ultrasound image, various ultrasound parameters (frequency, depth, gain, and power) were recorded. In addition, data about y-axis translation distance (millimeter from ARP = zero position), degrees of rotation of the ultrasound probe (z-axis), and rotation of the anatomical cervical spine model (GECM-axis, 0-90-180-270 degrees) were also collected. Furthermore, a photograph was made of the measurement setup showing the probe and the model positions as well as the projected laser beam cross. These photographs were used to document the position of the laser light beams on the cervical model with the simultaneously collected ultrasound images. These photographs served as an extra verification method for the probe position.

### Statistical Analysis

In order to estimate the consistency of the *in vitro* ultrasound method, two series of measurements of the dorsal view were performed with an interval of 4 weeks.<sup>10</sup> The dorsal spinous processes of all cervical levels were depicted and their positions (measured as horizontal translations in millimeters from the ARP, which in dorsal view was the posterior arch of C1) were documented. Each measurement was one observation.

A test-retest analysis was performed with SPSS 18.0 for Windows (SPSS Inc., Chicago, IL) using a single measures intraclass correlation coefficient to determine the reproducibility of the test results.

### Determination of Relevant Bony Landmarks

The protocol as described so far was used to systematically scan the cervical spine from dorsal, ventral, and lateral views (series 1-4) using standard probe positions ( $0^\circ$  and  $90^\circ$  z-axis). For cervical facet joints, laminae, and other potentially relevant bony landmarks, not optimally visible in the four views, an additional series of image collection was performed (series 5). In series 5, the ARP of the lateral view (the caudal tip of the mastoid process) was used as starting point. To depict the cervical bony ultrasound targets such as the facet joints and laminae, the model was rotated along the GECM-axis, until the laser cross was centered on one of these bony structures. The ultrasound probe was rotated (z-axis) in such a way that the facet joint or lamina was best seen on the ultrasound image. A list of cervical bony ultrasound targets of series 5, with scanning details, is presented in table 1.

### In Vivo Ultrasound Protocol Development

To develop a final *in vivo* ultrasound protocol with a feasible counting method to locate the exact cervical level, three *in vivo* ultrasound sessions in four healthy subjects (volunteers) and one *in vitro* session in our anatomical model were necessary.

In the first *in vivo* session, we used the lateral view protocol as developed in the anatomical model, starting from the mastoid process. The transverse process of C1 is clearly distinguishable in the *in vivo* situation, but sliding down the probe caudally, it turned out to be difficult to keep track of the osseous structures because of the overlying muscular and ligamentous structures. Because the mastoid process, the transverse process of C1, and the laminae are identifiable anatomical landmarks *in vivo*, we then tested a new protocol in our anatomical model (*in vitro* session):

1. First with the probe in the  $0^\circ$  z-axis position and the gelatin model in  $100^\circ$  (GECM-axis), the mastoid process and the transverse process of C1 were identified.
2. Next, the gelatin model was rotated to the  $75^\circ$  GECM-axis position until the C2 lamina was seen.
3. Then, a sliding movement with the probe was made in the caudal direction to view and count the laminae of C2 to C7.

With this protocol, it was possible to detect the segmental levels in our anatomical model reliably.

In the second *in vivo* session, this method of segmental level detection was tested in four subjects. When making the rotational sliding movement from the C1 transverse process to the lamina of C2, again, the continuity of the osseous structures was lost. We adjusted our *in vivo* protocol by skipping the first two steps of the protocol used in our anatomical model. Starting at the base of the skull (C0) from a dorsolateral position, we moved the probe at the level of the cervical laminae from C0 down to the posterior arch of C1 and further along the cervical laminae of C2 to C7, in one cranial to caudal line. This third,

**Table 1.** Overview of Anatomical Landmarks with Optimal Scanning Details (Series 5)

		GECM-axis Rotation	Probe Rotation (z-axis)
Anatomical reference point (= zero position)	Mastoid process (caudal tip of mastoid process)	100°	0°
C1	Transverse process	100°	0°
	Atlanto-axial joint	115°	0°
C2	Lamina	75°	0°
	Facet joint	110°	0°
C3	Lamina	75°	0°
	Facet joint	110°	345°
C4	Lamina	75°	0°
	Posterior tubercle	110°	90°
	Facet joint	110°	350°
C5	Lamina	75°	0°
	Facet joint	90°	345°
C6	Lamina	55°	0°
	Posterior tubercle	85°	90°
	Anterior tubercle	85°	90°
	Facet joint	75°	20°
C7	Lamina	45°	0°
	Transverse process	90°	90°

GECM = gelatin-embedded cervical model; GECM-axis = the longitudinal axis of the gelatin-embedded cervical model; z-axis = the axis through the center of the ultrasound probe.

final *in vivo* test showed that with this adjusted protocol, it is possible to identify the sequential levels of C1 to C7.

## Results

The test/retest analysis for positioning in the anatomical model (dorsal view) showed an intraclass correlation coefficient for single measures of 0.99.

All ultrasound images collected during this study were stored in a database together with the ultrasound stills, ultrasound parameters, and photographs. In addition, rotation details (z-axis and GECM-axis) and y-axis translation were recorded to document the optimal approach to obtain these ultrasound images. Highlights of ultrasound image collection are presented in this section.

### Systematic Ultrasound Image Collection (Dorsal, Ventral, and Lateral Views)

Anatomically validated ultrasound images of different cervical bony structures were collected in the dorsal, ventral, and left and right lateral views from both probe rotation positions (0° and 90° z-axis rotation).

In the dorsal view, the posterior arch of C1 and the spinous processes of C2 to C7 were clearly distinguishable on the ultrasound image (fig. 2, also see figure, Supplemental Digital Content 3, <http://links.lww.com/ALN/A996>, a figure that illustrates ultrasound imaging of C0 to C2 from dorsal view position). Compositions of the dorsal and ventral view images were made to get a more comprehensive view and to approximate the dynamic imaging of ultrasound scanning (see figures, Supplemental Digital Content 4, <http://links.lww.com/ALN/A997>, and Supplemental Digital Content

5, <http://links.lww.com/ALN/A998>, figures that illustrate a composition of ultrasound images with 0° z-axis probe rotation (long-axis view) of C0 to C7 of dorsal and ventral view).

By using 90° z-axis probe rotation (*in vivo* this would be called short-axis position or transverse plane), each cervical vertebra can be visualized, and differences in shapes of the dorsal spinal processes can be identified (fig. 3).

In the lateral views, the mastoid process (used as ARP) and the transverse process of C1 were well depicted on the ultrasound image (fig. 4).

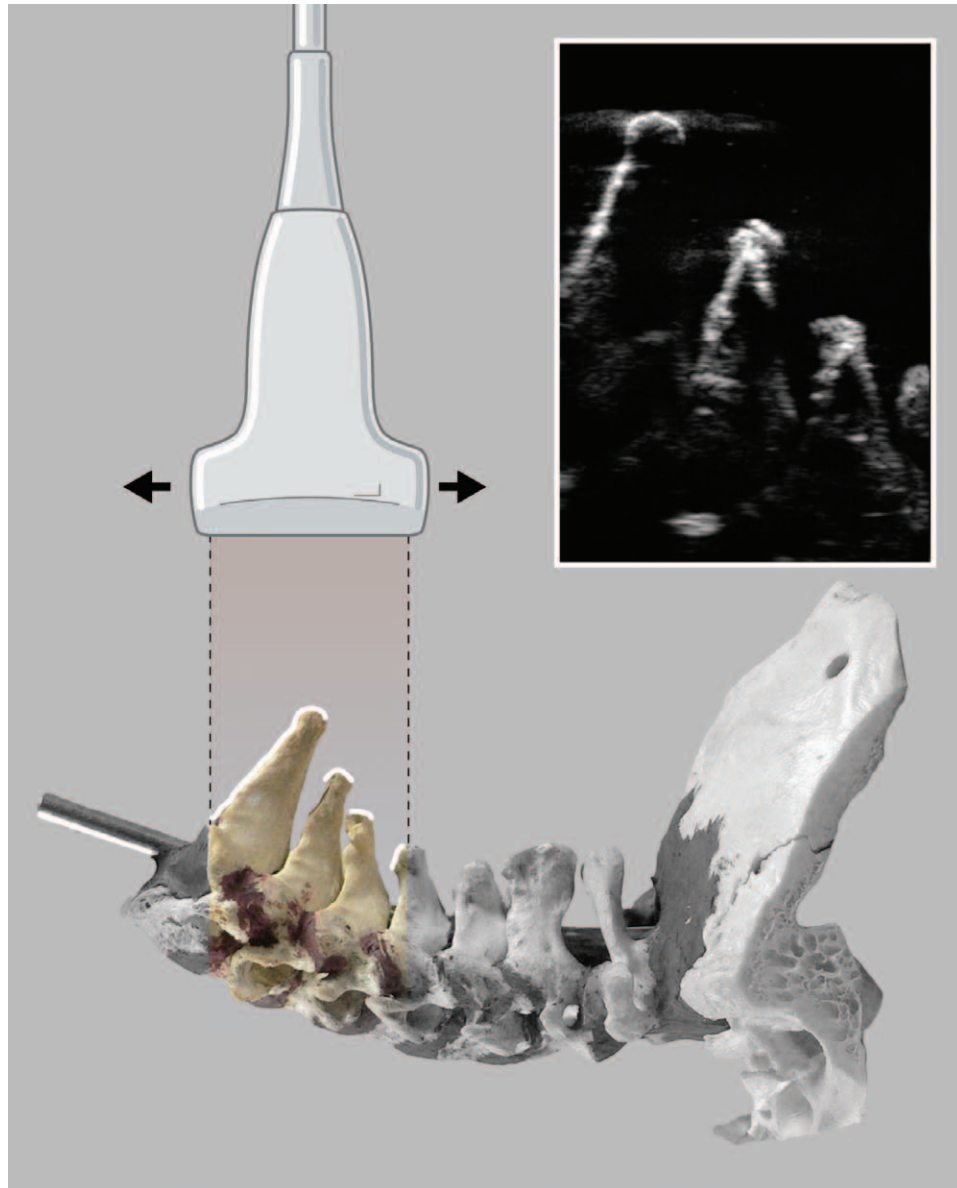
### Anatomical Landmarks

In addition to the bony structures seen in the dorsal (1), ventral (2), and both lateral views (3,4), a set of potential, relevant, specific anatomical landmarks was defined and anatomically validated (series 5, table 1). As an example, the transverse processes of C6 and C7 are shown in figure 5. Note that at the level of C6, both an anterior and a posterior tubercle can be identified. In contrast, at C7 only a posterior tubercle was found.

In series 5, we also aimed to depict the cervical laminae (fig. 6). When sliding the probe down over the cervical laminae, each cervical segment can be easily identified (see figure, Supplemental Digital Content 6, <http://links.lww.com/ALN/A999>, figure that illustrates the line of the sliding movement over the dorsal cervical laminae on the cervical anatomical model.).

### Determination of Cervical Segmental Levels In Vivo Using Ultrasound

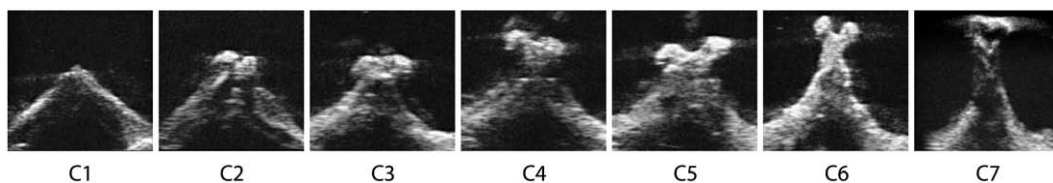
One of the aims of this study is to develop a method to determine the correct cervical segmental level *in vivo* using ultrasound. From our *in vitro* image collection, potentially



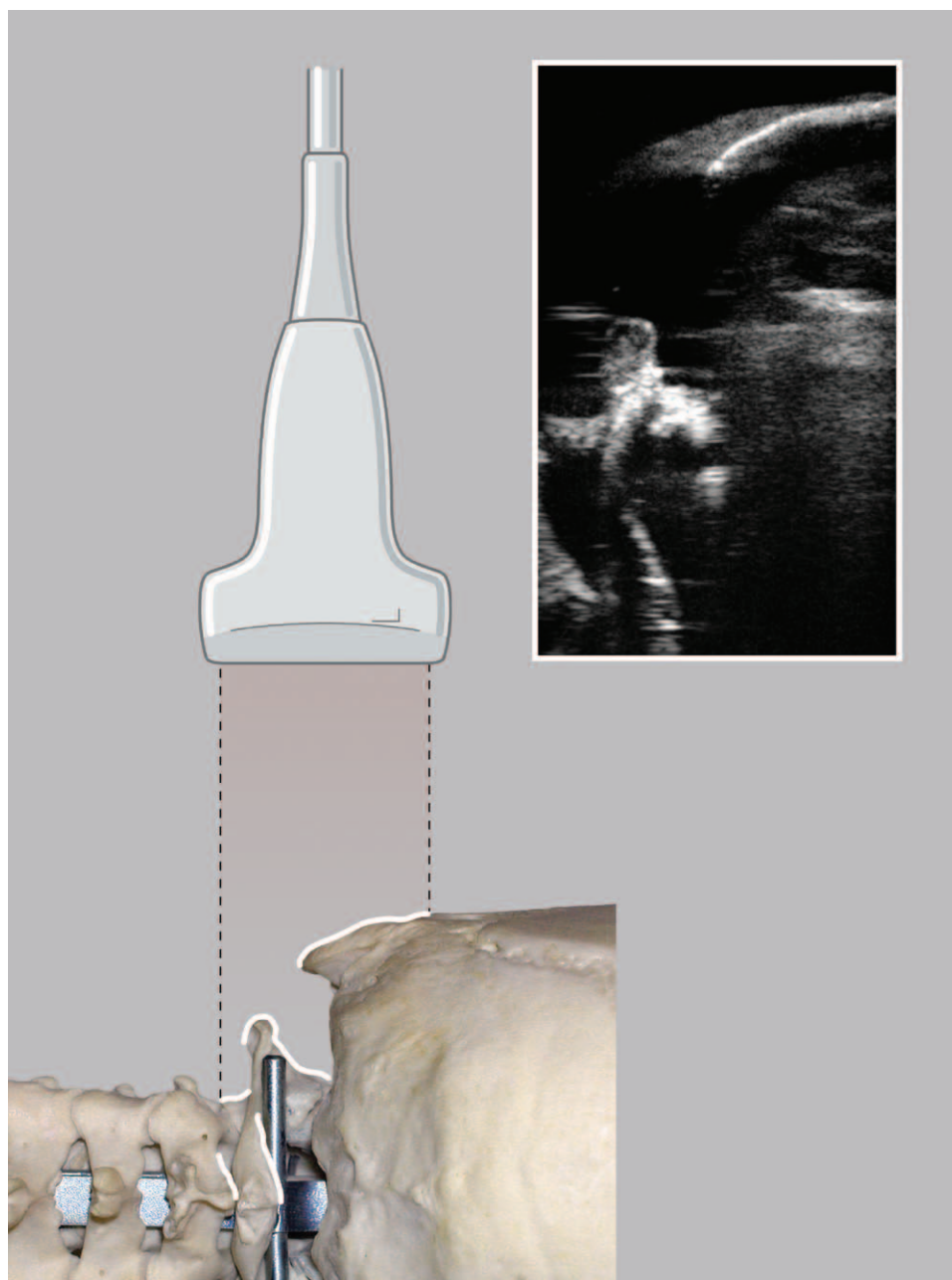
**Fig. 2.** Ultrasound imaging of C5–C7 (dorsal view, 0° z-axis probe rotation). Illustration shows how ultrasound beam reflects from dorsal bony surfaces of lower cervical vertebrae. *White line markings* in illustration correspond to ultrasound image shapes (ultrasound probe in 0° z-axis position or long-axis view).

useful anatomical landmarks appeared to be the mastoid process, the cranial base (C0), posterior arch (C1), dorsal spinal processes (C2–C7), the dorsal laminae (C2–C7), the facet joints (C1–C7), and the transverse processes of C1, C6, and C7.

By sliding down the ultrasound probe in long-axis position, starting from the cranial base, all cervical segments can be dynamically visualized without losing the continuity because of overlying muscular and ligamentous structures (fig. 7). That is why we used the cervical



**Fig. 3.** Ultrasound images of spinous processes of all cervical vertebrae (dorsal view, 90° z-axis probe rotation). Ultrasound images of spinous processes of C1 to C7 (dorsal view, 90° z-axis probe rotation, or short-axis view).



**Fig. 4.** Ultrasound imaging of mastoid process and transverse processes (lateral view, 0° z-axis probe rotation). Ultrasound imaging of mastoid process and transverse process of C1. The transverse process of C1 is a prominent bony structure of the higher cervical spine and can be used as a bony anatomical landmark. *White line markings* in illustration correspond to ultrasound image shapes.

vertebral dorsal laminae as bony landmarks in our final *in vivo* protocol.

## Discussion

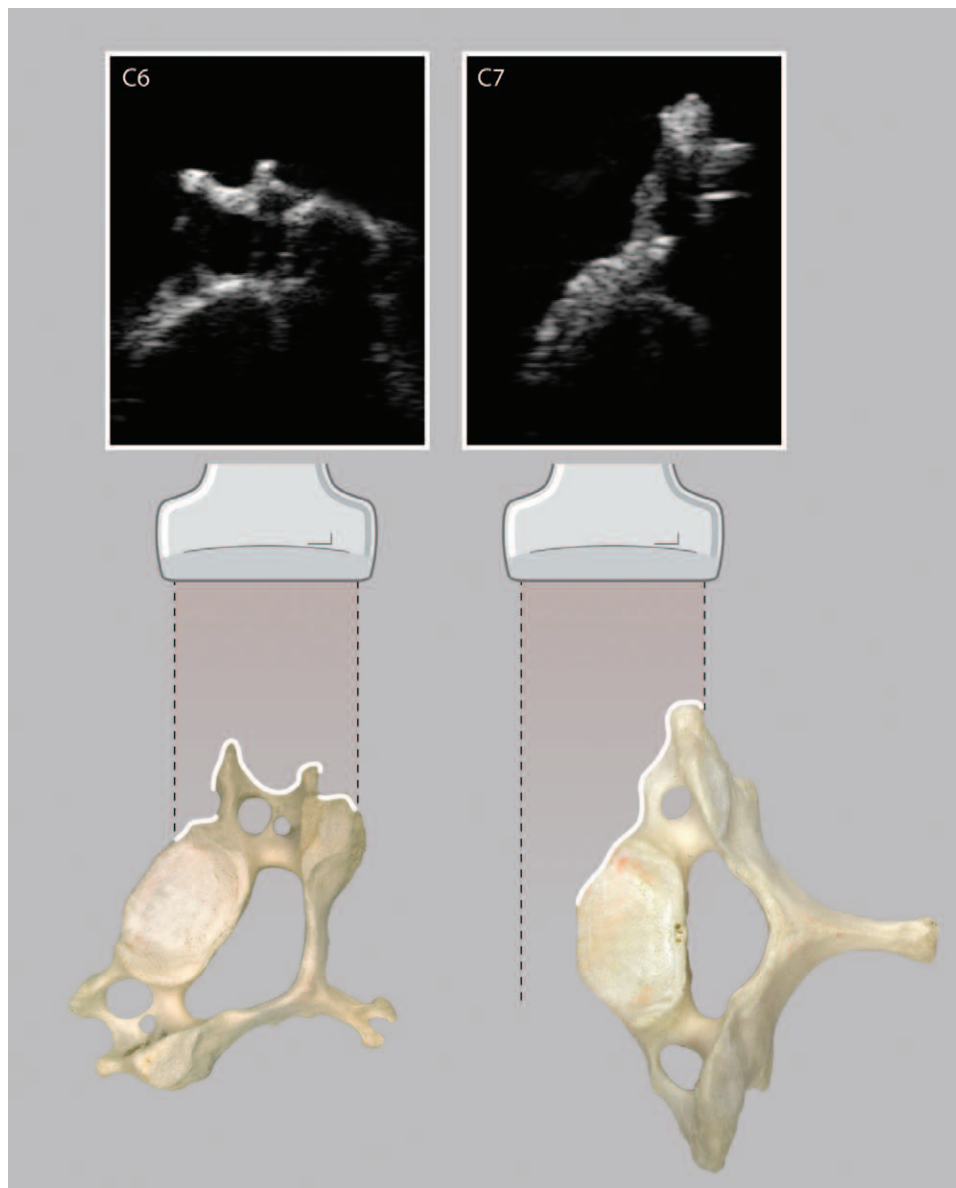
To our knowledge, this is the first study that systematically validated ultrasound images of all cervical vertebrae and related relevant bony landmarks.

A previous study also used an *in vitro* blinded gelatin model of the cervical spine, but it was unclear how the

ultrasound procedure was standardized.<sup>5</sup> Only the sixth and seventh cervical vertebrae were studied as anatomical landmarks to locate the cervical plexus. Reproducibility was evaluated by three different observers performing the procedure. Although the authors stated that all three observers placed their needle at the seventh cervical vertebra, no data were provided in that study about the exact needle position of the three observers.

In other studies, the ultrasound procedures to identify the specific cervical levels and the target nerves were





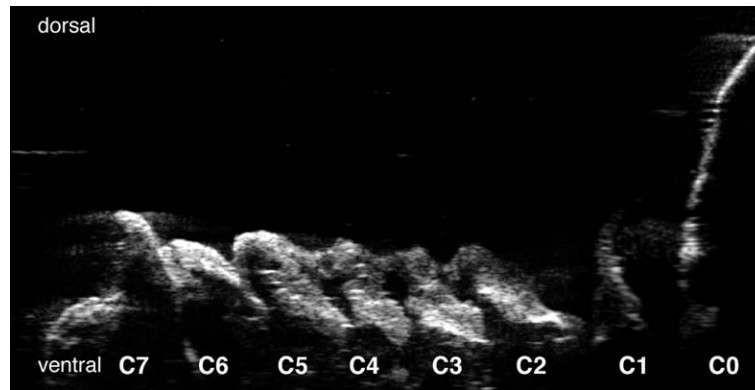
**Fig. 5.** Ultrasound imaging of C6 and C7. Illustration shows how ultrasound beam reflects from bony surfaces. *White line markings* in illustration correspond to ultrasound image shapes. Ultrasound image of transverse process of C6 (90° z-axis probe rotation; 85° rotation gelatin-embedded cervical model axis) and of transverse process of C7 (90° z-axis probe rotation; 90° rotation gelatin-embedded cervical model axis). Note that C7 has no anterior tubercle.

descriptive.<sup>6,8,9</sup> In the description of the ultrasound procedures, different cervical anatomical landmarks were mentioned such as the mastoid bone, bony structures of the atlas and axis, the tubercles of C6 and C7, and the vertebral artery. However, none of these structures, except for the C6 and C7 tubercles, were anatomically validated. Needles were placed under ultrasound guidance after identification of the segmental level and the target structure. None of these studies used standardized criteria for needle positions. The positions of the under ultrasound-placed needles were verified by computerized tomography scan or fluoroscopy. In a recently published study in healthy volunteers, with standardized criteria for needle positions, ultrasound-guided

needle placement was compared with fluoroscopy as reference test or definitive standard.<sup>11,12</sup> The final needle position aimed at a predefined structure (the middle of the cervical facet column) was correct in only 77% when controlled by radiography.<sup>11,13</sup>

If ultrasound guidance in cervical interventional pain treatments was to replace fluoroscopy, this ultrasound procedure must be reliable in identifying not only the target structure but also the correct cervical segmental level.<sup>2</sup>

In another recent study about ultrasound-guided needle placement aimed at the medial branch of the cervical facet joint, the position of the inserted needle was at the wrong cervical level as controlled by fluoroscopy in 2 of 50



**Fig. 6.** Composition of dorsolateral view (75° gelatin-embedded cervical model axis rotation, 0° z-axis probe rotation) Ultrasound images (C0–C7) of vertebral laminae. Composition of ultrasound images of the laminae of C1 to C7 (dorsolateral view). These images were acquired in our cervical spinal model by turning the cervical spine around the gelatin-embedded cervical model axis (75° rotation) keeping the probe in 0° z-axis probe rotation.

patients.<sup>14</sup> Validation of bony cervical structures seen on ultrasound images can be helpful to develop a more reliable ultrasound procedure to determine the different cervical segmental levels.

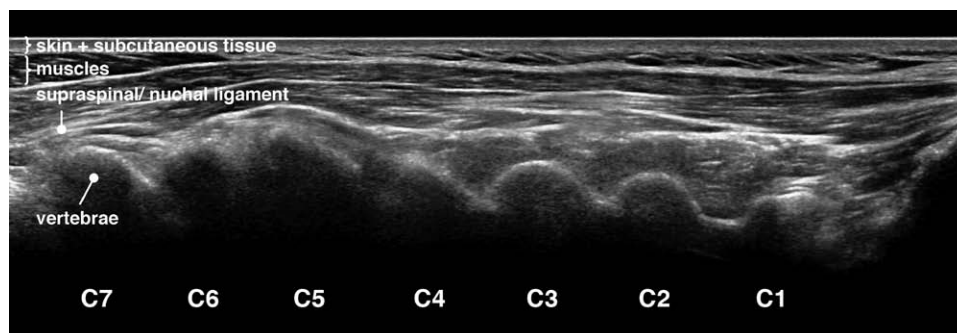
### Summary of Results

The intraclass correlation coefficient of 0.99 for single measures reflects an excellent reproducibility of the applied standardized *in vitro* ultrasound procedure. The use of laser lights in our study provided anatomically validated ultrasound images. Our study showed cervical ultrasound images in dorsal, ventral, and lateral views with clearly recognizable osseous features without the flaw of possible misinterpretation. In addition to this, potentially useful bony landmarks for clinical use in determination of the segmental level were defined. The clearly identifiable structures that could be used as key anatomical landmarks are the base of the skull, the mastoid process, the lateral process of C1, the C7 vertebra typically with a posterior tubercle and no anterior tubercle, and the laminae of C2 to C7. The best way to count the segmental levels *in vivo* is with the probe in long-axis position (0° z-axis position in our model), in a dorsolateral view at the level of the laminae. Starting at the base of the skull, sliding the probe caudally, the laminae of

all cervical levels can consecutively be seen. Even though the arch of C1 is small and sometimes located deeper than the laminae of C2 to C7, it is a better method than using the transverse process of C1 as an anatomical landmark. This is because rotational movement along the longitudinal axis of the neck makes orientation of osseous structures difficult, which then causes counting of the segmental levels to be less reliable.

### Educational Applications

Ultrasound expertise is largely a matter of pattern recognition and therefore has a steep learning curve. The ultrasound images of our study can be used as reference images in practical instructional courses for interventional pain treatments. They can be used as a first step in the interpretation of the *in vivo* ultrasound image and for highlighting anatomical bony landmarks. The use of phantoms in the training for ultrasound-guided interventions in pain medicine may facilitate the learning curve, and there is an emerging consensus that it is no longer acceptable to use patients to gain early experience. Other ultrasound-training models have been described.<sup>15–17</sup> Our gelatin model with a cervical spine, if blinded, can be used for anatomical location and level confirmation and as a training model for



**Fig. 7.** Composition of *in vivo* ultrasound images of vertebral laminae. Composition of *in vivo* ultrasound images aimed at the base of the skull and the laminae of C1 to C7, with a sliding cranio caudal movement. Despite the overlying soft-tissue structures, the consecutive cervical laminae can be seen and counted.

ultrasound-guided needle placement. Advantages of our gelatin model are its low costs, technical simplicity, and reproducibility.

### Methodological Limitations

This study was performed in an *in vitro* setting. We scanned the cervical spine from several directions, but the ultrasound images from ventral view will be of little clinical use. Only one cervical spine was used; therefore, extrapolation to other cervical spines is not possible. Anatomical variation, congenital disorders, and/or cervical bony degeneration can show different ultrasound bony images.

For ultrasound-guided pain procedures, it is important to visualize key landmark structures including nerves, blood vessels, pleura, muscles, tendons, fascia, and bone. Only a bony cervical spine was used to build the model: soft-tissue structures such as muscles, vascular structures, and nerves were not included. Therefore, our *in vitro* ultrasound images differ from ultrasound images in daily practice. However, bony structures are often most striking and therefore important reference points used in ultrasound imaging of the spine.

### Future Research

Recently, recommendations for the education and training in ultrasound-guided pain medicine were published. One of the objectives was to highlight and outline the current recommended ultrasound technique for key interventional procedures.<sup>18</sup> Our model could be useful in description, evaluation, and teaching of these recommended techniques. Our model helped to find a reliable *in vivo* procedure to count and detect the cervical segmental levels. It would be meaningful if our *in vitro* gelatin model could be further expanded with muscles, vascular structures, and nerves. Further research must show whether our model can be implemented in education and training for ultrasound-guided cervical interventional pain management procedures and whether other regions of the spine (*e.g.*, lumbar, sacral) can be used as a specimen in our model.

In conclusion, ultrasound bony images of cervical vertebrae can be validated with this *in vitro* model. Validated ultrasound bony images of our model were used to develop an ultrasound procedure to identify the different cervical segmental levels *in vivo*.

### Acknowledgments

The authors thank Johan Hekking, B.Sc. (Department of Anatomy and Embryology, Maastricht University, Maastricht, The Netherlands), and Leon Huibers, B.Sc. (Department of Anatomy and Embryology, Maastricht University), for their technical assistance with the gelatin model and their help with photography. The authors also thank Rogier Trompert, M.Sc. (Department of Anatomy and Embryology, Maastricht University), and Greet Mommen, M.Sc. (Department of Anatomy and Embryology, Maastricht University), for editing the ultrasound images and making the additional illustrations.

Support was provided solely from institutional and/or departmental sources.

### Competing Interests

The authors declare no competing interests.

### Correspondence

Address correspondence to Dr. van Eerd: Maastricht University Medical Center, Department of Anesthesiology and Pain Management, University Pain Center Maastricht, PO Box 5800, 6202 AZ Maastricht, The Netherlands. [mveerd@gmail.com](mailto:mveerd@gmail.com). This article may be accessed for personal use at no charge through the Journal Web site, [www.anesthesiology.org](http://www.anesthesiology.org).

### References

1. Narouze S, Peng PW: Ultrasound-guided interventional procedures in pain medicine: A review of anatomy, sonoanatomy, and procedures. Part II: Axial structures. *Reg Anesth Pain Med* 2010; 35:386–96
2. Narouze SN: Ultrasound-guided cervical spine injections: Ultrasound “prevents” whereas contrast fluoroscopy “detects” intravascular injections. *Reg Anesth Pain Med* 2012; 37:127–30
3. Gofeld M: Ultrasonography in pain: A critical review. *Pain Practice* 2008; 8:226–40
4. Gofeld M, Bhatia A, Abbas S, Ganapathy S, Johnson M: Development and validation of a new technique for ultrasound-guided stellate ganglion block. *Reg Anesth Pain Med* 2009; 34:475–9
5. Martinoli C, Bianchi S, Santacroce E, Pugliese F, Graif M, Derchi LE: Brachial plexus sonography: A technique for assessing the root level. *AJR Am J Roentgenol* 2002; 179:699–702
6. Galiano K, Obwegeser AA, Bodner G, Freund MC, Gruber H, Maurer H, Schatzer R, Fiegele T, Ploner F: Ultrasound-guided facet joint injections in the middle to lower cervical spine: A CT-controlled sonoanatomic study. *Clin J Pain* 2006; 22:538–43
7. Lee SH, Kang CH, Derby R, Yang SN, Lee JE, Kim JH, Kim SS, Lee SI: Ultrasound-guided radiofrequency neurotomy in cervical spine: Sonoanatomic study of a new technique in cadavers. *Clin Radiol* 2008; 63:1205–12
8. Eichenberger U, Greher M, Kapral S, Marhofer P, Wiest R, Remonda L, Bogduk N, Curatolo M: Sonographic visualization and ultrasound-guided block of the third occipital nerve: Prospective for a new method to diagnose C2-C3 zygapophysial joint pain. *ANESTHESIOLOGY* 2006; 104:303–8
9. Narouze SN, Vydyanathan A, Kapural L, Sessler DI, Mekhail N: Ultrasound-guided cervical selective nerve root block. *Reg Anesth Pain Med* 2009; 34:343–8
10. Patijn J, Ellis RF: Low back pain: Reproducibility of diagnostic procedures in manual/musculoskeletal medicine. *J Orthop Med* 2001; 23:36–42
11. Siegenthaler A, Mlekusch S, Trelle S, Schliessbach J, Curatolo M, Eichenberger U: Accuracy of ultrasound-guided nerve blocks of the cervical zygapophysial joints. *ANESTHESIOLOGY* 2012; 117:347–52
12. Gjørup T: The kappa coefficient and the prevalence of a diagnosis. *Methods Inf Med* 1988; 27:184–6
13. Buvanendran A, Rathmell JP: Ultrasound *versus* fluoroscopy in image-guided pain treatment: Use caution. *ANESTHESIOLOGY* 2012; 117:236–7

14. Finlayson RJ, Gupta G, Alhujairi M, Dugani S, Tran de QH: Cervical medial branch block: A novel technique using ultrasound guidance. *Reg Anesth Pain Med* 2012; 37:219–23
15. Osmer CL: A gelatine-based ultrasound phantom. *Anaesthesia* 2008; 63:107
16. Hocking G, Hebard S, Mitchell CH: A review of the benefits and pitfalls of phantoms in ultrasound-guided regional anesthesia. *Reg Anesth Pain Med* 2011; 36:162–70
17. Lerman IR, Souzalnitski D, Narouze S: A low-cost, durable, combined ultrasound and fluoroscopic phantom for cervical transforaminal injections. *Reg Anesth Pain Med* 2012; 37:344–8
18. Narouze SN, Provenzano D, Peng P, Eichenberger U, Lee SC, Nicholls B, Moriggl B: The American Society of Regional Anesthesia and Pain Medicine, the European Society of Regional Anesthesia and Pain Therapy, and the Asian Australasian Federation of Pain Societies Joint Committee recommendations for education and training in ultrasound-guided interventional pain procedures. *Reg Anesth and Pain Med* 2012; 37:657–64