Maastricht University

Osteoarthritis of the Atlanto-odontoid joint : a radiological and clinical study

Citation for published version (APA):

Zapletal, J. (1995). *Osteoarthritis of the Atlanto-odontoid joint : a radiological and clinical study*. [Doctoral Thesis, Maastricht University]. Rijksuniversiteit Limburg. https://doi.org/10.26481/dis.19950908jz

Document status and date:
Published: 01/01/1995

DOI:
10.26481/dis.19950908jz

Document Version:
Publisher's PDF, also known as Version of record

Please check the document version of this publication:

• A submitted manuscript is the version of the article upon submission and before peer-review. There can be important differences between the submitted version and the official published version of record. People interested in the research are advised to contact the author for the final version of the publication, or visit the DOI to the publisher's website.
• The final author version and the galley proof are versions of the publication after peer review.
• The final published version features the final layout of the paper including the volume, issue and page numbers.

Link to publication

General rights
Copyright and moral rights for the publications made accessible in the public portal are retained by the authors and/or other copyright owners and it is a condition of accessing publications that users recognise and abide by the legal requirements associated with these rights.

• Users may download and print one copy of any publication from the public portal for the purpose of private study or research.
• You may not further distribute the material or use it for any profit-making activity or commercial gain
• You may freely distribute the URL identifying the publication in the public portal.

If the publication is distributed under the terms of Article 25fa of the Dutch Copyright Act, indicated by the “Taverne” license above, please follow below link for the End User Agreement:

www.umlib.nl/taverne-license

Take down policy
If you believe that this document breaches copyright please contact us at:

repository@maastrichtuniversity.nl

providing details and we will investigate your claim.

Download date: 18 Apr. 2024

Osteoarthritis of the Atlanto-odontoid Joint
A Radiological and Clinical Study

Osteoarthritis of the Atlanto-Odontoid Joint
A Radiological and Clinical Study

Artrose van het Atlanto-Dentale Gewricht
Een Radiologische en Klinische Studie

PROEFSCHRIFT

ter verkrijging van de graad van doctor aan de Rijksuniversiteit te Maastricht, op gezag van de Rector Magnificus Prof. mr. M.J. Cohen, volgens het besluit van het College van Dekanen in het openbaar te verdedigen op 8 september 1995 om 16.00 uur

Door

Jiri Zapletal

Promotor: Prof. dr. J.T. Wilmink

Co-promotor: Dr. R.E.M. Hekster (Leyenburg ziekenhuis, Den Haag)

Beoordelingscommissie:

- Prof.dr. J. Troost, hoogleraar Neurologie (voorzitter)
- Prof. dr. E.A. Beuls, hoogleraar Neuroanatomie (Universiteit van Diepenbeek, Belgie)
- Dr. A van Ooy, UD vakgroep Orthopaedie
- Prof. dr. L. Penning, em. hoogleraar Radiologie (Rijksuniversiteit Groningen)
- Prof. dr. J.W.J.L. Stapert, hoogleraar Algemene Heelkunde i.h.b. de Traumatologie

The publication of this thesis was financially supported by; Het Nationaal Reumafonds, Siemens, Byk, Guerbet, Nycomed, Schering, Kodak and Asta.

Druk: J.H. Pasmans b.v., 's- Gravenhage

Aan mijn ouders

Voor Monique

This thesis is based on the following publications

Chapter 2 Atlanto-odontoid osteoarthritis: appearance and prevalence at CT
Spine 1995; 20:49-53

Chapter 3 Relationship between atlanto-odontoid osteoarthritis and idiopathic suboccipital neck pain
Accepted for publication in Neuroradiology

Chapter 4 Atlanto-odontoid osteoarthritis: comparison of lateral cervical projection and CT
Accepted for publication in European Spine Journal (in press)

Chapter 5 MR imaging of severe atlanto-odontoid osteoarthritis
Submitted
Accepted as Scientific Exhibit ESNR. Budapest September 1995

Chapter 6 Vacuum phenomenon in osteoarthritis of the atlanto-odontoid joint: CT findings
Skeletal Radiology 1995; 24:131-133

Chapter 7 Association of transverse ligament calcification with atlanto-odontoid osteoarthritis
Accepted for publication in Neuroradiology (in press)

CONTENTS

Chapter 1 INTRODUCTION 11

1.1 General 12
1.2 Aim of the study 13
1.3 A short history 13
1.4 Bibliography 15

Chapter 2 ATLANTO-ODONTOID OSTEOARTHRITIS: APPEARANCE AND PREVALENCE AT COMPUTED TOMOGRAPHY 21

2.1 Abstract 23
2.2 Introduction 24
2.3 Materials and methods 24
2.4 Results 25
2.5 Discussion 28
2.6 References 31

Chapter 3 RELATIONSHIP BETWEEN ATLANTO-ODONTOID OSTEOARTHRITIS AND IDIOPATHIC SUBOCCIPITAL NECK PAIN 33

3.1 Abstract 35
3.2 Introduction 36
3.3 Materials and methods 36
3.4 Results 39
3.5 Discussion 40
3.6 References 42

Chapter 4 ATLANTO-ODONTOID OSTEOARTHRITIS: COMPARISON OF LATERAL CERVICAL PROJECTION AND CT 45

4.1 Abstract 47
4.2 Intoduction 48
4.3 Materials and methods 48
4.4 Results 49
4.5 Discussion 54
4.6 References 56

Chapter 5 MR IMAGING OF SEVERE ATLANTO-ODONTOID OSTEOARTHRITIS 59

5.1 Abstract 61
5.2 Introduction 62
5.3 Materials and methods 62
5.4 Normal Anatomy 63
5.5 Results 64
5.6 Discussion 66
5.7 References 67

Chapter 6 VACUUM PHENOMENON IN OSTEOARTHRITIS OF THE ATLANTO-ODONTOID JOINT: CT FINDINGS 69

6.1 Abstract 71
6.2 Introduction 72
6.3 Materials and methods 72
6.4 Results 72
6.5 Discussion 75
6.6 References 77

Chapter 7 ASSOCIATION OF TRANSVERSE LIGAMENT CALCIFICATION WITH ATLANTO-ODONTOID OSTEOARTHRITIS 79

7.1 Abstract 81
7.2 Introduction 82
7.3 Materials and methods 82
7.4 Results 84
7.5 Discussion 85
7.6 References 87

Chapter 8

- Summary and Conclusions 89
- Samenvatting en Conclusies 93

- Acknowledgements 97
- Curriculum Vitae 97

CHAPTER 1

INTRODUCTION

1.1 General

Degenerative joint disease (osteoarthritis) is an important cause of morbidity and disability in the community. The prevalence of degenerative joint disease is high, especially in the elderly, and still increasing due to increasing longevity. Osteoarthritis of the various joint sites involved (knee, hip, cervical spine ect.) has differing associations and expression. Each involvement should therefore be considered as a different condition.

Regarding degenerative disease of the cervical spine, spondylarthrosis and disc degeneration as seen on radiographs of the cervical spine have received considerable attention in the literature. These degenerative abnormalities are frequently regarded as a pathological state related to the production of neck pain or brachialgia. However, osteoarthritis of the functionally important atlanto-odontoid joint, situated between the anterior arch of the atlas (C1) and odontoid process of the axis (C2), is a condition about which little is known. This is probably due to frequent obscurement of this functionally important synovial joint (see Figure) by overlying skull base structures on routine radiographs of the cervical spine. Furthermore, clinicians rarely ask for diagnostic studies directed toward atlanto-odontoid osteoarthritis due to a lack of awareness of the clinical importance of degenerative changes within this particular joint.

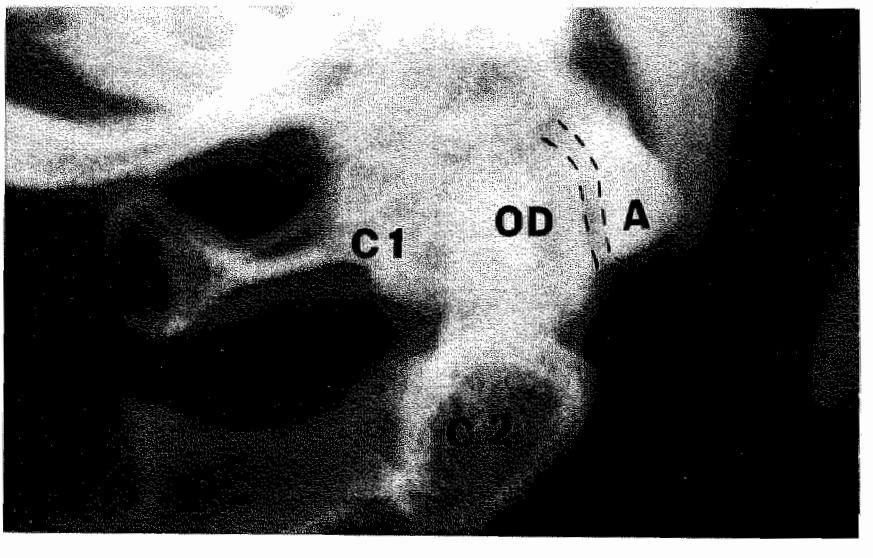

Figure *The C1-C2 segment is the most mobile region of the cervical spine. The primary motion at the C1-C2 joint is rotation (38^0 -92^0).*
A *= anterior arch of C1* ***OD*** *= odontoid process of C2*

Some authors have suggested that atlanto-odontoid osteoarthritis is a process which might be at the origin of pain in the suboccipital region. Unfortunately this association has been based only on a few case reports or small samples of preselected patients. Our appreciation of the high frequency of patients with chronic suboccipital pain has led us to undertake studies regarding the appearance of atlanto-odontoid osteoarthritis on radiographs, CT and MR, furthermore regarding prevalence of degenerative changes on CT and finally regarding a possible relationship between CT findings in atlanto-odontoid osteoarthritis and pain in the suboccipital region.

1.2 Aim of the study

One of the main purposes of a radiological imaging study is to detect and characterize morphologic changes that may explain a patient's symptomatology. The aim of this study was to document the prevalence and appearance of atlanto-odontoid osteoarthritis on computed tomography and to determine whether presence or severity of visible degenerative changes at the atlanto-odontoid joint on CT was associated with symptoms in the suboccipital region (**Chapter 2 and 3**). Furthermore we were interested in the accuracy of lateral cervical spine radiography in the detection and grading of degenerative change in atlanto-odontoid joint osteoarthritis (**Chapter 4**). Another interesting field was the appearance of atlanto-odontoid osteoarthritis on Magnetic Resonance Imaging (**Chapter 5**). Finally, gas accumulation (vacuum phenomenon) within the atlanto-odontoid joint and transverse ligament calcification located posteriorly to the odontoid process, were visible in some patients with atlanto-odontoid osteoarthritis. The prevalence of the transverse ligament calcification and prevalence of the vacuum phenomenon within the atlanto-odontoid joint, which has not been reported previously, was evaluated. Furthermore, we studied whether the gas accumulation or transverse ligament calcification was associated with the degenerative process at the atlanto-odontoid joint (**Chapter 6 and 7**).

1.3 A short history [1]

1935

Shore studied macerated bones derived from vertebral columns assembled for anatomical or anthropological research. 32.2% of specimens of atlas and axis showed degenerative disease at the atlanto-odontoid joint.

---

1 Only literature with specific historical impact regarding degenerative change at the AO joint is discussed

Although no clinical notes were available he stated: "Osteoarthritis of the anterior atlanto-axoid joint might well have a clinical interest". Furthermore he noted that osteoarthritis is commoner in the atlanto-odontoid joint than any of the dorsal intervertebral joints, exept in those of the lumbar region.

1942

Olsson discussed the radiographic findings in degenerative arthritis of the atlanto-odontoid joint. He noted that degenerative change at this particular joint can occur without degenerative abnormalities at other joints of the cervical spine.

1969

Sager studied 100 postmortem cervical spines and found radiographic changes of osteoarthritis in 50 patients. The abnormalities reached a prevalence of 85% in patients aged 65 to 90 years. Degenerative arthritis in the atlanto-odontoid joint was far more common than in lateral atlantoaxial or zygoaphophyseal joints.

1969

Fischer and Schmidt reported that degenerative changes at the atlanto-odontoid joint occur frequently on radiographs in the elderly and can be predisposed to or accelerated by a variety of developmental and/or acquired factors.

1981

Harata et al encountered, over a period of years, 31 patients suffering from advanced atlanto-axial osteoarthritis detected on radiographs. They reported ten patients who sufferred from this condition and complained of (sub)occipital headache. They also found that 71% of these patients had radiographic abnormalities at the atlanto-odontoid and lateral atlanto-axial joints, whereas 17% had degenerative changes of the atlanto-odontoid joint alone. Furthermore, cadaver specimen showed that osteoarthritis of the atlanto-odontoid joint showed the same histologic changes as seen in osteoarthritis in other joints.

1981

Skaane and Klott described the appearance of a horseshoelike calcification around the odontoid process ("crowned odontoid") which can frequently been shown on transbuccal or a.p. tomography in patients with atlanto-odontoid osteoarthritis. This horseshoelike calcification represents mainly osteophyte formation on the superior border of the anterior arch of the atlas.

1982

Bogduk gave a detailed description of the anatomy of the upper cervical dorsal rami on cadavers. According to the author, noxious stimuli to structures such as the atlanto-odontoid joint (innervated by the C2 spinal nerve) can cause occipito-cervical pain. Furthermore he stated: "On clinical grounds alone, this reffered pain may be difficult to distinguish from pain syndromes such as tension headache and common migraine".

1990

Genez et al. evaluated cervical spine radiographs in 31 patients with limited motion, (sub)occipital headache and other problems involving the neck. All radiographs showed abnormalities of the atlanto-odontoid joint.

1991

Genez stated: "The clinical significance of CT and radiographic findings in atlanto-odontoid osteoarthritis has not been elucidated with certainty". "Further studies should address this issue".

1.4 Bibliography

LP Adams, A Tregidga, JP Driver-Jowitt, P Selby, S Wynchank. Analysis of motion of the head. *Spine* 1994 3; 266-271

M Alund, SE Larsson. Three-dimensional analysis of neck motion. A clinical Method. *Spine* 1990; 15: 87-91

JP Barrett jr, E Rashkoff, EC Sirna, A Wilson. Correlation of roentgenographic patterns and clinical manifestations of symptomatic idiopathic osteoarthritis of the knee. *Clin Orth and Rel Res* 1990; 4: 179-183

J Berato, O Dutour. A propos de l'artrose atlanto-odontoidienne "morbus ignobilis". *Revue du Rhumatisme* 1989; 56: 883

N Bogduk. The clinical anatomy of the cervical dorsal rami. *Spine* 1982; 7: 319-330

N Bogduk. Local anesthetic bloks of the second cervical ganglion: A technique with application in occipital headache. *Cephalagia* 1981; 1: 41-50

JP Bouvet, JM le Parc, B Michalski, C Benlahrache, L Auquier. Acute neck pain due to calcifications surrounding the odontoid process: The crowned dens Syndrome. *Arthritis and Rheumatism* 1985; 28: 1417-1420

G Bovim, H Schrader, T Sand. Neck pain in the general population. *Spine* 1994; 19: 1307-1309

GF Carrera, VM Haughton, A Syvertsen, AL Williams. Computed tomography of the lumbar facet joints. *Radiology* 1980; 134: 145-148

JL Dietemann, JM Metzger, JF Bonneville, A Wackenheim. Ossification du ligament transverse de l'atlas. *J Radiol* 1979; 60: 209-210

Y Dirheimer, C Bensimon, D Christmann, C Wackenheim. Syndesmo-odontoid joint and calcium pyrophosphate dihydrate deposition disease (CPPD). *Neuroradiology* 1983; 25: 319-321

Y Dirheimer, A Wackenheim. L'apophyse odontoide couronnee. *Sem Hop Paris* 1974; 50: 2077-2080

Y Dirheimer, C Wackenheim, JL Dietemann. Calcification of the transverse ligament in calcium dihydrate deposition disease (CPPD). *Neuroradiology* 1985; 27: 87

P Dreyfuss, M Michaelsen, D Fletcher. Atlanto-occipital and lateral atlanto-axial pain patterns. *Spine* 1994; 19: 1125-1131

J-L Dumas, P Thoreux, P Attali, D Goldlust, JP Chevrel. Three-dimensional CT analysis of atlantoaxial rotation: results in the normal subjects. *Surg Radiol Anat* 1994; 16: 199-204

J Edmeads. The cervical spine and headache. *Neurology* 1988; 38: 1874-1878

J Edmeads. Headaches and head pains associated with diseases of the cervical spine. *Medical clinics of North america* 1978; 62: 533-543

G Ehni, B Benner. Occipital neuralgia and the C1-C2 arthrosis syndrome. *J Neurosurg* 1984; 61: 961-965

GY El- Khoury, JE Tozzi, CR Clark, E Foucar, AH Menezes, WRK Smoker. Massive calcium pyrophosphate crystal deposition at the craniovertebral junction. *AJR* 1985; 145: 777-778

MH Ellman, NL Brown, B Levin. Narrowing of knee joint space in patients with pseudo-gout. *Ann Rheum Dis* 1981; 40: 34-36

E Fisher, H Schmidt. Die degenerativen Veranderungen des vorderen Atlanto-dentalen Gelenks. *Fortschr Rontgenstr* 1969; 111: 552-558

AM Fournier, J Rathelot. L'arthrose atlanto-odontoidienne: sa frequence comme d'algies nucales. *J Radiol Electrl* 1959; 40: 812-813

ZB Friedenberg, WT Miller. Degenerative disc disease of the cervical spine. *The Journal of bone and Joint Surgery* 1963; 45a: 1171-1178

BM Genez. Atlantoodontoid osteoarthritis. *Critical Reviews in Diagnostic Imaging* 1991; 32: 301-321

BM Genez, JJ Willis, CE Lowrey et al. CT findings of degenerative arthritis of the atlanto-odontoid joint. *AJR* 1990; 154: 315-318

JT Halla, JG Hardin. Atlantoaxial (C1-C2) facet joint osteoarthritis: a distinctive clinical syndrome. *Arthritis and Rheumatism* 1987; 30: 577-582

S Harata, S Tohno, T Kawagishi. Osteoarthritis of the atlanto-axial joint. *Internal Orthopeadics* 1981; 5: 277-282

HAMJ ten Have, F Eulderink. Degenerative changes in the cervical spine and their relationship to its mobility. *Pathology* 1980; 132: 133-159

CA Heller, P Stanley, B Lewis-Jones, RF Heller. Value of X-ray examinations of the cervical spine. *British Medical Journal* 1983; 287: 1276-1278

RJ Herzog. The goal of spinal imaging. *Spine* 1994;19: 2486-2488

J Hjarbaek, PW Kristensen, P Hauge. Spinal gas collection demonstrated at CT. *Acta Radiol* 1992; 33: 93-97

JL Hollander. Osteoarthritis, Perspectives on treatment. *Postgraduate Medicine* 1980; 68: 161-168

B Joseph, B Kumar. Gallie's fusion for atlantoaxial arthrosis with occipital neuralgia. *Spine* 1994; 19: 454-455

JH Kellgren, JS Lawrence. Radiological assesment of rheumatoid arthritis. *Ann Rheum Dis* 1957; 16: 485-493

J Kenez, L Turoczy, P Barsi, R Veres. Retro-odontoid "ghost" pseudotumors in atlanto-axial instability caused by rheumatoid arthritis. *Neuroradiology* 1993; 35: 367-369

BL Kidd, PI Mapp, DR Blake, SJ Gibson, JM Polak. Neurogenic influences in arthritis. *Ann Rheum Dis* 1990; 49: 649-652

D Ladre, D Mathieu, J Frija, A Gaston, N Vasile. Spinal vacuum phenomenon: CT diagnosis and significance. *J Comput Assist Tomogr* 1982; 6: 671-675

H Lai, S Goto, M Yamagata, T Tamaki, H Moriya, K Takahashi, M Mimura. Three-dimensional motion of the upper cervical spine in rheumatoid arthritis. *Spine* 1994; 3: 272-276

JS Lawrence, JM Bremmer, F Bier. Osteo-arthrosis prevalence in the population and relationship between symptoms and X-ray changes. *Ann Rheum Dis* 1966; 25: 1-24

CP Lee, MDF Deck, JB Kneeland, PT Cahill. MR imaging of the craniocervical junction. *AJNR* 1985; 6: 209-213

DM Lefkowitz, RM Quencer. Vacuum facet phenomenon: A computed tomographic sign of degenerative spondylolisthesis. *Radiology* 1982; 144: 562

T McAlindon, P Dieppe. Osteoarthritis: definitions and criteria. *Ann Rheum Dis* 1989; 48; 531-532

MT Modic, JS Ross, TJ Masaryk. Imaging of degenerative disease of the spine. *Clinical Orthopaedics and Related Research* 1989; 239: 109-120

F Molina, JE Ramcharan, BD Wyke. Structure and function of articular receptor systems in the cervical spine. *J Bone Joint Surg* 1976; 58B: 255-256

RW Moskowitz. Primary osteoarthritis: Epidemiology, clinical aspects, and general management. *The American Journal of Medicine* 1987; 83: 5-9

O Olsson. Arthrosis deformans des vorderen Zahngelenkes. *Fortschr Rontgenstr* 1942; 66: 233-239

L Penning. Normal movements of the cervical spine. *AJR* 1978; 130: 317-326

L Penning, JT Wilmink. Rotation of the cervical spine. a CT study in normal subjects. *Spine* 1987; 12: 732-738

V Pfaffenrath, R Dandekar, W Pollmann. Cervicogenic headache- the clinical picture, radiological findings and hypothesis on its pathophysiology. *Headache* 1987; 27: 495-499

M Reijnierse, JL Bloem, J Doornbos, HM Kroon. The signal intensity of the normal odontoid process (dens) displayed on magnetic resonance images. *Skeletal Radiol* 1992; 21: 519 521

D Resnick. Degenerative disease of the vertebral column. *Radiology* 1985; 156: 3-14

D Resnick, C Pineda. Vertebral involvement in calcium pyrophosphate dihydrate crystal deposition disease. *Radiology* 1984; 153: 55-60

D Resnick, G Niwayama, J Guerra, V Vint, J Usselman. Spinal vacuum phenomena: Anatomical study and review. *Radiology* 1981; 139: 341-348

D Ruwaard, PGN Kramers. Volksgezondheid toekomst verkenning. De gezondheids toestand van de Nederlandse bevolking in de periode 1950-2010. *Medisch Contact* 1994; 49: 187-191

P Sager. Spondylosis cervicalis. A pathological and osteoarcheologic study of osteochondrosis intervertebralis cervicalis, arthrosis uncovertebralis and spondylarthrosis cervicalis. Munskgaard Copenhagen 1969; 101-102.

RN Sener, GT Ripeckyj, PM Otto, RA Rauch, JR Jinkins. Recognition of abnormalities on computed scout images in CT examinations of the head and spine. *Neuroradiology* 1993; 35: 229-231

KW Sievers, U Dietrich, E Lohr. Radiologische aspecte des kraniozervikalen Ubergangs. *Dtsch Med Wschr* 1992; 117: 1072- 1077

ME Schweitzer, J Hodler, V Cervilla, D Resnick. Craniovertebral junction: Normal anatomy with MR correlation. *AJR* 1992; 158: 1087-1090

LR Shore. On Osteo-arthritis in the dorsal intervertebral joints. A study in morbid anatomy. *Br J Surg* 1935; 22: 833-849

P Skaane, KJ Klott. Die peridentale Aureole bei der vorderen Atlantodentalarthrose. *Fortschr rontgenstr* 1981; 134: 62-68

WRK Smoker. Craniovertebral junction: Normal anatomy, craniometry, and congenital anomalies. *Radiographics* 1994; 14: 255-277

A Stolt-Nielsen, TA Frederiksen, O Sjaastad. Headache due to an extra joint between head and neck. *Headache* 1995; 35: 44-47

G Sze, MN Brandt-Zawadski, ChR Wilson, D Norman, TH Newton. Pseudotumor of the craniovertebral junction associated with chronic subluxation: MR imaging studies. *Radiology* 1986; 161: 391-394

JG Teplick, SK Teplick, L Goodman, ME Haskin. Pitfalls and unusual findings in computed tomography of the lumbar spine. *J Comput Assist Tomogr* 1982; 6: 888-893

J Treleaven, G Jull, L Atkinson. Cervical musculoskeletal dysfunction in post-contusional headache. *Cephalagia* 1994; 14: 273-279

M Weber, H Gerber. Akutes zervikalsyndrom bei chondrocalcinose. *Schweiz Med Wschr* 1991; 121: 642-645

E Wilkins, P Dieppe, P Maddison, G Evison. Osteoarthritis and articular chondrocalcinosis in the elderly. *Ann Rheum Dis* 1983; 42: 280-284

B Wyke. Neurology of the cervical spinal joints. *Physiotherapy* 1979; 65: 72-76

Z Yetkin, K Chintapalli, DL Daniels, VM Haughton. Gas in spinal articulations. *Neuroradiology* 1986; 28: 50-56

DK Yousefzadeh. The value of traction during roentgenography of the wrist and metacarpophalangeal joints. *Skeletal Radiology* 1979; 4: 29-33

D Zitnan, S Sitaj. Natural course of articular chondrocalsinosis. *Arthritis and Rheum* 1976; 19: 369-390

CHAPTER 2

ATLANTO-ODONTOID OSTEOARTHRITIS: APPEARANCE AND PREVALENCE AT COMPUTED TOMOGRAPHY

J Zapletal[1], REM Hekster[1], JS Straver[2], JT Wilmink[3]

1 Department of Radiology, Leyenburg Hospital , The Hague
2 Department of Neurology, Leyenburg Hospital, The Hague
3 Department of Neuroradiology, University Hospital Maastricht

Published in:
Spine 1995; Volume 20, Number 1, pp 49-53

2.1 Abstract

In this prospective study, we evaluated the atlanto-odontoid (AO) joint in 500 consecutive patients who underwent computed tomography (CT) of the brain or paranasal sinuses. The objective of the study was to determine age specificity of various morphologic abnormalities related to osteoarthritis at the AO joint in patients referred for CT primarily to exclude brain or sinus abnormalities. In all patients, at least two axial slices through the AO joint were evaluated by two authors, and agreement was reached by consensus. Abnormal morphology was categorized into three groups: (1) osteophytosis; (2) obliteration of the joint space; and (3) transverse ligament calcification. In a significant percentage of older individuals some form of degenerative disease is present. These changes show a roughly linear progression with advancing age. We conclude that morphologic changes related to AO osteoarthritis are frequent coincidental findings in patients referred for CT examination of the brain or paranasal sinuses.

2.2 Introduction

Neck pain is a frequent complaint. Patients with symptoms relating to the cervical spine usually are examined initially with conventional radiography. Correlating the radiographic findings with the patient's symptomatology is difficult.

Radiographs of the cervical spine provide direct information about the vertebrae, intervertebral disk height and intervertebral joints but evaluation of the atlantoodontoid (AO) joint (anterior C1-C2 joint) is difficult because of overlying osseous structures. Computed tomography (CT) is an excellent imaging modality for visualizing the AO joint because it may reveal findings invisible on conventional radiography [8] .

Because of its function and situation, the AO joint is subject to degenerative changes [5,12]. These changes are similar to those commonly observed in other synovial joints and include narrowing of the joint space, marginal cortical thickening and osteophyte formation. Another abnormality seen occasionally by CT in older patients, is transverse ligament calcification [7].

To our knowledge no previous study has addressed specifically the prevalence of these changes within the AO joint as detected on CT. Prompted by the frequent observation of morphologic changes in the AO joint in patients who underwent a CT scan of the brain, we undertook a prospective study to determine age specificity and the presence of various morphologic abnormalities at the AO joint in patients referred for CT of the brain or the paranasal sinuses.

2.3 Materials and methods

A consecutive series of 500 unselected patients undergoing CT scans of the brain or paranasal sinuses was studied. There were 245 men and 255 women ranging in age from 20 to 93 years. In all patients, CT was performed primarily to exclude brain or sinus abnormalities. No patient in this study was referred for detection of degenerative arthrosis.

In all patients at least two axial contiguous slices through the anterior C1-C2 joint were evaluated (Figure 1). All CT examinations were performed by standard technique (420 mAs, 120 kVp) on a Siemens, Somatom PLUS-S, Erlangen, using 5-mm slices. All images were reviewed by two authors (J.Z. and R.E.M.H) and agreement was reached by consensus.

We studied the AO joint in each patient in soft tissue and bone window settings. When a sign of degenerative disease was found, its morphology was categorized into one of three groups: (1) osteophytosis; (2) obliteration of the joint space; (3) transverse ligament calcification. Additionally, the prevalence of osteophytosis together with obliteration of the joint space was evaluated. "Osteophytosis" referred to excrescences arising from the articular facet of the atlas and projecting around the odontoid process (Figure 2).

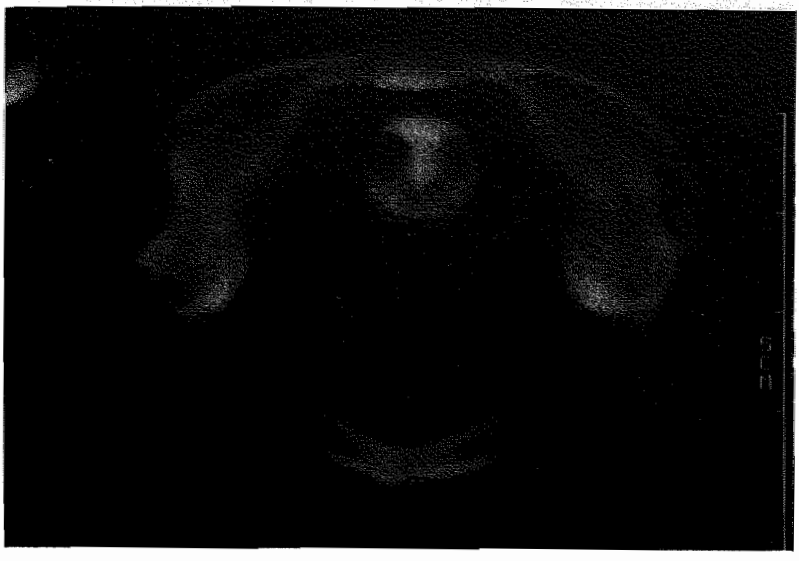

Figure 1. *Normal atlanto-odontoid joint. Axial CT shows normal joint space width and absence of degenerative signs*

"Obliteration of the joint space" referred to disappearance of the AO joint space, with or without sclerosis of the bony structures (Figure 3). "Transverse ligament calcifications" referred to linear or mottled calcifications in the ligament immediately posterior to the odontoid (Figure 4). Other uncommon degenerative features such as small cysts and small para-articular ossicles, best identifiable with thin slices (2 mm.) have been omitted from-analysis but were visualized in several cases (Figure 5).

2.4 Results

In Figure 6 the degenerative changes are summarized. Some form of degenerative disease was seen in a significant percentage of individuals and the frequency of all types of degenerative changes in the AO joint increased with age. No degenerative abnormalities were found before the 4th decade. After the 4th decade, the changes showed a roughly linear progression with advancing age. The number of patients studied was 78 in the 5th, 77 in the 6th, 86 in the 7th, 138 in the 8th and 46 in the 9th decade.

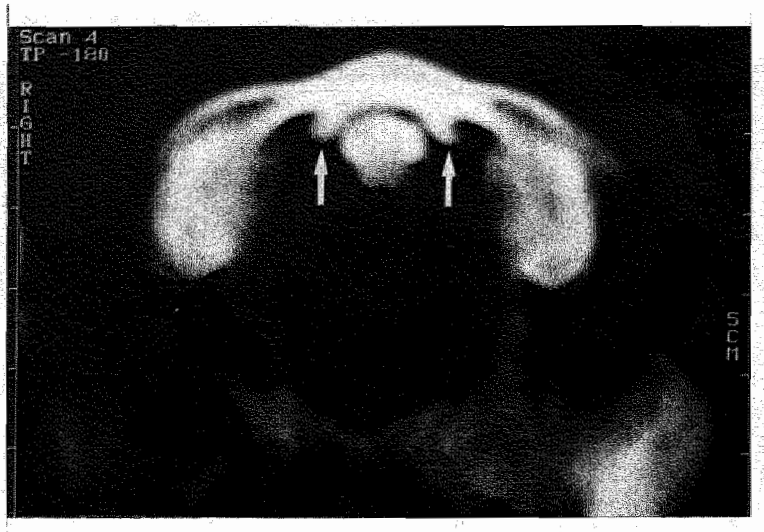

Figure 2. *Axial CT demonstrates median facet osteophytes (arrows)*

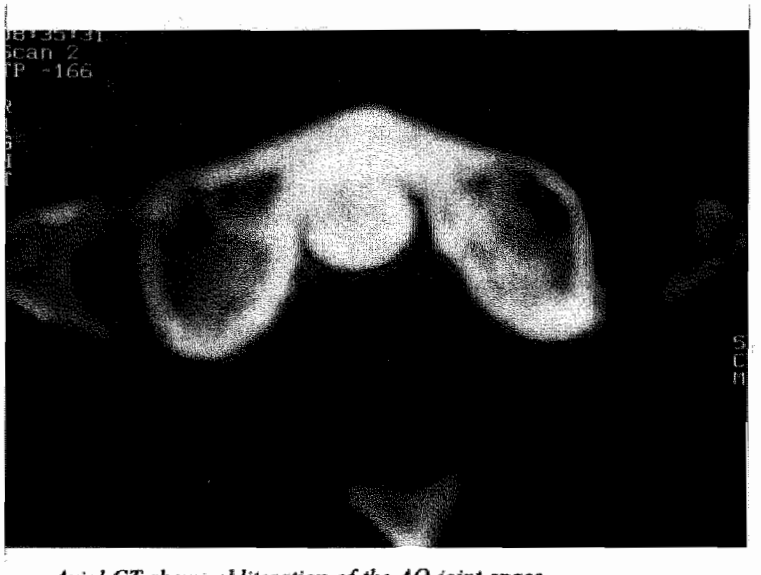

Figure 3. *Axial CT shows obliteration of the AO joint space*

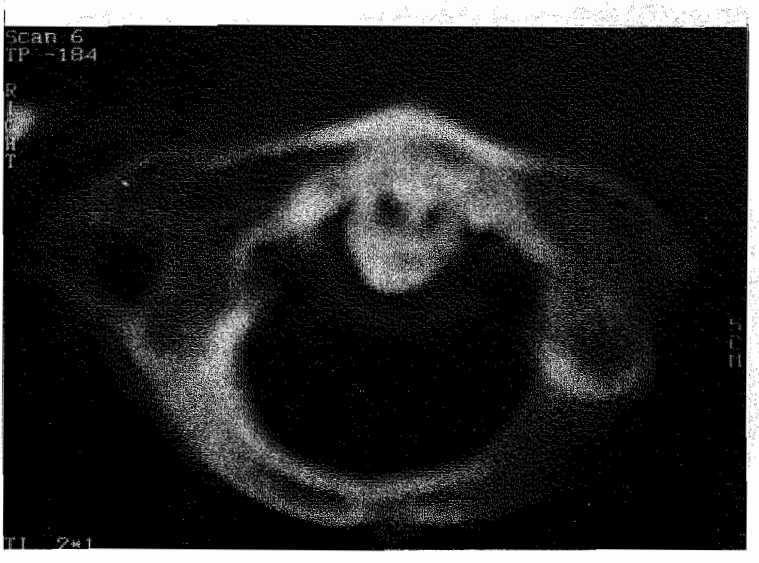

Figure 4. *Axial CT demonstrates a thin AO joint rim of calcification posterior to the odontoid together with an obliteration of the AO joint space*

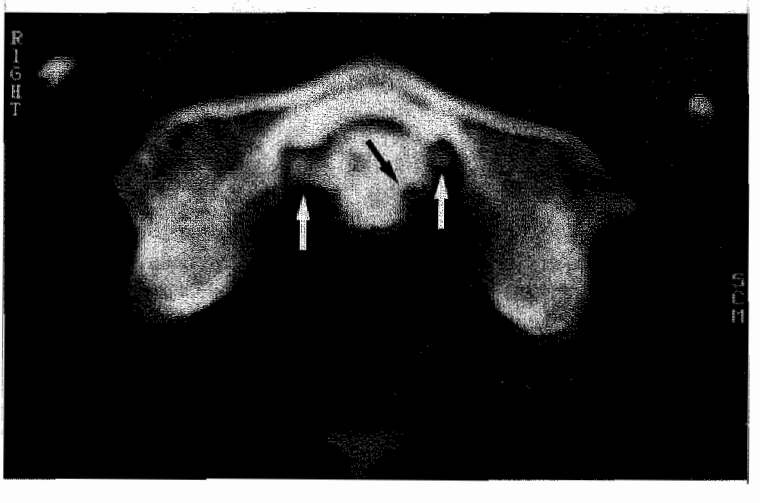

Figure 5. *Axial CT shows a small degenerative cyst in the odontoid process (black arrow) and small para-articular ossicles (white arrows)*

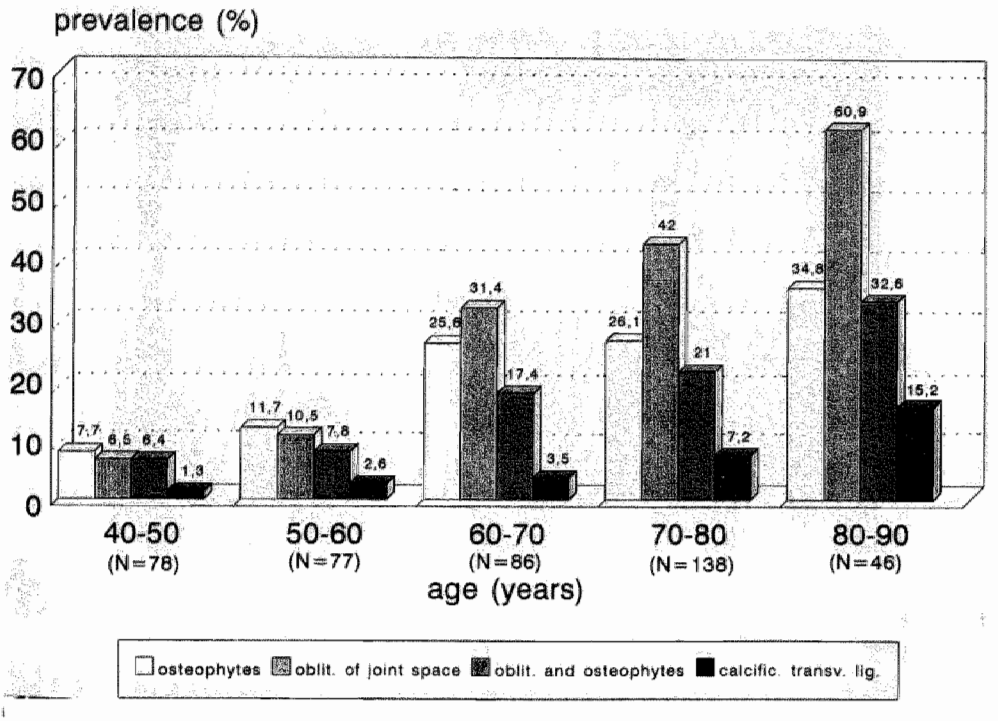

Figure 6. *Age specific prevalence (expressed as percentage) of degenerative abnormalities at the atlanto-odontoid joint in a group of 500 consecutive patients referred for CT of the brain or paranasal sinuses.*

2.5 Discussion

Little attention has been paid to degenerative changes at the the AO joint in the literature, presumably owing to its obscurement by overlying structures on routine lateral and antero-posterior views of the cervical spine and also because of a paucity of information about its clinical importance. Recognition of AO osteoarthritis usually requires a transbuccal view or tomography. These techniques frequently show a horsehoelike calcification around the odontoid process ("crowned odontoid") indicating excrescences mainly from the median facet of the atlas [15] (Figure 7). CT is the best way to demonstrate these bony changes (Figure 8). Other morphologic changes at the AO joint, also best identifiable with CT, are obliteration of the joint space and transverse ligament calcifications immediately posterior to the odontoid. Even small degenerative cysts in the odontoid process, the atlas or both and free para-articular ossicles can sometimes be demonstrated especially when thin slices are used [8].

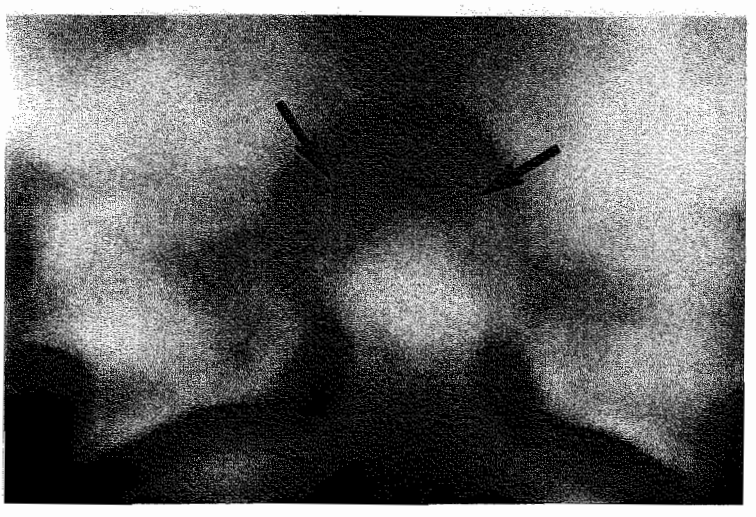

Figure 7. *A-P Tomography shows a horseshoelike calcification around the odontoid process (arrows).*

This CT study shows that morphologic changes related to AO osteoarthritis are frequent coincidental findings in patients referred for CT examination of the brain or paranasal sinuses. The changes appear after the age of 40 years, and increase with advancing age. Obliteration of the joint space is the most frequent degenerative sign in the eldery. This finding may be present without osteophytes especially in the eighth and ninth decade. Conversely, osteophytes were seen frequently in combination with obliteration of the joint space.

Computed tomography can demonstrate calcium deposition spreading from the attachment of one tubercle to the other [3]. These calcifications have been described in hydroxyapatite (HA) and most frequently in calcium pyrophosphate dihydrate deposition disease (CPPD) [1,2]. Whether or not degenerative change at the anterior aspect of the odontoid plays a role in transverse ligament calcification formation is uncertain. Because transverse ligament calcification was frequently associated with other morphologic abnormalities at the AO joint, our observations support the concept that these calcifications are related to the degenerative process [13]

Accumulation of gas within the AO joint has, to our knowledge, not been described in the literature. A "vacuum phenomenon" within other cervical or lumbar apophyseal joints has generally been equated with the presence of degenerative disease [11,14]. In this study 10 patients revealed a vacuum phenomenon, all in association with other degenerative characteristics within the joint. Thus, the vacuum phenomenon within the AO joint may be an additional sign, which indicates the presence of AO osteoarthritis

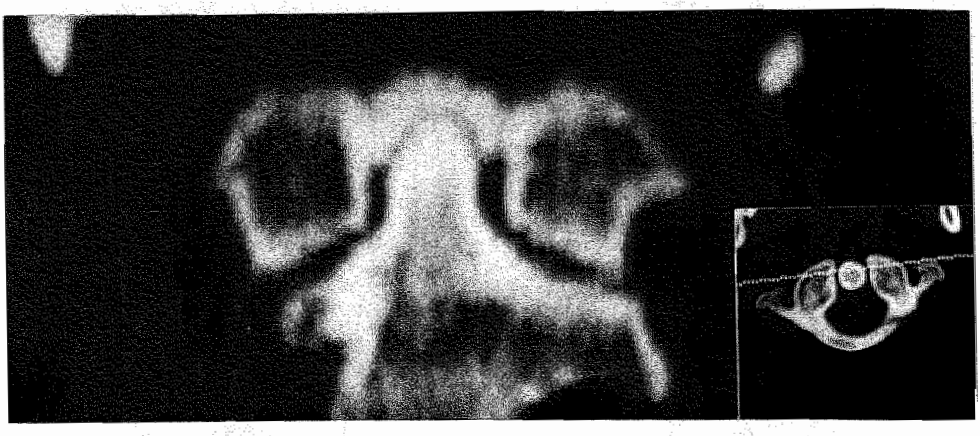

Figure 8. *Coronal CT reconstruction; Calcifications around the odontoid process, indicating excrescences mainly from the median facet of the atlas.*

Inflammatory masses (pseudotumors) can occasionally occur at the craniovertebral junction [16]. In our series of 500 CT scans we did not encounter any inflammatory mass. This gives some idea of the rarity of pseudotumors encountered at the cranio-vertebral junction on CT.

A difficult problem lies in establishing the relationship of clinical symptoms to the observed morphological changes. Until the present, the clinical significance of AO osteoarthritis has not been elucidated with certainty. Several authors have suggested that the pathologic changes can cause suboccipital headache and stiff neck [1,6,7,9,11,12,15]. On the other hand, suboccipital neuralgia has been ascribed frequently to unilateral degenerative disease of the C1-C2 lateral articulation [4,10]. Lateral C1-C2 osteoarthritis and AO osteoarthritis occur together frequently since both articulations work in common [9]. Thus, degenerative changes at both articulations can produce symptoms in the suboccipital region.

In a previous study we evaluated various pain syndromes in patients with crowned odontoids. Our findings support the suggestion that suboccipital headache is a common symptom in patients with signs of AO osteoarthritis [17]. Although it remains difficult to decide whether these complaints are produced by the morphologic changes at the AO joint alone. Therefore, AO osteoarthritis must be viewed as one of the differential diagnoses of suboccipital headache. Hence, awareness of the appearance and prevalence of degenerative changes in the AO joint on CT is important.

There is no apparent specific therapy for AO osteoarthritis. CT will at least enable accurate assessement of this condition and may be useful in patient selection for physical therapy and possibly aid in developing a relevant therapy.

2.6 References

1 Bouvet J-P, Parc le J-M, Michalski B, Benlahrache C, Auquier L. Acute neck pain due to calcifications surrounding the odontoid process: The crowned dens syndrome. *Arthritis and Rheumatism* 1985; 28: 1417-20.

2 Dirheimer Y, Bensimon C, Christmann D, Wackenheim C. Syndesmo-odontoid joint and calcium pyrophosphate dihydrate deposition disease (CPPD). *Neuroradiology* 1983; 25: 319-21.

3 Dirheimer Y, Wackenheim C, Dietemann JL. Calcification of the transverse ligament in calcium dihydrate deposition disease (CPPD). *Neuroradiology* 1985; 27: 87

4 Ehni G, Benner B. Occipital neuralgia and the C1-2 arthrosis syndrome. *J Neurosurg* 1984; 61: 961-5.

5 Fischer E, Schmidt H. Die degenerativen Veranderungen des vorderen Atlantodentalen Gelenks. *Fortschr Rontgenstr 1969*; 111: 552-8.

6 Fournier AM, Rathelot J. L'arthrose atlanto-odontoidienne: sa frequence comme d'algies nucales. *J Radiol Electrol 1959;* 40: 812-3.

7 Genez BM. Atlantoodontoid osteoarthritis. *Critical Reviews in Diagnostic Imaging* 1991; 32: 301-21.

8 Genez BM, Willis JJ, Lowrey CE et al. CT findings of degenerative arthritis of the atlantoodontoid joint. *AJR* 1990; 154: 315-8.

9 Harata S, Tohno S, Kawagishi T. Osteoarthritis of the atlanto-axial joint. *Internat Orthopaedics* 1981; 5: 277-82.

10 Joseph B, Kumar B. Gallie's fusion for atlantoaxial arthrosis with occipital neuralgia. *Spine* 1994; 19: 454-5.

11 Lefkowitz DM, Quencer RM. Vacuum facet phenomenon: A computed tomographic sign of degenerative spondylolisthesis. *Radiology* 1982; 144: 562.

12 Olsson O. Arthrosis deformans des vorderen Zahngelenkes. *Fortschr Rontgenstr* 1942; 66: 233-9.

13 Resnick D, Pineda C. Vertebral involvement in calcium pyrophosphate dihydrate crystal deposition disease. *Radiology* 1984; 153: 55-60.

14 Resnick D, Niwayama G, Guerra J, Vint V, Usselman J. Spinal vacuum phenomena: Anatomical study and review. *Radiology* 1981; 139: 341-8.

15 Skaane P, Klott KJ. Die peridentale Aureole bei der vorderen Atlanto-dental Arthrose. *Fortschr Rongenstr* 1981; 134: 62-8.

16 Sze G, Brant-Zawadski MN, Wilson ChR, Norman D, Newton TH. Pseudo-tumor of the craniovertebral junction associated with chronic subluxation: MR imaging studies. *Radiology* 1986; 161:391-4.

17 Zapletal J, Hekster REM, Straver JS. Osteoarthritis of the atlantoodontoid joint; Paper presented at the scientific assembly of the NVvR. *Ned Tijdschr Geneeskd* 1993; 137: 2116-7.

CHAPTER 3

RELATIONSHIP BETWEEN ATLANTO-ODONTOID OSTEOARTHRITIS AND IDIOPATHIC SUBOCCIPITAL NECK PAIN

J Zapletal[1], REM Hekster[1], JS Straver[2], JT Wilmink[3], J Hermans[4]

1 Department of Radiology, Leyenburg Hospital, The Hague
2 Department of Neurology, Leyenburg Hospital, The Hague
3 Department of Neuroradiology, University Hospital Maastricht
4 Department of Medical Statistics, University of Leiden

Accepted for publication in:
Neuroradiology

3.1 Abstract

In the present paper the relationship of atlanto-odontoid (AO) osteoarthritis to suboccipital pain is discussed. A questionnaire regarding suboccipital neck pain was presented to a group of 210 consecutive patients undergoing computed tomography (CT) of the brain or sinuses for a variety of indications. In all patients the AO joint and the lateral scout image of the cervical spine was studied. In 104 patients (49%) degenerative changes at the AO joint were seen. 89 patients (42%) reported experiencing pain in the suboccipital region although these symptoms were not the reason for CT in any patient. Statistical analysis of the prevalence of suboccipital neck pain in all patients showed that presence of AO osteoarthritis seen at CT is related to the occurrence of these symptoms. This association remained significant in the same study population after excluding patients with a history of rheumatoid arthritis, migrane, stress, neck trauma or patients with signs of degenerative changes of C2-C7 on the computed lateral scout image.

3.2 Introduction

Chronic neck pain is a frequent symptom in the general population [1]. It is w recognized that disorders of the upper cervical spine can be a source of suboccipital ne pain. These disorders frequently include congenital abnormalities, trauma, neoplasms a arthropathies [2,3,4]. Regarding arthropathies, rheumatoid arthritis of the C1-C2 joint receiving increased attention as a potential cause of pain in the suboccipital region [5,6].

Degenerative arthropathy (osteoarthritis) in the upper cervical spine at the late C1-C2 joint has also been described as a potential pain-generating process causing refer pain radiating into the suboccipital region [7,8]. However, the clinical implication of oste arthritis (OA) at the functionally important atlanto-odontoid (AO) joint, which is mu more common than osteoarthritis at other cervical joints and which can be clearly visua zed on CT [9,10], has received little attention in the literature [11,12,13]. In this study, evaluated the AO joint by computed tomography (CT) in an unselected group of patie to establish possible relationship between AO osteoarthritis and suboccipital pain.

3.3 Materials and methods

The study population consisted out of 210 outpatients (108 men and 102 wom age between 17 and 91 years, mean 57 years) seen consecutively over a 6-month peri All patients were referred for computed tomography (CT) of the brain or sinuses exclude cranial abnormalities. No patient was referred as a part of an investigation of generalized arthropathy or due to pain in the suboccipital region. In all patients the asp of the AO joint and cervical spine on the lateral scout image routinely performed from up to the vertex to indicate levels for study and to assist in gantry angulation, was evalu ted. CT was performed on a Siemens Somatom plus-S scanner with 5-mm contiguo slices.

Clinical evaluation. Each patient was asked to complete a questionnaire which includ queries on age and sex, and on; 1) whether patients experienced pain in the suboccipi region, 2) whether patients had a history of rheumatoid arthritis and, 3) whether rece neck trauma, 4) stress or 5) migraine was present and has led to symptoms in the subo cipital region.

Radiologic evaluation. CT of the AO joint and the lateral scout image of the cervical spine of each patient was studied by two radiologists without knowledge of the clinical data. Agreement was reached by consensus. Presence of AO osteoarthritis was rated on a three point scale: Grade 0: normal, Grade 1: moderate degenerative changes, Grade 2: severe degenerative changes. Grade 0 referred to a normal AO joint space. Grade 1 referred to narrowing of the AO joint space and bony hypertrophy around the fovea dentis. Grade 2 referred to obliteration of the AO joint space as well as sclerosis and osteophytes arising from the fovea dentis. In each patient, the lateral scout image of the cervical spine, which can reveal degenerative abnormalities of the spine [14], was examined for presence of possible pain-generating processes other than a degenerative process at the AO joint (Fig. 1). On the lateral scout image presence of 1) cervical disk space narrowing, 2) spondylosis, 3) intervertebral arthrosis, or osseous abnormality (anomaly or tumour) was noted.

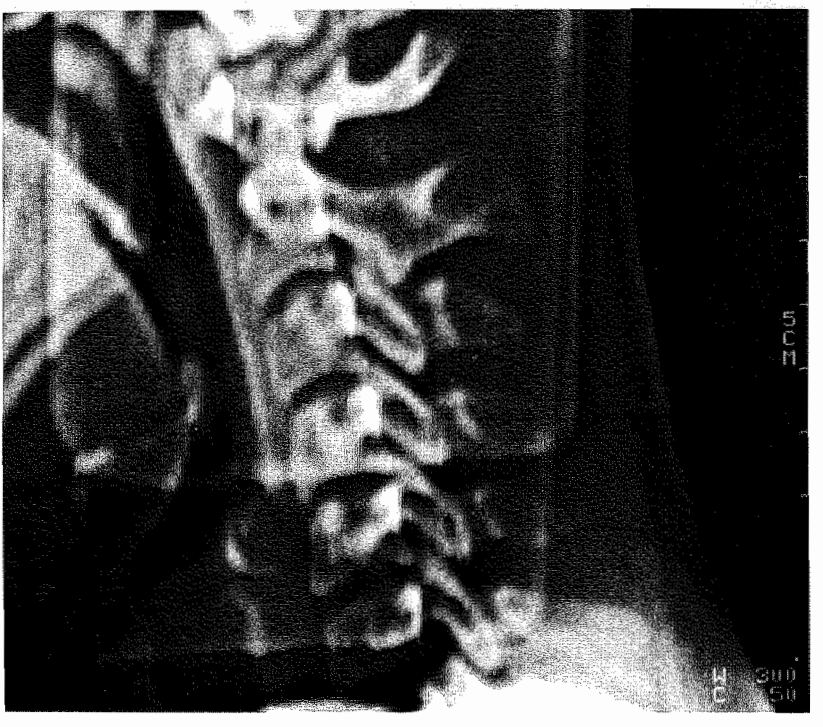

Figure 1. *Lateral topogram shows absence of degenerative changes such as spondylosis, disc space narrowing and intervertebral osteoarthritis.*

All radiologic findings and data collected from the request forms were evaluated at first for all patients. A second analysis was done after exclusion of all patients with a history of rheumatoid arthritis, neck trauma, stress or migraine, and patients with an anomaly, disc space narrowing or signs of degenerative change of the cervical spine other than AO osteoarthrosis detected on the lateral scout image (**exclusion criteria**). The occurrence of neck pain in the suboccipital region was related to the grade of AO osteoarthritis, first for all patients, second after excluding patients according to exclusion criteria. A possible relationship of age was investigated, chi-square tests were used for statistical analysis.

Table 1

Relationship between AO osteoarthritis and suboccipital neck pain in all patients. (N= 210)

Grade of degenerative change	Suboccipital neck pain		Total
	Absent	**Present**	
0	80	26 (25%)	106
1	22	30 (58%)	52
2	19	33 (63%)	52
Total	121	89 (42%)	210

P< 0.001

Relationship of degenerative abnormalities at the AO joint to suboccipital pain is shown in table 1. No patient had signs of an anomaly or tumour at the craniovertebral junction visible on CT or lateral scout image.

The overall prevalence of suboccipital pain was 42% (43 men, 46 women). The prevalence of these symptoms was significantly related to the grade of osteoarthritis (P< 0.001), with a marked increase from grade 0 to grade 1. No degenerative changes were found before the fourth decade. For middle-aged patients (40-60 years) and older patients (> 60 years) a similar relation between degenerative changes at the AO joint and suboccipital neck pain was found (see table 2).

The association between symptoms and degenerative changes at the AO joint was also similary highly significant in the second study group after application of the exclusion criteria, see table 3.

Table 2

Relationship between degenerative changes at the AO joint and suboccipital neck pain by age

		Suboccipital neck pain			
Age (years)	Grade Deg. Change	**Absent**	**Present**	Total	
< 40	**0**	30	14 (32%)	44	
	1	0	0	0	
	2	0	0	0	
40-60	**0**	13	6 (32%)	19	
	1	3	11 (79%)	14	P< 0.001
	2	0	8 (100%)	8	
> 60	**0**	27	6 (18%)	33	
	1	19	19 (50%)	38	P=0.002
	2	19	25 (57%)	44	

Table 3

Relationship between AO osteoarthritis and suboccipital neck pain after exclusion of patients according to exclusion criteria. (N=86)

Grade of degenerative change	Suboccipital neck pain		Total
	Absent	**Present**	
0	48	3 (6%)	51
1	6	14 (70%)	20
2	3	12 (80%)	15
	57	29 (34%)	86

P< 0.001

3.5 Discussion

As early as 1935 Shore suggested that osteoarthritis at the AO joint might have a clinical interest [12]. In the following years, some authors have mentioned the occurence of degenerative abnormalities at the AO joint [10,11,13,15]. Nevertheless, to date no reports of correlation between degenerative abnormalities at this functionally important joint, possessing great rotatory mobility, and pain in the suboccipital region have appeared.

In previous studies we reported the CT appearance and the high prevalence of various degenerative signs at the AO joint in the elderly [9,16]. In this study, we tried to elucidate the relationship of the frequently encountered degenerative abnormalities at the AO joint to referred chronic pain in the suboccipital region.

The results show that many patients (42%), referred for examination for a variety of other indications, experience pain in the suboccipital region. Statistical analysis in all patients examined show that presence of AO osteoarthritis carries a predisposition to these symptoms in the suboccipital region.

Since rheumatoid arthritis, migraine, trauma, cervical spine anomalies, spondylarthrosis or cervical spine disk disease can also be at the origin of pain in the occipitocervical region, it was necessary to consider those with and without these abnormalities in studying symptoms [2,3]. After application of exclusion criteria in order to reduce the possibility of other suboccipital pain-generating processes, results showed also for this restricted group of patients, that presence of degenerative changes is associated (highly significant) with chronic pain in the suboccipital region.

On the whole, AO osteoarthritis must be considered only as a predisposing factor rather than a definite cause of referred pain in the suboccipital region since several patients with moderate or severe AO osteoarthritis had no symptoms in this region. Furthermore a coexistence of lateral C1-C2 osteoarthritis as an additional pain generating factor could not be seen on lateral topograms and therefore not be excluded. However, previous pathological examinations indicate that the prevalence of lateral C1-C2 osteoarthritis is much lower than that of AO osteoarthritis [11,12]. We conclude that AO osteoarthritis, which is underreported on routine cervical spine radiographs due to overprojection of the joint by skull base structures, is frequently present in the elderly, and in most cases associated with suboccipital pain. Particular attention should therefore be given to this joint in elderly patients with idiopathic pain in the suboccipital region.

3.6 References

1. Bovim G, Schrader H, Sand T (1994) Neck pain in the general population. *Spine* 19: 1307-1309

2. Edmeads J (1978) Headaches and head pains associated with diseases of the cervical spine. *Medical Clinics of North America* 62: 533-544

3. Edmeads J (1988) The cervical spine and headache. *Neurology* 38: 1874-1878

4. Smoker WRK (1994) Craniovertebral junction: Normal anatomy, craniometry, and congenital anomalies. *Radiographics* 14: 255-277

5. Bland JH (1974) Rheumatoid arthritis of the cervical spine. *J Rheumatol* 1: 319-342

6. Morizono Y, Sakou T, Kawaida H (1987) Upper cervical involvement in rheumatoid arthritis. *Spine* 12: 721-725

7. Halla JT, Hardin JG (1987) Atlantoaxial (C1-C2) facet joint osteoarthritis: A distinctive clinical syndrome. *Arthritis and Rheumatism* 30: 577-582

8. Star MJ, Curd JG, Thorne RP (1992) atlantoaxial lateral mass osteoarthritis. A frequently overlooked cause of severe occipitocervical pain. *Spine* 17: 71-76

9. Zapletal J, Hekster REM, Straver JS, Wilmink JT (1995) Atlanto-odontoid osteoarthritis: appearance and prevalence on CT. *Spine* 20: 49-53

10. Genez BM , Willis JJ, Lowrey CE et al (1990) CT findings of degenerative arthritis of the atlantoodontoid joint. *AJR* 154: 315-318

11. Sager P (1969) Spondylosis cervicalis. A pathological and osteoarcheologic study of osteochondrosis intervertebralis cervicalis, arthrosis uncovertebralis and spondylarthrosis cervicalis, Munskgaard, Copenhagen 101-102

12. Shore LR (1935) On osteo-arthritis in the dorsal intervertebral joints. A study in morbid anatomy. *Br J Surg* 22: 833-849

13. Harata S, Tohno S, Kawagishi T (1981) Osteoarthritis of the atlanto-axial joint. *Int Orth* 5: 277-282

14. Sener RN, Ripeckyj GT, Otto PM, Rauch RA, Jinkins JR (1993) Recognition of Abnormalities on computed scout images in CT examination of the head and spine. *Neuroradiology* 35: 229-231

15. Olsson O (1942) Arthrosis deformans des vorderen Zahngelenks. *Fortschr Rontgenstr* 66: 233- 239

16. Zapletal J, Hekster REM, Straver JS, Wilmink JT, Hermans (1995) Association of transverse ligament calcification with atlanto-odontoid osteoarthritis. *Neuroradiology* in press

CHAPTER 4

ATLANTO-ODONTOID OSTEOARTHRITIS: COMPARISON OF LATERAL CERVICAL PROJECTION AND CT

J Zapletal[1], REM Hekster[1], JT Wilmink[2], J Hermans[3], J Schipper[1], WMC Mallens[1]

1 Department of Radiology, Leyenburg Hospital, The Hague
2 Department of Neuroradiology, University Hospital Maastricht
3 Department of Medical Statistics, University of Leiden

Accepted for publication in:
European Spine Journal

4.1 Abstract

The purpose of this study was to assess the accuracy of lateral cervical spine radiography in the detection of degenerative atlanto-odontoid (AO) osteoarthritis, with CT as gold standard. In 50 patients, lateral radiographs and CT of the AO joint were blindly and independently graded by two radiologists: 0= normal, 1= mild degenerative disease, 2= severe degenerative disease. Radiography was most accurate in distinguishing absent or mild from severe disease (83% sensitivity, 84% specificity). Sensitivity in distinguishing absent disease from mild or severe disease was 87%. Specificity however, was low (52%) due to overestimation of the degenerative involvement on radiography. It is concluded that conventional radiography is a useful technique in screening for AO osteoarthritis, especially in severely degenerated joints. However, CT provides the best radiographic detail necessary for accurate diagnosis.

4.2 Introduction

Since the early 1940s, several authors have suggested a possible correlation between high cervical/suboccipital headache with motion disturbance, and atlanto-odontoid (AO) osteoarthritis [1-4,10,12]. Patients with symptoms referrable to the upper cervical spine or suboccipital area are routinely first examined by conventional radiography. The greatest value of this diagnostic modality lies in providing a rapid and inexpensive screening. Only the lateral projection can provide adequate information about the anatomical relationships at the AO joint because of obscuration of this joint by overlying osseous structures on the frontal view, and inadequate visualisation on the oblique views. Degenerative abnormalities that can be seen on a lateral radiograph include narrowing or obliteration of the space between the anterior arch of the atlas and the odontoid process, cortical thickening, and osteophytosis [8].

To our knowledge, an evaluation of the accuracy of lateral cervical radiographs in the detection of AO osteoarthritis has not been reported in the literature. Prompted by the frequent and clear demonstration of degenerative changes at the AO joint in patients who underwent computed tomography (CT) of the craniovertebral junction, we undertook a prospective study to evaluate the sensitivity and specificity of lateral cervical spine radiographs in the assessment of degenerative AO osteoarthritis. We used CT as the quality standard.

4.3 Materials and Methods

The study population included 50 patients (29 women and 21 men, aged 21-86 years) referred for a CT scan of the brain, paranasal sinuses, craniovertebral junction or cervical spine between September 1993 and January 1994. Patients were included in the study if a lateral cervical spine radiograph had been performed in the 1 year preceding the CT examination. In all patients, at least two CT slices through the anterior C1-C2 joint were performed. All CT examinations were performed by means of standard techniques (420 mAs, 120 kVp; Somatom plus-S, Siemens, Erlangen, Germany) with 5-mm parallel sections. The AO joint was photographed at both soft-tissue and bone window settings in each patient. All CT slices and lateral radiographs of the cervical spine were blindly and independently interpreted by two experienced radiologists (W.M.C.M. and J.S.). The names and ages of the patients were masked. The degree of abnormality was scored on a three point scale; 0= normal, 1= mild degenerative disease, 2= severe degenerative disease. "Normal" referred to a normal AO joint space. "Mild degenerative disease" referred to narrowing of the joint space and some hypertrophy of the superior, inferior and lateral articular surface of the joint.

"Severe degenerative disease" referred to obliteration of the joint space, sclerosis and marked osteophytes arising from the lateral, superior and inferior surface of the anterior arch of the atlas (Figures 1 and 2) . For both imaging methods, kappa values for interobserver agreement and for agreement between the two methods scored by each observer were calculated. Additionally, sensitivity, specificity, positive predictive value and negative predictive value for each group (normal vs mild or severe, and normal or mild vs severe) were determined with CT as gold standard.

4.4 Results

All CT scans and lateral radiographs demonstrated the AO joint sufficiently well to permit scoring. On CT, the two observers showed agreement in 44 of 50 AO joints (88%). There was a disagreement within one grade in the remaining 6 patients (12%). The kappa value was 0.80, indicating good interobserver agreement. Regarding the lateral radiographs of the cervical spine, there was complete interobserver agreement in the scores of 32 of 50 AO joints (64%). There was disagreement within one grade in the remaining 18 patients (36%). The kappa value on lateral radiographs was 0.46, indicating moderate interobserver agreement (Table 1).

Both observers evaluated 50 AO joints on CT images and lateral radiographs. The first observer (A) achieved perfect agreement in 31 cases (67%); in 14 cases there was discrepancy of one grade and in 5 cases discrepancy of two grades. The radiographic score was higher than CT 14 times and 5 times the opposite occurred. The kappa coefficient of agreement between the two methods was 0.42. The second observer (B) achieved perfect agreement in 28 cases (56%); with one grade discrepancy in 20 cases and in two grades discrepancy in 2 cases. The radiographic score was higher than CT 19 times and 3 times the opposite occurred. The kappa coefficient of agreement between the two methods for observer B was 0.34 (Table 2). Thus both observers showed moderate agreement between the two methods.

Table 3 summarises the radiographic interpretations of both observers in distinguishing degrees of degenerative involvement (normal vs mild or severe, and normal or mild vs severe) at the AO joint, using CT as gold standard. Sensitivity in distinguishing normal vs mild or severe, and normal or mild vs severe as well as specificity in the latter group, was high. On the other hand, specificity in distinguishing normal vs mild or severe was relatively low.

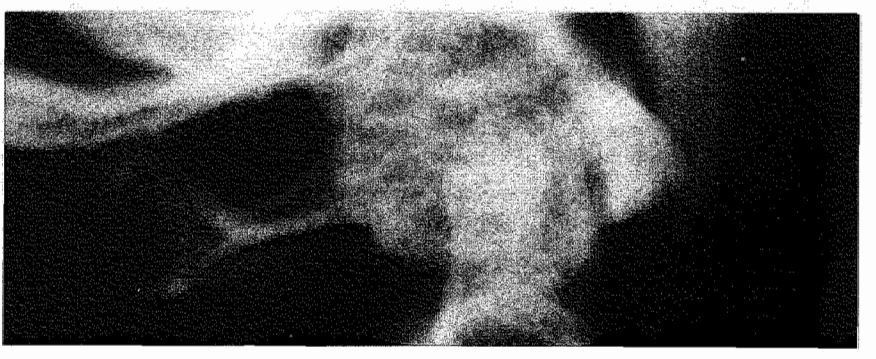

Grade 0

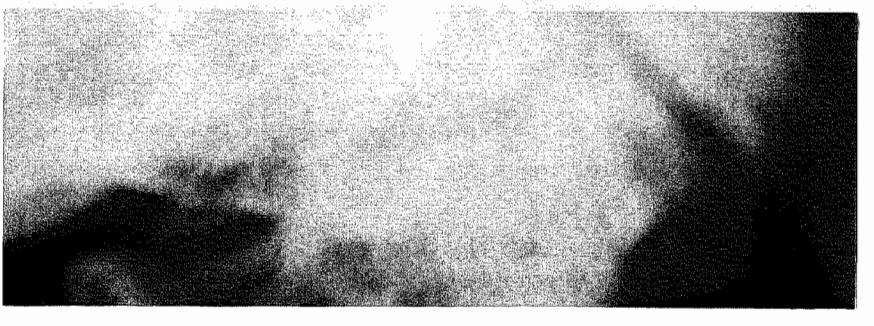

Grade 1

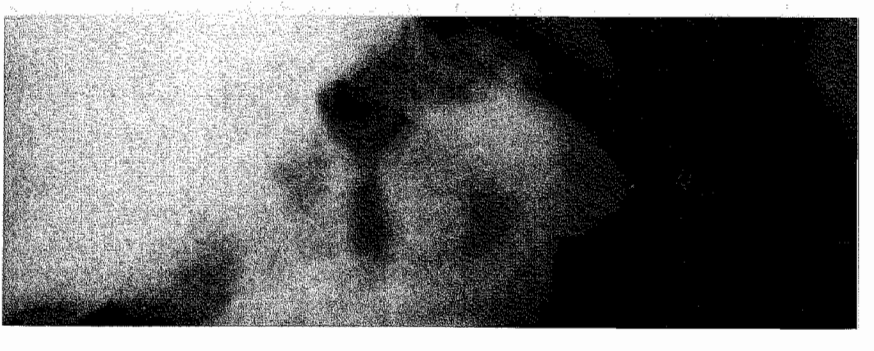

Grade 2

Figure 1

Grades (0,1,2) of Atlanto-odontoid osteoarthritis as seen on lateral radiographs of the cervical spine

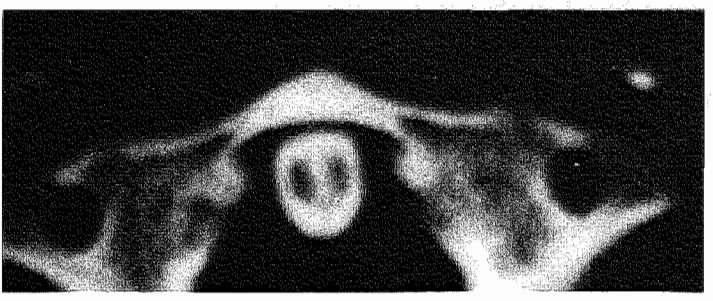

Grade 0



Grade 1

Grade 2

Figure 2

Grades (0,1,2) of Atlanto-odontoid osteoarthritis as seen on Computed Tomography

Table 1

Interobserver agreement (Kappa) in the evaluation of degenerative involvement in AO osteoarthritis on lateral radiographs and CT

0= normal, **1**= mild degenerative disease, **2**= severe degenerative disease.

Lateral radiography

		Observer B			
		0	**1**	**2**	
Observer A	**0**	12	6	0	18
	1	4	10	4	18
	2	0	4	10	14
		16	20	14	50

Kappa = 0.46

CT

		Observer B			
		0	**1**	**2**	
Observer A	**0**	25	1	0	26
	1	3	11	0	14
	2	0	2	8	10
		28	14	8	50

Kappa = 0.80

Table 2

Agreement (Kappa) between lateral radiography and CT scored by observer A and observer B.

0= normal, **1**= mild degenerative disease, **2**= severe degenerative disease

Observer A

		CT			
		0	**1**	**2**	
Lateral radiography	**0**	15	2	1	18
	1	7	9	2	18
	2	4	3	7	14
		26	14	10	50

Kappa = 0.42

Observer B

		CT			
		0	**1**	**2**	
Lateral radiography	**0**	13	3	0	16
	1	13	7	0	20
	2	2	4	8	14
		28	14	8	50

Kappa = 0.34

Table 3

Analysis of radiographic interpretations, in distinguishing degrees of degenerative involvement at the AO joint, using CT as gold standard

		sensitivity (%)	specificity (%)	pos.pred. value (%)	neg. pred. value (%)
normal vs mild or severe	Obs. A	21/24= 88	15/26= 58	21/32= 66	15/18= 83
	Obs. B	19/22= 86	13/28= 46	19/34= 56	13/16= 81
normal or mild vs severe	Obs. A	7/10= 70	33/40= 83	7/14= 50	33/36= 92
	Obs. B	8/8= 100	36/42= 85	8/14= 57	36/36= 100

4.5 Discussion

In 1942, Olsson [7] discussed the radiographic findings in degenerative arthritis of the AO joint and suggested that a decreased range of motion and high cervical neck pain could be due to AO osteoarthritis.

Sager [8] found that degenerative changes in the AO joint are more common than in the lateral atlanto-axial or apophyseal joints of the cervical spine, probably due to different patterns of stress and excursion. Additionally Fischer and Schmidt [2] noted that degenerative changes at the AO joint occur frequently in the elderly and can be predisposed to or accelerated by a variety of developmental and/or acquired factors.

Harata et al [6], in a study of 31 patients with AO osteoarthritis, found that degenerative abnormalities occur predominantly between the ages of 50 and 70 years without sex difference. He reported several patients with AO osteoarthritis complaining of suboccipital headache. He also found, on pathological examination of cadaver specimens, that AO osteoarthritis showed the same histologic changes found in osteoarthritis of the other joints.

In a previous study, we evaluated diverse pain syndromes and the coexistence of cervical spondylarthrosis in 40 patients with severe AO osteoarthritis [11]. Our findings showed that suboccipital or high cervical pain is a common symptom in patients with severe AO osteoarthritis. Furthermore, marked degenerative abnormalities at the AO joint occurred in the absence of other radiographic degenerative abnormalities of the cervical spine in 20% of patients.

CT is an excellent imaging modality for visualising the AO joint [5, 12]. Conventional radiography of the cervical spine has significant limitations in the evaluation of the AO joint. Overlying bony structures can make it impossible to identify anatomic abnormalities on frontal or oblique views. Transbuccal views are unrevealing of the AO joint space, but may show a horseshoelike calcification around the odontoid process in AO osteoarthritis, representing osteophyte formation on the superior and lateral border of the anterior arch of the atlas.

No previous study has assessed the accuracy of conventional radiography in the detection of AO osteoarthritis. In this study we used CT as the gold standard with which to investigate and compare the sensitivity and specificity of conventional lateral radiography of the cervical spine in depicting degenerative changes at the AO joint. Our findings indicate good interobserver agreement in the evaluation of degenerative AO disease on CT. In evaluating AO osteoarthritis on lateral radiographs, experienced radiologists achieved moderate interobserver agreement. No disparity greater than one grade was noted. On the other hand, both observers tended to overestimate the degree of degenerative involvement on lateral radiographs.

The study further indicates that lateral radiography of the cervical spine is useful for the detection of severe degenerative disease. On the other hand, the specificity of lateral radiography in distinguishing absent from mild or severe degenerative disease is relatively low owing to the tendency for overestimation of the disease; no abnormalities, as graded with CT criteria, was sometimes graded as mild on the basis of conventional radiographs.

In conclusion, lateral radiography of the cervical spine in patients with pain related to the suboccipital area is a rapid, inexpensive and valuable modality in screening for degenerative disease, especially severe degenerative changes at the AO joint. However, CT is best for assesssment of this condition.

4.6 References

1. Bouvet JP, Parc le JM, Michalski B, Benlarache C, Auquier L (1985) Acute neck pain due to calcifications surrounding the odontoid process: The crowned dens syndrome. *Arthritis and Rheumatism* 28: 1417-1420

2. Fischer E, Schmidt H (1969) Die degenerativen veranderungen des vorderen atlantodentalen Gelenks. *Fortschr Rontgenstr* 111: 552-558

3. Fournier AM, Rathelot J (1959) L'arthrose atlanto-odontoidienne: sa frequence comme d'algies nucales. *J Radiol Electrol* 40: 812-813

4. Genez BM (1991) Atlantoodontoid osteoarthritis. *Critical Reviews in Diagnostic Imaging* 32: 301-321

5. Genez BM, Willis JJ, Lowrey CE, Lauerman WC, Woodruff W, Diaz MJ, Higgs JB (1990) CT findings of degenerative arthritis of the atlantoodontoid joint. *AJR* 154: 315-318

6. Harata S, Tohno S, Kawagishi T (1981) Osteoarthritis of the atlanto-axial joint. *Int Orth* 5: 277-282

7. Olsson O (1942) Arthrosis deformans des vorderen Zahngelenkes. *Fortschr Rontgenstr* 66: 233-239

8. Resnick D (1985) Degenerative diseases of the vertebral Column. *Radiology* 156: 3-14

9. Sager P (1969) Spondylosis cervicalis. A pathological and osteoarchaeologic study of osteochondrosis intervertebralis cervicalis, arthrosis uncovertebralis and spondylarthrosis cervicalis. Munskgaard, Copenhagen, pp 101-102

10. Skaane P, Klott KJ (1981) Die peridentale Aureole bei der vorderen Atlanto-dental-arthrose. *Fortschr Rontgenstr* 134: 62-68

11. Zapletal J, Hekster REM, Straver JS (1993) Osteoarthritis of the atlantoodontoid joint. *Ned Tijdschr Geneeskd* 137: 2116-2117

12. Zapletal J, Hekster REM, Straver JS, Wilmink JT (1995) Atlantoodontoid osteo-arthritis: appearance and prevalence at CT. *Spine* 20: 49-53

CHAPTER 5

MR IMAGING OF SEVERE ATLANTO-ODONTOID OSTEOARTHRITIS

J Zapletal[1], REM Hekster[1], FEE Treurniet[1], JT Wilmink[2]

1 Department of Radiology, Leyenburg Hospital, The Hague
2 Department of Neuroradiology, University Hospital Maastricht

Submitted for publication

5.1 Abstract

We present the magnetic resonance (MR) appearance of severe degenerative changes at the atlanto-odontoid (AO) joint. Degenerative changes such as obliteration of the AO joint space, subchondral sclerosis and osteophytosis were clearly depicted on T1-weighted MR images with fast gradient echo pulse sequences. Recognition of these advanced degenerative changes on MR can be helpful in the differential diagnosis in patients with suboccipital neck pain.

5.2 Introduction

The atlanto-odontoid (AO) joint is a synovial joint located between the anterior arch of C1 and the odontoid process of C2. Degenerative arthrosis (osteoarthritis) at this functionally important joint occurs mainly in the elderly [1]. The degenerative changes at the AO joint are similar to those commonly observed in other synovial joints and include narrowing of the joint space, subchondral sclerosis and osteophyte formation [2].

The appearance of AO osteoarthritis on Computed tomography (CT), conventional-tomography or plain radiography and relation between AO osteoarthritis and suboccipital neck pain have been documented in previous reports [2-6]. However, to our knowledge, the MR appearance of AO osteoarthritis has not yet been described. We report the MR appearance of severe degenerative changes at the AO joint on T1-weighted (gradient-echo) images and correlate findings on MR to those found on lateral radiographs of the cervical spine.

5.3 Materials and Methods

The study group consisted of 6 patients, three men and three women between the ages of 58 and 82 years (mean, 72 years), without history of rheumatoid disease, in whom MR of the cervical spine including the craniocervical junction and lateral radiographs of the cervical spine had been performed within one year of each other. All patients had signs of severe degenerative changes at the AO joint on previous radiographs. They were referred for MR to exclude abnormalities of the intervertebral discs or spinal cord. MR imaging was performed using a 0.5 T Philips T5-II unit and a quadrature neck coil. During MR imaging of the cervical spine, images of the AO joint were obtained in the axial, sagittal and coronal planes using a gradient-echo multislice sequence with the following parameters: 30/13 (TR/TE), 30^0 flip angle, 18 cm FOV, 3-mm section thickness, 1.5-mm interslice gap, 205×256 matrix.

In all patients sagittal T1-weighted (gradient-echo) images were correlated with lateral radiographs of the cervical spine. AO joint abnormalities seen on lateral radiographs were divided in 1) osteophytes arising at the apex of the AO joint, 2) obliteration of the AO joint space and 3) subchondral sclerosis of the anterior arch and ventral aspect of the odontoid process.

5.4 Normal Anatomy

On sagittal and axial T1-weighted images, normal articular cartilage between the anterior arch of the atlas and the odontoid process is seen as a thin zone of moderate signal intensity [7]. Normal adjacent subchondral cortical bone at the AO joint can be identified as a well delineated low intensity rim at the posterior aspect of the anterior arch and ventral aspect of the odontoid process (Fig.1).

Figure 1. *Mid-sagittal T1-weighted image (30/13 TR/TE) of the craniocervical junction. A normal moderate signal between the anterior arch of C1 and the odontoid process due to a normal cartilage and low signal intensity normal adjecent subchondral bone at the anterior arch and odontoid process can be identified.*

5.5 Results

Osteophytes arising from the apex of the AO joint seen on lateral radiographs of the cervical spine were identified as low intensity spurs extending from the upper aspect of the anterior arch of C1 and apex of the odontoid process. AO joint space obliteration seen on radiographs was associated with disappearance of signal between the articular facets of the fovea dentis and odontoid process. Subchondral sclerosis was noted as increased thickness of the low-intensity subchondral cortical bone of the anterior arch and odontoid process (Fig. 2). All these degenerative findings were also visualised on axial images of the AO joint (Fig. 3). In addition coronal images showed crownlike excrescences as a low signal halo around the apex of the odontoid process representing osteophytes arising mainly from the upper and lateral aspect of the fovea dentis (Fig. 4). No inflammatory mass or pannus was detected in our patients.

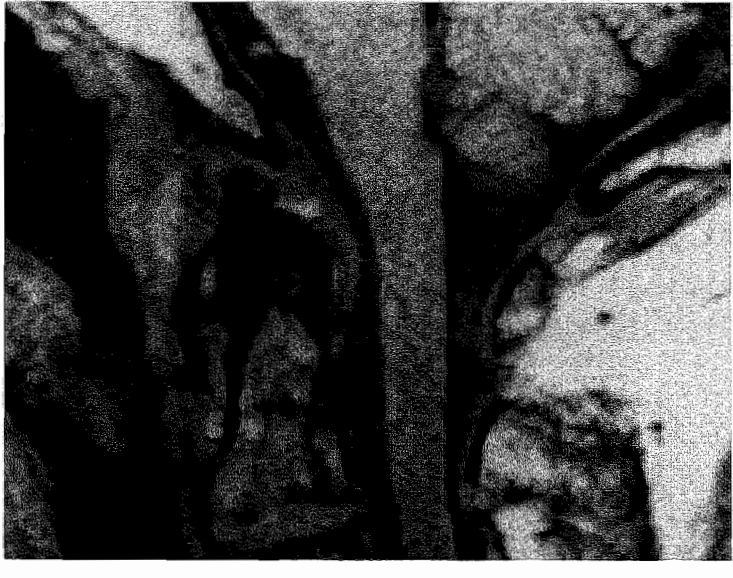

Figure 2. *Mid-sagittal T1-weighted image (30/13 TR/TE) of the cranio-cervical junction demonstrates signal loss within the atlantoodontoid joint space due to cartilage loss and joint narrowing. Furthermore, increased thickness of the low intensity subchondral cortical bone due to bone sclerosis and low intensity spurs arising at the apex of the anterior arch and odontoid process can be identified.*

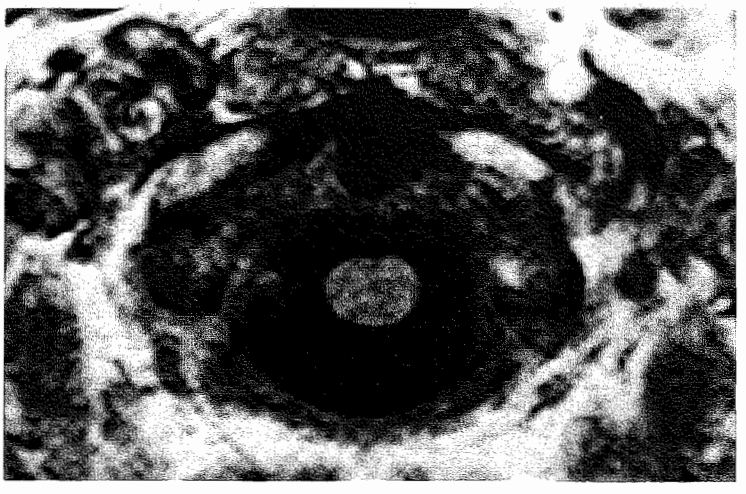

Figure 3. *Transverse T1-weighted MR image (30/13 TR/TE) shows obliteration of the atlanto-odontoid joint space, subchondral sclerosis and spurs extending from the lateral aspect of the fovea dentis.*

Figure 4. *Coronal T1-weighted MR image (30/13 TR/TE) demonstrates a low signal halo around the apex of the odontoid process representing the marked osteophytes arising at the apex and lateral aspect of the fovea dentis.*

5.6 Discussion

The craniovertebral junction, including the AO joint is seen in virtually every sagittal MR imaging study of the brain or cervical spine. Disorders that can affect this area are congenital abnormalities, trauma, neoplasms and arthropathies. These processes lead to abnormal mechanics that may cause pain and other disorders [8,9]. In this context, osteoarthritis at the AO joint has been recognized as a pathological state occasionally related to suboccipital neck pain [2-5].

To date, well penetrated lateral radiographs of the cervical spine, conventional tomography or CT have, been used in the evaluation of the degenerative process at the AO joint [4,10]. This report shows that MR imaging, in addition to these imaging techniques, can provide an excellent mean of delineating cartilage and bony changes in severe AO osteoarthritis. T1-weighted (gradient-echo) images were very suitable for identifying joint pathology; The sagittal and axial sections demonstrated loss of the articular cartilage as disappearance a zone of moderate signal between the anterior arch and odontoid process. Extensive subchondral or bony sclerosis was visualised as increased thickness of the low intensity subchondral bone in the dorsal aspect of the anterior arch of C1 and ventral aspect of the odontoid process. Osteophytes arising at the joint were seen as excrescences of low intensity at the apex on sagittal sections, lateral aspect of the fovea dentis on axial sections or as a low signal halo around the apex of the odontoid process on coronal sections.

Recognition of these abnormalities on MR can be helpful in the differential diagnosis in patients with suboccipital pain since our previous study suggests that these symptoms frequently occur in patients with this condition [11].

5.7 References

1. Fischer E, Schmidt. Die degenerativen veranderungen des vorderen Atlanto-dentalen Gelenks. *Fortschr Rontgenstr* 1969; 111: 552-558.

2. Shore LR. On osteo-arthritis in the dorsal intervertebral joints. A study in morbid anatomy. *Br J Surg* 1935; 22: 833-849.

3. Harata S, Tohno S, Kawagishi T. Osteoarthritis of the atlanto-axial joint. *Int Orth* 1981; 5: 277-282.

4. Genez BM, Willis JJ, Lowrey CE et al. CT findings of degenerative arthritis of the atlantoodontoid joint. *AJR* 1990; 154: 315-318.

5. Fournier AM, Rathelot J. L'arthrose atlanto-odontoidienne: sa frequence comme d'algies nucales. *J Radiol Electrl* 1959; 40: 812-813.

6. Zapletal J, Hekster REM, Straver JS, Wilmink JT. Atlantoodontoid osteoarthritis: Appearance and prevalence at computed tomography. *Spine* 1995; 20: 49-53

7. Schweitzer ME, Hodler J, Cervilla V, Resnick D. Craniovertebral junction: Normal anatomy with MR correlation. *AJR* 1992; 158: 1087-1090.

8. Lee BCP, Deck MDF, Kneeland JB, Cahill PT. MR imaging of the cranio-cervical junction. *AJNR* 1985; 6: 209-213.

9. Smoker WR. Craniovertebral junction: Normal anatomy, craniometry, and congenital anomalies. *Radiographics* 1994; 14: 255-277.

10. Skaane P, Klott K-J. Die peridentale Aureole (crowned odontoid process) bei der vorderen Atlantodentalarthrose. *Fortschr Rontgenstr* 1981; 134: 62-68.

11. Zapletal J, Hekster REM, Straver JS, Wilmink JT, Hermans J. Relationship between atlanto-odontoid osteoarthritis and idiopathic suboccipital neck pain. *Neuroradiology* in press.

CHAPTER 6

VACUUM PHENOMENON IN OSTEOARTHRITIS OF THE ATLANTO-ODONTOID JOINT: CT FINDINGS

J Zapletal[1], REM Hekster[1], JT Wilmink[2], J Hermans[3]

1 Department of Radiology, Leyenburg Hospital, The Hague
2 Department of Neuroradiology, University Hospital Maastricht
3 Department of Medical Statistics, University of Leiden

Published in:
Skeletal Radiology 1995 24: 131-133

6.1 Abstract

Out of 620 consecutive examinations of the atlanto-odontoid (AO) joint in patients referred for computed tomography (CT) of the brain or paranasal sinuses, gas collection within the AO joint was observed in 12 patients (1.9%). Degenerative abnormalities at the AO joint were significantly more frequent in patients with a gas-induced vacuum phenomenon than in an age matched control group. The CT findings and association of the vacuum phenomenon with osteoarthritis of the AO joint are discussed.

6.2 Introduction

An accumulation of gas in closed joint spaces is referred to as a "vacuum phenomenon". The phenomenon is observed in degenerated peripheral joints, and in normal joints under traction [1]. It is produced by lack of fluid within the articular cavity and negative pressure within the joint, attracting gas from surrounding extracellular spaces [2]. In the spine, this phenomenon, generally equated with the presence of degenerative disease, is well known within the facet joints of the lumbar spine [3]. In the atlanto-odontoid joint, however, the vacuum phenomenon has to the best of our knowledge not been reported previously. The observation of this phenomenon within the atlanto-odontoid joint has led us to determine the frequency of its occurrence in patients referred for computed tomography (CT) of the brain or paranasal sinuses at our institution. In addition, we investigated whether the vacuum phenomenon was associated with degenerative changes at the atlanto-odontoid joint.

6.3 Materials and Methods

During a period of 6 months (July to December 1993) 620 patients (297 males and 323 females) aged 20 to 93 years (mean 65 years) underwent CT examination of the brain or paranasal sinuses for suspected brain or sinus abnormalities. A digital image and gantry angulation was used to obtain scans through the anterior C1-C2 joint. Routine 5mm CT scans (420 mAs, 120 kV) were obtained using a Somatom plus-S (Siemens) unit. In all 620 cases the CT images were reviewed and gas accumulation within the atlanto-odontoid joint and degenerative abnormalities such as obliteration of the joint space, osteophytes arising from the facet of the atlas and transverse ligament calcifications were recorded.

6.4 Results

Of 620 patients studied, gas collection within the atlanto-odontoid joint was present in 12 patients (1,9%) aged 46 - 77 years (mean 63 years),- 7 males and 5 females (Fig. 1). The incidence of the gas induced vacuum phenomenon increased only slightly with age (Table 1). In some patients a vacuum phenomenon was present on only one side of the midline within the articular cavity (Fig. 2). In all 12 patients degenerative abnormalities were seen at the AO joint: 11 out of 12 patients (92%) had osteophytes arising from the fovea dentis of the atlas (Fig. 3), in 7 patients (58%) an obliteration of the joint space was present, and in 3 patients (25%) transverse ligament calcifications were seen (Table 2). All these features were significantly more common in patients with the vacuum phenomenon than in the age-matched control group (Table 3). The same conclusion is reached in respect of the whole cohort, without restriction to age-matched controls.

Table 1. *Incidence of vacuum phenomenon in relation to age*

Age (years)	no. of patients	Vacuum phenomenon yes	no
40-50	94	2 (2.1%)	92 (97.9%)
50-60	94	2 (2.1%)	92 (97.9%)
60-70	118	3 (2.5%)	115 (97.5%)
70-80	172	5 (2.9%)	167 (97.1%)
Total	478	12 (2.5%)	466 (97.5%)

Figure 1. *Accumulation of gas within the upper part of the atlanto-odontoid joint (arrow).*

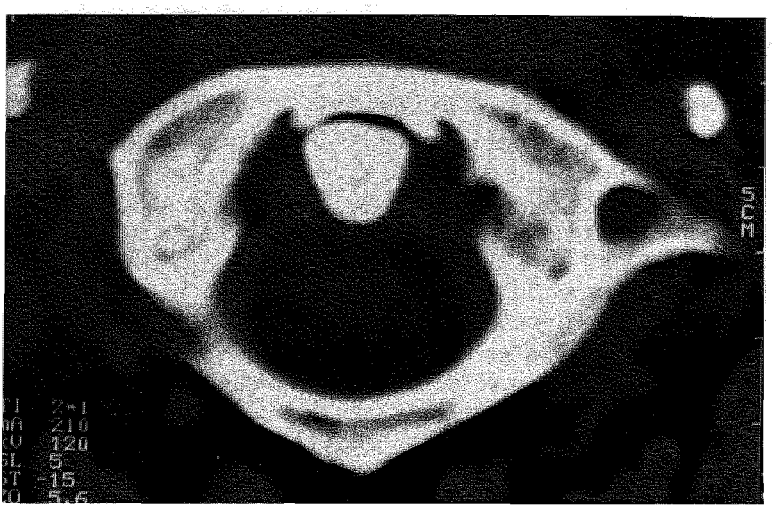

Figure 2. *Axial CT demonstrates only a small accumulation of gas on one side of the midline together with osteophytes arising from the fovea dentis of the atlas.*

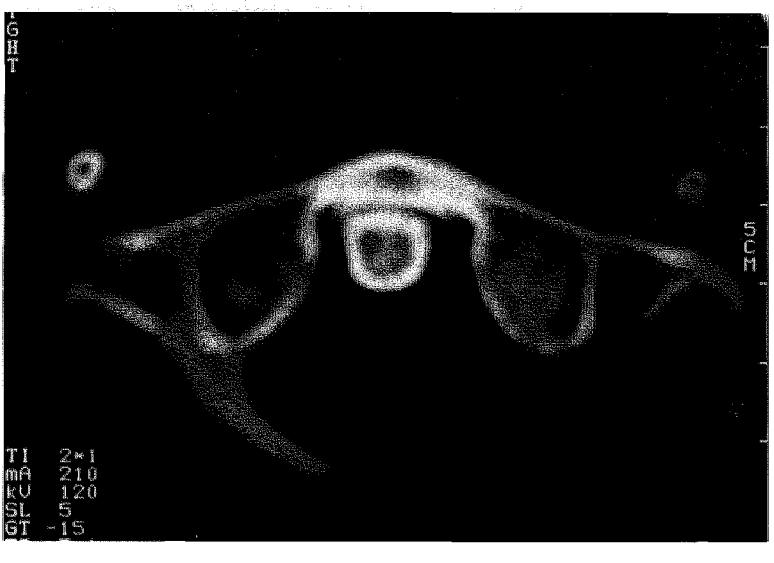

Figure 3. *CT slice shows narrowing of the joint space and osteophytes arising from the median facet of the atlas.*

6.5 Discussion

In 1942 Knutsson described the radiologic findings and occurrence of the vacuum phenomenon in degenerated intervertebral disks [4]. Since then, the frequency of this sign in degenerative disk and other disk disease has been documented in numerous publications [2,5,6]. It is seen in almost half of the cases of the CT studies of the lumbar spine in patients over 40 years old [7].

The presence of a vacuum phenomenon in facet joints of the lumbar spine at CT, was first reported by Carrera et al. in 1980 [3], who found it in 20 out of 100 consecutive patients with low back pain and sciatica. More recently, Hjarbaek et al [8] demonstrated gas within degenerated facet joints in 9 out of 234 (3,8%) CT examinations of the lumbar spine. In addition, gas within a facet joint of the lumbar spine may occasionally be found in degenerative spondylolisthesis due to traction and creation of a space between opposing articulating surfaces [9].

Table 2. *Other degenerative abnormalities at the atlanto-odontoid joint in the 12 patients with the vacuum phenomenon*

Case: no	Age (years)	Gender	Vacuum phenomenon AO joint	Osteophytes fovea dentis	Obliteration of AO joint space	Transverse ligament calcification
1	46	m	+	+	+	-
2	49	m	+	+	-	-
3	51	m	+	+	-	-
4	58	m	+	+	+	+
5	60	m	+	+	+	-
6	60	f	+	+	-	-
7	63	f	+	+	+	-
8	70	f	+	+	-	-
9	71	m	+	-	-	+
10	72	f	+	+	+	-
11	74	f	+	+	+	+
12	77	m	+	+	+	-

Although gas collections in the intervertebral disks and lumbar facet joints have been known for many years, we have not been able to find a description of gas-induced vacuum phenomenon within the atlanto-odontoid joint. In the present study, vacuum phenomena within the atlanto-odontoid joint were observed in 12 of 620 patients (1,9%) examined for brain or sinus abnormalities. The phenomenon was found only after the fourth decade of life and became slightly more common with age. Comparison of the prevalence of degenerative abnormalities at the atlanto-odontoid joint in patients with the vacuum phenomenon and in age matched controls shows a greater prevalence in the former group This difference was statistically significant for all evaluated degenerative signs. We therefore assume that the vacuum phenomenon within the atlanto-odontoid joint is associated with degeneration of the the articulating surfaces. The mechanism may be slight anterior subluxation of C1, which can produce a negative pressure within the degenerated joint and thereby attract gas from surrounding extracellular spaces.

It has frequently been suggested that degenerative changes at the atlanto-odontoid joint can cause suboccipital headache and a stiff neck [10-14]. In this context, our findings should serve to apprise radiologists of the existence of the vacuum phenomenon at the atlanto-odontoid joint and its association with degenerative changes.

Table 3. *Correlation between vacuum phenomenon and degenerative abnormalities at the atlanto-odontoid joint. Controls (N= 466) are age matched.*

		Vacuum phenomenon		P-value
		Present	**Absent**	
		n (%)	n (%)	
Osteophytes fovea dentis	**Present**	11 (92%)	92 (20%)	< 0.001
	Absent	1 (8%)	374 (80%)	
Obliteration of AO joint space	**Present**	7 (58%)	110 (24%)	0.02
	Absent	5 (42%)	356 (76%)	
Transverse ligament calcification	**Present**	3 (25%)	17 (4%)	0.004
	Absent	9 (75%)	449 (96%)	

6.6 References

1. Yousefzadeh DK (1979) The value of traction during roentgenography of the wrist and metacarpophalangeal joints. *Skeletal Radiol* 4 : 29

2. Resnick D, Niwayama G, Guerra J, Vint V, Usselman J (1981) Spinal vacuum phenomena: Anatomical study and review. *Radiology* 139 : 341

3. Carrera GF, Haughton VM, Syvertsen A, Williams AL (1980) Computed tomography of the lumbar facet joints. *Radiology* 134: 145

4. Knutsson F (1942) The vacuum phenomenon in the intervertebral discs. *Acta Radiol* 23: 173

5. Teplick JG, Teplick SK, Goodman L, Haskin ME (1982) Pitfalls and unusual findings in computed tomography of the lumbar spine. *J Comput Assist Tomogr* 6 : 888

6. Yetkin Z, Chintapalli K, Daniels DL, Haughton VM (1986) Gas in spinal articulations. *Neuroradiology* 28 : 150

7. Ladre D, Mathieu D, Frija J, Gaston A, Vasile N (1982) Spinal vacuum phenomenon: CT diagnosis and significance. *J Comput Assist Tomogr* 6 : 671

8. Hjarbaek J, Kristensen PW, Hauge P (1992) Spinal gas collection demonstrated at CT. *Acta Radiol* 33 : 93

9. Lefkowitz DM, Quencer RM (1982) Vacuum facet phenomenon: a computed tomographic sign of degenerative spondylolisthesis. *Radiology* 144: 562

10. Genez BM (1991) Atlantoodontoid osteoarthritis. *Critical Reviews in Diagnostic Imaging*: 301

11. Genez BM, Willis JJ, Lowrey ChE, Lauerman WC, Woodruff W, Diaz MJ, Higgs JB (1990) CT findings of degenerative arthritis of the atlantoodontoid joint. *Am J Roentgenol* 154 : 315

12. Harata S, Tohno S, Kawagishi T (1981) Osteoarthritis of the atlanto-axial joint. *Int Orth* 5 : 277

13. Shore LR (1935) On osteo-arthritis in the dorsal intervertebral joints A study in morbid anatomy. *Br J Surg* 22 : 833

14. Skaane P, Klott K-J (1981) Die peridentale Aureole (crowned odontoid process) bei der vorderen atlantodentalarthrose. *Fortschr Rontgenstr* 134 : 62

CHAPTER 7

ASSOCIATION OF TRANSVERSE LIGAMENT CALCIFICATION WITH ATLANTO-ODONTOID OSTEOARTHRITIS

J Zapletal[1], REM Hekster[1], JS Straver[2], JT Wilmink[3], J Hermans[4]

1 Department of Radiology, Leyenburg Hospital, The Hague
2 Department of Neurology, Leyenburg Hospital, The Hague
3 Department of Neuroradiology, University Hospital Maastricht
4 Department of Medical Statistics, University of Leiden

Accepted for publication in:
Neuroradiology

7.1 Abstract

The craniocervical junction was evaluated in a consecutive group of 700 unselected patients undergoing CT of the brain or paranasal sinuses, to investigate whether transverse ligament calcification was associated with advanced degenerative changes at the anterior atlanto-odontoid (AO) joint. Calcific deposits within the transverse ligament were seen in 40 patients (5.7%). The prevalence of this condition increased with age. Advanced degenerative changes (marked osteophytes and obliteration of the joint space) at the anterior AO joint were significantly more frequent in patients with transverse ligament calcification than in age-matched controls. We conclude that transverse ligament calcification is seen frequently in the elderly and very frequently with advanced degenerative changes at the anterior AO joint

7.2 Introduction

Calcification of the transverse atlanto-odontoid (AO) ligament has been reported in patients with crystal deposition disease [1,2]. The association between crystal deposition and joint degeneration in peripheral joints has received considerable attention [3,4]. However an association between calcification of the transverse ligament and advanced degenerative changes of the anterior AO joint has not been reported.

Frequent observation of transverse ligament calcification in combination with advanced anterior AO osteoarthritis on computed tomography (CT) in patients undergoing an examination including the craniocervical junction has led us to investigate whether these calcific deposits posterior to the odontoid process were associated with advanced degenerative changes in the anterior AO joint.

7.3 Materials and Methods

The atlanto-odontoid joint was studied in 700 consecutive unselected patients undergoing CT of the brain or paranasal sinuses for suspected brain or sinus abnormalities. All examinations were performed by means of standard technique (420 mAs, 120 kV, 5 mm parallel sections). The craniovertebral junction was assessed in each patient and photographed with both soft tissue and bone window settings.

We classified advanced degenerative changes at the anterior AO joint and partial or total calcification of the transverse ligament (Figs. 1-2). All images were reviwed by two of us (JZ and REMH) and agreement was reached by consensus.

The following morphological changes at the anterior AO joint were noted:

(1) obliteration of the anterior AO joint space

(2) marked osteophytes arising from the fovea dentis of the atlas

(3) both of the above

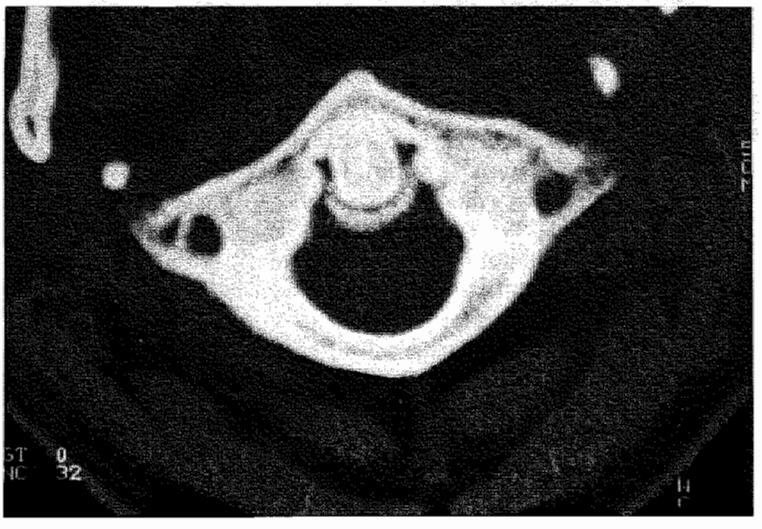

Figure 1. *Calcific deposits in the transverse ligament and obliteration of the atlanto-odontoid joint space.*

Figure 2. *Transverse ligament calcification with obliteration of the atlanto-odontoid joint space and osteophytes arising from the fovea dentis at the anterior arch of C1.*

7.4 Results

In 700 CT examinations performed in an 8-month period, calcific deposits within the transverse ligament were seen in 40 patients (5,7%): 24 women and 16 men, ranging in age from 40 to 88 years (mean 75 years). Figure 3 shows the percentage prevalence of patients with calcific deposits within the transverse ligament in each decade. Of the 40 patients, 34 (85%) showed advanced degenerative abnormalities (osteophytes or obliteration of the joint space, or both) at the anterior AO joint.

Table 1 compares the prevalence of these advanced degenerative signs in patients with transverse ligament calcification with that in an age-matched group of 561 patients without ligamentous calcification. Statistical differences between the groups were computed with the chi-square test. Statistical significance was defined as $P < 0.01$. Osteophytes, obliteration of the joint space or both were very significantly more frequent in patients with transverse ligament calcification than in the other patients.

Table 1 *Frequency of signs of degeneration at the anterior AO joint in 40 patients with and 561 age-matched patients without transverse ligament calcification.*

		Transverse ligament calcification		P value
		Present	**Absent**	
Osteophytes	**Present**	22 (55%)	123 (22%)	< 0.001
	Absent	18 (45%)	438 (78%)	
Obliteration of the joint space	**Present**	30 (75%)	163 (29%)	< 0.001
	Absent	10 (25%)	398 (71%)	
Osteophytes and obliteration of the joint space	**Present**	18 (45%)	119 (21%)	< 0.001
	Absent	22 (55%)	442 (79%)	

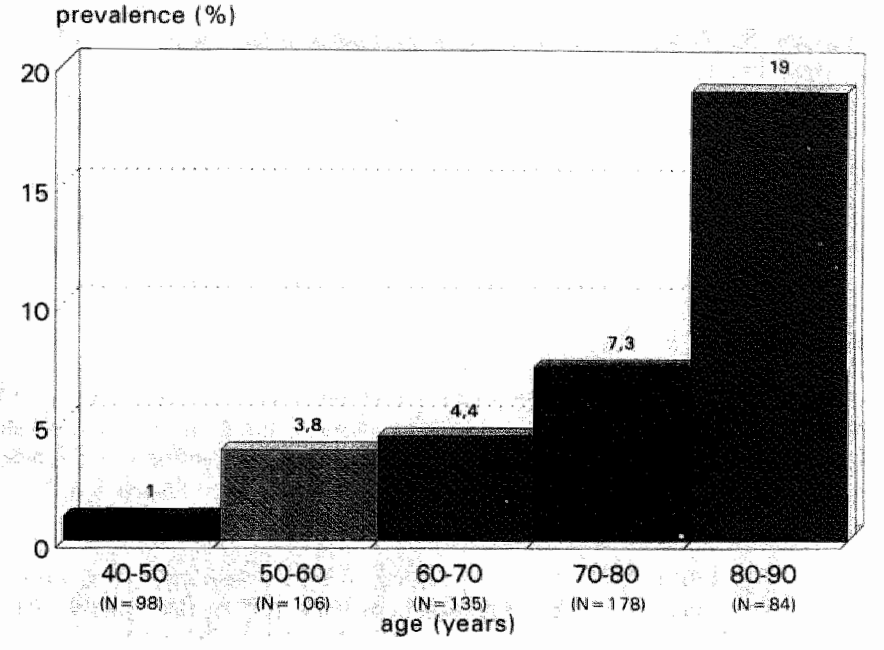

Figure 3. *Percentage prevalence with age of transverse ligament calcification in patients referred for CT of the brain or paranasal sinuses.*

7.5 Discussion

Calcification within peripheral joints due to crystal deposits in patients with calcium pyrophosphate dihydrate deposition disease (CPPD) may be fairly common in the elderly, especially in the knee joint [5]. CPPD is a general term applied to a disorder that may cause a crystal induced acute synovitis (pseudogout) with calcification of cartilage (chondrocalcinosis), joint capsules, ligaments and tendons. Ligaments of the cervical spine involved by crystal deposition disease include the ligamentum flavum, and posterior longitudinal ligament and transverse ligament [2]. Dirheimer et al [6] reported a 44% frequency of calcification of the posterior odontoid region on conventional tomography in patients with definite or possible CPPD, and Bouvet et al. [7] reported four patients with transverse ligament calcification and postulated that the calcific deposits could be caused by hydroxyapatite (HA) crystals as well as calcium pyrophosphate.

A definite relationship between calcification due to crystal deposition in HA or CPPD and secondary osteoarthritis in peripheral joints has been described [3,4,8]. However, a relationship between transverse ligament calcification and advanced degenerative changes at the anterior AO joint is unknown.

We have shown that calcific deposits are common in the elderly and that patients with transverse ligament calcification have a significantly higher incidence of advanced degenerative signs at the anterior AO joint than others of the same age. The part played by calcific deposits posterior to the odontoid process in the aetiology of degenerative changes at the anterior AO joint is unclear.

Transverse ligament calcification has been described a possible cause of cervical pain and restricted neck movements in patients with CPPD [7,9,10]. Succesful treatment of this condition, usually with anti-inflammatory drugs in patients with CPPD has been reported [7,10]. Degenerative change in the anterior AO joint has also been described as a possible cause of neck pain and restricted motion [11-13]. However, relevant therapy for this latter condition has, to date, not been established [14] .

Although the exact contribution of the morphological abnormalities at the anterior AO joint and transverse ligament to the production of symptoms still has to be elucidated, we think that radiologists and clinicians should be aware of the frequency of this calcification and of the frequent coexistence of advanced degenerative changes in the anterior AO joint.

7.6 Literature

1. Dirheimer Y, Wackenheim C, Dietemann JL (1985) Calcification of the transverse-ligament in calcium dihydrate deposition disease (CPPD). *Neuroradiology* 27:87

2. Resnick D, Pineda C (1984) Vertebral involvement in calcium pyrophosphate dihydrate crystal deposition disease. *Radiology* 153: 55-60

3. Wilkins E, Dieppe P, Maddison P, Evison G (1983) Osteoarthritis and articular chondro-calcinosis in the elderly. *Ann Rheum Dis* 42: 280-284

4. Ellman MH, Brown NL, Levin B (1981) Narrowing of knee joint space in patients with pseudogout. *Ann Rheum Dis* 40: 34-36

5. Resnick D, Niwayama G, Goergen TG, Utsinger PD, Shapiro RF, Haselwood DH,Wiesner KB (1977) Clinical, radiographic and pathologic abnormalities in calciumpyrophosphate dihydrate deposition disease (CPPD): pseudogout. *Radiology* 122: 1-15

6. Dirheimer Y, Bensimon C, Christmann D, Wackenheim C (1983) Syndesmo-odontoid joint and calcium pyrophosphate dihydrate deposition disease(CPPD). *Neuroradiology* 25: 319-321

7. Bouvet JP, Parc le JM, Michalski B, Benlahrache C, Auquier L (1985) Acute neck pain due to calcifications surrounding the odontoid process: the crowned dens syndrome. *Arthritis Rheum* 28: 1417-1420

8. Zitnan D, Sitaj S (1976) Natural course of articular chondrocalcinosis. *Arthritis Rheum* 19: 369-390.

9. El-Khoury GY, Tozzi JE, Clark CR, Foucar E, Menezes AH, Smoker WRK (1985) Massive calcium pyrophosphate crystal deposition at the craniovertebral junction. *AJR* 145: 777-778

10. Weber M, Gerber H (1991) Akutes zervikalsyndrom bei chondrocalcinose. *Schweiz Med Wschr* 121: 642-645

11. Fischer E, Schmidt H (1969) Die degenerativen veranderungen des vorderen Atlantodentalen Gelenks. *Fortschr Rontgenstr* 111: 552-558

12. Fournier AM, Rathelot J (1959) L'arthrose atlanto-odontoidienne: sa frequence comme d'algies nucales. *J Radiol Electrol* 40: 812-813

13. Skaane P, Klott KJ (1981) Die peridentale Aureole bei der vorderen Atlanto-dentalarthrose. *Fortschr Rontgenstr* 134: 62-68

14. Genez BM (1991) Atlantoodontoid osteoarthritis. *Critical Reviews in Diagnostic Imaging* 32: 301-321

CHAPTER 8

Summary and Conclusions

Samenvatting en Conclusies

Summary and conclusions

This study is concerned with radiological and clinical properties of degenerative changes at the atlanto-odontoid (anterior C1-C2) joint. In peripheral joints, degenerative change (osteoarthritis) is a well known cause of joint complaints and disability in the elderly. Regarding the cervical spine, patients with chronic pain in the suboccipital and neck region are traditionally examined with conventional radiography. This examination is suitable to identify degenerative changes at most cervical joints. However, the atlanto-odontoid joint which is located just below the skull base is frequently difficult to evaluate on conventional radiographs of the cervical spine due to overlying skull base structures. Computed tomography (CT) can overcome the obscuration of this fuctionally important joint, and show degenerative abnormalities to better advantage.

In **chapter 1** the objective of this study, which is to study the radiological appearance, prevalence and clinical significance (pain in the suboccipital region) of degenerative changes at the atlanto-odontoid joint is discussed. Furthermore, a short overview of the literature with specific historical impact regarding degenerative changes at the atlanto-odontoid joint is presented.

The radiologic appearance and prevalence of various degenerative changes at the atlanto-odontoid joint (osteophytosis, obliteration of the joint space and transverse ligament calcification) seen in patients undergoing CT of the brain or paranasal sinuses is described in **chapter 2**. The study demonstrates that degenerative disease at this joint is present in a significant percentage of older individuals. The prevalence of the degenerative changes at the atlanto-odontoid joint shows a roughly linear progression with advancing age.

In **chapter 3** the relationship of degenerative changes at the atlanto-odontoid joint, demonstrated by CT, to pain in the suboccipital region, is discussed. The degenerative abnormalities were graded (normal, mild or severe) with CT criteria used in the study described in chapter 4. The results of this study show that many patients (42%), referred to our institution for CT examination on account of a variety of other indications, experience pain in the suboccipital region. Mild and mostly severe degenerative changes seen at CT predispose (statistically significant compared with an age matched control group) to occurrence of these symptoms. However, some patients with mild or even with severe atlanto-odontoid had no complaints. Nevertheless, the predisposition of atlanto-odontoid osteoarthritis to suboccipital pain indicates that particular attention to this joint should be given in elderly patients with pain in the suboccipital region. Atlanto-odontoid osteoarthritis should therefore always be considered in the differential diagnosis in patients with this complaint.

The purpose of the study discussed in **chapter 4** was to assess the accuracy of lateral cervical spine radiography in the detection and grading of atlanto-odontoid osteoarthritis, with CT as gold standard. Findings indicate a good interobserver agreement in the evaluation of atlanto-odontoid osteoarthritis graded on a three grade scale on CT, and moderate interobserver agreement on lateral radiographs of the cervical spine. Conventional radiography was most accurate in distinguishing absent (grade=0) or mild (grade=1) disease from severe (grade=2) disease (83% sensitivity, 84% specificity). Sensitivity in distinguishing absent disease from mild or severe disease was 87%. Specificity however, was low (52%), due to overestimation of the degenerative involvement on radiography. It is concluded that lateral radiography of the cervical spine is a useful technique in screening for severe degenerative change at the atlanto-odontoid joint. However, CT is more useful as it provides better radiologic detail necessary for accurate diagnosis and grading of degenerative involvement in osteoarthritis at the atlanto-odontoid joint.

In **chapter 5** Magnetic Resonance Imaging (MRI) of severe degenerative changes at the atlanto-odontoid joint is presented. This study with comparison of conventional radiographs of the cranio-vertebral junction with MRI, shows that MR imaging can provide an excellent means of delineating cartilaginous and bony changes at the atlanto-odontoid joint in severe atlanto-odontoid osteoarthritis. An advantage of MRI is its capacity to completely display the craniocervical junction and cervical region together with its versatility of direct imaging in multiple planes and visualisation of the soft tissue structures. The exact accuracy of MRI in grading of the degenerative changes at the atlanto-odontoid joint has still to be evaluated.

Out of 620 consecutive examinations of the atlanto-odontoid joint in patients referred for CT of the brain or paranasal sinuses, gas collection (vacuum phenomenon) within the atlanto-odontoid joint was observed in 12 patients (1.9%). Degenerative abnormalities at the atlanto-odontoid joint were significantly more frequent in patients with a vacuum phenomenon than in an age matched control group. The CT findings and association of the vacuum phenomenon with osteoarthritis of the atlanto-odontoid joint are discussed in **chapter 6**.

The craniocervical junction was assessed in 700 consecutive unselected patients undergoing CT of the brain or paranasal sinuses, to investigate whether transverse ligament calcification was associated with degenerative changes at the anterior atlanto-odontoid joint. Calcific deposits within the transverse ligament were seen in 40 patients (5.7%). The prevalence of this condition increased with age. Advanced degenerative changes at the atlanto-odontoid joint were significantly more frequent in patients with transverse ligament calcification than in age-matched controls. The CT findings and frequent coexistence of advanced degenerative changes at the anterior atlanto-odontoid joint in patients with transverse ligament calcification are described in **chapter 7**.

In conclusion, atlanto-odontoid osteoarthritis, is occasionally encountered in the middle aged and frequently in the elderly. Degenerative changes at this particular joint can occur without degenerative abnormalities at other joints of the cervical spine. Despite the high prevalence of the degenerative disease at this articulation, radiologists rarely note these changes on radiographic, CT or MRI examination. This study shows that lateral radiography of the cervical spine is a rapid and inexpensive technique in screening for severe degenerative change at the atlanto-odontoid joint. An excellent assesment and grading of the morphologic changes at the atlanto-odontoid joint in mild and severe atlanto-odontoid osteoarthritis is possible by CT. MR imaging can also delineate degenerative changes in severe atlanto-odontoid osteoarthritis. However, the exact accuracy of MRI in grading of the degenerative changes at the atlanto-odontoid joint has still to be evaluated. The classification of the degenerative involvement is important as mild and mostly severe degenerative changes seen at CT predispose to occurence of suboccipital pain. Particular attention should therefore be given to this joint in patients with pain in the suboccipital region. In this context, a vacuum phenomenon within the atlanto-odontoid joint as well as transverse ligament calcification should serve to apprise radiologists of the frequent coexistence of these abnormalities with advanced degenerative changes at the atlanto-odontoid joint.

Finally, osteoarthritis at the atlanto-odontoid joint seems to be irreversible, but much can be done to ease pain and preserve function. In this regard, physical and/or manual therapy may be effective. New studies will have to be undertaken with patients with atlanto-odontoid osteoarthritis and serious complaints to compare the outcome of various treatments. If this will lead to an effective therapy with relief of symptoms and a better quality of daily life then it will become even more relevant to document and to classify the degenerative abnormalities at this functionally important articulation.

Samenvatting en conclusies

Dit proefschrift beschrijft radiologische en klinische aspecten van degeneratieve afwijkingen van het atlanto-dentale (voorste C1-C2) gewricht. Degeneratieve afwijkingen van perifere gewrichten vormen een bekende oorzaak voor pijnklachten en invaliditeit bij ouderen. Wat de cervicale wervelkolom betreft, worden patienten met chronische pijnklachten in de suboccipitale en nek regio gewoonlijk onderzocht door middel van conventioneel radiologisch onderzoek. Dit onderzoek is zeer geschikt voor de beoordeling van degeneratieve afwijkingen van de meeste cervicale gewrichten. Het vlak onder de schedelbasis gelegen atlanto-dentale gewricht is echter op conventionele opnamen van de cervicale wervelkolom vaak moeilijk te beoordelen. Computer tomografie (CT) is in staat degeneratieve afwijkingen in dit functioneel belangrijke gewricht beter in beeld te brengen.

In **hoofdstuk 1** wordt het doel van de studie; radiologische kenmerken, prevalentie en klinische significantie (suboccipitale pijn) van degeneratieve afwijkingen van het atlanto-dentale gewricht, besproken. Tevens wordt een kort historisch overzicht gegeven van de literatuur over atlanto-dentale artrose.

De radiologische kenmerken en prevalentie van degeneratieve afwijkingen van het atlanto-dentale gewricht (osteofyten, obliteratie van de gewrichtsspleet en verkalkingen in het ligamentum transversum), zoals gezien bij patienten die een CT onderzoek van de hersenen of neusbijholten ondergingen, worden in **hoofdstuk 2** toegelicht. Deze studie toont aan dat bij een hoog percentage van oudere mensen meerdere kenmerken van degeneratieve afwijkingen in dit gewricht aanwezig zijn. De prevalentie van de degeneratieve afwijkingen van het atlanto-dentale gewricht neemt vrijwel lineair toe met de leeftijd.

In **hoofdstuk 3** wordt ingegaan op de relatie tussen op CT zichtbare atlanto-dentale artrose en pijn in de suboccipitale regio. De degeneratieve veranderingen werden gegradeerd (in normaal, matig en ernstig) door middel van CT criteria, welke beschreven worden in hoofdstuk 4. Hoewel de patiënten voor andere klachten werden doorverwezen, bleken velen (42%) pijnklachten in de suboccipitale regio te hebben. De aanwezigheid van matige of ernstige atlanto-dentale artrose predisponeerde (vergeleken met een in leeftijd gelijkwaardige controle groep statistisch significant) voor suboccipitale pijnklachten. Daarentegen konden patienten met matige of zelfs met ernstige degeneratieve afwijkingen ook volledig klachtenvrij zijn. Desalniettemin dient, gezien de bovenbeschreven predispositie, atlanto-dentale artrose altijd te worden opgenomen in de differentiaal diagnose van pijn in de suboccipitale regio.

Het doel van de studie, toegelicht in **hoofdstuk 4**, was om de nauwkeurigheid van de conventionele laterale opname van de cervicale wevelkolom ten aanzien van de detectie en gradering van atlanto-dentale artrose te bepalen. De CT-scan werd hierbij gebruikt als de gouden standaard. De bevindingen tonen een goede overeenstemming aan tussen verschillende waarnemers bij de evaluatie van atlanto-dentale artrose (graad 0, 1 en 2) op CT en een matige overeenstemming bij de beoordeling van atlanto-dentale artrose op conventionele laterale opnamen van de cervicale wervelkolom. De conventionele röntgen-opname was nauwkeurig in het onderscheid tussen afwezige (graad=0) of matige (graad=1) en ernstige (graad=2) degeneratieve afwijkingen (83% sensitiviteit, 84% specificiteit). De sensitiviteit bij het onderscheid tussen afwezige en matige of uitgebreide degeneratieve afwijkingen bedroeg 87%. De specificiteit was echter relatief laag (52%) door de over-schatting van de degeneratieve afwijkingen op de röntgen opname. De conclusie van deze studie is dat de conventionele laterale röntgen opname van de cervicale wervelkolom waardevol is bij de screening van ernstige (graad=2) degeneratieve afwijkingen aan het atlanto-dentale gewricht. Door een beter radiologisch detail is de CT echter geschikter voor diagnose en gradering van degeneratieve afwijkingen aan dit gewricht.

In **hoofdstuk 5** worden de op de Kernspin Resonantie Tomografie of Magnetic Resonance Imaging (MRI) zichtbare ernstige degeneratieve afwijkingen van het atlanto-dentale gewricht gepresenteerd. Deze studie, waarbij conventioneel röntgenonderzoek van de cranio-cervicale overgang wordt vergeleken met de MRI, toont dat MRI uitstekend kraakbenige en ossale afwijkingen bij ernstige atlanto-dentale artrose kan weergeven. De voordelen van de MRI zijn de mogelijkheden om de craniocervicale overgang en cervicale regio in zijn geheel in meerdere vlakken af te beelden met daarnaast een goede visualisatie van de weke delen. De geschiktheid van MRI ten aanzien van gradering van atlanto-dentale artrose dient echter nog te worden geëvalueerd.

Van de 620 opeenvolgend onderzochte patienten, verwezen voor CT onderzoek van de hersenen of neusbijholten, werd bij 12 (1.9%) patienten een gas ophoping (vacuüm fenomeen) in het atlanto-dentale gewricht gezien. Degeneratieve afwijkingen aan het atlanto-dentale gewricht kwamen significant vaker voor bij patiënten met een door gas veroorzaakt vacuüm fenomeen vergeleken met een in leeftijd overeenkomstige controle groep. De CT bevindingen en verband tussen het vacuüm fenomeen en artrose van het atlanto-dentale gewricht worden in **hoofdstuk 6** besproken.

De cranio-cervicale overgang werd bij 700 ongeselecteerde opeenvolgende pati-enten beoordeeld om te onderzoeken of er een verband bestaat tussen artrose aan het atlanto-dentale gewricht en verkalkingen in het ligamentum transversum. Bij 40 patiënten (5.7%) werden verkalkingen in het ligamentum transversum waargenomen. De prevalentie van deze bevindingen toonde een lineair verband met het stijgen van de leeftijd.

Vergevorderde degeneratieve afwijkingen aan het voorste atlanto-dentale gewricht kwamen significant vaker voor bij patienten met verkalkingen in het ligamentum transversum vergeleken met een in leeftijd overeenkomstige controle groep. De CT bevindingen en de vaak voorkomende coëxistentie van artrose aan het voorste atlanto-dentale gewricht en ligamentum transversum verkalkingen, worden in **hoofdstuk** 7 beschreven.

De conclusies luiden dat atrose van het atlanto-dentale gewricht soms op middelbare leeftijd en vaak bij ouderen voorkomt. Degeneratieve veranderingen van dit gewricht kunnen zonder degenerative afwijkingen aan andere cervicale gewrichten voorkomen. Ondanks de hoge prevalentie van atlanto-dentale artrose worden de afwijkingen op conventionele röntgen opnamen, CT of MRI in het algemeen nauwelijks opgemerkt. De studie toont dat de conventionele laterale opname van de cervicale wervelkolom een snelle en relatief goedkope methode is om ernstige atlanto-dentale artrose aan te tonen. CT is in staat de morphologische veranderingen aan het atlanto-dentale gewricht uitstekend weer te geven en biedt de mogelijkheid de degeneratieve afwijkingen betrouwbaar te graderen in matig en ernstig. Kernspin Resonantie Tomografie (MRI) kan ook uitstekend ernstige kraakbenige en ossale afwijkingen bij ernstige atlanto-dentale artrose weergeven. De geschiktheid van MRI ten aanzien van de classificatie van atlanto-dentale artrose dient echter nog verder te worden geëvalueerd. Het classificeren van de degeneratieve afwijkingen is van belang gezien de predispositie van matige en vooral van ernstige atlanto-dentale artrose voor suboccipitale pijnklachten. Extra aandacht voor dit gewricht is bij patienten met onbegrepen suboccipitale pijnklachten derhalve op zijn plaats. In dit verband dient het voorkomen van het vacuüm fenomeen in het atlanto-dentale gewricht evenals verkalkingen in het ligamentum transversum, vaak in samenhang met vergevorderde degeneratieve veranderingen aan het atlanto-dentale gewricht, te worden opgemerkt.
Tenslotte, alhoewel osteoartrose van het atlanto-dentale gewricht een irreversibel proces lijkt te zijn, kan er bij hinderlijke klachten veel gedaan worden aan vermindering van pijnklachten en behoud van functie. Met name fysiotherapie en/of manuele therapie lijkt in dit opzicht succesvol. Nieuwe studies zijn nodig om het effect van diverse mogelijke behandelingen van hinderlijke suboccipitale pijnklachten, bij patienten met atlanto-dentale artrose, te toetsen. Indien dit zal leiden tot een effectieve therapie met vermindering van de klachten en een verbetering van de levenskwaliteit dan zal het belang, om de degeneratieve afwijkingen aan dit functioneel belangrijke gewricht te vermelden en te classificeren, verder toenemen.

Acknowledgements

The studies presented in this thesis were performed in the Department of Diagnostic Radiology of the Leyenburg Hospital (Head: Dr. R.E.M. Hekster)

The author wishes to acknowledge gratefully all those who contributed to the realization of this thesis, in particular;

Dr. R.E.M. Hekster who offered me ample opportunity, encouragement and constructive advice during the preparation of this thesis.
Prof. Dr. J.T. Wilmink for his stimulating assistance and revision of the manuscripts.
Dr. J. Hermans for his support in practical and statistical problems.
J. Straver for his co-authorship of several manuscripts.
W.M.C. Mallens for his help and enthusiasm in solving computer problems. I am also most grateful for the use of his computer.
F.E.E. Treurniet for his support in the analysis of the MR study.
J. Schipper for his support in the film interpretation sessions.
Dr. C. Stam for his help and ideas in the preparation of the "stellingen"
The audiovisual department for the photography and illustrations.
Furthermore, I would like to thank the librarians, the secretariat and the workers of the CT and MR department for their co-operation during the studies.

Curriculum Vitae

The author was born in Olmutz (Czech.) on July 3, 1961. After finishing the secondary school, atheneum B (Rembrandt Lyceum in Leiden) in 1981, he began to study medicine at the University of Antwerp (Belgium). In 1984 he continued his medical training at the University of Leiden where he graduated in 1988. After receiving his medical degree, he worked as a resident in the Neurosurgery department of the Leiden University Hospital (head: H. van Dulken). From July 1990 to July 1995 he received training in Radiology at the Department of Radiology of the Leyenburg Hospital in The Hague (head: Dr. R.E.M. Hekster). From July 1995 he is employed as chef de clinique at the Radiology department, St. Antonius Hospital in Nieuwegein. The work described in this thesis was initiated at the end of 1992.