

# Yield of Adding chest CT to Abdominal CT to Detect COVID-19 in Patients Presenting With Acute Gastrointestinal Symptoms (SCOUT-3): Multicenter Study

Citation for published version (APA):

Borgstein, A. B. J., Scheijmans, J. C. G., Puylaert, C. A. J., Keywani, K., Lobatto, M. E., Orsini, R. G., Veilinga, T. V., van Rossen, J., Scheerder, M. J., Voermans, R. P., Han, A. X., Russell, C. A., Prins, J. M., Gietema, H. A., Stoker, J., Boermeester, M. A., Gisbertz, S. S., Besselink, M. G., & SCOUT Study Group (2022). Yield of Adding chest CT to Abdominal CT to Detect COVID-19 in Patients Presenting With Acute Gastrointestinal Symptoms (SCOUT-3): Multicenter Study. *Annals of Surgery*, 276(6), E758-E763. <https://doi.org/10.1097/SLA.0000000000004678>

## Document status and date:

Published: 01/12/2022

## DOI:

[10.1097/SLA.0000000000004678](https://doi.org/10.1097/SLA.0000000000004678)

## Document Version:

Publisher's PDF, also known as Version of record

## Document license:

Taverne

## Please check the document version of this publication:

- A submitted manuscript is the version of the article upon submission and before peer-review. There can be important differences between the submitted version and the official published version of record. People interested in the research are advised to contact the author for the final version of the publication, or visit the DOI to the publisher's website.
- The final author version and the galley proof are versions of the publication after peer review.
- The final published version features the final layout of the paper including the volume, issue and page numbers.

[Link to publication](#)

## General rights

Copyright and moral rights for the publications made accessible in the public portal are retained by the authors and/or other copyright owners and it is a condition of accessing publications that users recognise and abide by the legal requirements associated with these rights.

- Users may download and print one copy of any publication from the public portal for the purpose of private study or research.
- You may not further distribute the material or use it for any profit-making activity or commercial gain
- You may freely distribute the URL identifying the publication in the public portal.

If the publication is distributed under the terms of Article 25fa of the Dutch Copyright Act, indicated by the "Taverne" license above, please follow below link for the End User Agreement:

[www.umlib.nl/taverne-license](http://www.umlib.nl/taverne-license)

## Take down policy

If you believe that this document breaches copyright please contact us at:

[repository@maastrichtuniversity.nl](mailto:repository@maastrichtuniversity.nl)

providing details and we will investigate your claim.

Download date: 24 Apr. 2024

# Yield of Adding chest CT to Abdominal CT to Detect COVID-19 in Patients Presenting With Acute Gastrointestinal Symptoms (SCOUT-3): Multicenter Study

A.B.J. Borgstein, MD,\* J.C.G. Scheijmans, MD,† C.A.J. Puylaert, MD, PhD,‡  
 K. Keywani, BSc,\* M.E. Lobatto, MD, PhD,§ R.G. Orsini, MD, PhD,||  
 T. van Rees Veilinga, MD,¶ J. van Rossen, MD,# M.J. Scheerder, MD,‡  
 R.P. Voermans, MD, PhD,\*\* A.X. Han, PhD,†† C.A. Russell, PhD,††  
 J.M. Prins, MD, PhD,‡‡ H.A. Gietema, MD, PhD,§§ J. Stoker, MD, PhD,‡  
 M.A. Boermeester, MD, PhD,† S.S. Gisbertz, MD, PhD,\* and  
 M.G. Besselink, MD, PhD,\*✉ on behalf of the SCOUT study group

**Objective:** To determine the incremental yield of standardized addition of chest CT to abdominal CT to detect COVID-19 in patients presenting with primarily acute gastrointestinal symptoms requiring abdominal imaging.

**Summary Background Data:** Around 20% of patients with COVID-19 present with gastrointestinal symptoms. COVID-19 might be neglected in these patients, as the focus could be on finding abdominal pathology. During the COVID-19 pandemic, several centers have routinely added chest CT to abdominal CT to detect possible COVID-19 in patients presenting with gastrointestinal symptoms. However, the incremental yield of this strategy is unknown.

**Methods:** This multicenter study in 6 Dutch centers included consecutive adult patients presenting with acute nontraumatic gastrointestinal symptoms, who underwent standardized combined abdominal and chest CT between March 15, 2020 and April 30, 2020. All CT scans were read for signs of COVID-19 related pulmonary sequelae using the CO-RADS score. The primary outcome was the yield of high COVID-19 suspicion (CO-RADS 4-5) based on chest CT.

**Results:** A total of 392 patients were included. Radiologic suspicion for COVID-19 (CO-RADS 4-5) was present in 17 (4.3%) patients, eleven of which were diagnosed with COVID-19. Only 5 patients with CO-RADS 4-5 presented without any respiratory symptoms and were diagnosed with COVID-19. No relation with community prevalence could be detected.

**Conclusion:** The yield of adding chest CT to abdominal CT to detect COVID-19 in patients presenting with acute gastrointestinal symptoms is extremely low with an additional detection rate of around 1%.

**Keywords:** chest CT, CO-RADS, COVID-19, GI-symptoms

(*Ann Surg* 2022;276:e758–e763)

Patients with COVID-19 typically present with respiratory symptoms, fever, and/or fatigue.<sup>1,2</sup> However, there is growing evidence that SARS-CoV-2 can affect the small intestine, liver, pancreas, and kidneys as well.<sup>3</sup> Hence, patients with COVID-19 may present with gastrointestinal symptoms, including abdominal pain, diarrhea, anorexia, or vomiting,<sup>2,4-8</sup> with limited respiratory symptoms. One study found that nearly 20% of COVID-19 patients presented with concomitant gastrointestinal symptoms,<sup>9</sup> whereas in another study 16% of COVID-19 patients presented merely with gastrointestinal symptoms.<sup>10</sup> The atypical presentation of this group provides a clinical challenge, as clinicians might focus on finding abdominal pathology. No standardized diagnostic work-up, including the role of routine chest computed tomography (CT), has been described in these patients.

The (pre-COVID-19) Dutch guideline recommends a step-up imaging scheme for patients presenting with acute abdominal pain, starting with ultrasound and followed by abdominal CT if needed.<sup>11,12</sup> During the current COVID-19 pandemic, some centers have implemented standard use of abdominal CT with the standard addition of chest CT to detect possible SARS-CoV-2 infections in patients presenting with acute gastrointestinal symptoms, as these symptoms could be related to COVID-19.

However, the yield of combined CT chest-abdomen for detection of COVID-19 in patients with acute gastrointestinal symptoms is unknown. The aim of this study is to evaluate the incremental yield of high COVID-19 suspicion based on

From the \*Department of Surgery, Cancer Center Amsterdam, Amsterdam UMC, University of Amsterdam, Amsterdam, the Netherlands; †Department of Surgery, Amsterdam Gastroenterology Endocrinology Metabolism, Amsterdam UMC, University of Amsterdam, Amsterdam, the Netherlands; ‡Department of Radiology and Nuclear Medicine, Amsterdam Gastroenterology Endocrinology Metabolism, Amsterdam UMC, University of Amsterdam, Amsterdam, the Netherlands; §Department of Radiology, Spaarne Gasthuis, Haarlem and Hoofddorp, the Netherlands; ||Department of Surgery, Maastricht UMC+, Maastricht, the Netherlands; ¶Department of Radiology, Haaglanden Medical Center, Den Haag, the Netherlands; #Department of Radiology, Hospital Group Twente, Almelo, the Netherlands; \*\*Department of Gastroenterology and Hepatology, Amsterdam UMC, University of Amsterdam, Amsterdam, the Netherlands; ††Laboratory of Applied Evolutionary Biology, Amsterdam UMC, University of Amsterdam, Amsterdam, the Netherlands; ‡‡Department of Internal Medicine, Amsterdam Institute for Infection and Immunity (AI&I), Amsterdam

UMC, University of Amsterdam, Amsterdam, the Netherlands; §§Department of Radiology and Nuclear Medicine, Maastricht UMC+, Maastricht, the Netherlands.

✉m.g.besselink@amsterdamumc.nl.

A.B.J.B. and J.C.G.S. contributed equally to this article.

J.M.P., H.A.G., J.S., M.A.B., S.S.G., and M.G.B. contributed equally to this article.

A.B.J. Borgstein and J.C.G. Scheijmans shared first authorship.

J.M. Prins, H.A. Gietema, J. Stoker, M.A. Boermeester, S.S. Gisbertz, and M.G. Besselink shared last authorship.

The authors report no conflicts of interest.

Supplemental digital content is available for this article. Direct URL citations appear in the printed text and are provided in the HTML and PDF versions of this article on the journal's Web site ([www.annalsofsurgery.com](http://www.annalsofsurgery.com)).

Copyright © 2020 Wolters Kluwer Health, Inc. All rights reserved.

ISSN: 0003-4932/22/27606-e758

DOI: 10.1097/SLA.0000000000004678

standard addition of chest CT to abdominal CT in patients presenting with acute gastrointestinal symptoms.

## METHODS

This retrospective, multicenter study was conducted at 3 academic and 3 teaching hospitals in the Netherlands. Centers could participate in the study if the combination of chest and abdominal CT was part of the standard diagnostic work-up for patients who presented during the COVID-19 pandemic with acute gastrointestinal symptoms at the emergency department in whom abdominal imaging was required. Ethical approval was waived by the institutional review boards because of the observational nature of the study. Patient data was only used if patients did not opt-out for participation in this study.

### Study Population

Eligible were consecutive adult patients presenting at the emergency department with primarily acute nontraumatic gastrointestinal symptoms, who underwent combined chest-abdominal CT between March 15, 2020 to April 30, 2020. This study period represents the period with the highest COVID-19 prevalence in the Netherlands at the start of the pandemic.

Patients were excluded if the primary complaint was other than abdominal (mild respiratory symptoms could be present, but only if interpreted as secondary to the abdominal complaints), if a chest CT was incomplete (defined as not including the basal lungs up to at least the level of the carina), or if patients were not able to object to participation in the study.

### Data Collection

Patient demographics, clinical characteristics including emergency department presentation and known risk factors for COVID-19, CT reports, and 30-day clinical outcomes were collected from the electronic patient record. For chest CT imaging, the CO-RADS score for suspicion of COVID-19 diagnosis was used (1, very low suspicion; 2, low suspicion, 3, equivocal, 4, high suspicion, 5, very high suspicion).<sup>13</sup> For abdominal CT, diagnoses causative for the GI-symptoms were collected. Abbreviated postal codes were collected to analyze regional differences in the primary outcome.

### Study Outcomes

Our primary outcome was the yield of high COVID-19 suspicion based on abdominal CT combined with chest CT (CO-RADS 4-5) in patients presenting with primary acute nontraumatic gastrointestinal symptoms.

Patients were diagnosed with COVID-19 if reverse-transcriptase polymerase chain reaction (RT-PCR) results were positive. Alternatively, in patients with CO-RADS 4-5 and negative RT-PCR, the treating physician evaluated the COVID-19 diagnosis based on clinical presentation, CT findings, and lab results, as sensitivity of RT-PCR is limited. All RT-PCR's were performed within 24 hours after presentation at the emergency department.

Secondary outcomes were the total number of patients diagnosed with COVID-19, the yield of COVID-19 suspicion based on chest CT stratified according to the presence of COVID-19 respiratory symptoms and the relationship between COVID-19 community prevalence and positive yield of chest-abdomen CT screening.

## Relationship to Community Prevalence

Patients were stratified by their province of residence and date of presentation at the emergency department to investigate the relationship between the primary outcome and community prevalence of COVID-19. Publicly available prevalence data was obtained from the Dutch National Institute for Public Health and the Environment.<sup>14</sup> The number of inhabitants per province in 2020 were obtained from the Central Agency of Statistics in the Netherlands.<sup>15</sup> The positive yield of COVID-19 diagnoses based on combined chest-abdomen CT and RT-PCR was compared to the mean daily COVID-19 admissions per 100,000 inhabitants within a 7-day window around each patient's presentation at the emergency department.

## Statistical Analysis

Clinical characteristics were described using frequency tables. Continuous data were presented as mean with standard deviation, unless stated otherwise. Categorical variables were presented as frequencies and percentages. Categorical variables were compared using the  $\chi^2$  test or Fisher exact test. All P values were based on 2-sided tests and  $P < 0.05$  was considered statistically significant. Data were analyzed using SPSS version 26 (IBM, Armonk, New York, USA)

## RESULTS

### Patient Characteristics

Between March 15, 2020 and April 30, 2020, a total of 392 consecutive patients, who presented at the emergency departments of the 6 participating centers with primary acute nontraumatic gastrointestinal symptoms and underwent combined chest-abdomen CT were included, see Figure 1 and Table 1 summarizes the characteristics of all patients.

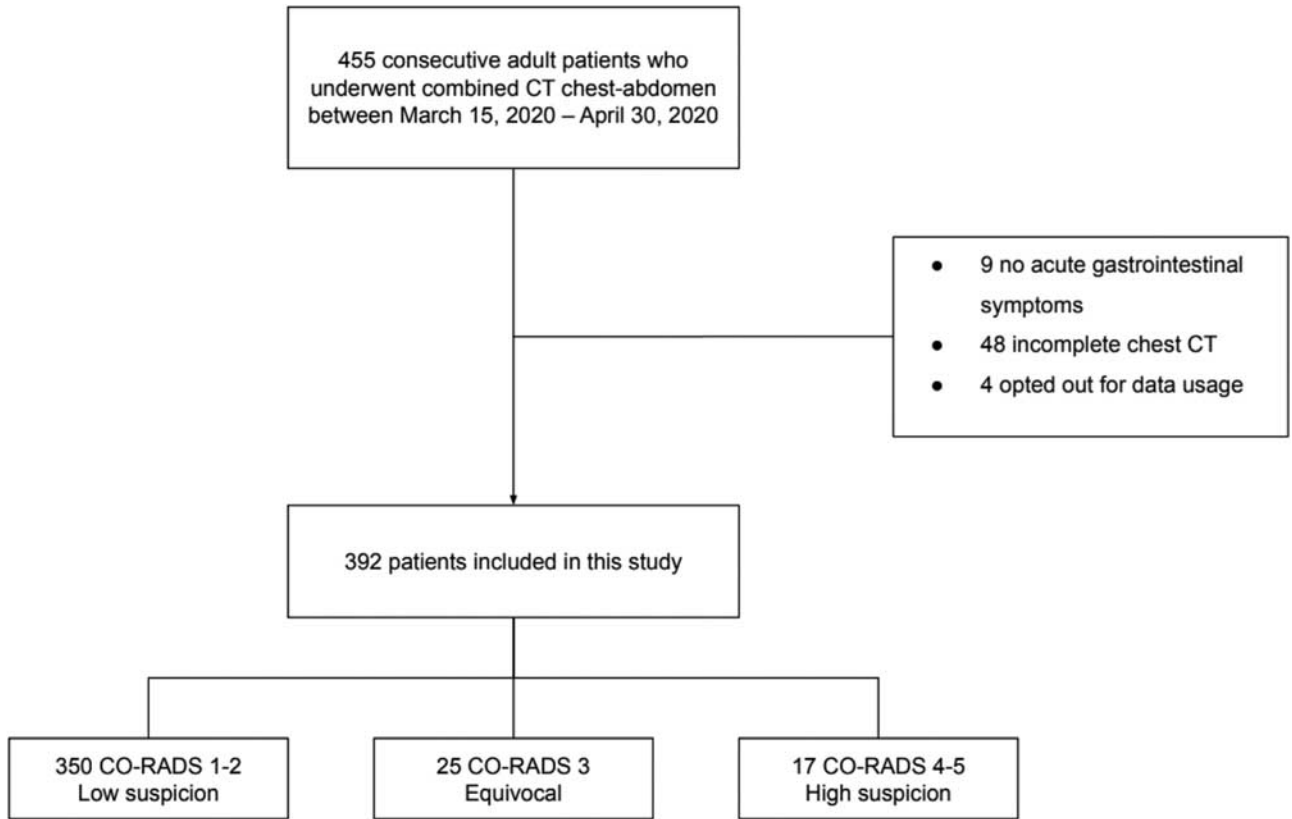
### The Yield of COVID-19 Suspicion

Table 2 describes the yield of COVID-19 suspicion based on combined chest-abdomen CT and primary RT-PCR testing results. In 17 of 392 (4.3%) patients, chest CT was scored as CO-RADS 4 or 5. All of these 17 patients underwent RT-PCR testing for SARS-CoV-2; 8 tested positive, 8 tested negative, and 1 test was inconclusive. Overall, 11 of 17 patients with CO-RADS 4-5 were diagnosed with COVID-19; 3 of which were diagnosed with COVID-19 based on CO-RADS 5 and clinical presentation without RT-PCR confirmation.

In 25 (6.4%) patients, chest CT was read as CO-RADS 3. Twenty-two of these 25 patients underwent RT-PCR testing; 3 patients tested positive, whereas 19 patients tested negative. In total, 4 patients with a CO-RADS 3 were diagnosed with COVID-19, one based on clinical presentation and chest CT findings.

Of the 350 patients with a CO-RADS 1-2, 156 had RT-PCR testing. Three patients tested positive, 152 patients tested negative, and 1 test was inconclusive. Overall, 2 patients with a CO-RADS 1 (no signs of pulmonary infection) and 1 patient with a CO-RADS 2 (signs of infection, but judged as not caused by COVID-19) were diagnosed with COVID-19.

Overall, 23 patients with an initial negative RT-PCR received a repeat RT-PCR test within 4 days after presentation at the emergency department, however, none of these patients tested positive. Therefore, 18 patients (4.6%) were diagnosed with COVID-19: 11 patients with CO-RADS 4-5 and 7 patients with CO-RADS 1-3 plus a positive RT-PCR.



**FIGURE 1.** Flowchart of patients undergoing combined CT chest-abdomen for gastrointestinal symptoms.

**TABLE 1.** Baseline Characteristics of Patients With Acute Gastrointestinal Symptoms Who Underwent Combined CT Chest-abdomen

Characteristics	N = 392
Age, median (IQR), yrs	59 (43–73)
Age, range, yrs	18–95
Female sex, no./total no. (%)	214/392 (54.6)
Body-mass index, median (IQR), kg/m <sup>2</sup>	21.8 (19.3–25.7)
Body-mass index > 30, no./total no. (%)	24/392 (6.1)
Smoking history, no./total no. (%)	
Never smoked	95/392 (24.2)
Former smoker	41/392 (10.5)
Current smoker	61/392 (15.6)
Unknown	195/392 (49.7)
Comorbidities, no./total no. (%)	
Chronic obstructive pulmonary disease	26/392 (6.6)
Diabetes	53/392 (13.5)
Hypertension	118/392 (30.1)
Coronary heart disease	37/392 (9.4)
Heart failure	17/392 (4.3)
Cerebrovascular disease	29/392 (7.4)
ASA classification, no./total no. (%)	
1	40/392 (10.2)
2	46/392 (11.7)
3	44/392 (11.3)
4	6/392 (1.5)
Unknown	256/392 (65.3)

ASA indicates American Society of Anesthesiologists; CT, computed tomography; IQR, interquartile range.

Table 1 S1, <http://links.lww.com/SLA/C812> describes the yield of COVID-19 suspicion based on combined chest-abdomen CT and RT-PCR results for each of the participating centers. Table S2, <http://links.lww.com/SLA/C812> summarizes the follow-up information of the 18 proven COVID-19 patients. Eleven patients were admitted to the hospital, no patients were admitted to the intensive care unit, and 2 patients were deceased. Of the 4 COVID-19 patients without RTPCR confirmation, none received additional RT-PCR testing. One patient was recovering from a previous SARS-CoV-2 infection. One patient was admitted to the hospital for 1 day and none of these patients were readmitted to the hospital or deceased. Table S3, <http://links.lww.com/SLA/C812> provides an overview of all definitive diagnoses established within seven days after initial presentation at the emergency department.

**CO-RADS Stratified for Respiratory Symptoms**

Table 3 summarizes the CO-RADS classification stratified according to the presence of typical COVID-19 respiratory symptoms. According to history taking and physical examination, significantly more patients with a CO-RADS 4-5 were coughing compared to those with CO-RADS 1-2 or CO-RADS 3 (29.4% vs 9.4% and 12.0%, respectively;  $P = 0.032$ ) and/or had fever (70.6% vs 28.5% and 26.6%, respectively;  $P < 0.001$ ). In each group (CO-RADS 1-2, 3, or 4-5), one of the patients had been in close contact with a known COVID-19 patient and none of the patients traveled to a foreign country within 14 days before presentation at the emergency department. Overall, 5 of the 11 patients with CO-RADS 4-5, who

Downloaded from <http://journals.lww.com/annalsurgery> by BMDMIS6PHKav1zEoum1tQINM44+hJLHEZg9bsH-06XXM10HCyWCX1AWNvYQpIIQIHd3D00QRyT7VSF14C9Vc1YabgGZXd9Gj2MwZLel= on 10/24/2023

**TABLE 2.** COVID-19 Suspicion Based on Combined Chest-abdomen CT Findings, With or Without RT-PCR Confirmation

Chest CT CO-RADS*	No./Total No. (%)	RT-PCR Performed† Total No. (%)	No./ Total No. (%)	Positive No./ Total No. (%)	Negative No./ Total No. (%)	Inconclusive No./ Total No. (%)	COVID-19 Diagnosis‡ Total No. (%)
CO-RADS 1	325/392 (82.9)	136/325 (41.8)		2/136 (1.5)	133/136 (97.8)	1/136 (0.7)	2/325 (0.6)
CO-RADS 2	25/392 (6.4)	20/25 (80.0)		1/20 (5.0)	19/20 (95.0)	0/0 (0.0)	1/25 (4.0)
CO-RADS 3	25/392 (6.4)	22/25 (88.0)		3/25 (13.6)	19/25 (86.4)	0/0 (0.0)	4/25 (16.0)
CO-RADS 4	7/392 (1.6)	7/7 (100.0)		3/7 (42.9)	4/7 (57.1)	0/0 (0.0)	3/7 (42.9)
CO-RADS 5	10/392 (2.6)	10/10 (100.0)		5/10 (50.0)	4/10 (40.0)	1/1 (10.0)	8/10 (80.0)

\*Positive chest CT result was defined as a CO-RADS 4-5.

†Performed at the emergency department or within 24 hours after presentation at the emergency department.

‡Definitive COVID-19 diagnosis based on combined CT chest-abdomen, history taking, and physical examination; with or without RT-PCR confirmation. CT indicates computed tomography; RT-PCR, reverse-transcriptase polymerase chain reaction.

were diagnosed with COVID-19, presented without any respiratory symptoms.

### Relationship With Community Prevalence

To assess the relationship between the yield of combined chest-abdomen CT (CO-RADS 4-5) and COVID-19 community prevalence in the Netherlands, the cohort of patients studied was stratified according to their date of diagnosis and province of residence. Aggregating the data in a sliding window of 7 days, the combined positive yield was plotted against the mean number of daily COVID-19 admissions per 100,000 inhabitants within the same time period in their respective province (Fig. 2 and Table S1, <http://links.lww.com/SLA/C812>). There was no discernible correlation between the yield of high COVID-19 suspicion based on chest-abdomen CT and community prevalence of COVID-19.

## DISCUSSION

This study has evaluated the yield of standardized addition of chest CT to abdominal CT for COVID-19 suspicion in patients presenting with primarily acute nontraumatic gastrointestinal symptoms requiring abdominal imaging. The number of chest CT scans suspicious for COVID-19 was 17 (4.3%), of which 11 were diagnosed with COVID-19. Five of the 11 patients with CO-RADS 4-5 and COVID-19 diagnosis presented without any respiratory symptoms.

Hossain et al investigated the number of COVID-19 diagnoses based on unexpected findings in the included lung zones at CT abdomen/pelvis or cervical spine/neck in patients with non-respiratory symptoms presenting at the emergency department.<sup>16</sup> Out of 2815 included patients, 299 (10.6%) had positive CT lung base/apical findings suggesting COVID-19 pneumonia. All 299 patients underwent RT-PCR testing, of which 44 (14.7%) tested

positive for SARS-CoV-2. Siegel et al reported 3 patients presenting at the emergency department with abdominal pain, without respiratory symptoms suggesting COVID-19, who underwent abdominal CT and in whom the radiologist was the first to suggest COVID-19 infection because of findings in the lung bases.<sup>17</sup> The authors concluded that COVID-19 may present primarily with abdominal symptoms, and that lung base findings on abdominal CT can provide the first signs of a possible SARS-CoV-2 infection.

One other study investigated the yield of adding routine chest CT to abdominal CT to identify COVID-19 in emergency general surgical admissions.<sup>18</sup> In a research letter, the authors report a total of 212 patients, identifying 12 (5.6%) patients as radiologically suspected for COVID-19, which is in line with our results (4.3%). The reported sensitivity was 60.0%. Overall, the authors concluded that standard inclusion of chest CT, together with abdominal CT, did not contribute to the identification of COVID-19 in emergency general surgical admissions. However, they did not describe the clinical presentation of patients in the emergency department. Therefore, it is unknown how many patients also had pulmonary symptoms, which would initiate diagnostic work-up for COVID-19 independent of the clinical workup for their abdominal complaints. Additionally, the authors did not provide information on RT-PCR results, which are essential to confirm COVID-19 diagnoses.

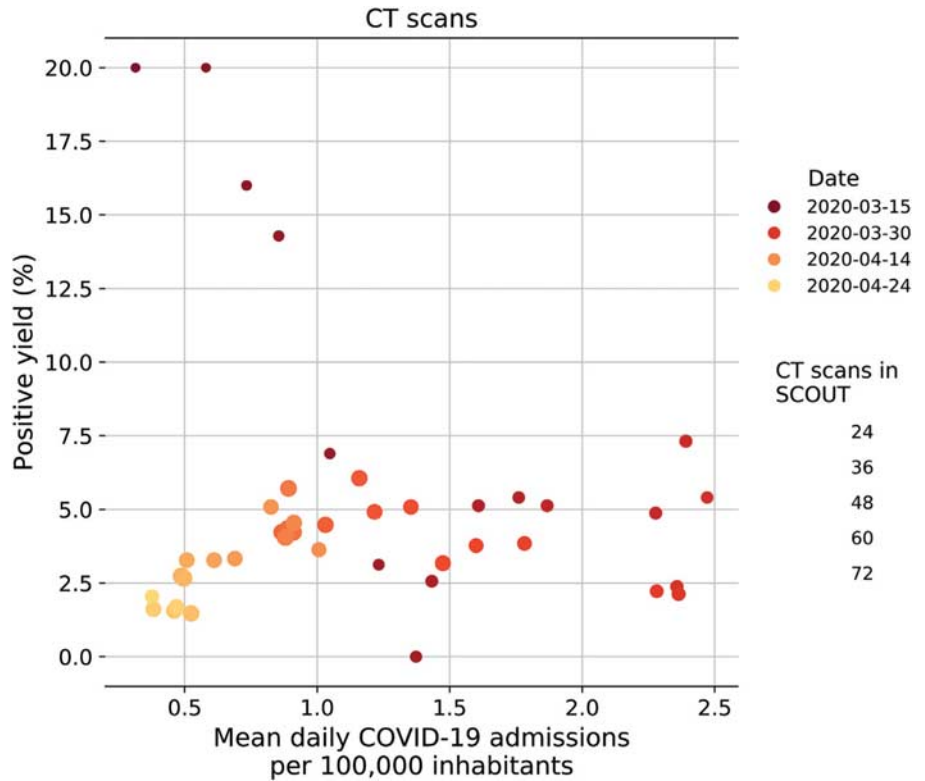
RT-PCR is the reference standard to establish a SARS-CoV-2 infection.<sup>19</sup> However, although being highly specific, sensitivity is considered to be moderate.<sup>20-22</sup> Therefore, several studies have suggested addition of chest CT to RT-PCR, in patients suspected of COVID-19 to ensure an accurate diagnosis.<sup>23,24</sup> A recent study investigated the added value of chest CT in suspected COVID-19 patients.<sup>25</sup> The primary outcome was the proportion of patients with an initially negative RT-PCR, who had a positive chest CT result (CO-RADS 4-5). In 38

**TABLE 3.** CO-RADS Classification in 392 Patients Presenting With Acute Gastrointestinal Symptoms, Stratified According to the Presence Of Typical COVID-19 Respiratory Symptoms

Clinical symptoms, no./total no. (%)*	Total:	CO-RADS 1-2	CO-RADS 3	CO-RADS 4-5	P-value
Cough	38/360 (10.6)	30/318 (9.4)	3/25 (12.0)	5/17 (29.4)	0.032†
Dyspnea	40/352 (11.4)	35/310 (11.3)	3/25 (12.0)	2/17 (11.8)	0.993
Fever (> 38.0)	103/361 (28.5)	85/320 (26.6)	6/24 (25.0)	12/17 (70.6)	<0.001†
Cold-like symptoms	18/265 (6.8)	13/230 (5.7)	3/20 (15.0)	2/15 (13.3)	0.164
Malaise	99/295 (33.6)	86/260 (33.1)	5/21 (23.8)	8/14 (57.1)	0.110
Exposure to COVID-19, no./total no. (%)					
Travelled to a foreign country within past 14 d	0/204 (0.0)	0/177 (0.0)	0/15 (0.0)	0/12 (0.0)	—
Contact with a known COVID-19 patient	3/207 (1.4)	1/181	1/15 (6.7)	1/11 (9.1)	0.015†

\*Clinical symptom presented if at least 75% of all included patients were questioned for this symptom during emergency presentation.

†Significant difference.



**FIGURE 2.** Scatter plot of positive COVID-19 yield based on combined CT chest-abdomen screening (CO-RADS 4-5) against community prevalence, measured by the mean daily COVID-19 related hospital admissions per 100,000 inhabitants. Each dot plots the positive yield of CT chest-abdomen screening within a sliding window of seven days against community prevalence during the same time in the respective province of residence as the patients who were tested. Points are colored by the date of the 1st day of the seven-day time period and sized by the number of CT screenings performed within each period.

out of 127 (29.9%) patients with a negative or intermediate RT-PCR, chest CT showed a high suspicion for COVID-19. Thirty-one (81.6%) of those patients were diagnosed with COVID-19 after repeated RT-PCR testing or clinical follow-up. In line with these findings, we found a discrepancy between percentage of COVID-19 suspicion based on chest CT (4.3%) and RT-PCR confirmed SARS-CoV-2 infections (2.0%). However, our patient group was not suspected of COVID-19.

In a previous study, we evaluated the yield of preoperative screening for COVID-19 with the use of chest CT and RT-PCR in patients without COVID-19 symptoms.<sup>26</sup> We found that screening with RT-PCR detected SARS-CoV-2 in at least 1 in every 100 asymptomatic patients before elective or emergency surgery. The yield increased up to 6% when the daily COVID-19 daily hospital admissions rate exceeded 1.5 per 100,000 inhabitants and was therefore in conjunction with community prevalence of COVID-19. This study was performed during the same period as the current study. Hence, the percentage of COVID-19 patients without respiratory symptoms in the general population was around 6% in our study period. The yield of chest CT in the current study did not increase with community prevalence and did not correlate with the percentage of asymptomatic SARS-CoV-2 positive patients in the general population.

Previous studies found that around 20% of COVID-19 patients present with gastrointestinal symptoms next to respiratory symptoms. Moreover, around 5% to 16% of patients might present with gastrointestinal symptoms only, without any respiratory complaints.<sup>9,10</sup> In our study, significantly more patients with high suspicion of COVID-19 based on chest CT presented with a cough or fever, identified after careful history taking and physical examination. Only 5 patients with CO-RADS 4-5 and who were diagnosed with COVID-19 presented without any respiratory symptoms.

Our study has limitations. First, patients were included retrospectively. The clinical symptoms at presentation were not assessed using a standardized questionnaire. Therefore, some patients with primarily respiratory symptoms or without evident gastrointestinal symptoms might have been unknowingly included. Second, we found that the yield of suspected COVID-19 based on additional CT chest did not correlate with COVID-19 community prevalence. One might have expected that the number of patients with suspected COVID-19 based on chest CT would have increased with higher community prevalence of COVID-19. It is possible that selection bias could have influenced the yield of chest CT. Physicians were more aware of possible SARS-CoV-2 infection as the general COVID-19 knowledge and community prevalence increased in the Netherlands. Therefore, the number of patients who were primarily suspected for COVID-19, with or without respiratory symptoms, during presentation at the emergency department could have been higher in our study period. Hence, yield of the chest CT could have been higher if all patients with solely gastrointestinal symptoms would have been included in this study. Third, 197 (52.5%) patients with CO-RADS 1-3 did not undergo RT-PCR testing. Therefore, it is unknown in how many of these patients without suspicion for COVID-19 based on chest CT findings, acute gastrointestinal symptoms could have been caused by a SARS-CoV-2 infection.

In conclusion, the yield of adding chest CT to abdominal CT to detect COVID-19 in patients presenting with acute gastrointestinal symptoms is extremely low with an additional detection rate of around 1%.

**REFERENCES**

1. Velavan TP, Meyer CG. The COVID-19 epidemic. *Trop Med Int Health.* 2020;25:278–280.

Downloaded from http://journals.lww.com/annalsofsurgery by BHDMS5P5Hkx1Z5Eoum11QIN44+KJLHEZG5siH0oXMI10iC0yWCX1AWNyQpI10iH1D313D00R8RyT7VSFF14C8V1C1YabogZGXdgj2MwZLel= on 10/24/2023

2. Guan W, Ni Z, Hu Y, et al. Clinical characteristics of Coronavirus disease 2019 in China. *N Engl J Med*. 2020;382:1708–1720.
3. Li YC, Bai WZ, Hashikawa T. The neuroinvasive potential of SARS-CoV2 may play a role in the respiratory failure of COVID-19 patients. *J Med Virol*. 2020;92:552–555.
4. Sippola S, Grönroos J, Sallinen V, et al. A randomised placebo-controlled double-blind multicentre trial comparing antibiotic therapy with placebo in the treatment of uncomplicated acute appendicitis: APPAC III trial study protocol. *BMJ Open*. 2018;8:e023623.
5. Chang Z, Mbbs L, Dipspmed M, et al. COVID-19 and elective surgery: 7 practical tips for a safe, successful and sustainable reboot. *Ann Surg*. 2020.
6. Saeed U, Sellevoll HB, Young VS, et al. Covid-19 may present with acute abdominal pain 107. *Br J Surg*. 2020;107:e186–e187. John Wiley and Sons Ltd.
7. Han C, Duan C, Zhang S, et al. Digestive Symptoms in COVID-19 Patients With Mild Disease Severity. *Am J Gastroenterol*. 2020;115:916–923.
8. Gu J, Han B, Wang J. COVID-19: gastrointestinal manifestations and potential fecal–oral transmission. *Gastroenterology*. 2020;158:1518–1519. W. B. Saunders.
9. Pan L, Mu M, Yang P, et al. Clinical characteristics of COVID-19 patients with digestive symptoms in Hubei, China. *Am J Gastroenterol*. 2020;115:1.
10. Luo S, Zhang X, Xu H. Don't Overlook digestive symptoms in patients with 2019 novel Coronavirus disease (COVID-19). *Clin Gastroenterol Hepatol*. 2020;18:1636–1637.
11. Gans S, Pols M, Stoker J, et al. Richtlijn 'Diagnostiek acute buikpijn bij volwassenen. *NTVG*. 2014. Available at: <https://www.ntvg.nl/system/files/publications/a7494.pdf>. Accessed August 14, 2020.
12. Laméris W, Van Randen A, Wouter Van EsH, et al. Imaging strategies for detection of urgent conditions in patients with acute abdominal pain: diagnostic accuracy study. *BMJ*. 2009;339:29–33.
13. Prokop M, van Everdingen W, van Rees Vellinga T, et al. CO-RADS - a categorical CT assessment scheme for patients with suspected COVID-19: definition and evaluation. *Radiology*. 2020;296:E97–E104.
14. Rijksinstituut voor Volksgezondheid en Milieu | RIVM. Available at: <https://www.rivm.nl/>. Accessed July 31, 2020.
15. StatLine. Available at: <https://opendata.cbs.nl/#/CBS/nl/>. Accessed July 31, 2020.
16. Hossain R, Lazarus MS, Roudenko A, et al. CT Scans obtained for nonpulmonary indications: associated respiratory findings of COVID-19. *Radiology*. 2020;296:E173–E179.
17. Siegel A, Chang PJ, Jarou ZJ, et al. Lung base findings of coronavirus disease (COVID-19) on abdominal CT in patients with predominant gastrointestinal symptoms. *Am J Roentgenol*. 2020;215:607–609.
18. Brennan C, Morrissey B, Dubois-Marshall S, et al. COVID-19: no benefit of chest inclusion in acute abdomen CT. *Br J Surg*. 2020;107:e474–e475.
19. Cheng MP, Papenburg J, Desjardins M, et al. Diagnostic testing for severe acute respiratory syndrome-related Coronavirus 2: a narrative review. *Ann Int Med*. 2020;172:726–734.
20. Wang W, Xu Y, Gao R, et al. Detection of SARS-CoV-2 in Different Types of Clinical Specimens. *JAMA*. 2020;323:1843–1844.
21. Xie X, Zhong Z, Zhao W, et al. Chest CT for typical coronavirus disease 2019 (COVID-19) pneumonia: relationship to negative RT-PCR testing. *Radiology*. 2020;296:E41–E45.
22. Long C, Xu H, Shen Q, et al. Diagnosis of the Coronavirus disease (COVID-19): rRT-PCR or CT? *Eur J Radiol*. 2020;126:108961.
23. Rubin GD, Ryerson CJ, Haramati LB, et al. The role of chest imaging in patient management during the COVID-19 pandemic: a multinational consensus statement from the fleischner society. *Chest*. 2020;296:172–180.
24. Ai T, Yang Z, Hou H, et al. Correlation of chest CT and RT-PCR testing for Coronavirus disease 2019 (COVID-19) in China: a report of 1014 cases. *Radiology*. 2020;296:E32–E40.
25. Korevaar DA, Kootte RS, Smits LP, et al. Added value of chest CT in suspected COVID-19: an analysis of 239 patients. *Eur Respir J*. 2020;56:2001377.
26. Puylaert CAJ, Scheijmans JCG, Borgstein ABJ, et al. Yield of screening for COVID-19 in asymptomatic patients prior to elective or emergency surgery using chest CT and RT-PCR (SCOUT). *Ann Surg*. 2020;272:919–924.