Maastricht University

Diagnostic and therapeutic aspects of inversion trauma of the ankle joint

Citation for published version (APA):

van Moppes, F. I., & van den Hoogenband, C. R. (1982). *Diagnostic and therapeutic aspects of inversion trauma of the ankle joint*. [Doctoral Thesis, Maastricht University]. Rijksuniversiteit Limburg.

Document status and date:
Published: 01/01/1982

Document Version:
Publisher's PDF, also known as Version of record

Please check the document version of this publication:

• A submitted manuscript is the version of the article upon submission and before peer-review. There can be important differences between the submitted version and the official published version of record. People interested in the research are advised to contact the author for the final version of the publication, or visit the DOI to the publisher's website.
• The final author version and the galley proof are versions of the publication after peer review.
• The final published version features the final layout of the paper including the volume, issue and page numbers.

Link to publication

General rights
Copyright and moral rights for the publications made accessible in the public portal are retained by the authors and/or other copyright owners and it is a condition of accessing publications that users recognise and abide by the legal requirements associated with these rights.

• Users may download and print one copy of any publication from the public portal for the purpose of private study or research.
• You may not further distribute the material or use it for any profit-making activity or commercial gain
• You may freely distribute the URL identifying the publication in the public portal.

If the publication is distributed under the terms of Article 25fa of the Dutch Copyright Act, indicated by the “Taverne” license above, please follow below link for the End User Agreement:

www.umlib.nl/taverne-license

Take down policy
If you believe that this document breaches copyright please contact us at:

repository@maastrichtuniversity.nl

providing details and we will investigate your claim.

Download date: 23 Apr. 2024

Diagnostic and therapeutic aspects of inversion trauma of the ankle joint

Proefschrift

Ter verkrijging van de graad van doctor in de geneeskunde aan de Rijksuniversiteit Limburg te Maastricht, op gezag van de rector magnificus Prof. Dr. H.C. Hemker volgens besluit van het College van Dekanen in het openbaar te verdedigen in de aula van de universiteit op 15 januari 1982 des namiddags te drie uur.

door

Floris Isaac van Moppes
geboren te Amsterdam

en

Cornelis Reindert van den Hoogenband
geboren te Bandung (Indonesia)

Promotor:	Prof. Dr. J.M. Greep
Referenten: F.I. van Moppes	Prof. Dr. J. Drukker Dr. H. Sanches
Referenten: C.R. van den Hoogenband	Prof. Dr. J. Drukker Prof. Dr. C. Burri Dr. W.H. van der Slikke

'Fleiri hljóta að geta sagt frá samskonar reynslu: allt í einu er framandi land komið inn í tilveru okkar. Hálfringluð verðum við þess áskynja eftir nokkra hrið að þetta land skiptir ae meira máli í vitund okkar. Það er orðið annað föðurland okkar.'

Bent A. Koch

'It is worse to sprain an ankle,
than to break it' (Watson-Jones)
But no longer!

To Gabi, David and Ruben
To my mother
To the memory of my father

To Astrid, Pieter and Veronique
To my mother
To the memory of my father

Contents

Part 1
C.R. van den Hoogenband
F.I. van Moppes

1. Introduction and outline of study 1
   - 1.1. Introduction 1
   - 1.2. Outline of study 2
     - 1.2.1. Anatomical aspects of the ankle joint 2
     - 1.2.2. Stress examination of the ankle joint 2
     - 1.2.3. Arthrography 2
     - 1.2.4. Unusual aspects of ankle arthrography 2
     - 1.2.5. Clinical diagnostic aspects of inversion trauma of the ankle 2
     - 1.2.6. Treatment of lateral ankle ligament lesions 3
     - 1.2.7. Final remarks 3

2. Anatomy of the ankle joint 3
   - 2.1. Introduction 3
   - 2.2. Literature 3
   - 2.3. Pilot cadaver study 7
     - 2.3.1. – method and material 7
     - 2.3.2. – results 7
     - 2.3.3. – discussion 13
   - 2.4. Functional anatomy – literature 13

Part 2
Diagnostic aspects of ankle arthrography and stress examination
F.I. van Moppes

3. Stress examination of the ankle following inversion trauma 17
   - 3.1. Introduction 17
   - 3.2. Literature 17
     - 3.2.1. Inversion stress examination 17
       - 3.2.1.1. Use of anaesthesia 17
       - 3.2.1.2. Examination technique 18
       - 3.2.1.3. Measurement technique 19
       - 3.2.1.4. Normal values 19
     - 3.2.2. Anterior drawer sign 19
       - 3.2.2.1. Use of anaesthesia 19
       - 3.2.2.2. Examination technique 19
       - 3.2.2.3. Measurement technique 20
       - 3.2.2.4. Normal values 21
   - 3.3. Results of a preliminary study on stress examination 21
     - 3.3.1. Introduction 21
     - 3.3.2. Methods and materials 21
     - 3.3.3. Results 22
   - 3.4. Discussion 23

4. Ankle arthrography – technique, interpretation and complications
4.1. Introduction 24
4.2. Technique 24
4.3. Interpretation of ankle arthrography – review of literature 25
4.3.1. Introduction 25
4.3.2. Normal arthrogram 25
4.3.3. Abnormal arthrogram 26
4.4. Complications of ankle arthrography 28
4.4.1. Introduction 28
4.4.2. Case-history 28
4.4.3. Discussion 28
4.4.4. Summary 29

5. Arthrographic differential diagnosis of rupture of the anterior talofibular ligament, the joint capsule and the anterior tibiofibular ligament
5.1. Introduction 29
5.2. Review of literature 30
5.3. Important anatomic structures 30
5.4. Methods and materials 32
5.5. Results 33
5.5.1. Cadaver study 33
5.5.2. Cadaver arthrogram study 33
5.5.3. Evaluation of arthrograms on patients 34
5.6. Discussion 38
5.7. Conclusions 39

6. The significance of filling of tendon sheaths and talotarsal joints in ankle arthrography
6.1. Introduction 40
6.2. Review of literature 40
6.3. Important anatomic structures 41
6.4. Methods and materials 41
6.5. Results 41
6.6. Discussion 43
6.7. Conclusions 46

7. Arthrography, talar tilt and surgical findings after inversion trauma of the ankle – general evaluation
7.1. Introduction 46
7.2. Methods and materials 47
7.2.1. Prospective study 47
7.2.2. Retrospective study 47
7.2.3. General study 47
7.3. Results 48
7.3.1. Results of prospective study 48
7.3.2. Results of retrospective study 50
7.3.3. Results of general study 50
7.4. Discussion and general evaluation 54
7.5. Conclusions 59

8. Unusual aspects of ankle arthrography
8.1. Introduction 59
8.2. Venous filling in ankle arthrography 59
8.3. Lymphatic filling in ankle arthrography 60
8.3.1. Introduction 60
8.3.2. Discussion 60
8.4. Less common indications for ankle arthrography 62

9. Adhesive capsulitis of the ankle (frozen ankle)
9.1. Introduction 63
9.2. Methods and materials 64
9.3. Results 65
9.4. Discussion 67
9.5. Conclusions 70

10. Summary (part 2) 71

Part 3
C.R. van den Hoogenband

11. Inversion trauma of the ankle joint – diagnostic features
11.1. Review of literature 73
11.1.1. Clinical diagnosis, history and clinical examination 73
11.1.2. Radiological stress examination 75
11.1.3. Ankle arthrography 75
11.1.4. Conclusions 75
11.2. Diagnostic study 76
11.2.1. Methods and materials 76
11.2.2. Evaluation of clinical diagnosis 77
11.2.2.1. History 77
11.2.2.2. Physical examination 79
11.2.2.3. Clinical stress examination 80
11.2.3. Evaluation of radiological stress examination (summary) 82
11.2.4. Evaluation of arthrography (summary) 83
11.2.5. Conclusions 84

12. Treatment of lateral ankle ligament injuries
12.1. Review of literature 84
12.1.1. Introduction 84
12.1.2. Results of conservative treatment 85
12.1.3. Results of surgical treatment 86
12.1.4. Comparative studies of conservative and surgical therapy 90
12.1.5. Experimental studies 99
12.2. Methods and materials 100
12.3. Results 102
12.3.1. Operative findings 102
12.3.2. Therapeutic results 104
12.4. Discussion 116

13. Summary (Part 3) 119

Part 4
F.I. van Moppes
C.R. van den Hoogenband

14. Final remarks and summary 121

15. – Samenvatting 124
– Instruction for the application of a Coumans ankle bandage in the treatment of lateral ligament injuries 127
– Short exercise programme after bandage applications 147
– List of permissions 150
– References 151
– Acknowledgements 165
– Curriculum Vitae 167

Part 1

C.R. van den Hoogenband
F.I. van Moppes

1. Introduction and outline of study

1.1. Introduction

An ankle injury forces many otherwise fit patients to visit hospital and the epidemiology of ankle sprains is impressive. Ankle injury with or without fracture or ligamentous rupture is most common among non-professional sportsmen. Underestimating the injury may have serious consequences and a weak, unstable or stiff joint is undesirable for any person, but could be a disaster for sportsmen. Although prevention is extremely important, diagnosis, treatment and rehabilitation with the ultimate goal of restoration of normal ankle function of this common and incapacitating injury remains mandatory. The first part of this study presents anatomical aspects of the connective tissue apparatus of the ankle, the second part deals with radiodiagnostic aspects of lateral ankle ligament injuries, while in the third part clinical diagnostic aspects and the treatment of lateral ankle ligament injuries are discussed.

It is the radiologists' task to gather in the shortest time, with minimum discomfort to the patient and at minimum cost, as much information as possible about the extent of the damage. In addition to the clinical information, this should provide the surgeon with the basis of treatment. Up to now, ankle arthrography and stress examinations have been the principal diagnostic tools. In 1978 a clinical trial of various treatments of ankle ligament injuries was started in Maastricht. On the assumption that a particular treatment should be based on an exact knowledge of the nature of a ligamentous injury, the trial demanded an exact diagnosis by whatever methods available. A study of the vast amount of literature related to anatomy, diagnosis and treatment of ankle ligament injury showed that many questions remained unanswered and it was therefore essential to re-examine the grey and disputed areas within present knowledge.

Prior to 1978 in Maastricht, patients with lateral ligament injuries assessed by clinical examination, plain X-rays and X-ray inversion stress examination, were treated by plaster cast for six weeks, often followed by rehabilitation under the direction of the physiotherapy department. In severe cases (i.e. clear instability of the ankle joint) operation was performed to obtain anatomical and functional repair of the injured ligaments. As after-treatment, a plaster cast was applied, followed by physiotherapy. Per year 1000 to 1200 patients with fresh inversion injuries of the ankle were observed in the casualty department. 15 to 20% of all patients were treated as described above, because of a suspected lateral ligament lesion. Over the years it was felt that the routine treatment was unsatisfactory from the point of view of both patient and surgeon, and a simpler and more effective method of treating this kind of injury was sought, to improve both short and long term results.

Since 1945, Mr. P.F. Coumans, working as a surgical dresser in Kerkrade, has treated different types of ligamentous injury, with a combination of tape and elastic bandage, providing early mobilization. The success of his bandage therapy was well known to many Dutch sportsmen who consequently consulted him with several sportsinjuries. In the light of both Mr. Coumans' experience and descriptions in the

literature by Freeman (1967) and Broström (1965) of results in the treatment of lateral ligament injuries with a non-specific elastic bandage, it was considered worthwhile to compare the above mentioned three different types of treatment (surgical repair, plaster cast and Coumans-bandage) in a prospective clinical trial.

1.2. Outline of study

1.2.1. Anatomical aspects of the ankle joint

Chapter 2 presents the standard anatomical description of the ankle joint region as found in textbooks and other literature, followed by a pilot cadaver study of the particular relationships between anterior tibiofibular and talofibular ligaments, and the joint capsule. Chapter 5 is devoted to the arthrographic differential diagnosis of trauma to these ligaments in view of the results of the anatomical study. Particular attention is paid to the region of the calcaneofibular ligament and especially its relationship to the peroneus tendon sheath and joint capsule.
In subsequent chapters of parts 2 and 3, the anatomical information relevant to the subject under discussion is summarized. The results are also applied to the last part of chapter 2, concerning the description of the functional anatomy of the ankle joint.

1.2.2. Stress examination of the ankle joint

Chapter 3 discusses the technique and diagnostic value of such examinations. Particular mention is made of the types of anaesthesia used. Chapter 5 presents a cadaver study of the influence of the various anterolateral structures on the results of inversion stress examination. Chapter 7 compares the relative diagnostic values of stress examination and ankle arthrography.

1.2.3. Arthrography

Chapter 4 presents arthrographic techniques and complications and reviews the literature with regard to interpretation and criteria of normality.
The following controversial areas are selected for further study:
1.
Differential diagnosis of rupture of anterior tibiofibular and talofibular ligaments, and joint capsule (chapter 5).
2.
Significance of arthrographic contrast filling of tendon sheaths and talotarsal joints (chapter 6).
3.
Relative diagnostic value of arthrography and stress examination in relation to surgical findings (chapter 7).

1.2.4. Unusual aspects of ankle arthrography

Chapter 8 presents some unusual aspects of ankle arthrography including the filling of lymphatic vessels and venules, and discusses the significance of such features. Rare indications for ankle arthrography are also discussed, and in chapter 9 one particular such indication, namely the frozen ankle syndrome, is dealt with, together with a study of intra-articular ankle joint pressure measurement.

1.2.5. Clinical diagnostic aspects of inversion trauma of the ankle

Part 3 begins in chapter 11, with a review of the literature concerning the clinical

diagnosis of lateral ligament lesions, and continues with an evaluation of the results of a clinical diagnostic examination in a series of 150 patients, submitted to the trial to compare various treatments of lateral ligament lesions.

1.2.6. Treatment of lateral ankle ligament lesions

Chapter 12 begins with a review of the literature concerning the treatment of lateral ankle ligament lesions and also presents the results of a comparative prospective randomized study of 150 patients treated with surgical repair of the ligaments, plaster cast immobilization or early mobilization with a Coumans-bandage.

1.2.7. Final remarks

Part 4 begins with a summary of the important results of this thesis, followed by final remarks on their practical implications, and concludes with detailed instructions, for both the application of the Coumans-bandage and the accompanying exercise programme.

2. Anatomy of the ankle joint

2.1. Introduction

This chapter deals primarily with a pilot study of anatomical aspects of the ankle joint, in particular the tibiofibular syndesmosis and the anterolateral region of the joint. Though not always clearly described in literature, these regions are particularly important because of their close relationship and frequent involvement in a variety of ankle joint trauma.

The first part of this chapter deals with the normal anatomy, as described in standard literature, of the main structures of interest to radiologists and surgeons, namely, the anterior tibiofibular and anterior talofibular ligaments, the joint capsule, the calcaneofibular ligament and the peroneus tendon sheath.

The second part of this chapter presents a cadaver study carried out to determine the interrelationships of these structures in greater detail.

In the third part the functional anatomy will be described.

2.2 Literature

The following anatomical description is based on textbooks by Anson (1953 and 1971), Campbell (1971), Gardner (1966), Gray (1981), Lanz and Wachsmuth (1972), Spalteholtz (1965), Töndury (1966) and papers by Broström (1964, 1965 A), Gerbert (1975), Gordon (1970), Prins (1978), Sanders (1977), Sósa (1975) en Tóth (1974).

The tibia and fibula are connected distally by the tibiofibular syndesmosis which firmly unites both tibial and fibular periostea and is formed by anterior and posterior tibiofibular ligaments. The anterior tibiofibular ligament is a strong triangular band extending obliquely downwards from the distal lateral border of the tibia, to the distal anterior border of the fibula. It has both deep and superficial fibres, the latter extending along the edge of the fibula, almost to the origin of the anterior talofibular ligament.

Anteriorly it is related to the peroneus tertius muscle (if present) and the fascia of the leg, and laterally it is continuous with the junction between periosteum and joint capsule. The transition zone between anterior and posterior tibiofibular ligaments is often called the interosseous ligament. Proximally, the tibiofibular syndesmosis is

continuous with the interosseous membrane of the leg. The posterior tibiofibular ligament follows a course, similar to its anterior counterpart, but on the posterior surfaces of tibia and fibula.

The ankle or talocrural joint, generally considered to be a hinge joint, is formed by the inferior and malleolar articular surfaces of the tibia, the malleolar articular surface of the fibula and the superior, medial and lateral articular surfaces of the talar trochlea. The articular surfaces show considerable individual variation. The tibia and fibula form the so-called ankle mortise, wider in front than behind, in which the talus moves. Three pairs of discongruous asymmetric saddlejoint-surfaces can be distinguished between tibiofibular mortise and talar trochlea.

First, the superior articular surface of the talar trochlea, wider anteriorly than posteriorly and convex in an anteroposterior direction, articulates with the inferior articular surface of the tibia. Medially, the nearly sagittally orientated articular surface on the lateral side of the medial malleolus corresponds to the medial articular surface of the talar trochlea. The articular surface on the medial side of the lateral malleolus has a main orientation in craniocaudal direction; in this direction it is convex, whereas in anteroposterior direction it is concave. This articular surface corresponds with the lateral surface on the talar trochlea, which consequently has a much larger surface area than the medial surface. The ankle joint cavity may connect with the subtalar joint and medial flexor tendon sheaths and also, according to some authors, with the peroneus tendon sheaths.

The bones of the ankle joint proper are connected by the joint capsule, reinforced laterally and medially by ligaments. The joint capsule comprises both synovial and fibrous membranes. There are synovial membrane recesses both anteriorly and posteriorly, dependent on the position of the foot. There is usually a tibiofibular recess which may extend proximally up to 2.5 cm. The fibrous capsule with its ligamentous reinforcements is continuous with the periostea of tibia, fibula and talus at the border between bone and articular cartilage.

Proximally the capsule is continuous with the periosteal margin of the anterior tibiofibular ligament. Distally it is continuous with the periosteum of the talus close to the margin of the trochlear articular surfaces, except anteriorly where it passes onto the non-articular portion of the talar neck, a few millimetres distal to the articular margin. Distolaterally the junctional zone is just inferior and anterior to the angle between the superior and lateral trochlear facets. Anteriorly the fibrous capsule is continuous with the fibrous portion of the extensor tendon sheaths and medially with those of the flexor tendon sheaths.

The capsule is reinforced medially by the deltoid ligament, laterally by the capsular anterior and posterior talofibular ligaments, and a third ligament (the calcaneofibular ligament) being described as extra-capsular.

The anterior talofibular ligament passes forwards and medially from the anterior margin of the lateral malleolus to the talus, anterior to the lateral facet of the trochlea. The posterior talofibular ligament is a strong thick band running, almost horizontally, from the lower part of the lateral malleolar fossa to the lateral tubercle of the posterior process of the talus and may be fan-shaped with a consequent variation in fibre tract length. The calcaneofibular ligament extends distally and slightly posteriorly from the anterior margin of the lateral surface of the malleolus to a tubercle on the middle of the lateral surface of the calcaneus, and bridges both talocrural and subtalar joints.

Caudolaterally it is related to the common peroneal tendon sheath. The collagen

fibres of this ligament radiate into the craniomedial wall of the tendon sheath.
The deep fascia of the leg is strengthened at the ankle by additional transverse fibres which form thickened bands covering the tendon sheaths of the flexor, extensor and peroneus muscles, called the flexor retinaculum, superior and inferior extensor retinacula and peroneus retinaculum, dorsomedially, anteriorly and dorsolaterally respectively.
The inferior extensor retinaculum divides anteromedially into proximal and distal bands (hence the alternative name 'cruciform ligament'), and caudolaterally it is continuous with the inferior peroneal retinaculum. The retinacula are continuous with and partly envelop the fibrous portions of the tendon sheaths and some fibres are in turn fixed to the periosteum, thus giving rise to the so-called 'osteotendinous channels'. Fat pads are interposed between joint capsule, tendon sheaths, retinacula and other fascial layers.

Vascular and nerve supply
The arterial supply to the ankle region is derived from branches of the anterior and posterior tibial arteries and peroneal artery. There is superficial and deep venous drainage into the great and small saphenous veins, the deep anterior and posterior tibial veins and the peroneal vein. The lymphatic vessels run parallel with the superficial and deep venous systems.
The cutaneous sensory nerve supply of the lateral malleolar region is derived from the sural, tibial and superficial peroneal nerves, whereas that of the joint capsule is derived from the sural, tibial, deep peroneal and saphenous nerves (note: this pattern of innervation has implications for local anaesthesia (Freeman 1967 A, B, Prins 1978)). The detailed innervation of the joint capsule is as follows: the saphenous nerve supplies part of the medial capsule, the sural nerve supplies a part of the posterior and anterolateral side of the capsule, the anterior area between these two regions being supplied by the deep peroneal nerve. The tibial nerve supplies the remainder of the posterior part of the capsule.

Index figures 1 - 8

1. Lateral malleolus
2. Tibia
3. Talar trochlea
4. Tarsal sinus
5. Posterior talocalcaneal joint (subtalar joint)
6. Talocrural joint
7. Anterior talofibular ligament
8. Calcaneofibular ligament
9. Fibres parallel to calcaneofibular ligament
10. Anterior tibiofibular ligament
11. Peroneus tendon sheath
12. Tendons of peroneus muscles
13. Tendons of extensor digitorum longus and extensor hallucis longus muscles
14. Extensor digitorum brevis and extensor hallucis brevis muscles
15. Distal part of inferior extensor retinaculum
16. Proximal part of inferior extensor retinaculum

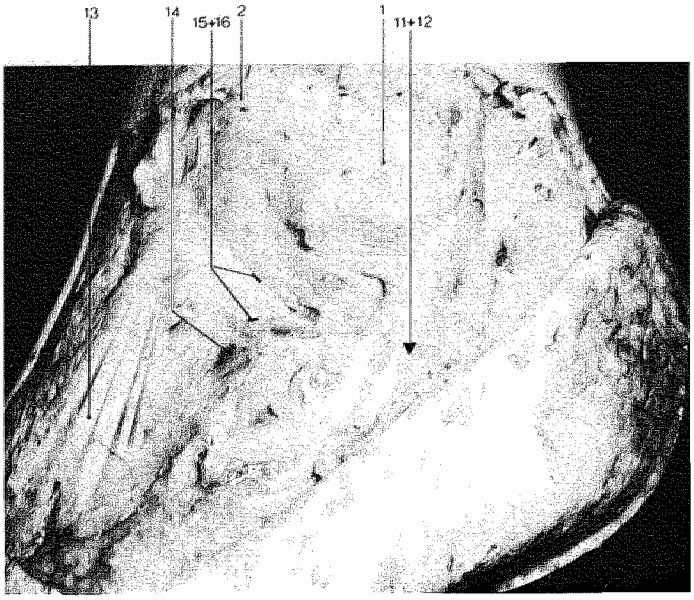

Figure 1

Lateral view of left ankle, after removal of skin and subcutaneous fat tissue, showing the superficial structures around the lateral malleolus.

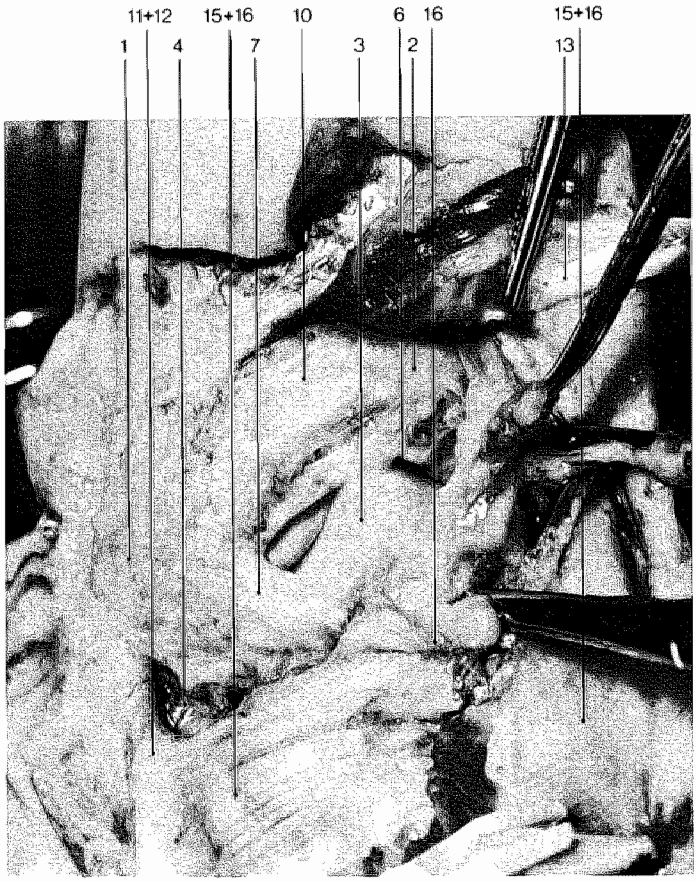

Figure 2

Oblique view of lateral aspect of right ankle, showing the relationships between anterior talofibular and anterior tibiofibular ligaments.
The superficial structures have been dissected and where necessary divided and reflected. Both fibre direction and lateral malleolar insertion of anterior talofibular (7) and anterior tibiofibular (10) ligaments are clearly seen. The capsule together with its other reinforcements derived from the proximal part of the extensor retinaculum have been removed.

2.3. Pilot cadaver study

2.3.1. Method and material

The anatomical relationships between joint capsule, anterior tibiofibular and talofibular ligaments, calcaneofibular ligament and peroneal tendon sheath were studied on ankles of twenty unfixed cadavers in which death had not been the result of trauma. The age at death varied between 50 and 80 years. Skin and subcutaneous tissues were removed (fig. 1). Further careful blunt dissection was then carried out, in particular, sparing the orientation of the connective tissue structures, to provide better understanding of their anatomical structure and relations.

2.3.2. Results

The joint cavity of the talocrural joint is enclosed by a capsule which is continuous with the adjoining periostea. The capsule is partly reinforced by collagenous fibre tracts. One of these tracts is named the anterior talofibular ligament. Another, named the anterior tibiofibular ligament, is situated alongside the anterocaudal margin of the tibia and assumes a labrum-like form. Both these ligaments are firmly inserted into the bone and periosteum of the mid-anterior surface of the lateral malleolus. There is no intermingling of fibres and the collagenous fibre tracts are more or less at right angles to each other (fig. 2). The tibiofibular ligament is invariably the strongest of the two, its superficial fibres extending further caudolaterally than its deep fibres. Careful dissection demarcates the reinforced parts of the capsule from the remainder, and it was found that there are reinforcing collagen tracts additional to the well known ligaments, particularly when the anterior talofibular ligament is small. These tracts have a more or less craniocaudal direction and are, in common with the anterior talofibular ligament, of varying thickness. In the dissection shown in figures 3 and 4, the non-reinforced parts of the capsule on the anterolateral side have been removed, leaving two spaces. The lateral space is bounded by the anterior talofibular and anterior tibiofibular ligaments and one other longitudinal reinforcing collagen band. This band, together with a further band, more medially, forms the boundaries of the second space. The first space is easily produced accidently during dissection of the anterior talofibular ligament by rupture of the capsule along the distal margin of the anterior tibiofibular ligament.

The other reinforcing capsular tracts are integral with fibrous parts of tendon sheaths and fibre tracts of the retinacula, to the extent that dissection of the tendon sheaths and retinacula sometimes inevitably opens the joint capsule, with the consequence that separation of these capsular reinforcements is mostly artefactual. In some specimens, the anterior talofibular ligament is of such a thickness, that it continues far medially. No other reinforcement is then found (fig. 5).

Careful dissection, from the anterior talofibular ligament towards the peroneus tendon sheath, shows the capsule with its reinforcements to be continuous with the peroneus tendon sheath (fig. 6).

By opening the peroneus tendon sheath directly distal to the lateral malleolus and removing the anterolateral wall of the sheath over a distance of about 2 cm, the peroneus tendons were displayed. These were then removed in order to study the anatomical features of the posteromedial part of the peroneus tendon sheath. The calcaneofibular fibres are found to be continuous with the fibrous tissue, producing the osseotendinous tract, called the peroneus tendon sheath. A remarkable finding is the existence of fibres parallel to the classical calcaneofibular ligament which, together with the ligament, form a continuous structure inseparable from the

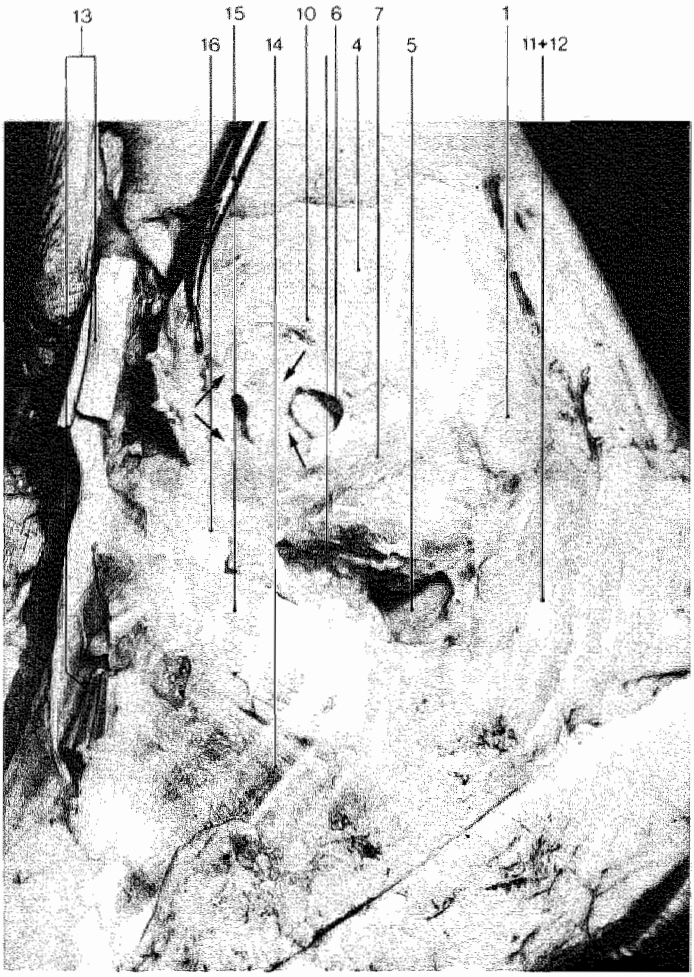

Figure 3

Oblique view of lateral aspect of left ankle, showing the relationships between reinforced and non-reinforced parts of the capsule.
Two well defined but non-reinforced parts of the capsule have been removed, the first bordered by anterior talofibular (7) and tibiofibular ligaments (10) and a further capsular reinforcement (arrows) derived from the proximal part of the inferior extensor retinaculum (16) and the second, bordered by the capsular reinforcement already mentioned (arrows) and by a second capsular reinforcements (arrow heads) also derived from the inferior extensor retinaculum. The subtalar joint (5) has been opened by removing its non-reinforced capsular part.

surrounding fibrous tissue or joint capsule by even the most careful dissection (figs. 7 and 8).
In summary, careful dissection demonstrates a continuum of collagenous tissue in the ankle joint region, comprising a coherent system of retinacula and tendon sheaths continuous with joint capsule and periosteum.
In all prepared cadaver ankles, special attention was paid to the angle between the vertical axis of the fibula and the direction of the calcaneofibular fibres. It was estimated that this angle varied between 100 to 140° in different subjects, as schematically shown in figure 9.
There was similar variation in the thickness of the fibre tracts. In several specimens with an intact calcaneofibular ligament, the ankle joint was stressed by an increasing inversion movement, causing increasing tension in the calcaneofibular fibres. Progressive division of these fibres increased the movement, which was seen to consist of both talar and subtalar joint components.

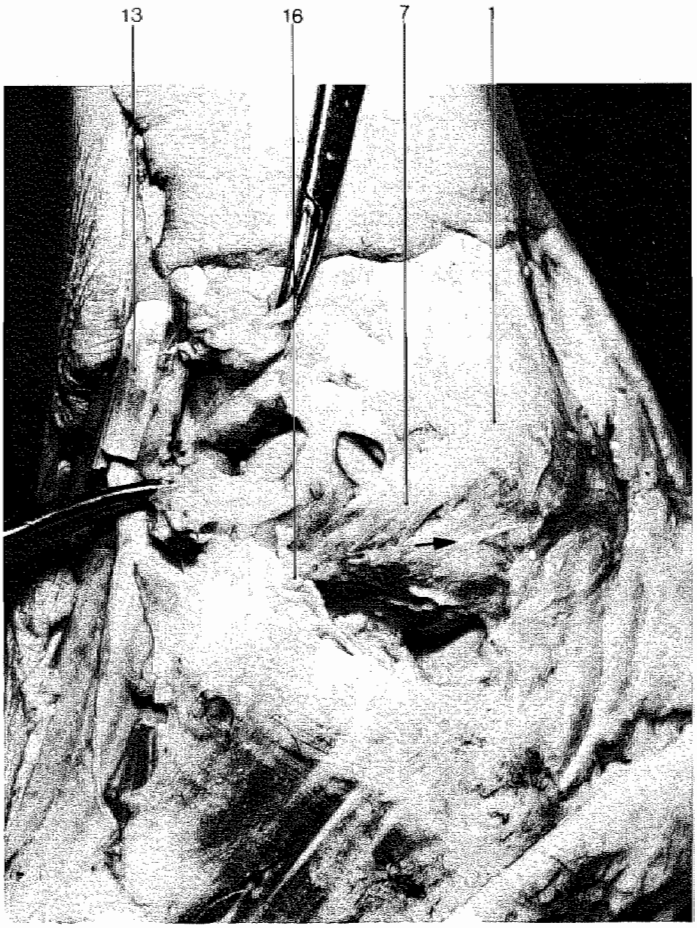

Figure 4

Further dissection of the same ankle as shown in figure 3. The most medial defect has been further extended medially by removing the medial reinforced capsular band.
Note the non-reinforced area in the anterior talofibular ligament (arrow head).

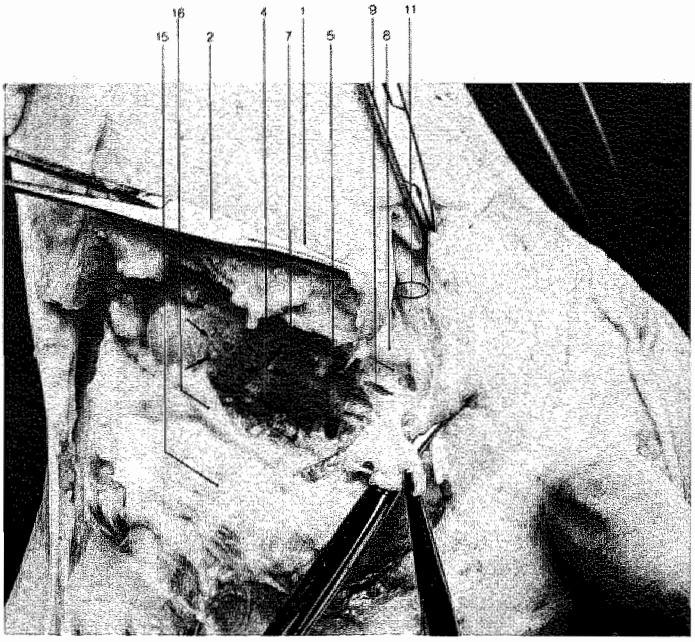

Figure 5

Oblique lateral view of left ankle, showing relationships between anterior talofibular ligament, calcaneofibular ligament, peroneus tendon sheath and joint capsule. Superficial structures together with fatbody have been dissected and removed. Unusually broad and thick anterior talofibular ligament (7) (compare figures 2, 3 and 4), with a clear transition between reinforced and non-reinforced parts of the capsule (arrows). No other reinforcements were present in this specimen. The peroneus tendon sheath (11) has been opened and the various radiating fibre tracts making up the calcaneofibular ligament are shown (4). In this case a weak spot in the centre of the anterior talofibular ligament is present (arrow head). The posterior talocalcaneal joint has been opened (5).

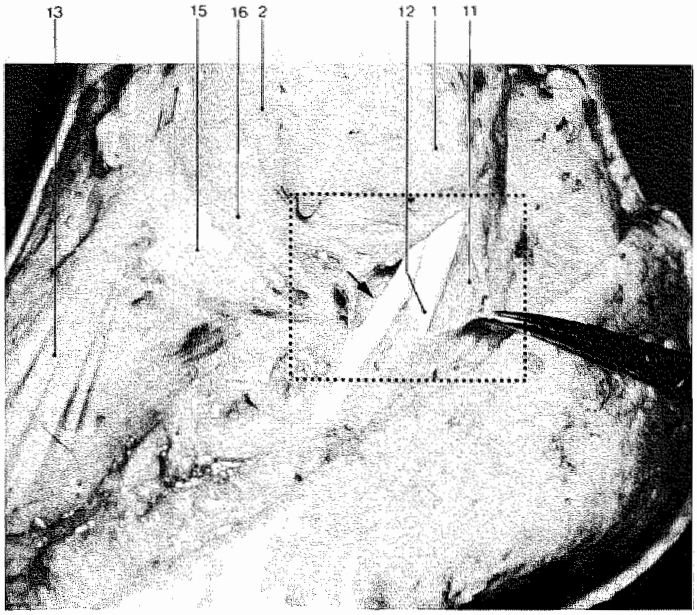

Figure 6

Lateral view of left ankle.
The peroneus tendon sheath is opened, showing the long and short peroneal tendons (arrow).

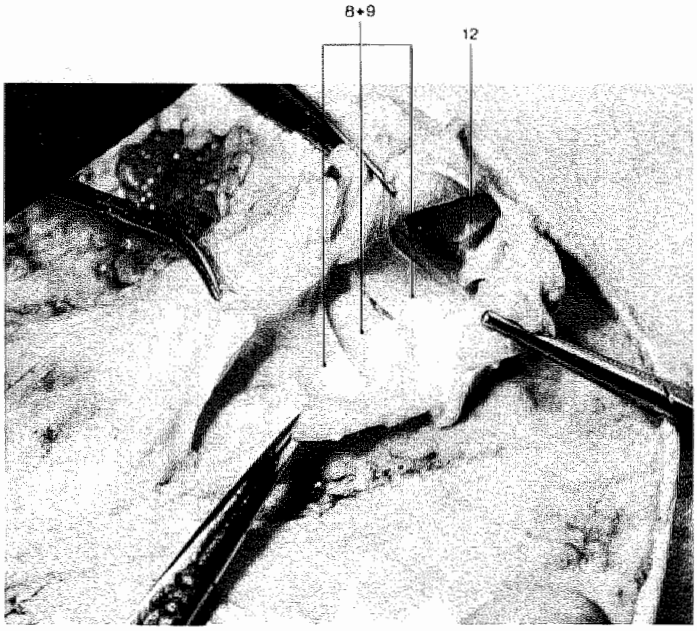

Figure 7

Lateral view of left ankle, detail of figure 6.
The peroneal tendons are removed, showing several ligamentous structures as part of the posterior side of the peroneus tendon sheath. In this case an isolated calcaneofibular ligament can not be distinguished from other ligamentous structures.

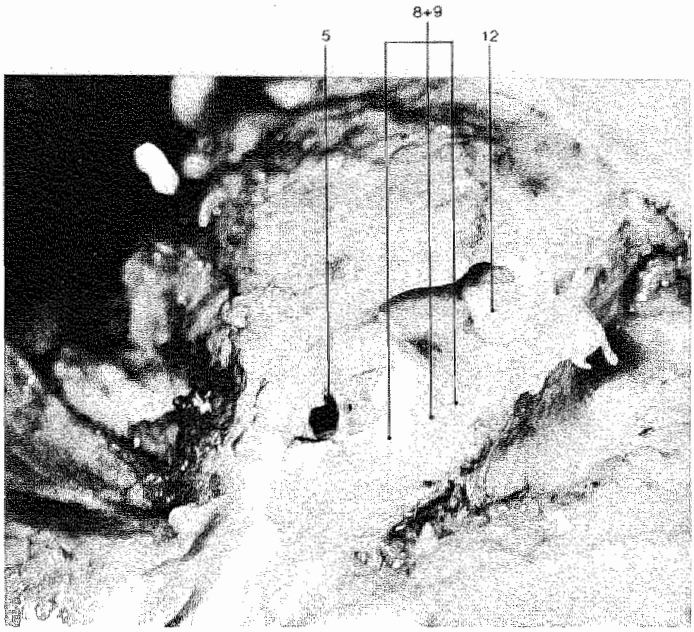

Figure 8

View of left ankle, same detail as figure 7.
By careful division of the calcaneofibular fibres, the subtalar joint cavity is directly opened, showing a continuum of collagen tissue in the calcaneofibular region.

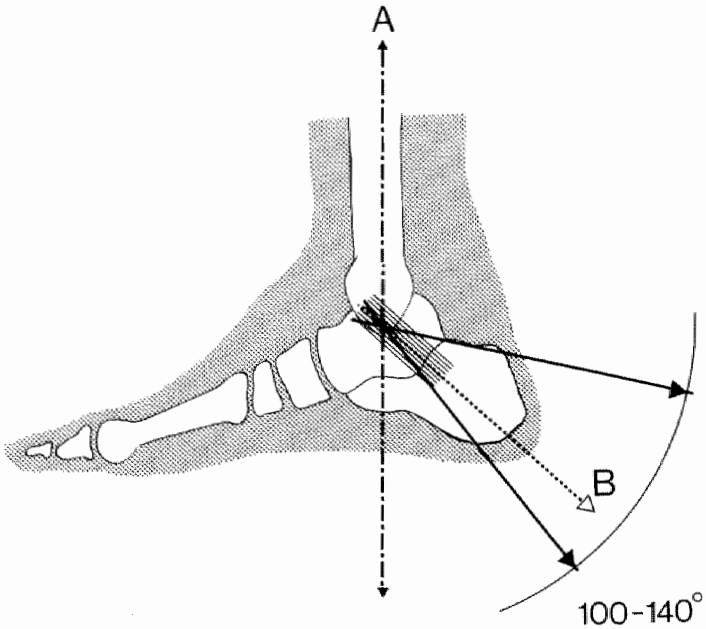

Figure 9

Schematical view of the lateral malleolus.
A = long axis of the lateral malleolus.
B = direction of the calcaneofibular fibers.
Inter-individual variation between 100 and 140° to a vertical axis.

2.3.3. Discussion

The most important fact emerging from dissections of unfixed ankles is that there are often more capsular reinforcing collagen structures than normally described in textbooks and other literature, and furthermore, that the connective tissue apparatus forms a continuous three-dimensional system of layers, fibre tracts and sheaths. These capsular reinforcing structures are integral parts of retinacula and fibrous tendon sheaths, and consequently their separation is artificial.

In contrast to the literature, the calcaneofibular ligament, shown in this study to consist of tracts of collagenous fibres, has to be considered as a capsular reinforcement. As previously mentioned the posteromedial part of the peroneus tendon sheath is continuous with the joint capsule. Thus a capsular lesion may lead to an open communication between the ankle joint cavity and the peroneus tendon sheath (chapters 6 and 7). The deepest fibre tracts of this calcaneofibular complex constitute a connection between talar and calcaneal periostea, but, they should not be considered as a distinct lateral talocalcaneal ligament, because they are continuous with the other calcaneofibular fibres.

In general, both surgeon and radiologist look for a clear cut diagnosis in terms of damage to ligaments, capsule or syndesmosis, in the hope that the choice of treatment may be equally clear cut. To this end the surgeon uses the results of stress radiography and arthrography as diagnostic aids. The surgeon expects the radiologist to express his diagnosis in specific terms, as given in standard anatomical textbooks, on the basis of fixed specimen. From an anatomical and functional point of view, however, it is impossible to consider the collagen skeleton other than as an entity (van Mameren 1981).

2.4. Functional anatomy - literature

C.R. van den Hoogenband

The leg and the forefoot are connected by a chain of joints, of which the talocrural joint is one link. This chain operates as a functional entity, the various links functioning in mutual interplay. The motility of this chain is highly dependent on the way it is permitted to move: movements in the open chain situation (as during the sway phase) are different from movements in the closed chain situation (as during the stance phase).

A short description of the separate joints and an indication of their motility (mostly in the open chain situation) are given below.

The most important joints are the subtalar and the talocalcaneonavicular joints, respectively back and front compartments of the midtarsal joint.

1.

The **subtalar or posterior talocalcaneal joint** is a separate compartment behind the tarsal sinus. It is formed by the articular surface on the lower part of the body of the talus and the posterior articular surface of the upper part of the calcaneus. The talar articular surface has a concave-convex saddle shaped aspect whereas the corresponding articular surface of the calcaneus has a convex-concave saddle shaped aspect. The articular margins are connected by a short capsule thickened in the form of the talocalcaneal ligaments, medially and laterally, and a strong ligament placed in the tarsal sinus, the interosseous talocalcaneal ligament. Based on our observations, the calcaneofibular ligament has also to be considered as a part of this capsule.

2.
The **talocalcaneonavicular joint** lies in front of the tarsal sinus. The head of the talus is rounded and presents at its front part a large ovoid convex articular surface for the articular surface of the navicular bone. Below, the middle calcaneal facet for the sustentaculum tali is prolonged onto the head where it is called the anterior calcaneal facet. A convex ovoid facet on the inferior medial aspect of the head is related to the plantar calcaneonavicular ligament, which forms part of the socket of the talocalcaneonavicular compartment. This plantar calcaneonavicular ligament runs from the margin of the sustentaculum tali to the lower margin of the navicular bone. On its intra-articular aspect, this ligament has a triangular shaped dense fibrous part, a functional part of the joint surface (Drukker 1975).
The talocalcaneonavicular joint can be considered as a ball and socket joint in which the head of the talus fits into the socket, formed by the navicular bone in front, the calcaneus below and the plantar calcaneonavicular ligament in between. The dorsal talonavicular ligament and the dorsomedial part of the bifurcate ligament reinforce the capsule of this joint.
In addition to the midtarsal joint, the transverse tarsal joint (joint of Chopart) is described as the combination of the calcaneocuboideal joint and the talonavicular connection. The saddle shaped calcaneocuboideal joint is formed by the anterior aspect of the calcaneus and the posterior aspect of the cuboid.
The other intertarsal joints between cuboid, cuneiform and navicular bones, important though they are in the functioning of the foot, will not be discussed here.
The co-ordinated function of the talocrural joint, the subtalar compartment, the talocalcaneonavicular compartment and the transverse tarsal joint is the basis of the major part of the motility of the foot. The movements in the talocrural joint are dorsiflexion and plantarflexion, the axis of the movement passing approximately horizontally through the malleoli. Though, in general, a greater degree of plantarflexion than dorsiflexion of the foot is possible, there is considerable individual variation in these movements. The angle between full plantar- and dorsiflexion varies between 60° and 105° depending on factors such as form of the joint, age, race, training etc. These movements are described in relation to the neutral position where the line passing from the heel to the third toe is at a right angle to the lower leg.
De Vogel (1961) already proved that the talocrural joint is not a pure hinge joint. He observed small rotation and tilt movements during both dorsi- and plantarflexion, which are easily explained by the saddle shape of the articular surfaces. Moving the foot in dorsiflexion is accompanied by abduction and pronation of the talus, and correspondingly plantarflexion by adduction and supination. Because of the anatomy of the joint surfaces of the ankle mortise and talar trochlea, already described in chapter 2.3. (close packed position), the most stable position of this joint is in full dorsiflexion. Most of the collagenous fibre tracts of the talocrural joint are under tension in this position. The midtarsal joint can be considered as a 'trochoid type' joint (Drukker 1975) as it is a combination of a saddle shaped joint (subtalar compartment) and a 'ball and socket' joint (talocalcaneonavicular compartment).
The movements in this joint are generally described as taking place around an axis entering at the superomedial aspect of the talar neck, running through the tarsal sinus and emerging at the posterolateral tubercle of the calcaneus. Around this axis, two important movements of the foot are possible: inversion, an inward rotation, and eversion, an outward rotation. Inversion is frequently described (Karpandji 1974) as a combination of plantarflexion, adduction and supination of the midtarsal joint, but

because these movements cannot be made separately, differentiation between them is confusing (Drukker 1975). The extent of full inversion/eversion is 60 to 90°. Pronation and supination take place particularly around the sagittal axis of the transverse tarsal joint, to a maximum of 10° (Drukker 1975, Karpandji 1974) and in the other tarsal joints.

The influence of the so-called lateral ligaments of the ankle on these movements is described by many authors, and there is general agreement about the anterior talofibular ligament. Inversion, as a consequence of the other movements of the chain, produces a tilt movement of the talocrural joint, which causes tightening of the anterior talofibular ligament. The role of the calcaneofibular ligament has often been ignored. Prins (1978) observed in cadaver ankles that plantarflexion was not responsible for tightening of the calcaneofibular ligament. Such a tightening, however, could be brought about by slight external rotation of the leg in combination with a fixed position of the foot, resulting in a slight supinatory movement of the subtalar joint, and consequently tightening of the calcaneofibular ligament. By such mechanisms, trauma could produce a succession of insults to both capsule and ligaments of the lateral region of the ankle joint.

The literature contains little information on the biomechanical aspects of the ankle joint. Huiskes (1979) describes the importance of the position of the ligaments in relation to the axis of the movement. Their influence on the stability of the ankle could be explained by the course of the collagenous fibre tracts in relation to the respective directions of movement in the ankle joint. In figure 10 the influence on the motility of an imaginary joint by three different ligaments is schematically shown. Because ligament 1 has an insertion in the rotation axis it will not inhibit movements of the joint, while ligament 2 and 3 will develop an increasing resistance by moving their insertion further from this axis.

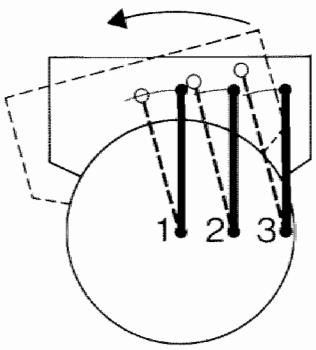

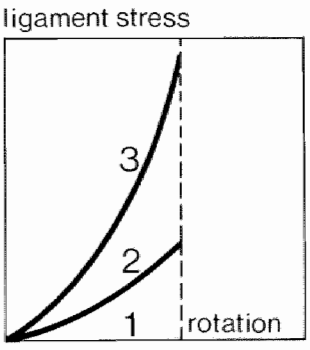

Figure 10

The importance of the position of ligaments to the stability of the joint can be similarly explained. Figure 11 shows the decreasing stability given by three different ligaments on tilting another imaginary joint.

The muscles of the lower leg are essential to motility in the chain of joints between leg and forefoot.

Of course, the effect of muscle action differs depending on whether the leg and foot are in a free moving or closed chain position. In the latter, they maximally influence the total weight of the body (minus one foot), contracting in a concentric or an

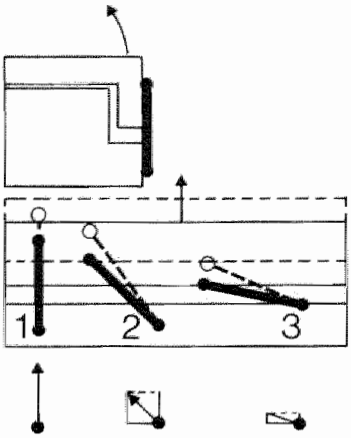

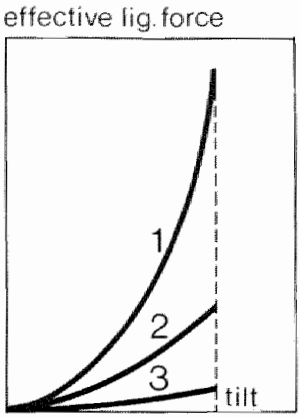

Figure 11

eccentric mode. In the former, less stressing position, the weight to be levered is only that of the foot.
That none of these muscles is mono-articular is one cause why the afore-mentioned chain functions as a pluri-articular entity. It is therefore useless to sum up the function of the muscles in relation to each separate joint. An understanding of muscle function is of utmost importance to the restoration of function after injury (chapter 12), and is therefore summarized here in relation to the normal movements of the pluri-articular chain. For the sake of simplicity this is given with the foot in the open chain situation and for concentric contractions, notwithstanding the fact that in the closed chain situation the muscles have to work much harder.

Dorsiflexion
m. tibialis anterior

plantarflexion inversion/supination	plantarflexion eversion/pronation
m. gastrocnemius m. soleus m. tibialis posterior	m. peroneus longus m. peroneus brevis

With the foot in stance phase the long and short flexors and extensors of the toes may be contracting simultaneously with plantar- and dorsiflexors respectively.

Part 2

Diagnostic aspects of ankle arthrography and stress examination
F.I. van Moppes

3. Stress examination of the ankle, following inversion trauma

3.1. Introduction

Inversion trauma of the ankle is a condition familiar to both surgeons and radiologists, but the resultant ligamentous damage presents a diagnostic problem, which is the subject of much disagreement. After fracture has been excluded, radiography is frequently supplemented by two stress examination techniques:
1.
Inversion force is applied to the lateral dorsal part of the foot with fixation of the lower leg. This tends to produce separation of the articular surfaces of tibia and talus, with an angle, open laterally, which may be measured radiologically on A-P view. This angle is referred to as 'the talar tilt angle' (fig. 12).
2.
With the foot fixed, force is applied to the leg, just above the ankle joint, in a posterior direction. This tends to induce dislocation of the ankle joint with an anterior and caudal component of talar movement relative to the tibia. The actual movement is usually more complex and includes forward rotation of the talus about a transverse axis. The resultant displacement is referred to as the 'anterior drawer sign' (fig. 12), and several methods of radiological measurement are used.

3.2. Literature

3.2.1. Inversion stress examination

3.2.1.1. Use of anaesthesia

Some authors (Boomsma 1979, Cailliet 1971, Freeman 1965 B, Kleiger 1956) perform inversion stress examination without anaesthetic, claiming that the procedure is not unacceptably painful if performed with care. Majority opinion, however, is in favour of the use of some form of anaesthetic to reduce pain and muscle resistance. Local anaesthesia may be achieved in a variety of ways. Infiltration of local

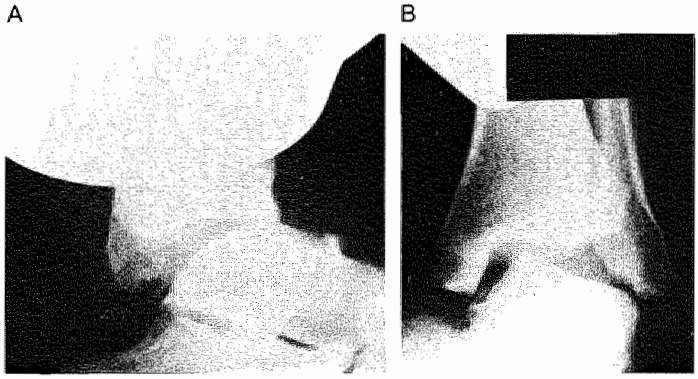

Figure 12

a) Anterior drawer sign,
b) talar tilt.

anaesthetic into the site of maximum pain has the advantage of being a quick and simple technique, but may increase the degree of soft tissue damage (Prins 1978) and cannot adequately block pain originating from the capsule and deeper parts of the joint.
Another approach is to perform a regional nerve block around the tibial and common peroneal nerves in the popliteal fossa (Adler 1976 A, Clark 1965, Freeman 1965 B) or at the head of the fibula (Ruth 1961) or around the superficial peroneal nerve where it emerges through the deep fascia, some 8 to 10 cm above the lateral malleolus (Gerlach 1978, Reichen 1975). Once again, however, pain originating in the joint itself is not fully blocked, due to the shared innervation of the joint capsule (Lanz-Wachsmuth 1972, Prins 1978) (Chapter 2). The logical approach to capsular anaesthesia is intra-articular local anaesthesia, and this is often combined with ankle arthrography (Van Moppes 1979 B, 1981, Prins 1978, Sanders 1976).
Complete elimination of pain and muscle resistance may be achieved by spinal or general anaesthesia, the former being reported by Broström (1966 B), Cedell (1975), Olson (1969), and the latter by Fleischer (1973), Laurin (1965), Olson (1969), Tóth (1974) and Wolter (1979 and 1980). The disadvantages of both techniques are that they require the services of a competent anaesthesist, prolong the investigation and increase the costs.

3.2.1.2. Examination technique

Inversion stress may be applied manually or mechanically, using some suitably constructed device (Boomsma 1979, Colton 1976, Laurin 1965, Rubin 1960, Schmidt 1978, Zinman 1979). Different authors use different devices and may apply different forces, but their literature does not always make adequate mention of this. Additionally, these devices may result in some degree of external tibial rotation, resulting radiologically in a reduced degree of talar tilt (Prins 1978, Rubin 1960).
Other authors use a knowledge of functional anatomy to test the various ligaments by applying inversion stress with the foot in various positions of flexion or extension, but there is disagreement as to the position in which the calcaneofibular and posterior talofibular ligaments are tested. Majority opinion is that the posterior talofibular ligament is taut with the ankle in full dorsiflexion, the calcaneofibular ligament at about 90°, and the anterior talofibular ligament in full plantarflexion (Clark 1965, Den Herder 1961, Hupfauer 1970, Lanz-Wachsmuth 1972, Makhani 1963, Noesberger 1976, Percey 1969, Plaue 1970).

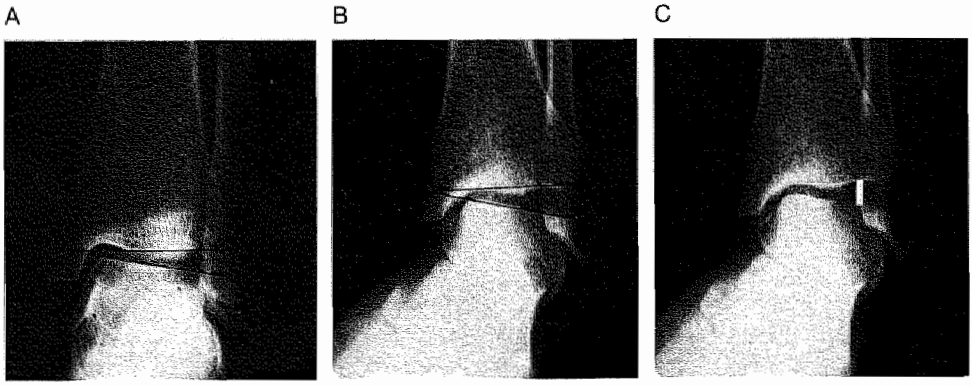

Figure 13 Three different measurement methods for talar tilt after inversion stress.

3.2.1.3. Measurement technique

This requires an accurately positioned A-P view of the ankle in stressed position. On this film, talar tilt may be measured in a variety of ways.

1.

The angle between lines drawn tangentially along the most distal part of the distal tibial articular surface and the two most proximal parts of the upper talar articular surface. (Anderson 1952, Prins 1978) (fig. 13a).

2.

The angle between lines drawn along the two most proximal points of both distal tibial and upper talar articular surfaces (Laurin 1965, Rubin 1960, Speeckaert 1978) (fig. 13b).

3.

Measurement of the separation between the lateral margins of the articular surfaces of distal tibia and talar body (Johanssen 1978, Paul 1978, Reichen 1975, Ruth 1961, Thomas 1973) (fig. 13c).

3.2.1.4. Normal values

There is no consensus whatsoever in the literature as to normality in the measurement of talar tilt. Unilateral variation ranges from 0 to 25° (Bonnin 1944, Laurin 1965, Lemberger 1971, Prins 1978, Rubin 1960). Most authors consider comparison with the contralateral ankle to be essential. Clark (1965) considered a talar tilt difference of more than 3° to be pathological, but most other authors settle for 4 to 6° (Colton 1976, Freeman 1965 B and C, Fordyce 1972, Gerbert 1975, Sanders 1977, Speeckaert 1978, Staples 1972).

However, in a study to establish normal values, Rubin (1960) and Bonnin (1944) report talar tilt differences of up to 19°, though the difference is usually less than 10° (Laurin 1968). This has led to the concept of the weak or so-called 'hypermobile' ankle joint (Bonnin 1944, Broström 1966 C, Fordyce 1972, Freeman 1965 B and C, Laurin 1965, Rubin 1960), which is variously defined as a talar tilt difference exceeding 3 to 5° in subjects who have no relevant history of trauma, but may complain of weak ankles. The prevalance of the hypermobile ankle joint is said to be 3 to 10% of the normal population (Bonnin 1944, Clark 1965, Pascoët 1972, Tausch 1978 A and B).

Lastly, Freeman (1965) and Tonino (1973) discount as normal talar tilt differences up to 4°, claiming that measurement error is always about 2°. When lateral articular separation is used as the measurement criterion, figures of 3 mm difference or more are considered to be pathological by several authors (Johannsen 1978, Paul 1978, Ruth 1960, Thomas 1973). Reichen (1975) states that the talar tilt is abnormal when there is a 'clear' opening of the joint space.

3.2.2. Anterior drawer sign

3.2.2.1. Use of anaesthesia

The literature already discussed (chapter 3.2.1.1.) under the heading of inversion stress examination is equally relevant to this type of stress examination, although some authors state that pain is minimal or absent compared to inversion stress examination, and therefore consider anaesthesia unnecessary (Johannsen 1978, Langer 1980).

3.2.2.2. Examination technique

As in inversion stress examination, both manual (Geesinck 1977, Hupfauer 1970,

Prins 1978, Sanders 1976) and mechanical (Adler 1976 A, Castaing 1962, Chirls 1973, Johannsen 1978, Langer 1980, Larsen 1976, Laurin 1965 and 1975, Lindstrandt 1977, Nussberger 1976, Seiler 1977 A) techniques are used. The forces applied vary from 4 to 38 kg (Johannsen 1978, Larsen 1976, Laurin 1975, Lindstrandt 1977, Seiler 1977 A) or are simply not mentioned (Adler 1976 A, Chirls 1973, Langer 1980, Nussberger 1976). Castaing (1972) maintains that there is no sense in applying force of more than 4 to 5 kg. Laurin (1975) applies the force for one minute, prior to radiography, supposedly to allow time for muscle relaxation. Lindstrandt (1977) similarly quotes times of 0.5 to 2.5 minutes, whereas Larsen (1977) allows an unspecified waiting time.
Laurin (1975) demonstrates a so-called 'physiological anterior drawer sign', which, he maintains, can be recognized by the fact that it decreases when the examination is repeated with the ankle in equinus position.

3.2.2.3. Measurement technique

Whereas most authors quantify talar tilt in some way, many do not do so with the anterior drawer sign. Broström (1965 B), Geesinck (1977), Hupfauer (1970), Prins (1978) perform the examination manually and make a subjective judgement without the benefit of X-ray. Others attempt to quantify their results, for instance:

1.
Lindstrandt (1977): in lateral projection the joint surfaces of the tibia and talus may be considered to describe arcs of concentric circles. This congruity disappears when the talus is displaced. The distance between the centres of these two circles indicates the degree of displacement.

2.
Larsen (1976): the perpendicular distance between the posterior border of the posterior talar process and the line of the posterior border of the fibula is measured (fig. 14a).

3.
Castaing (1972): the distance between the trochlea tali and the distal tibial articular surface is measured, but exact measuring points are not given.

4.
Müller (1977): the distance between the most distal point of the posterior tibial articular surface and a tangent to the talar articular surface is measured (fig. 14b).

A B

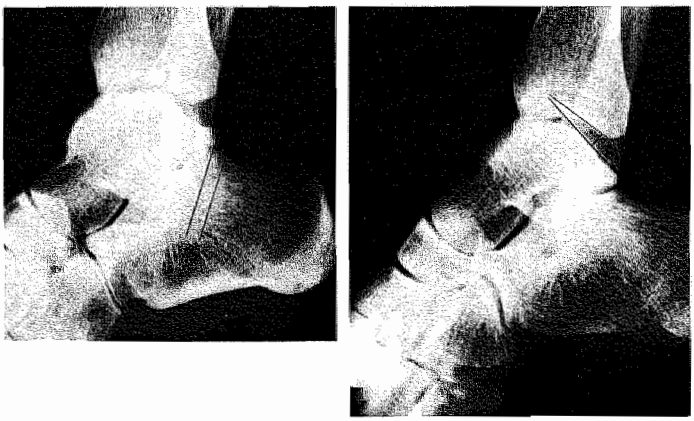

Figure 14

Measurement methods for the two different components of the anterior drawer sign.

3.2.2.4. Normal values

There is no general consensus as to normal values, even among workers who use the same measuring techniques. When posterior opening of the joint is measured in some manner, the maximum normal value quoted is up to 9 mm (Castaing 1972, Laurin 1975, Müller 1977, Noesberger 1976).

As with talar tilt, there is general agreement that the most significant value is the difference in measurement between left and right side, and differences of more than 2 or 3 mm are considered abnormal by Johannsen (1978), Landeros (1968), Langer (1980), Larsen (1976), Müller (1977), Noesberger (1976), Seiler (1977). The concept of hypermobile ankle joint is not generally used for the anterior drawer sign, although high values are found in otherwise normal subjects (Delplace 1975, Landeros 1968).

3.3. Results of a preliminary study on stress examination

3.3.1. Introduction

A high level of reproducibility and accuracy are essential features of any examination technique that is to be used as a standard diagnostic tool. Talar tilt and anterior drawer sign measurements are often applied separately or together in addition to arthrography and far-reaching diagnostic conclusions are drawn. However, review of the literature casts doubt in the reproducibility and accuracy of these particular diagnostic tools, so a preliminary study was undertaken in order to examine these aspects of the techniques (Van Moppes 1979 B).

3.3.2. Methods and materials

200 Healthy subjects aged between 10 and 50 years, with no previous history of ankle joint trauma were subjected to stress examination. One examiner performed bilateral inversion stress examinations (focus-film distance 70 cm) on the first 100 subjects and the resultant talar tilt differences were measured radiologically by the first two methods previously described in chapter 3.2.1.3. and illustrated in figures 13a and 13b.

Bilateral anteroposterior stress examination was performed on the second 100 subjects by the same examiner as follows: the subjects were supine and the heel was placed on an 8 cm high platform with the ankle joint in neutral position, and an immediate lateral X-ray was taken (focus-film distance 70 cm). A 4.5 kg sandbag (Castaing 1972) was then placed on the distal tibia about 10 cm above the ankle joint, two minutes relaxation time was allowed to elapse and a second lateral X-ray was taken. As previously mentioned, the anterior drawer sign is complex, although for the purposes of this examination, it was considered to consist of two components: posterior widening of the joint (tilting component) and anterior movement of the talus relative to the tibia (gliding component). A modification of the methods of Larssen (1976) and Müller (1977) (chapter 3.2.2.3.) was used for subsequent measurement and evaluation (figs. 14a and 14b).

The tilting component was derived from the differences, on stressed and non-stressed films, in the length of lines drawn perpendicularly from the most posterior point of the tibial articular surface to the point of intersection with the upper talar articular contour, while the gliding component was derived from the differences, on stressed and non-stressed films, in the horizontal distances between the posterior borders of fibula and talus. The resultant figures for left and right ankles were then compared and the absolute left-right differences for each subject were then

recorded. For both inversion stress examination and anterior drawer sign, these results were statistically evaluated by means of a frequency distribution.
In a number of selected cases, stress examinations were performed on the same subject by different examiners, to assess the effect of differences in both examiner and technique. Similarly, a number of doctors were asked to perform radiological measurement of talar tilt angle on stress films, firstly according to their own accepted methods, and subsequently after instruction on a standardized measurement method (fig. 13b).

3.3.3. Results

Inversion stress examinations

Radiologically satisfactory examination, permitting quantification of talar tilt angles, was possible in all 100 subjects. Both measurement methods (1 and 2) (figs. 13 a and b) yielded similar distribution patterns and statistical analysis suggested a talar tilt difference maximum value of 5 to 5.5° as the upper limit of normal. Values of 5.5° or more were found in 9% and 8% respectively, for the methods 1 and 2. The highest figure found was 9°. Measurement by method 2 (fig. 13b) was found to be easier and more accurate. The two methods could on occasion yield different results on the same patient (table 1). Figure 15 gives an example of the range of talar tilt angles produced by different examiners on the same subject. When different doctors applied their own personal measurement criteria to the same patient, the resultant left - right differences could vary considerably (table 2), but instruction on a standardized measurement technique reduced these differences.

A B C

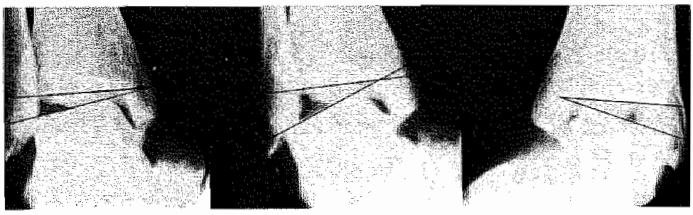

Figure 15

Talar tilt stress films performed by two examiners on the same patient.
a. first examiner: right ankle – talar tilt angle 10°
b. second examiner: right ankle – talar tilt angle 21°
c. second examiner: left ankle – talar tilt angle 12°

Table 1
Talar tilt measurements obtained on 4 selected patients by the same examiner, using two different techniques

	Method 1	Method 2
Patient A	2.5°	4°
Patient B	6.5°	8°
Patient C	5°	7°
Patient D	7°	3°

Table 2
Table showing the range in talar tilt difference measured by 4 different examiners, before and after instruction in a standardized measurement technique

Without instruction:		With instruction:	
Patient A	6.5° - 11°	Patient D	4° - 6°
Patient B	6° - 10°	Patient E	0° - 2.5°
Patient C	8° - 14°	Patient F	6.5° - 9°

Anterior-posterior stress technique
In 30 cases the examination was technically unsuccessful, because of rotational differences between the first and second film. Statistical analysis of the remaining 70 suggested maximum sliding and tilting normal values of 2 and 3 mm respectively. Five and 6% respectively had values above these upper limits of normal. A significant finding was that, in some subjects, there was no displacement in comparing the two films. Figure 16 shows the range of results obtained by two different techniques on the same patient.

A B

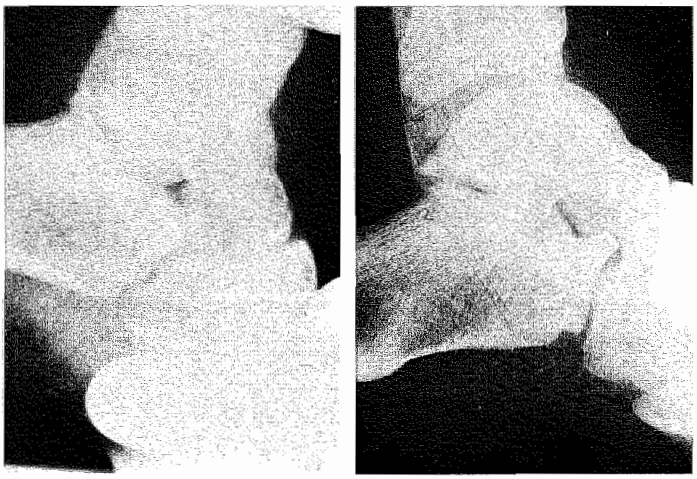

Figure 16
Anterior drawer sign film.
a. Manual A-P stress and film taken immediately.
b. Same patient after 4.5 kg sandbag stress for 2 minutes.

3.4. Discussion

The normal values established by this study are in agreement with those of other authors (chapters 3.2.1.4. and 3.2.2.4.). The results of both examination techniques are considerably dependent on both the exact method used and the skill and experience of the examiner. In all respects, inversion stress examination is simpler and more reliable. Anterior-posterior stress examination is time-consuming (which is particularly undesirable if the patient is under general anaesthesia) (chapter 7), requires more films and consequent radiation, and may be technically unsuccessful (Lindstrandt 1977), necessitating repetition, which is most unpleasant for traumatized patients. Failure to detect any displacement in some normal subjects could be explained by the weight of the leg itself causing maximal displacement prior to the

first film, and would constitute a further disadvantage of the technique, as a radiodiagnostic tool.
In the literature, inversion stress examination is the technique most usually combined with arthrography.
For all these forgoing reasons, manually performed inversion stress examination alone, measured according to method 2 (fig. 13b), was chosen for further study.

4. Ankle arthrography - technique, interpretation and complications

4.1. Introduction

Ankle arthrography was first introduced in about 1940 (Wolff 1940, Hanssen 1941), but it was not until after 1960, with the pioneering work of Broström (1964, 1965 A and B, 1966 A, B and C), that it became popular as a method of diagnosing ligamentous pathology. It was introduced in the radiology department of the St. Annadal Hospital, Maastricht, in 1977. Since then about 700 ankle arthrograms have been performed, and these formed the basis of this study.

4.2. Technique

Ankle arthrography must be performed within seven days of the original trauma, to prevent subsequent organization of fibrin and blood clot from obscuring ligamentous pathology (Sanders 1976, Prins 1978).
The method used is as follows:
1.
the examination is carried out under full normal sterile conditions, using an iodine skin preparation. The joint is punctured anteriorly, the exact site being dependent on the site and size of the haematoma and oedema. If there is considerable traumatic swelling and oedema, the joint line can be estimated by palpation of the two malleoli.
2.
the correct position of the needle-point within the joint cavity is checked by one of the following methods:
a.
aspiration or spontaneous drainage of blood and/or synovial fluid.
b.
absence of resistance to the introduction of a small quantity (2-3 ml) lignocaine without adrenaline.
c.
in cases of doubt, the position may be checked fluoroscopically, although with practice in arthrographic technique, this is seldom necessary.
3.
a mixture of 8 ml contrast medium (Isopaque amin 220®), 2 ml lignocaine 1% without adrenaline and 0.5 ml hyaluronidase (75 I.U.), is injected slowly, until the patient complains of definite pain. The total quantity which can be injected is dependent on the normal volume of the joint cavity and its normal possible connections (chapter 9), presence or absence of capsule rupture, and the amount of any blood and/or clot in the joint.

4.
under fluoroscopic control, one anterior-posterior, one lateral and two oblique X-ray films are made. The most distal point of the lateral malleolus should be clearly visible on one of the projections.
5.
the examiner wears lead protective gloves and manually performs bilateral stress examination in order to evaluate talar tilt difference.
6.
a 'late' view in one of the four positions is taken under fluoroscopy, because sometimes ruptures are already sealed off by fibrin or blood clot, which may dislodge after inversion stress, thus producing a new contrast leakage pattern. This emphasizes the necessity of performing ankle arthrography within seven days after the initial trauma, before too much fibrinous organization prevents adequate demonstration of capsular or ligamentous pathology.

4.3. Interpretation of ankle arthrography - review of literature

4.3.1. Introduction

The diagnostic criteria used in the early work on ankle arthrography in our department, and described below, were those most commonly found in the literature.

4.3.2. Normal arthrogram

An ankle arthrogram is considered to be normal if there is no contrast leakage and if there are smooth contrast contours. The normal joint cavity has anterior, posterior and tibiofibular recesses, and has a capacity of 6 to 20 ml (Lanz-Wachsmuth 1972), Tausch 1978 C). The normal joint cavity may also communicate with the flexor tendon sheath and the subtalar joint (Broström, 1965 A, Fussell 1973, Olson 1969, Prins 1978, Sanders 1972, 1976 A) (fig. 17).
There is disagreement as to whether the peroneus tendon sheath may have normal

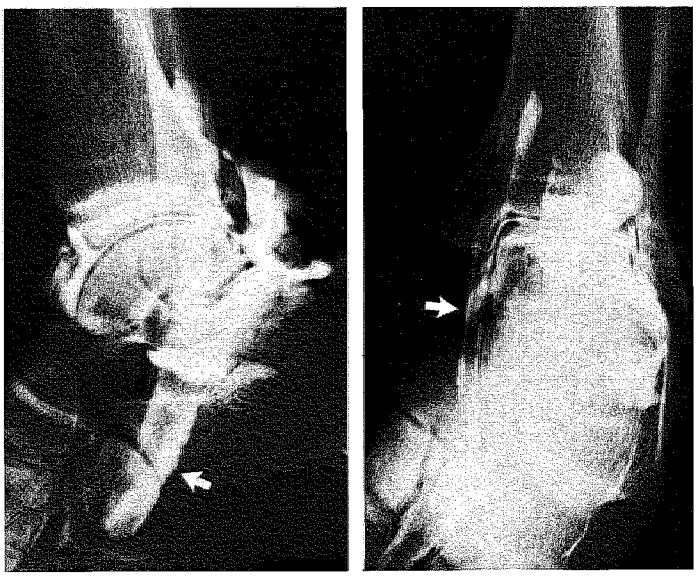

Figure 17

Normal arthrogram, showing ample recesses and filling of flexor tendon sheath (arrow) and talocalcaneal joint.

connection with the ankle joint and whether filling of a flexor tendon sheath and the subtalar joint may also have a traumatic origin. These disagreements form the subject of a study presented in chapter 6.

4.3.3. Abnormal arthrogram

1.

Rupture of the capsule of the ankle joint

Few authors classify the contrast leakage patterns in isolated capsule rupture: according to Percey (1969) and Lindholmer (1978), contrast leakage in a cranial direction with a flame-shaped appearance, extending onto the anterior aspect of the ankle joint, may be found as a diagnostic sign (Percey type 1).

2.

Rupture of anterior talofibular ligament

Most authors consider the diagnostic sign to be contrast leakage around and lateral to the lateral malleolus (Broström 1965, Goergen 1980, Makhani 1962, Mehrez 1970, Olson 1969, Prins 1978, Sanders 1972, 1976, 1977) (fig. 18a).

Percey (1969) quotes slightly different criteria.

A 'Percey type 2 lesion' consists of combined rupture of the anterior capsule and anterior talofibular ligament, and is indicated by anterior and lateral contrast leakage.

A 'Percey type 3 lesion' consists of rupture of all lateral structures, and is indicated by massive contrast leakage anteriorly and laterally, often around the tip of the lateral malleolus, and, on occasion with upward spread along the lateral aspect of the fibula. Lindholmer (1978) gives a much more extended classification of ligamentous rupture, based on the various types of contrast extravasation patterns, by estimating the posterolateral border of the extra-articular contrast medium, and not the total extent of extra-articular contrast spread.

Diagnostic accuracy for rupture of the anterior talofibular ligament is reported to be about 90-95%.

A

B

Figure 18

a. Contrast leakage distal and lateral to the lateral malleolus.
b. Contrast leakage distal and lateral to the lateral malleolus and filling of the peroneus tendon sheath.

3.
Rupture of calcaneofibular ligament
Rupture of this ligament generally occurs in combination with anterior talofibular ligament rupture, and many authors consider this combined injury to be indicated by leakage around and lateral to the lateral malleolus, together with filling of the peroneus tendon sheath (fig. 18b) and/or a talar tilt difference of at least 10° (Broström 1965 A, Gerbert 1975, Gordon 1970, Kaye 1977, Lüning 1969, Olson 1969, Sanders 1972, 1977, Spiegel 1975).
The reported specificity of a filled peroneus tendon sheath, as indicator of a calcaneofibular ligament rupture, varies between 72% and 98%. Prins (1978) also considers an unilateral talar tilt of at least 15° to be diagnostic of calcaneofibular ligament rupture. Isolated calcaneofibular ligament rupture is said to result from pure hyperdorsiflexion trauma in which case there is isolated filling of the peroneus tendon sheath, although this is extremely rare (Prins 1978, Speeckaert 1978).
Calcaneofibular ligament rupture is also implicit in the massive contrast leakage pattern which Percey (1969) considers diagnostic of his type 3 lesion.
According to Lindholmers' classification (1978), calcaneofibular ligament rupture would be indicated by the presence of contrast posterior to the middle of the lateral malleolus on lateral view. There are isolated reports of two further diagnostic criteria in recent literature, both of which claim a specificity at least as good as Lindholmer and Percey or peroneus tendon sheath filling. These are the 'oblique axial view' (Vuust 1980) and the 'stress tenogram', (contrast injection into the common peroneus tendon sheath, combined with stress examination) (Black 1978, Evans 1979).
Because several authors (Gerbert 1975, Gordon 1970, Schweigel 1977, Tóth 1975, Zinman 1979) consider arthrographic filling of the peroneus tendon sheath to be a normal finding, a study was devoted to the significance of this finding and is presented in chapter 6. A full study on the diagnosis of calcaneofibular ligament rupture is presented in chapter 7.
4.
Rupture of posterior talofibular ligament
This is invariably accompanied by rupture of the other two lateral ligaments. There are no specific arthrographic signs mentioned in the literature. The injury may be inferred, if, in addition to the arthrographic signs of anterior talofibular and calcaneofibular ligament rupture, there is also gross instability of the joint (Colton 1976, Gerbert 1975, Olson 1969).
However, each author has his own definition of gross instability. For the purpose of this study, this was defined as a talar tilt difference of at least 20°.
5.
Rupture of anterior tibiofibular ligament
The accepted arthrographic criteria for anterior tibiofibular ligament rupture are absence of a contrast free zone anterior to the distal tibia and absence of tibiofibular recess filling, the latter signifying adjacent capsular rupture (Broström 1964, 1965 A, Fussell 1973, Mehrez 1970, Olson 1969 and 1981, Sanders 1977, Spiegel 1975, Stepanuk 1977). Although some authors (Broström 1965, Spiegel 1975) confirm their results surgically, our early experience with ankle arthrography in the differential diagnosis of rupture of the joint capsule and anterior tibiofibular and talofibular ligaments, casts doubt on the reliability of these criteria, and the problem was therefore subject to a detailed study which is presented in chapter 5.

4.4. Complications of ankle arthrography

4.4.1. Introduction

A degree of pain and discomfort to the patient are almost invariable accompaniments of arthrography and should strictly be considered as side effects. However, arthrography in common with other invasive radiological techniques, may give rise to complications, the most frequent of which are:

1.
bacterial arthritis.

2.
acute allergic reaction to iodine based injectable contrast medium, or iodine based skin preparation substance.

3.
air embolism when performing double contrast arthrography.

4.
any of the normal complications associated with the use of a local anaesthetic.

It follows that open skin wounds, or serious skin disease around the ankle joint, and known hypersensitivity to iodine or local anaesthetic must all be considered as contra-indications to ankle arthrography. The major complication rate for arthrography in general in our department over a four year period was 1 in 3,000. As this happened to be a case in which ankle arthrography was being performed it is discussed here.

4.4.2. Case history

A 52 year old healthy lady with suspected lateral ligament injury, was submitted for ankle arthrography. The arthrogram itself showed no abnormality and the patient went home. Two days later, she was admitted to hospital with a history of severe pain and swelling of the ankle, particularly on the lateral side, associated with constitutional symptoms, developing some hours after arthrography.

On examination, the patient was afebrile, but the foot and ankle, particulary around the lateral malleolus, were red, swollen and tender.

The past history included cholecystectomy, laparoscopy, hiatius hernia repair and laparotomy for adhesions. Further inquiry revealed a history of acute hypersensivity reaction to local anaesthetic used in the course of laparoscopy and also dental extraction. After admission, aspiration of the joint was performed and yielded 5 ml of blood stained fluid, which was sterile on culture. The ESR was raised at 64 mm, but further laboratory investigations were all normal.

A provisional diagnosis of chemical arthritis was made, and the patient was treated with a dorsal plaster splint and bed-rest for two weeks, after which she was asymptomatic and had normal ankle function, so was discharged wearing an elastic bandage. Follow-up as an outpatient, four weeks after the original arthrogram, showed complete recovery and the ESR had returned to normal.

4.4.3. Discussion

Normal sterile precautions are all that is necessary for the prevention of bacterial arthritis as a complication of arthrography. In a series of over 25,000 arthrograms, Freiberger (1979) reports only one case of bacterial infection of a knee joint, which recovered completely after treatment, leaving no permanent joint damage. In an attempt to avoid aseptic chemical arthritis of an allergic type, it is customary only to inquire about iodine hypersensitivity, but the case-history described demonstrates

that a wiser general policy would be to take a full allergic history from every patient subjected to invasive radiological procedures.
In Freibergers' series (1979) of 25,000 patients, he reports only twenty cases of mild iodine allergic reaction, which were readily responsive to anti-histamines. Thyn (1979) describes only one case of urticaria out of 4,000 patients and Ricklin (1980) reports one case of angio-neurotic oedema out of 10,000 patients.
Double contrast arthrography is being increasingly used, particularly in arthrography of the knee and shoulder joints, and several cases of air embolism are described (Freiberger 1966, McCauley 1981). As already mentioned, pain during arthrography should be regarded more as a side-effect than a complication, and there have been a number of studies onto the nature of the pain. It is mainly related to distension of the joint and to the irritative effect of the contrast medium on the synovial membrane (Hall 1980, Mink 1980). Because ankle arthrography is frequently performed on an ankle which is already painful following inversion trauma, it is not always possible to assess the degree of morbidity and pain caused by arthrography, although it is our impression, after questioning several patients, that its duration is no longer than 24 hours.
Incorrect positioning of the injection needle may result in contrast extravasation into the tissues, which is painful, but the further possible complications of skin ulceration and sloughing, which Thomas (1978) described, following phlebography, are not reported. Pain in such cases seldom requires analgesics.

4.4.4. Summary

The overall complication rate of arthrography is low (less than 0.1%). Bacterial arthritis can be avoided by the use of standard sterile procedures, and the incidence of allergic reactions kept to a minimum by taking a proper history of allergy and hypersensitivity as a matter of course. Double contrast arthrography carries a small risk of air embolism, which should be born in mind before undertaking the procedure. Accidental extra-articular contrast injection is painful, but not otherwise associated with complications.

5. Arthrographic differential diagnosis of rupture of the anterior talofibular ligament, the joint capsule and the anterior tibiofibular ligament

5.1. Introduction

One of the main pathological features in ankle arthrography is contrast leakage from the joint into the soft tissues. Such leakage, however, may assume different patterns. According to arthrographic literature, anterior tibiofibular rupture is often described in isolation or together with anterior talofibular ligament rupture. It was our opinion that such an interpretation of the arthrographic findings was not in keeping with the clinical findings or history, and that anterior tibiofibular ligament rupture was an unlikely complication of the common type of ankle inversion injury. It is possible that site and size of capsular and ligamentous rupture are not the only factors governing the extent and pattern of contrast leakage from the joint into the soft tissues. In this study it was tried to ascertain whether it is possible to distinguish arthrographically rupture of the anterior talofibular and/or tibiofibular

ligament from non-specific capsular rupture and furthermore to define the role of the extra-articular (soft tissue) structures in governing the contrast leakage pattern.

5.2. Review of literature

In anterior talofibular ligament rupture, there is contrast leakage below and lateral to the lateral malleolus. On the lateral view some authors describe a contrast free zone, anterior to the distal tibial region (fig. 19). This contrast free zone is absent in anterior tibiofibular ligament rupture and accompanying capsular rupture is indicated by absence of the tibiofibular recess (Broström 1965, Dalinka 1980, Fussel 1973, Sanders 1976, 1977, Spiegel 1975, Stepanuk 1977) (fig. 19).
Hence, one could conclude that anterior talofibular ligament rupture is often accompanied by rupture of the anterior tibiofibular ligament (partial rupture of the syndesmosis). However, it is a commonly held opinion that rupture of the syndesmosis is a result of gross and serious injury (Campbell 1971, Cedell 1975, Colton 1976, Gerlach 1978, Kleiger 1974, Lauge-Hansen 1976).
In cases of gross inversion trauma, resulting in rupture of all lateral ligaments together with fracture of the lateral malleolus, there may also be rupture of the tibiofibular syndesmosis, because the largest diameter of the talus endorotates and supinates in the ankle mortise and ruptures the syndesmosis (Weber 1972). More often, rupture of the syndesmosis is accompanied by rupture of the medial structures and/or fracture of the medial malleolus (Broström 1964, Campbell 1971, Cedell 1975, Colton 1976, Lauge-Hansen 1976, Muschter 1974, Tausch 1978 A).
Both Lindholmer (1978) and Percey (1969) describe the contrast leakage pattern in isolated capsule rupture. Percey distinguishes this type of lesion from a combined rupture of the anterior talofibular ligament and anterior capsule. Usually the latter results in a more extensive contrast escape, both laterally and anteriorly. The capsule tears beyond the limit of the attachment of the anterior talofibular ligament to the joint capsule. According to Vuust (1980 A, B) it is difficult to distinguish capsular from anterior talofibular ligament rupture. The arthrographic findings and their interpretation in lateral ligament ruptures are often confirmed by surgical exploration, and the reliability of ankle arthrography is said to be high (Ala-Ketola 1975, Broström 1965 A, Lindholmer 1978, Prins 1978, Sanders 1976, 1977). Surgical confirmation of arthrographically diagnosed syndesmosal rupture is also found in the literature (Ala-Ketola 1975, Broström 1965 A). Both Lindholmer (1978) and Percey (1969) confirm their arthrographic data on capsular rupture surgically.

5.3. Important anatomic structures

The ankle joint capsule is reinforced laterally and medially by fibre tracts called ligaments, although there may be other reinforcing capsular bands of varying thickness which have a more or less craniocaudal direction. The capsule is more lax anteriorly and posteriorly where it may form recesses. The anterior and posterior talofibular ligaments are integral with the capsule. In our opinion, the calcaneofibular ligament is also a capsular structure, associated with the common peroneus tendon sheath. The anterolateral capsular structures are related to the more superficial structures of the fibrous tendon sheaths and retinacula. In addition to the anterior and posterior synovial membrane recesses already mentioned, there is also a recess between the distal tibia and fibula, lying between the anterior and posterior tibio-

fibular ligaments, called the tibiofibular recess. Both anterior tibiofibular and talofibular ligaments are continuous with the periosteum of the lateral malleolus and are inserted on its mid-anterior surface, their fibres being more or less at right angles to each other.

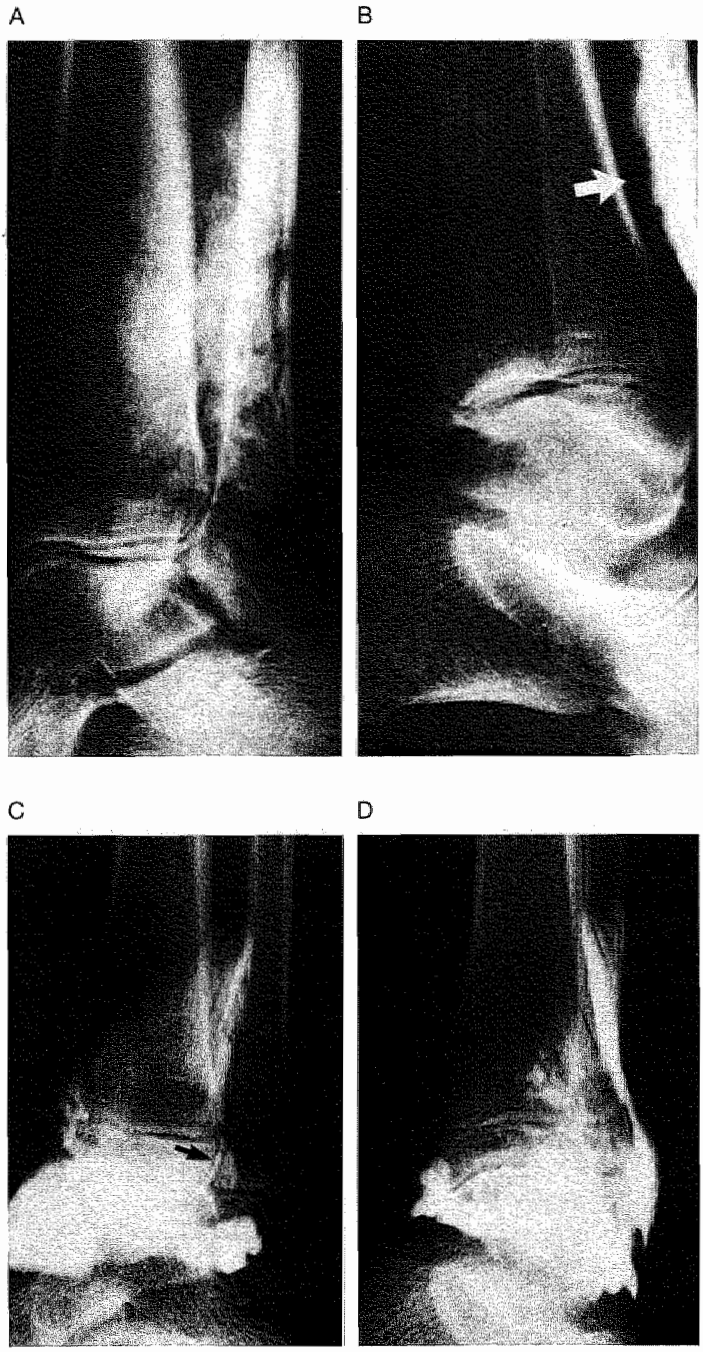

Figure 19

a, b. Contrast leakage in cranial direction, with contrast free zone on lateral view (arrow), without visible tibiofibular recess on A-P view.
c, d. Contrast leakage in cranial direction, without contrast free zone on laterial view, with visible tibiofibular recess on A-P view (small arrow).

5.4. Methods and materials

Further study of the subject was undertaken as follows:

1.

40 ankle arthrograms, in which there existed well developed contrast leakage and in which there was a lateral view of good quality available, were evaluated for the presence or absence of three selected diagnostic features:

a.

a contrast free zone on the lateral view (considered in the literature to indicate integrity of the anterior tibiofibular ligament).

b.

leakage below and lateral to the lateral malleolus and extravasation in a cranial direction (considered in the literature to indicate rupture of the anterior talofibular ligament).

c.

a contrast filled tibiofibular recess (considered in the literature to exclude capsular rupture accompanying tibiofibular ligament rupture).

In 14 cases the findings of surgical exploration were available. Nine of these patients are the first of a group of 50 patients operated upon, and described in further detail in chapter 7.

This group of 50 patients constituted one of three trial groups described in part 3 of this thesis. The remaining five patients were operated upon prior to the commencement of this clinical trial, because, at that time, surgical repair of ruptured ligaments was thought to be essential to the restoration of normal ankle function. In no case was the inversion trauma complicated by fracture and/or dislocation.

2.

Twenty cadaver ankles were studied for the effect of inversion and eversion stress on the various ankle ligaments after various stages of dissection of the capsule and its reinforcements.

3.

Cadaver ankle arthrography after division of different structures was performed on twenty ankles and the pattern of contrast extravasation studied. One or more of the following classical anatomic structures were divided: anterior tibiofibular ligament, anterior talofibular ligament, the tibiofibular recess and the remaining parts of the joint capsule. The tibiofibular recess was opened in a cranial direction, through an incision in the anterior capsule. Care was taken to avoid opening the joint cavity, when dividing the anterior tibiofibular ligament. After each dissection the wound was closed in layers as carefully as possible, and an arthrogram was performed with 8 ml of Isopaque-amin 220®, and on occasion followed by a double contrast arthrogram by the injection of some air.

4.

In the course of the cadaver studies, technical errors resulted from time to time in the contrast medium being injected only into the soft tissues, resulting in two main contrast patterns radiologically: diffuse or more layered contrast spread. Therefore, in several other specimen, about 8 ml contrast was deliberately injected into the soft tissues, and the effect was evaluated radiologically. The injections were made subcutaneously and as deep as possible anterior to or at the tip of the lateral malleolus, taking care not to inject into the ankle joint cavity.

5.5. Results

5.5.1. Cadaver study

It was found that forced inversion of the intact ankle places primary stress on the three lateral ligaments and anterolateral part of the capsule. If a further capsular rupture occurs in addition to the disruption of the anterior talofibular ligament, it occurs progressively along the line of its junction to the anterior tibiofibular ligament, in the direction of the tibiofibular recess and may even extend into this recess or beyond.

Subsequent successive division of the lateral ligaments produces an increasing talar tilt, although this was not measured radiologically. That portion of the capsule just anterodistal to, and continuous with the periosteal junction of the anterior tibiofibular ligament, is usually non-reinforced, thin, lax and ruptures easily. Increased tension on the anterior tibiofibular ligament could not be produced by inversion stress alone, and was only detectable when extreme inversion stress was applied following division of all lateral ligaments and capsular reinforcements, retinacula and fibrous tendon sheaths. It was further noted that progressive division of the capsular reinforcing bands, retinacula and fibrous tendon sheaths, resulted in a correspondingly increased talar tilt. On the other hand, only moderate eversion stress had to be applied to produce damage to the syndesmosis.

5.5.2. Cadaver arthrogram study

After division of the anterior talofibular ligament, there was contrast leakage below and lateral to the lateral malleolus (fig. 20). There was no contrast leakage however, if only the anterior tibiofibular ligament was divided. Incisions of various sizes and at various sites in the joint capsule did not result in important differences in contrast leakage. No correlation was found between the existence of a contrast free zone and the presence or absence of a rupture of any ankle joint structure. If the anterior talofibular ligament was left intact, no contrast leakage occurred below and lateral to the lateral malleolus, but leakage did occur in various cranial directions (figs. 21, 22, 23). Incision of the tibiofibular recess resulted in similar extravasation patterns to those of other capsule ruptures. The pattern of contrast spread, however, was inevitably influenced by leakage back through the capsular incision, however

Figure 20

Cadaver arthrogram showing contrast extravasation pattern after division of a normally developed anterior talofibular ligament, resulting in leakage distal and lateral to the lateral malleolus.

Figure 21

Extravasation (cadaver arthrogram) after anteromedial capsular incision.

carefully this was repaired. Deliberate extra-articular contrast injection at subcutaneous level resulted in a diffuse contrast leakage pattern and at deeper levels produced a more layered pattern (fig. 24). Figure 25 shows the arthrogram typical of patients in whom, by accident, the contrast was only partly injected into the joint itself, most of the contrast thereby entering the soft tissues. This contrast spread pattern resembles the pattern found in subcutaneous and deep contrast injections on cadavers.

5.5.3. Evaluation of arthrograms on patients

Arthrographic findings

In 8 out of 40 arthrograms on lateral films, a contrast free zone was noted. In the other 32 cases there was no contrast free zone. The presence of a contrast filled tibiofibular recess was found in 5 of the 8 cases in which a contrast free zone existed and in 16 of the 32 cases where there was no contrast free zone (table 3). In 34 arthrograms there was contrast leakage in a cranial direction and below and lateral to the lateral malleolus. In six patients there was no leakage below and

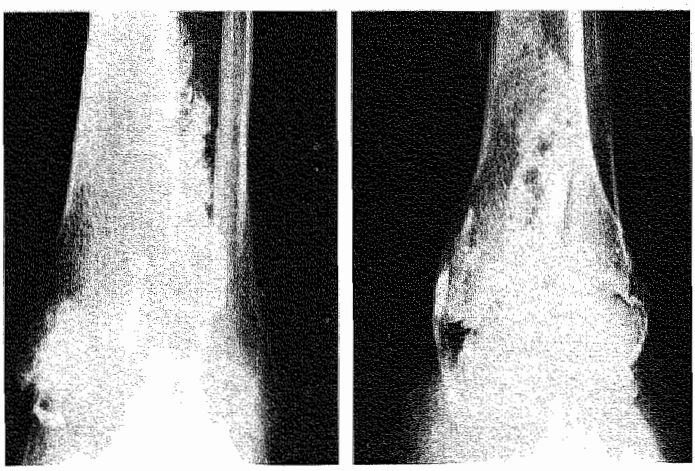

Figure 22

Examples of extravasation pattern (cadaver arthrogram) after incision of the capsule at tibiofibular recess level (see text).

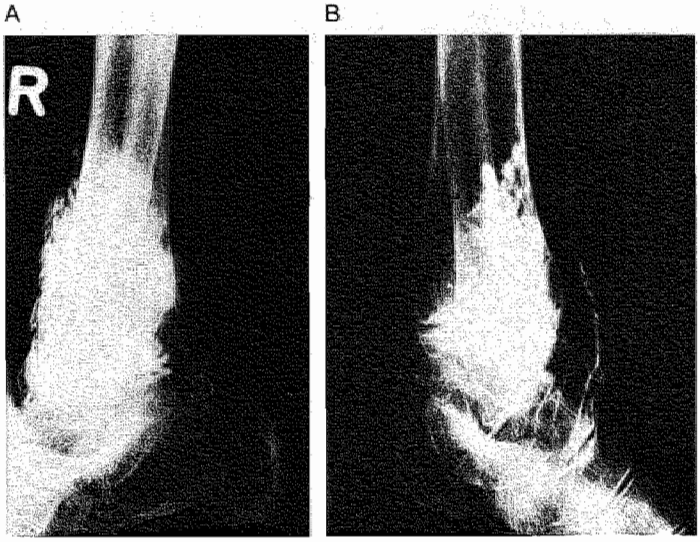

Figure 23

A) Extravasation pattern (cadaver arthrogram) after anterolateral capsular incision and division of the anterior tibiofibular ligament.
B) Extravasation pattern (cadaver arthrogram) after anterolateral capsular incision.

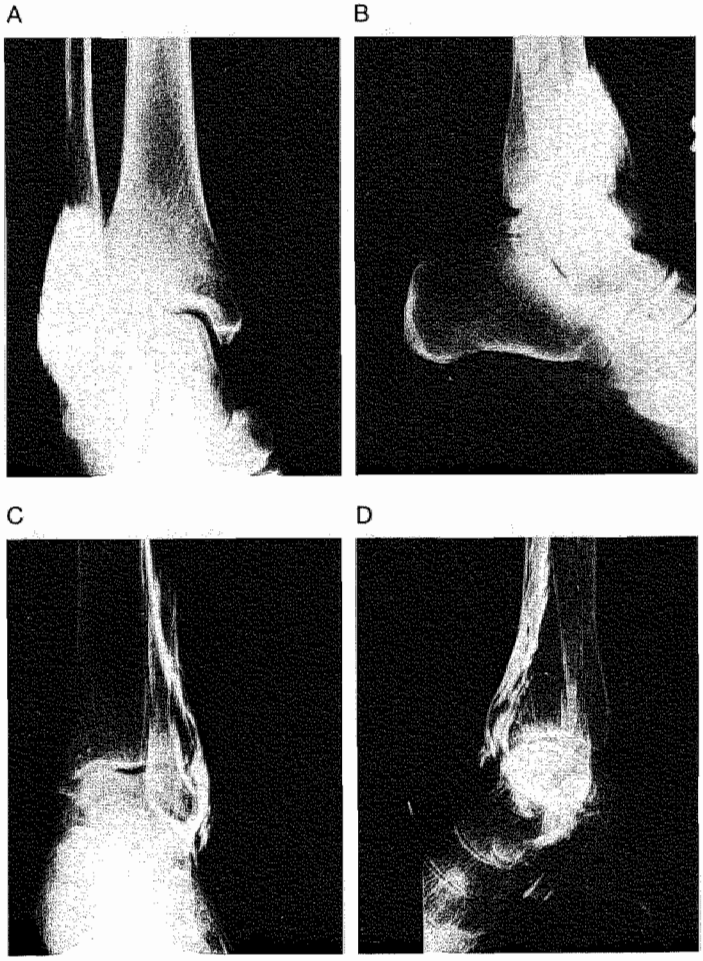

Figure 24

a, b. Deliberate superficial extra-articular contrast injection.
(Note: diffuse pattern of spread).
c, d. Deliberate deep extra-articular contrast injection.
(Note: layered pattern of spread).

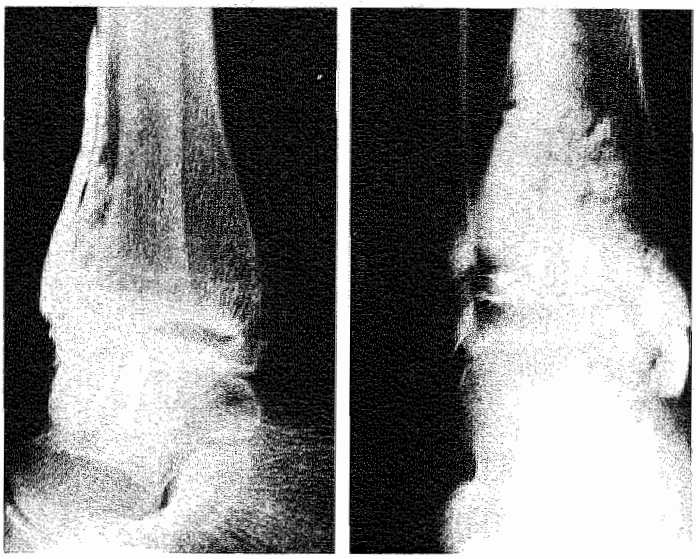

Figure 25

Attempted 'arthrogram' of a patient in which the contrast accidently leaked into the soft tissues. Compare with figure 24.

lateral to the lateral malleolus, but leakage had occurred only in a more cranial direction on A-P view.

Surgical findings

Operation was performed in fourteen patients (table 3) (figs. 26, 27). In no case did operation confirm any abnormality or disruption of the syndesmosis. In all but one case (in which there was an isolated rupture of the anterolateral capsule) the

Table 3

	Number of patients:	Tibiofibular recess on arthrogram Present:	Absent:
Contrast free zone	8	5	3
No contrast free zone	32	16	16
	Total number of patients:	Number of patients operated:	Number with intact syndesmosis at operation:
Contrast free zone TF recess filled	5	3	3
Contrast free zone TF recess not filled	3	1	1
No contrast free zone TF recess filled	16	5	5
No contrast free zone TF recess not filled	16	5	5

Comparison between arthrographic criteria for anterior tibiofibular ligament rupture and surgical findings. TF recess = talofibular recess.

Figure 26

No leakage below and lateral to the lateral malleolus. No visible tibiofibular recess. No contrast free zone on lateral view (not shown). Probable diagnosis: capsular rupture only, confirmed surgically.

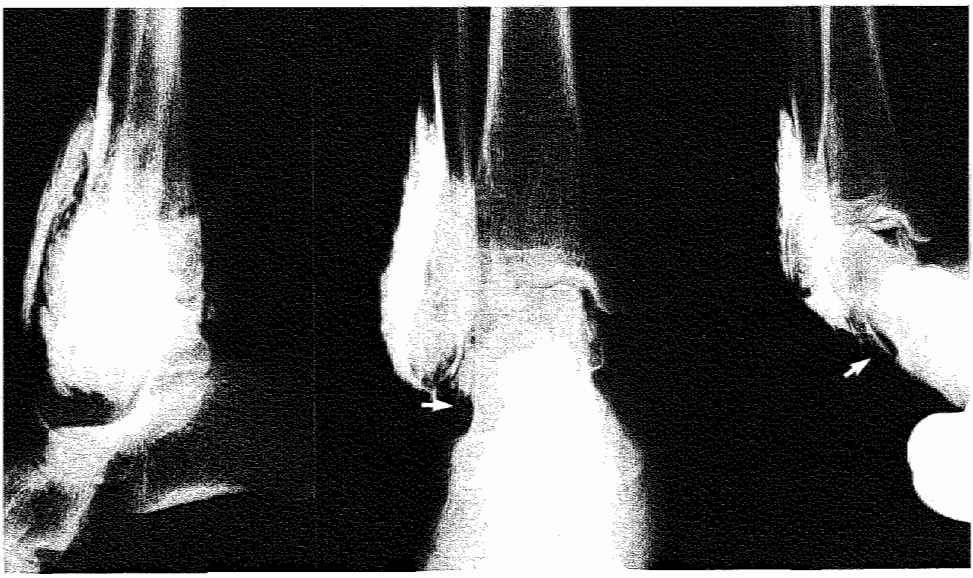

Figure 27

No contrast free zone on lateral view, no visible tibiofibular recess. At operation, no syndesmosal damage, but all three lateral ligaments ruptured. Talar tilt difference 42°, filling of the peroneus tendon sheath (arrow).

minimum finding was a ruptured anterior talofibular ligament. Particularly close inspection of the syndesmosal region was possible in cases of total lateral ligament rupture. In cases of ligamentous rupture with an accompanying capsule rupture, the latter took place along the border of the periosteal junction with the anterior tibiofibular ligament, but left this ligament intact. This was also the site of the capsule rupture in the one patient with an isolated capsule rupture.

5.6 Discussion

In no case did operation show any abnormality or disruption of the syndesmosis, where suggested by hitherto accepted arthrographic criteria. Neither the presence or absence of a contrast free zone, nor the filling or otherwise of the tibiofibular recess gave any information as to the integrity of the anterior tibiofibular ligament. Study of the literature and the results of this study indicate that it is very unlikely that rupture of the anterior tibiofibular ligament is a frequent consequence of the common inversion sprain of the ankle, even if complicated by rupture of one or more lateral ligaments. Furthermore, the anterior tibiofibular ligament is structurally so strong that it is highly unlikely that a capsular rupture could extend into this ligament. This study indicates that in isolated capsule rupture, contrast leakage is in an anterocranial direction only, and that further analysis of the exact leakage pattern will not yield additional diagnostic information. In 6 of the 40 arthrograms there was no leakage below and lateral to the lateral malleolus but leakage had occurred in a cranial direction. We interpreted this as indicating only isolated capsule rupture, as confirmed operatively in one patient in whom this particular contrast leakage pattern was not recognized, the patient being thought to have an anterior talofibular ligament rupture. In a subsequent series, described in chapter 7, there was also one similar case. In both cases, capsule rupture had occurred just distal to the periosteal junction with the anterior tibiofibular ligament as previously described.

Physiologically, the ankle joint is protected against extremes of all normal movements of the foot by the shape of the articular surfaces and the whole system of reinforcing connective tissue structures already described in chapter 2, although pathological forces do rupture these structures. Unusually, trauma may occur in such a manner as to cause internal forces in unprotected directions, and it is likely that this is the mechanism of isolated capsule ruptures.

Although some authors suggest that it is possible to use the presence or absence of a contrast free zone or filled tibiofibular recess as indicators of integrity of the anterior tibiofibular ligament, in our study such a correlation was not found. It is therefore impossible to differentiate arthrographically between ruptures of the capsule or anterior tibiofibular ligament, even in cases of serious trauma, because it is very unlikely that an isolated rupture of the anterior tibiofibular ligament occurs without accompanying capsule rupture. This study has shown that all above mentioned leakage patterns may occur in the absence of rupture of the anterior tibiofibular ligament.

Indeed, this type of serious injury (syndesmosal rupture) is best diagnosed from the clinical and normal radiological signs, and arthrography has nothing to add and may even be contra-indicated in cases of compound fractures.

By contrast, a clear arthrographic distinction can be made between capsule and anterior talofibular ligament rupture. This study also indicates that the pattern of contrast spread is determined by the nature of ligamentous rupture, the arrangement

of the soft tissues and the extent of any traumatic damage sustained by them. This may be illustrated by two patients in both of whom there existed a large haematoma, which caused the contrast to be separated from the bony structures to a significant degree (fig. 28).

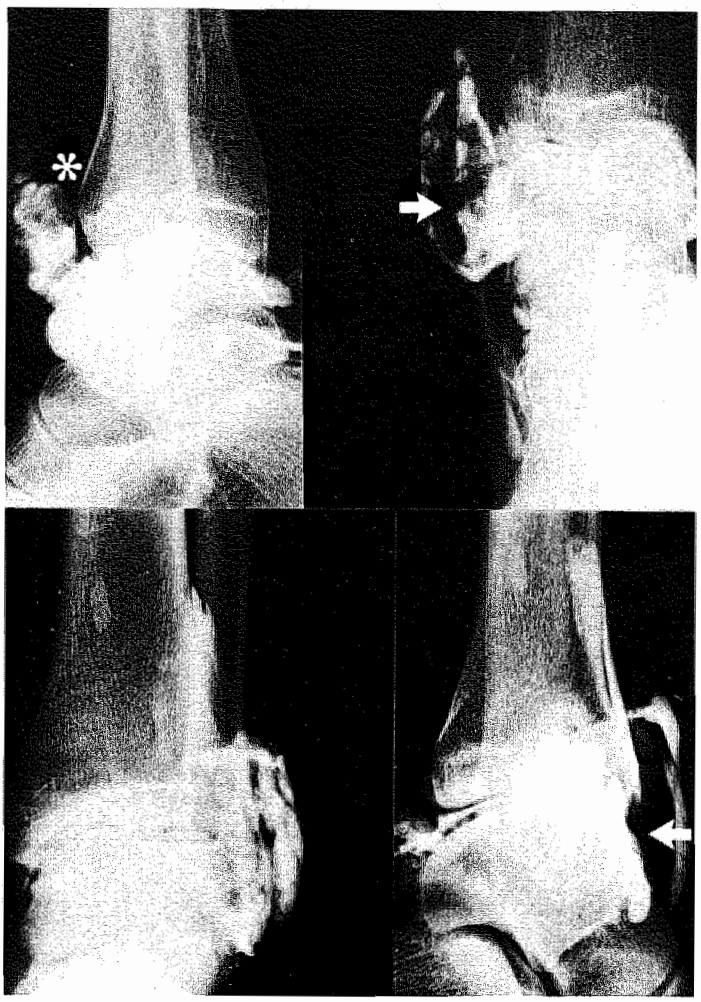

Figure 28

Arthrogram of two patients with large anterolateral and anterior haematomata. Note the large distance between the contrast and bony structures (asterisk, arrows).

5.7. Conclusions

From literature study, surgical findings and cadaver experiments, it is unlikely that, in an inversion type ankle sprain, rupture of the anterior tibiofibular ligament frequently accompanies rupture of the capsule and its reinforcing ligaments. Contrary to the experience of other authors, the presence or absence of 1) a contrast free zone, 2) the tibiofibular recess or 3) both together, on ankle arthrography was found to be in no way indicative of rupture of the anterior tibiofibular ligament. Leakage below and lateral to the lateral malleolus indicates rupture of the anterior talofibular ligament.

Contrast leakage out of the joint into the soft tissues without leakage below and lateral to the lateral malleolus indicates rupture of the joint capsule. Contrast spread in the soft tissues is determined by the arrangement of and damage to the connective tissue apparatus and the soft tissues, and also the size of the haematoma.

6. The significance of filling of tendon sheaths and talotarsal joints in ankle arthrography

6.1. Introduction

The presence or absence of arthrographic filling of the peroneus tendon sheath may be of significance in the diagnosis of rupture of the calcaneofibular ligament, but there is disagreement about the validity of this sign.

According to several authors (Castaing 1972, Evans 1979, Percey 1969, Prins 1978, Vuust 1980 A, B, Weber 1972) the classification of patients with ankle inversion trauma into those with minor and major lesions, according to the number of ruptured lateral ligaments, may have both therapeutic and prognostic applications. Whereas single ligament rupture is regarded as a minor lesion, all multiple ruptures are major lesions. There is also doubt as to the significance of the commonly observed arthrographic filling of the flexor tendon sheaths and talotarsal joints. This study seeks to elucidate these problems.

6.2. Review of literature

There is an 8 to 22% reported incidence of contrast filling of the mediodorsal (flexor) tendon sheaths in otherwise normal (chaper 4) arthrograms (Broström 1964, 1965 A, Goergen 1980, Den Herder 1961, Lanz-Wachsmuth 1972, Mehrez 1970, Olson 1969, Stepanuk 1975).

Similarly there is a 0 to 16% reported incidence of communication between the ankle and posterior talocalcaneal joints (Broström 1965 A, Goergen 1980, Lanz-Wachsmuth 1972, Mehrez 1970, Prins 1978, Resnick 1974). Confusingly, Broström (1965 A) also states that filling of the talotarsal joints may be traumatic in origin.

Some authors (Ala Ketola 1977, Broström 1965 A, Kaye 1977, Makhani 1972, Olson 1969, Prins 1978, Sanders 1972, 1977) consider peroneus tendon sheath filling to be pathological, usually indicative of calcaneofibular ligament rupture, the diagnostic reliability being given as 70 to 98% by Broström (1965 B), Lindholmer (1978) and Prins (1978). Others (Gerbert 1975, Fordyce 1972, Fussell 1973, Haage 1967, Schweigel 1977, Tóth 1974, Zinnman 1979) consider such filling to indicate a normal connection between peroneus tendon sheath and joint cavity, the incidence being given as 14% by Gordon (1970) and 26% by Pascoët (1975).

However, filling may also result from previous extensive ruptures, and according to Broström (1965 A) this was the case in about 10% of his series.

According to some authors (Prins 1978, Speeckaert 1978), isolated rupture of the calcaneofibular ligament can occur as a result of hyperdorsiflexion trauma, in which case there is isolated contrast leakage into the peroneus tendon sheath, but this is extremely rare.

6.3. Important anatomic structures

As described in chapter 2, the fibres of the calcaneofibular ligament, like the other reinforcing lateral ligaments, are capsular structures. For most of their length, these fibre tracts are intimately related on their lateral aspect to the common tendon sheath of the peroneus longus and brevis muscles. The tendon sheaths of the flexor hallucis longus, flexor digitorum longus and tibialis posterior muscles, lie on the mediodorsal side of the ankle. Together with the rest of the tarsus, the talus forms a two-compartment joint, comprising the talocalcaneal or subtalar compartment, posteriorly, and the talocalcaneonavicular compartment, anteriorly. The subtalar joint is formed by the posterior articular facets of talus and calcaneus. The anterior articulation comprises the intermediate and ventral articular facets of the head of the talus, which articulate with a socket by the anterior facet of the calcaneus, the plantar calcaneonavicular ligament and the posterior facet of the navicular bone. Normally there is no communication between the two talotarsal joints.
The associated ligamentous structure is as follows:
the posterior talocalcaneal or subtalar joint capsule is reinforced by the lateral and medial talocalcaneal ligaments, the anterior capsule is reinforced by the talonavicular and calcaneonavicular ligaments, while the interosseous talocalcaneal ligament (incidently, one of the strongest ligaments in the body), is entirely extra-capsular. The superficial layers of the lateral talocalcaneal ligament are closely associated with the deeper fibres of the calcaneofibular ligament.

6.4. Methods and materials

In order to investigate the possibility of a normal connection between the peroneus tendon sheath and the ankle joint cavity, bilateral ankle arthrography on 40 non-traumatized cadavers was performed. Contrast medium (8 ml Isopaque-amin 220®) followed by as much air as possible was injected in an attempt to fill the peroneus tendon sheath by distension. The cadavers were aged between 50 and 80 years at the time of death, and no forceful manipulations of the ankles were performed post mortem. The results were compared with data from 450 patients with both normal and abnormal arthrograms after inversion trauma, 80% of whom were aged between 15 and 40 years. All arthrograms were performed as described in chapter 4 and the diagnostic criteria applied are described in chapters 4 and 5.
In the three groups (cadavers, patients with normal arthrograms following inversion trauma, and patients with abnormal arthrograms following inversion trauma), the percentage incidences of medial tendon sheath, talotarsal joints and peroneus tendon sheath filling, were compared.
Twenty patients, with a history of inversion trauma ten days to six months previously, were submitted to ankle arthrography on account of persistent pain, swelling or subjective feelings of instability.

6.5. Results

No peroneus tendon sheath filling was found in either normal arthrograms after inversion trauma or in distension arthrography on cadavers, which contrasts with the 42.6% incidence of filling in the abnormal arthrogram group, in which the minimum damage was an anterior talofibular ligament rupture as judged by the normal criteria (table 4). This difference is significant ($p < 0,05$). The incidence of flexor tendon

sheath filling was 13.3% in normal arthrograms, 12.6% in abnormal arthrograms and 15% in cadavers (table 4). The corresponding incidences of subtalar joint filling were 12%, 13% and 12.5% respectively (table 4).
Filling of the talocalcaneonavicular joint (fig. 30) occurred only five times in total, but at least once in each group.
In the abnormal group, the percentage incidence of subtalar joint filling was 7.3% of those in which peroneus tendon sheath filling had occurred, and 5.7% of those in which peroneus tendon sheath filling was absent. The corresponding figures for flexor tendon sheath filling in relation to peroneus tendon sheath filling were 5.7% and 7.0% respectively (table 5). All these incidences show no statistically significant differences ($p < 0,05$).
Of the twenty patients with a history of old inversion trauma, two had demonstrable peroneus tendon sheath filling (fig. 29), and in both the contra-lateral side was normal.

Table 4

	Normal arthrogram: (n = 150)	Abnormal arthrogram: (n = 300)	Cadaver arthrogram: (n = 80)
Filling of talocalcaneal joint	18 (12%)	39 (13%)	10 (12.5%)
Filling of flexor tendon sheaths	20 (13.3%)	38 (12.6%)	12 (15%)
Filling of peroneus tendon sheath	0 (0%)	128 (42.6%)	0 (0%)

Comparison between percentage incidence of filling of talocalcaneal joint, flexor tendon sheaths and peroneus tendon sheath in patients with normal and abnormal arthrograms and in cadavers.

Table 5

	Pathological arthrograms (n = 300): Filling of peroneus tendon sheath present:	Filling of peroneus tendon sheath absent:
Filling of talocalcaneal joint	22 (7.3%)	17 (5.7%)
Filling of flexor tendon sheaths	17 (5.7%)	21 (7%)

Incidence of peroneus tendon sheath filling related to filling of the talocalcaneal joint and filling of the flexor tendon sheaths.

6.6. Discussion

Arthrographic peroneus tendon sheath filling could not be provoked by air contrast distension arthrography on cadavers, nor was it observed in patients whose ankle arthrograms following inversion trauma were otherwise normal. These results confirm majority opinion that the phenomenon is always pathologically significant. The fact that it is also independent of age indicates that degenerative factors play no part. Three different mechanisms producing peroneus tendon sheath filling are suggested:

1.
It occurs, together with contrast leakage around the lateral malleolus, after inversion trauma, and indicates anterior talofibular ligament rupture in combination with rupture of fibres of the calcaneofibular ligament and/or the wall of the peroneus tendon sheath.

2.
It occurs in isolation after acute pure hyperdorsiflexion injury and indicates isolated rupture of the calcaneofibular ligament. Such an occurrence is extremely rare and as there is no own experience with such trauma, we have to rely on the literature.

3.
It occurs in isolation in patients with a history of old inversion trauma with obvious rupture of lateral structures.
This could be demonstrated in two out of a group of twenty patients whose initial trauma had occurred between ten days and six months previously. In all twenty

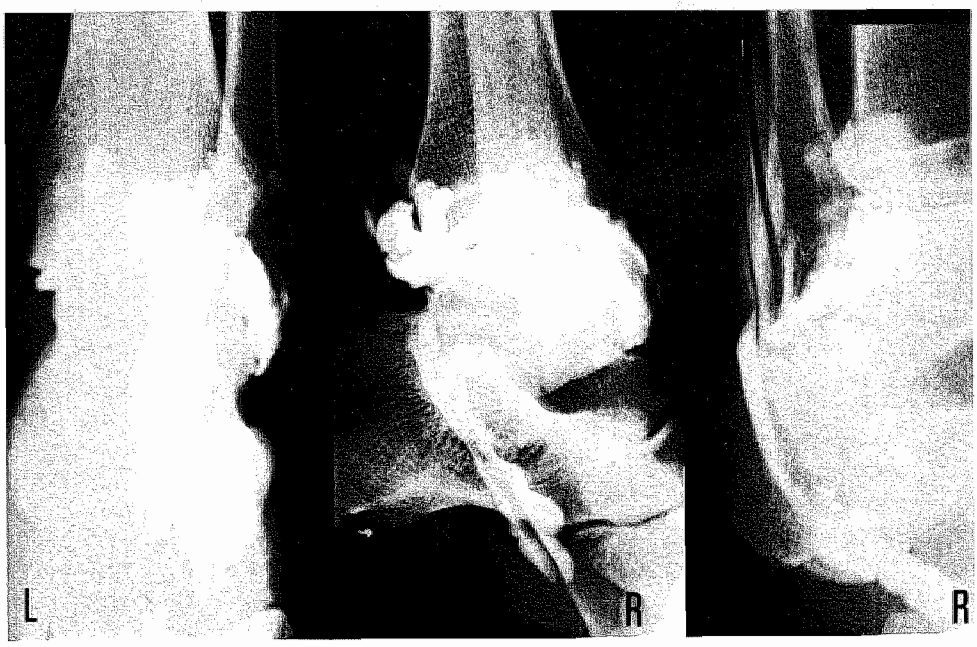

Figure 29

Ankle arthrogram performed several weeks after serious inversion trauma. The two views of the right ankle show a filled peroneus tendon sheath. Compare left ankle: no abnormality.

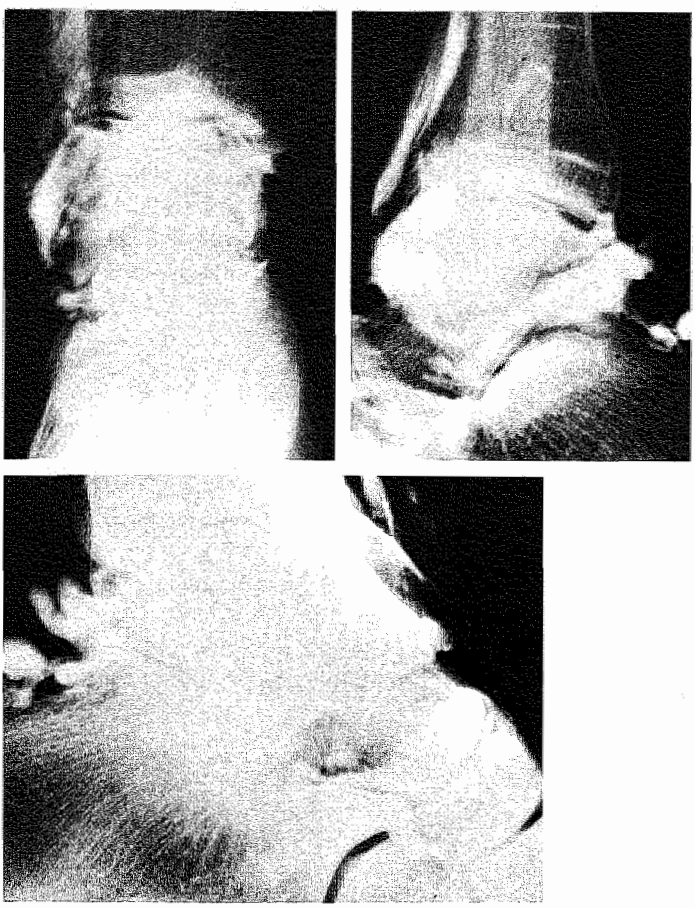

Figure 30

Patient with filling of subtalar and talocalcaneonavicular joints and rupture of anterior talofibular ligament.

patients, the clinical history and examination were such that one could have expected abnormal arthrography, had this been performed in the immediate post-traumatic period. However, the only late arthrographic findings were two cases of isolated filling of the common peroneus tendon sheath, whereas the contralateral side was normal.

The opinion of several authors, that a normal connection between the ankle joint cavity and the peroneus tendon sheath may exist, could not be confirmed. Though Gordon (1970) used standard projections, he demonstrated such filling only on lateral films, and not on anterior-posterior views. On lateral views it is generally not possible to distinguish between lateral and medial structures, in particular when they have a similar aspect.

Flexor tendon sheath filling occurred without significant differences in all three studied groups, and our percentage incidence is comparable with other figures in the literature. The incidence of subtalar joint filling in the three groups was not significantly different, and the figures are comparable with those in the literature (Broström 1965 B, Mehrez 1970, Olson 1969, Prins 1978, Resnick 1974).

There was no statistically significant difference in the incidence of subtalar joint and flexor tendon sheath filling in relation to peroneus tendon sheath filling. Functionally the subtalar joint is important, together with the ankle joint, for inversion and

eversion movements of the foot (Resnick 1974), and the lateral ligamentous structures of both joints are closely related (Prins 1978). It could therefore be argued that inversion trauma may damage the lateral connective tissue structures of both joints, resulting in a traumatic connection between them, and this would be demonstrable arthrographically. The findings in the following patient (fig. 31) could be interpreted in relation to these postulates. A patient presented with a history of ankle inversion trauma and arthrography performed in the immediate post-traumatic period, was normal. Treatment was conservative. The patient presented again six months later, following a further inversion injury to the same ankle, and the clinical signs included pain, swelling and haematoma. Arthrography was repeated and showed evidence of lateral ligamentous damage, with filling of the subtalar joint cavity, which, because absent on the first arthrogram, was presumed to be traumatic in origin.
Talocalcaneonavicular joint filling was so infrequent that it is not possible to discuss its significance.

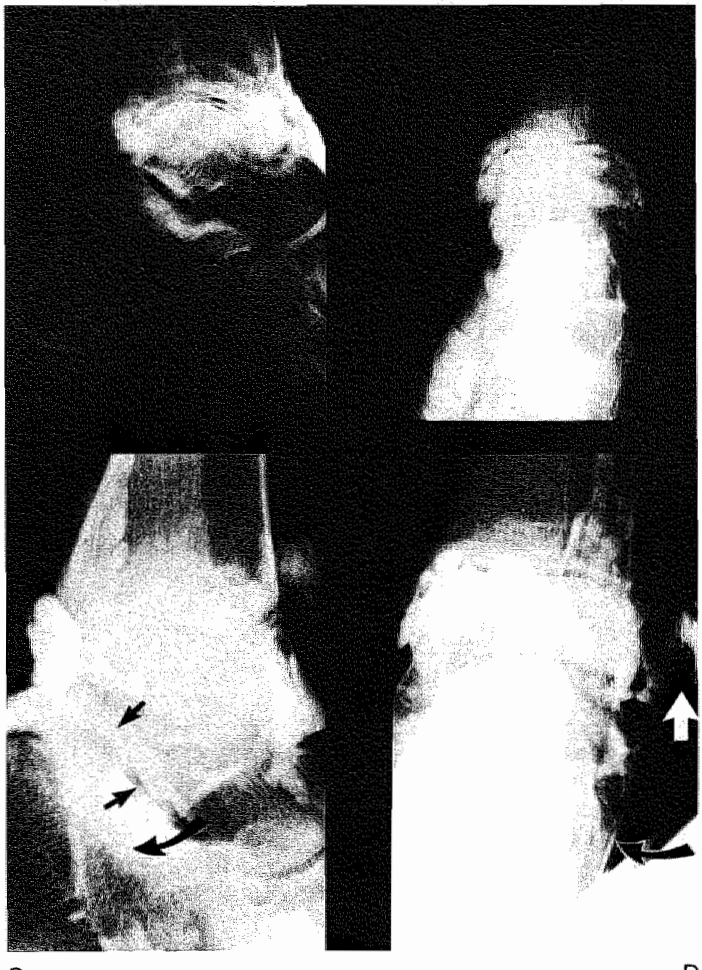

Figure 31

This patient sustained inversion trauma on two occasions six months apart.
a, b. Arthrogram after first trauma: no abnormality, no filling of talocalcaneal joint or tendon sheaths.
c, d. Arthrogram after second trauma: evidence of anterior talofibular ligament rupture (large arrow). Filling of peroneus tendon sheath (curved arrow) and talocalcaneal joint (short arrows).

6.7. Conclusions

Arthrographic filling of the flexor tendon sheaths and the subtalar joint are common findings in normal and abnormal arthrograms, a traumatic cause cannot be differentiated arthrographically, whereas filling of the common peroneus tendon sheath is always of pathological significance.

7. Arthrography, talar tilt and surgical findings after inversion trauma of the ankle – general evaluation

7.1. Introduction

The purpose of the study described in this chapter was to test the validity of the criteria suggested by previous studies as summarized in table 6. In a prospective study of 50 patients (group A of the clinical trial described in part 3) the arthrographic diagnoses were compared with surgical findings. In a retrospective study of the diagnostic reliability of inversion stress examination in the same 50 patients, the use of general anaesthesia was compared with local anaesthesia as part of the arthrographic technique, and both sets of results were compared with the surgical and arthrographic data. Finally, all arthrograms performed during a four years' study period were re-examined in a general study and in 436 it was possible to compare the results of inversion stress examination and arthrography.

Table 6
Summary of diagnostic arthrographic criteria

Normal arthrogram:
Contrast margin smooth, well defined, showing well developed recesses and no leakage; possible communication with flexor tendon sheaths and subtalar joint.

Abnormal arthrogram:

1. Anterior talofibular ligament rupture:	1. leakage below and lateral to the lateral malleolus.
2. Combined anterior talofibular and calcaneofibular ligament rupture:	2. as (1) above + peroneus tendon sheath filling and/or talar tilt difference greater than 10°.
3. Combined anterior and posterior talofibular and calcaneofibular ligament rupture:	3. no specific criteria; pattern (1) and/or (2) possible; gross instability (talar tilt difference greater than 20°).
4. Capsule rupture:	4. all other leakage patterns.

7.2. Methods and materials

7.2.1. Prospective study

Out of a total of 700 patients undergoing ankle arthrography, 50 were surgically explored and the surgical findings permitted a critical evaluation of the arthrographic diagnostic interpretation based on criteria listed in table 6. The selection of this patient group is described in part 3. Arthrographically diagnosed isolated capsule ruptures were considered to be minor lesions and therefore not operated upon. Patients operated upon were aged between 15 and 56 years (80% between 20 and 40 years: 41 male, 9 female). At operation the following structures were examined: superficial structures, the joint capsule, ligaments and the peroneus tendon sheath. In the light of the work by Fussell (1973), Olson (1969), and Staples (1975), an attempt was made to correlate the size of the extravasated column of contrast medium lateral to the lateral malleolus with the size of anterior talofibular ligament rupture.

7.2.2. Retrospective study

Inversion stress examination under general anaesthesia, immediately prior to operation, was performed on 35 of the 50 patients operated upon, and the resultant talar tilt values were compared with the corresponding values obtained under local anaesthesia, and, in turn, with the arthrographic findings. All these results were then examined in the light of the surgical findings. In all inversion stress examinations, a talar tilt difference of at least 5.5° was considered to indicate pathology.

7.2.3. General study

This comprised examination of three groups of patients in the following manner:

Group 1

In the course of the clinical trial, a total of 264 arthrograms was performed. Of the 170 abnormal arthrograms, 150 were subdivided into three therapeutic groups (part 3), and the total number of patients fulfilling the minimum diagnostic criteria of pathology for both inversion stress examination and arthrography (a minimum talar tilt difference of 5.5° and contrast leakage distal and lateral to the lateral malleolus respectively) was evaluated. The remaining twenty abnormal arthrograms were excluded from the trial, because of isolated capsular lesions or technical and administrative errors.

Group 2

The total number of arthrograms performed prior to the commencement of the clinical trial was 172, of which 114 were abnormal, and of these, 70 were examined by inversion stress without anaesthesia, prior to arthrography. The resultant talar tilt values were compared with those obtained under local anaesthesia. In 146 patients (of which 52 were arthrographically normal) the incidence of haemarthrosis was studied.

Group 3

Groups 1 and 2 were combined and the unilateral talar tilt data were compared with previously obtained data on the 200 ankles of 100 normal subjects (chapter 3). Additionally, the talar tilt differences in the 152 patients with normal arthrograms were compared with the values in the 100 normal subjects.

7.3. Results

7.3.1. Results of prospective study

7.3.1.1. Surgical results (table 7)

Findings were as follows: 49 cases of capsule rupture of variable size, 48 of anterior talofibular ligament rupture, of which 4 were partial, and 31 of calcaneofibular ligament rupture. Additionally there were 32 cases of peroneus tendon sheath pathology (rupture of the medial wall with or without filling with blood) of which 23 had an accompanying calcaneofibular ligament rupture. One case of an isolated capsule rupture was found (table 7, patient 22) and in one other case (table 7, patient 17) there was no clear rupture of capsule or ligament, but there was a hypoplastic anterior talofibular ligament and a blood-filled peroneus tendon sheath. There were four cases in which the inferior extensor retinaculum was ruptured.

7.3.1.2. Surgical evaluation of the diagnostic arthrographic criteria (tables 7 - 12)

7.3.1.2.1. **Anterior talofibular ligament rupture** (tables 7, 8 and 11)
This was confirmed in 48 out of 50 patients in whom the diagnosis had been made arthrographically. In four patients the rupture was partial, but this could not be distinguished arthrographically (fig. 32). Of the remaining two, in one there was an isolated capsule rupture and in the other no rupture of capsule or ligaments was found.

7.3.1.2.2. **Calcaneofibular ligament rupture** (tables 7, 8, 9, 10 and 12)
Of 31 cases of calcaneofibular ligament rupture, diagnosed surgically, 21 had associated anterior talofibular ligament rupture and 10 had associated rupture of both anterior and posterior talofibular ligaments. Out of these 31 patients, 23 (72%) had filling of the peroneus tendon sheath, a finding which occurred overall in 32 of the 50 patients operated upon. In all these 32 cases, surgical lesions were found: rupture of the medial wall of the tendon sheath, blood in the tendon sheath, rupture

A B

Figure 32

Two patients, both with partial anterior talofibular ligament rupture (confirmed at operation).
a. Standard arthrogram film (not shown) normal. Late film after inversion stress: little contrast leakage with some filling of the peroneus tendon sheath.
b. Substantial leakage on first film. High contrast column.

of fibres of the calcaneofibular ligament or a combination of these. Operative findings in the 18 patients with no peroneus tendon sheath filling are summarized in table 12. Ten of the 21 patients with a combined rupture of anterior talofibular and calcaneofibular ligaments had a talar tilt difference greater than 10°, without filling of peroneus tendon sheath and 8 had a talar tilt difference greater than 10°, with filling of the peroneus tendon sheath.

Table 7
Comparison between talar tilt difference with local anaesthesia (A), general anaesthesia (B), and number of ligament ruptures diagnosed arthrographically (C) and operatively (D) in 35 patients.

M = male, F = female, CR = capsule rupture, * = see text.

Number	Name	M/F	A	B	C	D
1	W	F	16	13	2	3
2	J	M	1.5	6	1	1
3	B	M	0	14	1	2
4	B	M	15	15	2	2
5	H	M	13	15	2	2
6	H	M	1	8	2	3
7	C	M	6.5	6.5	2	1
8	K	M	8	8	2	2
9	J	M	5.5	5.5	2	1
10	C	M	4	22	1	1
11	G	M	6	12	1	1
12	H	M	7	9	2	1
13	B	M	5	9	1	1
14	B	M	4	27	2	3
15	N	M	45	51	3	3
16	B	M	10	16	2	2
17	S	M	7	8	2	0 (CR?)*
18	L	M	21	21	3	1
19	S	M	9	32	2	3
20	S	F	12	20	2	3
21	S	M	14	22	2	2
22	J	F	3	3	1	0 (CR)*
23	T	M	9	12.5	2	2
24	L	F	10	14	2	2
25	D	M	12	27	2	2
26	D	M	0	14	2	2
27	A	M	3	24	1	3
28	L	F	6	6	1	2
29	V	M	0	0	1	1
30	F	M	8.5	12	2	2
31	R	M	15	21	2	3
32	R	M	21	40	3	1
33	W	M	8	11	2	1
34	G	M	3	8	2	2
35	K	M	− 1	− 1	2	1

7.3.1.2.3. **Posterior talofibular ligament rupture** (tables 7 and 8)
Rupture of this ligament was surgically confirmed in ten cases, always in combination with anterior talofibular and calcaneofibular ligament rupture. In three cases (under local anaesthesia) there was a talar tilt difference greater than 20°. Six out of eleven patients who had a talar tilt difference greater than 20° under general anaesthesia, had posterior talofibular ligament rupture.

7.3.2. Results of retrospective study

Evaluation of inversion stress examination (tables 7, 13 and 15)
A talar tilt difference of less than 5.5° was found in 15 (30%) out of 50 patients under local anaesthesia and in 3 out of 35 (8%) patients under general anaesthesia. Of the 35 patients examined under general anaesthesia, a talar tilt difference of less than 5.5° under local anaesthesia was found in 11 patients, including the 3 already

Table 8
Comparison between the number of ligament ruptures diagnosed arthrographically and subsequent operative findings in 50 patients.

Arth = number of ruptured ligaments diagnosed arthrographically
Op = number of ruptured ligaments found at operation
N = number of patients
CR = capsule rupture
T = total number of patients

Arthrographic diagnosis correct:		Arthrographic diagnosis wrong:					
Arth + Op	N	Arth	Op	N	Arth	Op	N
1	8	1	2	5	2	1	7
2	15	1	3	1	3	2	1
3	3	2	3	6	3	1	2
					1	CR	1
					2	0	1
T	26 (52%)			12 (24%)			12 (24%)

Table 9
Correlation of peroneus tendon sheath filling with calcaneofibular ligament (CF lig.) rupture in 50 patients.
N = number of patients.

Contrast filling of peroneus tendon sheath	N	Operative findings CF lig. ruptured	CF lig. intact
present	32	23	9
absent	18	8	10

mentioned. The average talar tilt difference was 9.6° in the 50 patients under local anaesthesia and 15.2° in the 35 patients under general anaesthesia, in which the value under local anaesthesia had been an everage of only 8.8°. In one case the talar tilt difference was greater under local anaesthesia than under general anaesthesia (table 7, patient 1). The talar tilt difference was found to be greater on the healthy side in two patients examined under local anaesthesia, and in one of these two, under general anaesthesia also (table 7, patient 35). Of the 35 patients examined under general anaesthesia, the detailed figures for the 33 patients with ligamentous rupture are summarized in table 13.

Table 10
Presence or absence of ankle joint pathology (see text) in 32 patients with arthrographic filling of peroneus tendon sheath.
N = number of patients

	N	Pathology	
		present	absent
Filled peroneus tendon sheath	32	32	0

Table 11

Number table 7	Patient	TTDL	TTDG	HC
—	J	0.5	–	8
12	H	7	9	2
13	B	5	9	5
23	T	9	12.5	6

Comparison between talar tilt difference with local (TTDL) and general (TTDG) anaesthesia and height of contrast column (HC) lateral to the lateral malleolus in four patients with a partial rupture of the anterior talofibular ligament, as confirmed operatively.

Table 12
Operative findings in eighteen patients with no arthrographic filling of the peroneus tendon sheath.
CF lig. = calcaneofibular ligament; N = number of patients

	normal peroneus tendon sheath at operation: N	abnormal peroneus tendon sheath at operation: N
CF lig. rupture	3	5
CF lig. intact	6	4

7.3.3. Results of general study

Group 1 (tables 14 and 16)

In the course of the prospective study, one patient was found to have isolated capsule rupture at operation, and retrospectively the arthrogram was seen to be consistent with this finding. Retrospectively therefore, the final number of arthrograms indicative of ligamentous damage was 149. Of these, the number with a talar tilt difference of 5° or less was 51, of which eight had a 'negative' talar tilt difference, indicating that the talar tilt on the healthy side was greater than on the

Table 13

Ruptured ligaments	Local anaesthesia			General anaesthesia		
		TTD			TTD	
	N	Range	Mean	N	Range	Mean
1. Anterior talofibular ligament	12	—1-21°	7°	12	—1-40°	11.7°
2. Anterior talofibular ligament + calcaneo-fibular ligament	13	0-15°	9.0°	13	6-27°	14.1°
3. Anterior talofibular ligament + calcaneo-fibular ligament + posterior talofibular ligament	8	1-45°	13.1°	8	8-51°	24.5°
1 + 2 + 3	33	—1-45°	9.0°	33	—1-51°	15.6°

Comparison of talar tilt difference with local and general anaesthesia in 33 patients with surgically proven ligamentous rupture.

N = number of patients; TTD = talar tilt difference

Table 14

TTD	Group 1 N = 149	Group 2 N = 114
0 – 5°	51 (34.2%)	51 (44.7%)
≥5.5°	98 (65.8%)	63 (55.3%)

TTD = talar tilt difference; N = number of patients

Comparison of talar tilt difference in two groups of patients with an abnormal arthrogram (all examinations performed under local anaesthesia):
group 1: all trial patients,
group 2: 114 pre-trial patients with abnormal arthrograms.

traumatized side. The remainder had a talar tilt difference greater than 5°. Of the 94 patients with negative arthrograms, six (6.4%) had a talar tilt difference greater than 5° (range 5.5 - 8°).

Group 2 (tables 14, 16, 17 and 18)
Of the 114 patients with abnormal arthrograms, 51 had a talar tilt difference of 5° or less, using local intra-articular anaesthesia, and again some had negative differences as above (group 1) (table 14). Of the 70 patients with abnormal arthrograms examined without anaesthesia, 51 had a talar tilt difference of 5° or less, but on re-examination with intra-articular local anaesthesia, this number was reduced to 30 (table 17).
Of the 58 patients with negative arthrograms, 4 (7%) had a talar tilt difference greater than 5° (range 5.5 - 7°). Of 92 patients with abnormal arthrograms studied for the incidence of haemarthrosis, haemarthrosis was found in 65. Of the corresponding 54 patients with negative arthrograms, 10 were found to have haemarthrosis.

Group 3 (table 19)
The large number of results in this group are best presented in tabular form, and reference should be made to table 19.

Table 15
Comparison between talar tilt difference in 50 patients with local anaesthesia and in 35 patients with general anaesthesia.
Ligamentous rupture was presumed when talar tilt difference was ≥5.5°.
N = number of patients; T = total number of patients; TTD = talar tilt difference

	T	TTD ≥ 5.5° N	TTD < 5.5° N
Talar tilt difference with local anaesthesia	50	35 (70%)	15 (30%)
Talar tilt difference with general anaesthesia	35	32 (92%)	3 (8%)

Table 16

TTD	N = 152 patients with normal arthrograms	N = 100 normal subjects
0 – 5°	142 (93%)	91 (91%)
≥5.5°	10 (7%)	9(9%)

Comparison of talar tilt difference in 152 patients with normal arthrograms (examined with local anaesthesia) and 100 normal subjects.
N = number of patients; TTD = talar tilt difference

7.4. Discussion and general evaluation

The studies presented here demonstrate that the use of general anaesthesia is essential to high diagnostic reliability in inversion stress examination, but also clearly demonstrate the overall superiority of arthrography in the diagnosis of ligamentous pathology. The overall diagnostic reliability of 96% for abnormal arthrograms in the group of patients operated upon differs little from figures of other

Table 17

TTD	N = 70 without LA	N = 70 with LA
0 – 5°	51 (73%)	30 (42%)
≥5.5°	19 (27%)	40 (58%)

TTD = talar tilt difference; LA = local anaesthesia; N = number of patients
Comparison of talar tilt difference in 70 patients with abnormal arthrograms, firstly without any anaesthesia and then with intra-articular local anaesthesia.

Table 18
Incidence of haemarthrosis in normal and abnormal arthrograms.

	Haemarthrosis present N	absent N	T
Abnormal	63 (68.5%)	29 (31.5%)	92
Normal	10 (19%)	42 (81%)	52

N = number of patients; T = total number of patients

Table 19
Comparison of unilateral talar tilt in different groups of patients and normal subjects.

Talar tilt	A N = 284	B N = 152 non-injured side	B N = 152 injured side	C N = 200
0 – 5°	165 (58%)	109 (72%)	105 (69%)	144 (72%)
≥5.5°	119 (42%)	43 (28%)	47 (31%)	56 (28%)

A = non-injured side in 284 patients with abnormal contralateral arthrogram
B = bilateral stress examinations in patients with arthrographically negative ankle trauma
C = both ankles in 100 normal subjects
N = number of patients

authors (Ala-Ketola 1977, Broström 1965, Lindholmer 1978, Prins 1978).
Arthrographically diagnosed ligamentous rupture was surgically confirmed in all but two out of 50 patients. In one of these patients the leakage pattern was typical of isolated capsule rupture, but this had not been correctly recognized pre-operatively; the talar tilt difference under both local and general anaesthesia was only 3° in this patient. In the other, combined anterior talofibular and calcaneofibular ligament rupture was suspected arthrographically, but at operation the capsule and ligaments were intact, although the anterior talofibular ligament was hypoplastic and there was blood in the peroneus tendon sheath. These findings could be accounted for by a capsule rupture, present at the time of arthrograhpy but sealed off by fibrin clot prior to operation, which had extended more laterally than usual because of the hypoplastic anterior talofibular ligament, and the resulting leakage pattern could then mimic the picture of anterior talofibular and calcaneofibular ligament rupture.
In 52% (26 patients) the surgical findings were exactly as predicted arthrographically, but the damage was in 24% (12 patients) more, and in 24% (12 patients) less than expected arthrographically. The correlation between the size of the capsule rupture, the ligamentous damage and the extent and height of the extravasated contrast material, suggested by Olson (1969), Fussell (1973) and Staples (1975) could not be confirmed.
Remarkably, there was no correlation between talar tilt difference and the extent of ligamentous rupture (tables 7, 8 and 13) (fig. 33). In general, there is an increase in talar tilt corresponding with the extent of ligamentous damage, but there is a large overlap. Unilateral talar tilt values are of no use whatsoever in the diagnosis of ligamentous injury.
We think this is due to the considerable individual variation in the connective tissue apparatus of the ankle, both in thickness and in number of reinforcing bands.
Tendon dislocation and retinacular rupture may also occur as a result of inversion trauma, and both may influence the resulting talar tilt (Akhtar 1980, Broström 1964, Percey 1969).
It is important to note that the talotarsal joint structures play an important role in both movement and stability of the foot (Goergen 1980, Resnick 1974, Rubin 1960). In the course of the cadaver studies, several cases were noted where gross osteo-arthrosis had eliminated all true ankle joint movements, and had led to atrophy of the ankle joint reinforcements, but inversion and eversion of the foot were preserved in the subtalar joints.
The minimum talar tilt difference, found in cases of anterior talofibular ligament rupture, was —1° which is in accord with the findings of Fordyce (1972) and Fröhlich (1980), that isolated anterior talofibular ligament rupture may be present regardless of the talar tilt difference value. Except with the use of general anaesthesia, the percentage of false negatives with stress examination techniques was considerable, although in three consecutive studies with intra-articular local anaesthesia the figures did show steady improvement (tables 17, 14 and 15 resp.) and this is most likely to be due to improvement in technical expertise. In the one patient in whom the talar tilt difference was smaller with general anaesthesia than with local anaesthesia, the general anaesthesia examination was done by an inexperienced examiner, whereas in all other cases the examinations were performed by the authors.
The effect of variations in examiner, technique and measurement method on talar tilt values has already been fully discussed in chapter 3. It is therefore very important that radiology departments should ensure that the responsibility for the conduct of

such examinations is delegated to as few examiners as possible. Even when such precautions are taken, different talar tilt values may well be found on repetition (Fordyce 1972), and we agree with Tonino (1973) that the reproducibility of talar tilt difference values will not be better than ± 2°. Therapeutic decisions should therefore not be based solely on talar tilt difference values. The results of clinical examination (chapter 11) also indicate that stress examinations (both inversion stress and anterior drawer sign) are of very limited value in determining the extent of lateral ligamentous injury.

A

B

C

Figure 33

A. In this patient there occurred leakage distal and lateral to the lateral malleolus and filling of the peroneus tendon sheath. The talar tilt difference with local anaesthesia was 21° and the talar tilt difference with general anaesthesia was 40°. Arthrographic diagnosis: rupture of all three ligaments. At operation there was rupture of anterior talofibular ligament only.
B and C: inversion stress under local anaesthesia (B) and general anaesthesia (C) in a patient in whom operation revealed rupture of all three ligaments.

The inversion stress studies also showed a 7% incidence of false positives (table 16) compared to arthrography, but this may be wholly of partly explained by the so-called hypermobile ankle syndrome, which was defined in chapter 3 as a talar tilt difference exceeding 5° in normal subjects, and has an incidence of 5-10%. The most likely explanation of this syndrome is normal anatomic variability. By measuring the articular surfaces in the ankle joint, Sósa (1975) concluded that disproportion of opposing articular surfaces predisposed to ankle joint instability. Rubin (1960), however, blames localized weak parts in lateral ligaments and peroneus muscles, but comments that a subjective complaint of 'weak ankles' is not necessarily borne out by abnormal talar tilt values. Plaue (1970) considers it to be the result of repeated but unnoticed minor ankle traumata, and Freeman (1965 B, C, 1967 A, B) concludes from experimental studies that it is due to defective joint proprioception. An alternative explanation of the 7% incidence of false positive inversion stress examination compared to arthrography is that these cases were indeed pathological and the arthrograms were false negatives, but our overall reliability figures for stress examination as compared to arthrography could not provide sufficient ethical reasons to operate upon such patients.

The mechanism of false negative arthrography could be fibrin or blood clot, sealing off a rupture, but to a great extent this can be prevented by performing arthrography within seven days of the original trauma. Any clot that has developed during this period is likely to be dislodged by the practice of combining arthrography with stress examination.

Broström (1964, 1965 A) and Lindholmer (1978) confirm the reliability of the normal arthrogram, their only false negatives having been performed more than seven days after the original trauma. However, a normal arthrogram does not prove that there is no damage at all: in 10 out of 52 normal arthrograms, blood was found in the joint cavity, which could indicate synovial damage in the absence of capsule or ligamentous rupture, or on the other hand may be iatrogenic.

Although arthrography is a sensitive indicator of ligamentous pathology, it is not sufficiently sensitive to differentiate double or treble ligamentous rupture. A 72% sensitivity for calcaneofibular ligament rupture, using peroneus tendon sheath filling as a diagnostic sign, was achieved, but the literature contains several reports claiming greater diagnostic accuracy than this (Black 1978, Evans 1979, Lindholmer 1978, Vuust 1980 A, B).

Vuust (1980 A, B) uses an oblique axial view during ankle arthrography, claiming that this enables the calcaneofibular ligament region to be viewed clear of superimposition of bone or anterior contrast leakage and then interpretes any contrast leakage in the posterior malleolar fossa as diagnostic of calcaneofibular ligament rupture. Using this method on a series of twenty patients, he obtained a diagnostic sensitivity of 96%, compared to only 74% using the criterion of peroneus tendon sheath filling. Although the oblique axial view may increase the specificity of arthrography, the claimed 96% seems remarkably high, particularly in view of the fact that Vuust (1980 A, B) only operated on patients for double ligamentous rupture as suggested by a Percey type 3 pattern or a 'positive' oblique axial view. However, we consider his understanding of the nature of the calcaneofibular ligament to be wrong, in that it is not an extra-capsular cord-like structure, but rather consists of a collection of parallel fibrous bands of varying thickness in continuity with the joint capsule and the posteromedial wall of the peroneus tendon sheath (chapter 2).

The interpretation of the diagnostic signs, previously considered to indicate calcaneofibular ligament rupture only, should therefore now be extended to include

peroneus tendon sheath rupture.
Lindholmer (1978) claims that contrast leakage posterior to the middle of the lateral malleolus on lateral view is diagnostic of calcaneofibular ligament rupture and quotes a specificity figure of 82%, compared to a figure of 70% for the peroneus tendon sheath filling sign, but he does not consider these figures to be significantly different. Retrospectively, Lindholmers' diagnostic criterion was applied to our 50 randomly selected patients and was found to be positive in 13 cases, of whom 75% had surgical confirmation of calcaneofibular ligament rupture, but also of the remaining 37 patients, 66% had evidence of calcaneofibular ligament rupture at operation. The extent of lateral contrast leakage is not easy to estimate. This is in agreement with Lindholmer (1978) and Broström (1965 B) who state that this is influenced by differences in series composition and arthrographic technique. By comparison, peroneus tendon sheath filling is much more clear cut.
Blacks' (1978) stress peroneal tenogram involves introduction of contrast into the common peroneus tendon sheath, combined with stress examinations. Resultant contrast in the ankle joint is regarded as diagnostic of calcaneofibular ligament rupture. His criteria for operation were gross instability and/or positive peroneal tenogram, and he found positive peroneal tenograms in 52% of partial and 92% of total calcaneofibular ligament ruptures. However, the figures in this study suggest that significant ruptures may be missed by failure to perform an arthrogram or stress examination under general anaesthesia. For reasons already mentioned we consider a positive stress peroneal tenogram to be equally indicative of peroneus tendon sheath rupture.
Arthrographic peroneus tendon sheath filling is always pathological, though not always indicative of calcaneofibular ligament rupture. The differential diagnosis is therefore as follows:
1.
Peroneus tendon sheath filling combined with leakage distal and lateral to the lateral malleolus: anterior talofibular ligament rupture with ruptured calcaneofibular ligament fibres and ruptured medial wall of the peroneus tendon sheath, either separately or in combination.
2.
Isolated peroneus tendon sheath filling:
a. If the history suggests pure hyperdorsiflexion trauma, one could suspect isolated calcaneofibular ligament rupture, although this is very rare, and anatomically unlikely.
b. Permanent connection with the ankle joint following previous rupture of the calcaneofibular ligament/peroneus tendon sheath structures. Peroneus tendon sheath filling may be prevented by blood or fibrin clots, therefore its absence does not exclude intra-articular pathology. If filling does occur spontaneously, it is our opinion that no further information can be obtained from an inversion stress examination, but in the absence of peroneus tendon sheath filling or other contrast leakage, we would recommend inversion stress examination in an attempt to dislodge any clot present and allow any possible leakage pattern to develop.
There remains at present no specific diagnostic sign for posterior talofibular ligament rupture.
In this work it is endeavoured to present a strong case for ankle arthrography being accepted as the diagnostic method of choice in ligamentous trauma of the ankle, but a number of authors hold a different opinion. Tonino (1973), for example, argues that arthrography results in an all too frequent diagnosis of minor lesions which are

of no serious consequence to the patient. The only lesions we would consider as minor would be isolated capsule rupture and partial anterior talofibular ligament rupture (fig. 33). It was shown that the former has a clearly defined leakage pattern, so such patients can be readily dismissed with bandage treatment only. The latter cannot be differentiated from total anterior talofibular ligament rupture, either arthrographically or by stress examination, so we can see no reason to exclude arthrography as a first line diagnostic technique.
Adler (1976) and Grönmark (1980) both argue that routine ankle arthrography is much too time-consuming, and Noesberger (1976) considers that the total work load would be excessive.
However, an experienced examiner can complete the entire procedure within 10 minutes, whereas stress examination under general or epidural anaesthesia is much more time-consuming, demands more patient preparation and carries a higher unit cost and risk for the patient. The only real disadvantage of ankle arthrography is the necessity to puncture the joint capsule, but, as was shown in chapter 4, the resultant complication rate is virtually nil.

7.5. Conclusions

Ankle arthrography is the diagnostic method of choice for ligamentous pathology of the ankle joint, on account of its diagnostic reliability, yield and technical objectivity. It is superior to inversion stress examination under local anaesthesia (96% and 70% respectively) and comparable to inversion stress under general anaesthesia (92%). Talar tilt difference cannot be correlated with the extent of ligamentous rupture and therefore inversion stress examination, while providing valuable additional information, must be regarded as a secondary technique to ankle arthrography. Peroneus tendon sheath filling is always pathological, but although this does not always indicate calcaneofibular ligament rupture, such rupture cannot be excluded in its absence. Standard arthrography may give a specificity of up to 72% in the diagnosis of multiple ligament pathology, and although certain other procedures, notably Blacks' stress peroneal tenogram, may improve on this figure, such methods should be additional to standard arthrography. It is in the light of the anatomic structure of the ankle doubtful whether the additional X-rays and punctures required can be justified.

8. Unusual aspects of ankle arthrography

8.1. Introduction

One of the main pathological features in ankle arthrography is contrast extravasation through capsular or ligamentous rupture into soft tissue. However, the 700 arthrograms performed during the four years' study period brought to light several other interesting features, which are now presented and discussed together with a short literature review of less common indications for ankle arthrography.

8.2. Venous filling in ankle arthrography

In four cases contrast filling of venules was noted, a phenomenon which, to our knowledge, has not hitherto been described in any of the general arthrographic literature. All four arthrograms were technically uneventful, and two were normal by

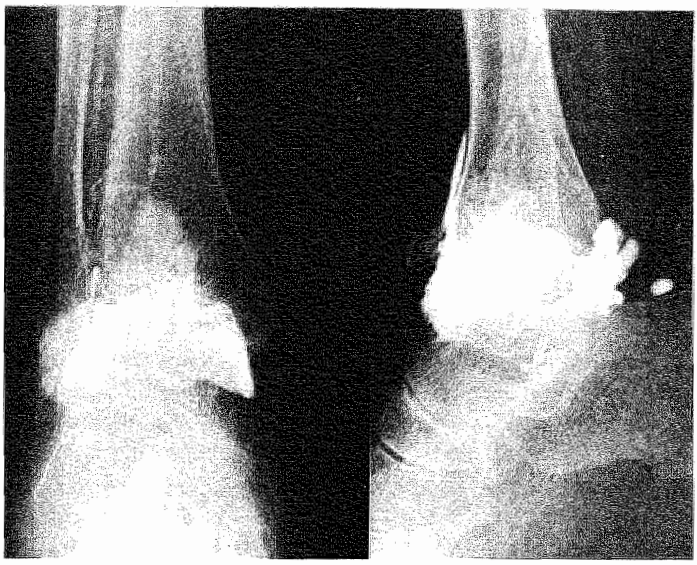

Figure 34

Filling of veins during ankle arthrography.

all other criteria while the other two showed signs of ligamentous rupture (fig. 34). The most likely cause of venous filling in arthrography is accidental needle penetration of a vein and therefore the phenomenon is most likely an undesired side effect.

8.3. Lymphatic filling in ankle arthrography

8.3.1. Introduction

Eight cases were observed, three of which are already reported in the literature (Van Moppes 1980). In all cases this occurred in the absence of other vascular filling. The other reports in the literature are by Haage (1970), Lüning (1968) and Reinhardt (1973). In seven patients the occurrence of lymphatic vessel filling in otherwise normal arthrograms was observed. The eighth case showed the typical contrast pattern of ligamentous rupture together with filling of a lymphatic vessel (fig. 35). Once again, the arthrograms were technically uneventful.

8.3.2. Discussion

Lymphatic filling is known to occur in arthrograms of ankle, wrist, knee and shoulder joints in patients suffering from rheumatoid arthritis (Desmet 1975, Ennevaara 1967, Harrison 1971, 1977, Lewin 1972, Resnick 1974 B, Weissman 1981, Weston 1969 and 1978). Arthrographic filling of lymphatic vessels in rheumatoid arthritis is described with an incidence varying from 10 to 40% (Desmet 1975, Harrison 1971, Hugh 1977, Resnick 1974 B, Weissman 1981, Weston 1969 and 1978).

Lewin (1972) explains the phenomenon as follows: there is a hyperplastic lymphatic system response, typical of rheumatoid arthritis, at the synovial, lymphnode and lymphatic channel levels, associated with an increased permeability of the synovial membrane, resulting in the lymphangiographic effect seen during contrast arthrography. He confirms the increased absorption rate and turnover with isotope studies. The eight patients in our study were all post-traumatic and displayed no clinical evidence of rheumatoid arthritis and this was confirmed arthrographically by

the complete absence of diffuse nodular filling defects, abnormal connections with tendon sheaths and irregular capsular attachments.
Lüning (1968) describes a case of lymphatic filling on arthrography, fourteen days after trauma, in which aspiration, immediately prior to injection of contrast, yielded some white fluid which he attributes to a traumatic fistula between the joint cavity and the lymphatic system. In a similar case, but performed 2½ months after trauma,

A

B

Figure 35

a. Filling of lymphatic vessels in an otherwise normal ankle arthrogram.
b. Filling of a lymphatic vessel in an arthrogram which showed ligamentous rupture.

Reinhardt (1973) was able to aspirate about 5 ml of greenish fluid. He suggests four possible explanations for the phenomenon of lymphatic filling at arthrography:

1.
High contrast injection pressure, although he was unable to reproduce this by the deliberate use of high injection pressure in 26 further cases.

2.
Trauma, although he considered this an unlikely explanation, since the arthrogram was performed 2½ months post trauma.

3.
Pre-existing connections between joint cavity and lymphatic vessels, although he considers this also unlikely, because the phenomenon is unknown in normal arthrography and is too briefly visible to be due to established anatomical connections.

4.
Infection or rheumatoid disease. In the case he reports there was no evidence of the latter, but he considers the presence of abnormal fluid within the joint cavity to be indicative of an infectious process.

Haage (1970) reports three cases of lymphatic filling at arthrography, two of which had arthrographic evidence of capsular or ligamentous damage. He considers that lymphatic vessel filling is invariably pathological, and the result of synovial membrane damage. When performing ankle arthrography, it is necessary to introduce the contrast under a certain amount of pressure, because, if a ligamentous defect is sealed off by a fibrin clot, it is often necessary first to dislodge this before the defect can be demonstrated. In such cases, there is an immediate decrease in the sensation of pressure and also a reduction in the pain which occurs when the contrast is being injected into the ankle joint.

It is important to note that the phenomenon of lymphatic filling occurred in seven normal arthrograms, where contrary to cases of ligamentous rupture, the contrast medium cannot leak out of the joint space. In the eighth case, it was noticed that a rather high injection pressure was necessary to dislodge the fibrin or blood clot and to show the ligamentous defect. The existence of some haemarthrosis in otherwise normal arthrograms (table 18, chapter 7) may indicate some synovial membrane damage.

In conclusion, therefore, synovial membrane damage is the most likely cause of lymphatic filling at arthrography, and a high injection pressure facilitates this phenomenon.

8.4. Less common indications for ankle arthrography

Ankle arthrography is reported to be of value in a number of degenerative and post-traumatic conditions, for example in assessing cartilaginous integrity in fractures through the articular surface, in osteo-arthrosis and osteochondritis dissecans, with or without loose body (Goergen 1980, Kaye 1979, Olson 1981, Smith 1977). Positive, negative or double contrast arthrography are sometimes combined with multidirectional tomography to detect small loose bodies in the ankle joint (Goergen 1980, Kaye 1979, Olson 1981, Smith 1977, Wolkow 1973). Chirls (1973) and Zinmann (1979) also use the double contrast technique in the diagnosis of ligamentous pathology.

Ankle arthrography may also be used in the evaluation of rheumatoid arthritis.

The pathognomonic features have already been mentioned in this chapter.
In the assessment of ganglia and their connections, the use of arthrography, sometimes combined with ganglionography, is reported by Daffner (1977) and Goergen (1980).
Interventional arthrography can be used to unlock a locked knee joint (Griffith 1979) or distend a frozen shoulder joint (Andrén 1965, Gilula 1978), although the therapeutic value of this latter technique in frozen ankle syndrome is uncertain (chapter 9).
Finally, several authors report the simultaneous use of ankle and subtalar joint arthrography in the evaluation of talipes and other congenital deformities of children (Goergen 1980, Hjelmstedt 1977, Sahlstedt 1976).

9. Adhesive capsulitis of the ankle (frozen ankle)

9.1. Introduction

After a simple, uncomplicated ankle sprain (i.e. without ligamentous rupture or fracture) a number of patients complain of continuing discomfort, pain or swelling. A few develop such impairment of the ankle connective tissue structures that even normal walking is disturbed. This group of patients constitutes a difficult diagnostic problem. Physical examination, though non-specific, may reveal muscle wasting and limitation of the normal range of active and/or passive movements. Plain film findings are usually non-specific. These findings can be compared with similar syndromes in the shoulder, known as 'frozen shoulder', (Claessen 1969, Ennevaara 1967, Goldman 1976, Lundberg 1969, Neviazer 1949, 1964, Reeves 1966) (fig. 39), and the knee (Pavlov 1980) and terms such as 'adhesive capsulitis' or 'frozen ankle' have been used. The arthrogram is useful in the diagnosis of this condition, and several diagnostic criteria are described (Goldman 1976, Van Moppes 1979 A) (fig. 36):

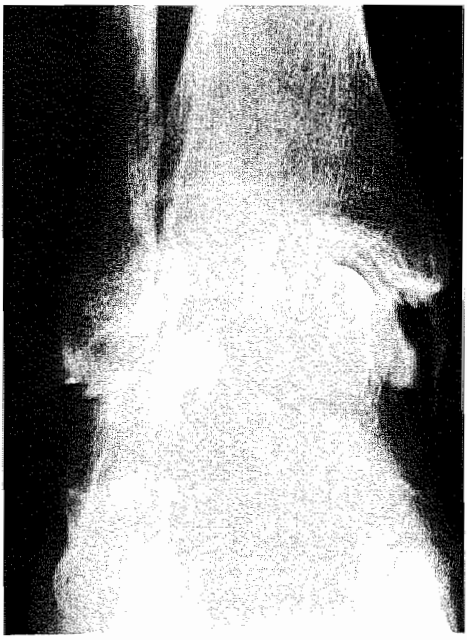

Figure 36

Frozen ankle syndrome: small contracted joint, with only an open tibiofibular recess.

1. Resistance to the injection of small amounts of contrast medium.
2. A decrease in joint capacity.
3. Obliteration of the normally well developed anterior, posterior and tibiofibular joint recesses.
4. A powerful leakage of contrast along the needle or needle track.

The normal joint capacity is variously quoted in the literature as 6 - 20 ml (Goldman 1976, Lanz-Wachsmuth 1972, Tausch 1978 B, C, 1979). This is probably due to the fact that it is possible, with sufficiently high injection pressure, to 'inflate' the joint to a considerable degree, to the normal elasticity of the capsule and to often existing normal connections with flexor tendon sheaths and the subtalar joint.
The standard 15 ml of contrast mixture is therefore often accommodated by normal joints, but such injections may cause pain to the patient. Similarly, distension due to arthritis causes pain.
Little is known, however, about the normal physiological capacity and intra-articular hydrostatic pressure of the normal ankle joint. The powerful leakage of intra-articular contrast material from a 'frozen ankle', subjectively suggests an increase of intra-articular pressure. A study was therefore made of normal intra-articular pressure and joint capacity and the results compared with those found in suspected cases of frozen ankle syndrome.

9.2. Methods and materials (fig. 37)

Ankle joint capacity and intra-articular pressure were measured in 10 normal subjects (5 male, 5 female, aged 19-33 years).
The ankle joint was punctured anteriorly with a 21 gauge needle, to which was then connected a 110 cm standard disposable central venous pressure line manometer and a three-way tap. A syringe filled with 0.9% saline was connected to the free arm of the three-way tap, and the manometer filled with saline. The tap was then turned to open the joint cavity to the manometer and the resting intra-articular pressure

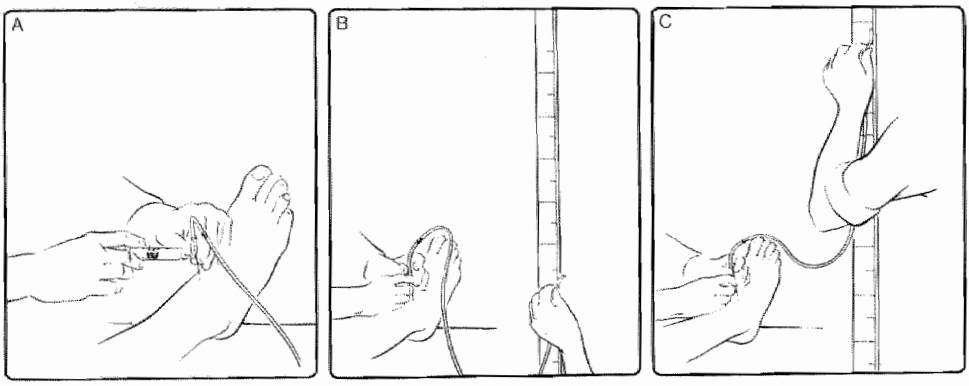

Figure 37

a. Introduction of 0.9% NaCl solution.
b. Measurement of intra-articular hydrostatic pressure.
c. As above (b), but recording higher pressure.

measured in centimetres of water. Progressive quantities of saline were then introduced into the joint, until the volunteers complained of pain and the total quantity added was defined as 'pain threshold capacity', because it is not possible to quantify pain sensation due to its subjective nature (Jayson 1970). The intra-articular pressure was measured after the introduction of 1, 3, 5, 7 and 9 ml. The same procedures were then performed on four patients (aged between 20 and 40, all male) with clinically suspected frozen ankle syndrome, and an arthrogram performed on all but one.

In nineteen of the twenty ankles of the normal subjects and in all post-traumatic cases the procedure was technically satisfactory. The needle could be correctly placed into the ankle joint cavity resulting in clear movements of the fluid meniscus of the manometer following initial easy introduction of saline. In none of the ankles studied in this manner was there any pre-existing effusion.

9.3. Results

9.3.1. Results on normal subjects (tables 20 and 21)

The 'pain threshold capacities' in 17 subjects ranged from 5 to 9 ml. Both ankles of subjects 7 and 8 (both tall young girls) had a capacity of only 5 ml and only two ankles had a capacity of more than 9 ml (left ankles of subjects 4 and 6). Any attempt to introduce further quantities of saline after the onset of pain resulted in a sharp rise of intra-articular pressure. In all but two subjects, results for both pressure and capacity in both left and right ankles were approximately equal. It is interesting to note that some ankles had a negative resting pressure.

9.3.2. Results on patients (tables 21, 22, 23)

Three of the four patients had very high intra-articular pressures, associated with very small 'pain threshold capacities' (fig. 38). In two patients, there was an extremely sharp rise in intra-articular pressure when only 3 ml of saline had been introduced, and in the third this occurred at the introduction of only 5 ml. These results were taken to support the clinical diagnosis of frozen ankle. An arthrogram was performed in two of these subjects, and in both there were typical features of frozen ankle. In the fourth patient, pain threshold capacity, intra-articular pressure

Figure 38

Frozen ankle syndrome. Pain threshold capacity 5 ml; small irregular recesses; very high intra-articular joint pressure at 5 ml.

Table 20
Intra-articular ankle joint pressure values in 19 ankles of 10 normal subjects.

Injected quantity of 0.9% NaCl		R 0	R 1	R 3	R 5	R 7	R 9	L 0	L 1	L 3	L 5	L 7	L 9
v.M.	32 I	2	9	17	18	30	49*	5	14	17	20	35	50*
F.M.	32 II	—1	3	12	25	43*	B	—1	7	18	35	43*	B
vd.H.	33 III	—2	5	20	55	71*	B	—2	6	28	49	76*	B
I.H.	21 IV	5	12	12	29	42	78*	7	8	12	16	24	29°
MdM.	20 V	0	4	21	39	64*	110	4	B	12	25	45	91*
H.S.	23 VI	1	4	13	28	41	83*	—5	2	10	19	32	70°
N.C.	20 VII	0	2	48	73*	B	B	5	15	36	104*	B	B
P.W.	19 VIII	5	16	44	84*	110	B	3	18	41	88*	110	B
F.M.	23 IX	A	A	A	A	A	A	3	22	37	41	53	A
I.W.	22 X	0	8	17	37	85*	110	0	8	17	37	85*	110
	$\bar{x}$	1.1	7	22.6	43.1	60.8	86	1.9	11.1	22.8	43.4	55.9	70
	S	2.3	4.4	12.5	21.5	25.3	27.8	3.6	6.1	11.1	28.4	26.9	28.7
L + R	$\bar{x}$	1.5	9.0	22.7	43.3	58.2	78						
L + R	S	3.1	5.6	11.7	25.3	26.3	27.1						

* = pain threshold capacity
° = pain threshold capacity not reached
A = technical failure
B = not measured
$\bar{x}$ = mean value
S = standard deviation

and arthrogram were all normal, and in particular, the arthrogram showed well developed recesses and filling of the flexor tendon sheaths. On the strength of all these results, the diagnosis of frozen ankle syndrome was rejected.
Note: some figures in both normals and abnormals are artificially low because the maximum pressure was beyond the limits of the manometer used (indicated by values > 110).

9.4. Discussion

Recurrent ankle sprains are common, each sprain being accompanied by capsule swelling, oedema and frequently haemarthrosis. The ankle joint capsule is an

Table 21

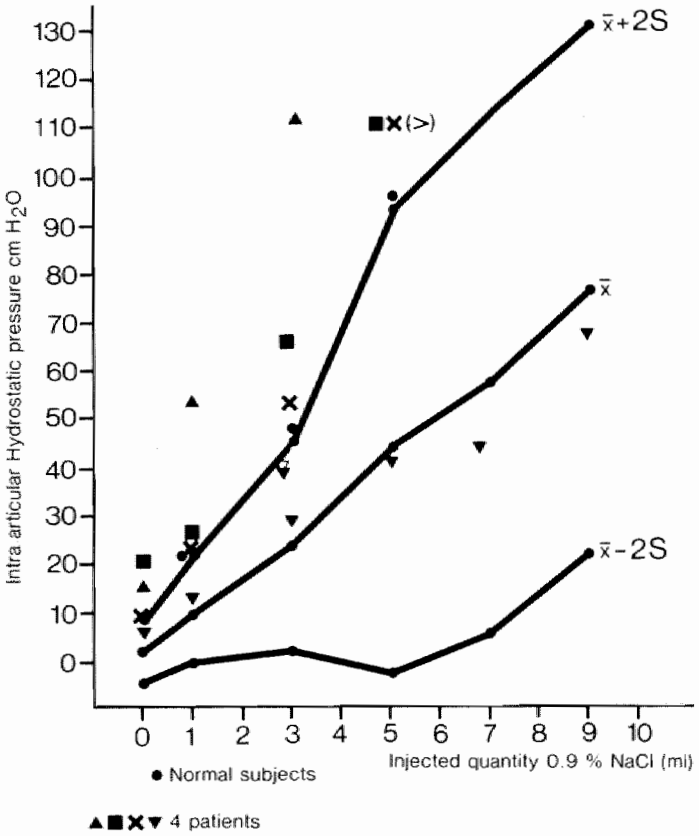

Range of intra-articular ankle joint pressure values in 10 normal subjects, compared with values in 4 patients with suspected adhesive capsulitis (A.C.).
$\bar{x}$ = mean; $\bar{x}$ + 2S, $\bar{x}$—2S = 95% and 5% value; ● = values in normal subjects >x + 2S;■ = patient with suspected A.C., Rt ankle; ▲ = patient with suspected A.C., Lt ankle; x = patient with suspected A.C., Lt ankle; ▼ = patient with suspected A.C., Rt. ankle.

integral part of the ankle ligamentous structures, and in the case of ligamentous rupture, the capsule is therefore nearly always involved.
Clayton (1965) did experimental investigation on the healing of sprained ankles. In the first week after trauma, he found changes in the capsule, characterized by oedema, lymphoid infiltration and fibroblastic proliferation. After four weeks it was possible to demonstrate an increase of collagen and fibroblasts followed by fibrosis and contraction of the capsule. The capsule contracture was responsible for the limitation of the ankle movements. Broström (1966 A, C), found capsular scar formation at operation after repeated trauma. Further causes of ankle stiffness are synovial adhesions, oedema, or repeated microtraumata resulting from overactive physiotherapy (Colton 1976, Watson-Jones 1976).
Furthermore, rest and immobilization may contribute to the problem, by increasing venous and lymphoid stasis and the resultant oedema, and in failing to break down any synovial adhesions formed in the immediate post-traumatic period (Goldman 1977, Watson-Jones 1976). Repeated trauma may cause a 'traumatic ossification' of the anterior capsule, particularly in footballers (Watson-Jones 1976, Hendriks 1981).

Table 22
Range of intra-articular joint pressure (cm H_20) in 4 patients with suspected frozen ankle syndrome.
▲ ■ X ▼ see table 21

Injected quantity of 0.9% NaCl (ml)			0	1	3	5	7	9
patient I	▲	left ankle	15	53	110			
patient II	■	right ankle	20	25	65	>110		
patient III	X	left ankle	8	22	50	>110		
patient IV	▼	right ankle	5	11	25	34	36	62

Table 23

Normal subjects	Patients
Lt $\bar{x}$ = 16.3 cm H_2O/ml	
	$\bar{x}$ = 27.2 cm H_2O/ml
Rt $\bar{x}$ = 18.3 cm H_2O/ml	

Comparison of mean values ($\bar{x}$) of maximum pressure – capacity gradient in 9 right (Rt), 10 left (Lt) normal ankles with 3 patients with confirmed adhesive capsulitis.

Note 1
There was technical failure in the right ankle of one of the normal subjects (table 20).

Note 2
The fourth patient (table 22) is excluded from the mean because both arthrogram and pressure values were normal.

A

Figure 39

a. Arthrogram of normal shoulder joint with well developed recesses and filling of biceps tendon sheath.
b. Frozen shoulder syndrome. Decreased joint content. No visible biceps tendon sheath.

B

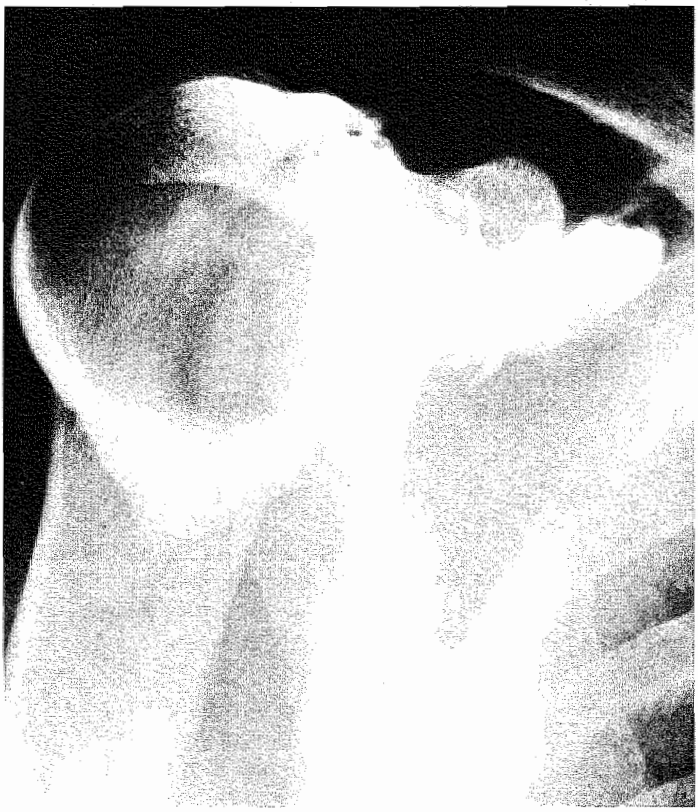

The clinical syndrome of adhesive capsulitis in the ankle should be differentiated from other post-traumatic complications, the most important of which are Südeck atrophy and osteo-arthrosis, both of which give diagnostic features on plain films, and osteochondritis with or without loose body, which may also be diagnosed on plain films, but may additionally require tomography and/or arthrography (chapter 8.4).
Ankle arthrography and manometry may provide useful supporting information in the diagnosis of frozen ankle syndrome. Pain threshold capacity of 5 ml or less, together with high resistance to injection, is abnormal. In order to quantify the latter, the maximum pressure increase in centimetres of water per 1 ml saline injected, was calculated for all the normal and abnormal ankles studied (table 23). Although some figures for two of the patients are artificially low, because the maximum pressure recorded was in fact much higher than the reach of the manometer used, the average pressure/capacity gradient in the abnormal ankles was at least 48% higher than the average figure for the normals. This suggests a remarkable decrease in capsular elasticity in frozen ankle syndrome. In similar work on the knee joint, Jayson (1970) points out that intra-articular joint pressure is a function of the action of an elastic joint capsule on the fluid content of the joint, and that pressure rise on increasing the fluid content is determined by capsular elasticity.
Increased intra-articular knee joint pressure in rheumatoid arthritis is explained by fibrosis and thickening of the joint capsule (Dixon 1964, Jayson 1970, Van der Leeden 1974). Negative intra-articular pressure values were also found by Dixon (1964) and Jayson (1970) in normal knees.
The reduced ankle joint capacity, seen in the abnormal patients, can be partly explained by reduced capsular elasticity, but may also be due to adhesions, closing-off of normal connection with the subtalar joint and flexor tendon sheaths. This can be compared with the frozen shoulder syndrome, were the normal connection with the biceps tendon sheath cannot be arthrographically demonstrated (fig. 39).
The history in the four patients in this study, together with the two patients demonstrated in a previous study (Van Moppes 1979 A), suggests two main causes of frozen ankle syndrome, namely repeated inversion trauma with inadequate treatment, or excessively prolonged immobilization following sprain or fracture. In the past, treatment of frozen ankle has been mainly empirical. When there is prolonged and recurrent pain following ankle trauma, together with limitation of active and passive ankle movement, an ankle arthrogram is indicated. From a prophylactic point of view, early mobilization following ankle sprain, supported by intensive physiotherapy, may be advisible (Watson-Jones 1976).
In addition, the bandage therapy, further described in part 3, should be regarded as an essential part of the treatment.
In the treatment of a frozen shoulder, distension arthrography as a therapeutic as well as diagnostic procedure has been described (Andrén 1965, Gilula 1978, Resnick 1981), with some successful results.

9.5. Conclusion

Adhesive capsulitis or 'frozen ankle' is a syndrome resulting from repeated ankle sprain, or following immobilization after trauma. Ankle arthrography is a useful and safe diagnostic procedure in this syndrome, and manometry provides useful information about the elasticity of the joint capsule.

10. Summary (Part 2)

Any critical study of the large amount of literature on lateral ankle ligament lesions will immediately reveal the current areas of dispute surrounding the two major radiodiagnostic methods, namely stress examination and arthrography. The second part of this thesis was concerned with a further re-evaluation of these techniques, aimed at selecting a diagnostic programme with the best balance of diagnostic usefulness, patient acceptability, technical ease and low unit cost.

700 Patients were examined by arthrography and stress examination, and in 500 (of whom 55 were operated upon) the results were studied in the light of experimental arthrographic investigations, cadaver dissections and surgical findings.

The cadaver study (part 1) revealed that the ligamentous apparatus around the ankle is part of a three dimensional system throughout the body, and distinguishable as at least three distinct reinforcing capsular fibre tracts of considerably varying thickness, often supplemented by additional similar bands derived from and integral with more superficial structures.

On grounds of technical ease, reproducibility and accuracy, the inversion stress examination was selected in favour of the anterior drawer sign as the stress method to be compared with arthrography. In performing the inversion stress examination, the parameter measured was talar tilt difference. This could not be correlated with the extent of ligamentous damage, because it was found to be so dependent on anatomical variation, pain and muscle resistance, and technical factors such as any anaesthetic used, stress force used and the experience of the examiner, quite apart from the effect of the connective tissue damage that the examination technique is designed to assess.

By contrast, arthrography was found to be simple, cheap, reliable, quick and safe, and more technically objective than inversion stress examination. Using experimentally tested diagnostic arthrographic criteria, arthrography yielded a sensitivity in our studies of 96% compared to a comparable figure for inversion stress under local anaesthesia of only 70%. The latter can be improved to 92% by the use of general anaesthesia, but in our opinion, the resultant attendant costs and risks make the procedure no longer comparable with simple arthrography.

Arthrographic specificity for multiple ligament pathology was reduced to 72%, mainly because posterior talofibular ligament rupture cannot be demonstrated arthrographically. Peroneus tendon sheath filling is always pathological, but although this does not always indicate calcaneofibular ligament rupture, such rupture cannot be excluded in its absence.

Contrary to some other opinions, there is no specific pattern of contrast extravasation for anterior tibiofibular ligament rupture. By contrast, both isolated capsule rupture and anterior talofibular ligament rupture have clearly distinguishable arthrographic patterns.

There was an 1% incidence of lymphatic filling in arthrography, which should be considered, even on its own, as evidence of synovial damage, with or without ligamentous rupture. Arthrography is the diagnostic method of choice in the assessment of reduced joint capacity and capsular elasticity which are the cardinal features of the frozen ankle syndrome.

Part 3

C.R. van den Hoogenband

11. Inversion trauma of the ankle joint – diagnostic features

11.1. Review of literature

11.1.1. Clinical diagnosis, history and clinical examination

History

Patients often find it difficult to give an exact description of an accident, and the information is frequently wrong or in large part absent altogether. Only 60% of 239 patients reported by Broström (1965) were able to describe the circumstances, most indicating an internal rotation or adduction of the foot even when arthrography revealed rupture of the anterior tibiofibular and/or deltoid ligaments. The literature contains little on this subject, and only Prins (1978), in his well documented thesis, gives a careful description of the patient's history in relation to aetiology of ankle injuries. He studied 298 patients (M:F ratio 70:30) aged between 8 and 57 years (50%: 15 - 25 years). Right and left ankles were injured in 61% and 39% respectively. 67% of accidents were sports injuries, 6% road traffic accident, 5% work- and 22% home-accidents.

In an attempt to establish the movement of the foot aetiologically responsible for the injury, the patient was asked to demonstrate the movement of the foot at the time of the accident, using the healthy side. Remarkably, 48% of patients could not remember or reconstruct the way their foot had mechanically reacted at the time of the accident.

The remaining 52% described such a variety of movements that the obvious conclusion was that no relationship exists between a patient's description of the movement at the time of the accident and the nature of the trauma to the ligaments. His data also revealed no relationship to previously sustained ankle injuries, in that a previous ankle sprain did not appear to entail a greater risk of a more severe ligamentous injury later on. Most patients (65%) reported to hospital within 6 hours of the accident. Nevertheless 13% with a ligamentous injury sought medical care after 24 hours or longer. The degree of weight bearing and walking after the accident showed no correlation with the severity of the injury as demonstrated arthrographically. Because of all these facts, Prins (1978) concludes that statements about the nature of the traumatizing movements, any earlier sprain, a tendency for the ankle to give way, or the possibility of weight bearing after the sprain, were of little value in the diagnosis of extent of ligamentous injury, if any.

Clinical examination

The acute presenting clinical features are pain and swelling. Of 104 patients operated on for lateral ligamentous injury, 47% had heard or felt a 'crack' (Duquennoy 1975). The visible characteristics of haematoma usually take a few days to develop.

Swelling

Soon after the accident, a rounded swelling usually develops in front of the lateral malleolus, the well known 'signe de la coquille d'oeuf'. This extends over and below

the fibula and, to a lesser extent, over the dorsum of the foot (Ruth 1961), and, according to Broström (1965), is frequently fluctuant around the lateral malleolus. Prins (1978) usually saw the patient after arthrographic examination, i.e. after he had worn a compressive bandage, by which time there was no longer any swelling over the tarsal sinus, but there was marked bruising discoloration of the skin, where blood pigment had penetrated the subcutaneous layer.
95% Of patients with severe ligamentous injury showed swelling in front of, below, behind and covering the lateral malleolus, while 55% of patients without proven ligamentous injury showed this typical pattern. In Prins' material, discoloration of the skin was a very characteristic sign of sprained ankles, and the extent of this around the lateral part of the heel could be correlated with the severity of the ligamentous injury.
Prins is the only author who describes the frequently found discoloration on the medial side of the ankle, just below the medial malleolus. He thought that in these cases the hematoma had spread from the tarsal sinus to the subcutaneous layer, through a crural fascia defect anterodistal to the malleolus.

Pain
It is pain that initially alarms the patient enough to consult a physician. A distinction is frequently made between 'pressure pain' and pain related to the ruptured ligaments involved, described as 'traction pain'. According to some authors (Frost 1974, Landeros 1968) traction pain usually results from partial ligamentous rupture, while little or no pain suggests total rupture. Broström's patients all had traction pain, while Prins (1978) described slight difference in pain sensation in patients with and without ruptured ligaments.
On the other hand, pressure pain was predominantly localized to the lateral malleolus in those with arthrographically proven rupture and even more so in those with a more extensive rupture. He suggests that extent of the swelling and pressure pain correlate with the extent of the post-traumatic hematoma.

Examination in stressed position
According to a majority of papers in the literature, anterior talofibular ligament rupture, in isolation or in combination with calcaneofibular ligament rupture, results in abnormal anterior talar mobility, the 'anterior drawer sign' (ADS), and in an abnormal talar tilting movement in the tibiofibular mortise, the 'talar tilt sign' (TT). It is generally assumed that pain and apprehension in the patient make clinical demonstration of these signs impossible without general anaesthesia, even local anaesthesia frequently proving insufficient.
There are some data in the literature concerning clinical use of these signs in the examination of sprained ankles. Prins (1978), in his description of the difficult technique of performing the anterior drawer sign movement, distinguishes a 'pronounced' (+), 'doubtful' (±) or 'absent' (—) ADS. When pain rendered examination in a stressed position impossible, the finding was recorded as 'unknown', and this was the case in over 10% of those with severe ligamentous injuries. The anterior drawer sign was positive in 27% in the group where Prins (1978) described one ligament lesion and 48% in the group with more severe ligament ruptures.
The clinical talar tilt sign is even more difficult to demonstrate on account of pain, according to many authors. Prins (1978) records an increasing number of 'unknown' results with progressively more severe ligamentous damage. The TT phenomenon

was not demonstrable in over 80% of the patients with mild or no ligamentous injury nor in 40% of patients with severe ligamentous injury, and yet he correlates a positive talar tilt sign with more severe ligamentous injury!

1.1.2. Radiological stress examination

In part 2 of this thesis a literature review of radiological aspects is given. Consequently, radiological stress examination and arthrography will be discussed here only in relation to surgical aspects.
In cases of ankle injury, standard X-rays (A-P and lateral) are essential to exclude fractures. Chondro-osseous and bony avulsion fractures of the talar trochlea laterally, and sometimes medially, are classified by many as ligamentous damage. After fracture has been excluded, radiography is frequently supplemented by two stress examination techniques:
1.
inversion stress examination
With the lower leg fixed, and the foot held in 30° to 60° plantar flexion, inversion force is gradually applied to the lateral dorsal part of the foot. This tends to produce separation of the articular surfaces of tibia and talus with an angle, open laterally, which may be measured radiologically on A.P. view. This angle is referred to as the 'talar tilt angle'.
2.
anterior drawer sign
With the foot fixed in 30° to 60° plantarflexion, force is applied to the leg, just above the ankle joint in a posterior direction.
This tends to induce dislocation of the ankle joint with an anterior and caudal component of talar movement, relative to the tibia. The resultant displacement is referred to as the 'anterior drawer sign' and several methods of radiological measurement are used (see part 2).

1.1.3. Ankle arthrography

By injecting contrast medium into a joint, radiographical visualization of the contours of the articular cavity is possible.
Arthrographic examination of the tibiotalar joint in the diagnosis of ankle injury was introduced in Scandinavia (Hanson 1941, Wolff 1940). Wide-spread use of this technique followed the publications of Broström (1964, 1965). The technique of injecting a mixture of contrast medium and local anaesthetic is described in part 2. The abnormal arthrographic findings in lateral ligament injuries are summarized in table 6.

1.1.4. Conclusions

The literature contains little information about history and clinical examination after ankle inversion trauma. The patient's history of the accident, weight bearing ability, and signs such as pain and swelling seem to be of little value in indicating the presence, absence of extent of lateral ligament rupture.
Clinical examination of the ankle joint in stressed positions (talar tilt and anterior drawer sign) is of relatively little value because of muscle resistance caused by pain, although a positive talar tilt sign seems to be related to more severe ligament damage.
Although the literature is agreed on the usefulness of X-ray examination as a

diagnostic aid in ankle inversion trauma, the value of radiological stress examination under local anaesthesia is doubtful for several reasons described in part 2. General or spinal anaesthesia is considered preferable. Ankle arthrography seems to be the most reliable method of evaluating abnormalities due to lateral ligament ruptures.

11.2. Diagnostic study

11.2.1. Methods and materials

From 1-3-1979 to 01-05-1980, all patients with acute ankle sprains seen in the casualty department of St. Annadal Hospital, Maastricht, were submitted to a prospective randomized study, the aim of which was to compare three different methods of treatment of lateral ankle ligament rupture.

History and physical examination were followed by standard radiographic examination, including an A-P and lateral film of the ankle to exclude fracture. Avulsion fractures of the two malleoli, the navicular bone, the calcaneus and cuboid bones, though not classified as fractures, were also excluded from the trial. All cases of suspected lateral ligament damage, however mild the symptoms, were initially treated with a compression bandage and a below knee plaster splint to prevent equinus position of the foot, followed by instruction on leg elevation. A prescription for an anti-inflammatory analgesic (Tanderil® 200 mg t.i.s.) was also given. Primary treatment was almost exclusively on an outpatient basis. An appointment was made for follow-up at the next trauma clinic, within five to seven days of trauma. The average interval between injury and follow-up was 4.65 days and never more than 6 days. The first follow-up examination consisted of clinical examination, followed by ankle arthrography, if necessary.
Cases with minimal or no symptoms or signs were diagnosed as 'minimal injury', given a simple elastic bandage and discharged. If there were symptoms of lateral ligament injury, such as pain, swelling or instability, physical examination was followed by ankle arthrography under local anaesthesia, combined with inversion stress examination. The radiographic examination was carried out by one of two specially trained radiologists. Based on the results of arthrographic examination, patients with lateral ligament rupture were randomly assigned to three further treatment groups (Chapter 12.2.).
Patients with a history of previous lateral ligament rupture were excluded from the study and treated by a special 'Coumans-bandage' (Chapter 12.2.).

Results

A total of 911 patients with acute ankle sprains were seen in the casualty department of St. Annadal Hospital, Maastricht during the study period.
The first selection based on history, physical examination, and standard X-ray films gave the following results:

N	Symptoms	Treatment
240	minimal symptoms	elastic bandage
75	severe symptoms and radiographic evidence of a fracture of the lateral malleolus	plaster cast or operative therapy
596	mild, moderate or severe symptoms, but no radiological evidence of fracture	initial treatment (see text)

The 5 to 7 days follow-up of all patients with suspected lateral ligament injury, was by special consultation at the trauma clinic.
The plaster splint and bandage were removed, and the ankle examined for swelling, pain and stability with the following results:

N	Symptoms	Treatment/follow-up
342	minimal symptoms or patients < 15 yr and > 55 yr	elastic bandage or Coumans-bandage
254	mild, moderate or severe symptoms	arthrographic exam. invers. stress exam.

The second group, consisting of 264 patients, was further subdivided on the basis of arthrographic and stress examination as follows:

Diagnosis		N	Treatment
1	No lateral ligament rupture (fresh trauma, one or more positive clinical symptoms, no arthrographic or stress examination abnormalities)	94	elastic bandage or Coumans-bandage
2	Suspected isolated capsular or old ligamentous lesions. Technical and administrative errors.	20	Coumans-bandage
3	Fresh lateral ligament rupture (abnormal arthrography without previous history of severe ankle trauma)	150	***trial*** (Ch. 12.2.) Group A: operation Group B: plaster Group C: Coumans-bandage

The last group (N = 150) was submitted to the trial program, with the results reported in following chapters.

11.2.2. Evaluation of clinical diagnosis

1.2.2.1. History

Age, sex and side of injury
A total of 109 (73%) male and 41 (27%) females, aged between 15 and 55 years (average: 27.6 years) were examined.

Table 24
Distribution by sex and trial group.

Treat. gp.	Total		A		B		C	
Sex	♂	♀	♂	♀	♂	♀	♂	♀
	109	41	41	9	34	16	34	16
Total	150		50		50		50	

There was a slight predominance of right-sided injuries.

Table 25
Distrubution by laterality and trial group

Treat. gr.	Total		A		B		C	
	Rt	Lt	Rt	Lt	Rt	Lt	Rt	Lt
N	79	71	20	30	27	23	32	18
Total	150		50		50		50	

Nature of accident

The majority of patients sustained their sprains while engaged in sport (table 26 and 27). The risk of severe injuries to ankle ligaments is particularly high in those sports that require players to jump up and down frequently in close proximity to opposing players, as in volleyball and basketball. In our material, 37% of the patients who sustained sprains while engaged in sport were volleyball players, 22% soccer players and 18% basketball players. Over one third of the patients sustained their injury at home or in road traffic accidents.

Table 26
Distribution according to circumstances of injury

Treat. gp.	Total	A	B	C
Sport	90 (60%)	31	29	30
Traffic/home	56 (37%)	17	20	19
Unknown	4 (3%)	2	1	1

Table 27
Distribution according to sport

Sport	Total	A	B	C
Volleyball	33 (37%)	12	9	12
Soccer	20 (22%)	5	6	9
Basketball	16 (18%)	5	6	5
Others	21 (23%)	4	8	9
Total	90	26	29	35

Nature of foot movement causing injury

At the first visit to the casualty department, the patient was asked to describe the movement of his foot at the time of injury, and to demonstrate this using the uninjured foot and ankle.

Inversion was the most commonly demonstrated movement (table 28).

Table 28
Distribution of patients according to the type of strain

Type of strain	Total	A	B	C
Inversion	135	48	44	43
Eversion	0	0	0	0
Unknown or others	15	2	6	7
Total	150	50	50	50

In contrast to the literature, a surprising number of patients (90%) was able to reproduce the ankle movement reponsible for the injury, and generally interpreted by the surgeon as inversion.
Eversion movements were not demonstrated. There was no explanation for this finding. Even the sudden and unexpected nature of the accident dit not prevent them from recalling and reproducing the movement of their foot at the time. Patients with a previous ankle sprain were excluded from the trial, as treatments can only properly be compared with fresh injuries. In the trial groups, it was assumed that previous ankle sprains forgotten by the patient could only have been minor trauma.
Remarkably none of the patients consulted a family physician prior to presenting at the casualty department, in spite of the fact that the family physician is the centre of the health care system in the Netherlands. No special note was made of the exact interval between the accident and arrival at the department. Only the date of accident was noted. 98% Of the patients consulted the hospital emergency department within 24 hours of the accident. The mean age of the patient group was 27.6 years, and, as in other literature reports, the injury was most common in young males.
An inversion movement of the foot was almost always the cause of the accident and most patients sustained their injury in sport.

1.2.2.2. Physical examination
In examination of the sprained ankle, special attention is given to the location of pain and swelling. All patients developed pain and swelling in the region of the lateral malleolus soon after the accident. The different ways in which patients had or had not treated their ankle immediately after the accident influenced the extent of the swelling. All patients were re-examined within five to seven days of trauma, and the localization of pain and swelling were particularly noted. After the standard initial treatment with plaster splint, elevation and Tanderil®, most of the patients showed slight swelling and typical bruising discoloration of the skin, distal to the lateral malleolus. In 150 patients with proven lateral ligament lesions, location of pain and swelling will be described separately.

1.
Pain
Pain is a dominant symptom of sprained ankles. Table 29 shows the incidence of pain in the trial groups.

Table 29
Distribution of pain in trial groups.

	Total	A	B	C
Pain	146	48	48	50
No pain	0	0	0	0
Unknown	4	2	2	0
	150			

Attempts to give a detailed description of the area with maximal pain sensation were disappointing. In general, the pain area more or less corresponded with the area of hematoma. Pressure pain was predominantly localized just in front of the lateral malleolus and sometimes directly below.

2.
Swelling
In all 150 patients, swelling was found over and around the lateral malleolus, with a marked blue discoloration of the skin, distal to the lateral malleolus.
The extent of swelling and pressure pain in the lateral malleolar region correlated with the size of hematoma, but not with the severity of damage.
In a few cases, the discoloration reached the base of the toes, and in severe cases, even involved part of the calf. In 47 cases, hematoma on the medial side of the ankle, just below the medial malleolus, was seen. In the operated group, this sign could be evaluated.
15 Patients out of 50 in this group showed a discoloration on the medial side of the ankle. This did not correlate with the number of ruptured lateral ligaments found at operation (table 30).

Table 30
Number of ruptured lateral ligaments in relation to hematoma on the medial side of the ankle.

Number of ruptured ligaments	1	2
Number of patients with medial hematoma	8	7

N.B.: The extent of ligamentous damage was expressed in the prepared number of ruptured ligaments. The diagnostic criteria to determine this number of ruptured ligaments are given in chapter 7, table 6. This subject will be discusses in chapter 14.

Severe swelling and especially discoloration on the medial side, can be considered a sign of lateral ligament rupture, but do not correlate with the severity of the damage.

11.2.2.3. Clinical stress examination
This was carried out independent of the radiologist and without anaesthesia. Often the patient's defence reactions caused by pain rendered this examination impossible.
The two methods used were the anterior drawer sign and inversion stress

examination. Examination of the anterior drawer sign was performed with the patient lying on his back on the examination table. For the right ankle, the right hand firmly grips the lower leg from the front, just above the ankle joint, while the left hand grips the heel from behind. With the foot in 30-60° plantar flexion, the calcaneus is pulled gradually forward. The anterior drawer sign was considered positive when the talus could be displaced from the mortise. One sometimes has the impression that the talus rides over a step, sometimes producing a typical sulcus between the lateral malleolus and the border of the lateral trochlea.

Three grades of anterior drawer sign were noted: pronounced (+), doubtful (±) and absent (−). When pain rendered examination impossible, the finding was recorded as 'unknown'.

Clinical testing of talar tilt was performed with the patient sitting on the examination table and the foot in 30-60° plantar flexion. For the right ankle, the right hand holds the calf firmly while the left grips the calcaneus from below and slowly but forcibly inverts the foot. The talar tilt phenomenon is positive when the examiner feels the talus subluxate from the tibiofibular mortise.

Sometimes, if swelling is only slight, a typical sulcus is seen between the tip of the lateral malleolus and the lateral border of the talus.

The results are classified as pronounced (+), doubtful (±), absent (−) and 'unknown' when pain rendered the talar tilt examination impossible.

Results obtained by clinical stress examination are shown in tables 3l to 34.

Table 31
Anterior drawer sign (ADS) in different treatment groups

ADS	Total	A	B	C
Present	98 (65%)	37	30	31
Doubtful	19 (13%)	6	8	5
Absent	13 (9%)	3	5	5
Unknown	20 (13%)	4	7	9
	150	50	50	50

In the operated group (A), peroperative findings were compared with anterior drawer sign results (table 32).

Table 32
Correlation between positive ADS results and number of ruptured ligaments

	Number of ruptured ligaments				
ADS	0	1	2	3	Total
Present	1	15	13	8	37
Doubtful	–	2	2	2	6
Absent	–	1	2	–	3
Unknown	1	1	2	–	4

From this table no clear correlation can be made between a positive drawer sign and the extent of ligamentous injury. The anterior drawer sign was positive, or at least doubtful, in all cases of severe damage (10 patients with rupture of all 3 ligaments).

Table 33
Talar tilt sign in the different treatment groups

Talar tilt	Total	A	B	C
Present	71 (47%)	24	24	23
Doubtful	19 (13%)	5	7	7
Absent	32 (21%)	13	11	8
Unknown	28 (19%)	8	8	12
	150	50	50	50

Peroperative evaluation of the talar tilt phenomenon was again possible in the operated group (A) (table 34).

Table 34
Correlation between talar tilt sign and number of ruptured ligaments.

	Number of ruptured ligaments				
Talar tilt	0	1	2	3	Total
Present	1	10	8	5	24
Doubtful	-	1	2	2	5
Absent	-	4	6	3	13
Unknown	1	4	3	-	8

There is no significant correlation between a positive talar tilt and the number of ruptured ligaments. Even in severe cases (10 patients with 3 ligaments ruptured) talar tilt was absent in three cases (33%).
In conclusion, clinical stress examination is of a very litte value in determining the grade of severity of lateral ligament injuries.
Pain prevents satisfactory stress examination in a significant number of cases. The anterior drawer sign, as assessed clinically, is a slightly more sensitive indicator of ligamentous damage than the corresponding talar tilt sign, but demands a high degree of technical skill in the examiner. Satisfactory comparison between normal and injured side is impossible, and a further reason not to consider ADS and TT as valuable diagnostic criteria.

11.2.3. Evaluation of radiological stress examination (summary)

As part of the diagnostic program, 150 patients of the prospective trial underwent inversion stress examination under X-ray control. A talar tilt difference of more than 5.5° was considered pathological.
The results in the three treatment groups are given in table 35.

Table 35

	Mean talar tilt talar tilt	Mean talar tilt difference (local anaesthesia)	Mean unilateral difference (general anaesthesia)
Group A	13°	10°	15.5°*
Group B	12°	9°	–
Group C	12°	9°	–

* only 35 patients in this group were examined under general anaesthesia.

Evaluation of the diagnostic criterion (talar tilt difference of more than 5.5°) was only possible in group A.
An inversion stress examination was also performed in 35 of the 50 operated patients under general anaesthesia, to study the effect of this type of anaesthesia in relation to the results of inversion stress examination. The diagnostic reliability of a positive inversion stress examination under local anaesthesia was 70%, while under general anaesthesia this reliability increased to 92%. There was no significant correlation between talar tilt difference and the extent of ligamentous rupture (table 7).

The findings show that talar tilt examination under local anaesthesia is diagnostically unreliable, but proves to be a sensitive indicator of lateral ankle ligament pathology when performed under general anaesthesia. Talar tilt difference cannot be correlated with the extent of ligamentous injury.

11.2.4. Evaluation of arthrography (summary)

The technique and results of arthrography are fully described in part 2, and only the relevant surgical aspects will be discussed here. Table 6 summarizes the arthrographic criteria used for the presence and type of ankle ligament rupture. Table 36 classifies the three treatment groups by number of ligaments ruptured as indicated arthrographically.

Table 36
Number of ruptured ligaments predicted arthrographically

	N	1 (TFA) ligament ruptured	2 or more ligaments ruptured
Group A	50	19	31
Group B	50	21	29
Group C	50	20	30

Surgical evaluation in group A confirmed the arthrographic diagnosis of ligamentous rupture (unspecified) in 96% of cases (48 out of 50 patients). However, the diagnostic reliability of arthrography in predicting the number of ligaments damaged was only 52%, the damage in 24% being more and in 24% less extensive than predicted

arthrographically. Positive arthrography is therefore a sensitive indicator of ankle ligamentous pathology, but has a limited specificity.
However, the diagnostic reliability of a normal arthrogram (i.e. no contrast leakage) in predicting absence of ligamentous damage, remains unknown.

11.2.5. Conclusions

In this prospective study, surgical findings in a series of 50 patients permitted evaluation of the diagnostic techniques of ankle arthrography and inversion stress examination (talar tilt). A talar tilt difference of 5.5° or more was considered pathological. Both inversion stress examination under general anaesthesia and arthrography proved to be sensitive indicators of lateral ankle ligament pathology (92%, 96% respectively). Arthrography is superior to inversion stress examination, done under local anaesthesia (96%, 70% respectively).
Clinical diagnostic techniques proved to be of very little value, in contrast to the findings of Frost (1974), Landeros (1968) and Prins (1978). Similarly, the technical difficulty and subjective nature of clinical ankle stability tests and the frequent lack of comparisons with the healthy side, make it impossible to consider these clinical techniques as diagnostically reliable.

12. Treatment of lateral ankle ligament injuries

12.1. Review of literature

12.1.1. Introduction

Treatment of injury to the lateral ligament of the ankle involves a choice between conservative and operative methods. In the Netherlands, most of these injuries were treated conservatively, but influenced by several Dutch publications (Kooyman 1976, Prins 1978, Raaymakers 1979) a tendency to surgical treatment has developed in recent years.
In the international literature, there are advocates of both approaches, and it is difficult to compare opinions and published results, especially as diagnostic criteria for lateral ligament injuries are still a matter of discussion. Some authors only diagnose lesions on clinical grounds, and others (Delplace 1975, Noesberger 1976, Seiler 1977) base their diagnoses on the anterior drawer sign test, while most authors use the talar tilt sign (Freeman 1965, Hansen 1979, Kooyman 1976, Redler 1977, Reichen 1974, Thomas 1973, Tonino 1973) but, as pathological index, use a talar tilt difference varying between 5 and 9°. Ruth (1961) measures his talar tilt difference in millimetres and sometimes an unilateral talar tilt angle was measured (Thomas 1973). Some authors do not even mention the talar tilt angle used (Fleischer 1971, Grönmark 1980, Raaymakers 1979).
In recent years stress examination has been increasingly combined with arthrography (Broström 1965, Prins 1978, Sanders 1972, Staples 1975 A,B).
Comparison of published results in treatment is even more difficult, because of the different treatment methods used. Most authors (Broström 1965, Gunther 1941, Hansen 1979, Russe 1967), using conservative treatment, use plaster cast for six weeks, but others (Adler 1976, Tonino 1973) extend this to 10 or even 16 weeks. Certain authors distinguish minor and major lesions, and vary the length of treatment accordingly (Adler 1976, Duquennoy 1975).
Various follow-up methods are used:
questionnaire, patient's report, physical examination, stress radiography etc..

Interpretation of all but the latter is subjective. The follow-up period varies considerably, and short term results can never be compared with long term results. To give an impression of the various results, a review of the literature is now given for the results of three treatment aspects:
12.1.2. conservative treatment, 12.1.3. surgical treatment and 12.1.4. comparative studies of conservative versus surgical therapy.

12.1.2. Results of conservative treatment

Güttner in Böhler's (Vienna) Clinic published the first well documented paper in 1941. Based on talar tilt examination, the patient was given a plaster cast for 4 to 6 weeks when the talar tilt was up to 10 mm and for 8 to 16 weeks when the talar tilt exceeded 10 mm. Ninetyfour patients were followed up for a period of 1 to 2 years. Persistent symptoms and a widened unilateral joint space on forced inversion were classified as a bad result. He found the following results:

first group (TT up to 10 mm)	: 36% poor result
second group (TT more than 10 mm)	: 14% poor result

Two to three years after the injury 12 of the 19 patients with a bad result (63%) showed osteo-arthrotic changes in the talocrural joint.
In 1967, Russe, from the same centre, followed up 100 patients for 8 years. Cases with up to 8 mm talar tilt were given a plaster cast for 6 weeks, with up to 25 mm for 14 weeks, while some very bad cases were given a plaster for 16 weeks.
At follow-up, 53 patients had persistent symptoms. The talar tilt was 0° in 60 patients, 0° to 11° in 35 and 11° to 15° in 5 patients. Tonino (1973) in a small series of 22 patients with a talar tilt difference of more than 6°, applied a plaster cast for 12 weeks (!). One to two years of follow-up showed 7 patients (32%) with persistent pain, swelling and instability. Radiological control revealed a talar tilt difference of 5° in one case, and less than 5° in the remainder. The first patient also complained of functional instability.
Adler (1976) treated 60 patients with a talar tilt difference of 8 to 54° by plaster cast. He randomized these patients into three treatment groups: 17 were treated with a plaster cast for 8 weeks, 17 for 10 weeks and 26 for 12 weeks. After an unspecified follow-up period, 77% were found to be symptom-free. Patients treated for 12 weeks showed the best results, namely fewer complaints or symptoms, and significantly smaller talar tilt angles.
Thomas and Hofmann (1973) presented a retrospective study on 90 patients with lateral ligament lesion of the ankle, based on an unilateral talar tilt of more than 8 mm. They were treated by plaster cast for 6 to 15 weeks, according to the tilting distance in millimetres. They found a good radiographic result in 71%, but only 34 patients (32%) had absence of residual symptoms. This fact was explained as an unreliability of the patients (!), 82 patients (91%) giving that they were satisfied by the end-result!
In 1979 Hansen presented a series of 174 patients with lateral ligament injuries of the ankle. Based on a talar tilt difference of more than 6° on stress radiography and clinical examination, a diagnosis of ruptured lateral ligament was made. Of 174 patients, 144 were seen for follow-up for 3.1 to 6.1 years (mean 4.2 years), the mean age was 26.9 years. 130 Patients were treated with a plaster walking cast for 6 weeks and 14 by a supporting bandage. At follow-up 30 patients (20.8%) had residual

symptoms. Pain and swelling persisted in 2.8%, functional instability in 12.5% and a combination of these in 5.5% (total: 20.8% poor results).
Only four patients had major complaints. There was no difference between the 14 patients treated with bandage and the 130 patients treated with a walking cast. Some patients complained about symptoms in severe foot stress (e.g. sportsactivities), but not in normal use. All soccer players with residual symptoms (23%) had to give up playing soccer. Hansen (1979) is not dissatisfied with the results of conservative treatment despite the high number of soccer players that stopped their favourite sport.
Termansen (1979), a co-worker of Hansen, described the radiological and muscular status at follow-up in the same series of 144 patients.
Radiological follow-up consisted of standard and stress radiography with the talar tilt and anterior drawer sign. With a strain gauge dynamometer, plantar flexion strength was measured. At follow-up 28 patients (19.4%) had mechanical instability, by the criteria of 6° talar tilt difference in inversion stress. Nine patients had an anterior drawer sign exceeding 2 mm. Statistical analysis showed no relationship between this secondary instability and residual symptoms. Five patients had radiological evidence of osteo-arthrosis, but only one had residual symptons.
Strength of plantar flexion was measured in 124 patients, and found to be significantly less in the injured than in the uninjured leg, but there was no significant correlation between either residual symptoms or radiological instability and reduced strength. Both Termansen en Hansen (1979) concluded that there was no reason to change their conservative treatment program.
The best results are those given by Chirls (1973) in a series of 176 patients out of a group of 237. The follow-up period was 2 – 10 years. Patients with what he called stress instability (without further explanation) were treated with a below knee plaster cast and crutches for 6 weeks, followed by four weeks weight bearing with a below knee walking plaster.
The results were assessed on the basis of physical examination, including talar tilt and patient's complaints. Results were excellent in 166 patients (92%), good in 6 (3%) and bad in 4 patients (2%). In conclusion, treatment of a lateral ankle ligament injury by below knee plaster cast may leave sequelae such as pain, swelling, and mechanical or functional instability (e.g. 'giving way') in a fairly large proportion of cases, varying between 2 and 53% as summarized in table 37. It seems that the longer the cast is worn, the lower the incidence of mechanical instability (Adler 1976 B, Russe 1967, Tonino 1973).
No relationship could be found between symptoms like 'fear of the ankle giving way' and a demonstrable mechanical instability of the ankle (Chirls 1973, Termansen 1979).

12.1.3. Results of surgical treatment

The moderate to good results of conservative treatment do not explain the popular swing to a surgical approach in the treatment of lateral ankle ligament injuries since the 1960s. A desire to understand the exact nature of damage beneath the skin urged some authors like Ruth (1961) to surgical exploration and suture of ligamentous lesions, especially in severe cases. However, Freeman (1965) says 'the incision used healed poorly and was unnecessarily extensive', showing an obvious lack of experience with surgical treatment. Today only a few descriptions of the surgical approach are available. Only Prins (1978) gives a clear and well illustrated

Table 37
Results of studies on plaster cast immobilization treatment

Author:	Year:	Number of patients:	Lenght of plaster cast treatment:	Follow-up criteria:	Bad results:
Güttner	1941	94	8-12 weeks	TT in mm	minor lesions: 36% major lesions: 14%
Russe	1967	100	6-16 weeks	TT in degrees	53%
Tonino	1973	22	12 weeks	Phys. examination TT in degrees	32%
Adler	1976	60	8-12 weeks	TT in degrees Phys. examination	23%
Thomas	1973	90	6-15 weeks	Phys. examination TT in mm	9-32%
Hansen	1979	174 (140 follow-up)	6 weeks	TT in degrees ADS in mm Phys. examination	20.8%
Chirls	1973	237 (176 follow-up)	10 weeks	TT in degrees Phys. examination	2%

description of the optimal approach to the ligamentous lesion, listing the anatomical structures and layers encountered in the process. He states that a good operative result can only be achieved with uncomplicated wound healing, and that operative tissue damage must be kept to a minimum. Some authors were impressed by the extent of the ligamentous damage found at operation, and, for example, Pascoët (1972) declares that 'healing by simple fibrosis within a plaster cast can never occur', a statement quoted, in consequence, by advocates of surgical treatment! Reichen and Marti (1974) observed poor apposition of ligamentous stumps, sometimes with interposition of fatty tissue, in over half of 90 patients operated on for lateral ligament injury, a remarkable observation, not confirmed by any other author.
Another common argument used by advocates of surgical treatment is that abnormal motility resulting from failure to repair ligamentous damage, may lead to damage to the cartilage of the talar trochlea, though there is again no published evidence for this statement!
Apart from general risks of anaesthesia and operation some specific points against surgery are the risk of defective wound healing, frequently described damage to branches of the peroneal or sural nerves, with resultant paraesthesia or neuromatous pain in the scar and the poor suture hold on irregularly torn ligament ends.
Few authors describe their suture technique, but by general agreement, Dexon®is currently the material of choice. For the capsule and anterior talofibular ligament, Prins (1978) prefers a running suture with monofilament prolene.
Makhani (1962) operated on 34 ankles for lateral ligament injury, and described the nature and extent of the lesions, but fails to mention the number in each case. In one case he found a neuroma of the superficial peroneal nerve, after an unspecified period of follow-up. Postoperatively, he applied a plaster cast for 6 – 8 weeks, without weight bearing during the first four weeks.
Two bad results were seen: one patient with persistent pain for two months and another requiring plastic repair of the ligament because of recurrent sprains.
Grond (1973) reports a small series of 10 patients with lateral ligament lesions, based on radiological stress examination. He neither describes all his operative findings, nor his ultimate results because the main reason for publishing his paper was the fact that in two patients the ruptured ligament stumps were 'inverted' and could not be re-approximated even by peroperative manipulation of the foot, and he concludes that adequate repair was only possible by surgery.
Reichen and Marti (1975) from the Weber Clinic, representatives of the A.O. school in Switserland, report results in 74 of a series of 90 patients, followed up for 2 to 6 years after surgical treatment of lateral ligament rupture. The diagnosis was based on radiological stress examination under regional nerve-block anaesthesia. A talar tilt difference of more than 5° was held to be pathological. The authors do not describe the lesion observed at operation. A plaster cast was applied for six weeks postoperatively, apart from a brief period of exercise between the fourth postoperative day and the time of wound healing ('intermediate functional therapy'). Follow-up by re-examination in 51 patients and telephone interview in the remaining 23, revealed 56 (76%) to be symptom-free. Out of the remaining 18 patients, 8 (11%) reported considerable discomfort: three cases of recurrent swelling, three of frequent 'giving way' of the ankle, one of neuromatous pain and one of articular locking due to a loose body. Only two of these eight patients proved to have radiological instability of the talocrural joint.
Gordon (1976) reported eleven cases of lateral ligament lesions in athletic young people. Based on arthrographic examination (four cases) or radiological inversion

stress examination (seven cases) with an unilateral talar tilt of more than 10°, he treated what he called 'severe lesions' (two ligaments presumed ruptured) by surgical reconstruction and a plaster cast for five weeks postoperatively.
Later examination proved all the ankles to be clinically and radiologically stable. All patients resumed normal activity without symptoms. The author, Gordon, fails to give his clinical and radiological criteria for injury of this very small series.
Redler (1977) reports 27 cases of acute ankle inversion injury diagnosed by radiological stress examination, a talar tilt difference of more than 9° being considered pathological, but confusingly, the talar tilt averaged 22° in both the 17 injured and 17 uninjured ankles! In all patients damage to the lateral ligaments was found at operation.
26 Patients were re-examined, after at least four months, and all reported the ankle to be stable. Postoperative radiological stress examination was performed in 50%, and showed an average talar tilt of 6°. The remaining 13 were clinically stable, so the author concludes that, despite the fact that 9 out of 26 patients had 'minor complaints', surgical repair offers the best prognosis.
Raaymakers (1979) reports 105 patients with lateral ligament injuries, diagnosed on radiographic inversion stress examination, but does not give the precise talar tilt difference. 91 Patients were treated by primary suture, and followed up for an average of 2.6 years. Out of 69 patients followed up, 4% active in some sport before their accident had to give up their sport. 88% Were satisfied with the end-result. The remainder complained of functional instability, but in only four out of nine patients a correlation with talar tilt instability was found. The authors state that the anterior drawer sign measured radiologically seemed to be more reliable, but fail to mention why.
Kooyman (1976) operated on 80 patients for lateral ligament injury based on talar tilt difference of more than 6° radiolocally. 64 Were re-examined 6 months to 2½ years after treatment, and 80% had no complaints. Radiological inversion stress showed stability in 79%, partial stability in 16% (1-3° talar tilt difference) and instability in 5% (3-11° talar tilt difference). Eight patients had to undergo secondary surgical repair of the ligaments by the Watson-Jones procedure. The author points out that he could find no relationship between functional and mechanical instability.
Fleischer (1971) reports many cases at operation of ruptured anterior talofibular ligament stumps projecting into the articular cavity, causing interposition of tissue. In a series of 35 out of 51 patients, diagnosed by inversion stress radiography and treated by primary suture and six weeks walking cast, 3 patients with a previous lateral ligament injury continued to have severe complaints post-operatively. The other 32 patients showed excellent results, but the author fails to give the criteria for this opinion.
During the 9th Reisenburger workshop in W-Germany (1977) – at which the majority of participants were A.O. members – lesions in the area of the ankle joint were discussed. Rockenstein reported a series of 102 patients treated by primary ligament suture and plaster cast, based on a talar tilt difference of more than 5°.
93 Of the 102 were re-examined for an unspecified follow-up period. 78.5% Were symptom-free, and only one patient complained of functional instability. Most patients were re-examined radiographically, and in two patients mechanical instability was demonstrated on the inversion stress views. In conclusion, 92.5% of patients were satisfied with the end-result and, according to the author, operative therapy is a superior method of treating lateral ligament ruptures.
At the same congress, Seiler reported his results in 127 patients with lateral

ligament ruptures, treated by primary suture and plaster cast immobilization, but did not mention his diagnostic criteria. At operation, flake fracture loose bodies were found in 20% of cases. 100 Patients were re-examined in an 1 to 4 year follow-up period. Based on a questionnaire, physical examination and radiographic inversion stress examination, it turned out that 70% of patients were symptom-free and 18% had severe complaints of functional instability and other disabilities, while radiographic instability was found in only 5%. Contrary to other authors, Seiler (1977) found a correlation between mechanical and functional instability: four of the five patients with functional instability had a proven pathological talar tilt difference radiologically, but the author did not give his criteria for 'pathological'. In 3%, there were osteo-arthrotic changes on plain X-ray.
Based on these results, he promoted the operative treatment of lateral ligament injuries. In their final remarks, Burri and Rüter concluded that calcaneofibular ligament rupture is a strong indication for surgical repair, and although doubt exists about surgical repair of isolated anterior talofibular ligament rupture, they tended to recommend this because of the supposed role of this ligament in chronic supination instability.
It is a pity that only advocates of surgical therapy of lateral ligament injuries presented their series. No comparative studies or studies on conservative treatment were presented at this often quoted workshop.
In conclusion, (summarized in table 38), in the treatment of injuries of lateral ankle ligament injuries, surgical repair and application of a below knee plaster cast gave good results in a fairly large proportion of cases (70 to nearly 100%), only a small number of complications being mentioned. In most series the mean period before resuming daily work and sports activity is unknown. With one exception (Seiler 1977), no correlation could be found between proven mechanical instability and patients' complaints of 'giving way', swelling and pain.

12.1.4. Comparative studies of conservative and surgical therapy

For many reasons, such as incompatibility of diagnostic criteria, different populations, therapeutic methods etc., comparisons on strict statistical and scientific grounds are not possible. Nevertheless, Jäger and Wirth (1978) in their 'standard work' on capsule and ligament lesions, grouped together several studies on conservative treatment and compared the resultant group of 795 patients with a corresponding multi-study group of 469 surgically treated patients, and presented the following results:

	Patients	Results		
		good	fair/poor	bad
conservative treatment	795	574	145	76
(percentage)	(100)	(72)	(18)	(10)
surgical treatment	469	421	31	17
(percentage)	(100)	(90)	(6)	(4)

Their conclusion is a preference for surgical repair.
In our opinion prospective comparative studies are essential, but unfortunately few such well documented and soundly based scientific studies are available.
Nevertheless, the following comparative studies are worthy of note.

Table 38
Results of studies on surgical repair of lateral ligament ruptures

Author:	Year:	Number of patients:	Follow-up criteria:	Poor/bad results:
Makhani	1962	34	?	6%
Grond	1973	10	X-ray stress examination	20%
Reichen	1975	90 (70 follow-up)	Phys. examination/questionnaire X-ray stress examination	24%
Gordon	1976	11	?	0%
Redler	1977	27 (26 follow-up)	Phys. examination	35% (minor compl.)
Raaymakers	1979	105 (91 follow-up)	TTD in ?/ADS in ? Phys. examination	12%
Kooyman	1976	80	TTD in degrees	21%
Fleischer	1971	51 (35 follow-up)	? (stress radiogram)	9%
Rockenstein	1977	102 (93 follow-up)	Phys. examination/ Inversion stress radiogram	7.5%
Seiler	1977	127 (100 follow-up)	TTD in degrees Phys. examination	18-30%

In 1961 Ruth, interested in these injuries, followed 104 patients for two years after accident. The diagnosis was made when unilateral inversion stress radiography showed unilateral talar tilt opening greater than 2 mm laterally. He began his study with 54 surgically treated patients, of which 22 were re-examined 2½ years after treatment and 10 replied to questionnaires. A series of 190 patients were treated with plaster cast for six weeks and 72 were re-examined two years after treatment. No persistent mechanical instability (talar tilt >3 mm) was seen in the operated group, but three patients (9%) had major complaints.
Of patients treated with plaster cast, 25 (35%) had radiological ankle instability, but all had satisfactory function! Ruth remarked at the end of his study: 'fifty similarly sprained ankles should have been treated with taping, injections, or massage as well as more than six weeks of immobilization of plaster'. He did not believe that these treatment methods would improve his results, a remarkable conclusion in view of the good functional results in the conservatively treated group.
Niethart (1974), based on an unilateral talar tilt >10° or on arthrography, treated 27 patients with a plaster cast for eight weeks and operated on a further 51 followed by plaster cast for six weeks. Patients treated conservatively were discharged from follow-up five weeks sooner. Patients operated on required physiotherapy for seven weeks to restore the normal ankle mobility. Functional instability shortly after the treatment was noted in two patients (7%) of the conservative group and nine (18%) of the surgical group. The situation, however, was entirely different two to six years after treatment. Though not all patients were followed, symptoms persisted in 55% of the conservatively treated patients and in 41% of the operated group. Functional instability remained in 30% and 19% respectively, and a mechanical instability (positive talar tilt phenomenon) in 50% and 17% respectively, suggesting that the initially good results of conservative therapy diminish relatively rapidly when compared with surgical treatment.
Staples (1972) described his results in a retrospective study of 51 patients treated exclusively with plaster cast, basing the diagnosis on radiographic talar tilt difference of more than 5°. After a relatively long follow-up period of 9.4 years he found 41% of persistent symptoms, but only two (4%) had severe disability. Nevertheless, 45% of the patients had proven mechanical instability (talar tilt >5°). Of those with persistent symptoms or mechanical instability, six or seven patients had old ankle sprains giving the same problems before trauma as after cast treatment.
Consequently, Staples changed to surgical treatment for all lateral ligament lesions, and in 1975 published the results of 11.4 months follow-up in 23 patients. Symptoms persisted in 16%, and 5% showed mechanical instability. Staples stated in 1975: 'it is evident that our previous study of patients treated by cast immobilization for rupture of the lateral ligaments of the ankle cannot be accurately compared with the present review of patients treated by early operative repair. The diagnostic technique differed – arthrography was used only in the group operated on. In addition, exact diagnosis of ligament damage was possible only in the group operated on. Postoperative care was generally more closely supervised in the surgical patient'.
To create a control group for comparison with surgical treatment, a small group of nine patients was treated by cast immobilization, but as these patients had refused operation, they cannot be considered as a real control group. Nevertheless, Staples studied these patients one or more years after treatment: five out of nine patients (56%) had full symptomatic recovery, two had mild persistent functional instability and one patient was seriously disabled, requiring surgical reconstruction. One

patient was unavailable for follow-up. Because of the high percentage of patients with total recovery in the operation group, Staples preferred surgical therapy for lateral ligament ruptures. However, based on his practical experience and the reasonably good results of cast treatment described in literature, he advised cast treatment for the older or non-athletic individual with lateral ligament rupture.
Study of the above mentioned publications emphasizes the need for prospective, randomized studies.
One of the best known and best documented studies, using identical methods of diagnosis, treatment and follow-up in all cases, is that published by Broström in 1965.
In 281 patients, diagnosis was based on the radio-arthrographic criteria described in chapter 4. In addition to the various types of lateral ligament lesion, Broström encountered eight cases of ruptured deltoid ligament and 28 of anterior tibiofibular ligament rupture.
The patients were divided at random into three groups and treated by three different methods: surgical repair of the ligaments, followed by three weeks plaster cast (95 patients), immobilization in a below knee walking cast for three weeks (82 patients) and in the third group strapping of the ankle with adhesive plaster or an elastic bandage, followed by immediate mobilization (104 patients).
Follow-up was for one to six years, averaging four years for the surgical group, 3.6 years for the group treated with plaster and 3.7 years for the group treated with adhesive plaster or bandage.
242 Patients were re-examined, and in 36 of the remaining 39 cases, information was obtained with the aid of a questionnaire or by telephone.
Symptoms reported by patients are shown in table 39.

Table 39
End-results of treatment – patients' evaluation (Broström 1965)

Symptoms	Treatment (n of patients followed-up)		
	Suture + plaster cast	Plaster cast	Strapping
Slight, due to instability	2	13	13
Severe, due to instability	1	4	5
From operation scar	7	–	–
No symptoms	85	64	84
Total	95	81	102

Symptoms of instability occurred in some 20% of the conservatively treated groups and in only 3% of the surgically treated group. The symptoms caused by the surgical scars consisted of hypo-aesthesia over the outside of the foot, which did not greatly trouble the patients. In one case, severe skin necrosis necessitated a second operation to apply a free skin graft.
In follow-up, Broström paid special attention to the anterior drawer sign, which was only tested clinically. The results are shown in table 40.

Table 40
End-results of treatment – physical findings (Broström 1965)

Physical findings	Treatment (n of patients physically examined at follow-up) Suture + plaster cast	Plaster cast	Strapping
Induration of soft tissues	4	14	16
Reduced mobility	4	0	2
Anterior drawer sign-pos.	4	21	23
Neuroma in operation scar	7	–	–
Reduced sensibility	5	–	–
Normal status	64	48	43
Total	86	76	80

The incidence of a positive anterior drawer sign was the same in the two groups treated conservatively (30%), but only 5% in the operated group. Broström found no correlation between a positive anterior drawer sign and patients' symptoms. Only 50% of the patients with a positive anterior drawer sign were troubled by subjective ankle instability. Broström concludes that, although surgical treatment gave the best results, it is not to be recommended as a routine, and all ankle ligament injuries should be treated with an elastic bandage, for the following reasons.

1.
Routine surgical treatment of these common injuries would greatly increase workload in surgical units.

2.
Operation entails some risks, such as infection of the joint.

3.
Residual symptoms after conservative treatment are usually mild and not disabling.

4.
Secondary surgical repair of ruptured ligaments can be performed years after the injury if necessary, with good results.

5.
Strapping with an elastic bandage causes far less work absence than the other two methods.

The only possible comments on Broström's conclusion have already been made by Prins (1978). First, restriction of surgery to the severe cases (21% of Broström's material) would greatly limit the demands on surgical clinics. Second, immobilization in plaster for only three weeks compared to the usual six weeks may not allow the ligaments time to regain their maximal strength, although there is no literature evidence for this.

In 1978, Prins published his thesis on diagnosis and treatment of lateral ligament injuries. This comprehensive study presented a well documented prospective randomized series of 298 patients with sprained ankles. Ruptures of ankle ligaments were demonstrated by ankle arthrography, using the Broström criteria to determine the grade of severity. He divided the patients into three groups, based on the supposed severity of lesion.

The first group of 101 patients, where arthrographic examination revealed no capsular or ligamentous lesion, were treated with an elastic bandage. In the second group, consisting of 93 patients, arthrography suggested rupture of the talofibular ligament and adjoining capsule. These ruptures were classified as minor lesions, and the patients were placed in two treatment groups, even numbers being treated with an elastic bandage, odd numbers with a below knee plaster cast for three weeks. The third group (104 patients), where arthrographic findings suggested anterior talofibular as well as calcaneofibular ligament rupture, were treated surgically (45 patients) or with a below knee plaster cast for six weeks (59 patients).
Prins (1978) evaluated short term results, some weeks after treatment, based on the patient's report about resumption of normal activity.
At the six month follow-up, results were based on patient's opinion and physical examination. For ethical reasons, only the third group was re-examined radiologically.
Table 41 summarizes the main follow-up results in group 2, and generally reveals no significant differences.

Table 41
Summary of results after treatment in group 2 (Prins 1978)

Treatment groups	Bandage (n = 41)	Plaster cast (n = 49)
Resumption of daily activities (weeks)		
averages	3.9	5.6
Corrected for plaster cast	6.9	5.6
New ankle sprain (%)	10	12
Pain on weight bearing (%)	68	71
Swelling (%):		
only after weight bearing	27	22
total	29	22
Fear of ankle giving way (%):		
only on uneven ground	93	92
total	93	94
Impairment of every day activities (%)	98	96
Resumption of sport (weeks)	41	56
Physical examination (%):		
swelling	12	12
tenderness	17	10
pos. drawer sign	61	45
pos. talar tilt	27	22

Table 42 summarizes the results for group 3 and shows that the group treated surgically had fewer residual and (highly significantly) better mechanical stability. Consequently, Prins (1978) preferred operative treatment for multiple lateral ligament injury.

Table 42
Summary of results after treatment in group 3 (Prins 1978)

Treatment groups	Operation (N = 45)	Plaster cast (N = 59)
Resumption of daily activities (weeks)		
averages	5.8	9.2
Corrected for plaster cast	8.8	9.2
New ankle sprain (%)	0	11
Pain on weight bearing (%)	7	63
Swelling (%):		
only after weight bearing	2	24
total	2	29
Fear of ankle giving way (%):		
only on uneven ground	20	92
total	22	92
Impairment of every day activities (%)	98	98
Resumption of sport (weeks)	77	29
Physical examination (%):		
swelling	0	15
tenderness	4	12
pos. drawer sign	31	63
pos. talar tilt	11	41
Radiological examination:		
drawer sign in mm average	4.4	5.6
talar tilt in degrees average	3.4	9.9

This study by Prins (1978) deserves some comment. First, division into minor and major lesions is based on radio-arthrographic criteria, which in our experience are only moderately reliable in determining the number of ligaments involved. An artificial division into major and minor lesions is thus created. Another problem is the short follow-up period. Physiotherapy, an essential part of treatment, was omitted. Correlation between mechanical instability and patient's symptoms is not mentioned.

In the literature, only three reports could be found of comparative studies, which include mobilization therapy such as taping or bandaging. Broström's study (1965), gave rather good results for bandaging. No special method was used, only an ordinary bandage.
The two other reports about bandaging the ankle are important.
Freeman's study (1965) was based on 46 partial and complete ruptures of the lateral ligament of the ankle, in 45 patients with no previous ankle symptoms. The diagnosis was made by stress radiography, a talar tilt difference of six or more degrees being considered to be pathological. Three randomly selected treatment groups were made:

12 ankles	strapping and mobilization
18 ankles	immobilization in plaster of Paris for six weeks
16 ankles	suture of the ligament followed by immobilization (unknown period)
46 ankles	

All patients were treated in a physiotherapy department as soon as possible. 40 Injuries were followed up clinically. Stress radiography was repeated on 42 patients (43 injuries) approximately three months after injury. One year after injury, 44 patients completed a postal questionnaire describing the state of their ankle at that time.

Results:
– final mechanical stability of the ankle:
(mechanical instability, being a talar tilt difference (TTD) of more than 4°)

mobilization	: 2 patients out of 12	TTD>4°
immobilization	: 2 patients out of 18	TTD>4°
suture + immobilization	: 0 patients out of 16	TTD>4°

– duration of initial disability:

symptomless:	mobilization (tape)	: 12 weeks after injury
	immobilization (cast)	: 22 weeks after injury
	suture + immobilization	: 26 weeks after injury

– incidence and nature of complaints one year after the injury:
The proportion of patients treated by mobilization finally becoming asymptomatic was similar to the proportion of patients treated by immobilization. But the results in the group treated by suture plus immobilization were markedly worse, only 4 out of 16 patients, compared with 16 out of 29 in the other group, becoming symptom-free. In all three groups the proportion of patients who complained that their foot tended to give away, in addition to being painful or swollen, was very similar.
As Freeman (1965) stated: 'it should be particularly stressed that, since every patient originally had a symptomless ankle, their final complaints must have been due to the injury described in this study'.
Freeman (1965) concludes that suture and immobilization guarantee final mechanical stability, but the advantages are not striking. The average duration of early disability was shortest after treatment by mobilization. After one year the highest incidence of persistent complaints was found in the group treated by suture of the ligament.
In all three groups the incidence of late functional instability was 40%. Importantly, he admits that the late symptomatic results would possibly have been better if a more limited incision had been used or if the suture had been followed by graduated mobilization, rather than by immobilization.
In considering the overall advantages and disadvantages, including the hazardous and time consuming procedure of suturing the ligament, he concludes that a preference for conservative treatment is reasonable. Only perhaps a loose body requiring removal or a total rupture of the lateral ligament (talar tilt angle difference of more than 30°) are relative indications for operation.

Later, Freeman (1967) tried to correlate the findings of functional instability with those of mechanical instability, but no relationship could be found and he concluded that the pathological process which is usually responsible for functional instability of the foot after a lateral ligament injury is at present unknown.
In his third article Freeman (1967) describes aetiology and prevention of functional instability of the foot, and states that, in particular, the mechanoreceptors in the human foot and ankle, may (among other receptors) control the instantaneous and qualitatively precise contraction of the calf muscles which must occur if the foot has to remain stable on uneven ground. The articular nerve fibres lying in ligament and capsule tissue, are ruptured in ligament ruptures, which may lead to partial joint de-afferentiation, which may be permanent. Freeman demonstrated experimentally that surgical neurectomy (of the cat's knee) leads to disturbances of the locomotion and reflex behaviour.
In a study of 95 patients after a ligamentous injury at the foot and ankle, he looked for a so-called proprioceptive deficit, using a modification of Romberg's sign. These patients were treated in one of three ways: 1. immobilization of the foot and ankle, 2. conventional physiotherapy or 3. exercises designed to develop co-ordination of the calf muscles. Freeman concludes that ligamentous injuries of the foot and ankle frequently produce a proprioceptive deficit affecting the muscles of the injured leg. This deficit is responsible for the symptoms of giving way of the foot. The incidence of both proprioceptive deficit and symptoms of giving way can substantially be reduced by treatment after injury with the co-ordination exercises he described. This treatment was based on the hope that some central process might compensate for the articular de-afferentiation and its consequent proprioceptive deficit and that such a process might be more effective by deliberate training.
Recently another publication of a comparative study was presented.
Grönmark (1980) described the results of a prospective randomized study of a series of 95 patients with an average age of 26.2 years treated and followed up for 17 months. The patients were divided into three treatment groups: 32 patients were treated with primary suture and plaster of Paris for six weeks, 33 patients with plaster of Paris only and 30 patients with strapping by means of non-elastic zinc-oxide strips. In strapping, they used a figure of eight pattern in which all the turns were crossed over the ankle, and eversion and inversion movements of the calcaneus were thus prevented, but some flexion and extension were allowed.
The diagnosis was based on clinical examination and an unspecified positive talar tilt sign on radiographic stress views. Unfortunately Grönmark (1980) also failed to describe his follow-up findings completely.
76 Patients (80%) were free of symptoms, but 19 (20%) had residual symptoms such as moderate pain after prolonged weight bearing and a slight tendency of the ankle to tilt. No radiographic re-examination of the ankle joint in stressed position was done. One patient of the operation group developed a deep vein thrombosis.
The results obtained in each of the three treatment groups were:

operation	:	97% free of symptoms
strapping	:	77% free of symptoms
plaster	:	67% free of symptoms

Grönmark points out that 'even if operation in our hands gave the best results, it does not mean that every patient with such an injury should be offered operative

treatment' and concludes without a reasonable explanation, that 'young physically active people, particularly active sportmen, are recommended for primary suture, combined with splinting in a plaster cast for at least six weeks'. Strapping is, according to Grönmark (1980), preferred if conservative treatment is indicated.

In conclusion, only a few good comparative studies reporting results of treatment of lateral ligament injuries are available. A preference for operative treatment is obvious and in general this kind of treatment achieves good results. Only Freeman (1965) reported poor results of surgical treatment, whereas Broström (1965), despite the good results of surgical therapy, advocates treatment of lateral ligament injuries with a bandage. The mechanical stability desired and achieved after surgical therapy does not seem to correlate with patients' symptoms and therefore there is some doubt as to whether a complicated and rather expensive method like operation should be advocated.

12.1.5. Experimental studies

It is clear that advocates of surgical repair of ruptured lateral ankle ligaments aim to provide an anatomical reconstruction of the ruptured ligaments, claiming that anatomical reconstruction (i.e. juxtaposition of the ligament stumps), prevents the formation of extensive presumably worthless scar tissue. There is a modest amount of nevertheless interesting literature reporting experimental work on influence of surgical repair and mobilization/immobilization on ligamentous healing, although the studies presented here only concern knee ligaments, or, in the case of animal studies, ligaments comparable to knee ligaments.

In a study of ruptured medial collateral rabbit knee ligaments followed by surgical repair, Hütschenreuter (1974) observed better results in a group treated by early mobilization than in a group treated by immobilization in plaster cast. In histological studies of the ligaments, a parallel arrangement of fibroblasts was found in the group treated by early mobilization after operation. In a study from the same centre, El Saman (1978) reported a higher tensile strength of partially cut and surgically reconstructed medial collateral ligaments of rabbit knees after mobilization treatment than after immobilization.

Noyes (1977) studied the effect of immobility on the biomechanical properties of an anterior cruciate bone-ligament-bone-unit of Rhesus monkeys. He reported significant decreases in maximum failure load. The change in mechanical properties, following immobility, indicated a significant alteration in the projected functional capacity of the ligament unit to resist loading and to resist elongation, factors which relate directly to the ligament's ability to provide joint stability. Even after resumed activity, it required up to 12 months in the Rhesus animal until ultimate strength properties returned to normal!

In animal studies (Jack 1958) only the results of good opposition of the ligament stumps of ruptured medial ligaments of the knee versus non-opposed stumps are reported. Histological differences between the two groups were found, the well opposed stumps being already united by collagen fibres in a parallel pattern. No publications could be found about the functional results. Based on experimental and clinical observations (A.O. group, i.e. Burri 1978 et al.) early mobilization after rigid fixation of fractures and surgical repair of ligament lesions of the knee, seems preferable. No experimental studies could be found reporting the effect of early mobilization on the results of ankle ligament lesions, and only some clinical results

(Broström 1965, Freeman 1965, Prins 1978) are available, showing moderate to good results of early mobilization.
The influence of mobilization should have been made the subject of an experimental study, comparing the results of surgical repair versus conservative treatment of ankle ligament rupture.
Awaiting the development of such an experimental study, we preferred to start a comparative clinical study, involving the use of a specially applied bandage (Coumans-bandage) followed by early mobilization. The results of this prospective randomized trial are reported in the remainder of this chapter.

12.2 Methods and materials

From 1-3-1979 to 1-5-1980, 150 patients with lateral ligament ruptures of the ankle joint, as judged by the diagnostic criteria discussed in chapter 11.2, were randomly divided into three treatment groups, schematically shown in table 43.
The patients in this trial were not able to influence the choice of such a group.

Operation group (Group A)
After the standard pre-operative examination, described in chapter 11, patients were operated upon the day after admission. Operation was performed under general anaesthesia with endotracheal intubation. The patient was slightly turned on his side, with the uninjured leg beneath and flexed at the hip and knee. An air inflated bandage above the knee was used to exsanguinate the leg. After desinfection with one percent alcohol-iodine solution and draping around the operation field (foot, ankle and distal half of the calf) the skin was covered with plastic adhesive sheet. A boomerang shaped skin incision was made on the anterodistal side of the lateral malleolus over a length of approximately 4 cm. The subcutaneous layer was divided and visible vessels were ligated with vicryl 3 × 0. The premalleolar fatty pad was severed in stages to the crural fascia, which was incised. An initial inspection of the ruptured capsular ligamentous area was made and followed by incision of the peroneal tendon sheath to provide better exposure of the calcaneofibular ligaments. Manipulation of the foot towards inversion gave a clear view of the totally ruptured ligament. The peroneal tendons were held out of the way by a blunt retractor. A careful search for avulsion fractures etc. was carried out. Reconstruction of the capsule and ligament rupture was performed using interrupted stitches of 4 × 0 vicryl, starting dorsally and the calcaneofibular ligament was mostly repaired using a mattress stitch. A running suture to prevent the risk of cutting out of the wound edges is not necessary. With the foot in eversion, all sutures were first placed, then tightened. Then the crural fascia was closed with vicryl, and the skin was closed with Donati knotted vertical mattress sutures of mersilene or nylon. After removal of surgical drapes and application of a compressive bandage to the foot, ankle and lower leg, a below knee L- and U-shaped plaster splint was applied. The tourniquet was then released.
The patient was kept in bed for three or four days postoperatively, with the foot elevated, and protected by oral anticoagulans (Sintrom mitis®). On the fourth or fifth day, the patient was mobilized for short periods with two elbow crutches.
One week postoperatively, the cast was removed, the wound inspected and stitches removed and, after application of a below knee walking plaster, the patient was discharged and allowed to resume full weight bearing 36 hours after application of

Table 43

	1 week	2 weeks	3 weeks	4 weeks	5 weeks	6 weeks
GROUP A – admission to the hospital – operation 1 day after admission – 1 week relative rest plaster splint no weight bearing	– removal stitches – below knee walking cast – full weight bearing – discharged					– removal of cast – Tubigrip® tubular bandage – physiotherapy
GROUP B – below knee walking cast – full weight bearing						– removal of cast – Tubigrip® tubular bandage – physiotherapy
GROUP C – bandage (Coumans) – exercise instruction – full weight bearing		– new bandage		– new bandage		– removal of bandage – elastic bandage if necessary – no physiotherapy

the cast. An appointment was made for the trauma clinic five weeks after discharge. Then, (six weeks after operation) the cast was removed and an elastic tubular bandage (Tubigrip®) was given to be applied below the knee for walking. Full weight bearing was allowed and physiotherapy commenced one day later. The physiotherapist was asked to treat the patient daily, for two weeks, by exercise, massage and supportive ultra-short wave therapy. The exercise program was given with the aim of restoring full muscle function and strength to the ankle.

Plaster cast group (group B)
The patients conservatively treated by plaster cast were given a cotton lined below knee walking plaster, applied in the same way as in the operation group, with the foot in slight eversion position, and full weight bearing allowed after 36 hours, providing the cast had fully dried. Patients were seen six weeks later to remove the cast, followed by the same after-treatment described for the patients in group A.

Bandage group (group C)
A detailed description of the Coumans bandage method is given at the end of this study.
For practical and technical reasons, the bandage was applied by Mr. Coumans himself, immediately after arthrography. The patient was then immediately allowed full weight bearing, and instruction was given on the use of the ankle during walking, and on a series of exercises, which are also described at the end of this study. Two and four weeks after the application of the first bandage, the bandage was removed, the skin cleaned and a new bandage was applied. No further instruction or physiotherapy was given.

Patients were requested to undergo four examinations during a follow-up program to assess the therapeutic results, based on patient's opinion, physical findings and inversion stress examination (after 1 year only), 9, 12, 24 weeks and 1 year after trauma, and if patients failed to keep their appointment, they were reminded by letter or telephone to come to the next clinic. In only three cases (two in the operation group and one in the plaster cast group) follow-up was incomplete, but this small number hardly influenced the statistical evaluation of the results.
Patient's judgement about the results of treatment was obtained by means of a questionnaire, with enquiries about daily and sports activities. A careful examination of the ankle joint at rest and in passive and active movement was then made. Finally, one year after trauma, a standard radiological control including inversion stress examination of both ankles was performed.

12.3. Results

12.3.1. Operative findings

Findings were as follows: 49 cases of capsule rupture of variable size, 48 of anterior talofibular ligament rupture, of which 4 were partial, and 31 of calcaneofibular ligament rupture. Additionally there were 32 cases of peroneus tendon sheath pathology (rupture of the medial wall with or without filling with blood) of which 23 had an accompanying calcaneofibular ligament rupture. One case of an isolated capsule rupture was found (table 7, patient 22) and in one other case (table 7, patient 17) there was no clear rupture of capsule or ligament, but there was a hypoplastic

anterior talofibular ligament and a blood filled peroneus tendon sheath. There were four cases in which the inferior extensor retinaculum was ruptured. In 41 cases the crural fascia was found to be ruptured. In the remainder this fascia was opened and any intra-articular haematoma present evacuated. Partial ruptures, particularly of the calcaneofibular ligament, i.e. capsule rupture with partial defect in the posterior wall of the peroneus tendon sheath, were classified as 'ruptured calcaneofibular ligament'. In nearly all cases the anterior tibiofibular ligament was inspected, but no rupture could be found. The foot was inverted to determine the damage to the posterior talofibular ligament, and, if ruptured, this was carefully reconstructed. In two cases small avulsion fractures of the lateral malleolus, not visible radiologically, were found. The loose fragments could be replaced and attached to the malleolus with one or two vicryl stitches.
In accordance with the findings of the anatomical study (chapter 2), a separate talocalcaneal ligament could not be distinguished in the lateral region of the ankle joint.
In all cases the ruptured ends of the collagenous fibre tracts could be easily re-approximated, no interposition of tissue being detected.

Figure 40
Number of patients in each treatment group back to work, plotted against the weeks after trauma.

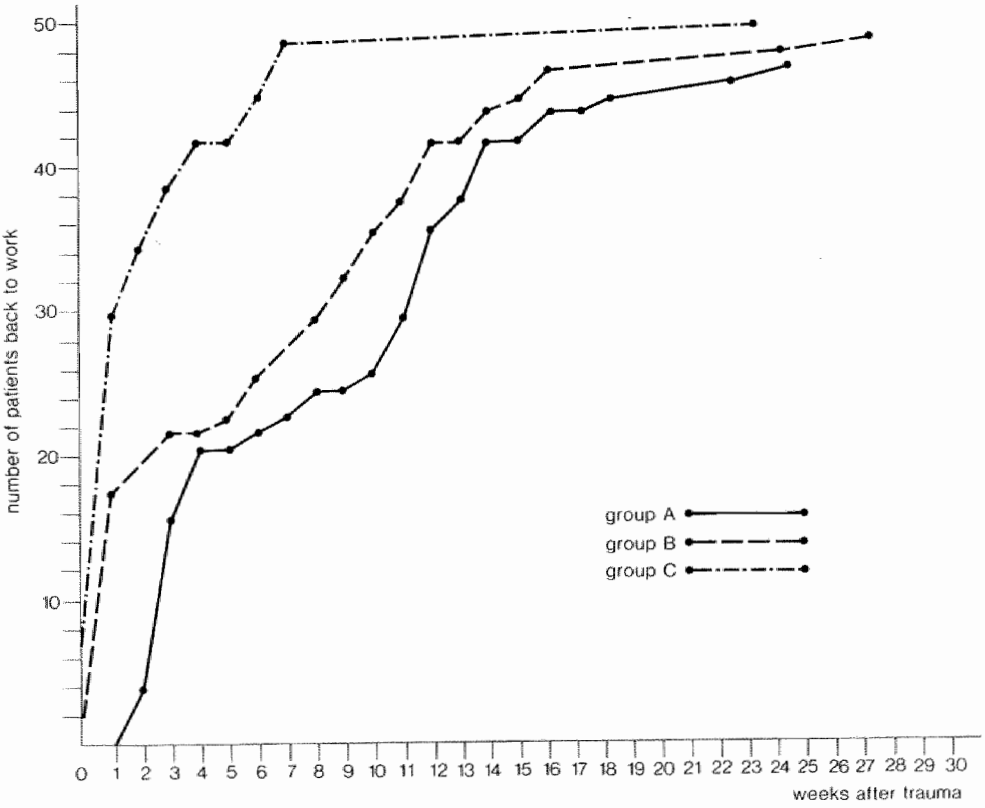

Note: after six weeks a second acceleration of the curves takes place in all three treatment groups. The treatment programme ends after six to seven weeks.

12.3.2. Therapeutic results

Restoration of normal activity is of utmost importance to the patient. No differentiation was made between school work, heavy work, sitting work etc., because it was assumed that the division of different activities was much the same for each category. In table 44 and figure 40, the average number of weeks of incapacity are shown.

Table 44
Resumption of daily work activities (averages in weeks)

Group A	9.7 weeks	A = operation
Group B	6.8 weeks	B = plaster
Group C	2.5 weeks	C = bandage

As shown in table 44 and figure 40 a remarkable difference could be found between the group treated by bandage therapy and the other treatment groups. It is clear that even a small operation like surgical repair of lateral ligament injuries, involves a rather long period of work absence, averaging over two months in our study.
Complaints during normal activity were obtained by asking the patient about pain and swelling in daily activities, such as walking or climbing stairs.
The patient was first asked when his walking returned to normal.
Table 45 shows that after nine weeks 32% of the patients in group A, and rather fewer in group B, could still not walk normally.
After twelve weeks the three groups hardly differed from each other.

Table 45
Normal walking pattern (rel. freq.)

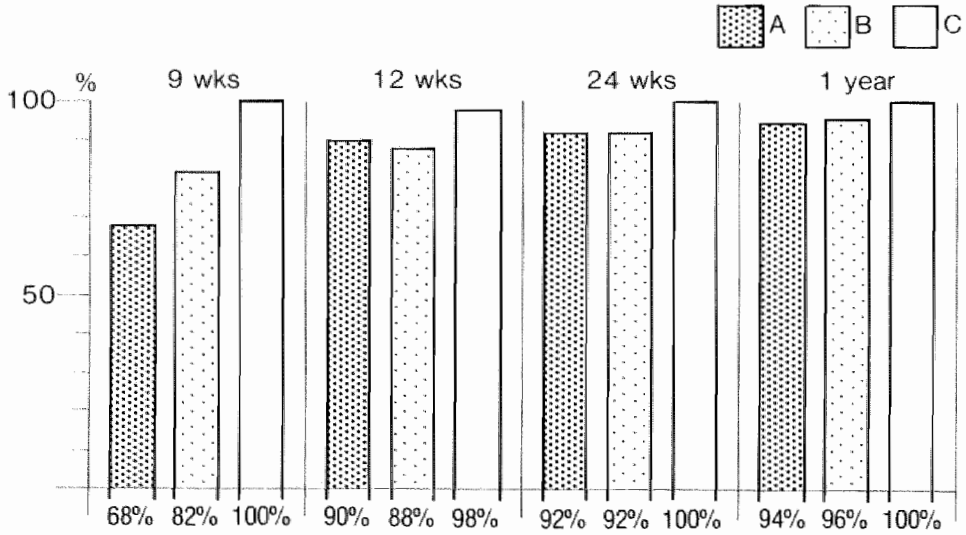

Table 46

Full ability to climb stairs (rel. freq.)

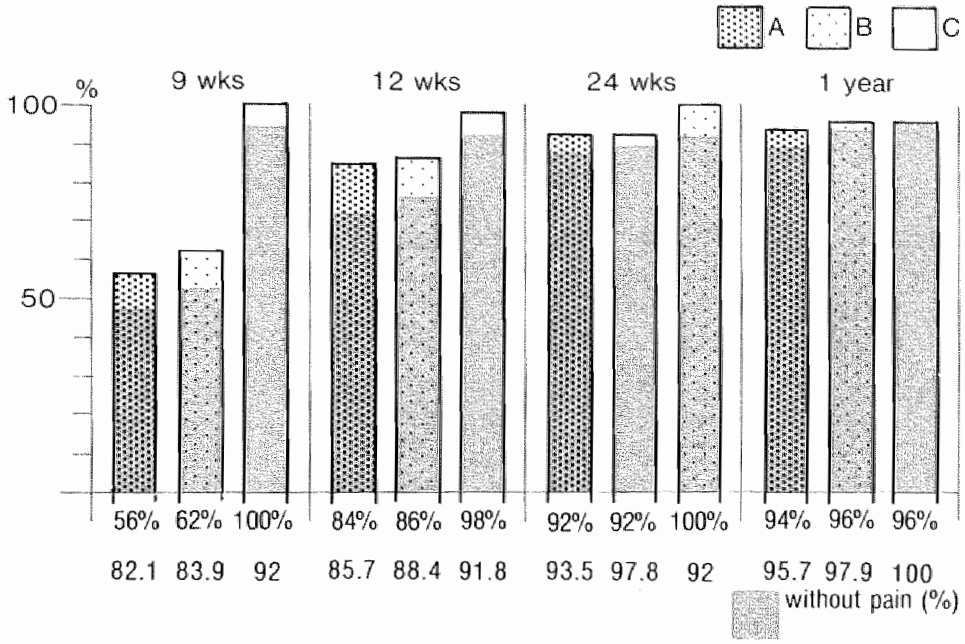

As shown in table 46 a more difficult movement like climbing stairs gives rise to many problems in groups A and B, even after twelve weeks, some 15% being unable to climb stairs without difficulty, whereas the bandage patients did not complain at all.

(x^2 – test – $P<0.05$)

Table 47

Pain in rest (rel. freq.)

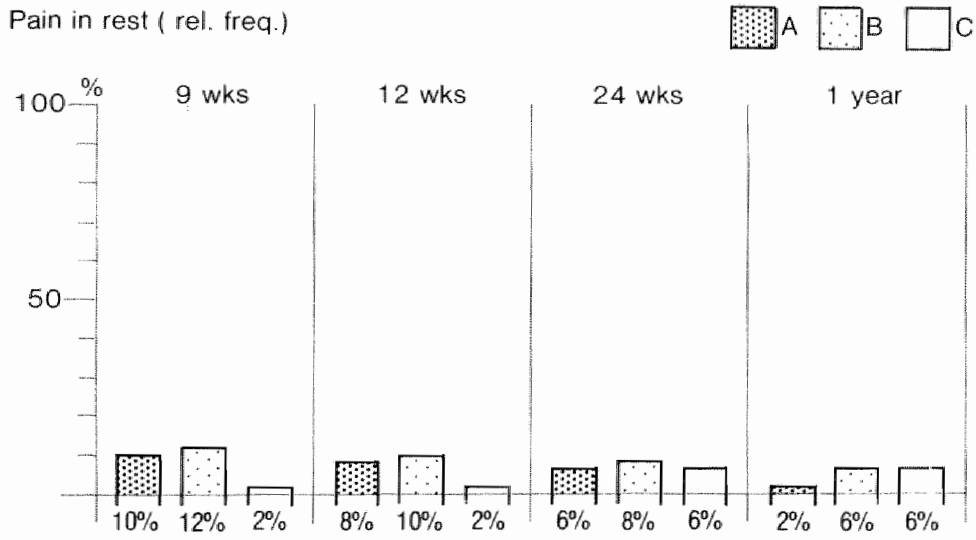

Table 48

Pain on weight bearing (rel. freq.)

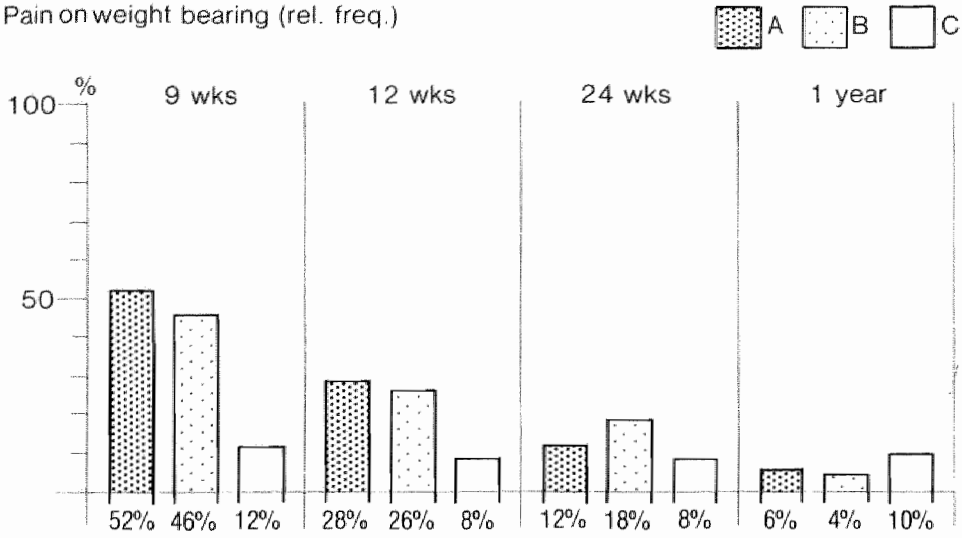

Pain

Disturbances in normal activities were mainly caused by pain. As shown in table 47, a small number of patients, equally spread over the three treatment groups, had pain at rest, but increasingly more pain occurred on weight bearing (table 48) and climbing stairs (table 49), especially in groups A and B (x^2-test: $P < 0.25$). Only after 24 weeks no significant difference could be found between the three treatment groups.

Table 49

Pain on climbing stairs (rel. freq.)

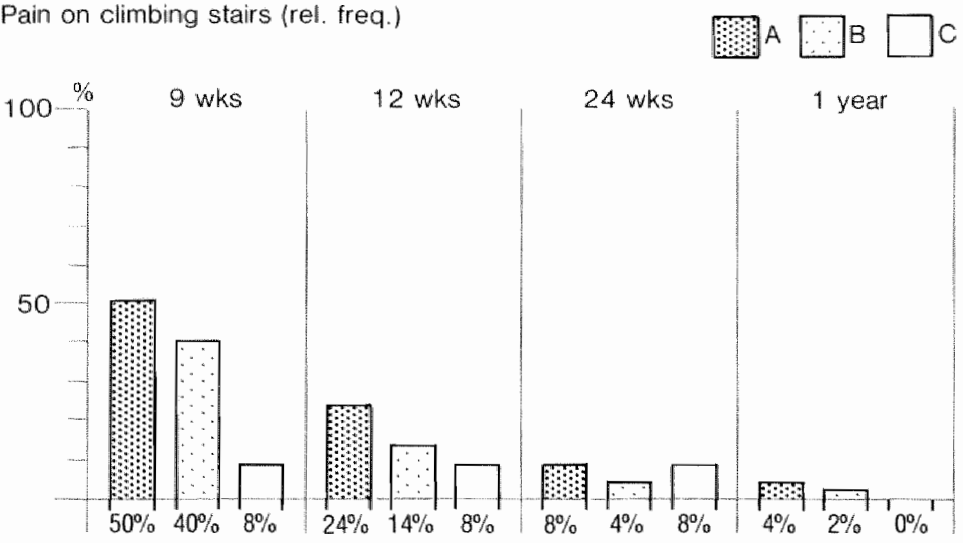

In all cases pain correlated fully with inability to walk normally or climb stairs, but the occurrence of swelling of the ankle during the day or in the evening showed no correlation with inability to perform daily activities.

Swelling

Patients were asked about swelling during the day or at the end of the day.
If patients complained about swelling during the day, they were asked whether the swelling increased by the end of the day.
Table 50 and 51 show the relatively small number of patients in the bandage group complaining about swelling.

A relatively high number of patients (28%) in group A still complained of swelling after six months, but after one year the group C patients had slightly more complaints (not significant).

Table 50

Complaints about swelling of the ankle-region during the day (rel. freq.)

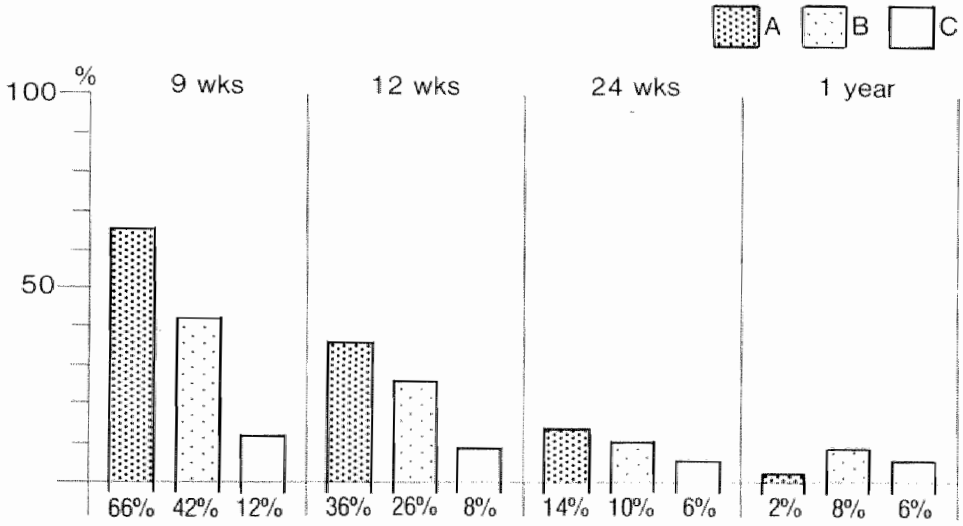

Sport

Information about sports activity was first obtained by asking the patient about reactions of the ankle joint to jumping. They were asked whether they could jump on both feet. The positive answers are shown in table 52, 'unknown' or 'unable' being considered as negative. Patients were also asked about pain on jumping. A considerable number of patients in groups A and B (no significant difference), were unable to jump without pain until after 24 weeks, whereas the bandaged patients reached this point far earlier.

Resumption of sports activity is an indicator of functional recovery. All patients were asked about sports activity, and if they did not play any sport, they were excluded from further questions about this item. Sportsmen were asked whether they had fully resumed (competition) sports activity and if so, a question was asked about pain and swelling during or after these activities.

Table 51

Complaints about swelling at the end of the day (rel. freq.)

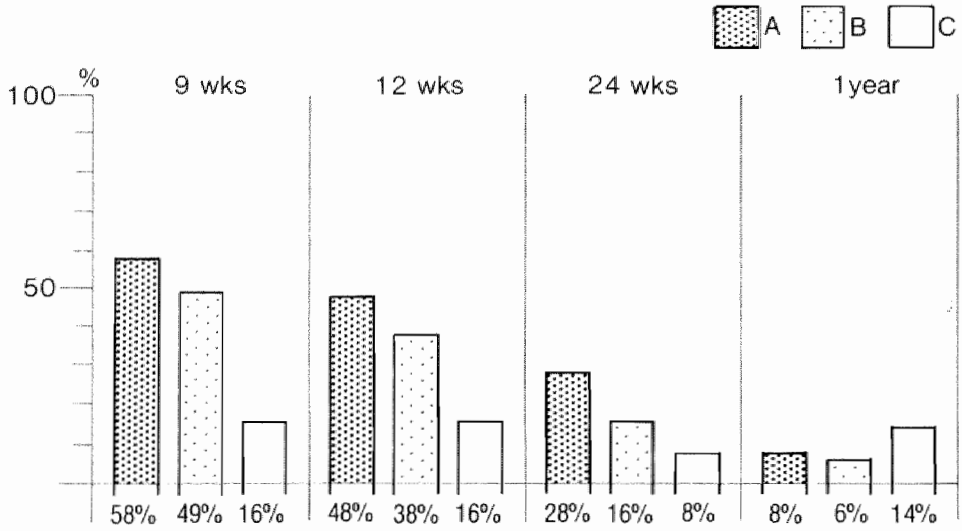

The results showed (table 53) that even after twelve weeks, less than half the patients in group A and B had restarted their sports activities, while most of the patients treated by a bandage reported full resumption of sport (x^2-test: $P < 0.005$).

Table 52

Full ability to jump (rel. freq.)

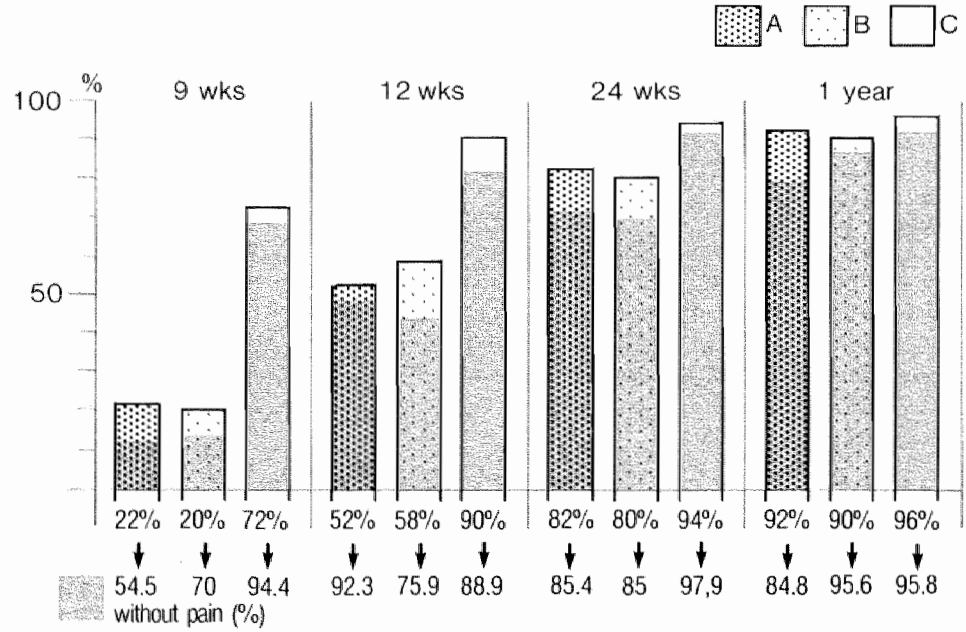

Table 53
Resumption of sportactivities
(results corrected for sportsmen) (rel. freq.)

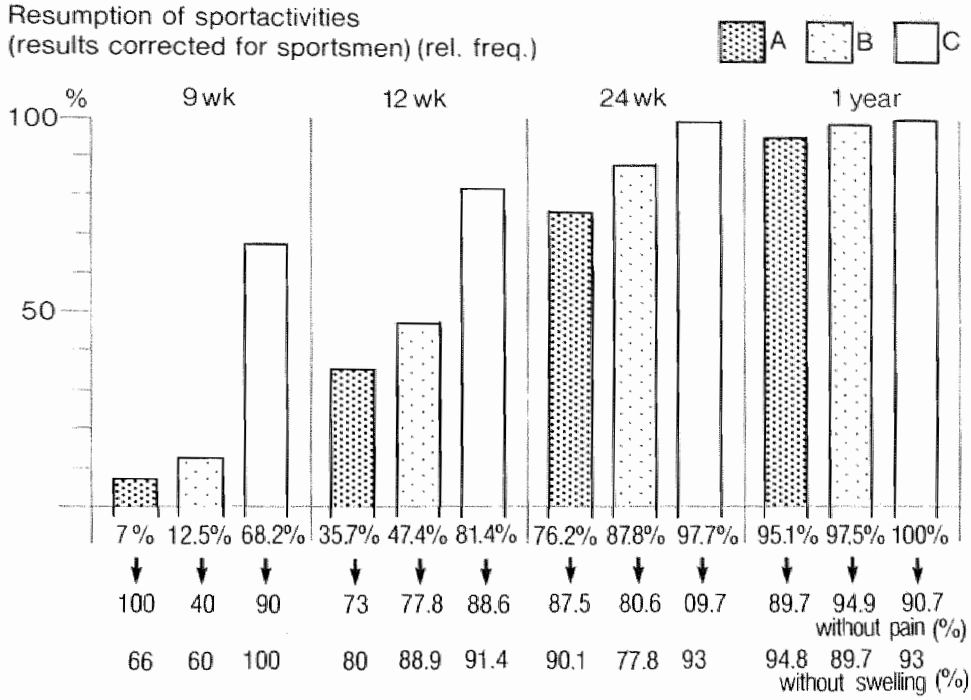

Fear of ankle giving way

Many authors (Freeman 1965, Broström 1965, Prins 1978 etc.) pay attention to the phenomenon of 'fear of ankle giving way'. All patients were asked whether they had fear of weakness with a tendency of the ankle to give way. If this was not the case, we asked about this fear while walking on uneven ground. In table 54 the positive answers are shown in relative frequencies, answers like 'no' and 'unknown' being considered as negative.

Table 54
Fear of ankle giving way (rel. freq.)

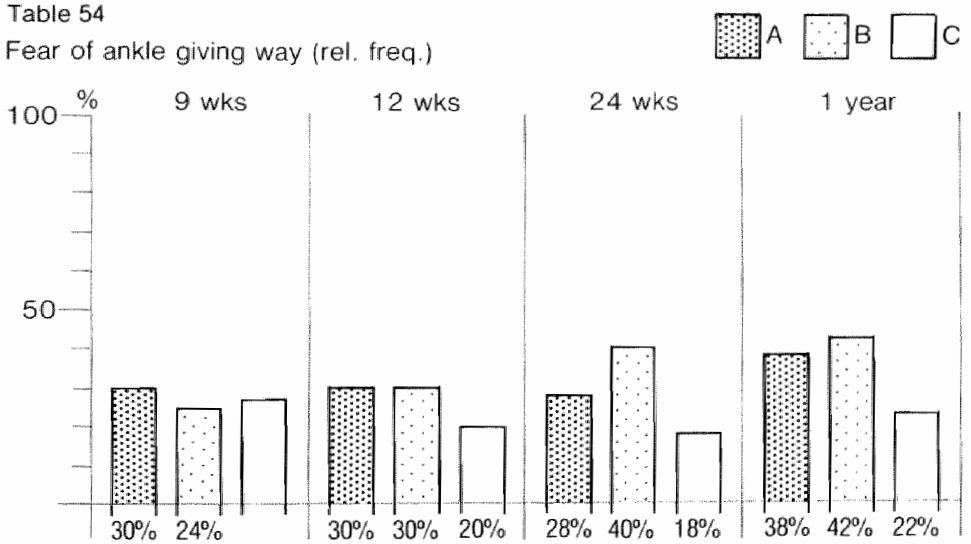

These results showed a rather large number of positive answers, especially in the A and B group, showing a remarkable constancy during the follow-up period. Because of the relatively high number of patients with limited activities during the first period a correspondingly high number of 'unknowns' was found in groups A and B. This could explain the constancy of this complaint over the follow-up period.
Recurrence of a sprain was the next item investigated. If the patient described any inversion trauma, followed by pain and swelling and a short period of disfunction of the ankle joint, occurring since the original trauma, this was interpreted as 'recurrent ankle sprain'. The results are given in table 55.

Table 55
Number of new ankle sprains (reported by the patients)

Group A	12
Group B	11
Group C	7

In one case (Group B), the clinical diagnosis of recurrent ankle sprain was confirmed arthrographically by the development of a typical leakage pattern six months after the original trauma. The patient was treated by a Coumans-bandage, mobilized, and full weight bearing was allowed. After eight weeks he was asymptomatic and back to work.
A possible correlation between the fear of ankle giving way and the severity of the trauma is of interest. In the literature, this is correlated with the number of ruptured ligaments, predicted arthrographically.
If we use the arthrographic criteria, the following results can be obtained (table 56).

Table 56
Fear of ankle giving way, one year after trauma, related to the supposed number of ligaments ruptured.

Group A (based on operative findings):			
number of ruptured ligaments	1	2	3
positive fear	9	6	4
Group B (based on arthrography):			
number of ruptured ligaments	1	2	3
positive fear	9	12	unknown
total number of patients	20	30	
Group C (based on arthrography):			
number of ruptured ligaments	1	2	3
positive fear	4	7	unknown
total number of patients	21	29	

The results (table 56) show no correlation between fear of ankle giving way and the supposed severity of trauma.

Table 57

Swelling of the ankle region (rel. freq.)

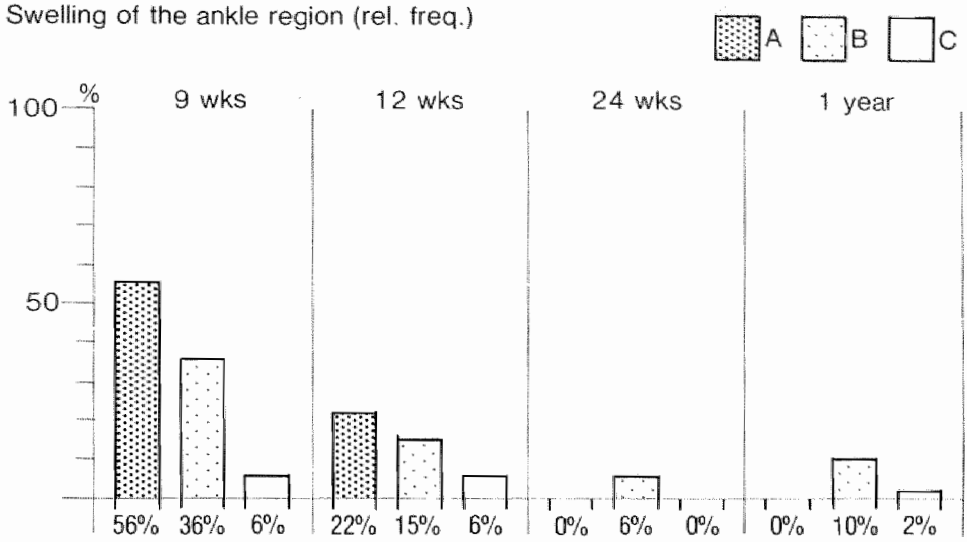

Physical examination

Swelling

Signs of swelling and atrophy were noted on physical examination. Swelling of the lateral side of the ankle joint, compared with the healthy side was found in the first weeks of follow-up. Nine weeks after trauma, 56% of the patients operated upon, showed a marked swelling of the lateral ankle region. However, no significant difference between the groups was found 6 months after trauma (table 57).
In the bandage group hardly any swelling was noted.

Table 58

Atrophy of calf muscles (rel. freq.)

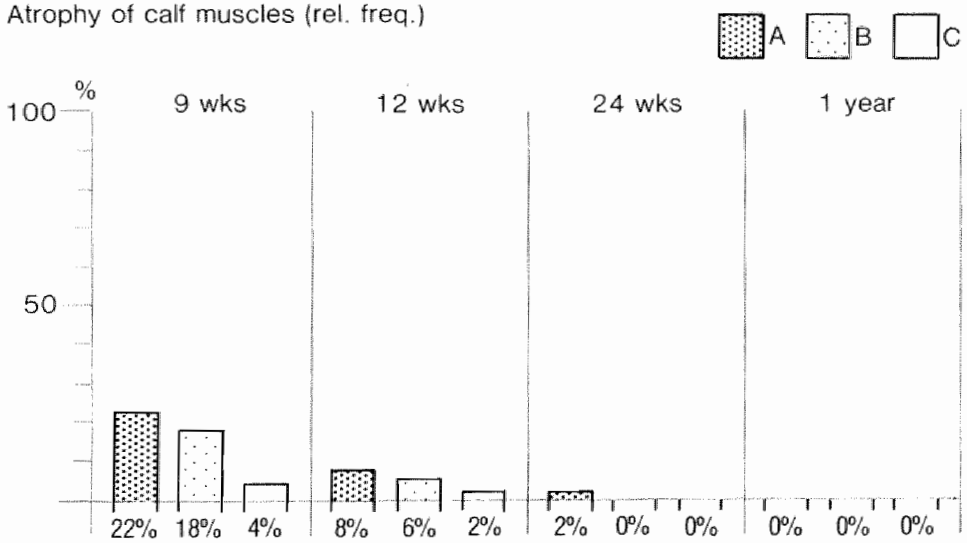

Table 59

Tenderness lateral malleolus/medial malleolus (rel. freq.)

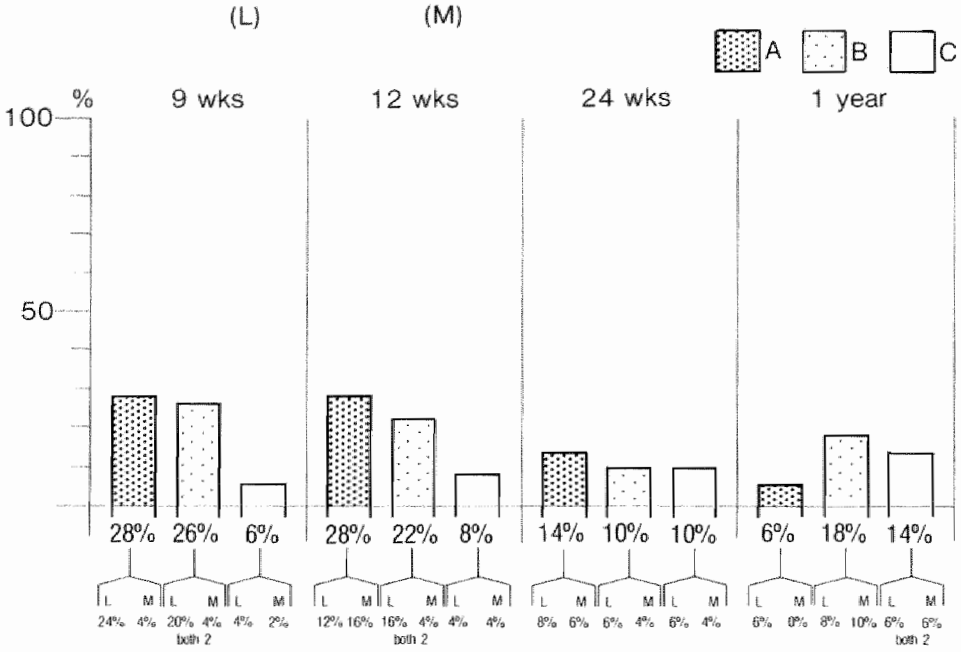

Muscle atrophy

The degree of calf muscle atrophy is difficult to estimate, because no reliable method of measurement is available. It was decided to speak of muscle atrophy only in cases of a severe decrease of the calf muscle contour, compared to the other side. The results are shown in table 58, showing significantly more atrophy (x^2-test: $p<0.005$) in groups A and B after nine weeks, while after twelve weeks no significant difference was found.

Again in the bandage group C, hardly any atrophy was noted.

Tenderness

After inspection, all patients were examined to find a possible location of tenderness. The results in table 59 show that the medial side of the ankle joint was also involved, relatively more in the late follow-ups. A relatively high number of patients in groups B and C still had tenderness in the ankle region after 1 year, while the patients of group A showed this phenomenon less at the last examination (x^2-test: $0.05<P<0.10$).

Mechanical instability

Mechanical instability of the ankle was clinically assessed by the anterior drawer sign and the talar tilt tests, positive signs being found in a minority of patients examined. Differences between the treatment groups were small, as shown in table 60.

Table 60

Positive anterior drawer sign - clinical testing
(+ data of pos. talar tilt = T.T.) (rel. freq.)

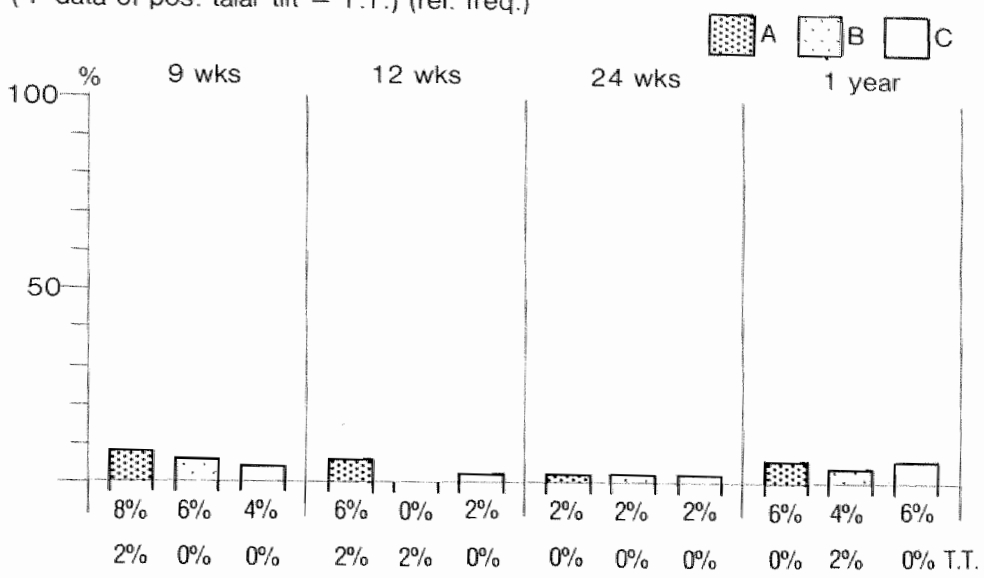

Ankle mobility

Ankle joint mobility was determined by measuring the angle between the sole of the foot and the tibial axis in full forced dorsiflexion and plantarflexion. The results, in table 61, show that after nine weeks, ankles treated by bandage therapy and early mobilization already had nearly full mobility, the ankles of groups A and B still being relatively stiff. (Note: values for each group within the range of standard deviation). From twelve weeks onwards, no difference between the groups could be found.

Table 61

Angle between maximal plantarflexion and dorsiflexion (average)

	9 weeks	12 weeks	24 weeks	1 year
Group A	74.1(SD 11.3)	87.0(SD 8.6)	93.7(SD 8.4)	98.2(SD 6.3)
Group B	77.2(SD 12.1)	90.6(SD 12.2)	99.3(SD 12.6)	104.2(SD 8.4)
Group C	86.1(SD 17.3)	92.7(SD 7.6)	97.8(SD 7.3)	100.3(SD 5.5)

At the end of the examination the patient was asked to squat and to walk on tiptoe. If performance of these actions was impaired and asymmetrical, this was recorded. Tables 62 and 63 show that only patients in groups A and B had trouble with these movements, but, after twelve weeks nearly all had returned to normal.

Table 62

Impairment to squat (rel. freq.)

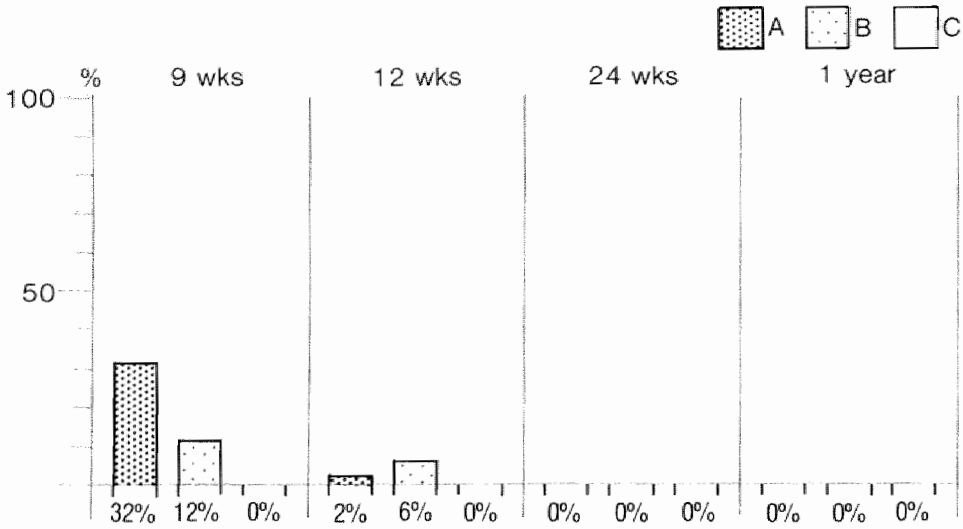

Table 63

Impairment to stand on tiptoe (rel. freq.)

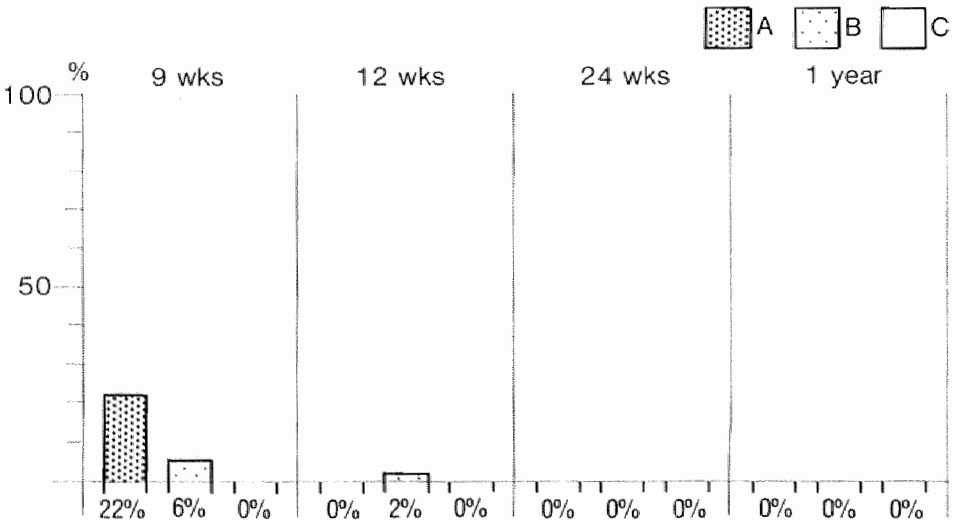

Radiological assessment one year after trauma

Follow-up assessment was supplemented after one year by inversion stress radiography of both ankles with measurement of talar tilt difference.

A radiological check for all other possible abnormalities such as osteoarthrotic changes, loose bodies etc. was made, but no abnormalities were found.

Table 64 gives the mean talar tilt values and differences.

Table 64
Stress radiography after one year

Mean talar tilt difference – inversion stress examination.

Group A	0°	SD: 2°	(TTD ≥ 5.5° n = 3)
Group B	1°	SD: 2°	(TTD ≥ 5.5° n = 7)
Group C	1°	SD: 2°	(TTD ≥ 5.5° n = 1)

Mean unilateral talar tilt – inversion stress examination.

Group A	4°	SD: 3°	(TT ≥ 5.5° n = 17)
Group B	5°	SD: 2°	(TT ≥ 5.5° n = 19)
Group C	4°	SD: 2°	(TT ≥ 5.5° n = 17)

The results showed less than one degree variation in the mean talar tilt angle differences, in all three treatment groups. There was a slight but insignificant difference in unilateral talar tilt between patients treated by plaster cast and the other two groups. We could not correlate the talar tilt data with either patients' symptoms or clinical abnormalities.
Tables 65 A and B show an attempt at correlation with the 'fear of giving way' symptom.

Table 65 A
Talar tilt difference ≥ 5.5° related to 'fear' of giving way

Group A	3 cases	1x positive 'fear' 2x negative 'fear'
Group B	7 cases	5x positive 'fear' 2x negative 'fear'
Group C	1 case	1x negative 'fear'
Total	11 cases	6x positive 'fear' 5x negative 'fear'

Table 65 B
Unilateral talar tilt difference ≥ 5.5° related to 'fear' of giving way

Group A	16 cases	4x positive 'fear' 12x negative 'fear'
Group B	21 cases	12x positive 'fear' 9x negative 'fear'
Group C	17 cases	4x positive 'fear' 13x negative 'fear'
Total	54 cases	20x positive 'fear' 34x negative 'fear'

Treatment complications

Any discussion on the relative merits of 3 treatment methods must include a review of possible and actual complications.

In the operated group, there was fortunately no defective wound healing, but three patients complained of wound pain and one of an area of hyperaesthesia (table 66). As already mentioned, careful inspection of the ankle joint was carried out at operation, and in three cases small flake fractures of the talar articular surface were found. These were removed, because re-insertion was impossible, and at one year follow-up, there were no radiological osteochondral abnormalities. In the conservatively treated patient groups inspection of the ankle joint could not be done, nevertheless no signs of loose bodies were observed during the follow-up period.

Table 66
Wound or scar disorders in group A (n = 50)
Infection = 0

	9 weeks	12 weeks	24 weeks	52 weeks
Pain	3	3	3	2
Hyperaesthesia	1	1	1	1

In the group treated with plaster, one patient complained of severe pain three weeks after application of the cast. Südeck's syndrome was suspected, the cast was therefore removed, and treatment with psysiotheraphy was started immediately. 'Adhesive capsulitis', generally considered to be a complication of ankle immobilization, was not seen in any of the 3 trial groups.

In the group of patients treated by bandage, one patient developed a mild skin reaction, seen after removal of the second bandage. The third bandage was therefore not applied, and instead an ordinary non-adhesive elastic bandage was used.

12.4 Discussion

The results of this comparative study on different treatment methods for lateral ankle ligament ruptures clearly show the collective advantages of early mobilization with a Coumans-bandage. Both, the rapid resumption of normal working activity, and the relatively low incidence of patient complaints in relation to both normal and intensive use of the ankle, in the short term, compare very favourably with the results of the two immobilization regimens of surgical repair of the ligaments, or simple plaster cast therapy. One must remember that there is a subjective element to both the information given by the patient and the interpretation made by the doctor in the assessment of these results, but, nevertheles, the rapid return to full sporting activity in patients treated by early mobilization is striking. Twelve weeks after trauma, nearly 80% of sportsmen treated in this manner had resumed sporting activity, the corresponding figure for the other groups barely reaching 40%. The resumption of full ankle function as expressed by a return to normal stair climbing and jumping ability, is again striking in the patients treated by bandage and mobilization. More objectively, physical examination also confirmed an earlier return to normal ankle joint mobility in the bandaged patients, when compared with the other two groups. The same trend is apparent for objective testing of the ability to

walk on tiptoe and squat. The long term results, as indicated by the one year follow-up, showed no significant differences, and were completely normal in all three treatment groups.

In terms of end-results, a much lower incidence of so-called 'unstable' ankles was found than reported by Broström (1965), but we can give no reasonable explanation for this finding, and it is doubtful whether this criterion has any functional implications. Clinical and radiological tests of stability showed no relationship with patients' functional satisfaction. At one year follow-up, the incidence of hypermobile ankles, as tested mechanically, lies entirely within the range of normality found in normal subjects, and in patients with normal arthrograms (part 2).
Unfortunately, our results are as yet relatively short-term, when compared with those of some other authors. The follow-up periods of Prins (1978) and Broström (1965) are comparable with our own. Prins felt that the time taken to resume normal every day activity was an unsuitable criterion for the comparison of different treatment programs.
Broström found significantly less work absence (mean 18 days) in the group of patients treated with elastic bandage, and this was confirmed by the results of this study. This finding forms the basis of his principle argument in favour of early mobilization of patients with lateral ankle ligament lesions.
From the point of view of treatment, advocates of surgical reconstruction emphasize the necessity to restore normal anatomy, to prevent a subsequent laxity of the ligamentous structures. This is a remarkable point of view, considering that nearly all studies in the literature fail to show any relationship between recurrent sprains, fear of the ankle giving way and radiographically measured instability. Such a point of view may be the result of a tendency to extrapolate to the ankle joint the known importance of the ligamentous structures in the knee joint. Broström (1965) recognizes this problem in stating that the anatomical construction of the ankle joint is basically different from that of the knee joint. Consequently, the collateral knee ligaments play a more important role in providing joint stability than the corresponding ligaments in the ankle. Our anatomical study on the ankle joint has already cast doubt on the isolated nature and role of the ankle ligaments.
In common with other authors (Kooyman 1976, Raaymakers 1979, Reichen 1975), no correlation was found between a fear of the ankle giving way and the severity of ligamentous pathology, as judged by inversion stress radiography and arthrography. It has to be remembered, however, that arthrography is limited in its ability to predict the severity of ankle trauma, and it is doubtful whether other diagnostic aids can improve on this (chapter 7). Twice as many patients treated by surgery and plaster cast in our material (groups A and B) complained of fear of the ankle giving way than those treated by bandage and mobilization (group C). The incidence of recurrent sprains in groups A and B was also higher.
Our data clearly indicate that attention should be paid not so much to the detailed nature of ligamentous damage or to its detailed reconstruction, as to the more important role of early mobilization of patients after application of a special supporting bandage, aimed at preventing loss of muscle tone and bulk and also ligamentous strength.
Freeman's publication (1965) suggests that recovery of ankle joint proprioception could play an important role, but this has not yet been adequately investigated from a neurophysiological point of view, and, in our view, the role of proprioception in recovery of function remains unclear. Furthermore, experimental work on animals

(El Saman 1978, Noyes 1977) clearly shows the consequences of immobilization, in terms of atrophy of connective tissue, although comparable experimental and clinical studies are required to confirm these findings in man.
The excellent results of early mobilization in patients in this prospective study provide good confirmatory evidence in this regard. The function of the bandage used in our treatment method requires particular discussion. The special manner of tape-application severely restricts free movement of the ankle joint, but this has not been objectively assessed, so further discussion must, of necessity, be hypothetical. It is of interest that these tapes produce a degree of skin traction, which could induce a proprioceptive reflex, resulting in contraction of the lower leg muscles, to prevent over-inversion. The bandage also operates in a conventional manner in preventing further swelling of the ankle. When the bandage was first changed after 2 weeks, the ankle region contours were surprisingly normal in nearly all cases. Many patients commented favourably on the feeling of support obtained from the bandage, and although they were forbidden to restart sport within six weeks of injury, several patients began careful running or jogging, four to five weeks after trauma, without any particular problems.
It seems reasonable to talk in terms of late results after a follow-up period of one year, but the period is obviously too short to detect possible osteoarthrotic change in injured joints. The results in all three treatment groups after one year were acceptable in that nearly all sportsmen had resumed full sporting activity, regardless of treatment method. Although we do not consider follow-up examination by inversion stress radiography to be as relevant as is generally assumed, the talar tilt differences, so obtained, showed no significant differences between the three treatment groups.
All the results in favour of early mobilization lead to the question, already posed by Broström (1965), as to whether treatment could be omitted altogether. This question is of course unanswerable, as there is no study with an untreated control group, and very doubtful, because, in the absence of treatment, resultant increased swelling will prevent the patient from using his ankle normally and probably bring about an abnormal walking pattern.
The results of our prospective randomized trial lead us to the following conclusions:
1.
Based on short and long term results, therapy with Coumans-bandage, followed by early mobilization, is the treatment of choice for all lateral ligament injuries.
2.
The need for anatomical reconstruction of ruptured lateral ligaments is neither confirmed by clinical results, nor by the findings of inversion stress radiography, (although we do not necessarily regard this as a reliable evaluation method).
3.
Immobilization, either as a chosen method of treatment, or enforced by surgical repair, leads to impairment of ankle joint function with a consequently longer recovery period than treatment by early mobilization in a Coumans-bandage.
4.
Post-traumatic complaints, such as fear of the ankle giving way or recurrent sprain, cannot be correlated with the degree of talar tilt found by inversion stress radiography.
5.
Based on the results of the prospective randomized study, operation or plaster cast immobilization no longer has any place in the treatment of ankle ligament injuries.

13. Summary (Part 3)

An extensive review of the diagnostic aspects of ankle inversion trauma reveals little data relating surgical findings to clinical diagnosis. The most commonly used radiodiagnostic test in inversion trauma has been inversion stress radiography, but in recent years, this has been supplemented by the more reliable technique of arthrography.

In a thorough evaluation of the clinical diagnostic features in 150 patients with lateral ankle ligament rupture, no reliable diagnostic sign was found. A careful study of the available radiodiagnostic methods is described in part 2 and reveals the overall superiority of ankle arthrography in the assessment of ankle ligament injuries.

A prospective randomized clinical trial of three different treatment programmes for lateral ankle injuries is presented, and early mobilization in a Coumans-bandage emerges as the treatment of choice. The short term results show particular advantages when compared to the groups treated by surgical repair or plaster cast immobilization, and in the long term, the results remain at least as good as the other two treatment groups.

Part 4

F.I. van Moppes – C.R. van den Hoogenband

14. Final remarks and summary

The purpose of this combined study was to attempt a radical reappraisal of present concepts of diagnosis and treatment of inversion trauma of the ankle. This involved a prospective comparative randomized trial of three therapeutic methods. Two of these (surgery and plaster cast immobilization) are already well documented in the literature and the third (early mobilization in a Coumans-bandage) is a specialization, which over many years has gained an excellent reputation, all be it on an empirical basis, of the widely used technique of bandage therapy. On the assumption that proper treatment demands the fullest possible diagnostic picture, an extensive investigation of available diagnostic methods was undertaken, and, in order to be able to express the diagnostic picture in precise anatomical terms, the anatomy of the ankle joint region was carefully re-examined.

The results of the therapeutic trial were conclusive in that early mobilization in a Coumans-bandage gave excellent one year results overall. The use of the Coumans-bandage yielded significant advantages over the other two methods in the immediate posttraumatic period, in that there was rapid return to normal and sporting activity. Secondary advantages are avoidance of hospitalization, of additional tissue damage caused by surgery, and of the side effects of immobilization. Furthermore, the Coumans-bandage method shows an excellent cost benefit value when compared with the other two methods.

It is remarkable that in the discussion in literature concerning the surgical repair of lateral ankle ligaments, nothing can be found about iatrogenic damage to the tissues during the operation procedure. The damage to the tissues caused by operation, performed with the aim to obtain perfect anatomical reconstruction of the ligaments, cannot be neglected.

A careful evaluation of symptoms and signs in the trial groups revealed that assessment of severity of connective tissue damage by clinical methods could not be substantiated by surgical findings.

A comprehensive study of currently available radiodiagnostic methods revealed the overall superiority of arthrography in demonstrating the existence of ligamentous damage in the ankle. However, none of these methods could, with any useful degree of reliability, predict the extent of any ligamentous damage, surgical findings frequently bearing little or no relationship to radiological predictions.

The unfortunate conclusion of these parts of the study is that neither clinical nor radiological techniques can provide the detailed diagnostic description thought to be necessary for appropriate therapy.

The anatomical study was undertaken with the intention to obtain a detailed picture of the individual ligamentous structures of the ankle joint, but, contrary to expectations and the belief of many surgeons, radiologists and even some anatomists, it was found that the connective tissue apparatus of the ankle could not be considered in terms of a 'string and elastic band model', but more as a connective tissue continuum with reinforced and non-reinforced parts, showing considerable individual variation.

In terms of current medical thinking, the goal of this study was to provide a detailed

(possibly complex) anatomical description, which could be expressed in diagnostic terms by a proven (possibly sophisticated) diagnostic method, providing the basis for an appropriately chosen (possibly also sophisticated) proven therapeutic method. However, the conclusions of the study must be that the expected detailed specific description cannot be made, and, consequently, diagnosis must be expressed in more general terms. Even in such general terms, neither clinical nor radiological assessment can do anything more than indicate the presence or absence of connective tissue damage. Statements about severity of damage are so frequently at variance with surgical findings that they are, for all practical purposes, useless. Even if a diagnostic indication of severity could be given in anatomic terms, this would not necessarily bear any relationship to the functional severity of the injury. The most remarkable conclusion of all is that, regardless of the anatomical or functional severity of the injury, mobilization with Coumans-bandage therapy produces the best overall therapeutic results. In consequence, the routine use of clinical and radiological stress examinations, ankle arthrography, surgery and plaster cast immobilization in the diagnosis and treatment of lateral ankle ligament pathology should be abandoned and replaced by the following program:

1.
All cases of inversion trauma of the ankle should be examined by standard radiography to exclude fracture.

2.
With the exception of cases with only minimal swelling, pain and discomfort, all patients should be initially treated with a plaster cast for four days, supplemented, if necessary, by elevation, bedrest and an anti-inflammatory analgesic drug.

3.
Patients with only minimal symptoms and signs either initially or after four days plaster cast therapy, should be treated by two weeks elastic bandage therapy.

4.
All other cases should be treated by a full program of six weeks Coumans-bandage therapy (changed every two weeks), careful instruction on an exercise program, and full active mobilization in normal daily activity, as soon as symptoms permit.

Table 67
Diagnostic and therapeutic protocol for inversion trauma of the ankle joint.

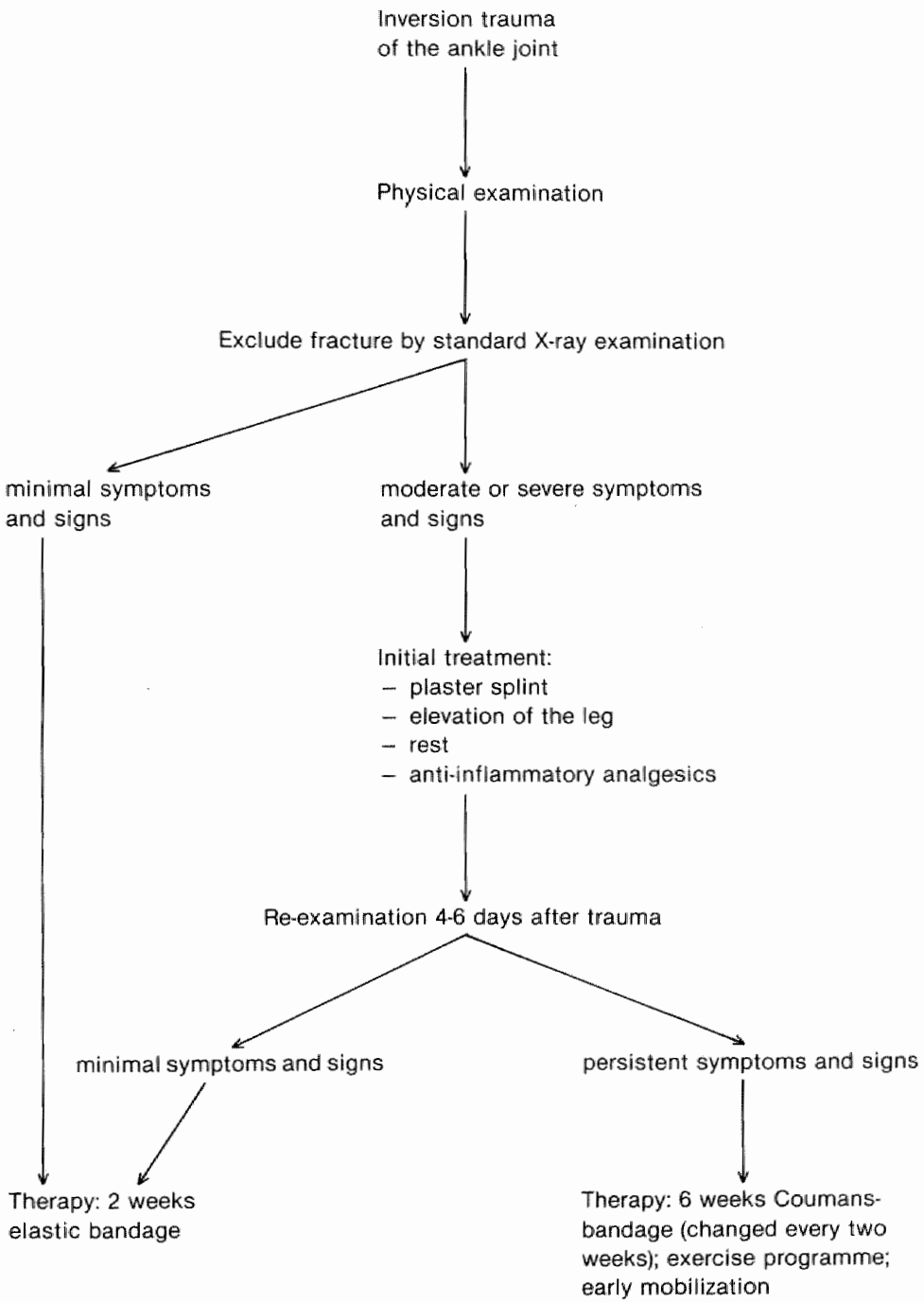

15. Samenvatting

Het inversietrauma van de enkel is een veelvuldig voorkomend letsel. Tot nu toe was het gebruikelijk om op basis van klinische en röntgenologische gegevens de ernst van de gevolgen van dit trauma, met name het letsel van het laterale bandapparaat, te classificeren.
Voornamelijk afhankelijk van het standpunt van de behandelende specialist wordt hierna een keuze gemaakt uit verschillende vormen van conservatieve en operatieve therapie. De laatste jaren is een duidelijke tendens waarneembaar, aan een operatieve benadering de voorkeur te geven.
Naar aanleiding van goede resultaten, verkregen met een conservatieve bandage-behandeling volgens de methode Coumans werd besloten een vergelijkend onderzoek in te stellen, ten einde tot een goede en objectieve beoordeling van de effecten van verschillende behandelingsmethoden te komen. De noodzaak werd gevoeld de behandeling vooraf te laten gaan door een uitgebreide en betrouwbare diagnostiek.
Hiertoe werden een anatomische en een radiodiagnostische studie opgezet om inzicht te krijgen in de anatomische aspecten in verhouding tot zowel radiodiagnostische technieken als therapeutische mogelijkheden.
Vervolgens werd een prospectieve, gerandomiseerde trial opgezet waarin alle laesies van het laterale bandapparaat van de enkel, ten gevolge van een inversietrauma, werden ondergebracht.
In deze trial werd de reconstructie van enkelbanden gevolgd door immobilisatie in loopgips vergeleken met immobilisatie in een gipsverband en mobilisatie in een Coumans-bandage.
In dit dubbelproefschrift worden de resultaten van de anatomische en radiodiagnostische studies alsmede van de prospectieve, gerandomiseerde therapeutische trial vastgelegd.

In deel 1 wordt aan de hand van een pilot cadaver-enkelstudie aangetoond dat het steunende bindweefselapparaat van de enkel beschouwd moet worden als een continuum, bestaande uit versterkte en niet versterkte kapsulaire elementen in driedimensionale samenhang met peesscheden en retinacula. Scheiding in kapsel en ligamenten is ten dele artificiëel en niet reëel en meer uit praktische en terminologische motieven ingegeven. Zo blijkt bijvoorbeeld, dat die vezels welke in de klassieke anatomische literatuur het extra-kapsulaire ligamentum calcaneofibulare genoemd worden, als kapsulaire versterkingselementen beschouwd dienen te worden.

In deel 2 worden de meest gebruikte radiodiagnostische methoden, inversie-stressonderzoek en arthrografie besproken en vergeleken. Op basis van onder andere experimenteel verkregen gegevens, werden criteria voor de diagnose van letsels van het laterale bindweefselapparaat van de enkel opgesteld. Deze criteria werden getoetst aan de tijdens operatie verkregen bevindingen. Het blijkt dat zowel arthrografie als stressonderzoek (zelfs onder algehele narcose) de ernst en uitgebreidheid van letsels van het laterale bindweefselapparaat van de enkel niet met voldoende betrouwbaarheid vaststellen, waarbij vermeld dient te worden dat arthrografie de meest betrouwbare methode is om zulke laesies aan te tonen.

In deel 3 worden aan de hand van de resultaten van een prospectief gerandomiseerd

onderzoek bij 150 patiënten verschillende aspecten van de behandeling van enkeltraumata besproken.
In de literatuur over het inversietrauma wordt veelal een onderscheid gemaakt tussen ernstige en niet ernstige enkelbandrupturen. Belangrijke consequenties worden hieraan verbonden ten aanzien van het therapeutische beleid in die zin dat voor ernstige laesies voornamelijk operatieve reconstructie noodzakelijk wordt geacht. Uit het gecombineerde onderzoek naar anatomische relatie, diagnostiek en therapie blijkt dat deze indeling en conclusie niet wenselijk zijn en diagnostisch een dergelijk onderscheid niet te maken valt.
Uit de resultaten van de trial blijkt onmiskenbaar dat behandeling met de speciaal geconstrueerde bandage volgens Coumans in combinatie met mobilisatie vele voordelen biedt boven operatieve en conservatieve behandeling met loopgips. Met name het snelle functionele herstel van het enkelgewricht door de combinatie van bandage en mobilisatie onderscheidt deze behandelingsmethode duidelijk gunstig van de andere twee.
Het meest opvallende voordeel van de bandagemethode is de snelle hervatting van de normale dagelijkse activiteiten en de vlotte terugkeer in de sport. Naast economische voordelen is de korte arbeidsongeschiktheidsduur met deze methode opvallend.
Uit de follow-up studie die voor alle behandelde patiënten minimaal 1 jaar beslaat blijkt, dat met de drie toegepaste behandelingsmethoden na deze periode geen significante verschillen in behandelingsresultaat aantoonbaar zijn. Wel menen wij dat tot nu toe in de literatuur de bij operatieve benadering tijdelijk veroorzaakte iatrogene schade aan structuren rond het enkelgewricht maar zelden naar voren wordt gebracht. In de discussie omtrent de wenselijkheid van zorgvuldige anatomische reconstructie van geruptureerde enkelbanden is dit eveneens een mee te beoordelen element.

Op grond van de resultaten en follow-up studie moet gesteld worden dat de eenvoudige en veilige Coumans-bandagebehandeling de voorkeur verdient boven alle andere, operatieve en/of immobiliserende methoden. De Coumans-bandage kan ook zonder problemen toegepast worden bij eenvoudige letsels van de enkel. Deze behandelingsmethode heeft belangrijke gevolgen voor het diagnostische programma. Uitvoerige diagnostiek kan achterwege blijven bij gebrek aan therapeutische consequenties.
Op grond van de resultaten van deze gecombineerde studie kan men naast het klinisch onderzoek volstaan met een standaard röntgenologisch onderzoek ter uitsluiting van fracturen. Arthrografie dient gereserveerd te blijven voor de diagnostiek van sommige degeneratieve aandoeningen van het enkelgewricht zoals capsulitis adhaesiva, ziektebeelden die overigens zelden worden gezien.
Samenvattend kunnen de volgende aanbevelingen ten aanzien van diagnostiek en therapie van laterale enkelbandlaesies worden gegeven:

1.
Na inversietrauma van het enkelgewricht is het noodzakelijk om een standaard röntgenonderzoek in twee richtingen van de enkel te maken ter uitsluiting van fracturen.

2.
In alle gevallen van pijn en zwelling dient begonnen te worden met een initiële behandeling die bestaat uit: immobilisatie in een gipsspalk voor vier dagen en, indien

noodzakelijk, het advies om rust te nemen met het been hoog gelegen. Medicatie met antiphlogistica kan overwogen worden.

3.

Patiënten met minimale klachten en symptomen direct na het trauma of na 4 dagen initiële behandeling dienen met een normale elastische zwachtel behandeld te worden.

4.

Bij alle andere patiënten moet de immobilisatie worden beëindigd met een volledig programma van driemaal 2 weken Coumans-bandage, gevolgd door snelle actieve mobilisatie. Bij deze mobilisatie, direct in aansluiting aan het aanleggen van de eerste bandage, dient vooral gelet te worden op een juiste ontwikkeling van het looppatroon. Dagelijkse activiteiten kunnen hervat worden zodra de symptomen dat toelaten.

Instruction for the application of a Coumans ankle bandage in the treatment of lateral ligament injuries.

Materials:

- razor
- plastic spray to protect the skin
- elastic porous adhesive bandage 7.5 cm and 5 cm
- non-elastic porous adhesive tape 2.5 cm

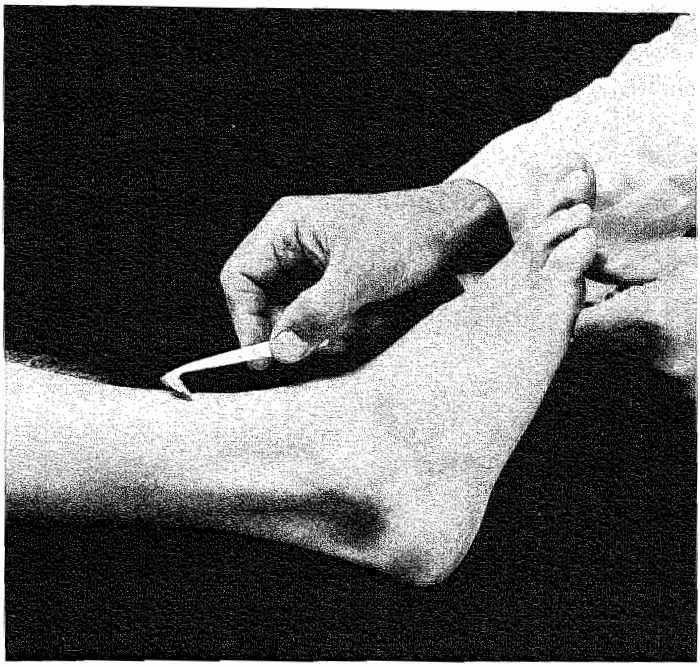

Figure 1

Shaving the skin of the ankle and lower leg 10 cm proximal to the malleoli.

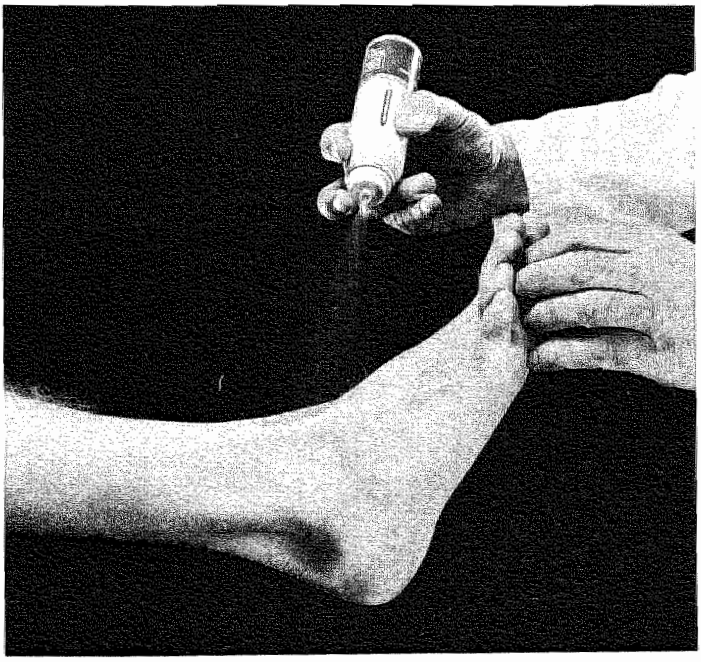

Figure 2

Skin protection with plastic spray.

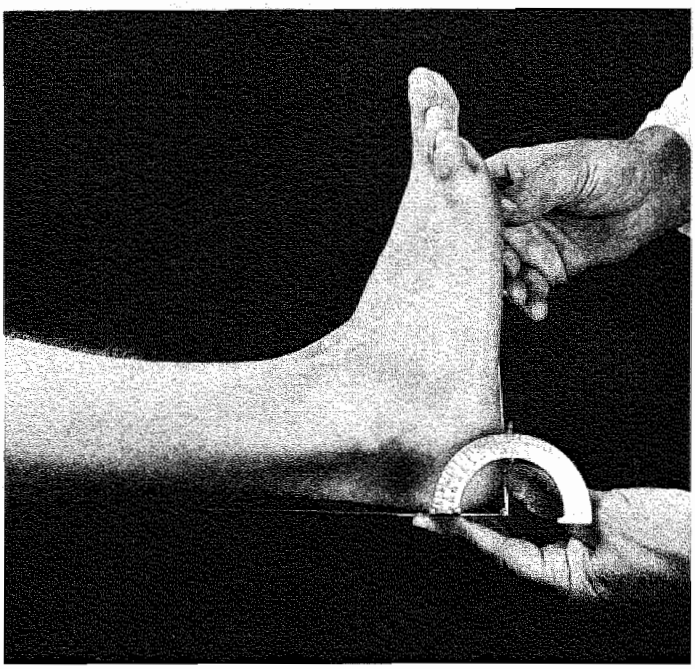

Figure 3

Correct position of the foot with the sole of the foot at 90° to the long axis of the lower leg.

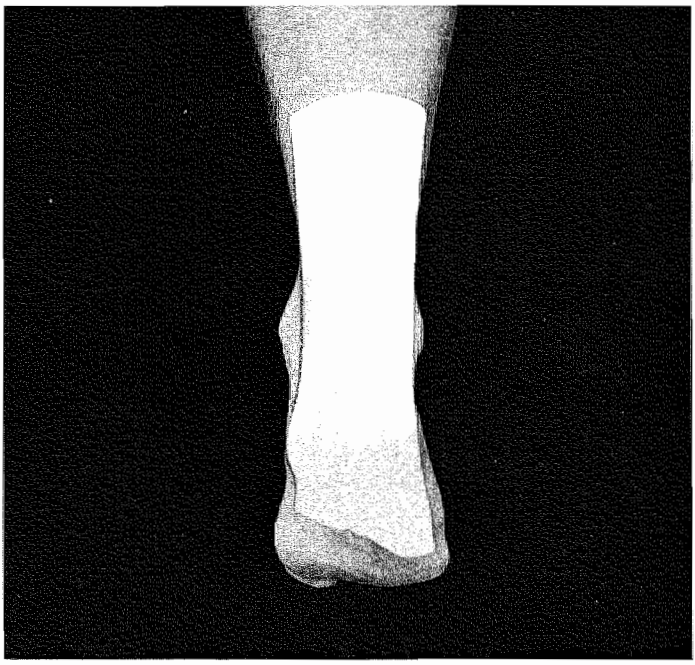

Figure 4

7.5 cm tape running from approximately 20 cm proximal to the heel to the middle of the sole of the foot (The 'L-TAPE').

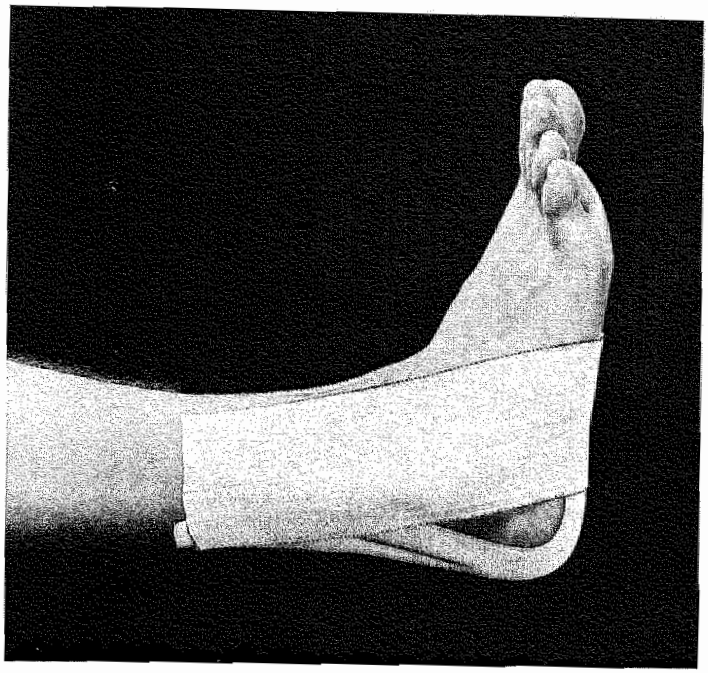

Figure 5

7.5 cm tape stretched around the sole of the foot, covering both malleoli and reaching the same level of the leg as the 'L-Tape' (The 'U-tape').

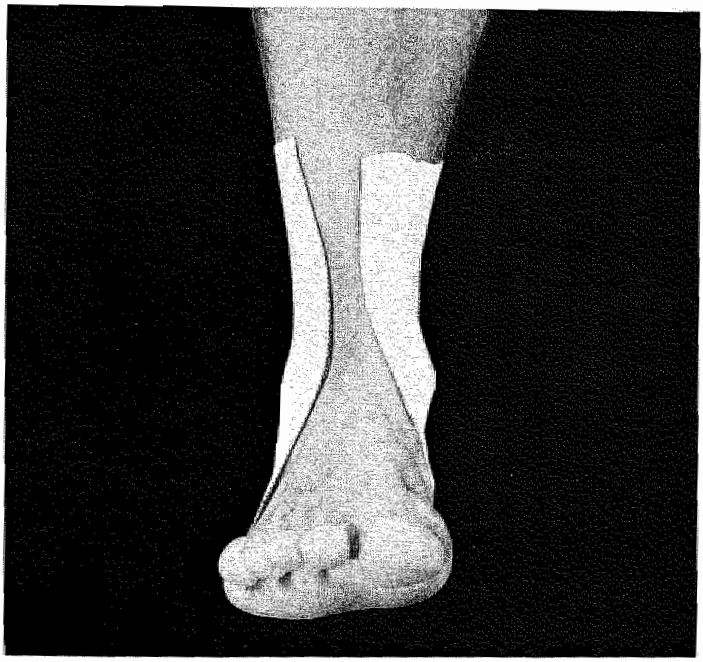

Figure 6

Anterior view.

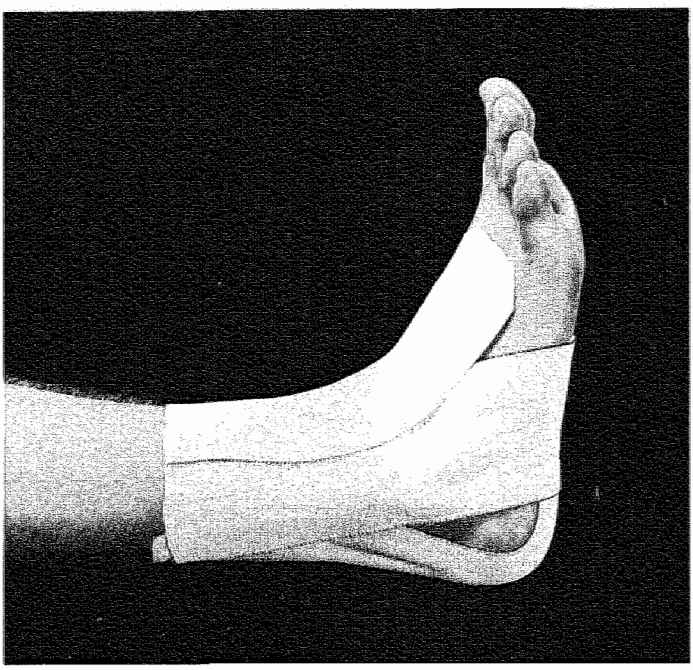

Figure 7

7.5 cm tape, stretched over the anterior aspect, from the base of the toes to the same proximal height of the first two strips. (The 'Anterior L-Tape').

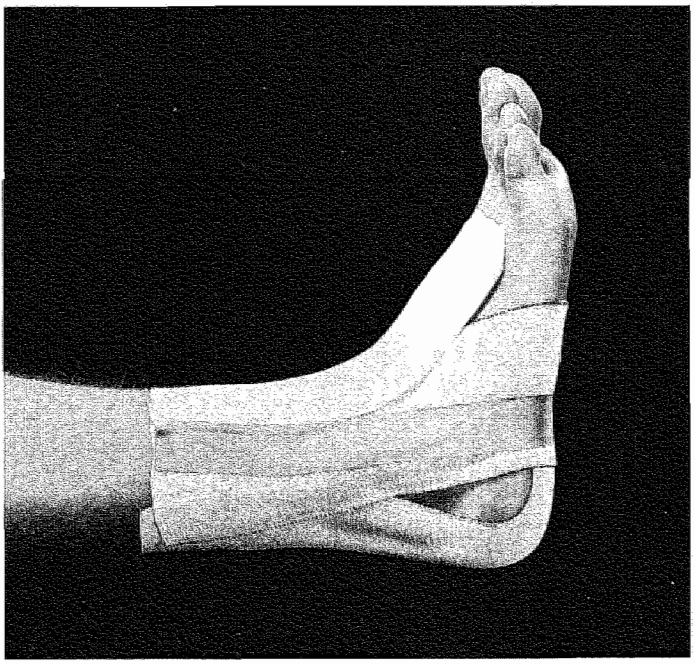

Figure 8

Tape application (2.5 cm tape). First, one tape in U-position, running from medial to lateral, around the sole of the foot, covering both malleoli.

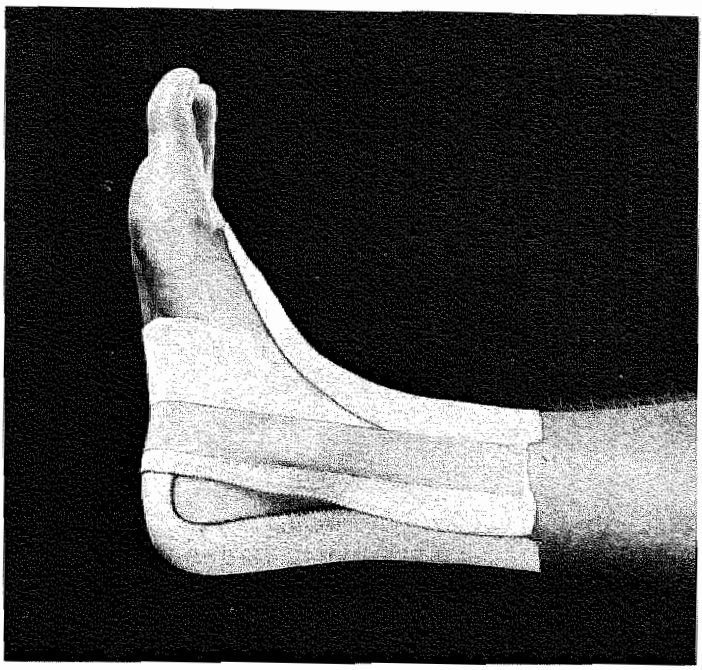

Figure 9

Medial view of fig. 8.

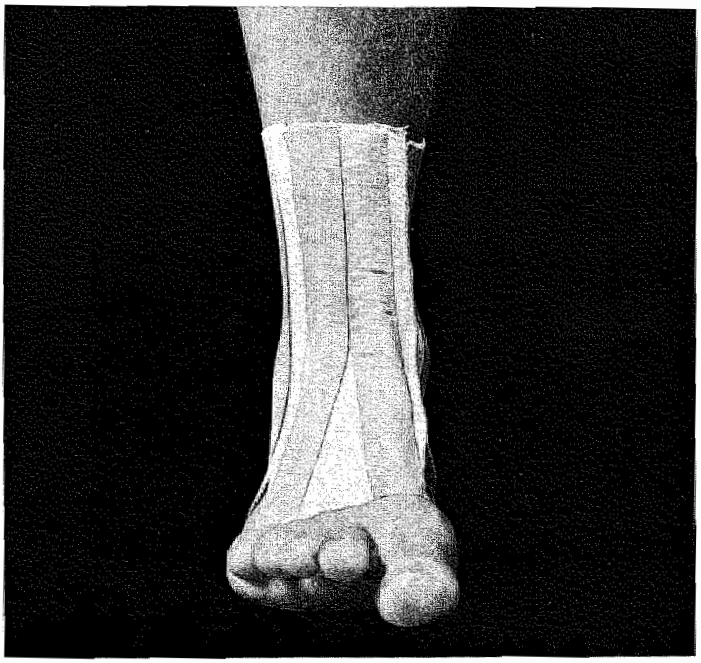

Figure 10

Two anterior strips starting at the level of the 1st and 5th m.c.p. joints respectively.

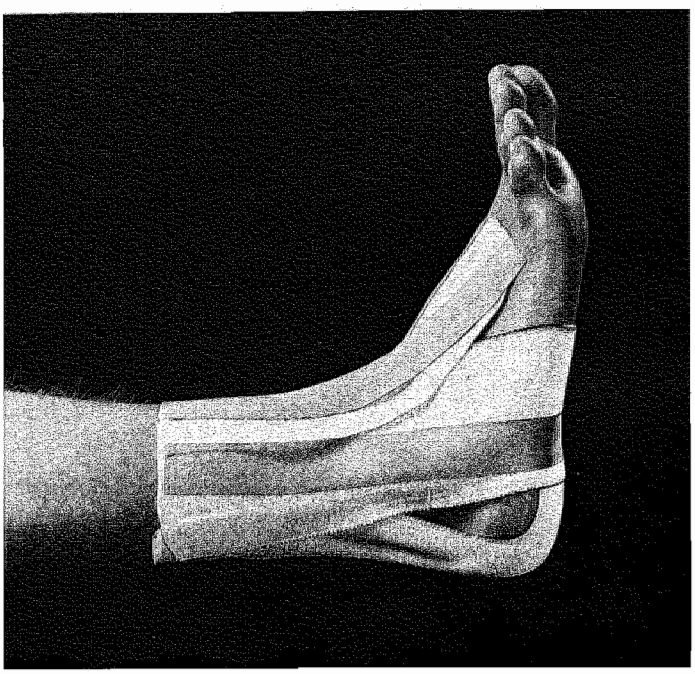

Figure 11

Lateral view of fig. 10.

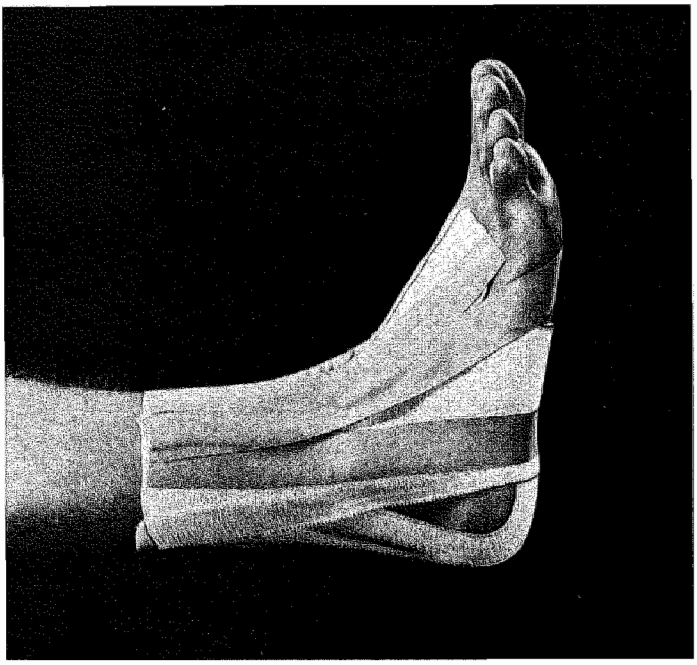

Figure 12

Two strips: the first, running lateral to the strip of fig. 11, reaching the midline of the sole of the foot running just proximal to the 5th m.c.p. joint. The second strip is applied in the same way, medially.

Figure 13

View of the sole of the foot, showing both strips coming together in the midline (see arrow).

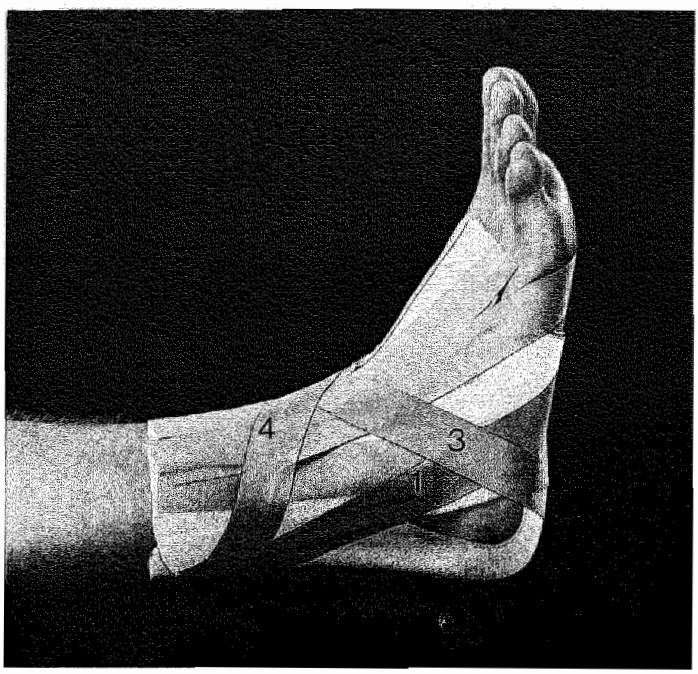

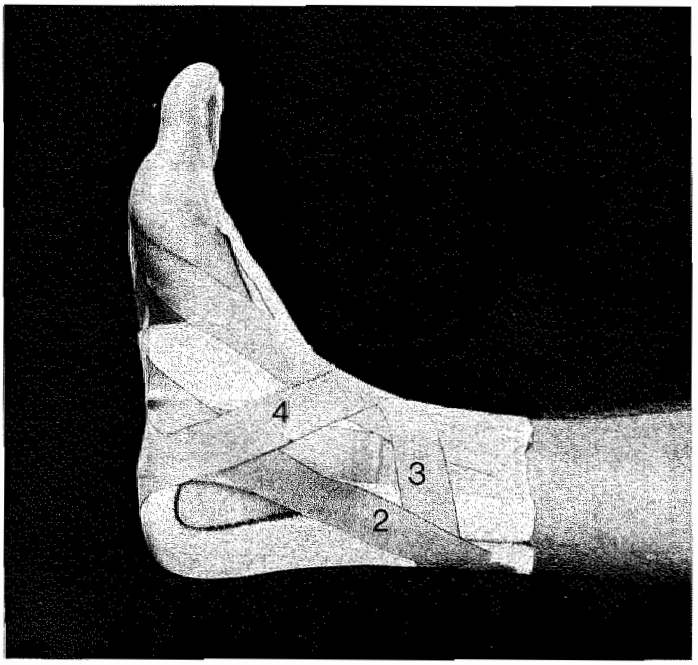

Figures 14-15-16-17

Application of tapes in 'retinacular' V-formation around the malleoli, four tapes (2.5 cm).

1. Tape starting posteriorly, just lateral to the midline of the calf, passing the lateral malleolus dorsally, running to the midpoint of the sole.

2. Tape starting posteriorly, just medial to the midline of the calf, passing the medial malleolus dorsally and running to the midpoint of the sole.

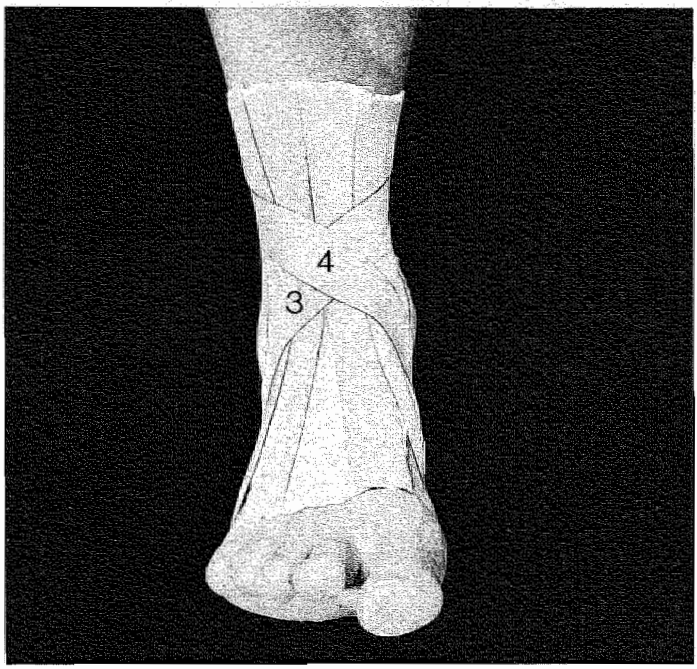

3. Spiral-tape, starting posteriorly just lateral to the midline of the calf, running over medial and anterior aspects diagonally to the lateral side, passing just anterior to the lateral malleolus towards the heel, forming a 'V' on the lateral side together with tape 1.

4. Spiral-tape, starting posteriorly just medial to the midline of the calf, running over lateral and anterior aspects crossing tape 3 in midline, passing just anterior to the medial malleolus towards the heel, forming a 'V' on the medial side together with tape 2.

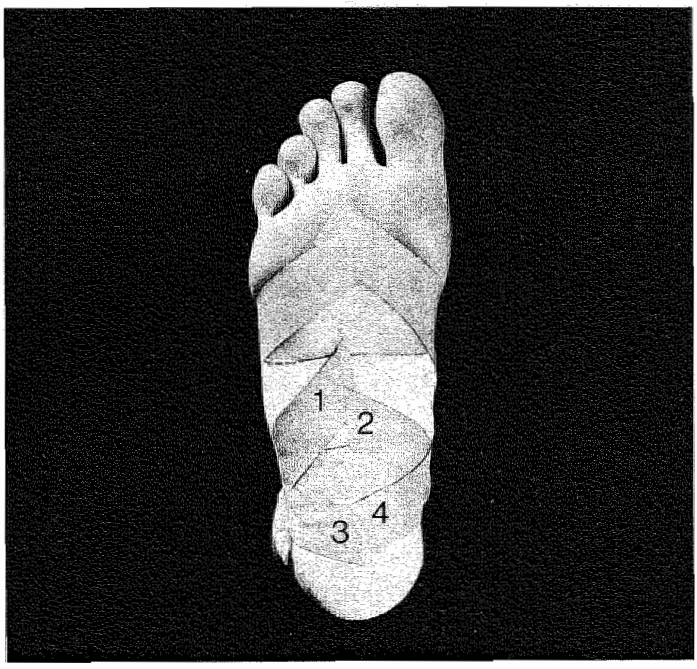

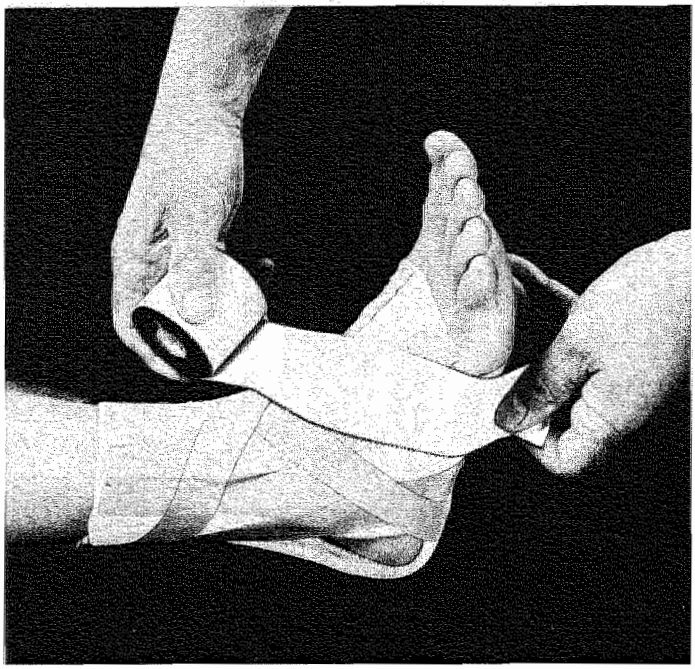

Figure 18

Adhesive bandage (5 cm) for fixation of the tape-formation, starting laterally on the lateral margin of the foot just proximal to the 5th m.c.p. joint, diagonally to the medial malleolus.

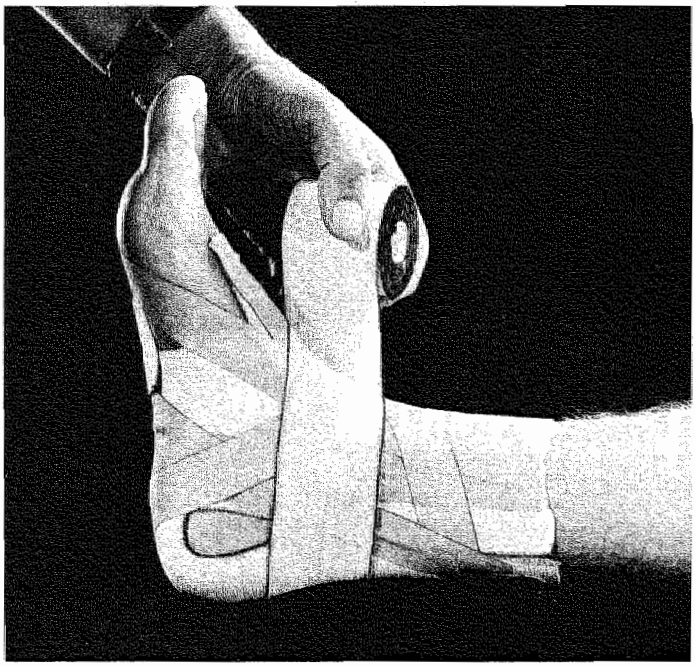

Figure 19

Passing right over the medial malleolus and Achilles tendon to the lateral side.

Figure 20

Passing right over the lateral malleolus and then just proximal to the 1st m.c.p. joint to the distal part of the sole of the foot.

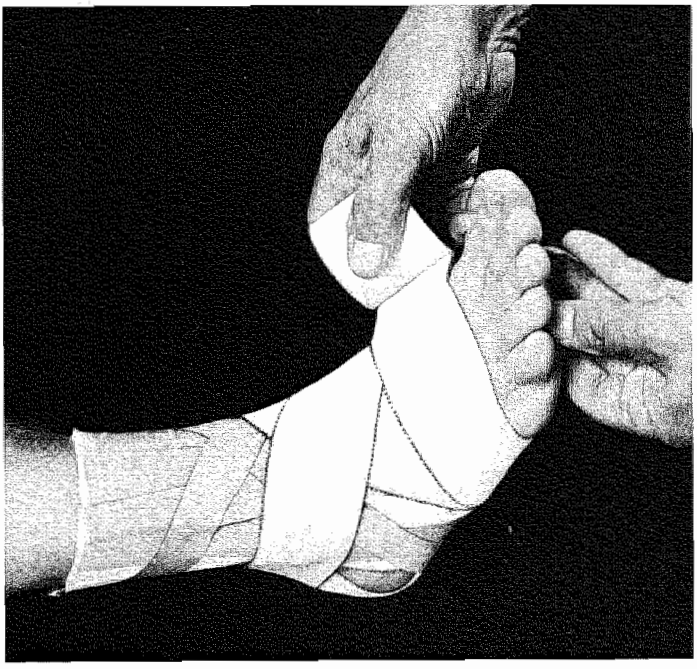

Figure 21

Making one full turn around the forefoot.

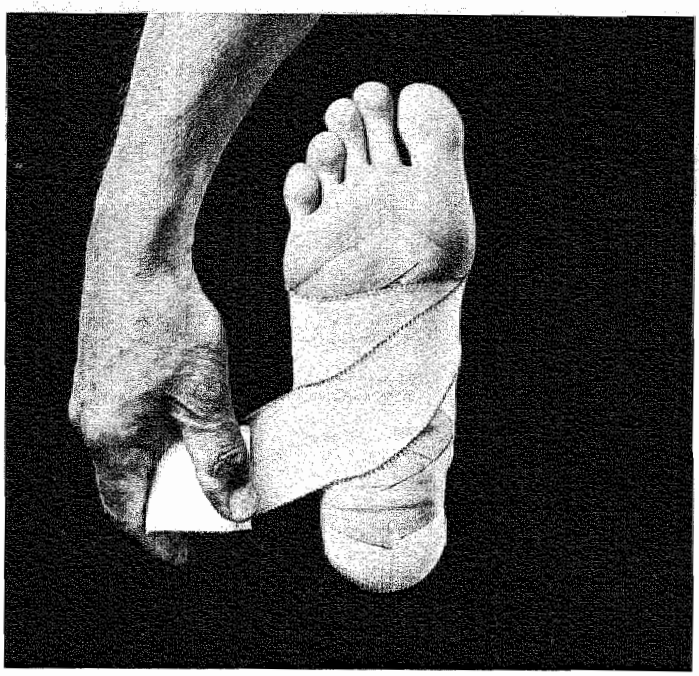

Figure 22

Ending on the lateral border of the foot, dorsal to the start of the full turn.

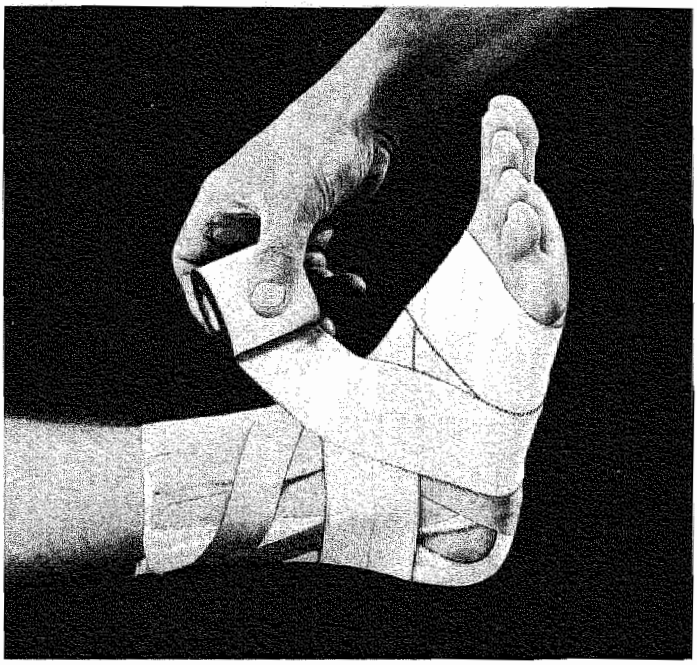

Figure 23

Then diagonally to the medial side.

Figure 24

and completing three circular turns up the distal part of the lower leg.

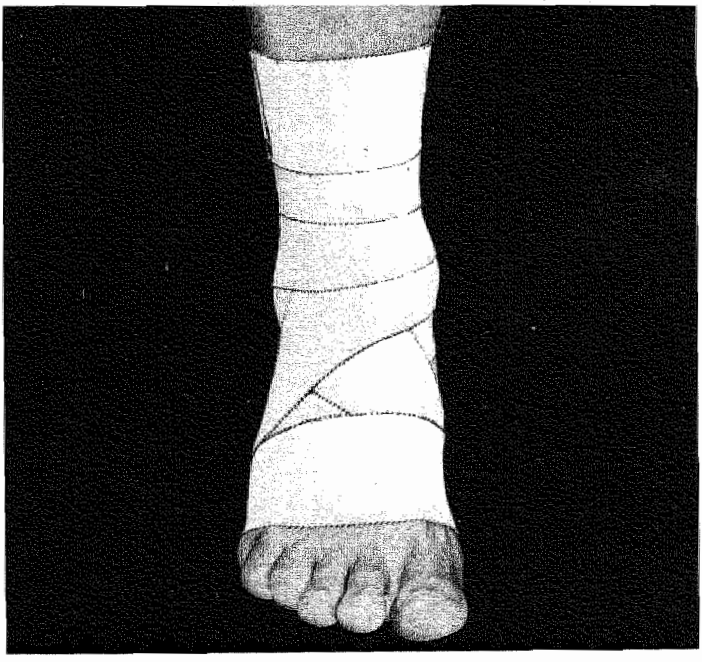

Figuur 25

Front view.

Figure 26

Medial view.

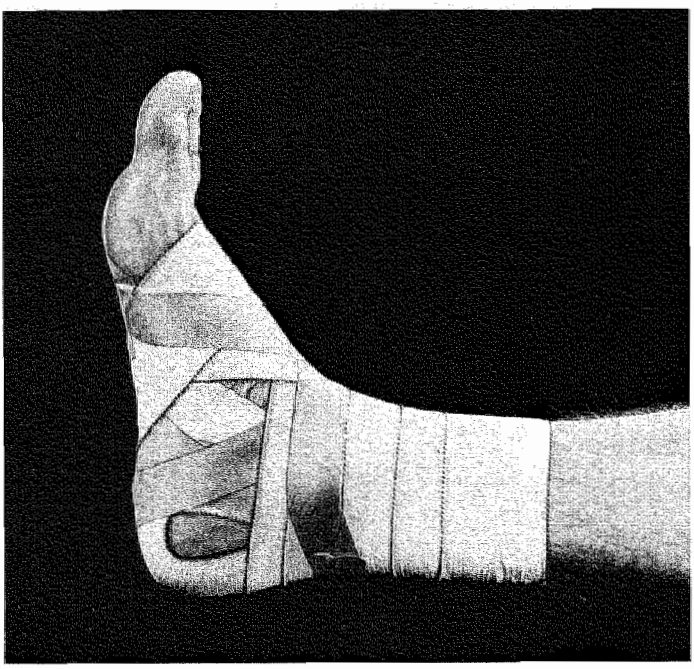

Figuur 27

Completion of the bandage with two supportive ankle tapes (2.5 cm) just below the malleoli.
The first tape starts posteriorly just lateral to the Achilles tendon, running distal to medial malleolus, then diagonally to the lateral margin of the foot and ending in midline of the sole of the foot.
The second tape runs similarly, distal to the lateral malleolus and crossing the first tape anteriorly.

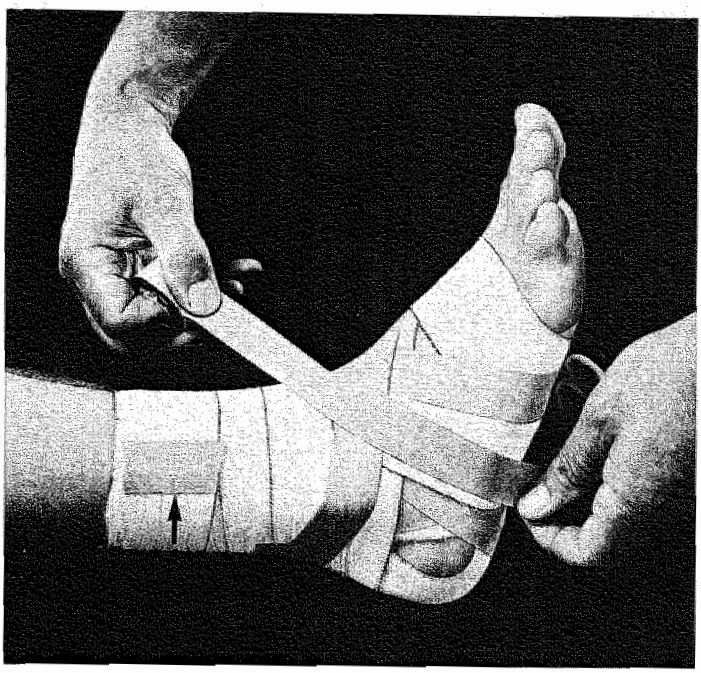

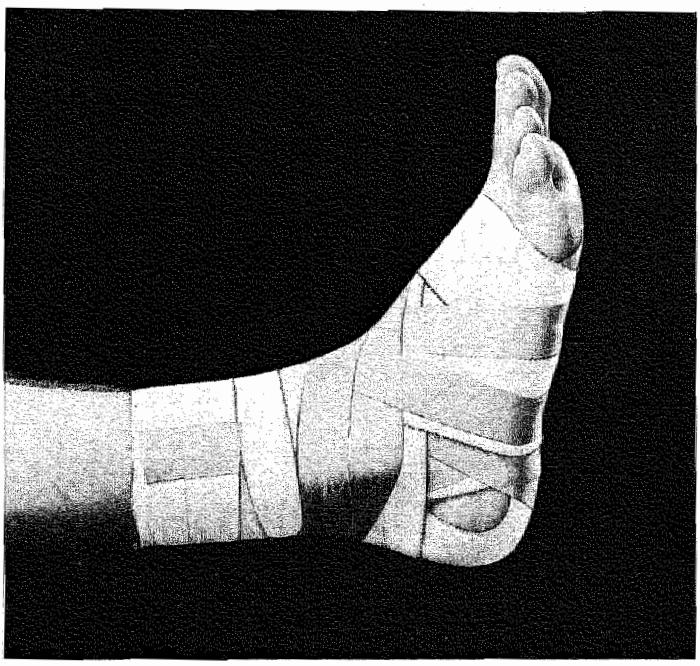

Figures 28/29

The last tape is a continuous tape, starting on the lateral side of the foot at the base of the 5th metatarsal, diagonally crossing anteriorly, then just proximal to the medial malleolus, over the Achilles tendon, passing proximal to the lateral malleolus and then diagonally to the medial margin of the foot, meeting the starting point of this tape in the midline of the sole of the foot. The end of the 5 cm adhesive bandage is fixed with a short tape (see arrow).

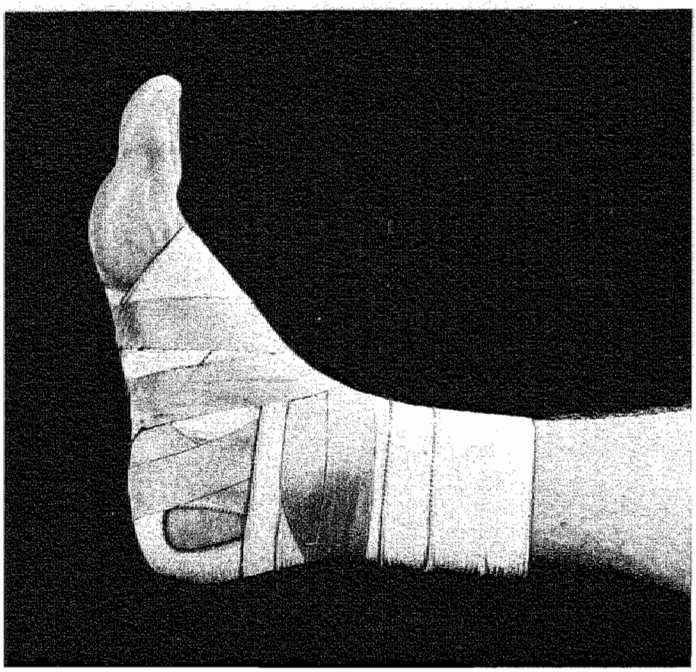

Figure 30

Complete bandage – medial view.

Figure 31

Complete bandage – front view.

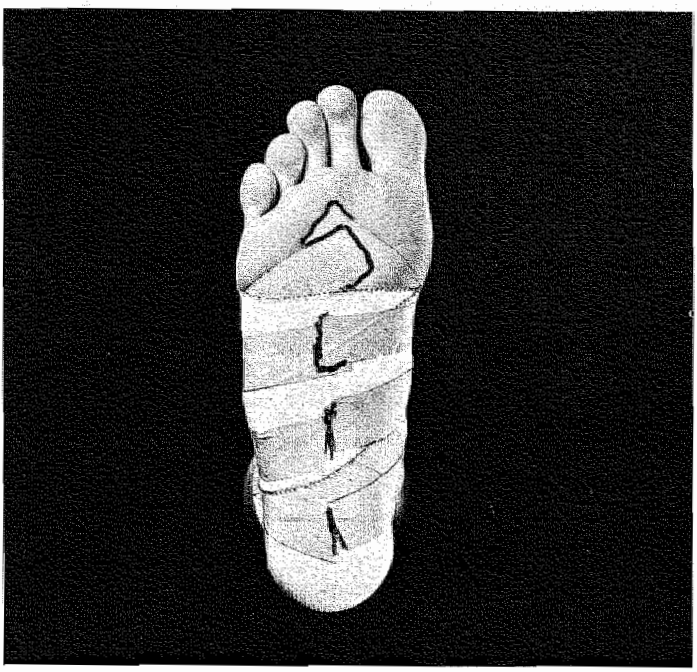

Figure 32

Complete bandage – plantar view.

Short exercise programme after bandage application.



Figure 1

The patient is encouraged to relax, with full weight bearing on **both feet.** Watch the vertical axis of the body, because the patient tends to put more weight on the uninjured leg.



Figure 2

Bend the knee on the injured side, thus putting full weight on the injured ankle.



Figure 3

Symmetrically dorsiflex both ankles by bending both knees. The heels maintain contact with the floor.



Figure 4

Full weight bearing on one foot, starting with the healthy ankle and then endeavouring to repeat on the injured side.

The exercise programme is continued by a walking exercise, to restore a normal gait (Cailliet 1968).
Watch the following points:
1. full weight bearing on the injured ankle, ensuring the body-axis remains vertical.
2. check for equal length of step.
3. to restore a normal gait, the patient must consciously exaggerate weight bearing on the injured ankle.
4. check the interrelationship of the movements of pelvis, knee and ankle during walking (Cailliet 1968).

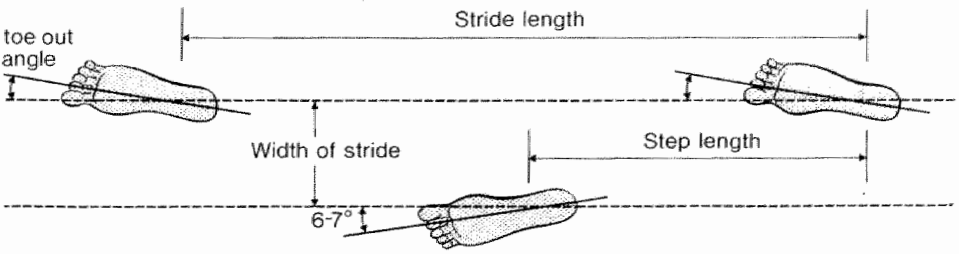

List of permissions

Some of the illustrations and tables and part of the text of this present work are taken from previously published articles, and are published here with permission of the editors.
The articles concerned are as follows:

Van Moppes, F.I.; Van den Hoogenband, C.R.; Greep, J.M. (1979 A):
Adhesive capsulitis of the ankle (frozen ankle).
Arch. Orthop. Trauma. Surg. 94, 313.
Figures 17 and 36.

Van Moppes, F.I.; Van Engelshoven, J.M.A.; Van den Hoogenband, C.R. (1979 B):
Comparison between talar tilt, anterior drawer sign and ankle arthrography in ankle ligament lesions.
J. Belge Radiol. 62, 441.
Figures 13, 14, 15 and 16.

Van Moppes, F.I.; Van den Hoogenband, C.R.; Betts-Brown, A (1980 A):
Filling of lymphatic vessels in ankle arthrography.
Diagn. Imaging 49, 171.
Figure 35.

Van Moppes, F.I.; Van den Hoogenband, C.R. (1980 B):
The significance of the peroneus tendon sheath in ankle arthrography.
Fortschr. Röntgenstr. 132, 573.
Figure 29.

Van Moppes, F.I.; Meyer, F.; Van den Hoogenband, C.R. (1980 C):
Arthrographic differential diagnosis between ruptures of the anterior talofibular ligament, the joint capsule, and the anterior tibiofibular ligament.
Fortschr. Röntgenstr. 133, 534.
Figures 24 a,d; 25, 26, 27 and 28; table 3.

Van Moppes, F.I.; Van den Hoogenband, C.R.; Van Engelshoven, J.M.A.; Betts-Brown, A. (1981):
Arthrography, talar tilt and surgical findings after inversion trauma of the ankle.
Fortschr. Röntgenstr. 134.
Figure 32 A; tables 7, 8, 9, 10, 12 and 15.

References

ADLER, H. (1976 A):
Die anteriore Instabilität des oberen Sprunggelenkes bei Aussenknöchelbandläsionen.
Z. Orthop. 114, 987

ADLER, H. (1976 B):
Therapie und Prognose der frischen Aussenknöchelbandläsion.
Hefte Unfallheilkd. 79, 101

ALA-KETOLA, L.; PURANEN, J. (1977):
Arthrography in the diagnosis of ligament injuries and classification of ankle injuries.
Radiology 125, 63

AKHTAR, M; LEVINE, J. (1980):
Dislocation of extensor digitorum longus tendons after spontaneous rupture of the inferior retinaculum of the ankle.
J. Bone Joint Surg. 62A, 1210

ANDERSON, K.J.; LECOCQ, J.F. (1952):
Recurrent anterior subluxation of the ankle joint.
J. Bone Joint Surg. 34A, 853

ANDRÉN, L.; LUNDBERG, G.J. (1965):
Treatment of rigid shoulders by joint distension during arthrography.
Acta Orthop. Scand. 36, 45

ANSON, B.J. (1953):
Morris human anatomy.
Editor: McGraw-Hill Book Co., New York, 12th edition.

ANSON, B.J.; McVay, C.B. (1971):
Surgical anatomy.
Editor: W.B. Saunders Co., Philadelphia.

BLACK, H.M.; BRAND, R.L.; EICHELBERGER, M.R. (1978):
An improved technique for the evaluation of ligamentous injury in severe ankle sprains.
Am. J. Sports Med. 6, 276

BONNIN, J.G. (1944):
The hypermobile ankle.
Proc. R. Soc. Med. 37, 282

BOOMSMA, J.H.B. (1979):
A new method for X-ray examination of the anterior-posterior stress of the ankle.
Diagn. Imaging 48, 90

BROSTRÖM, L. (1964):
Sprained ankles. 1. Anatomic lesions in recent sprains.
Acta Chir. Scand. 128, 483

BROSTRÖM, L.; LILJEDAHL, S.O. (1965 A):
Sprained ankles. 2. Arthrographic diagnosis of recent ligament ruptures.
Acta Chir. Scand. 129, 485

BROSTRÖM, L. (1965 B):
Sprained ankles 3. Clinical observations in recent ligament ruptures.
Acta Chir. Scand. 130, 560

BROSTRÖM, L.; SUNDELIN, P. (1966 A):
Sprained ankles. 4. Histologic changes in recent and chronic ligament ruptures.
Acta Chir. Scand. 132, 248

BROSTRÖM, L. (1966 B):
Sprained ankles. 5. Treatment and prognosis in recent ligament ruptures.
Acta Chir. Scand. 132, 537

BROSTRÖM, L. (1966 C):
Sprained ankles. 6. Surgical treatment of 'chronic' ligament ruptures.
Acta Chir. Scand. 132, 551

BURRI, C; RÜTER, A. (1978):
Verletzungen des oberen Sprunggelenkes.
9. Reisenburger Workshop zur klinischen Unfallchirurgie.
Hefte Unfallheilkd. 131.

CAILLIET, R. (1968):
Foot and ankle pain.
Editor: F.A. Davis Co., Philadelphia, Ch. 3, 45

CAMPBELL, W.C. (1971):
Operative orthopaedics edited by Crenshow, A.H.
Editor: E.V, Mosby Co., Saint Louis, 5th edition.

CASTAING, J.; DELPLACE, J. (1972):
Entorses de la cheville. Intérêt de l'étude de la stabilité dans le plan sagittal pour le diagnosis de gravité.
Rev. Chir. Orthop. 58, 51

McCAULEY, R.G.K.; WUNDERLICH, B.K.; ZIMBLER, S. (1981):
Air embolism as a complication of hip arthrography.
Skeletal Radiol. 6, 11

CEDELL, C.A. (1975):
Ankle lesions.
Acta Orthop. Scand. 46, 425

CHIRLS, M. (1973):
Inversion injuries of the ankle.
J. Med. Soc. NJ. 70, 751

CLAES, L.; BURRI, C.; MUTSCHLER, W.; PLANK, E. (1979):
Experimentelle Untersuchungen zur Biomechanik der Seitenbänder am Kniegelenk.
Langenbecks Arch. Chir. Suppl. Chir. Forum '79 für experimentelle und klinische Forschung.

CLAES, L.; BURRI, C.; MUTSCHLER, W. (1980):
Biomechanical and histologic evaluation of refixation of ruptured collateral ligaments.
Langenbecks Arch. Chir. Suppl. Chir. Forum '80 für experimentelle und klinische Forschung.

CLAESSEN, H. (1969):
De pijnlijke schouder. De Nederlandse Bibliotheek der Geneeskunde.
Editor: Stafleu, vol. 46.

CLARK, B.J.; DERBY, A.E. (1965):
Injuries of the lateral ligament of the ankle, conservative versus operative repair.
Can. J. Surg. 8, 358

CLAYTON, J; MILES, J.S. (1965):
Experimental investigations of ligament healing.
Clin. Orthop. 61, 146

COLTON, T.C.L. (1976):
Injuries of the ankle.
In: Watson Jones – Fractures and joint injuries.
Editor: J.N. Wilson, Churchill, Livingstone, London, vol. 2. 5th edition.

DAFFNER, R.H.; WHITFIELD, P.W. (1977):
Recurrent ganglion cyst. The value of preoperative ganglionography.
Am. J. Roentgenol. 129, 345

DALINKA, M.R. (1980):
Arthrography.
Editor: Springer Verlag, Berlin, Heidelberg, New York.

DELPLACE, J.; CASTAING, J. (1975 A):
Apports de l'étude radiographique du tiroir astragalien anterieur.
Rev. Chir. Orthop. suppl. 2, 61: 137

DELPLACE, J.; FLOCOUD-CASTAING, J. (1975 B):
Resultats à propos de 83 cas observés la service des urgences de C.H.R. de Tours.
Rev. Chir. Orthop. suppl. 2, 61: 146

DESMET, A.S.; TING, Y.M.; WEISS, J.J. (1975):
Shoulder arthrography in R.A.
Radiology 116, 601

DIXON, A.S.J.; GRANT, C. (1964):
Acute synovial rupture in rheumatoid arthritis.
Lancet 1, 742

DRUKKER, J.; JANSEN, J.C. (1975):
Compendium anatomie.
De Tijdstroom, Lochum.

DUQUENNOY, J.A.; DECOULX, J. (1972):
Les lésions ligamentaires du cou de pied.
Acta Orthop. Belg. 38, 672

EL SAMAN, M.; HUTSCHENREUTER, P.; CLAES, L. (1978):
Zugfestigkeiten und histologische Heilverläufe partiell durchtrennter Knieseitenbänder nach oder ohne Gipsruhigstellung.
Chir. Forum. suppl. Langenbecks Arch. Chir.

ENNEVAARA, K. (1967):
The painful shoulder joint in R.A.
Acta Rheum. Scand. suppl. 2.

EVANS, G.S.; FRENYO, S.D. (1979):
The stress-tenogram in the diagnosis of ruptures of the lateral ligament of the ankle.
J. Bone Joint Surg. vol. 61B, 347

FLEISCHER, H. (1971):
Diagnostik und Therapie der Kapselschäden des oberen Sprunggelenkes.
Zentrallbl. Chir. vol. 29, 979

FORDYCE, A.J.W.; HORN, C.V. (1972):
Arthrography in recent injuries of the ligaments of the ankle.
J. Bone Joint Surg. vol. 54B. 116

FREEMAN, M.A.R. (1965 A):
Treatment of ruptures of the lateral ligament of the ankle.
J. Bone Joint Surg. vol. 47B, 661

FREEMAN, M.A.R. (1965 B):
Instability of the foot after injuries to the lateral ligament of the ankle.
J. Bone Joint Surg. vol. 47B, 669

FREEMAN, M.A.R.; DEAN, M.R.E.; MANHAM, I.W.F. (1965 C):
The etiology and prevention of functional instability of the foot.
J. Bone Joint Surg. vol. 47B, 678

FREEMAN, M.A.R.; WYKE, B. (1967 A):
The innervation of the ankle joint. An anatomical and histological study in the cat.
Acta Anat. vol. 68, 321

FREEMAN, M.A.R.; WYKE, B. (1967 B):
Articular reflexes at the ankle joint. An electromyographic study of normal and abnormal influences of ankle joint mechanoreceptors upon reflex activity in the leg muscles.
Br. J. Surg. vol. 54, 990

FREIBERGER, R.H.; KILLORAN, P.J. (1966):
Arthrography of the knee by double contrast method.
Am. J. Roentgenol. 97, 736

FREIBERGER, R.H.; KAYE, J.J. (1979):
Arthrography.
Editor: Appleton century crafts, New York.

FRÖHLICH, J.; GOTZEN, L.; ADAM, U. (1980):
Evaluation of stress roentgenograms of the upper ankle joint.
Hefte Unfallheilkd. 83, 457

FROST, H.M. (1974):
Does the ligament injury require surgery?
Clin. Orthop. 103, 49

FUSSELL, M.E.; GODLEY, D.R. (1973):
Ankle arthrography in acute sprains.
Clin. Orthop. 93, 278

GARDNER, G.; RAHILLY, O. (1966):
Anatomy.
Editor: Saunders, London, sec. edition.

GEESINK, R.G.T. (1977):
Ander zicht op enkelbandlaesies.
Ned. Tijdschr. Geneeskd. 121, 1446

GERBERT, J. (1975):
Ligamentous injuries of the ankle joint.
J. Am. Podiatry Assoc. 65, 803.

GERLACH, F.; BITTSCHEIDT, H.; FRANKEN T. (1978):
Die Röntgendiagnostik der Verletzungen des oberen Sprunggelenkes.
Roentgenbl. 31, 503.

GILULA, L.A.; SCHOENECKER, P.L.; MURPHY, W.A. (1978):
Shoulder arthrography as a treatment modality.
Am. J. Roentgenol. 131, 1047

GLASTRUP, H. (1965):
Arthrography in acute ankle lesions.
Acta Orthop. Scand. 36, 337

GOERGEN, T.G.; RESNICK, D. (1980):
Arthrography of the ankle and hindfoot.
In: Arthrography, Dalinka, M.
Editor: Springer Verlag, Berlin, Heidelberg, New York.

GOLDMAN, A.B.; KATZ, M.C.; FREIBERGER, R.H. (1976):
Posttraumatic adhesive capsulitis of the ankle: arthrographic diagnosis.
Am. J. Roentgenol. 127, 585

GORDON, R.B. (1970):
Arthrography of the ankle joint.
J. Bone Joint Surg. 52A, 1623

GORDON, L.; DUNN, E.; MALIN, T.H. (1976):
Lateral collateral ligament ankle injuries in young athletic individuals.
J. Trauma 16, 225

GRAY, H. (1981):
Gray's Anatomy.
Editor: D.V. Davies, Longmans, Green L. Co. ltd., London , 36th edition.

GRIFFITH, H.J. (1979):
Interventional radiology. The muscoloskeletal system.
Radiol. Clin. North Am. vol. 17, 475

GRÖNMARK, T.; JOHNSON, O.; KOGSTAD, O. (1980):
Rupture of the lateral ligament of the ankle. A controlled clinical trial.
Injury 2, 215

GÜTTNER, L. (1941):
Erkennung und Behandlung der Bänderrisse am äusseren Knöchel mit Teilverrenkung des Sprungbeines im Sinne der Supination (subluxatio supinatoria pedis).
Arch. Orthop. Unfallchir. 41, 287

HAAGE, H. (1967):
Die Arthrographie des Sprunggelenkes.
Radiologe 5, 137

HAAGE, H. (1970):
Lymphgefässfüllung bei der Arthrographie mit positivem Kontrastmittel.
Fortschr. Röntgenstr. 112, 485

HALL, F.M.; ROSENTHAL, D.I.; GOLDBERG, T.P.; WYSHAK, G. (1981):
Morbidity from shoulder arthrography: etiology, incidence and prevention.
Am. J. Roentgenol. 136, 59

HANSEN, H.; DAMHOLT, V.; TERMANSEN, N.B. (1979):
Clinical and social status following injury to the lateral ligaments of the ankle.
Acta Orthop. Scand. 50, 699

HANSSEN, C.J. (1941):
Arthrographic studies of the ankle joint.
Acta Radiol. (Diagn.) 22, 281

HARRISON, M.; FREIBERGER, R.H.; RANAWAT, C.S. (1971):
Arthrography of the rheumatoid wrist joint.
Am. J. Roentgen. 112, 480

HENDRIKS, E.R.H.A. (1981):
Chronische enkelklachten.
Geneeskunde en sport, 14, 44

HERDER den, J.W. (1961):
De arthrografie van het enkelgewricht.
Thesis, Amsterdam.

HERMANS, G.P.H. (1977):
Sporttraumatologie.
Reuma Wereldwijd 1, 3,5

HJELMSTEDT, A.; SAHLSTEDT, B. (1977):
Simultaneous arthrography of the talocrural and talonavicular joints in children. 3
Measurements on normal feet.
Acta Radiol. (Diagn.) 513

HJELMSTEDT, A.; SAHLSTEDT, B. (1978):
Simultaneous arthrography of the talocrural and talonavicular joints in children. 4
Measurements on congenital club feet.
Acta Radiol. (Diagn.) 19, 221

HUG, G.; DIXON, A.S.J. (1977):
Ankle joint synoviography in rheumatoid arthritis.
Ann. Rheum. Dis. 36, 352

HUISKES, R. (1979):
Biomechanische aspecten van het enkelgewricht.
Geneeskunde en sport vol. 12, 15

HUPFAUER, W. (1970):
Beitrag zur Diagnostik der frischen fibularen Bandruptur.
Monatsschr. Unfallheilkd. 73, 178

HUTSCHENREUTER, P.; BURRI, C. (1974):
Biomechanische Untersuchungen an den Bändern des Kniegelenkes.
Helv. Chir. Acta 41, 51

JÄGER, M.; WIRTH, C.J. (1978):
Kapselbandlaesionen – Biomechanik, Diagnostik und Therapie.
Editor: G. Thieme Verlag, Stuttgart.

JAYSON, M.I.V.; DIXON, A.S.J. (1970):
Intra-articular pressure in rheumatoid arthritis of the knee.
Ann. Rheum. Dis. 29, 261.

JOHANNSEN, A. (1978):
Radiologic diagnosis of lateral ligament lesion of the ankle.
Acta Orthop. Scand. 49, 295

KARPANDJI, I.A. (1974):
The fysiology of the joints, vol. 2.
Editor: Churchill Livingstone, Edinburgh, London, New York, sec. edition.

KAYE, J.J.; BOHNE, W.H.O. (1977):
A radiographic study of the ligamentous anatomy of the ankle.
Radiology 125, 659

KAYE, J.J. (1979):
In: Arthrography, Freiberger, R.H.; Kaye, J.J.
Editor: Appleton century crafts, New York.

KLEIGER, B. (1956):
The mechanism of ankle injuries.
J. Bone Joint Surg. vol. 38A, 59

KLEIGER, B. (1974):
Mechanisms of ankle injury.
Orthop. Clin. North Am. vol. 5, 127

KOOYMAN, M.A.P.; PONSEN, R.J.G. (1976):
Surgical treatment of acute injuries of the lateral ligament of the ankle joint and chronical lateral ligament insufficiency.
Acta Orthop. Belg. 42, 445

LANDEROS, O.; FROST, H.M.; HIGGINS, C.C. (1978):
Posttraumatic anterior ankle instability.
Clin. Orthop. 56, 525

LANGER, R.; LANGER, M.; GLÖCKLER, W.Th.; SCHUMACHER, K.A.; DEWITZ v., H. (1980):
Radiologische Diagnostik der fibulo-talaren Bandläsionen an Hand von handgehaltenen und apparategedrückten Aufnahmen.
Roentgenbl. 33, 399

LANZ von, T.; WACHSMUTH, W. (1972):
Praktische Anatomie. Bein und Statik, zweite neubearbeitete Ausgabe von J. Lang und W. Wachsmuth.
Editor: Springer Verlag, Berlin, Heidelberg, New York.

LARSEN, E. (1976):
Den Instabile Ankel.
Ugeskr. Laeger 138, 1989

LAUGE-HANSEN, N. (1976):
Entstehung und Erkennung der Verletzungen des oberen Sprunggelenkes.
Hefte Unfallheilkd. 92, 3

LAURIN, C.; ONELLET, R.; ST. JACQUES, R. (1968):
Talar and subtalar tilt: an experimental investigation.
Can. J. Surg. 11, 270

LAURIN, C.; MATHIEU, J. (1971):
Das instabile obere Sprunggelenk.
Helv. Chir. Acta 3, 326

LAURIN, C.; ST. JACQUES, R. (1975):
L'investigation radiologique des entorses récentes et recidivantes de la cheville.
Union Méd. Can. 94, 737

LAURIN, C.; MATHIEU, J. (1965):
Sagittal mobility of the normal ankle.
Clin. Orthop. 108, 99

LEEDEN van der, H. (1974):
De kniekuilcyste en het pseudothrombosebeen.
Ned. Tijdschr. Geneeskd. 118, 427

LEMBERGER, U.; KRAMER, J. (1971):
Das instabile obere Sprunggelenk.
Helv. Chir. Acta 3, 326

LEWIN, J.R.; MULHERN, L.M. (1972):
Lymphatic visualization during contrast arthrography of the knee.
Radiology 103, 577

LINDHOLMER, E.; FOGED, N.; JENSEN, J.Th. (1978):
Arthrography of the ankle, value in diagnosis of rupture of the lateral ankle ligements.
Acta Radiol. (Diagn.) 19, 585

LINDSTRANDT, A.; MORTENSSON, W. (1977):
Anterior instability in the ankle joint following acute lateral sprain.
Acta Radiol. (Diagn.) 18, 529

LOHMAN, A. (1972):
Vorm en Beweging.
Editor: Oosthoek, Utrecht.

LUNDBERG, B.J. (1969):
The frozen shoulder. Clinical and radiographic observations.
Acta Orthop. Scand. (suppl.) 119

LÜNING, M.; ROMANIK, R.A. (1968):
Spontane Lymphgefässdarstellung nach Arthrographie des oberen Sprunggelenkes.
Fortschr. Röntgenstr. 108, 400

LÜNING, M.; KRUPP, I.; BIEDERMANN, F. (1969):
Erfahrungen mit der Sprunggelenksarthrographie zum Nachweis älterer Bandläsionen.
Beitr. Orthop. Traumatol. 16, 29

MAKHANI, J.S. (1962):
Lacerations of the lateral ligaments of the ankle.
J. Int. Coll. Surg. 385, 454

MAMEREN van, H.; DRUKKER, J. (1981):
An alternative description of anatomical relations of muscle tissue and connective tissue in the lateral part of the cubital region.
Their intimate relation and possible clinical implication.
(Submitted for publication).

MEHREZ, M.; EL GENEIDY, S (1970):
Arthrography of the ankle.
J. Bone Joint Surg. 52B, 368

MINK, J.H.; DICKERSON, R. (1980):
Air or CO_2 for knee arthrography?
Am. J. Roentgenol. 134, 991

MOPPES van, F.I.; HOOGENBAND van den, C.R.; GREEP, J.M. (1979 A):
Adhesive capsulitis of the ankle (frozen ankle).
Arch. Orthop. Trauma. Surg. 94, 313

MOPPES van, F.I.; ENGELSHOVEN van, J.M.A.; HOOGENBAND van den, C.R. (1979 B):
Comparison between talar tilt, anterior drawer sign and ankle arthrography in ankle ligament lesions.
J. Belge Radiol. 62, 441

MOPPES van, F.I.; HOOGENBAND van den, C.R.; BETTS-BROWN, A. (1980 A):
Filling of lymphatic vessels in ankle arthrography.
Diagn. Imaging 49, 171

MOPPES van, F.I.; HOOGENBAND van den, C.R. (1980 B):
The significance of the peroneus tendon sheath in ankle arthrography.
Fortschr. Röntgenstr. 132, 573

MOPPES van, F.I.; MEYER, F.; HOOGENBAND van den, C.R. (1980 C):
Arthrographic differential diagnosis between ruptures of the anterior talo-fibular ligament, the joint capsule and the anterior tibio-fibular ligament.
Fortschr. Röntgenstr. 133, 534

MOPPES van, F.I.; HOOGENBAND van den, C.R.; ENGELSHOVEN van, J.M.A.; BETTS-BROWN, A. (1981):
Arthrography, talar tilt and surgical findings after inversion trauma of the ankle.
Fortschr. Röntgenstr. 134.

MÜLLER, M.E.; ALLGÖWER, M.; SCHNEIDER, R.; WILLENEGGER, H. (1977):
Manual der Osteosynthese. Zweite neubearbeitete und erweiterte Auflage,
Editor: Springer Verlag, Berlin, Heidelberg, New York.

MUSCHTER, K.; GÖTZ, K. (1974):
Röntgenologische Ergebnisse konservativ behandelter Sprunggelenkstraumen mit Syndesmosebeteiligung.
Monatschr. Unfallheilkd. 77, 66

NEVIAZER, J.S. (1949):
Adhesive capsulitis of the shoulder. Instruction course lectures.
Am. Ac. Orthop. Surg. vol. 6, 281.

NEVIAZER, J.S. (1962):
Arthrography of the shoulder joint: study of findings in adhesive capsulitis of the shoulder.
J. Bone Joint Surg. 44A, 1321

NIETHARD, E. (1974):
Die Stabilität des Sprunggelenkes nach Ruptur des lateralen Bandapparates.
Arch. Orthop. Unfallchir. 80, 53

NOESBERGER, B. (1976):
Ein Halteapparat zum differenzierten Nachweis der fibularen Bandläsion.
Helv. Chir. Acta 43, 195

NOYES, F. (1977):
Functional properties of knee ligaments and alterations, induced by immobilization.
Clin. Orthop. 123, 210

OLSON, R.W. (1969):
Arthrography of the ankle: its use in the evaluation of ankle sprains.
Radiology 92, 1439

OLSON, R.W. (1981):
Ankle arthrography.
Radiol. Clin. North Am. vol. 19, 255

PASCOËT, G.; FOUCHER, G.; FOUCHER, O.; DARTEVELLE, D.; JAEGER, J.H. (1973):
Bilan lésionnel et place de la chirurgie dans les traumatises ligamentaires externes du cou-de-pied.
Chirurgie 98, 311

PASCOËT, G. (1975):
L'arthrographie tibio-tarsienne dans la traumatologie capsulo-ligamentaire du cou-de-pied.
Rev. Chir. Orthop. 61, 142

PAUL, U.; LÜNING, M. (1978):
Zur Diagnostik von Verletzungen des fibularen Bandapparates am oberen Sprunggelenk.
Beitr. Orthop. Traumatol. 25, 305

PAVLOV, H.; GOLDMAN, A.B. (1980):
The popliteus bursa: an indicator of subtle pathology.
Am. J. Roentgenol. 134, 313

PERCEY, E.H.; HILL, R. O.; CALLAGHAN, J.E. (1969):
The sprained ankle.
J. Trauma 9, 972

PLAUE, R.; HINZ, P. (1970):
Zur Röntgendiagnostik ligamentärer Sprunggelenksverletzungen.
Fortschr. Röntgenstr. 112, 769

PRINS, J.G. (1978):
Diagnosis and treatment of injury to the lateral ligaments of the ankle.
Acta Chir. Scand. (suppl.) 486

RAAYMAKERS, E.L.F.B. BERGENHENEGOUWEN v., D.P.; OS v., J.H.; MARTI, R.K. (1979):
Operatieve behandeling van de laterale enkelbandruptuur.
Geneeskunde en sport 12, 25

REDLER, J.; BROWN, G.; WILLIAMS, J.F. (1977):
Operative treatment of the acutely ruptured lateral ligament of the ankle.
South. Med. J. vol. 70

REEVES, B. (1966):
Arthrography of the shoulder.
J. Bone Joint Surg. 436, 424

REICHEN, A.; MARTI, R. (1975):
Die frische fibulare Bandruptur – Diagnose, Therapie, Resultate.
Helv. Chir. Acta 42, 23

REINHARDT, K. (1973):
Lymphgefässdarstellung bei Obersprunggelenksarthrographie.
Radiologe 13, 451

RESNICK, D. (1974 A):
Radiology of the talocalcaneal articulations.
Radiology 111, 581

RESNICK, D. (1974 B):
Arthrography in the evaluation of arthritic disorders of the wrist.
Radiology 113, 331

RESNICK, D. (1981):
Shoulder arthrography.
Radiol. Clin. North Am. vol. 19, 243

RICKLIN, P.; RÜTTIMAN, A.; DEL BUONO, M.S. (1980):
Die Meniscusläsion. 2e überarbeitete Ausgabe.
Editor: G. Thieme Verlag, Stuttgart, New York.

RUBIN, G.; WITTEN, M. (1960):
The talar tilt angle and the fibular collateral ligaments.
J. Bone Joint Surg. 42A, 311

RUSSE, O. (1967):
Subluxatio tali supinatoria.
Z. Unfallheilkd. 92, 104

RUTH, C.J. (1961):
The surgical treatment of injuries of the fibular collateral ligaments of the ankle.
J. Bone Joint Surg. 43A, 229

SAHLSTEDT, B. (1976):
Simultaneous arthrography of the talocrural and talonavicular joint in children. 1. Technique.
Acta Radiol. (Diagn.) 17, 545

SANDERS, H.W.A. (1972):
Diagnostiek van enkelbandletsels, betekenis van arthrografisch onderzoek.
Ned. Tijdschr. Geneeskd. 116, 1721

SANDERS, H.W.A. (1976):
Betekenis van röntgenologische onderzoekmethoden voor de diagnostiek van (laterale) enkelbandletsels.
Ned. Tijdschr. Geneeskd. 120, 2035

SANDERS, H.W.A. (1977):
Ankle arthrography and ankle distorsion.
Radiol. Clin. 46, 1.

SAVA, P. (1976):
Les interventions réparatrices dans les lésions capsulo-ligamentaires externes graves récentes de l'articulation tibio-tarsienne.
Thesis, Besançon.

SCHMIDT, H. (1978):
Erfahrungen mit einem Haltegerät zur Diagnostik von Bandverletzungen des oberen Sprunggelenkes.
Beitr. Orthop. Traumatol. 25, 41

SCHWEIGEL, J.F.; KNICKERBOCKER, W.J.; COOPERBERG, P. (1977):
A study of ankle instability utilizing ankle arthrography.
J. Trauma. vol. 17, 878

SEILER, H.; SCHWEIBERER, L. (1977 A):
Diagnostik und Therapie frischer und veralteter Bandverletzungen im Sprunggelenksbereich.
Chirurg 48, 756

SEILER, H.; HOLZRICHTER, D. (1977 B):
Ergebnisse nach Aussenbandnaht am oberen Sprunggelenk bei frischer Ruptur.
Hefte Unfallheilkd. 80. 151

SMITH, G.R.; WINQUIST, R.A.; ALLEN, T.M.K.; NORTHROP, C.H. (1977):
Subtle transchondral fractures of the talar dome: a radiologic perspective.
Radiology 124, 667

SÓSA, T.; PASINI, J. (1975):
Biomechanically important articular surfaces in the talocrural joint.
Anat. Embryol. 147, 203

SPALTEHOLZ-SPANNER (1959):
Handatlas der Anatomie des Menschen. 16e Ausgabe, erster Teil.
Editor: Scheltema & Holkema, Amsterdam.

SPEECKAERT, M.T.C. (1978):
De behandeling van laterale enkelbandletsels.
Ned. Tijdschr. Geneeskd. 122, 1612

SPIEGEL, P.K.; STAPLES, O.S. (1975):
Arthrography of the ankle joint: problems in diagnosing of acute lateral ligament injuries.
Radiology 114, 587

STAPLES, O.S. (1975 A):
Result study of ruptures of lateral ligaments of the ankle.
Clin. Orthop. Rel. Res. 85, 50

STAPLES, O.S. (1975 B):
Ruptures of the fibular collateral ligaments of the ankle.
J. Bone Joint Surg. 57A, 101

STEPANUK, M. (1977):
Arthrography of the ankle joint in the diagnosis of acute ankle sprains.
J. A.O.A. 76, 529

TAUSCH, W.; MAESS, M. (1978 A):
Ein Beitrag zur Diagnostik und Therapie der veralteten und chronischen fibularen Bandschäden des oberen Sprunggelenkes.
Beitr. Orthop. Traumatol. 25, 29

TAUSCH, W. (1978 B):
Die Diagnostik der Band- und Kapselverletzungen des oberen Sprunggelenkes.
Beitr. Orthop. Traumatol. 25, 25

TAUSCH, W. (1978 C):
Die Bedeutung der Arthrographie zur Diagnostik der frischen Band- und Kapselverletzungen des oberen Sprunggelenkes.
Beitr. Orthop. Traumatol. 25, 309

TAUSCH, W. (1979):
Die Technik, Fehler und Gefahren der Arthrografie des oberen Sprunggelenkes.
Beitr. Orthop. Traumatol. 26, 313

TERMANSEN, H.; HANSEN, H.; DAMHOLT, V. (1979):
Radiological and muscular status following injury to the lateral ligaments of the ankle.
Acta Orthop. Scand. 50, 705

THOMAS, E.; HOFMANN, H; KLEBS, J. (1973):
Konservative Behandlung massiver lateraler Bandschäden des oberen Sprunggelenkes.
Beitr. Orthop. 20, 359

THOMAS, M.L.; MacDONALD, L.M. (1978):
Complications of ascending phlebography of the leg.
Br. Medical J. 2, 317

THIJN, C.J.P. (1979):
Arthrography of the knee joint.
Editor: Springer Verlag, Bern, Heidelberg, New York.

TONINO, A.J. (1973):
Treatment of partial ruptures of the lateral ligament of the ankle in acute ankle sprains.
Arch. Chir. Neerl. 15, 119

TONINO, A.J. (1979):
Behandelingsresultaten van conservatief behandelde bandletsels van het enkelgewricht.
Geneeskunde en sport 12, 21

TÖNDERY, G. (1965):
Angewandte und topografische Anatomie.
Editor: G. Thieme Verlag, Stuttgart, New York.

TÓTH, S.; VARSÁNYI, Z.; TÓTH, F.; GASZTONYI, V. (1974):
Arthrografie mit positivem Kontrastmittel bei den Bandverletzungen des oberen Sprunggelenkes.
Monatschr. Unfallheilkd. 77, 545

VOGEL de, P.L. (1970):
Enige functioneel-anatomische aspecten van het bovenste spronggewricht.
Thesis, Leiden.

VUUST, M. (1980):
Arthrographic diagnosis of ruptured calcaneofibular ligament.
1. A new project tested on experimental injury post mortem.
Acta Radiol. (Diagn.) 21, 123

VUUST, M. (1980):
Arthrographic diagnosis of ruptured calcaneofibular ligament.
2. Clinical evaluation of a new method.
Acta Radiol. (Diagn.) 21, 231

WATSON-JONES, R. (1976):
Fractures and joint injuries.
Editor: J.H. Wilson, Churchill, Livingstone, London, 5th edition.

WEBER, B.G. (1972):
Verletzungen des oberen Sprunggelenkes.
Editor: Huber, Bern.

WEISSMAN, B.N. (1981):
Arthrography in artritis.
Radiol. Clin. North Am. vol. 19, 379

WESTON, W.J. (1969):
Lymphatic filling during positive contrast arthrography in rheumatoid arthritis.
Australas. Radiol. 13, 368

WESTON, W.J.; PALMER, D.G. (1978):
Soft tissues of the extremities. A radiologic study of rheumatic disease.
Editor: Springer Verlag, Berlin, Heidelberg, New York.

WOLFF, A (1940):
Arthrografi ar ankelled (summary).
Nord. Med. 8, 2449

WOLKOW, W.M.; MIRONOWA, S.S., PADNIN, I.A. (1973):
Traumatol. Prothesis (Moskau) 9, 1

WOLTER, D. (1979 and 1981):
Leitender Artz der chirurgischen Abteilung des St. Georg Krankenhauses, Hamburg, BRD.
Personal communication.

ZINMAN, CH.; VOLPIN, G.; MILITIANO, J.; NERUBAY, J.; OLIVER, S.; KATZNELSON, A. (1979):
Acute rupture of the lateral ligaments of the ankle joint; diagnosis and surgical treatment.
Am. Surg., July 1979, 465

Acknowledgements

Writing a thesis is not a solitary activity. It demands the support and encouragement of many people to guide it to its completion.

In particular:

Prof. Dr. J.M. Greep,
dear Co, It was you with your special interest in sports injuries who initiated the project, requesting the first ankle arthrogram in the radiological department, following the entire study through with criticism and advice to its conclusion. Your far-sightedness in introducing Mr. Coumans in our hospital provided us with a therapeutic technique, the value of which we have been able to demonstrate.

Prof. Dr. J. Drukker,
dear Jan, you first gave us a picture of the ankles' total structure rather than isolating radiological or surgical approaches. This, with your particular attention to detail was essential to the basis of this thesis. Your patience in correcting this thesis at times discouraged us, but was finally well rewarded.

Mr. P.F. Coumans,
dear Frans, the highly individual bandage therapy you developed was one of the subjects we studied, but your friendship and generous co-operation in the traumatological department were of even more importance.
We feel that part of this study can be considered to be yours.

A. Betts-Brown MA Oxon., BM,Bch.,
dear Andrew, your time and patience in grasping the subject and structure of this thesis, helping us to write it in 'Oxford English', has been invaluable to the standard of this work. Without your help and criticism we would not have been able to fulfill the scientific demands of writing a thesis and we feel that part of this study can be considered to be yours.

Dr. H. Sanches,
dear Henk, your constant support has made writing this thesis a little less arduous.

Drs. H. van Mameren,
dear Henk, your precise preparation according to your insight in the structure of the locomotor apparatus of cadaver ankles enabled us to grasp their architecture clearly.

Drs. F. Meijer,
dear Frank, your assistance with cadaver experiments was essential to the assessment of the diagnostic potential of ankle arthrography.

Drs. J. Stapert,
dear Jouwert, your support of our interest in traumatology and patient performance of the routine daily traumatological work, often on your own, gave us the peace to continue our study.

Mrs. Marie-Thérèse Finders-Velraad and Mrs. Luuk Beckers-Jussen,
dear Marie-Thérèse and Luuk, your apparently endless patience with pages of typescript and timely encouragement have often helped our flagging enthusiasm towards completion of this task.

Medical photography department,
dear Cor, Jo and Carla, we are very grateful to you all for the quality and accuracy of the photographs which appear in this thesis, of necessity only a few of the numerous ones we had to choose from.

Furthermore we wish to thank Drs. H. Kuipers for his help with the measurements of intra-articular ankle joint pressure; C.J. Lawrence, F.F.A.R.C.S. for his assistance in correcting part of the English text; Mrs. Fia Goessens-Lamkin for her assistance with the control study; Chris Voskamp for his high quality illustrations and preparation of the lay out; Miss Gerda Haemers and Miss Maartje Duyzings for their assistance with the last corrections of the manuscript, and the entire radiological and surgical department of the St. Annadal Hospital for their help, interest and encouragement, especially chief radiologists Dr. G.J. van der Plaats, Drs. B. Janevski and Drs. J.M.A. van Engelshoven, and the chief surgeons Prof. Dr. H.A.J. Lemmens, Prof. Dr. J. Jeekel, Dr. H. van Houtte, Prof. Dr. G. Kootstra, Dr. R.I.C. Wesdorp, Dr. P.B. Soeters and Dr. P.J.G. Jörning, who with other medical colleagues have made our training years so pleasant.
Last but not least so essential for the successful completion of this thesis has been the unerring support of our wives and children, who as a family have helped us survive the stress of such a venture, reminding us of the pleasures of normal family life to which we may now return.

Curriculum vitae

Kees-Rein van den Hoogenband was born on June 6th 1949 in Bandung (Indonesia). After graduating from High School, the Lorentz Lyceum in Eindhoven, he studied at the Medical Faculty in Utrecht from 1966 to 1973. From 1973 to 1974 he trained in general practice with C.P. Schouwstra, M.D. at the Philips Medical Centre, Eindhoven. From 1974 to 1976 he served in the Royal Dutch Air Force as a medical officer and in 1976 he started his training in general surgery at the surgical department of the Diaconessenhuis in Eindhoven (head Dr. H. Sluzewski), continuing from October 1976 at the surgical department of the St. Annadal Hospital (head Prof. Dr. J.M. Greep), University of Limburg in Maastricht. From May 1st to August 1st 1981 he worked at the department of traumatology (head Prof. Dr. C. Burri), University of Ulm - W.Germany.
On January 1st 1982, he was registered as a general surgeon. Since then he has been working as a chef de clinique in the St. Annadal Hospital of Maastricht, University of Limburg.

Floris Isaac van Moppes was born on October 5th 1947 in Amsterdam, The Netherlands. After graduating from high school, the Vondel Gymnasium in Amsterdam, he studied at the Medical Faculty of the Municipal University of Amsterdam from 1966 to 1974. From 1969-1972, he worked in the histology department (Jan Swammerdam institute, Prof. Dr. D.B. Kroon, Prof. Dr. J. James) and from 1974 to 1977, following qualification previously, in the internal medicine department of the 'Zonnestraal' General Hospital in Hilversum (Dr. T.G. Tan), as a G.P. in the St. Franciscus Hospital, Stykkisholmi, Iceland, in the pediatric department of the Municipal university ('Binnengasthuis') in Amsterdam (Prof. Dr. W.H.H. Tegelaers), in the surgical department of the Slotervaart Hospital (Dr. J. Bender) in Amsterdam and in the radiological department of the St. Lucas Hospital (Drs. A.K. Driessen, Drs. W.J. Kühler, Drs. W. Paul) in Amsterdam. In 1977, he started his residency in radiology at the radiology department of St. Annadal Hospital, University of Limburg, Maastricht (Dr. G.J. van der Plaats). In October and November 1979, he worked in the radiology department of 'St. Georg', General Hospital (Dr. O. Pohlenz, Dr. D. Bartelt) in Hamburg, W.Germany, and from September 1980 to January 1981 in the department of Neuroradiology (Prof. Dr. J. Valk) of the Hospital of the Free University of Amsterdam.
His registration as a radiologist took place in April 1981.

Druk: Crouzen B.V. - Maastricht.
Grafische vormgeving en illustratie: Chris Voskamp.

The publication of this thesis has been enabled by the financial support of:

- B.D.F. medical programme, Almere;
- Klinisch Genootschap Limburg.