Maastricht University

Arteriography of the lower leg : a comparative study between conventional arteriography and intraarterial digital subtraction arteriography

Citation for published version (APA):

Walstra, B. R. J. (1993). *Arteriography of the lower leg : a comparative study between conventional arteriography and intraarterial digital subtraction arteriography*. [Doctoral Thesis, Maastricht University]. Datawyse / Universitaire Pers Maastricht. https://doi.org/10.26481/dis.19930924bw

Document status and date:
Published: 01/01/1993

DOI:
10.26481/dis.19930924bw

Document Version:
Publisher's PDF, also known as Version of record

Please check the document version of this publication:

• A submitted manuscript is the version of the article upon submission and before peer-review. There can be important differences between the submitted version and the official published version of record. People interested in the research are advised to contact the author for the final version of the publication, or visit the DOI to the publisher's website.
• The final author version and the galley proof are versions of the publication after peer review.
• The final published version features the final layout of the paper including the volume, issue and page numbers.

Link to publication

General rights
Copyright and moral rights for the publications made accessible in the public portal are retained by the authors and/or other copyright owners and it is a condition of accessing publications that users recognise and abide by the legal requirements associated with these rights.

• Users may download and print one copy of any publication from the public portal for the purpose of private study or research.
• You may not further distribute the material or use it for any profit-making activity or commercial gain
• You may freely distribute the URL identifying the publication in the public portal.

If the publication is distributed under the terms of Article 25fa of the Dutch Copyright Act, indicated by the “Taverne” license above, please follow below link for the End User Agreement:

www.umlib.nl/taverne-license

Take down policy
If you believe that this document breaches copyright please contact us at:

repository@maastrichtuniversity.nl

providing details and we will investigate your claim.

Download date: 23 Apr. 2024

ARTERIOGRAPHY OF THE LOWER LEG

CIP-GEGEVENS KONINKLIJKE BIBLIOTHEEK, DEN HAAG

Walstra, Berend Robbe Jouke

Arteriography of the lower leg : a comparative study
between conventional arteriography and intraarterial
digital subtraction arteriography / Berend Robbe Jouke
Walstra. - Maastricht : Universitaire Pers Maastricht. -
Ill.
Proefschrift Maastricht. - Met lit. opg. - Met
samenvatting in het Nederlands.
ISBN 90-5278-090-0
Trefw.: gezondheidszorg ; economische aspecten /
angiografie / radiologie.

Boekverzorging: Datawyse | Universitaire Pers Maastricht

Het verschijnenvan dit boek is mede mogelijk geworden door de financiële steun van Bard Nederland, Geurbert Nederland, Nycomed en Schering.

ARTERIOGRAPHY OF THE LOWER LEG

A comparative study between conventional arteriography and intraarterial digital subtraction arteriography

PROEFSCHRIFT

ter verkrijging van de graad van doctor
aan de Rijksuniversiteit Limburg te Maastricht,
op gezag van de Rector Magnificus, Prof. Mr. M.J. Cohen,
volgens het besluit van het College van Dekanen,
in het openbaar te verdedigen
op vrijdag, 24 september 1993 om 16.00 uur

door

Berend Robbe Jouke Walstra

geboren te Haarlem in 1946

★
UPM
UNIVERSITAIRE PERS MAASTRICHT

Promotores:

Prof. dr. B.K. Janevski
Prof. dr. J.M.A. van Engelshoven

Beoordelingscommissie:

Prof. dr. P.J.E.H.M. Kitslaar, voorzitter
Prof. dr. P.J.C. van Breda Vriesman
Prof. dr. A.H. Keijser
Prof. dr. A.J. van der Linden
Prof. dr. W.P.T.M. Mali, Rijksuniversiteit Utrecht

" The man of science, by this mental habit of free criticism, is thereby always on the edge of *nonconformity*."

Reynaldo dos Santos

Aan Sabine, Frances en Sascha

CONTENTS

1.	**INTRODUCTION**	**13**
1.1.	Reason for performing this study	13
1.2.	Technology assessment: hierarchy and terminology	15
1.2.1.	*Hierarchy*	*15*
1.2.2.	*Terminology*	*15*
1.3.	Purpose of this study	16
1.4.	Contents and structure of this thesis	17
2.	**GENERAL ASPECTS OF PERIPHERAL VASCULAR DISEASE (P.V.D)**	**19**
2.1.	Arteriosclerosis, atherosclerosis	19
2.2.	Atherosclerosis of the extremities	19
2.3.	Pathology of atherosclerosis, fibrous plaques	20
2.4.	Plaque complications, hemodynamic considerations.	20
2.5.	Hemodynamic critical stenosis	20
2.6.	Collateral circulation	21
2.7.	Clinical aspects of arterial obstruction	22
2.8.	Disease classification	22
2.9.	Therapeutic aspects of arterial occlusive disease	22
2.9.1.	*Surgical therapy*	*23*
2.9.2.	*Radiological therapy*	*23*
2.10.	Arteriography in arterial occlusive disease	25
2.11.	Anatomy: the popliteal artery and its branches	25
2.11.1.	*Normal anatomy*	*26*
2.11.2.	*Collateral circulation of the lower leg*	*26*
2.11.3.	*Significance of popliteal arterial variants*	*27*
2.11.4.	*Significance of foot arterial anatomy; future prospects for IADSA?*	*27*
2.12.	This study	28
3.	**NON INVASIVE DIAGNOSTIC IN PERIPHERAL VASCULAR DISEASE: A BRIEF REVIEW OF METHODS**	**29**
3.1.	Palpation and auscultation	30
3.2.	Oscillography	30
3.3.	Plethysmography	30
3.4.	Doppler ultrasound	30
3.5.	B-mode ultrasound	31
3.6.	Microcirculatory studies	32
3.6.1.	*Transcutaneous pO_2 measurement*	*32*
3.6.2.	*Capillary microscopy*	*32*
3.6.3.	*Laser-Doppler*	*32*

3.7.	Radioisotope studies	32
3.8	Plain X-ray film	33
3.9.	Computed Tomography (CT)	33
3.10.	Magnetic Resonance Angiography (MRA)	33
3.11.	Direct intraarterial pressure recording	34
3.12.	This study	34
4.	**CONVENTIONAL ARTERIOGRAPHY**	**35**
4.1.	Historical aspects of aorto-iliac and lower extremity arteriography	36
4.2.	Arteriographic puncture techniques	37
4.2.1.	*Femoral approach*	*37*
4.2.2.	*Translumbar approach*	*37*
4.2.3.	*Axillary approach*	*37*
4.3.	Contrast Injection	38
4.4.	Visualized blood vessels	38
4.5.	Filming technique	38
4.6.	Technical considerations; calculation of the filming delay and duration of filming	40
4.7.	Techniques for improved distal arterial opacification.	40
4.8.	Complications of arteriography	41
4.8.1.	*Contrast medium reactions*	*41*
4.8.2.	*Renal complications*	*41*
4.8.3.	*Complications related to catheterization*	*42*
4.9.	Intraoperative arteriography	43
4.10.	Pitfalls in film interpretation in arteriography of the lower leg	43
4.10.1.	*Problems relating to Roentgenography*	*43*
4.10.2.	*Problems relating to bloodflow*	*44*
5.	**DIGITAL SUBTRACTION ANGIOGRAPHY**	**49**
5.1.	Definition; What is Digital Subtraction Angiography (DSA)?	49
5.2.	Subtraction	50
5.2.1.	*Introduction*	*50*
5.2.2.	*Photographic procedure*	*52*
5.2.3.	*Electronic procedure*	*52*
5.2.4.	*Advantages of subtraction*	*53*
5.2.5.	*Types of digital subtraction*	*53*
5.3.	Technical aspects of DSA	56
5.3.1.	*Types of equipment*	*56*
5.3.2.	*Components of a DSA system*	*57*
5.3.3.	*Resolution*	*61*
5.3.4.	*DSA evaluation with phantoms*	*62*
5.3.5.	*Image manipulation*	*62*
5.3.6.	*Image display*	*63*
5.3.7.	*Image storage*	*65*
5.4.	Intravenous Digital Subtraction Angiography (IVDSA)	66
5.4.1.	*Introduction*	*66*

5.4.2.	*Peripheral versus central venous injection*	67
5.4.3.	*Disadvantages*	68
5.4.4.	*Present day applications*	68
5.5.	Intraarterial Digital Subtraction Angiography (IADSA)	68
5.5.1.	*Introduction*	68
5.5.2.	*Field of view*	69
5.5.3.	*Automated stepping ("bolus-chase DSA")*	70
5.5.4.	*IADSA in interventional radiology*	71
5.6.	DSA in extremity trauma	71
5.7.	DSA and extremity tumors	72
5.8.	DSA and peripheral vascular bypass procedures, angioplasty	72
5.9.	Intra-operative DSA	73
5.10.	DSA and outpatient arteriography, cost benefits	73
6.	**COMPARISON BETWEEN CA AND DSA: A REVIEW OF THE LITERATURE**	**75**
7.	**CONSISTENCY STUDY: SUBJECTS, EQUIPMENT, EXAMINATION METHODS, DATA ANALYSIS**	**79**
7.1.	General design of this study	79
7.2.	Patient population	79
7.2.1.	*Clinical evaluation*	80
7.2.2.	*Non-invasive tests*	80
7.2.3.	*Indication for arteriography*	81
7.3.	Diagnostic imaging equipment	82
7.4.	Method of arteriography	85
7.4.1.	*Puncture and catheterization*	85
7.4.2.	*Conventional arteriography (CA)*	85
7.4.3	*Intraarterial digital subtraction angiography (IADSA)*	88
7.4.4.	*Vasodilatory influence of contrast medium*	90
7.5.	Method of film interpretation	90
7.5.1.	*Film reading*	90
7.5.2.	*Interpretability*	91
7.5.3.	*Description of the arteriogram (Angioscore)*	93
7.5.4.	*Collaterals*	93
7.5.5.	*Quality*	94
7.5.6.	*Graftability*	94
7.6.	Statistical analysis	95
7.6.1.	*Interobserver agreement and consistency*	95
7.6.2.	*Kappa*	96
7.6.3.	*Weighted Kappa*	96
7.6.4.	*Kappa values*	98
7.6.5.	*This study*	98
8.	**CONSISTENCY STUDY: RESULTS**	**101**
8.1.	Arteriograms	101
8.2.	Interpretability	103
8.2.1.	*Total number of interpretable arteries*	103

8.2.2.	*Interpretability of each artery*	*103*
8.3.	Quality	107
8.3.1.	*Popliteal artery*	*109*
8.3.2.	*Posterior tibial artery*	*109*
8.3.3.	*Anterior tibial artery*	*109*
8.3.4.	*Peroneal artery*	*109*
8.3.5.	*Conclusion*	*109*
8.4.	Hemodynamic evaluation	111
8.4.1.	*Total study group*	*111*
8.4.2.	*Hemodynamic evaluation of non-interpretable arteries*	*111*
8.4.3.	*Correlation between interpretability of CA and ABI*	*111*
8.5.	Consistency of interpretable arteries of the total study group	112
8.5.1.	*Multicategorical Angioscore*	*113*
8.5.2.	*50% Stenosis*	*113*
8.5.3.	*Occlusion*	*114*
8.6.	Vasodilatory influence: consistency of percutaneous needle puncture group: CA prior to IADSA	116
8.6.1.	*Number of interpretable arteries*	*117*
8.6.2.	*Multicategorical Angioscore*	*117*
8.6.3.	*50% Stenosis*	*117*
8.6.4.	*Occlusion*	*117*
8.7.	Vasodilatory influence: consistency of percutaneous needle puncture group: IADSA prior to CA	118
8.7.1.	*Number of interpretable arteries*	*119*
8.7.2.	*Multicategorical Angioscore*	*120*
8.7.3.	*50% Stenosis*	*121*
8.7.4.	*Occlusion*	*123*
8.8.	Collaterals	123
8.8.1.	*Interpretable arteries*	*123*
8.8.2.	*Consistency of collaterals with CA and IADSA*	*124*
8.9.	Graftability	125
8.9.1.	*Graftability score*	*126*
8.9.2.	*Correlation between judged graftability and actual grafted artery.*	*127*
9.	**CONSISTENCY STUDY: DISCUSSION OF RESULTS**	**129**
10.	**PATIENT RADIATION DOSES IN LOWER EXTREMITY ARTERIOGRAPHY: COMPARISON BETWEEN CA AND IADSA**	**135**
10.1.	Introduction	135
10.2.	Dose-area product (DAP) and entrance dose	135
10.3.	Materials and methods	136
10.4.	Results	137
10.4.1.	*Sex and age*	*137*
10.4.2.	*Frequency of lower extremity arteriography*	*138*
10.4.3.	*Diagnostic projections, images, fluoroscopy time*	*138*

10.4.4.	*DSA-frames*	*139*
10.4.5.	*Frequency of DSA projections*	*140*
10.4.6.	*Dose-area product per imaging technique*	*140*
10.4.7.	*Dose-area product per diagnostic projection*	*140*
10.4.8.	*Field size of X-ray beam*	*142*
10.4.9.	*Entrance dose in lower extremity arteriography*	*142*
10.5.	*Discussion*	*144*
11.	**A COST ANALYSIS OF CA AND IADSA**	**147**
11.1.	Introduction	147
11.2.	Materials and methods	147
11.3.	Results	148
11.3.1.	*Capital costs of equipment, depreciation, interest*	*148*
11.3.2.	*Maintenance of equipment*	*151*
11.3.3.	*X-ray contrast media*	*152*
11.3.4.	*Film costs*	*154*
11.3.5.	*Total costs per examination*	*155*
11.4.	Discussion	156
12.	**CONCLUSIONS AND RECOMMENDATIONS**	**159**
12.1.	Conclusions	159
12.2.	Recommendations	160
13.	**SUMMARY - SAMENVATTING**	**163**
	APPENDIX	**171**
	REFERENCES	**172**
	ACKNOWLEDGEMENT	**196**
	CURRICULUM VITAE	**199**

LIST OF ABBREVIATIONS

ABI	ankle brachial index
CA	conventional arteriography
CT	computer tomography
DAP	dose area product
DSA	digital subtraction angiography
G	gray
cGY	centigray
mGY	milligray
IADSA	intraarterial digital subtraction angiography
IVDSA	intravenous digital subtraction angiography
K	kappa
Kw	weighted kappa
MRI	magnetic resonance imaging
MRA	magnetic resonance angiography
PNP	percutaneous needle puncture
PTA	percutaneous transluminal angioplasty
TLA	translumbar aortography

REFERENCES

In this thesis the bibliographic references are characterized by the first letter of the last name of the first author and a number (such as [B4]) rather than simply a number. This convention combines the convenience, simplicity, and brevity of a reference symbol in the text with the usefulness of making it easier for the reader to find the reference to a given author's paper in the list of references, which are primarily arranged alphabetically. The secondary, numerical arrangement has no logic, and new references within each alphabetic subheading were simply added to the end of the list in that subheading without the need to renumber all subsequent references. This method, taken from a major cardiac surgery textbook, greatly simplified the preparation of this thesis and is recommended to others (from: Kirklin JW, Barrat-Boyes BG. Cardiac Surgery, New York: Wiley, 1986).

AUTHOR'S NOTE

In daily radiological practice and in the literature, the words "angiography" and "angiogram" are often used to imply "arteriography" or "arteriogram", although they also encompass the examination of veins. In the present study only arteries have been examined.

1. INTRODUCTION

1.1. REASON FOR PERFORMING THIS STUDY

Prior to the advent of endovascular therapy and distal bypass surgery, it was often sufficient to visualize the lower extremity arteries down to the popliteal artery. In those early days of arteriography with a moving table, the more distal vessels were even considered less important clinically, and it sufficed to adequately visualize arteries to the popliteal "trifurcation". Using a single bolus injection of contrast medium with a catheter in the aorta, the vasculature from the aortic bifurcation to the feet was, according to early reports, adequately visualized bilaterally in approximately 80% of patients. Visualization of vessels beyond the popliteal trifurcation required repeat injections of contrast medium with additional series of films[A12].

As vascular surgery and interventional radiology progress and bypass procedures and percutaneous transluminal angioplasty move more and more distally [B25,H12,J5], it is becoming necessary to improve the technique for visualization of the arteries of the lower leg. It has recently been reported that with standard conventional arteriography the subtrifurcation vessels in up to 70 percent of patients with severe disease[B44,F17,K1,K23,M29,O4,R19], are often inadequately visualized for reconstructive surgery,

Recent surgical literature advocates an aggressive policy in limb salvage therapy, in order to achieve revascularization of limbs which are at risk of an amputation (Figure 1.1)[A16,V7,V8,V9]. At the same time, new noninvasive tests-[G19,P5,S24] have been developed to provide complementary information to the patient's history and physical examination. Only after an analysis of all this information - including levels of obstruction, degree of disability, and other coexisting medical problems - can an appropiate management plan be formulated[R23]. Conventional arteriography (CA) is an invasive procedure and should be performed mainly if definitive therapy is contemplated[I3,P21]. Because non-invasive examinations like Doppler and ultrasound are deficient in accurately visualizing the arteries of the lower leg, an optimal arteriogram of the most peripheral vessels in the lower extremity is very important[C10,P5]. Peripheral arteriography is therefore still an important diagnosistic tool, because it is the principal procedure for identifying the peripheral vascular lesions responsible for symptoms, and characterizing the severity of arterial occlusive disease distal to the lesion (i.e. "runoff"). By staging the specific sites and extent of involvement of the vascular system, it can be determined which therapy could best be applied to the patient[L4,L15,M8,M17,N10]. Whereas diagnostic lower extremity arteriography used to be the goal, it is now often a preliminary step to a planned endovascular intervention, often in one sitting[D13]. For this reason, the radiologist performing the arteriography must have adequate knowledge

FIGURE 1.1
Foot threatened by amputation

of vascular disease and work in close cooperation with the vascular surgeons[C20,P21].

Over the last two decades, the development of newer, smaller and faster computers has led to a tumultuous growth in radiology. The computerization of angiography has led to the introduction of Digital Subtraction Angiography (DSA), adding a new dimension to the diagnosis of vascular disease. A few recent review articles have described the merits of DSA, especially in comparison with CA[C3,D2,J7,S41].

In a previous report from this hospital in 1981, it was noted that the consistency in interpreting translumbar aortograms (CA method) was very poor if one measured the interobserver agreement on the degree of arterial stenosis[B42]. In 1982, Turnipseed et al[T9] suggested that failure to visualize distal vasculature in ischemic patients by standard arteriography (CA method) is usually a technical problem and that bypass surgery is possible in many patients who might otherwise be considered for amputation. In their small series of 20 patients in whom CA failed to visualize tibial vessels, 70% were shown with intraarterial digital subtraction angiography (IADSA) to have at least one patent tibial vessel, and subsequently underwent distal artery bypass surgery. One main reason for performing this study was therefore to see whether IADSA is technically more adequate for visualizing lower leg arteries than CA, and consequently more consistent than CA in the diagnosis of arterial stenosis or occlusion. This could result in a higher vessel bypass rate with subsequent limb salvage and hence a lower amputation rate with better quality of life for the patient[H37].

Another reason for performing this study was to see whether there was any substantial difference in patient radiation dose between CA and IADSA. The reason was that very little data has been published on this aspect of angiography, whether it be CA[H30,M9] or DSA. Comparison studies between CA and IVDSA of cerebral vessels suggested a much lower dose (50-90%) for DSA[P2, P8,P20] than for CA. Reports on patient radiation dose in lower extremity IADSA are very scanty or anecdotal, and one report[L8] suggested a lower radiation dose

for IADSA in comparison with CA. For this reason, a radiation dose assessment was carried out as part of this study, to see whether indeed the use of IADSA resulted in lower radiation exposure to the patient.
Increasing costs in radiology have not only been brought about by the increased number of radiological procedures, but also by a continual improvement in the technology of diagnostic equipment. The literature is also very scanty on costdata specifically concerning IADSA, and most reports suggest that the use of IADSA[G2,L8,N3] saves costs, without a very elaborate assessment. For this reason a cost analysis was performed as part of this study, in order to see whether IADSA is indeed cheaper than CA.

1.2. TECHNOLOGY ASSESSMENT: Hierarchy and Terminology

The basic challenge to any medical procedure is: does it contribute positively to the health and well-being of the patient[H33]? Radiology, which uses expensive and complicated technologies, is especially an obvious target for increased attention[A1,F27].

1.2.1. Hierarchy

One can consider a five-stage hierarchy of imaging technology assessment: imaging efficacy, diagnostic efficacy, therapeutic efficacy, evaluation of patient outcome and cost-effectiveness assessment[H34]. In this study, the assessment has mainly been focussed on imaging and diagnostic efficacy, but some attention has also been paid to the last three stages.
For a long time CA was regarded as the "gold standard" for evaluation of vascular disease, but more recently this has been challenged by the advent of various new non-invasive diagnostic tests[B5,C6,C26] and new information about the low degree of interobserver agreement in coronary angiograms and translumbar aortography[B42,Z6]. This study should therefore not be interpreted as one in which CA is used as the gold standard of aorto-iliac and lower extremity arteriography, but simply as a comparison between CA and IADSA.

1.2.2. Terminology

The basic aim of the first part of this study was to compare the reading of arteriograms of CA and IADSA of lower leg arteries.

1.2.2.1. Interpretability

As was mentioned above, lower leg arteries in a number of patients are not adequately visualized below the popliteal trifurcation with CA after a first single bolus injection of contrast medium, and are therefore in fact non-inter-

pretable for the lower leg region. In this study therefore, an observer first had to assess whether an artery had been adequately visualized from the popliteal to the ankle region. The artery was then considered interpretable.

1.2.2.2. Consistency and validity

In comparing two types of examinations, one must determine consistency and validity. Consistency refers to the agreement of two processes in situations (such as studies of observer variability) in which neither process is assumed to be correct or definitive[F15]. The concept of consistency is sometimes also referred to as reliability, reproducibility, or repeatability[F11,F15,K35]. Agreement may be from test to test, or from observer to observer (interobserver agreement) or from time to time by the same observer (intraobserver agreement)[K35]. Consistency may be measured without reference to an external diagnosis ("gold standard"). One can imagine that serious inconsistency will lead to an imaging technique which is not consistently accurate[F11]. In this study consistency was determined only by comparing the level of interobserver agreement in reading CA films with the level of interobserver agreement in reading IADSA films of the same patients. Because agreement found between observers may be completely or partially based on chance, a method of statistical evaluation was selected which measures agreement corrected for chance[C8,F26,V10]. This method was originally introduced for paired observations, but because four observers participated in this study, a modified version of the statistical analysis was applied[S20,S21]. The method permits calculation of Kappa (K) as the measure of interobserver agreement corrected for chance.

Validity refers to the agreement of a principal process with the reference process that has been established as the (gold) standard[F15]. The concept of validity with a standard is also referred to as accuracy or correctness. In this study there was no external gold standard, which meant that validity could not be determined.

1.3. PURPOSE OF THIS STUDY

The purpose of this prospective study was five-fold:

1. to compare the interpretability of CA with IADSA of lower leg arteries;
2. to compare the consistency of readings of conventional arteriograms with those of intraarterial digital subtraction arteriograms of lower leg arteries;
3. to compare the assessment of graftability of CA and IADSA of lower leg arteries prospectively and in retrospect with the operation performed;
4. to compare the radiation doses for CA and IADSA of the lower extremities;
5. to compare costs of CA and IADSA of the lower extremities.

In this study, as part of purpose (1), attention was also paid to the the causes of non-interpretability of the angiographic examination. The two main causes of

non-interpretability are inadequate filling of arteries with contrast medium (low contrast) and/or bone cortex being superimposed over the artery (bone superposition). The judgment of interpretable or non-interpretable can be an indication of the quality of the angiographic procedure, see 7.5.5.
As CA and IADSA in the same patient were performed within a short timespan of each other, and contrast medium is shown to have vasodilatory properties (see 4.3.), one group of patients underwent first CA and then IADSA, while another group of patients first underwent IADSA and the CA. The reason behind this additional assessment was to see if any significant influence on the consistency of film reading (purpose 2) could be attributed to contrast medium.

The study was designed in such a way that answers to the following questions might be expected:

1. does the application of IADSA in arterial occlusive disease improve the interpretability (visualization) of lower leg arteries in comparison with CA? Which of the following factors account for differences in examination quality and subsequent non-interpretation of CA and IA-DSA films: a) low contrast, b) bone superposition, c) other factors (e.g. technical, artefacts) ?
2. is IADSA more consistent than CA for interpreting a multi-categorical Angioscore, 50% stenosis, occlusion or collateral blood flow? Does vasodilatation caused by intraarterial injection of contrast medium have any influence on the consistency of film interpretation in CA or IADSA?
3. Are more arteries assessed as graftable with IADSA than with CA?
4. Does the application of IADSA of the lower extremity cause a reduction of patient radiation doses in comparison with CA?
5. Is lower extremity arteriography less expensive if performed by IADSA in comparison with CA?

1.4. CONTENTS AND STRUCTURE OF THE THESIS.

The first part of this thesis contains brief reviews of the literature dealing with general aspects of peripheral vascular disease (Chapter 2) and noninvasive diagnostic methods used in the diagnosis of arterial occlusive disease (Chapter 3). This part also includes a more descriptive chapter on CA, relating especially to problems which can be encountered in performing aorto-iliac and lower extremity arteriography (Chapter 4). A detailed account of the development of DSA and, more specifically, its application in lower extremity disease is given in a separate chapter (Chapter 5). The first part of the thesis ends with a review of earlier studies, which have also compared CA with DSA (Chapter 6).
In the second part of this thesis, the consistency study is reported. The subjects, equipment, examination methods and data analysis are described in Chapter 7. Results of the consistency study are presented in detail in Chapter 8. Chapter 9 contains a discussion of these results and a comparison with the literature.

The third part of this thesis describes a study performed in a group of patients who underwent aorto-iliac and lower extremity arteriography according to the protocols for CA and IADSA, comparing the entrance doses for CA and IADSA. Examination methods, results and discussion are presented in Chapter 10.
The fourth and last part of this thesis describes a study in a group of patients who in the course of one year underwent aorto-iliac and lower extremity arteriography according to the protocol for CA and IADSA, evaluating and comparing certain costs which could possibly be different for CA and IADSA. Materials and methods, results, and discussion are presented in Chapter 11.
Chapter 12 contains the conclusions of these studies, followed by a brief note on consequences and recommendations.

2. GENERAL ASPECTS OF PERIPHERAL VASCULAR DISEASE

The term peripheral vascular disease in its broadest sense applies to disease of any of the blood vessels outside the heart and to disease of the lymph vessels-[F22]. Most diseases of the arteries are degenerative, the most common one being atherosclerosis.

2.1. ARTERIOSCLEROSIS, ATHEROSCLEROSIS

Arteriosclerosis denotes the "normal" aging process in arteries, characterized by thickening of the intimal layer, a loss of elasticity, an increase in calcium content, and an increase in vessel diameter. Age-related changes in the arteries affect primarily the intima and media and differ in type and degree in different vessels of the same individual. The aging changes do not represent a prelude to atherosclerosis in all arteries, although the severity of atherosclerosis is closely linked to aging in those arteries destined to become atherosclerotic[L29].
Atherosclerosis is a degenerative process characterized by the accumulation of cells, matrix fibers, lipids, and tissue debris in the intima, which may result in narrowing of the lumen and obstruction of blood flow, ulceration, thrombosis, embolization, and aneurysm formation with eventual artery wall rupture[Z5]. Risk factors for atherosclerosis are hyperlipoproteinemia, hypertension, cigarette smoking, diabetes mellitus, and genetic factors or family history of atherosclerotic disease[F20]. Theories on the pathogenesis of atherosclerosis have been described elsewhere, and are beyond the scope of this thesis[R20].

2.2. ATHEROSCLEROSIS OF THE EXTREMITIES

Chronic atherosclerotic occlusive disease of the extremities involves the aorta, the iliofemoral and popliteal arteries, and the medium-sized arteries below the knee. To a lesser extent are the upper extremities involved in this disease. The clinical disease is usually designated by long established terms as "arteriosclerosis obliterans" or "atherosclerosis obliterans"[J13].

2.3. PATHOLOGY OF ATHEROSCLEROSIS, FIBROUS PLAQUES

Arteries respond to acute hemodynamic alterations by changing caliber, either by constriction or dilation. Under normal conditions, adaptive alterations in lumen diameter are determined by the blood flow in the artery. Adaptive responses of arteries serve to maintain the structural and functional integrity of the arterial tree. Normal responses to altered biomechanical and hemodynamic conditions result in compensatory alterations in artery wall thickness, lumen diameter, or both. Pathologic conditions may cause alterations in wall thickness and lumen diameter that proceed to lumen stenosis, aneurysm formation, or obstructive intimal hyperplasia[Z5].
The characteristic atherosclerotic lesion or intimal deposit is the fibrous plaque. This lesion has a characteristic architecture consisting of a fibrous cap (a subendothelial region of smooth-muscle cells and connective tissue) and a deeper necrotic core. Calcification is a prominent feature of advanced plaques and may be quite extensive, involving both the superficial and deeper reaches of the plaques[Z5].
The common perception that atherosclerotic plaques bulge into the lumen of arteries reflects the fact that plaques used to be evaluated by arteriography, which reveals the lumen contour in a longitudinal view. A protrusion of plaque into the lumen is thus usually perceived as a narrowing of the lumen (stenosis).

2.4. PLAQUE COMPLICATIONS, HEMODYNAMIC CONSIDERATIONS

Clinical sequelae of atherosclerotic lesions are usually caused by plaque complications. Plaque disruption or ulceration may result in embolization of plaque materials, occlusion or embolizing thrombi. Critical lumen narrowing causes inadequate arterial circulation, resulting in arterial insufficiency and ischemia. This is characterized clinically by intermittent claudication or rest pain. In a more advanced stage it may also be manifested by ulceration and gangrene[Z5].

2.5. HEMODYNAMIC CRITICAL STENOSIS

A stenosis is more or less defined as an abrupt decrease in the cross-sectional area of an artery occupying some length of that artery, followed by a more or less abrupt increase of luminal cross-sectional area[K17].
A "critical stenosis" is defined as the percentage by which the cross-sectional area of a vessel must be reduced in order to produce a measurable drop in blood flow and pressure, or as a stenosis in which a further increase in the severity will cause a significant reduction in blood flow and pressure[B34,S29].
May et al.[M5,M6] assembled values from various authors who had studied the

problem in the dog and also calculated the "critical stenosis" values for various arteries in man. Experimentally, appreciable changes in pressure (a drop of 20 mmHg) and flow do not occur until the cross-sectional area of a vessel has been reduced by more than 75 percent (usually 80 to 90 percent)[B34]. The relation between the percentage of cross-sectional area reduction (A) and the percentage of diameter reduction (D) for an axisymmetric stenosis is given by the equation $A = (2 - D/100) D$[S50]. Assuming that the obstructing lesion is symmetric, this 75% reduction in cross-sectional area corresponds to at least a 50% reduction in diameter.
The length of a stenosis is of relatively minor importance for the energy loss across it. The resistances of stenoses in series are roughly additive, which means that multiple noncritical stenoses may act as a single critical stenosis and result in arterial insufficiency. If two stenoses of unequal caliber are in series, the tighter of the two has by far the greater effect on resistance[F21,S29,S47].

2.6. COLLATERAL CIRCULATION

Arterial stenoses are part of a complex hemodynamic circuit, consisting of the diseased major artery, a parallel system of collateral arteries, and a so-called peripheral runoff bed[S29]. To compensate for the increased resistance imposed by a highly stenotic or totally occlusive lesion, two mechanisms are invoked: collateral development and dilation of the resistance vessels in the peripheral bed[S47].
The collateral vessels consist of distributing branches of large and medium-sized arteries, which can be divided into stem arteries, midzone collaterals, and re-entry arteries[L28]. These vessels are pre-existing pathways that enlarge when a stenosis or an occlusion develops in the main arterial supply[J6]. On angiograms they appear as tortuous, dilated braches that allow the blood to bypass a stenosed or occluded section of an artery[M23]. The appearance of collateral vessels on angiograms is regarded as a reliable sign of a high degree of stenosis of the arterial lumen[T14].
Two types of collateral vessels can be distinguished on angiograms - direct and indirect. Direct collaterals are branches which arise proximal to the occluded segment and drain into the same artery distal to the occlusion. Indirect collaterals, however, arise from a different vessel and either drain into the distal portion of the occluded artery or are connected to the direct collaterals[J4]. The resistance of the collateral bed, however, always exceeds that of the major artery whose function it has replaced, and is fixed[L23]. This is in contrast to the peripheral runoff bed, which has a variable resistance[S47].

2.7. CLINICAL ASPECTS OF ARTERIAL OBSTRUCTION

Intermittent claudication is the most important symptom of occlusive arterial disease in the lower extremity. "Claudication" is defined as extremity pain, discomfort, or weakness consistently produced by the same amount of walking or equivalent muscular activity in a given patient and is promptly relieved by cessation of that activity[R14]. Patients may describe intermittent claudication in the calf of the leg by such terms as "cramp", "tightness", "tiredness", "aching", or "pain". Intermittent claudication indicates an inadequate supply of arterial blood to contracting muscles[F22]. The pain of intermittent claudication is considered to be related to the abnormal accumulation of metabolic products within the muscle[S47].
With further progression of the disease, limb flow becomes inadequate even when the patient is at rest and presents itself as ischemic rest pain. This is a severe pain, not readily controlled by analgesics, and is localized in the chronically ischemic extremity, in the forefoot and toes, or, if more proximal, does not spare these distal parts[R14]. The presence of ulceration or gangrene in severe cases indicates necrosis of tissue.

2.8. DISEASE CLASSIFICATION

A classification of the severity of arterial disease, on the basis of clinical symptoms, was proposed by Fontaine in 1950[F7,F8]:

Stage I: asymptomatic
Stage II: intermittent claudication
Stage III: ischemic rest pain
Stage IV: ulcerations or gangrene

Assessment and comparison of reports in the vascular surgery literature is often difficult because of a lack of standardized reporting practices. More recently, it has been suggested in the literature that standardization of different classification criteria should be used for acute and chronic ischemia when attempting to stratify limbs according to severity of ischemia[R14].

2.9. THERAPEUTIC ASPECTS OF ARTERIAL OCCLUSIVE DISEASE

In limbs with arterial obstruction the elevated fixed hemodynamic resistance imposed by the obstructed major arteries and their associated collaterals is the factor responsible for restricting blood flow to the periphery[S47]. Intermittent claudication and other symptoms of peripheral ischemia can only be relieved by reducing this fixed resistance.

2.9.1. *Surgical therapy*

As there are no drugs available that produce appreciable collateral dilation or regression of atherosclerotic plaques[C31], satisfactory reduction of the fixed resistance can in most cases only be accomplished by direct surgical means like endarterectomy, replacement grafting, and bypass grafting[S47].
In chronic critical ischemia, arterial reconstruction is often necessary to prevent the amputation of a foot or lower leg, an intervention often described as "limb salvage " or "foot salvage" therapy. As vascular surgery progresses, smaller and smaller vessels can be repaired and more and more extremities can be salvaged. The use of infrapopliteal arteries as outflow tracts for the revascularization of lower limbs threatened by ischemia has become a well-established surgical entity[A15,K33,R11].
Historically, reversed autogenous saphenous vein was first used for this purpose and it has continued to be the accepted material of choice[J10,K19,T17]. Of late, data has shown that the "in situ" method of saphenous vein grafting allows for both increased bypass patency and utilization of the vein. Leather et al[L20] reported an immediate patency rate (within 30 days postoperatively) of 94%, while cumulative patency rates by life-table analysis at 1, 2, and 3 years were 87%, 82% and 72% respectively.
Ascer et al[A7] described excellent graft patency and limb salvage results in 24 cases in which all major infrapopliteal arteries were occluded as determined by adequate preoperative angiography. Previously, these situations would have meant a major amputation, as distal arterial reconstruction was limited to bypasses to named arteries in the leg and foot performed with established good angiographic runoff, as indicated by the presence of an intact pedal arch[I2].

2.9.2. *Radiological therapy*

As interventional radiology progresses, recent reports suggest that various new interventional techniques may be a satisfactory alternative to surgical treatment of occlusion of the infrapopliteal arteries. This might be necessary in patients who are considered extremely poor surgical risks because of an underlying medical condition or who have an anatomy deemed inadequate for distal bypass surgery and in whom the the only alternative therapy would be amputation.

2.9.2.1. Percutaneous transluminal angioplasty (PTA)
Despite the fact that Dotter and Judkins[D10] described three cases of angioplasty of the tibioperoneal trunk in their classic paper on transluminal angioplasty in 1964, experience in dilation of the calf vessels has been limited. In early series tapered catheters were used for dilation with mixed results. However, since the advent of new low-profile balloon catheters and steerable guidewires, reports suggest that the success of infrapopliteal angioplasty has increased. Schwarten

and Cutliff[S31] dilated 145 arteries in 98 patients and reported a primary anatomic success rate of 97% with initial limb healing without amputation in 88%. Limb salvage rate after 2 years was 86%. Brown et al[B25] reported a 75% technical success rate in 11 patients, 89% of whom were diabetic, and an early response to successful angioplasty. Bakal et al[B26] analyzed 57 procedures in 53 patients, reporting technical success in 86% of procedures, with prompt clinical improvement in 80% of technically successful procedures. It has been suggested that as an arteriographic procedure can probably precipitate the transition from stenosis to occlusion, patients should be prepared to undergo angioplasty immediately after arteriography if necessary[F25].

2.9.2.2. Laser angioplasty

Sanborn et al[S34] reported successful sole laser thermal angioplasty in 88% of infrapopliteal and below-knee popliteal lesions in 10 patients. Initial clinical and hemodynamic improvement was observed in 70%, and clinical success was maintained after six months in 71%. However, a recent review of experimental and clinical literature has suggested that the role of lasers in treating vascular disease is not yet clear, and thus laser therapy should still be considered experimental, until adequate clinical studies confirm its efficacy[C24].
A clinical trial of 28 patients by White et al[W13] also confirmed the fact that laser angioplasty has a limited role in advanced peripheral vascular disease.

2.9.2.3. Atherectomy

The use of new reperfusion devices, such as the Kensey catheter, the atherolytic reperfusion wire device and the transluminal extraction catheter, has been reported for the desobstruction of suprapopliteal arteries, but not for arteries below the knee[D6,W6].

2.9.2.4. Summary of therapy

Technical advances and increased experience are beginning to yield excellent results in the treatment of lesions of the arteries below the knee, which were formerly considered inaccessible to and unsafe for angioplasty[C23]. Although the long-term efficacy still needs to be evaluated, the results of infrapopliteal artery angioplasty appear to approach those of distal bypass surgery, with less morbidity and mortality[B26]. In evaluating the results of peripheral PTA, the excellent results from innovative modern surgical bypass procedures must be considered. In a recent review of 110 operations, Taylor et al[T17] reported an 85% patency rate for reversed saphenous vein bypass grafts below the knee and claimed a 93% limb salvage rate at 5 years with a low complication rate.
As vascular surgery and interventional radiology progress, it is very important to have excellent visualization of the arteries of the lower leg as far distally as possible[S5].

2.10. ANGIOGRAPHY IN ARTERIAL OCCLUSIVE DISEASE

Several authors[A7,K19,L20,R11,T17] have confirmed the feasibility of using tibial arteries as bypass outflow sites. It is important to note that they stress the importance of adequate preoperative angiographic evaluation, especially when evaluating the quality or the diameter of the recipient branch by standard arteriography (CA) alone. This applies especially in cases of sequential arterial occlusions, whereby CA may overestimate the severity of the disease because of faint or incomplete visualization of the distal arteries. Ascer et al[A7] suggest that in such cases IADSA should be obtained to delineate the distal arterial tree more accurately. In their paper, adjunctive digital subtraction techniques were required to improve the visualization of the outflow tract in 5 of the 24 cases. Moreover, biplane films should be performed, whenever there is doubt, to correctly identify the patent recipient branch.
This concept of adjunctive IADSA was also described some years earlier by Turnipseed et al[T9], who applied CA to twenty patients with chronic arterial disease of a lower extremity to determine whether distal bypass surgery could be performed for limb salvage. CA provided anatomic detail of the aortoiliac and proximal femoral arteries in all cases, but even with 7 minutes of cuff-induced reactive hyperemia, arteriography failed to demonstrate the status of the tibial vessels and the plantar arcade. However, IADSA demonstrated a patent popliteal artery with at least one patent tibial vessel communicating with the distal arcade in 14 of 20 ischemic extremities (70%). Fourteen patients underwent distal artery bypass because of additional information provided by IADSA. The patency of the occult arteries in the distally reconstructed limbs was confirmed by intraoperative arteriograms. This implies that failure to visualize distal vasculature in ischemic patients by CA is usually a technical problem and that bypass surgery is possible in many patients who might otherwise be considered for amputation.

2.11. ANATOMY: The popliteal artery and its branches

With improvement in radiological and surgical techniques, the recognition and knowledge of the anatomic variability in this region assumes an important role in the management of patients with atherosclerosis or vascular injury of the lower leg.

2.11.1. Normal anatomy

The normal anatomy of the main arteries of the lower leg, i.e. the popliteal, posterior tibial, anterior tibial and peroneal (fibular) arteries, is described in major anatomical textbooks[G11,G25]. In some additional texts, special attention is paid to radiological anatomy[L16,W12].

The popliteal artery begins at the adductor hiatus and runs deep down through the popliteal fossa to reach the lower border of the popliteus muscle, where it divides into the posterior and anterior tibial arteries. The floor of the popliteal fossa is formed above by the popliteal surface of the femur[G25], and in interpreting vascular anatomy on X-ray films, the origin of the popliteal artery is a continuation of the superficial femoral artery at that point where the artery crosses the medial border of the femur. The average length of the popliteal artery is 18 cm, and its diameter 0.7 cm[L16]. Smaller branches of the popliteal artery include the cutaneous, muscular and genicular arteries.
The posterior tibial artery descends medially on the posterior aspect of the leg and terminates as the medial and lateral plantar arteries below the ankle joint. Its diameter is 2.23 to 4.15 mm[L16]. Smaller branches (apart from the peroneal artery) include a circumflex fibular, nutrient and muscle arteries, and an important communicating branch above the ankle with the peroneal artery.
The anterior tibial artery passes forward between the two heads of the posterior tibial muscle and through the interosseous membrane to the front of the leg, medial to the neck of the fibula. Descending on the anterior surface of the interosseous membrane, it gradually approaches the tibia, lying on it in the lower parts of the leg. At the level of the ankle joint, midway between the two malleoli, it becomes the dorsal pedal artery. The diameter of the anterior tibial artery is 1.19 to 3.5 mm[L16].
The peroneal (fibular) artery, arising from the posterior tibial artery about 2.5 cm below the popliteal division, passes obliquely towards the fibula, and descends along its medial side in the tibiofibular syndesmosis, to reach the lateral side of the calcaneus, where it divides into calcanean branches. Small branches include a nutrient and muscular arteries, and most important, a perforating and a communicating branch, which anastomose with the posterior tibial or its branches just above the ankle joint.

2.11.2. Collateral circulation of the lower leg

Genicular anastomoses are formed among the superficial femoral artery, the deep femoral artery, the popliteal artery (superior, middle and inferior genicular arteries), and the anterior tibial artery. This communication is not always adequate[L16].
Anastomoses in the legs and feet between the three arteries of the leg are formed in the region of the ankles (malleolar arteries) and in that of the heels (calcanean arteries) via the connections of the peroneal artery (communicating branch, perforating branch), and by way of the vessels of the plantar arch (dorsalis pedis and plantar branches)[L16].

2.11.3. *Significance of popliteal arterial variants*

With improvements in surgical and radiological techniques, recognition of variations in the division of the popliteal artery assumes an important role in the management of the patient with arteriosclerosis or vascular injury of the lower leg. Knowledge of these variants is important to angiographers and vascular surgeons, as they may influence the success of vascular grafting, direct surgical repair, transluminal angioplasty, embolectomy, or the diagnosis of arterial injury[B30,K24,M4]. In addition, a knowledge of the embryology of the popliteal artery provides a better understanding of the development of the atherosclerotic popliteal artery aneurysms and the popliteal artery entrapment syndrome[M4,S8].
In a review of 1000 arteriograms[K24], normal branching of the popliteal artery was found to be present in 92.2%. Among the 7.8% incidence of variants, the majority (72%) were either high origin of the anterior tibial artery or a trifurcation pattern. Special attention was also paid in this review to critical variation in arterial supply to the foot, which can be expected if the infrapopliteal vessels show a hypoplastic or aplastic anterior or posterior tibial artery and compensatory hypertrophy of the peroneal artery (saphena magna, or the peronea magna artery)[K24,S8].

2.11.4. *Significance of foot arterial anatomy; future prospects for IADSA?*

Visualisation of patent leg and foot arteries by preoperative arteriography is difficult if severe femoropopliteal occlusive disease markedly reduces limb blood flow. One of the essential factors for successful lower extremity bypass grafting is the presence of adequate distal runoff. Like the popliteal trifurcation in femoropopliteal bypass, the status of small arteries of the foot may be the best indicator of runoff for bypass grafting to the anterior tibial, posterior tibial, and peroneal arteries. It has been suggested that the integrity of the plantar arch is a reliable predictor of tibial graft patency[I2].
In routine preoperative arteriography (CA), the visualization of tibial or peroneal arteries at the calf or ankle level is often adequate for a choice of the site for construction of the distal anastomosis of the bypass graft. However, detailed arteriographic information on the foot vessels is often insufficient. O'Mara et al[O4] demonstrated the importance of intact primary and secondary pedal arches and communicating branches with the peroneal artery in evaluating the results of extended distal bypass surgery, with an 87.5% early graft patency rate in 40 limbs. They advocate the use of operative arteriography to demonstrate pedal arch anatomy, because this is usually not achieved with routine preoperative arteriography (CA). However, further improvement of the preoperative arteriographic technique for visualizing lower leg and foot arteries for limb salvage was demonstrated a year later by Turnipseed et al[T9],

describing the use of IADSA (combined with reactive hyperemia), in patients who had nonvisualized distal runoff by CA.

2.12. THIS STUDY

The above-mentioned paper[T9], describing the new diagnostic method of IADSA for determining limb salvage bypass candidates, provided the actual stimulus for the present study, in which the use of IADSA as an adjunct to CA was restricted to examination of the popliteal and lower leg region only, with the ankle joint as the lower border. Interpretation of foot vessels was not originally included in this study, although in later arteriographic examinations foot IADSA was performed more and more often, because of its easy application during the whole angiographic procedure and its diagnostic value.

3. NONINVASIVE DIAGNOSTIC METHODS IN PERIPHERAL VASCULAR DISEASE

A brief review of current methods

The purpose of this chapter is to review the current noninvasive diagnostic methods available for the evaluation of peripheral arterial disease. In the past, contrast arteriography was the standard diagnostic technique for evaluation of peripheral arterial disease, but it is subject to intra- and interobserver variability[B42], and cannot be used to assess the accuracy of physiologic or metabolic parameters. Invasive angiographic techniques involve expense, discomfort, and potential risks to the patient which preclude their use as routine screening and follow-up procedures[B28].
Currently, noninvasive testing is widely accepted as the initial diagnostic approach to diseases of the aorto-iliac and peripheral arteries[B10,F2,G21,S24]. Peripheral arteriography is rarely used for diagnosis; its role is one of staging, that is, of defining the specific sites and extent of involvement of the vascular system, so that it can be determined which therapeutic procedure might be best applied to the patient, be it surgical or radiological intervention. With such detailed information provided by noninvasive testing, one can tailor the arteriogram to provide the maximum amount of information with the minimum risk and discomfort to the patient[C20].

The methods in use are:
- Palpation and auscultation
- Oscillography
- Plethysmography
- Doppler ultrasound
- B-scan ultrasound
- Microcirculatory studies

3.1. PALPATION AND AUSCULTATION

The presence of arterial pulsation in patients with arterial occlusive disease signifies adequate bloodflow, at least at rest. However, this does not necessarily mean that the transporting arteries are competent. The collateral circulation may be so strongly developed that pulsations can be present at rest distally from an occlusion.
A bruit heard above an artery suggests a stenosis, but even this can be misleading. Leg arteries may have functional bruits which disappear after exercise.
Generally, these methods of diagnosis can be very inaccurate and thereby lead to false-positive and false-negative conclusions[B33,R23,S49].

3.2. OSCILLOGRAPHY

Systolic pressure may be measured by a pneumatic cuff, whereby the cuff pressure is gradually lowered in steps of 10 mmHg and the maximum excursions noted on the oscillograph at the highest pressure of the cuff[S24].

3.3. PLETHYSMOGRAPHY

The plethysmograph provides graphic recordings of changes in the dimensions of a portion of the body in response to each heartbeat or in response to temporary obstruction of venous return[B28,S34]. Most plethysmographs record directly or indirectly the change in volume of the digit, limb, or other part of the body. There are currently five different types of plethysmographs in use for evaluating peripheral vascular disease, each type employing a different transducer principle for recording the changes in body dimension[S48]. The types are:
1. water plethysmograph
2. photoelectric plethysmograph
3. strain gauge plethysmograph
4. air plethysmograph
5. impedance plethysmograph

This method of registration only examines the physiological function of the bloodvessels and does not define any anatomy.

3.4. DOPPLER ULTRASOUND

Doppler ultrasound detects blood flow by the frequency shift of ultrasound reflected from moving blood cells (Doppler effect)[G24,S48].
It may be used for three purposes:
1. blood velocity signal analysis

2. determination of systolic blood pressure
3. vascular imaging

The ultrasound detectors can generally be divided into two types:
1. continuous-wave devices, which emit an ultrasound beam without interruption, and
2. pulsed Doppler detectors, which transmit intermittent bursts of ultrasound which can be sampled for return signals at various times after transmission, permitting range resolution of detected flow at a given point from the transducer.

At the site of a stenosis the velocity signal becomes high-pitched and occasionally turbulent in character. In the presence of severe arterial occlusive disease with poor collateral circulation, the arterial velocity signal may even be unobtainable.
Assessment of peripheral vascular disease is usually performed by analyzing this velocity signal at various points along the major arterial trunks. The changes in shape of this velocity profile can be quantitated using measurements like "pulsatility index"[J3,K17,K20], but it is considered less useful for the assessment of the distal segments of the arterial tree[H8].
Determination of limb systolic blood pressure is a simple and useful application of the Doppler technique in screening for peripheral arterial occlusive disease. The best technique is to measure the ankle systolic blood pressure and relate it to the arm pressure as an ANKLE-BRACHIAL PRESSURE INDEX (ABI)[B33]. Normally, the ankle pressure is equal to or higher than that for an arm: ABI ≥ 1.0[S49]. In arterial occlusive disease the ankle pressure will be below that of the arm by an amount proportional to the degree of circulatory impairment. Patients with claudication normally have an ankle pressure index below 0.6. Patients with rest pain or gangrene usually have an ABI below 0.2, with the absolute ankle pressure often less than 50 mm Hg[H29].
Systolic blood pressure determination is also useful to assess the functional impairment of the circulation during stress of the circulation, or limb hyperemia. The best method for functional assessment of arterial occlusive disease of the lower extremities is to measure the ankle pressure response to treadmill exercise[B28,C6,F1,K8,S49].

3.5. B-SCAN ULTRASOUND

This technique graphically records cross-sectional anatomy on a storage oscilloscope by detecting reflected echos of ultrasound at various tissue interfaces within the range of the instrument[B28]. A combination of real-time B-scan and Doppler imaging (Duplex scanning) provides excellent morphologic and hemodynamic assessment of the arteries[G21,G24]. The popliteal artery can be

imaged with the patient turned in the prone position, but the tibial arteries have proved too small to be studied accurately with this method[O5].

3.6. MICROCIRCULATORY STUDIES

3.6.1. Transcutaneous pO_2 measurement

In this technique the partial pressure of tissue oxygen ($PtcO_2$ or $tcPO_2$) is measured transcutaneously to a skin depth of ca. 2 mm, via a special electrode applied to the skin. Following exercise, the $PtcO_2$ in normal people slowly declines to below resting values, while in patients with vascular disease it undergoes a sharp decline to below the level of the resting value. This decline produces a characteristic tracing that can be used to identify patients with vascular disease. It has also been used as an indicator of sufficient tissue perfusion, which is necessary for successful healing after below-knee amputation[B29,K27,S49].
This method actually provides more information about the microcirculation in an extremity than about the macrocirculation, and the value of this method in peripheral vascular disease still remains to be evaluated more completely.

3.6.2. Capillary microscopy

Capillary blood flow and capillary morphology were already assessed by capillary microscopy in previous centuries, and nowadays this method is used in combination with modern video and computer registration techniques. Once again, this method is especially useful in studying patients with microvascular disturbances, eg. vasospastic disorders of the hand. It has also been applied in the study of occlusive arterial disease of the lower extremities and an excellent account of this method is given in the thesis by Jacobs[J9].

3.6.3. Laser-Doppler

This is a noninvasive method for studying and evaluating the cutaneous blood flow by utilizing the Doppler shift of laser light backscattered from moving red blood cells in the cutaneous microcirculation[N7,S49].

3.7. RADIOISOTOPE STUDIES

After the injection of a small amount of radioisotope, blood flow, depot washout, or particle distribution is assessed by means of an external scintillation detector. The three techniques used in peripheral vascular disease are:

a. Radionuclide angiography, using Technetium labeled human serum albumin and red blood cells[R17].
b. Xenon-133 washout determination of arterial blood flow, mainly employed in the investigation of arterial disease and compartment compression syndromes[L25].
c. Radioactive microsphere assessment of regional blood flow and arteriovenous shunting[S45], used particularly in patients with advanced arterial occlusive disease and ischemic ulceration and in assessing results of lumbar sympathectomy.

3.8. PLAIN X-RAY FILM

Routine plain X-ray films may be an aid in diagnosing vascular disease, because of the presence of patchy calcifications of atheromas. Radiologically apparent calcified walls may alert the radiologist to the presence of serious vascular stenotic lesions or aneurysms[S35]. At present, it is good surgical practice to obtain plain X-rays of the lower extremity prior to femorocrural bypass operation, because extensive mural calcification can be a predictor of non-graftability.

3.9. COMPUTED TOMOGRAPHY (CT)

Computerized axial tomography is helpful in evaluating aortic aneurysms, but has little use in the evaluation of peripheral vascular disease[A9,G24,S35].

3.10. MAGNETIC RESONANCE ANGIOGRAPHY (MRA)

MRA is a generic term describing numerous imaging techniques that visualize vascular lumen morphology through MR signal changes resulting from time-of-flight phenomena and/or phase shifts caused by motion along imaging gradients. Because of the absence of physiologic motion in the extremities, they are ideal areas for vascular studies. This technique has been used to identify normal and occluded trifurcation vessels, although stenotic lesions are not portrayed as consistently[A3,G24]. The use of gadolinium contrast medium does improve MRA of lower extremity arteries, but MRA does not yet have the spatial resolution, selectivity or dynamic character of conventional angiography, and it is expensive[L27]. It is felt by most authors that the present role of MRA is that of an adjunct to conventional MR imaging[E1,H31]. However, one recent paper does decribe a greater sensitivity of MRA for detecting distal runoff vessels than CA in patients with peripheral arterial occlusive disease[O8]. The authors suggest that this may even improve the overall rate of limb salvage

among such patients. In the future, MRA and the new deveopment of cine-MR will probably play a greater role in the diagnosis of lower extremity disease-[C13,G24,M19].

3.11. DIRECT INTRAARTERIAL PRESSURE RECORDING

Although this chapter is primarily concerned with noninvasive measurements, direct femoral artery pressures are often used by surgeons to assess the hemodynamic status of the inflow to the leg[S48]. The significance of this technique, with measurements obtained before and after injection of papaverine chloride for patients who are candidates for surgery, has been described elsewhere[B13]. Most patients in limb salvage situations have severe infrainguinal or multisegmental disease, which makes knowledge of the contribution of suprainguinal disease to the problem essential to proper operative planning[F19].

3.12. THIS STUDY

In this study, the ankle-brachial index (ABI) at rest was used for patient classification.

4. CONVENTIONAL ARTERIOGRAPHY

This chapter presents a brief review of standard arteriographic technique, including history, equipment, puncture and catheterization techniques, injection techniques and complications. Special attention will also be paid to intraoperative arteriography and film interpretation, including pitfalls.

Angiography is a roentgenologic procedure that permits visualization of the internal anatomy of the heart and blood vessels by means of the intravascular injection of radiopaque contrast material. An arteriogram is the result of flowing blood in arteries being displaced by radiopaque material during roentgenographic exposure of the area where the artery lies. The following conditions during arteriography must be met: the contrast agent must be in the artery of interest, the roentgenogram must be of the area of interest, and there must be some form of synchronization of these events[M26]. In this study the term angiography refers solely to arteriography.

The arteriographic evaluation of patients with atherosclerosis involving the abdominal aorta and peripheral vessels is one of the most frequently requested special procedures. Arteriography is indicated for definition of the anatomy, evaluation of the severity and progression of the disease, assessment of the distal circulation, and the search for unsuspected lesions, such as thromboemboli and aneurysms[K25,K26,M20]. Unfortunately, the same disease that needs evaluation, by its involvement of the vessels we are attempting to catheterize, contributes to making the examination difficult.

The standard approaches to performing arteriography of the lower extremity vessels can be found in various standard textbooks[B27,K25,R22,W3]. The most reliable methods of arteriography use a system that provides a series of X-ray films, each covering the entire area of interest, initiated by automatic injection of the contrast agent through a catheter or needle that has been positioned in the artery of interest.

The angiographer must select the best X-ray projection; decide how many films are to be obtained over what period; determine the proper contrast agent, injection rate, and volume; and position the needle or catheter appropiately.

4.1. HISTORICAL ASPECTS OF AORTO-ILIAC AND LOWER EXTREMITY ARTERIOGRAPHY

The first arteriogram was made by Haschek and Lindenthal[H32] in January of 1896, by injecting the brachial artery of an amputated hand with a chalk solution and utilizing Roentgen's newly found rays[R21] to satisfactorily display these structures on a photographic plate (exposure time 57 minutes). Two years later, Codman opacified the aorta and its branches with mercury salts[C32]. These early efforts all involved the use of cadavers.

The first intentional catheterisation of the living arterial tree was performed in 1912 by Bleichroder[B39], who inserted a catheter into the femoral artery with the idea of perfusing an antiseptic solution directly into the uterine arteries of a patient with sepsis. More than 10 years later, the arterial tree distal to an arteriotomy site was first visualized by Berberich[B38]. In 1924, the first femoral arteriogram via a femoral arteriotomy was performed by Brooks[B37] to determine the extent of occlusive disease of the lower extremity.

In the late 1920's, Dos Santos in Portugal discovered that accidental puncture of the major vessels of the abdomen carried a surprisingly low morbidity. Consequently, he used a percutaneous translumbar approach to inject 100% sodium iodide in order to radiologically visualize the aorta and its branches, heralding the beginning of translumbar aortography[S3,S4,V4]. Since this proved to be an extremely painful procedure, it was necessary to perform it under general anesthesia.

There was considerable early criticism of Dos Santos' work, because of some serious complications, including fatalities. In the meantime, Fariñas in Cuba surgically exposed the femoral artery and then inserted a rubber catheter through it into the aorta, followed by injection of contrast agent[F24]. Because of this work, he is considered to be the father of catheter arteriography[C21,W7].

In 1949, the next important development was described by Radner[R15], who became the first to utilize a guide wire to stiffen the catheter and make more accurate placement possible. In 1951, Peirce[P22] brought the cause of arteriography a step further by using a large bore (12 to 15 gauge) needle to percutaneously enter the femoral artery, and threading it through a polyethylene catheter. This eliminated the need to expose an artery and repair it after arteriography. Because of the limitations of this needle-catheter system, only straight catheters could be used.

However, by 1953 all the prerequisites for modern arteriography had been met: suitable types of intravascular catheters and wire guides as well as safe, water-soluble contrast agents. The classic paper written by Seldinger[S6] in 1953 finally described a percutaneous technique which used all these individually proven commodities. After an initially slow acceptance, Seldinger's catheterization technique is now frequently and routinely performed in modern radiology departments.

4.2. ARTERIOGRAPHIC PUNCTURE TECHNIQUES

The lower extremities can be studied by the femoral, translumbar, or axillary artery approach, using a needle or catheter technique for contrast medium injection. All three approaches allow both lower extremities to be examined at the same time, while a femoral needle approach allows only single arteriography of one extremity.

4.2.1. Femoral approach

1. Percutaneous Needle Puncture (PNP): a retrograde femoral artery puncture is generally performed, using a stainless steel needle (Seldinger type) or a Teflon or plastic-sheath needle[A5]. For the sake of convenience, most radiologists use the right femoral artery if the pulse is not significantly diminished. For selective arteriography of the lower leg and foot, an antegrade femoral artery puncture is used.
2. Seldinger Catheter technique: after retrograde femoral artery puncture, a 65cm 5 or 6 French (Fr) pigtail catheter is placed in the distal abdominal aorta for an anterior-posterior arteriogram of the lower extremities (aortic flush angiography).

4.2.2. Translumbar approach

With this method, called translumbar aortography (TLA), the abdominal aorta can be punctured at two levels: high TLA, at the lower border of the 12th thoracic vertebra, and low TLA at the lower border of 2nd lumbar vertebra-[D3,G1,K28]. The patient is placed in a prone position. The skin entry site is midway between the lowest border of the lowest rib and the iliac crest, approximately 10 cm to the left of the spinous processes of the lumbar vertabrae. The special 17 gauge thin-walled TLA needle, having a closed end and two side holes, is inserted at a 60 to 70 degree angle from the skin surface into the aortic lumen.
An improvement of this method, using a catheter-sheath needle to allow antegrade aortography, has been described in various papers[A4,C2,G6,G14,H11].

4.2.3. Axillary approach

Using the right or left axillary artery, a 5 French or 6 French pigtail catheter of 100 cm length can be placed at the aortic bifurcation.

4.3. CONTRAST INJECTION

Injections of contrast agent may be made by means of a handheld syringe or an automatic injector. The contrast agent should be injected at a rate equal to or slightly exceeding the blood flow rate in the vessel into which it is being injected. In an average-sized patient, a total contrast dose of 60 to 70 ml at a rate of 8 to 12 ml/sec provides the best bilateral lower extremity arteriograms via catheter or TLA technique. For a single arteriogram, 35 to 40 ml of contrast medium is injected at 6 to 8 ml/sec[K28].

The hemodynamic effect of intraarterial injection of contrast medium into various organs has been investigated both experimentally and clinically. One of the main effects is a fall in blood pressure, caused by vasodilation[B7,H25, L26,R22]. This hemodynamic side-effect has especially been observed in the group of high-osmolar ionic contrast media. It has been noted that the low-osmolar substances are better tolerated hemodynamically[W14], which is why the low-osmolar contrast medium meglumine sodium ioxaglate (Hexabrix®) is routinely used in our department.

4.4. VISUALIZED BLOOD VESSELS

Radiographs of the abdomen and pelvis visualize the abdominal aorta, common iliac, external iliac and internal iliac arteries. Radiographs of the thigh visualize the femoral and profunda femoris arteries. In the knee region the popliteal artery and its trifurcation are visualized. Films of the lower limb/ ankle show posterior tibial, anterior tibial and peroneal arteries. Oblique projections of the pelvis / upper thigh region are often also performed to demonstrate the bifurcations of iliac and femoral vessels adequately (Figure 4.1).

In the evaluation of obstructive lesions of the popliteal and runoff arteries (posterior tibial, anterior tibial and peroneal), the anterioposterior view with slight internal rotation of the feet generally suffices. During examinations of both legs, the legs are taped together to reduce the area of very low X-ray absorption.

With a single bolus injection of contrast medium, the vasculature from aortic bifurcation to foot can be adequately shown in more than 80% of patients. In some patients, however, up to three injections with repeat film series may be necessary to adequately show vessels beyond the popliteal trifurcation[A12].

4.5. FILMING TECHNIQUE

Prior to making film exposures, the region of interest is defined by fluoroscopy with the aid of an image intensifier. The image intensifier in our department

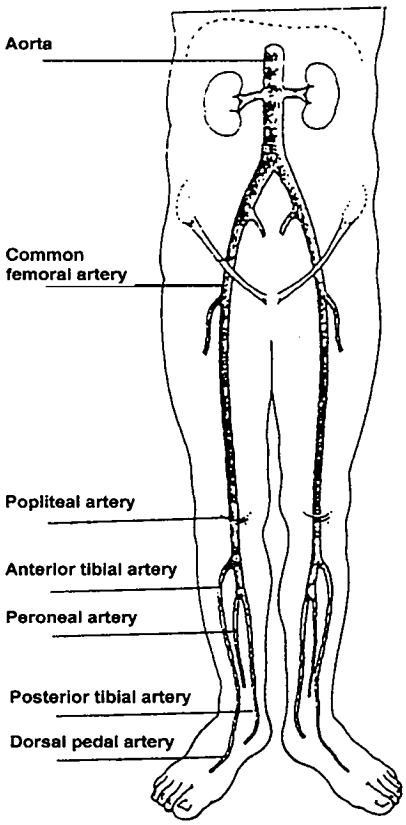

FIGURE 4.1.
Arteries in the abdomen, iliac region and legs. Note specifically the arteries of the lower leg which were observed in this study: popliteal artery, posterior tibial artery, anterior tibial artery and peroneal artery.

has three variable fields-of-view, viz. 6 inch (15 cm), 10 inch (25 cm), and 14 inch (35 cm). In CA, the 14 inch field-of-view is always used. In order to define proper exposure settings and correct positioning of the patient, a preliminary stepping run is made with test exposures before contrast medium is injected. Several rapid-filming devices are currently available. The purpose of each is to provide films or cassettes for multiple, sequential roentgenograms of any body area. For all conventional angiograms, a Puck filmchanger[A13] mounted on a three-dimensional C-arm is used, allowing angle angiography without turning the patient. The cut-film changer uses a 35 x 35 cm film, with a maximum loading capacity of 20 films and a changing rate of up to three films per second. A simple magazine allows daylight loading and unloading.

Ideally, the entire vascular system from the abdominal aorta to the toes should be angiographically displayed with a single bolus injection of contrast medium. This visualization can be accomplished by using the film changer and moving the patient cranially at the same rate at which the contrast medium progresses in the vascular system ("stepping table technique")[A12]. Alternatively, this visualization can be accomplished by moving the C-arm with X-ray tube and film changer caudally over the patient ("stepping X-ray tube technique"). A motorized C-arm moves the X-ray tube and film changer in a preset sequence, so that first the pelvis, then the thighs, knees, lower leg, ankle and foot are positioned over the film changer. The film changer is programmed to take films when the table stops and to pause while the C-arm moves. If the sequence is properly set, the contrast agent may be traced all the way to the feet with a single injection.

With this stepping system, between four and five filming positions are programmed. The program is controlled by a punch-card system, which lends itself to integration of injector, exposure sequence, and table-top or C-arm motion for long-leg angiography.

4.6. TECHNICAL CONSIDERATIONS; Calculation of the Filming Delay and Duration of Filming

The stepping technique seems satisfactory, but the main technical difficulty is estimation of the speed of the blood flow, which may vary dramatically with the disease process. Furthermore, even in one patient there may be a considerable difference between the speed of blood flow through one leg as compared with the other[A13,B27]. If a section of the vascular tree is inadequately visualized, a repeat injection with a stationary or abbreviated run is necessary to correct errors in timing[A8,A13,B27].

The speed of blood flow can be estimated by fluoroscopic observation of a small contrast bolus injected into the abdominal aorta or femoral artery, timing its arrival with a stopwatch at popliteal artery level[K25,M26]. This fluoroscopic timing method is not widely and routinely used, because experience has shown that a small contrast bolus is poorly visualized with fluoroscopy. The duration of filming for the evaluation of lower extremities for peripheral vascular disease should generally be extended for at least 25 seconds after the contrast injection is begun. In some patients with severe atherosclerosis at least 30 seconds delay is necessary to permit opacification of the distal vessels[K25].

4.7. TECHNIQUES FOR IMPROVED DISTAL ARTERIAL OPACIFICATION

In about 25% of all femoral arteriograms the popliteal and, particularly, the distal runoff arteries (tibial and peroneal) are inadequately visualized for anatomic delineation[K23]. The poor contrast visualization results from delayed or diminished blood flow to the lower leg. There are several methods for improving visualization of the distal vessels below the knee[D13]. Most of these methods lead to better opacification of vessels by inducing vasodilation and augmenting distal blood flow. This generally implies increasing the rate of contrast injection by 25 to 50% and increasing the total contrast volume by approximately 25%[K25,S5].

The various techniques for enhancement of distal arterial opacification include:

1. Injection of contrast medium at a rate and volume which cause vasodilation[L22,S38,S39].
2. Intraarterial injection of vasodilators e.g tolazoline[C26,F23,K15], papaverine, lidocaine, reserpine. Oral use has no value in atherosclerotic disease[C31].

3. Reactive hyperemia[C26,I2,K23]. This seems one of the best and most consistent methods for improving visualization of the distal small vessels.
4. Reflex hyperemia[K15]. Warming of the opposite extremity can induce a 100% increase in blood flow in the extremity under examination.
5. Antegrade arteriography.
6. Film subtraction (conventional).
7. Dry limb arteriography: with the aid of a double lumen balloon catheter, the artery is occluded to arrest circulation distal to the balloon[C25,C27].
8. Epidural anesthesia[S14].
9. Intraarterial DSA[K25].

4.8. COMPLICATIONS OF ARTERIOGRAPHY

The percutaneous needle puncture or catheterization method of aortography or arteriography has small but definite risks. Complications associated with angiography must,however, be evaluated in light of the patient's overall condition. It seems that many major complications observed in patients undergoing diagnostic angiography are related to the severity of their underlying illnesses and cannot be avoided despite careful angiographic technique[C33].
Angiographic complications can primarily be divided into:
1. Contrast medium reactions
2. Renal complications
3. Complications related to catheterization

4.8.1. Contrast Medium Reactions

The worldwide incidence of adverse reactions to intravascular contrast medium is about 5% for patients undergoing arteriography, venography, urography or cholangiography, whereby 0.006% of reactions proving fatal[S16]. In patients with a past history of contrast reaction, the incidence of another such reaction is three times greater than that of the normal population[S18]. Patients with asthma also form a high risk group, who may develop bronchospasms after exposure to contrast medium[S18]. Vaso-vagal reaction ("syncope"), as a result of vagal overstimulation, is another adverse effect caused by intravascular contrast medium which needs immediate and appropiate action[S19].

4.8.2. Renal complications

Renal failure induced by contrast medium is defined as an increase in serum creatinine level by at least 20% in the post-angiography period[C33]. Predisposing factors to contrast-induced renal complications include pre-existing renal diseases, marginal or abnormal renal function, diabetes mellitus, myeloma, hyperuricemia, proteinuria, dehydration, and advanced age (>55 years).[B40,C33]

Additional factors are the volume load of contrast medium used and additional medication (e.g. antibiotics). This means that patients undergoing multiple contrast studies (e.g CT) within a short time are also at risk. In most patients, contrast-induced renal failure is transient, with recovery occurring over several days or weeks, while in more severe cases dialysis may be required.
The use of IADSA instead of CA in patients who belong to a high-risk group could be very beneficiary, because the contrast medium volume and iodine concentration required are reduced by ca. 50% relative to those in CA.

4.8.3. Complications related to catheterization

In a survey of a large number of procedures (118,591 examinations), the overall complication rates for percutaneous arteriography were as follows: femoral, 1.73%; axillary, 3.29%; translumbar, 2.89%[H16]. The main types of puncture site complications were hematoma, occlusion or thrombus (caused by arterial dissection), false aneurysm formation, or an arteriovenous fistula. Fatal complications ranged between 0.3% and 0.9% In another review of 1762 percutaneous axillary artery catheterizations, the overall incidence of complications was 2.1%, with only 0.5% serious complications[M30].

4.8.3.1. Complications of Translumbar Aortography

Serious complications related to TLA are infrequent[P16,R3] and have been reported as ranging from 0.05%[S25] to 0.58% of cases[H16]. Complications observed with this technique include contrast extravasation, intramural contrast injection, dissection, and inadvertent cannulation of aortic branches[K30]. Retroperitoneal hemorrhage, which is usually minor, occurs in all patients and generally causes no clinical concern[A14,H9].
The majority of such complications has occurred with the older method of direct puncture technique with injection of contrast medium through a metal needle. A modification of TLA with a teflon sheath needle or catheter needle, introduced by Amplatz in 1963[A4], seems to make this procedure even safer [D4,H9,M10,R9].
Generally, the Seldinger technique for transfemoral aortic catheterization[S6] is now the method of choice for arteriography of aorto-iliac and peripheral vessels. However, narrowing or occlusion of the iliac or femoral arteries may sometimes make the transfemoral approach difficult, hazardous or even impossible. In those cases TLA is indicated primarily, or secondarily when a transfemoral catheterization has failed.

4.8.3.2. Complications of femoral approach

The most frequent complications of the femoral approach to catheterization or needle puncture are arterial dissection caused by the guide wire or catheter (needle) trauma with subintimal injection of contrast medium and hematoma at the puncture site. In a study of 1,217 examinations, the frequency of com-

plications at the puncture site which required surgery was remarkably low (0.14%)[S27].
As a late complication, it has been suggested that transfemoral arteriography predisposes to postoperative groin infection, but a definite relationship between the two has not been substantiated[L5].

4.9. INTRAOPERATIVE ARTERIOGRAPHY

Intraoperative arteriography has primarily been used to evaluate the adequacy of a vascular procedure in the extremities, such as embolectomy or a bypass graft. Sometimes it is done to delineate an area of vascular injury in the course of an emergency operation[M26]. It does require several modifications of conventional arteriographic techniques. The information must usually be obtained from a single exposure with suboptimal equipment.
In recent years, emphasis has been placed on performing intraoperative prebypass arteriography in order to extend operability in patients in whom preoperative arteriography was inadequate[F17,R19,S40]. Routine CA was found to be deficient in adequately visualizing the distal circulation in limb salvage patients, even with pharmacological manipulation or reactive hyperemia. In one study of 78 patients, only 14% of the preoperative CA examinations resulted in adequate visualization of tibial and pedal vessels. This was greatly improved by intraoperative arteriography, which showed adequate runoff in 84 % of the non-visualized cases[P18]. This extended reconstructability to many patients who would otherwise have undergone primary amputation.
However, a high-quality arteriogram should be obtained preoperatively in a properly equipped angiographic suite, for an optimal planning of the surgical procedure.

4.10. PITFALLS IN FILM INTERPRETATION IN ARTERIOGRAPHY OF THE LOWER LEG

During the interpretation of films obtained by arteriography, the angiographer may encounter two main problems:
1. problems relating to Roentgenography
2. problems relating to blood flow.

4.10.1. Problems relating to Roentgenography

Especially in CA, a vessel's outline may be obscured by overlying dense bone ("bone superposition"), see Figure 4.2.
The penetration of roentgen rays may be increased by raising the kilovoltage, producing an image with less contrast in which the relative opacity of the

overlapping structure is decreased without unacceptably compromising the opacity of the contrast medium of the vessel[M26]. This high-kilovoltage, low-contrast technique allows one to see vessels "through" the bony cortex in CA, but does require a repeat examination.
Subtraction techniques are not routinely applied in CA when the films are obtained with the moving-table or moving-tube technique, because no film of the tibial region without contrast material has been obtained for use as a mask in the subtraction procedure. This problem does not apply to IADSA, because instantaneous subtraction is performed electronically during the arteriographic procedure.
Stenoses may be obscured by superposition of vessels, particularly at arterial bifurcations. This requires oblique projections for better definition of the stenosis, and a technique for biplane arteriography of the lower extremities has been described[C15].
Another, less common technical factor which causes problems in film interpretation is leg movement during the examination. In CA this is caused by the painful, hot feeling of the flow of contrast medium, and it often results in incomplete visualization of the leg on the film. In IADSA, a slight movement of the leg can cause subtraction artefacts in the image, thereby compromising optimal interpretation of the artery on the hard-copy (film).

4.10.2. Problems relating to blood flow

Ideally, the entire vascular system from abdominal aorta to the toes should be demonstrated with a single bolus injection of contrast medium. However, the blood flow may vary considerably in diseased legs, even in one patient, which causes failure to demonstrate adequately the circulation of injected contrast medium as it flows from the aorta towards the ankles[B27], see Figure 4.3.
These non-filled vessels may not be visualized either because the volume of contrast medium is too small or because the film is exposed too soon after injection ("low contrast"). What appears to be a sharply circumscribed proximal point of occlusion may be merely the head of the slowly advancing column of contrast ("pseudo-occlusion" or "pseudo-stenosis")[K25,M26]. However, if at any given level of the arterial tree distal to the proximal level of occlusion, small arteries are demonstrated to be filled in continuity with proximal collateral branches, and if filling of the main-stem artery cannot be demonstrated at that level, then the main-stem artery at that level has an occlusion[W1].
In this event, one should normally alter the filming rate according to the observed flow and reexamine the nonvisualized circulation. Even then a certain amount of chance timing may still exist, and an adequate time delay for an interpretable examination is not guaranteed. In the worst cases an examination may have to be repeated a third time, with the consequence of additional load of contrast medium and radiation exposure. If knowing the exact extent of

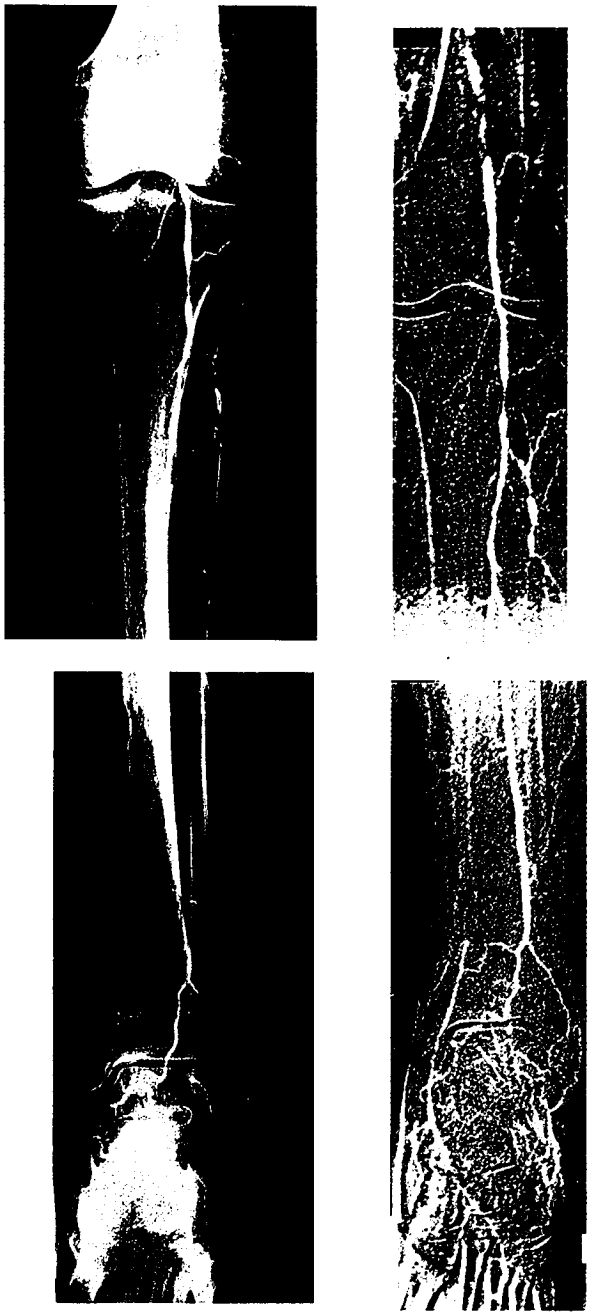

FIGURE 4.2.
In this left leg angiogram the peroneal artery was judged non-interpretable with CA due to bone superposition (a). With IADSA the peroneal artery was judged interpretable (b).

FIGURE 4.3.
TLA: presence of significant stenoses in proximal common iliac arteries (a) caused delayed difference in blood flow between right and left leg. All lower leg arteries except popliteal (b) were judged non-interpretable by CA (c). With IADSA the lower leg arteries were all judged interpretable (d).

occlusion is critical in planning the most appropiate revascularization procedure, one can also plan another angiographic run with prolonged serial filming centered over the critical area.
Another pitfall related to blood flow is early venous filling. The veins draining an extremity are usually seen on delayed films following arterial injection, especially if an occlusion is present[M26]. This should not be confused with the presence of an arteriovenous fistula, which itself is usually visualized, and causes only the affected vein and its proximal drainage to be filled with contrast medium.

5. DIGITAL SUBTRACTION ANGIOGRAPHY

Ever since the discovery of X-rays by Roentgen in 1895[R21], medical radiography has been performed with film as the image receptor. Recent advances in real-time digital video processing have led to a practical method called digital subtraction angiography (DSA), which detects small differences in the concentrations of the iodinated contrast material injected[M31].
In order to provide the reader with a basic understanding of DSA, a review is given of the development of the subtraction technique, the different types of digital subtraction, technical aspects of DSA and the components of a DSA system. As the implementation of photo-electronic digital radiology is resulting in new concepts and approaches to diagnostic radiology, special attention is also paid to the quality of spatial and contrast resolution, and possibilities for image manipulation and storage offered by this technique. The differences between intravenous DSA (IVDSA) and intraarterial DSA (IADSA) are highlighted, in combination with a description of special applications.

5.1. DEFINITION; WHAT IS DSA?

An accurate, concise description of DSA has been given by workers from the University of Wisconsin[K13], one of the pioneering institutions in the development of this technique:
"DSA is a computer method for logarithmically enhancing and manipulating the signal from a contrast agent that is administered in a blood vessel. The preinjection mask image is subtracted from each of the post injection images and the subtraction images are displayed in real time on a monitor. The data are initially stored on disk and tape, which allows further processing. For archival purposes, the images are recorded on film".
Although the method was originally described with intravenous administration of contrast medium, the advantages of DSA with intraarterial injections have gradually become recognized[C16]. It will probably become the major future approach for viewing the peripheral vascular system[C17].

As the purpose of this thesis is to compare the interpretation of images acquired via two different technologies, it is also necessary to define an "image". An image is a two-dimensional distribution of monochrome, usually black and white, or multichrome, full-color brightnesses, which is capable of conveying information to the viewer[V1].
An analog image (as in conventional angiography) is constructed to represent as faithfully as possible the X-ray shadows cast from a patient, in which case an image may have a continuous brightness distribution, limited only by maximum and minimum values of brightness. These values may be distributed continuously in space, the only constraint being the boundary of the image field.
A digital image is represented by picture elements, also known as "pixels". In this approach brightness or density continues to represent the maximum or minimum values as the limiting restraints, but between these extreme values is established a set of discrete, well-defined brightness levels or shades of gray. As for spatial distribution, these gray values may be found only at discrete, well-defined spatial positions, called picture elements or pixels.
A modern computer is essentially a digital adding machine that can manipulate the digital information of each pixel stored in its memory[S41]. Computer manipulations that can be performed include: 1) image subtractions; 2) edge enhancements; 3) noise suppression through image averaging, or pixel-to-pixel difference gauging, and 4) histogram enhancements.

5.2. SUBTRACTION

5.2.1. Introduction

The technique of radiographic subtraction was first described in 1934 in the Dutch medical literature (with German and English summary) by Ziedses des Plantes[Z1] (see Figure 5.1). This was complemented by his article in a German medical journal in 1935, describing its application in cerebral angiography[Z2]. A further application of its use in angiocardiography was published in 1959 (with English summary[Z3].
The first English language paper on this subject did not appear until 28 years later[H35]. This paper commented that the technique provided an economical photographic method of reducing the confusion of overlapping bony structures in angiographic studies. A good review of radiographic subtraction was presented in English in 1970 by Ziedses des Plantes himself[Z4], describing the photographic procedure, but also elaborating on the development of electronic subtraction, first introduced in 1963[H6]. Further development of computerized fluoroscopy took place only in the late 1970's[K29]. DSA is part of the larger phenomenon known as digital radiology. For DSA, the televized fluoroscopic image is converted point-by-point to digital data. These data are then manipu-

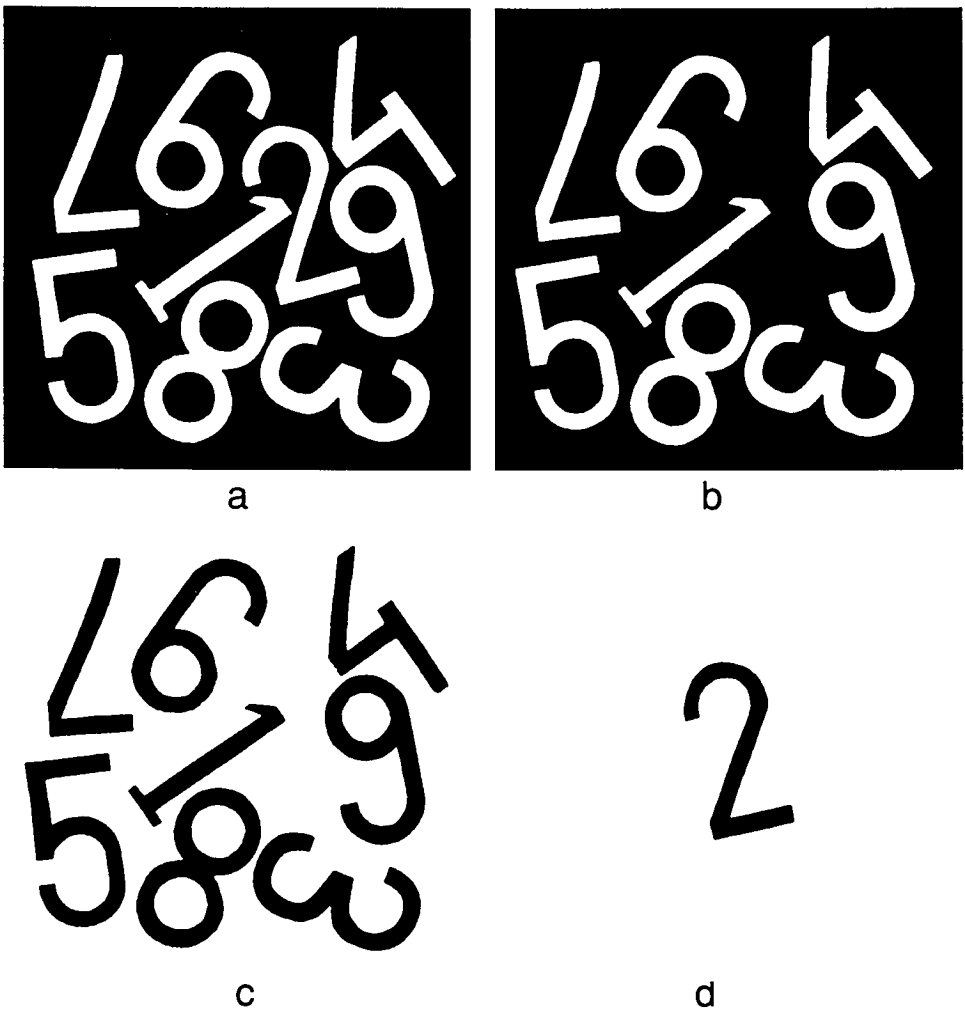

FIGURE 5.1
A simple example of conventional subtraction for use in radiology, first described by Ziedses des Plantes in 1934 [Z1] (reproduced with kind permission from the author). In DSA, the same process is performed digitally by the image processor (see Figure 5.2).
A X-ray of scattered metallic numbers.**B** X-ray as in Figure 5.1a after removal of number two. **C** Positive print of X-ray in Figure 5.1b (so-called "mask").**D** Reprint of X-ray in Figure 5.1a after masking it with the positive print in Figure 5.1c. This is the subtracted image.

lated in two operations[M7,K29,O3], of which the first is the process of image subtraction, while the second occurs after subtraction and entails expansion of the dynamic range of the subtracted image, which results in enhancement of the final image.
Subtraction can be used to visualize any difference between two radiographs. This may be the difference between an angiogram and an "empty" or "plain" radiograph, or the difference between two radiographs which are made during different phases of a movement, or even the difference between a hard radiograph made with a high kilovoltage and a soft radiograph made with a low kilovoltage. It is important that the object to be subtracted remains exactly in the same position during the procedure, as the slightest movement can impair the result of subtraction.

5.2.2. *Photographic procedure*

In an angiographic series of the photographic procedure the first film should be a plain X-ray picture, before any contrast medium is present in the vascular structures. The translucent positive print which is subsequently made from this plain radiograph is called the "mask". The mask and the most informative angiograms are subsequently superimposed on each other, and the observed density will be essentially uniform except where the mask and the radiograph differ, specifically where the contrast medium is present. The subtraction result is printed on a third film for final viewing. Altogether, considerable darkroom handling is necessary in order to obtain the final subtraction result. Another disadvantage of the film subtraction technique is that the angiographer is shooting blind in making the exposures, because he does not know when the contrast medium will arrive and disappear again; timing and duration of the exposure series may be inaccurate, and this applies especially to angiography of the lower limb in the presence of occlusive arterial disease.

5.2.3. *Electronic procedure*

The electronic procedure can be performed more quickly than the photographic procedure, and it is possible to change the degree to which the identical parts of the picture are cancelled out[M18,P10]. The success of image subtraction greatly depends on precise registration of the two images. Any small movement by the patient causes serious artefacts which are the more disturbing the more that contrast enhancement is applied. Therefore a so-called "postprocessing" mode is available in DSA equipment, which allows the radiologist to choose a new mask for optimal display as regards contrast filling of the vessel. Other obvious advantages are the instant availability of the images ("real-time imaging") and film cost reductions, because not every image acquired needs to be kept for archival purposes. The angiographer can choose a few images, representative of the pathology, and print these as hardcopies. In the near future

the archiving of medical images may become completely digital and even the use of hard copies may become obsolete. A disadvantage of the electronic procedure is the diminished spatial resolution provided by the video monitor image, as compared to the image acquired on conventional film.
As the precise physical and electronic aspects of DSA are beyond the scope of this thesis, the reader is referred to other sources for for further information regarding these factors and their influence on image quality[K18,N4,V6].

5.2.4. *Advantages of subtraction*

In general, the advantages of radiographic subtraction can be summarized as
1. providing image enhancement and,
2. improving and bringing out detail in areas hidden by overlying bone or poor contrast. These features may therefore save the investigation result if the density of contrast medium is insufficient to show a lesion[L24].

The two major additional advantages of DSA are the speed and obvious simplicity of computerized subtraction compared to standard film subtraction angiography.

5.2.5. *Types of digital subtraction*

Since the introduction of digital imaging techniques in radiology about 17 years ago with the arrival of computed tomography (CT) scanners[H36], a lot of research effort has been invested in finding digital alternatives (Digital Radiography) for the more conventional radiographic examinations[P15]. The image acquisition system and display system of a digital angiographic system is very similar to that of a computed tomography system. X-ray images are converted into an electric signal, digitized, processed, and displayed. The major difference between the two systems is that the x-ray recording medium in the digital system is an intensifier-television camera system, producing planar images, while CT employs a circular array of photodiodes, which produces a cross-sectional image. After having obtained their x-ray images, both systems display these pictures electronically on a video monitor. The images obtained with both systems have extremely high contrast resolution but lower spatial resolution when compared with the images obtained with standard x-ray film-screen systems. The contrast sensitivity of the digital subtraction system is approximately 1 per cent (O3).
In addition to this, previously unknown, sophisticated imaging procedures are being developed, also in the field of subtraction techniques. Subtraction can be performed with respect to physical variables other than time (temporal), such as energy or depth (tomography), each with its own characteristic properties. For the sake of clarity, a brief review is given of the various subtraction methods that have been studied for DSA applications, categorized according to the variables exploited in the subtraction process (time, energy or depth).

At the outset, one can distinguish "first-order" and "second-order" subtraction techniques[R5]. First-order techniques are those in which only one physical variable is used in forming the final difference image. Second-order techniques are those in which the final image is the result of a double subtraction: subtraction is first performed with respect to one variable, after which the difference between two of the first-order subtractions is used to obtain the final result.

First-order subtraction methods include:

- according to time:

1. Temporal subtraction (conventional DSA)[K18]: uses a mask, as in manual subtraction, which is subtracted from the images containing contrast medium acquired at a different time during the same run. The mask, ideally devoid of contrast medium, is usually made at the start of the run, but may be made at the end. More sophisticated methods have been developed, still using time as the physical variable, i.e. integrated masking, matched filtering, and recursive filtering. The major difference between the conventional DSA and these three newer methods lies in the number of images used to form each difference image. In contrast to conventional DSA, these three modifications all use X-ray exposures that extend over 1 to 10 seconds.
2. Integrated masking[E2,M21,R5]: in this method, several images, ideally all devoid of contrast, are added to form an integrated mask image. Likewise, a set of contrast-medium filled images are summed, and the final result of the integrated mask is the difference between the two integrated sums. It is an interesting fact that the first published intravenous DSA image of a human carotid artery was obtained by integrating 32 contiguous television frames (1.07 second integration time) to form each image[K29].
3. Matched filtering[E3,L10,L12,R4,R6]: in this method, a set of images made during a DSA run is weighted and integrated following the run. The filter weights are computed retrospectively by placing a region-of-interest (ROI) cursor over the artery of interest and measuring the local contrast dilution curve. The motivation for matched filtering comes from signal processing theory: the highest signal-to-noise ratio possible (best use of x-ray exposure) is attained if the weights used match the shape of the signal of interest, i.e. the bolus curve.
4. Recursive filtering[K31,L10,N8]: in this method, the image formed during a particalar frame time is a combination of the image presently being read from the television camera and the image formed during the previous frame. Performance of a recursive filter closely resembles a very laggy or sticky television camera. Unlike the previous methods, recursive filtering is prospective: filter time constants are selected before the DSA run.

In summary, the actual differences between the various temporal subtraction methods lie in the respective mathematical processing schemes performed by

the computer. An extensive description of these schemes is beyond the scope of this thesis.

- *according to energy:*

5. Energy subtraction: has been used in CT scanners, and on an experimental basis in DSA. Pulses of high and low energy X-rays are produced and the images digitized and subtracted, producing residual images of the bone and vessels. This so-called dual-beam energy subtraction[B36] is therefore the first order difference between two images acquired using two different x-ray spectra, but within a timespan considered insignificant relative to the phenomen under study. This method can be used to suppress the image contrast from a single material such as soft tissue but contrast from all other materials remains, including that from iodine and bone. Hence, this method is not particularly helpful in displaying vessels without overlying bone, but may be useful in the abdomen, since the pulses are close in time and diminish motion artefacts.

- according to depth:

6. Tomographic imaging[S44]: isolation of depth can be achieved with digital fluorographic systems. In addition, the production of multiple tomofluorographic planes from a single set of projection data, called tomosynthesis, has been reported[M25].

Second-order subtraction methods include:

7. Tomographic DSA[K9,K12,L10,N6,V2]: by combining the above-mentioned tomofluorographic method with those of DSA, specifically temporal filtering DSA, one can benefit from the advantages of both methods. The tomographic motion "isolates" only those contrast-filled vessels which lie within the desired plane, blurring out all others. In the future, three dimensional display may add to the utility of this method. It is thought that tomographic DSA, although an approximate tomographic process, will be more successful for vascular imaging than longitudinal tomography alone, because most of the nonarterial image contrast will have been removed by the filtering (subtraction) process. Very little has been published about another method, using the stereoscopic technique with DSA[T3].
8. Hybrid subtraction[B35,E4,F3,F6,G16,L10,L17,M21,R7]: uses energy-subtracted images as a sequence for temporal subtraction action and is able to remove both bone images and motion artefacts. The major limitation of hybrid subtraction relative to temporal subtraction DSA is its degraded iodine signal-to-noise ratio (SNR), which is a factor 2.5 to 3.0 smaller. This loss can

be compensated for by employing special temporal filtering techniques, as described bove[R7].

The major question with regard to hybrid subtraction is that of its applicability. The use of this technique will mainly be dictated by the failure rate of temporal subtraction DSA and by the fraction of these failures which is due to soft-tissue motion artefacts.

5.3. TECHNICAL ASPECTS OF DSA

5.3.1. Types of equipment

Two different types of major DSA equipment[H5,J7] are available at present: 1) the integrated system and 2) the add-on system.

1. Integrated systems are produced by the major X-ray equipment manufacturers and are designed to produce the best images possible. One reason given for not mixing equipment is the need for optimization of all links in the imaging chain. For example, a 5-year old image intensifier may not meet the specifications of a new cesium-iodide image-intensifier. Another reason is that synchronization of the DSA equipment and the x-ray generators is complicated, and incompatabilities may exist between different manufacturers' generators. Integrated systems which are more expensive than add-on systems are either continuous or pulsed systems.
   The pulsed system is preferred because it achieves a high dose rate per image without giving a high dose rate to the patient. The high dose rate per pulse means that it is seldom necessary to integrate images by adding pulses together, and motion artefacts are usually avoided. The pulse mode consists of very short, intense x-ray bursts similar to those of routine angiography, which are subsequently read out by the television camera[O3]. The x-ray burst, with a very heavy photon flux, saturates the image intensifier and this produces a very intense light output to the television camera. At this point, the television camera has been turned off except for the target, which accepts this light image and retains it as an electronic charge. The scanning beam for readout is then turned on, and the target is read out.
2. Add-on systems take the television signal from a fluoroscopic system and digitize it at 3-25 frames/second, working in a continuous mode. The continuous fluoro mode uses low-dose (5mA to 20mA per exposure) images, but does require integration of up to 20 to 30 images to produce a satisfactory, non-photon limited image. The advantage of such a system is that no modification of the existing image intensifier-television camera system is needed. It can therefore be added to an existing angiographic apparatus[C5]. However, as both the x-ray and the television camera are on

continuously, and multiple fields are integrated to form one x-ray image both for the mask and the subtraction image, the resolution of these images is often poor and the images appear granular because of a poor signal-to-noise ratio. This applies especially to intravenous examinations. An advantage is that add-on systems are cheaper, and may be mobile, so that if the angiographic table in a screening room breaks down, the DSA equipment can be moved to another room.

With these add-on systems it is also possible to use DSA in i) portable systems and ii) biplane exposure modes.

i. Portable DSA.
This mode of angiography is especially beneficial in the setting of an emergency room for trauma, in an intensive care unit with critically ill and physically unstable patients encumbered by a host of monitoring equipment, and in an operating theatre to control vascular procedures. One paper mentioned a significant decrease in time interval from arrival in the emergency room to arteriogram completion in a number of intraarterial studies[K21].

ii. Biplane DSA.
In another paper[P14] a prototype add-on system is described that is capable of producing digitized video-fluoroscopic images simultaneously from both anterior and lateral imaging chains of a conventional biplane system. This should improve the accuracy of cardio-ventricular function studies and reduce the need for additional views and repeated injections of contrast medium.

Only one paper[B31] has described an evaluation of ten integrated DSA-systems and five DSA units used as add-on systems in multi-purpose x-ray equipment. The performance of these add-on systems was found to be significantly lower compared to top of the line integrated DSA equipment. The paper also stressed the significance of periodical measurements of contrast detectability and spatial resolution, in order to recognize at an early stage any changes in image quality.

5.3.2. Components of a DSA System

The equipment used in modern digital subtraction angiography is a combination of x-ray equipment and high-speed image-processing equipment[H5,K32,L10, O1,O2,O3,O7], with the following individual components (Figure 5.2):

1. X-ray generator,
2. X-ray tube,
3. Image Intensifier,
4. Television system,
5. Amplifier and Analog-Digital Converter,

6. Image Processor,
7. Image Acquisition Console with display monitor

1. X-ray Generator. The necessary conditions are as follows. i.) The x-ray generator must be capable of producing high-flux short-exposure images to reduce motion artefacts. ii.) The x-ray output must be constant from one exposure to the next, so that perfect-density subtraction is obtained from sequential images. This means that the generator must have a consistent on and off pulse as well as a fast rise and flat plateau. Any constant potential generator and almost any three-phase generator can satisfy these requirements. iii.) Another desirable feature is the ability to rapidly switch KvP and mAs, so that dual energy subtraction can be performed.
2. X-ray Tube. A high heat capacity tube is necessary so that multiple high-intensity exposures can be made. The requirement for a satisfactory image in DSA is that an average dose to the image intensifier of 1 millirad (mR) per exposure must be used to obtain a satisfactory signal-to-noise ratio (SNR) in the final subtracted image. Special x-ray tube collimation[G12] and x-ray beam filtration[K5] are required in DSA systems because of the limited dynamic range of the television camera and the necessity of having a uniform x-ray beam exposure to the image intensifier. This limitation is most evident in final subtraction images as the so-called *saturation artifact*, in those areas of an image where the lowest x-ray attenuation has occurred through patient anatomy.
3. Image Intensifier. The image intensifier is the x-ray-detector in the DSA image recording system. The modern cesium-iodide image intensifier is one of the strongest links in the DSA image chain, but the characteristics of these devices are somewhat different from those of standard fluorographic intensifiers. For DSA applications, the image intensifier must operate at a 1-2 mR per image exposure rate without loss of contrast or resolution. This is higher than for conventional fluoroscopy.[H5] The x-ray pattern impinges on the input phosphor of the image intensifier and is converted to a light pattern at the output phosphor. This light image is conveyed to the videocamera by tandem lenses or fibreoptic coupling. Images are obtained at varying rates, generally 1 to 3 frames per second, but can go up to 30 frames per second. It is desirable to have a large-field image-intensifier, 36 to 40cm in diameter, so that entire anatomical regions, e.g. chest, abdomen, or both lower extremities can be accomodated in one field[L10]. A larger image intensifier will decrease the spatial resolution of the final image, because the 512 x 512 matrix has to encompass a larger image input area. Although this can be compensated for by incorporating a 1024 x 1024 matrix, this only results in modest improvement in resolution[G8].
4. Television System. The TV system serves to convert the optical image of the image intensifier to an electronic signal that can be digitized. A variable aperture iris is interposed between the output of the image intensifier and the input of the television camera. This iris is set so that the amount of light produced by a 1-mR exposure to the intensifier completely fills the dynamic range of the

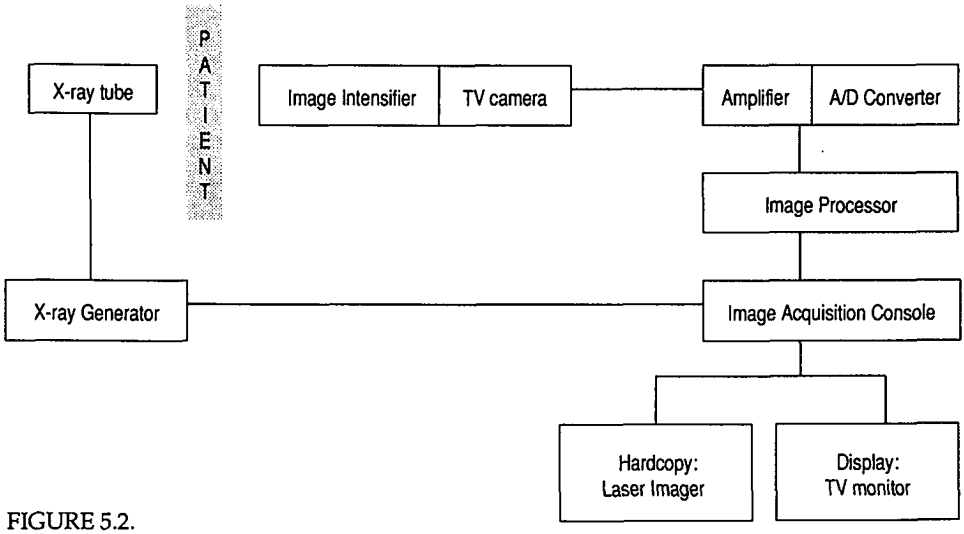

FIGURE 5.2.
Schematic drawing of a DSA system

television system. Because of the exponential attenuation of x-rays in the patient's body, most DSA systems provide some form of logarithmic processing of the video signal to compensate for varying tissue thickness[K10]. Concepts of noise and signal-to-noise ratio in TV systems need special consideration, as noise is perhaps the single most important limitation to successful digital fluorographic imaging. *Noise*, in a very broad sense, can be regarded as any structures or characteristics of an image that interfere with the observer's interpretation of it[K18]. In a DSA system, it can be caused by a second electrical signal (interference), which originates primarily from the TV camera, by some physical process such as the quantum noise which originates from a limitation in the number of x-rays per image, and from the digitization noise which reflects the uncertainty associated with quantizing the video signal into a finite number of digital levels. *Signal-to-noise ratio* (SNR) is the ratio of the signal voltage to the noise voltage (100:1, 1000:1, etc.). The SNR of a standard radiographic system is roughly 100:1, while the standard fluoroscopic system raises this to 200:1. These systems have poor low-contrast detectability (low-contrast sensitivity). CT has an SNR of 2000:1 and, like DSA, has high contrast sensitivity. The older method of interlaced readout (scanning) of the videocamera target has been mostly superseded by the use of pulsed-sequential imaging, i.e. sequential readout after a short pulsed radiation exposure[L10]. This has stimulated the development of new video cameras with SNRs in excess of 1000:1, mainly of the plumbicon type[K10]. The disadvantages of the Isocon camera systems are: poor SNR, inefficient optical coupling and sensitivity to scattered radiation, although diagnostic images have been obtained with this system using lower levels of radiation and lower doses of contrast material[B4].

5. Analog-to-Digital (A-D) Converter. The television signal, which is normally 1 millivolt, is amplified to 5 millivolts to enter the analog-to-digital converter. This amplifier can be either linear or logarithmic. X-ray attenuation within the body is mainly logarithmic, and a logarithmic amplifier will help correct for the uneven attenuation of the x-rays as they pass through the patient. After amplification, the image must be converted from its analog form to a digital form. The analog image, which is a representation (or analog) of a fixed quantity by means of a physical variable, such as shades of gray in the radiographic film or the brightness of the image intensifier, must be converted to the digital form in which a discrete value, rather than a continuous variable, represents the x-rays exiting an object. This process of digitization is performed by an analog-to-digital converter (A/D converter), the efficiency of which can be defined by the rate of digitization (conversion time) and intensity resolution (depth of digitization). The A/D converter assigns specific discrete digital values to the output signals of the television camera. The rate of digitization is in microseconds for all systems. The depth of digitization (exactness of the assigned value) is important because it is related to the number of shades of gray that can be displayed; the greater the depth of digitization, the larger the number of shades of gray which becomes available for the final image[H5]. Commercially available A/D converters provide 256 gray (2^8 or 8 bits) to 1,024 gray (2^{10} or 10 bits) levels. It is at this point, after digitization, that the image is entered into one of the two memories and the subtraction and enhancement are performed.

6. Image Processor. The image processor is the heart of the DSA because it is the part of the system where subtraction and image enhancement take place. A typical image processor and controller is based on a 16-bit microprocessor configuration using the Motorola 68000 chip. There are four functions: 1) x-ray-controller; 2) image acquisition device with command over the x-ray system; 3) control of the image memory in which images are stored and displayed; 4) analysis console for the images once they have been obtained[O3]. The matrix of the image processor influences the spatial resolution of the image. A matrix for our purpose can be defined as a rectangular array of *picture elements (pixels)*. The size of the matrix is defined by the number of pixels per side, and as the pixel is the smallest element in the picture, the spatial resolution of the system is defined by the pixel size. The most common matrix sizes in DSA are 256 x 256 and 512 x 512. This matrix size should also be considered relative to the field size of the image intensifier (see below).

7. Image Acquisition console. The console is the interface between the operator (radiologist) of the x-ray equipment and the image processor. The angiographer can use the function keys to perform the necessary functions, e.g. 1) run the unit in fluoro mode or in image acquisition mode; 2) set various image acquisition parameters; 3) set the mA, KvP, and iris controls; 4) initiate x-ray exposure; 5) display the final subtracted images on the video monitor.

The acquisition of images is mainly performed in the following three modes of temporal technique:

1. serial imaging, the most common mode, is used where image acquisition rates can be relatively low (from one to eight images per second). This mode allows for the greatest degree of flexibility in image acquisition and may be achieved with a short-pulsed x-ray exposure or by a longer exposure with variable addition and averaging of individual television frames;
2. continuous or dynamic mode uses an acquisition rate of 30 frames/sec with resultant shorter x-ray exposure times, decreased photon flux per image, and decreased resolution in comparison to the serial mode. This mode is used for rapidly changing dynamic processes, such as occur in cardiac imaging[J11]. In both modes described above, a precontrast image is used as the mask, followed by contrast injection;
3. time-interval-difference (TID) mode uses a rate of 30 frames/sec, subtraction being performed between each successive image (recursive filtering). A variation of this, delevoped for cardiac angiography, is gated interval difference (GID) imaging, whereby the time interval is equal to the cardiac period.

5.3.3. *Resolution*

The term resolution relates to both contrast and spatial definition[J2].
The *contrast* resolution of the system is related to its ability to discriminate between the subtracted contrast filled vessel and the "noise" of the system[B2]. This noise is produced by quantum mottle, scatter, image intensifier glare[S9,S10] electronic noise and digitization sampling errors[C12,K10]. It can be reduced by increasing the dose rate and by averaging the digitized image. Early investigations in the imaging capability of DSA indicated that this method exhibited a greater sensitivity to contrast media than conventional film subtraction units-[M1]. Assessment using 0.6-8mm diameter tubes filled with contrast medium containing 5 mg iodine/ml showed that the minimum diameter of tubes that could be detected varied between 1 and 4mm for different manufacturers and detection was affected by the radiation dose and the image intensifier diameter used[B31].
The *spatial* resolution of photographic film at its maximum is about 10 line pairs (lp) per millimeter. The theoretical resolution of DSA is limited by the matrix size to 1.28 lp/mm for a 20 cm field using a 512 x 512 matrix. Larger matrices are available, but DSA cannot at present exceed the limitation of about 4.5 lp/mm imposed by the resolution of the image intensifier[J7,K32]. The image processor has a fixed matrix size so that when a larger area is viewed, each pixel is larger, giving a reduced spatial resolution in addition to the loss of contrast resolution from increased scatter. If the matrix size were increased to 1024 x 1024 the memory required would be quadrupled, and although in theory this

should increase spatial resolution, in practice the gain is not as much as expected[G8].

5.3.4. *DSA evaluation with phantoms*

Continuing advances in digital subtraction imaging demonstrate the need for critical evaluation of the performance of DSA equipment. Periodical measurements of performance are therefore necessary to maintain a constant image quality. To accomplish this, phantoms have been developed as a tool for the evaluation of all new DSA equipment and as a quality assurance tool for regular evaluation of DSA systems[B31,F13,G10,W2].

5.3.5. *Image Manipulation.*

The major advantage of storage of digital information is that data can be manipulated to provide more information[B3,S41], and digital subtraction is only one product of this manipulation. Other methods of image manipulation are:

1. "Contrast level alteration" of the image similar to window level alteration of a CT scan image, and this can be used to enhance the unsubtracted image when subtraction is not applicable.
2. "Pixel shifting": allows shifting of pixel information horizontally, vertically, or obliquely to improve superposition of mask and contrast images[L10].
3. "Landmarking": allows reintroduction of sufficient background detail into the subtracted image to see the relationship between a vessel and the surrounding bony anatomy[J7].
4. "Roadmapping": is the ability to present to the angiographer on a television screen the subtracted image with the screening image superimposed to facilitate catheter manipulation. It speeds selective catheterization and can be an aid in a variety of interventional procedures[T15].
5. "Parametric imaging". The analysis of circulatory dynamics by functional data extraction from radiologic image sequences constitutes the latest development of digital imaging techniques in angiography[B18,B23]. This angiographic parameter imaging is closely related to functional studies in nuclear medicine and is also termed "quantitative angiography"[H7]. It may refer to any type of measurement of vessel diameter and luminal narrowing from angiographic images[B14,H1,L7,], or to an analysis of relative blood flow using videodensitometric methods. Measurements of width changes or density changes over time can be made, using the data to produce areas, volumes and calculations of percentage stenoses and relative flows[B19,C4, H15,H19,K11,L3,S11]. The densitometric method is the most accurate measure of the severity of stenoses, since it is reliant neither on spatial resolution nor on assumptions of cross-sectional shape[K6]. This method has also shown to be reliable in the assessment of flow measurement in below-knee bypasses with or without a distal arteriovenous fistula[S43]. Certain parameters ex-

tracted from time-density curves, analogous to the time-activity curves of nuclear medicine, can be used as a measure of overall organ perfusion or blood transit time between different vascular compartments, or as an indication of the initial delivery of contrast material to an organ. They have also found use in the analysis of myocardial perfusion, before and after pharmacological intervention, and in examination of the cerebral and renal circulations[H22].

5.3.6. *Image display*

The display is the device by which the observer (radiologist) judges the usefulness of radiologic studies. At present, the film/viewbox is still the standard[T12]. Images on conventional radiographic film are a common and omnipresent part of life in a radiology department and its many functions include: primary image capture, image display, image storage, image communication, and consultation medium. In the near future, conventional film and its supporting technologies will probably be replaced, but new technology cannot generally succeed until all tasks of film are superseded at levels which are medically justifiable as well as being economical and practical[B3].
Several new modalities (CT, MRI, Ultrasound, Nuclear Medicine, and DSA) use other display devices, the most common being the cathode ray tube (CRT), and it is estimated that 30-50% of the images created today are seen initially on CRT displays. Most of these displays on CRT are subsequently filmed. The real questions are, how much information is necessary to enable the radiologist to make the same decision from a CRT display as from film and how far can we expect the state of display technology to advance toward producing a cost-effective alternative to conventional film systems? At present, the only routine applications of electronic image capture and extensive visual editing prior to hard copy generation are found in DSA. The majority of such angiographic images are expected to contain no medically relevant information. This, combined with the cost of the great quantities of film used in full size film changers and the high degree of radiologist involvement in most angiographic procedures, has led to the practice of selecting only those electronic images which are of medical utility prior to hard copy generation[B3].
In conventional angiography, the use of special purpose equipment, i.e., angiographic film changers, does permit some optimization of the examination procedure, but does not allow any subsequent image processing. Film displays are a "frozen" selection of the available image displays, while electronic viewing, either of images captured on film or produced electronically, allows a much more complete manipulation of the image. Simple processing of soft copy images such as the setting of contrast and brightness levels on a monitor or the setting of window and level does not substantially increase viewing time. Necessary image processing can be performed, either automatically or by paramedical personnel, prior to the radiologist's diagnostic use of the image.

After a series of analog images has been digitized and some sort of processing has been performed on a single image or image series, the process is still incomplete. One could evaluate the final image information by programming the computer to print out the numbers associated with each pixel, but a more common strategy is to reconvert the digital information into an analog image that can be viewed on a cathode ray tube (TV monitor) or made into a film transparency[K10]. At present, the major and crucial developmental challenge is the presentation of the diagnostic information of these digital images to the physician.

The first option, namely video presentation of digital images on a tv-monitor, is inexpensive and easy to implement with conventional television systems, but the image quality required for medical diagnostics is different from that of broadcast television, and the picture resolution required for minimum diagnostic quality may be at least four times greater. With this method, even properly executed electronic images can be no match for a good photographic procedure. Another problem related to this method is the complex mixture of incompatible television systems around the world; different formats are used in the United States, Canada and Japan (NTSC), Europe, excluding France (PAL), France and French speaking nations in Africa, and the Soviet Union (SECAM). In the future, this problem may be resolved by the international acceptance of a universal television system of "high definition television" (HDTV), with video display monitors which do have sufficient picture resolution for medical diagnostic imaging[V3].

The second option, photographic presentation of digital images, is achieved by three basic methods[L18]:

1) multiformat matrix camera recording;
2) laser electronic image recording; and
3) dry silver paper image recording.

1. *Multiformat matrix camera recording*

In the multiformat video camera system, analog video signals from the display console are connected to the CRT of the camera system. The displayed image is recorded on multiformat imager film in different selectable formats. The film is the primary recording medium and has several disadvantages related to noise, decreased contrast and spatial resolution and peripheral image distortion. However, this method does provide reasonably good quality images for many digitally formatted imaging modalities.

2. *Laser Electronic Image Recording*

Laser imaging is the latest evolution of the CRT photography-based multiformat imaging of the 1980's. Recording digital images on special film without noticeable digitization artifacts, the laser printers are capable of producing

ultra-high quality laser-scanned images, which are visually not very different from an analog image. In one paper, the ROC analysis showed little statistical difference in radiologists' responses, whether they were reading conventional chest radiographs or 1024x1024 laser-printed digital radiographs for the detection of lung nodules[T13]. A laser imager provides excellent hardcopy images with low opical distortion, high spatial resolution and high contrast. Multiple copies are easily generated, and a single recorder can be shared among several imaging systems (e.g. CT and DSA). Because digital data are subject to contrast enhancement and image manipulations, it has the potential to salvage diagnostically suboptimal radiographs, thereby reducing patient dose[L19,T13]. It is anticipated that laser scanning and laser printing systems will be commonplace in future radiology departments.

3. Dry Silver Paper Image Recording

Image data from a video source are recorded on dry silver paper using either a laser recorder or fiber-optic CRT faceplate. The diagnostic quality of paper copies for DSA has been considered equal to that of film copies in a clinical evaluation, but inferior for MRI or CT[L18]. It is the simplest, fastest and most cost-effective hardcopy method of transmitting digital images to referring physicians or of archiving an image in a patient's medical records. In the future it may become routine practice to provide paper copy images of imaging studies in patients' charts[L18].

5.3.7. Image storage

The question of the storage and retrieval of DSA images remains a problem, as it is with the other imaging modalities. At the present state of technology, analog data storage is cheaper and the only means for real-time, high-resolution, and high-frame-rate image acquisition. Analog storage media, i.e. video magnetic tape and disk, and film, theoretically limit the range of later reprocessing and manipulating of archival data. At present, most archived DSA images are in the form of hard-copied film transparencies of CRT images, and this also applies to the other digital technologies such as CT, MRI and Nuclear Medicine. However. as digital technology advances, there will be a greater imperative to store all collected data in the digital mode. Although magnetic tape is a reasonably inexpensive means of digital data storage, it has the drawbacks of being cumbersome and necessitating sequential access to images. that is, one image after another has to be passed until the desired image data is reached.

The problem of data storage and transfer is defined by the matrix size of the image processor. For example, a 512 x 512 matrix contains 262,144 bits of data or pieces of information for storage in digital form. Data are quantified in terms of bits and bytes (8 bits = 1 byte; 10^6 bytes = 1 Megabyte). To double the matrix size from 512 x 512 to 1024 x 1024, one needs to quadruple the memory

necessary to store each image[G8,H5]. In the near future, with the improvement of digital TV techniques, the 1024-matrix will be probably viewed as the standard for digital angiography and radiography[H10].
The problem of digital image storage is being solved, although the system is still in development, by the application of Digital Optical Recording (DOR), mainly in the form of laser digital disks[A10]. In a DOR system, recordings are produced by means of a sharply focused laser beam that, on impact with the recording medium, changes the physical characteristics of the medium[H27]. This technique provides permanent digital images stored in a random access manner, analogous to a phonograph record, in that one can select any spot on the disk to display. The technical implementation of DOR promises to offer reliable and readily accessable storage of digital images in the form of nonerasable disks, erasable disks, optical tape and optical cards.
The application of DOR technology is also an important step in the development of Picture Archiving and Communication Systems (PACS). The future of PACS depends on satisfactory and affordable solutions to three basic requirements: electronic display and processing of images, fast transmission, and readily accessible and reliable storage. DOR promises to comply with these requirements. The potential advantages of a PACS include better image data management and protection, rapid access to distributed image databases from different diagnostic modalities, and the availability of an inexhaustable number of copies of each image[G23].
The future of radiology is related to the rapid development of computerized technology, and probably within the next 5 to 10 years, the predicted existence of a totally digital radiology department will become a reality[C22,C29,D11,S30,S41].

5.4. INTRAVENOUS DIGITAL SUBTRACTION ANGIOGRAPHY (IVDSA)

5.4.1. Introduction

Before the introduction of DSA the trend in arteriography was towards increasing selectivity of catheterization for specific problems with the aim of improving visualization of the vessel or target organ, and the avoidance of overlying and confusing vascular opacification. The entry of DSA into clinical practice in the late 1970s was initially accompanied by some wildly optimistic claims[C16,C30,O1,T8,T16]. IVDSA tried to reverse the trend of selective catheterization, and a vague sense of uneasiness entered the minds of radiologists, who thought that their work was perhaps to be replaced by first year residents and nurses[L9,M14].
Intravenous arteriography, however, did not start with the advent of DSA[R24]. In 1939 angiography of the heart and great vessels was performed by the venous injection of contrast medium into an arm vein[R25]. The technique was developed further after World War 2, and to achieve better visualization,

bilateral hand injections of contrast medium of 50mls each were given into each arm[S42]. However, because of the long exposure time, low contrast and other hemodynamic factors, examinations were often not satisfactory.

5.4.2. *Peripheral versus central venous injection*

With DSA intravenous injections can be given peripherally or centrally and produce nonselective angiography[M14,S28,W4]. Peripheral intravenous injections can be made through a 16G butterfly needle or angiocath placed in the basilic vein on the medial side of the arm. Subsequently, 30-50 mls of contrast medium containing 300-370 mg I_2/ml (e.g. Hexabrix 320) are injected at a rate of 15 mls/s, and this is repeated for each view or position.
The claimed advantages of peripheral intravenous examinations are that they are non-invasive and quicker since they can be done without using sterile packs, that the short intravenous catheter (Angiocath) can be put in place outside the catheter room and that no arterial compression is required after the procedure[P11,M14].
In experiments using repeated injections into the cephalic vein, subclavian vein and the main pulmonary artery in dogs, more central injections caused a greater density in the femoral artery over a shorter time[R12]. There was little improvement with pulmonary artery compared with superior vena cava (SVC) injections, and it is thought that pulmonary artery injections with ionic contrast medium increase the central volume and reduce the cardiac output. In the belief that central intravenous injections therefore produce better images, many radiologists tend to use central injections, thereby losing IVDSA's claim of being "non-invasive" and of being a quick and simple procedure.Central intravenous injections are made through a pigtail catheter positioned in the superior vena cava or right atrium, using the standard exchange technique. The volume of contrast is the same as for peripheral injections, but the rate can be increased to 25 ml/s. Injections into the right atrium produce mixing with blood from both the inferior vena cava and the SVC, giving a uniformly opacified bolus[M14, S1,S28].
Patients having both central and peripheral injections of ionic contrast media preferred the peripheral ones[P12]. Comparisons of images produced after peripheral and central injections in the same patients showed no significant difference in image quality in one study[L21]. Hemodynamic changes are induced in patients by injection of ionic contrast material, whether injected into a vein or into left ventricle[M2]. The supposed greater safety of IVDSA, which involves the rapid central delivery of large volumes of contrast medium, should be reconsidered. There is a markedly higher incidence of severe idiosyncratic reactions to iodinated contrast agents when they are delivered intravenously[D12]. It is true that arterial studies carry risks of arterial injury, extravasation, and embolisation, but the incidence of these complications is

small in experienced hands, especially with the newer small 4 French and 5 French catheters.

5.4.3. *Disadvantages*

Soon after the introduction of DSA it was found that intravenous injections are of little use in patients with poor cardiac output, in those who are breathless, or those who cannot keep still, and the use of non-selective arterial injections was then advocated[C17,H24,T11]. In fact, the patients for whom IVDSA was originally most strongly urged, e.g., the elderly and the ill, are actually the least suitable. It involves a considerable stress to the cardiovascular system and kidneys, and is likely to be relatively ineffective in producing good images[H18].
In conclusion, the requirements for optimum image quality in IVDSA are: large Iodine dose per injection; good cardiac output; low osmolality of contrast agent, centrally placed catheter. The disadvantages of IVDSA can be summarized as follows: relatively poor image quality; multiple imaging sequences needed; large volumes of contrast medium required; not non-invasive; not always quick and simple; not necessarily safe[D2,S28].

5.4.4. *Present day applications*

The indications for IVDSA are mainly derived from its applicability as a relatively less invasive outpatient procedure and include: evaluation of the carotid and vertebral arteries; screening for diseases of the aorta; screening for renovascular hypertension and evaluation of renal transplants; follow-up of patients after vascular reconstruction and evaluation of pulmonary embolism-[C3].
In the management of vascular disease of the extremities, IVDSA is only suited to a focused evaluation of abdominal, pelvic and thigh vessels[B16,C19,H21,K7, L11,R10,S7,S12,S23,T2,T10]. With IVDSA, diagnostic quality images of the distal extremity vessels have been described, but often in patients with normal cardiac function, which is often not the case in patients with arterial occlusive diease of the extremities[H3,H14]. In one paper, whole body IVDSA was described using a computed radiography system, beneficial in 12 patients with Takayasu arteriitis, a widespread sclerotic arterial disease[N2].

5.5. INTRAARTERIAL DIGITAL SUBTRACTION ANGIOGRAPHY (IADSA)

5.5.1. *Introduction*

The development of DSA was accomanied by considerable enthusiasm in predicting that simple intravenous administration of contrast medium could be used to replace conventional arteriography. This prediction was made despite

the fact that few images of outstanding quality were produced and there were no clinical studies demonstrating application in all clinical areas[K16]. Initial application was intended to be evaluation of the extracranial vascular structures, primarily by intravenous injection of contrast material[M7,M12]. As clinical experience developed, it became apparent that the use of IVDSA had significant limitations, such as poor cardiac output, vessel superposition, and misregistration artifact[C17,S23] (see also 5.4.3).
Intraarterial DSA circumvents two of the above mentioned limitations, namely poor cardiac output and vessel superposition. Additionally, it was immediately found to have several advantages over CA: a) less contrast medium (concentration and volume), b) reduced need for selective catheterization, c) lower film cost, d) shortened examination time, e) the ability to obtain a "road map", and f) more ready detection of contrast medium[C17]. These advantages were soon confirmed in other papers[D1,K4], which especially noted reductions in contrast volume of up to 75%[N1]. This can be very beneficial in the examination of hypertensive patients[I1]. Owing to its improved contrast sensitivity, relatively dilute contrast boluses are injected for IADSA in comparison with CA[F4].
In peripheral vascular disease, the tibioperoneal vessels cannot be defined adequately with IVDSA. This is caused by the fact that a DSA signal reflects photon attenuation by iodinated vessels and is dependent on both the concentration of iodine and the vessel diameter, that is, the "iodine path length"[F4]. With intra-arterial injection, even using a dilute contrast bolus, the intra-arterial iodine concentration is significantly higher than that achieved with standard IVDSA injection techniques. Thus, at equivalent radiation dose, vessel resolution is significantly better with IADSA than with IVDSA.
In the conventional arteriographic evaluation of patients with peripheral vascular disease, considerable effort is required to opacify vessels in the lower leg. Despite the use of large volumes of contrast medium, delayed timing of exposures and reactive hyperemia, a number of patients have been seen in whom it was impossible to opacify runoff vessels preoperatively. Later, demonstration of lower leg vessels was performed intraoperatively by direct popliteal or tibial arteriography performed via cutdown in the operating room before bypass surgery or amputation[C17,K13]. However, if CA was immediately followed by IADSA of the lower leg vessels, it was noticed that a number of patients, up to 70%, with no bypassable vessels shown by CA, did have open runoff vessels with IADSA[T9]. Conversely, none of the patients in whom it was impossible to demonstrate runoff vessels with a satisfactory IADSA, were noted to have such vessels when a tibial cutdown with arteriography was performed in the operating room[K13].

5.5.2. *Field of view*

For a complete arteriographic examination of the circulation from the pelvis to the feet, an intraarterial examination is required. In the evaluation of peripheral

vascular disease with DSA, limitations of image intensifier field size become more critical than in some other areas of evaluation. In the initial reports, examinations were performed using 9-inch (23 cm) field sizes, thereby severely restricting the area of examination with one contrast medium injection. Nowadays, however, with the advent of 14-inch (35 cm) field sizes, it is possible to obtain bilateral lower extremity DSA studies over a larger length. The problem of an air gap between the two lower extremities can be solved by using the crossed-leg technique[G4]. Prior to injection of contrast medium and filming, the patient's legs are crossed at the ankles. In this position, the legs are tightly taped at the ankle and below the knee joint, resulting in tight approximation of soft tissues.
In one report, the use of a 16-inch (40 cm) intensifier was found to be useful for peripheral vascular disease[P1]. Even with the use of a 22-inch (57 cm) image intensifier, 95% of cases of IADSA of lower extremities were considered diagnostic[B20]. As spatial resolution is in part dependent on pixel size (field of view divided by display matrix), lower spatial resolution results from the use of a larger intensifier format. With a commonly used 512 matrix and a 30-cm intensifier, pixel size is 0.6 mm and limiting resolution is 0.8 lp/mm[F4]. In a recent paper, presented at the Radiological Society of North America (RSNA) Congress (Chicago,1989), based on a series of 180 patients, it was found that using a high-resolution system with a 1024 x 1024 matrix and a 40-cm imaging intensifier, the image quality of the lower leg behind stenoses was higher with IADSA than with CA. The high imaging quality of digital angiography without the subtraction also allowed excellent functional angiography in patients with an entrapment syndrome[H13].

5.5.3. Automated stepping ("bolus-chase DSA")

Conventional lower extremity arteriography is usually performed using a ceiling tube and long cassette changer, a programmable moving table top in conjunction with a film changer, or a programmable movable X-ray tube with film changer. With adequate contrast injection, and appropiate timing of radiation exposure, diagnostic images suitable for operative planning can be obtained.
DSA examinations may be obtained with conventional technique using bolus contrast injection with subtraction images limited to a specified region. However, extremity examinations then require five or six separate injections for an examination of the circulation from the aortic bifurcation to the ankles. To circumvent this problem, "bolus-chase" DSA techniques have been implemented to shorten procedure time. Two techniques for implementing bolus-chase arteriography have been demonstrated.
One approach is to employ conventional DSA for a sequence of proximal subtraction images and then utilize arterial contrast clearance for a washout image in a second contiguous position. This technique is limited to imaging

two contiguous regions with one contrast injection but avoids problems of reregistration of the table-top or X-ray-tube and of patient anatomy. In addition, this technique allows the use of different contrast material bolus concentrations for thigh imaging as compared with calf imaging[F5].
An alternative approach involves the use of preliminary mask images of the thighs and calves obtained in sequence from the groin to the ankle. Following bolus contrast injection, an automated table or X-ray tube is moved to preselected positions by the angiographer observing the subtraction images on line. Reregistration of the subtraction images at the exact site of the mask images could be a significant problem with this technique. In addition, patient motion could easily occur between the mask and the subsequent series of live subtraction images[F4]. In a preliminary report, presented at the RSNA Congress (Chicago, 1989), good quality images were obtained after a single contrast medium injection of 60 mls in 25 examinations. Additional series were reduced to only those patients for whom significant differences in flow between the extremities necessitated different timing, as is known from CA as well[F16].
If this method is perfected, the use of DSA technique with automated stepping may totally replace conventional angiography of the peripheral arteries.

5.5.4. IADSA in interventional procedures

IADSA has been of significant benefit in the performance of therapeutic interventional procedures. The advantages of IADSA include improved contrast resolution, instantaneous subtraction capability, and immediate image availability[C7]. Reduced contrast volumes and concentration result in reduced pain and discomfort and also decrease contrast-related risks.
During percutaneous transluminal angioplasty, DSA is frequently employed to provide morphologic evaluation of the angioplasty site as well as the distal run-off. Real-time fluoroscopic DSA or "road-mapping"[T15] is an extremely valuable tool in negotiating difficult stenoses and dealing with lesions at points of bifurcation or trifurcation.
During catheter-directed infusion of a variety of agents, DSA can be extremely useful as a primary imaging modality, and it is of particular benefit during fibrinolytic infusions, in which increased contrast sensitivity allows decreased injection flow rates and improved detection of contrast material within a clot and filling of collateral vessels.

5.6. DSA IN EXTREMITY TRAUMA

With IADSA the angiographic evaluation of vascular injuries (e.g. arteriovenous fistulae, pseudoaneurysms, hemorrhage) can be accomplished rapidly and with minimal catheter use and manipulation, which is particularly important for critically ill patients who have significant immobility because of multi-

ple fractures. Also, the amount of contrast material injected, patient discomfort and film cost are reduced[G9,S22]. Even with IVDSA, iatrogenic arteriovenous fistula (AVF) caused by previous cardiac catheterization procedures could be satisfactorily identified[P7]. In two other studies a comparison was made between CA and IADSA for evaluation of peripheral vascular trauma, one showing a good correlation between CA and IADSA for detection of pseudoaneurysm, AVF, extravasation, occlusion, intimal flap, wall irregularity, and spasm[H26]. In the second study, both CA and IADSA showed an equal diagnostic ability for the same parameters[S13]. CA was considered slightly better for detecting intimal dissection because of better spatial resolution, but overall, IADSA was considered better for initial evaluation, being quicker, more convenient and economical.

5.7. DSA AND EXTREMITY TUMORS

Preoperative evaluation of extremity tumors using IVDSA has proved useful in ascertaining the nature of the lesion, its extension to soft tissues and joints, and the presence of arteriovenous shunts[S15]. IVDSA has been considered especially helpful in demonstrating the presence or absence of major vessel involvement by tumor when this could not be definitely ascertained on CT[P3]. In a comparative study with CA, IADSA showed an equal diagnostic ability and even reduction a of procedure time and radiation dosage, combined with cost savings of film and contrast medium[L8].

5.8. DSA AND PERIPHERAL VASCULAR BYPASS PROCEDURES AND ANGIOPLASTY

IVDSA provides an easy method of assessing the results of surgery[B9] and of angioplasty[C1]. Because of its invasive nature, CA as well as IADSA is used with reluctance for early post-operative evaluation of vascular reconstruction and angioplasty. IVDSA can readily identify graft patency and occlusions, with minimum patient discomfort and on an outpatient basis, makaing it less expensive than routine angiography[B22,G17,P9,S22]. Even the patency of ilio-iliac crossover venous bypass grafts after postthrombotic occlusion of an iliac vein can be demonstrated with IVDSA[A6].
In evaluating peripheral bypasses to the popliteal artery or crural vessels, the quality of the IVDSA images may be poor because of poor perfusion in thin vessels. Nevertheless, most of these investigations give useful information about anatomic configuration and functioning of the graft and its anastomoses. Clinically unsuspected complications may be detected[T1]. If a severe stenosis is found after IVDSA, then one can consider performing IADSA, with concomitant dilatation of the stenosis.

In comparison with CA, IVDSA was found 100% accurate in the determination of graft patency, and in most patients it provided reliable information regarding the status of the distal anastomosis and the patency of the distal runoff. It is considered preferable to CA for objective documentation of long-term graft patency[P13].

5.9. INTRA-OPERATIVE DSA

A very innovative method is the use of intra-operative DSA for immediate evaluation of an in situ saphenous vein bypass. Immediate correction of significant abnormalities avoids later re-operation. This technique is made possible by the use of a mobile C-arm with image intensifier and TV camera, connected via cables to a processor in the radiology department[K14].

5.10. DSA AND OUTPATIENT ANGIOGRAPHY, COST BENEFITS

Invasive radiological examinations, particularly arteriograms, have long been deemed inpatient hospital procedures, because of the potential risks of arteriography. The original enthusiasm for IVDSA as a noninvasive procedure suggested a strong increase of outpatient procedures. It also seemed better suited than CA to certain categories of patients, such as those who are asymptomatic but at high risk. However, increasing use of IVDSA has highlighted its inadequacies in general, e.g. poor cardiac output, patient motion, vessel superimposition, which especially produce nondiagnostic examinations of the lower legs.

The cost effectiveness of outpatient CA has already been studied[A2,W5], and cerebral, peripheral, visceral, and cardiac catheterizations have been considered safe in selected cases, using 5-8French catheters[A2,G18,R16,S26,W5]. With the development of high-flow 3-5F catheters and small guide wires, as well as the use of small needle puncture techniques, the safety of angiography and intervention can be improved even more, so that outpatient catheterization procedures could become routine[C34]. The three major advantages of miniature catheters for angiography are a) a smaller arterial entry port for improved hemostasis and less local thrombosis; b) reduced likelihood of iatrogenic occlusion of stenotic arteries, a property dependent on the square of the catheter radius; and c) less catheter surface area exposed to the blood stream, resulting in less thombotic surface aggregate[H28]. In general, 4-F catheters provide excellent abdominal aortography and run-off examinations, and single extremity angiography can nearly always be done with a 3-F catheter.

With IADSA, the use of miniature catheters combines the small caliber needed to minimize intraarterial catheter complications with the advantages of IADSA, to produce high quality images on an outpatient basis[B6,B15,N3,R2]. A complica-

tion caused by the miniature catheters themselves is a so-called "jet-effect", that occurs when injection pressures approach catheter tolerance (1000 psi), and this can cause subintimal extravasation of contrast medium. The high-flow jet does not occur (in 5-F catheters) when flow-restrictive end holes and side-holes are used[D7].

Another advantage of using IADSA with miniature catheters is the application of transbrachial catheterization with minimization of complications. Radiologists are reluctant to use the brachial artery, because they believe its smaller size makes puncture more difficult, and because of the higher complication rate reported in CA, as compared to transfemoral catheterization and even translumbar aortography[H16]. In a recent study of 660 arteriographic examinations, IADSA was performed from a brachial artery approach using a 4-F pigtail catheter, most of which (>95%) were performed as outpatient procedures. Only two brachial artery complications (0.3%) occured which were severe enough to warrant surgery[G13]. Although routine use of transbrachial IADSA for peripheral vascular disease is probably not advisable, it can be a convenient solution in patients in whom trans-femoral DSA is contra-indicated because of previous surgery or markedly reduced femoral pulsation[H4].

6. COMPARISON BETWEEN CA AND DSA

A review of the literature

As vascular surgery and interventional radiology progress and bypass procedures and percutaneous transluminal angioplasty move more and more distally, it becomes necessary to improve the techniques for visualization of the arteries of the lower leg and foot. The surgical literature contains numerous references to poor visualization of the distal lower limb (below the knee) with conventional angiography[F17,P18,T9]. An optimal arteriogram of the most peripheral vessels of the lower extremities is even more important because non-invasive studies such as Doppler and ultrasound are insufficient in these areas[J12]. In surgery, an aggressive approach to limb salvage has been advocated in recent years, sometimes in combination with percutaneous transluminal angioplasty. Visualization of small distal vessels is very important because bypass graft patency has been shown to correlate well with an intact runoff system[K1,M29,O4]. Primary amputation rates decreased from 41% to 5% and total amputation rates from 49% to 14% in one series of 2829 patients with critical lower extremity ischemia[V9]. In another series of 1196 patients, 88% with arterial reconstructions still had their limbs at death. The cumulative life table patency and limb salvage rates of small vessel and axillopopliteal bypasses were more than 50% at two years[V7].

In major surgical[A16] and radiological textbooks[K25], as well as in a number of papers[B15,C17,D1,F4,H20,S17], the use of IADSA has been propagated as a method of obtaining adequate diagnostic information on the vascular tree right down to the foot, especially when CA fails to do so. It has been shown that conventional preoperative arteriography can be performed optimally by using a single-leg injection method with film-screen technique[S39]. However this study used large volumes of contrast medium (60 mls) injected into the external iliac artery, combining this with the use of a long-leg changer instead of a translating table. The long-leg changer is less sensitive to timing errors of contrast flow in the extremity, but is more sensitive to the variations in radiologic exposure from the pelvis to the ankles[A11]. In CA the lack of demonstrable contrast in the branches of the infrapopliteal arteries is an indication of the inadequacy of the study rather than a sign of inoperability.

However, the literature comparing IADSA with CA is scanty, and the role of DSA in peripheral arteriography has not yet been convincingly defined[J1]. The importance of this fact is that for many years, conventional arteriography has been regarded as the "gold standard" for diagnosis and visualization of obstructive arterial disease of the lower extremities. In the last fifteen years, non-invasive tests in the vascular laboratory have taken over the primary role of diagnosis.

The first comparative studies mainly related to the cerebral circulation, and compared CA with IVDSA[G22,M15,M27,V11]. These were followed by other comparative studies, also comparing CA and IVDSA in other body regions[B8,F10, H14,L1]. The comparison parameters, however, are often very subjective and poorly defined, and results show very inadequate statistical analysis or are anecdotal, with no data on sensitivity, specificity or consistency. One paper has compared CA as the gold standard with IVDSA in 23 patients for peripheral vascular disease[H2], but no proper statistical analysis was given. Visualization of tibial and peroneal vessels was considered inadequate. Generally speaking, although DSA has a greater contrast resolution than CA, the dilution of contrast medium is too great and spatial resolution too limited in IVDSA for adequate visualization of infrapopliteal vessels, especially in atherosclerotic extremities-[C3]. Therefore, IVDSA should not be used for the angiographic workup of lower leg disease.

Direct comparison studies have shown that the diagnostic image quality of IADSA is equivalent to that of CA for cerebral examinations[B12], trauma[G9,S13], limb tumors[L8], and hepatic tumors[F12,T4] as well as for the digital arteries of the hand[M13].

A number of studies have been published comparing IADSA with CA, specifically for patients with vascular insufficiency of the lower limbs[F28,G2,H38,S17,S32]. No validity (conformity) or reliability (consistency) results were noted. In a few papers, IADSA has been described as an adjunctive examination to conventional arteriography in one procedure[B44,G5,M3]. In one study, adjunctive IADSA visualized 66% of crural arteries and pedal arches which were not visualized by CA. Also, in the absence of visualization of the distal circulation by preoperative CA, the early patency results in those patients with IADSA nonvisualization (41%) was decidedly inferior to those in whom visualization was obtained with IADSA (75%)[D5]. The parameter used for evaluation in this study was only a subjective grading as excellent/satisfactory or poor/inadequate visualization of crural arteries or runoff.

Very few papers have been published with a prospective randomized study. One study examined 63 consecutive patients by CA alone, IADSA alone, or CA with IADSA of nonvisualized areas[G2], patients being assigned to a group in a random fashion. IADSA resulted in cost savings of film and contrast material but required a significantly longer examination period. Image analysis by a radiologist and vascular surgeon showed less detail in the aortoiliac region in DSA images, but did show the runoff vessels better than CA (runoff only to

mid-calf!). Image analysis was performed using a scoring scale for quality of visualization as excellent, good, poor but diagnostic, nondiagnostic and not relevant, which is a fairly subjective parameter scaling. This is the only paper which mentions the use of a kappa test in statistical analysis to measure interobserver agreement, but no kappa values are given. A serious disadvantage of this study was the use of a 9-inch (23 cm) image intensifier, requiring longer examination time and more regional exposures.

Only one recent paper, by Smith et al[S46], showed a similarity to this study by comparing the degree of vessel visualization (opacification) and grade of stenosis between CA and IADSA in the same patients in a prospective random fashion. In this study, contrast injections were given only into the external iliac artery. Good correlation for severity of vessel stenosis and adequacy of vessel opacification, particularly in tibial vessels, was found between the two techniques.

The results of a pilot study for the present thesis were presented at the meeting of the Radiological Society of North America in Chicago in November 1989, reporting better interobserver agreement in IADSA than in CA of the lower leg[W10].

In summary, according to a number of reports advocating the use of IADSA, the main advantages of this technique are fourfold. First, IADSA examination frequently results in a 30-50% reduction in the amount and concentration of contrast medium used[C17,D2,K3,M11,S17]. Second, IADSA examinations are said to be completed faster than CA examinations, largely because one can view the images immediately on the video monitor[C17,K3,]. Third, significant savings may be made in the cost of the film by using DSA[C17,D8,D9,K3]. Finally, the ability to use a diluted contrast medium significantly reduces patient discomfort, though this should be less of a problem with the use of low-osmolar contrast media [C7,D2].

7. CONSISTENCY STUDY

Subjects, equipment, examination methods, data analysis

7.1. GENERAL DESIGN OF THE STUDY

This prospective study was carried out in the Department of Radiology of the University Hospital of Maastricht, after the installation of a new angiography suite with DSA equipment. Three main aspects can be distinguished in the design of this study. First, the performance of CA and adjunctive IADSA examinations of the lower leg as one procedure in all patients who were referred for arteriography of aorto-iliac and lower limb arteries between November 1987 and November 1988. These arteriograms constituted the basic material for the study. The second part comprised extensive data collection after a blinded, independent reading of the hardcopies (films) of the knee and lower leg regions of these examinations by four different observers. The third part of the study was an elaborate statistical analysis of these data, to calculate the interobserver agreement for different parameters. Prior to starting this study, consent was obtained from the Medical Ethics Committee of the hospital.

7.2. PATIENT POPULATION

In principle, all patients admitted to the hospital for arteriography of the lower extremities, with or without examination of the abdominal aorta and the pelvic arteries, were included in the study. Most patients were considered possible candidates for a vascular operation on the basis of the examination by a surgeon and of vascular laboratory tests, see 7.2.2.[R18]. No other selection criteria were used.
Since the main area of interest of the study was the obstructive arterial lesion in the lower leg, a number of angiographic procedures were excluded from the study. According to a protocol agreed upon by the vascular surgeons and the radiology department prior to the beginning of the study, patients referred for a problem concerning only the abdominal aorta, the aorto-iliac vessels, the femoral artery bifurcation, an aorta prosthesis, or a femoro-popliteal bypass,

were initially examined with IVDSA. These patients were not included in the study.
The patients referred for a problem concerning aorto-iliac and peripheral vessels, or only peripheral vessels (femoro-popliteal and crural arteries), were examined by CA as performed routinely in the angiographic suite. In the same procedure, and in the same patient, IADSA of only the knee and lower leg/ankle region was performed, with contrast injection via the same arterial puncture site. The CA and IADSA examinations were generally 15 minutes apart. These were to be the patients included in the study.

7.2.1. Clinical evaluation

All patients in the study had been preselected by the referring surgeon on the basis of history, physical signs and noninvasive physiologic tests (see 7.2.2) suggestive of obstructive arterial disease of the lower limb. In the general evaluation of the patient, associated conditions such as diabetes mellitus, hypertension, myocardial ischemia, blood dyscrasias, and previous allergic response to radiopaque contrast medium were assessed. On the basis of history and physical examination, the patient could often be graded according to the classification of arterial occlusive disease proposed by Fontaine[F7,F8]:

Grade I: asymptomatic,
Grade II: intermittent claudication,
Grade III: rest pain,
Grade IV: ulcerations or gangrene.

Because this classification was not consistently specified in the medical records of all patients, no evaluation of patient selection was performed in correlation with their symptoms. However, according to the records, most of the patients with an indication for angiography did belong to grade II, III, or IV, indications which were already in use before the beginning of this study.

7.2.2. Noninvasive tests

All patients underwent routine non-invasive tests before their arteriography. All tests were performed during a single uninterrupted session in the same room in the vascular laboratory at a constant room temperature. Before the start of the tests all patients rested in a supine position on the examination tablle for 20 minutes.
The vascular laboratory tests which were usually performed consisted of:

1. systolic ankle pressure recording (Doppler method) at rest and after (treadmill) exercise test (see 3.4).
2. segmental systolic pressure recording (Doppler method) at rest at thigh and calf level (see 3.4).
3. systolic pressure recording in the toes (plethysmographic method) (see 3.3).

4. Duplex recording of aorto-iliac vessels (see 3.5).
5. (invasive) femoral artery pressure recording, before and after papaverine injection (see 3.11).

The segmental systolic pressure measurements were obtained by using a Doppler ultrasound velocity detector (Vasculab®) and blood pressure cuffs placed around the thigh, calf and ankle. The systolic blood pressures of both arms were determined using the Doppler method. The arm with the highest systolic pressure at rest was used as reference.
The ankle-brachial pressure index (ABI) was calculated by dividing the systolic ankle pressure by the systolic brachial artery pressure. The resting ABI in normal patients is usually 1.0 or greater. The resting ABI in moderate to severe claudication averages about 0.6, while patients suffering from rest pain and ischaemic trophic disturbances usually have ankle-brachial indices below 0.5[K17,K34,P4,R13].

In the present study a simple grading of ABI values was made, which correlates reasonably well with the clinical symptoms of the Fontaine classification.

ABI	Symptom
0.8 - 1.0 (or >)	asymptomatic
0.6 - 0.8	intermittent claudication
0.4 - 0.6	rest pain
0- 0.4	ulcer/gangrene

First, the number of extremities belonging to each grade of ABI values was calculated.
Secondly, in the interpretation of films it became evident that in a number of arteriograms, certain arteries were considered non-interpretable by the four observers. The mean ankle-brachial index of the extremities with noninterpretable arteries was calculated.

Thirdly, it was noticed that the greater number of noninterpretable arteries occurred with CA examinations. The question then arose whether there is any relation between the interpretability of CA and the value of the ABI. More specfically, does the percentage of (non) interpretable arteries in the group with ABI<.6 in CA differ significantly from the percentage of (non) interpretable arteries in the group with ABI>.6?

7.2.3. Indication for arteriography

After the initial patient interview and examination, complemented by noninvasive testing, had established the nature and severity of the vascular problem,

a decision was made whether or not the patient was a likely candidate for operation. If it was decided to proceed with operation after this initial evaluation, arteriography was planned in order to assess the morphologic and anatomic characteristics of the vascular segments involved, and to judge the feasibility of reconstructive vascular surgery or balloon angioplasty.
Informed consent for the examination was obtained after explaining the procedure[P23]. In all patients renal function was determined prior to the procedure and if the patient was receiving anticoagulant therapy, the appropriate clotting tests were performed. To prevent complications from hematomas or bleeding at the puncture site, anticoagulation was temporarily reduced before arteriography.

7.3. DIAGNOSTIC IMAGING EQUIPMENT

The angiographic suite comprised two separate diagnostic X-ray systems. Most of the angiographic procedures were performed with a universal system, the Philips® Diagnost Arc (Philips Medical Systems, Best) with a programmable stepping C-arm. The universal system was completed by a ceiling mounted X-ray tube, which is used for biplane angiography and selective cut film angiography (CA) of hands and feet.
The Diagnost Arc consisted of an X-ray beam carrier (floor to ceiling column supporting a C-shaped arm), an X-ray tube, an image intensifier subsystem with TV chain, a 35- by 35-cm Puck UD 4 serial film changer (Elema-Schonander®, Solina, Sweden) and an add-on DSA-unit. The film changer unit and image intensifier were both linked to the C-arm by a revolving head, opposite the X-ray tube. The Diagnost Arc had a longitudinal travel of 178 cm and a lateral movement of 69 cm. The mobile C-arm permitted lateral and cranial-caudal tube angulation (Figure 7.1).
Using the film changer for CA, an automatic stepping facility could be used for posterior-anterior projections. Up to four steps could be made in every run (i.e. five positions): the step length was fixed at 22 cm for each step. The patient support had a free overhang of 205 cm, enabling total body angiography. In a test run, test exposures could be made and high voltage, tube load and diaphragm could be set for each individual position. Settings were automatically stored for the subsequent exposure run.
Using the image intensifier, images were acquired for DSA and were stored in 512 x 512 data matrices, up to 3.3 frames per second.

Characteristic features and system parts of the universal angiographic diagnostic X-ray imaging system were as follows:

- X-ray tube:
  The X-ray tube (type: Super Rotalix SRM 15/50) was linked to the C-arm; focal spot sizes were 0.3 mm and 0.7 mm.

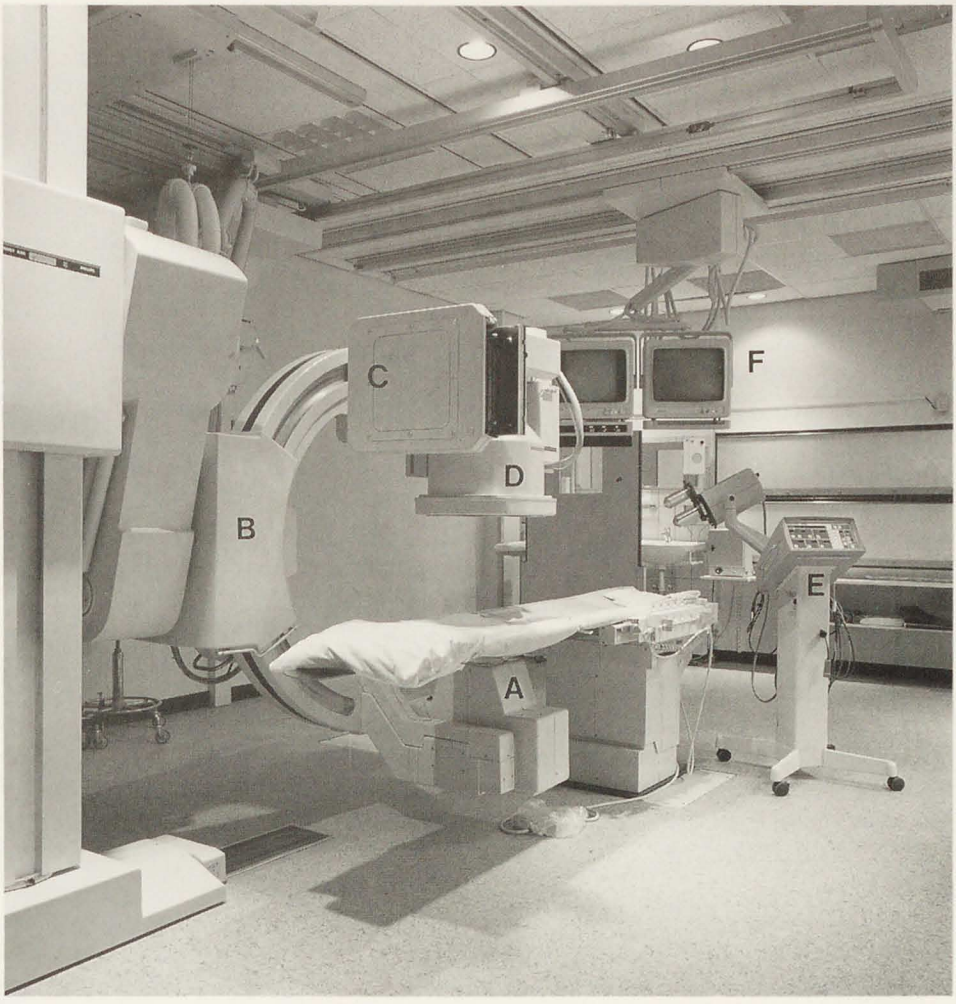

FIGURE 7.1.
Angiography suite: a) angiographic table, b) C-arm with rotating head with c) PUCK film-changer and d) Image intensifier, e) Power injector, f) on-line video monitors.

Patient table:
Angio Diagnost 3 patient support. Tabletop height adjustment range was 29 cm. Tabletop movement was 35 cm longitudinally and 12 cm laterally to either side of the central line. A free overhang of 205 cm enabled total body angiography. Table top width was 43 cm. Catheterisation arm support, compression bands and patient retainer straps could be attached to the table.
X-ray attenuation by the table equaled 0.9-1.0 mm aluminium equivalent.

- X-ray generator:
  Philips® Maximus CM 100 generator (12 pulse generator, maximum tube load 1,000 mAs, maximum output power 100 kwatt).

Imaging systems:

- *Fluoroscopy:*
A trimode structured cesium iodide-input phosphor 14 inch (35 cm) image intensifier was linked to the C-arm, opposite the X-ray tube. The imaging system contained a Plumbicon camera pick-up tube.
When using the image intensifier, the source-to-image distance could be varied between 85 and 110 cm.
The minimum distance between the image receptor and the patient's body was 10 cm.

- *Conventional arteriography (CA):*
A conventional Puck UD4 35/35 film changer for 35 x 35 cm films was attached to the C-arm, next to the image intensifier. Film changer and image intensifier were both mounted on a revolving head. A punch card program selector (PCQ, Siemens®), enabled rapid serial full size radiography. Maximum speed was 3 exposures per second; maximum capacity was 20 films per cassette. A high voltage reduction unit for peripheral arteriography was applied, in combination with the PCQ, which controlled longitudinal C-arm movements. A gadolinium/lanthanum intensifying screen was used in the PUCK UD4 film cassette [Titan U]. During CA, using the film changer, the source-to-image distance was fixed at 100 cm. The minimum distance between the film and the patient's body was 5 cm.

- *DSA:*
A digital subtraction system, Technicare DR 960-B add-on DSA (General Electric®), was linked to the image intensifier. Four DSA-matrix sizes were available: 128x128, 256x256, 512x512, and 1024x1024. Angiographic examinations were generally performed using 512x512 matrices; maximum frame rate was 3.3 frames/sec.
Hardcopies of selected DSA-frames were made with a frame recording system (Laser Imager 3M®), using 35x43 cm film in a 6-frame division mode or a single frame mode. The minimum distance between the image receptor and the patient's body was 10 cm.

7.4. METHOD OF ARTERIOGRAPHY

This section includes general information as well as characteristic data for system parameters of the diagnostic imaging systems. It also describes the methods used for arterial puncture, CA and IADSA in more detail.
The arteriography of a patient was performed by the radiologist who was on duty in the angiographic suite at the time, according to the rotation schedule of our radiology department. As already mentioned, it was not possible to have the CA examination and IADSA examination of the same patient performed by two different radiologists because of manpower and organisation problems. The arteriography procedure was to be performed according to a standardised protocol, already referred to in 7.2.1. In all, the arteriograms in this study were performed by seven different radiologists (or residents under supervision).
In the angiographic suite a record was kept of each angiographic examination, noting type of examination, number of runs per injection, contrast medium used (with concentration and volume), arteriographic puncture site and type, and any complications.

7.4.1. Puncture and catheterization

The arterial puncture site was determined according to clinical symptoms and the presence of a palpable pulse. Puncture of the common femoral artery (see Figure 4.1) was preferred because of the artery's proximity to the aorta and lower extremities and its superficial location in the inguinal area. Prior to arterial puncture, skin and subcutaneous layer were anaesthetized locally. Examples of catheter and puncture needles are shown in Figure 7.2.

If examination was required of both the aorto-iliac and the peripheral vessels of two legs, or if a cross-over approach was necessary to examine one leg, a Seldinger catheterization was performed using a pigtail catheter (5.5 French High-Flo pigtail catheter Cook® HBP 5.5-38-12s-65 cm length, see Figure 7.3.
If both femoral pulses were absent or very weak, translumbar aortography (TLA) was performed as an alternative to percutaneous femoral artery catheterization, using a special TLA needle (Van Dongen needle), see Figure 7.2 and Figure 4.3.
If only one leg was to be examined, a percutaneous needle puncture (PNP) technique was performed, using an Angiographic Needle (Cordis® 17 gauge, 4 inches long, for a.045in diameter guide wire), see Figure 7.4.

7.4.2. Conventional Arteriography (CA)

In all examinations (except three) a single bolus injection of an ionic low-osmolar contrast medium, (meglumine/sodium ioxoglate Hexabrix® 320) was injected by a Medrad® Powerinjector Mark IV (Figure 7.1). A nonionic low

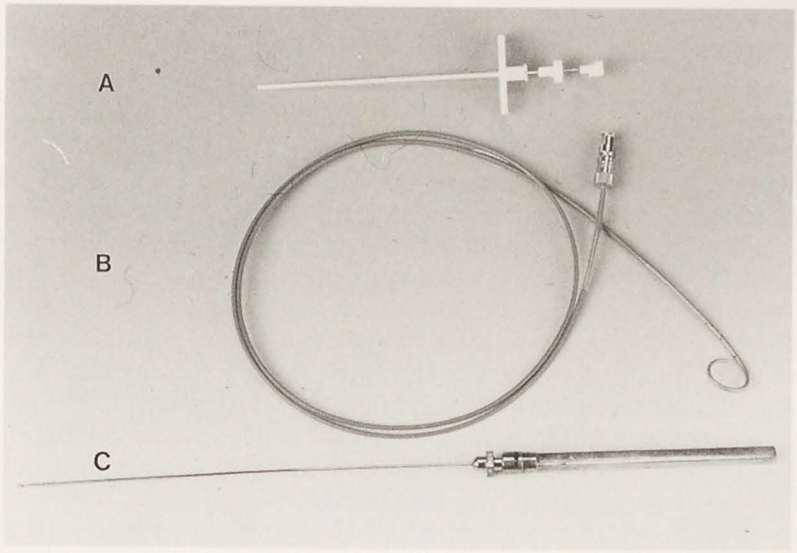

FIGURE 7.2.
Puncture and catheterization equipment: a) Angiocath needle with sheath, b) Pigtail catheter, c) Translumabar aortography needle.

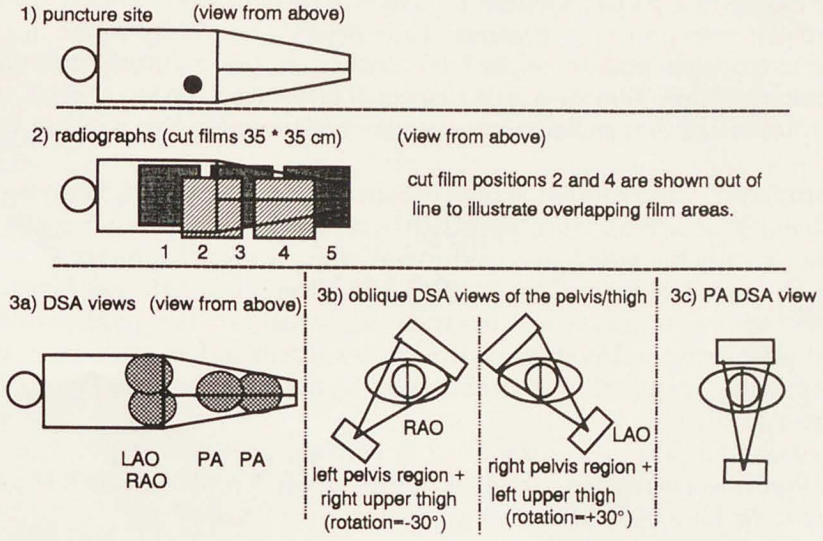

FIGURE 7.3.
Schematic drawing of bilateral arteriography: 1) puncture site in femoral artery for Seldinger catheterization, preferably on the right side. If no palpable pulse, puncture was performed on the left. For puncture site of TLA, see Figure 4.3. 2) exposure positions for CA. 3) exposure postions for IADSA.
(Acknowledgement: figure was compiled with Drawperfect®, and reproduced with kind permission from Mr. P.J. Kicken).

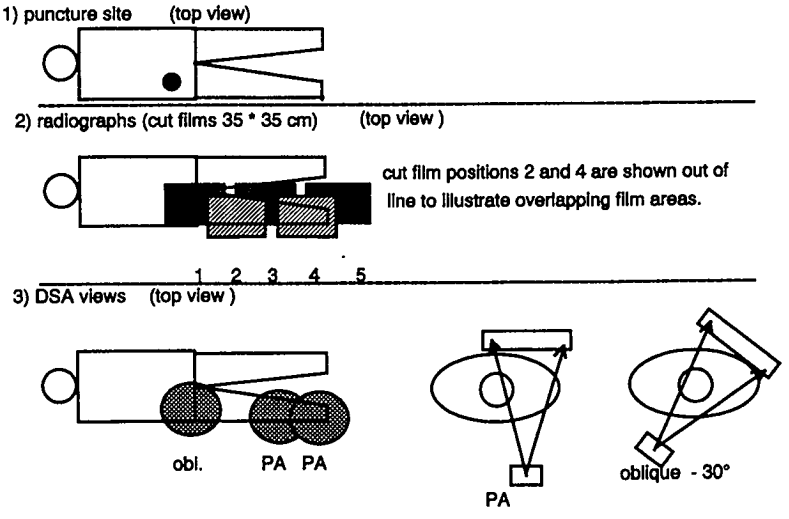

FIGURE 7.4.
Schematic drawing of single leg arteriography: 1) needle puncture site, 2) exposure positions for CA, 3) exposure positions for IADSA.
(Acknowledgement: figure was compiled with Drawperfect®, and reproduced with kind permission from Mr. P.J. Kicken)

osmolar contrast medium Iohexol (Omnipaque® 350) was used without complicatons in three patients with a suspected history of contrast allergy.
The standard injection bolus of contrast medium and injection rate for each method was:

- Seldinger catheter: 70 mls at 15 mls/sec at 900PSI (pounds per square inch pressure),
- TLA: 70 mls at 8mls/sec at 450 PSI,
- PNP: 40 mls at 6mls/sec at 200 PSI.

The stepping X-ray tube was programmed beforehand to stop serially and take radiographs of regions of the abdomen, pelvis (Seldinger and TLA), thigh, knee, and lower leg/ankle (and foot), see Figure 7.3 and 7.4.
Programming of the stepping C-arm included setting of the high voltage, tube load (mAs), and diaphragm for each radiographic position. Anatomical structures in the regions of interest were previewed during fluoroscopy, using the 14 inch image intensifier.
The bolus contrast injection from the Power injector triggered the sequential filming and stepping movement of the Xray tube after a two-second delay. Each step, taking one second, involved displacement of the X-ray tube and imaging system by 22 cm, resulting in a diagnostic overlap of approx. 7 cm for sequential radiographs.

The standard film exposure rate was as follows:

Seldinger catheterization and TLA (14 films):
- abdomen, one per second for 3 seconds,
- pelvis, one per second for 3 seconds,
- thighs, one per second for 3 seconds,
- knees, one per 2 seconds for 6 seconds, and
- lower legs, one per 2 seconds for 4 seconds.

Percutaneous needle puncture (14 films):
- pelvis, one per second for 3 seconds,
- thigh, one per second for 3 seconds,
- knee, one per 2 seconds for 6 seconds,
- lower leg, one per 2 seconds for 6 seconds,
- ankle/foot, one per 2 seconds for 4 seconds.

In CA, an optimal procedure can demonstrate the whole arterial tree form aorta to pedal arteries after one single injection of contrast medium ("single bolus angiogram").
After a single bolus angiogram was obtained with CA, the knee and lower leg-ankle region were visualized again using IADSA. A repeat CA examination was only performed if the vascular tree was not adequately visualized above the knee region.

7.4.3. Intraarterial digital subtraction angiography (IADSA)

Following the CA examination, IADSA was performed with a static X-ray tube and image intensifier (for exceptions, see 7.4.4).
The image intensifier was first positioned at the popliteal region with the knee joint positioned at the border of the upper and middle thirds of the fluoroscopic image, in order to visualize the popliteal division in this image. A single bolus injection of the same contrast medium was given, and exposures were made using the same time delay to the popliteal region as in CA. Secondly, the image intensifier was positioned at the lower leg/ankle region with the ankle joint just visible at the lower border of the fluoroscopy circle and a second bolus injection of the same contrast medium was given. After an adequate time delay following contrast medium injection, exposures were made of this region. Because of the large 35 cm image intensifier, the two fields of view always overlapped and complete visualisation of the lower leg was achieved. Examination of the foot was excluded from this study (Figures 7.3 and 7.4).
The main advantage of DSA, viz. higher contrast resolution than CA, was exploited by using the same contrast medium but strongly diluted to 50% less iodine concentration. Also, approximately 50% less volume was injected in most arteriographic examinations using the same Medrad Power Injector.

The usual injection volume for one DSA examination was:
- Seldinger catheter: 40mls at 15mls/second at 900PSI,
- TLA: 40mls at 8mls/second at 450PSI,
- PNP: 20mls at 6mls/second at 200PSI.

Timing problems with blood flow, as described for CA, rarely occur with IADSA examination, because the Xray-tube with Image intensifier remains stationary over the region of interest (knee or lower leg/ankle). Contrast flow was visualized on the video monitor (Figure 7.5) at a rate of one frame per second to a maximum of 25 frames ("real-time imaging"), thus practically always capturing blood vessel flow if present, even in different frames in the two legs of the same patient in one-sided occlusive disease.

If the combination of CA and adjunctive IADSA of knee and lower leg/ankle was considered an adequate study for clinical use by the radiologist performing the examination, no further runs were performed and the examination was concluded. If a region of interest was not adequately visualised by CA or by IADSA, it was left to the initiative of the radiologist performing the examination to decide which technology to use in order to produce an optimal and interpretable examination. All IADSA images were postprocessed with remasking and pixel shifting to obtain optimal images at all levels. Enough



FIGURE 7.5.
Angiography suite: lead-shielded area containing: a) punch card equipment for CA stepping, and b) DSA-console with video monitors for on-line viewing.

images were photographed so that all levels had maximum contrast visualization and an image with bones to serve as landmarks.
In the early stages of the present study, the DSA frames were recorded by a multiformat camera, (Matrix instruments® Video Imager), displaying the images on a 20 x 24 cm film, either singly or in a four-frame division mode, which was rather small. In a later phase of this study (eight months after the start) the frames were recorded by a Laser Imager 3M®, using 35 x 43 cm film in a 6-frame division mode (Figure 4.3) with a greatly enhanced image quality, thereby fully exploiting the possibilities of digital recording of images (S65).
The CA and IADSA films were subsequently routed via the normal procedure to the X-ray archive.

7.4.4. Vasodilatory influence of contrast medium

One of the properties of contrast medium is that it can cause vasodilatation (see 4.3). If vasodilatation should be present from a previous injection, this might have a significant influence on the observer readings when comparing the film interpretations of the two different modalities. In order to examine this, a consecutive number of patients who underwent percutaneous needle puncture angiography underwent CA prior to IADSA (CA-IADSA), while the remaining patients underwent IADSA followed by CA (IADSA-CA).

7.5. METHOD OF FILM INTERPRETATION

7.5.1. Film reading

Approximately three to six months after the examination date (in order to minimize the effects of observer recall) all arteriograms were retrieved from the X-ray archive and the films (hardcopies) of the knee and lower leg/ankle region were viewed independently by four observers, two radiologists and two vascular surgeons. Observer 1 was a general radiologist with ten years experience after registration. Observer 2 was a vascular radiologist with more than twenty years experience in vascular radiology. Observers 3 and 4 were two vascular surgeons with more than ten years experience in vascular surgery. The observers were blinded with regard to the name and birth date of the patient, and the date of examination. Clinical details, including results of noninvasive tests, were also unknown to the observer. This is an accepted method of preventing bias in the interpretation of the films[B48,B52]. After six months of arteriographic examinations according to the study protocol, the CA films of this first 6-month group of patients were interpreted by the four observers independently in a first series of viewing sessions. Approximately one month later, the IADSA films of the same patients were interpreted by the four observers independently. After 12 months of arteriographic examinations,

films of the second 6-months group of patients were read in a second series of viewing sessions,with at least one month between CA and IADSA readings. All images were viewed by all four observers on the same X-ray viewing cabinet under the same circumstances at the end of a normal working day.
In order to ensure that the area of the knee and lower leg region in the CA images correlated exactly with that in the IADSA images, they were all viewed by the author prior to observer analysis, and if necessary, identical cutoff boundaries were marked on the film in pencil.
In the knee region image the proximal interpretable boundary was formed by the origin of the popliteal artery, at the crossover point of the superficial femoral artery with the medial cortex edge of the femur. The distal boundary in this image included the popliteal trifurcation and proximal parts of the posterior tibial, anterior tibial and peroneal arteries.
In the lower leg region image there was always a slight proximal overlap in the continuation of the above mentioned three main lower leg arteries in CA and IADSA; the most distal interpretable boundary was formed by the ankle joint.
In CA there were generally three films to interpret for the knee region and two films for the lower leg region. In IADSA there were generally one or two films to interpret which included the images of both regions.
After reading the films under the supervision of the author, the judgment of each observer was marked on a data-form for computer processing (see Appendix) in the appropiate box for the following parameters:

- interpretability (see 7.5.2)
- multicategorical Angioscore (see 7.5.3)
- collateral circulation (see 7.5.4)
- quality (see 7.5.5)
- graftability (only by the two vascular surgeons, see 7.5.6)

7.5.2. *Interpretability*

In order to allow statistical analyses of interobserver agreement, the angiographic examination had to be considered interpretable for CA as well as IADSA, and noninterpretable (nonvisualized) arteries had to be excluded. From the start of the present study, each observer had to mark the interpretability of popliteal, posterior tibial, anterior tibial and peroneal arteries.
Because the purpose of this study was to compare the consistency (interobserver agreement) of CA with that of IADSA, the artery which was being judged had to be scored interpretable by all four observers for CA as well as IADSA (see Figure 7.6). Any artery which was considered non-interpretable by any one observer in either CA or IADSA had to be excluded from further computation of the interobserver agreement.

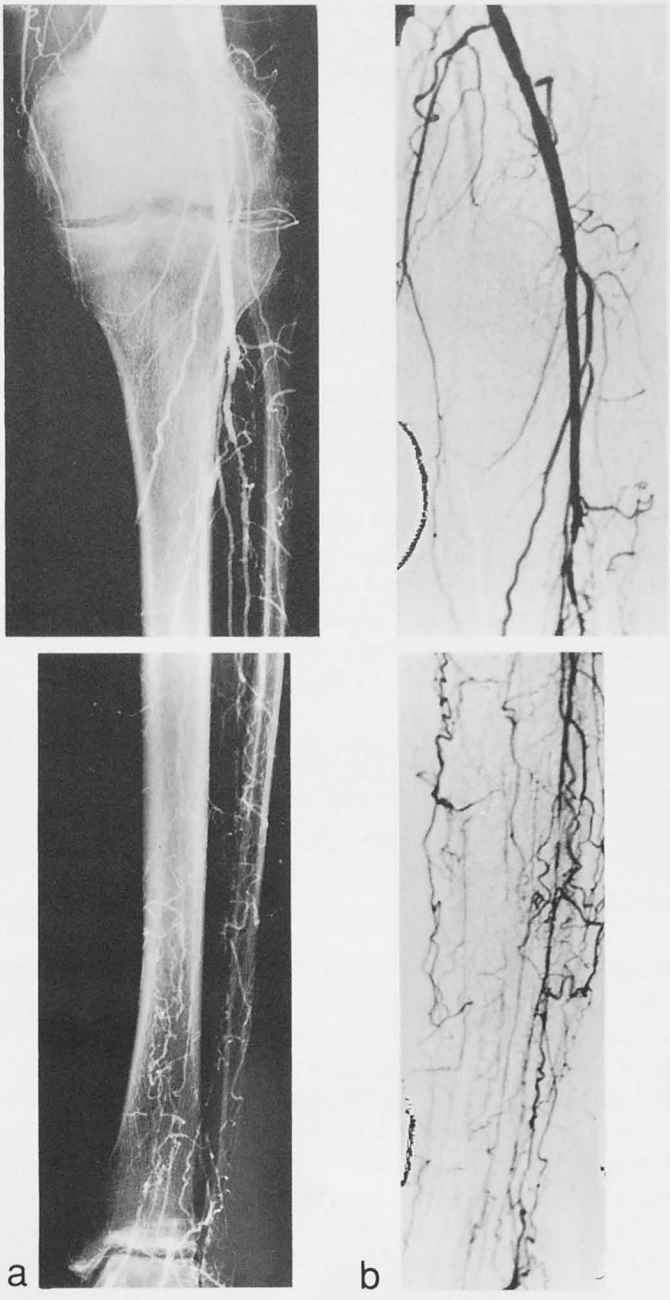

FIGURE 7.6.
Example of CA (a) and IADSA (b) of the same lower leg judged interpretable for all four arteries by all four observers.

7.5.3. *Description of the arteriogram (Angioscore)*

Each observer had to grade the degree of maximum stenosis of the popliteal, posterior tibial, anterior tibial, and peroneal arteries separately according to a five-point categorical stenosis scale, named the "Angioscore". In the case of multiple stenoses in an artery, the severest stenosis was measured to characterize that artery. An occlusion was defined as a 100 percent stenosis or total obstruction of the vessel lumen.
Stenosis was graded into the following five categories, similar to those proposed by Morton et al[M16]:
1) 0 - 24%,
2) 25 - 49%,
3) 50 - 74%,
4) 75 - 99%,
5) 100% or occlusion.
The gradings were based on manual measurements of the diameter of the artery with a standard ruler or a special magnifying loupe with a built-in 0.1 mm scale for very small vessels. All measurements of arterial stenosis were performed with the same instruments (one geometric ruler and one magnifying glass with 0.1 mm scale) by all observers (Figure 7.7).

The degree of stenosis was calculated from these measurements using the equation:

$$\%\ stenosis = 100\ x\ (1 - \frac{diameter\ of\ diseased\ segment}{normal\ diameter\ of\ this\ vessel})$$

7.5.4. *Collaterals*

Each observer had to indicate whether collaterals (indirect or direct) were present, going to or coming from each separate artery, or indicate if this was not interpretable on the film.
A familiarity with the characteristics of collateral blood flow at the level of the distal point of arterial stenosis or occlusion has become important for accuracy of interpretation. If, at any given level of the arterial tree distal to the proximal level of occlusion, small arteries are demonstrated to be filled in continuity by proximal collateral branches, and if filling of the main-stem artery cannot be demonstrated at that level, then the main-stem artery at that level is occluded-[W1].
From the start of the study, the Angioscore and collaterals were marked on the angiography report form for data analysis. At a later stage (after the first six months), marking was also performed for quality and graftability.

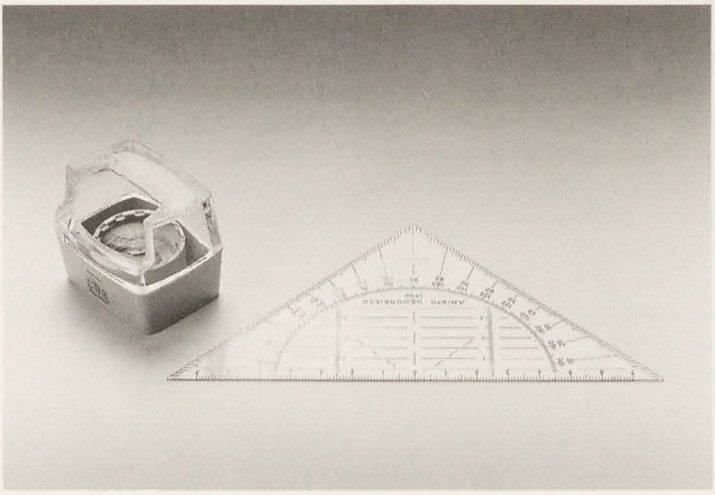

FIGURE 7.7.
Measuring equipment: a) magnifying glass with 0.1mm scale, b) ruler with 1mm scale.

7.5.5. *Quality*

During the viewing sessions of the first 6-months group, it was noticed that a substantial number of CA films obtained, after a single bolus injection of contrast medium, were considered non-interpretable for two main reasons: the lower leg arteries were not adequately visualized with contrast medium to the ankle region ("low contrast"), and there was often difficulty in interpreting stenoses if they were superimposed over the cortex of the underlying bone ("bone superposition"). IADSA films were sometimes considered noninterpretable due to subtraction artefact or saturation glare[B21].
Therefore, in reading the films of the second 6-months group of patients (patients 49-100), each observer also had to mark the cause of non-interpretability (n.i.) as:

a. low contrast
b. bone superposition
c. other factors (e.g. technical, artefacts)

7.5.6. *Graftability*

Although no parameters were specified for the assessment of graftability, a paramount factor in the consideration of local operability and in the determination of the desired levels of surgical exposure is the demonstration of the distal extent of gross disease. In addition to the location of the lower extent of complete arterial occlusion, the degree of intimal disease in the distal patent arterial segment is recognized as a major factor in local operability[W1]. Because the two surgeons both had more than ten years of experience in vascular

surgery, the assessment of graftability was left to their own judgment, as normally happens in surgical clinical practice.
In reading the films of the second 6-months group of patients (patients 49-100), the two vascular surgeons separately had to judge whether a vessel was considered amenable to grafting. This was therefore solely a subjective impression of the surgeon, based only on the angiogram.
In retrospect, the vessels which were judged amenable to grafting by both surgeons, were compared with the vessels which had actually been grafted according to the operation record. On reviewing the operation records of patients 49-100, only those legs with a femoro-crural bypass to either a patent posterior tibial, anterior tibial or peroneal artery were compared with the scores for suggested graftability on the data form.
The purpose of this exercise was to compare the difference between the number of arteries judged graftable according to sole interpretation of CA angiograms and that according to sole interpretation of IADSA angiograms.

7.6. STATISTICAL ANALYSIS

Statistical analysis was performed on a VAX mainframe computer in the Computer Centre of the Biomedical Department, University of Limburg. To calculate the various Kappa values as a measure of interobserver agreement, a program written in Fortran was used, compiled by the biostatistician of the Department of Medical Statistics of the University of Limburg. The significance of differences (p value) between the various Kappa values was calculated by means of a paired t-test, using a Ministat® statistics program on a personal computer. To calculate the significance of differences in interpretability between CA and IADSA, the Fisher exact probability test was used on a personal computer.

7.6.1. Interobserver agreement and consistency

Consistency refers to the agreement between two processes (or results) in situations in which neither process is assumed to be correct or definitive[F15]. Consistency has also been referred to as reliability, reproducibility and repeatability[C8,F11,L2]. One may refer to the consistency from test to test or from observer to observer or from time to time by the same observer. For example, the findings of two physicians may be called consistent if they both agree on the findings. Agreement between two or more physicians is termed "inter-observer agreement." Agreement between repeated observations by the same physician is termed "intra-observer agreement"[K35]. Inconsistency of interpretation by different readers (interobserver variability) must be differentiated from that of different interpretations by the same reader (intraobserver variability). Consistency takes particular importance if a test is to be used in the follow-up of

disease or as a reference standard for other tests[L2]. Determining the consistency of a diagnostic test is a prerequisite to the evaluation of its conformity (validity or accuracy), which uses a gold standard. In this study, it was only the consistency of reading CA films that was compared with that of IADSA films; it should not be interpreted as one in which CA is used as the gold standard.

7.6.2. Kappa

Because interobserver agreement may be completely or partially achieved by chance, a method of statistical evaluation was selected which measures agreement corrected for chance[C8,F26,K35,S33]. This method uses the calculation of Kappa (=K) as the measure of interobserver agreement corrected for chance.
The Kappa coefficient is the proportion of agreement after chance agreement has been removed from consideration, or alternatively, the proportion of chance-expected disagreement which does not occur[C8].

Kappa is calculated according to the formula[C8]:

$$K = \frac{P_o - P_c}{1 - P_c}$$

Po = observed agreement,
Pc = calculated chance agreement,
1 - Pc = measure of possible improvement in the proportion of agreement,
Po - Pc = actual improvement.
An example of Kappa calculation is given in Table 7.1.

The standard error of kappa was computed in order to indicate how accurately the agreement was measured.

7.6.3. Weighted Kappa

Kappa itself treats all disagreements equally. The further development to weighted kappa was motivated by studies in which it was the feeling of the investigator that some disagreements in assignments were of greater gravity than others.
Cohen[C35] described a generalization to weighted Kappa (=Kw), which provides for the incorporation of ratio-scaled degrees of agreement (or disagreement) such that agreements of varying gravity (or disagreements of varying degree) are weighted accordingly. Schouten[S20,S36] considered using weighted kappa for the measurement of pairwise agreement among many observers.
In simple language, this means that disagreement in choosing two close possibilities is not as serious as disagreement in choosing two less proximate possibilities[B43].

Table 7.1. Agreement among all four observers: Observed (Obs.) and Expected (Exp.) proportions of popliteal artery stenosis classified by two random observers.

Category* the one observer		Category another observer					
		1 0-24% stenosis	2 25-49% stenosis	3 50-74% stenosis	4 75-99% stenosis	5 100% occlusion	Total
1	Obs[1]	*0.38*	0.03	0.01	0.00	0.00	0.42
	Exp[2]	*0.18*	0.03	0.03	0.02	0.17	
2	Obs.	0.03	*0.01*	0.02	0.00	0.00	0.06
	Exp.	0.03	*0.00*	0.00	0.00	0.02	
3	Obs.	0.01	0.02	*0.04*	0.01	0.01	0.08
	Exp.	0.03	0.03	*0.01*	0.00	0.03	
4	Obs.	0.00	0.00	0.01	*0.03*	0.00	0.04
	Exp.	0.02	0.00	0.00	*0.00*	0.02	
5	Obs.	0.00	0.00	0.01	0.00	*0.39*	0.40
	Exp.	0.17	0.02	0.03	0.02	*0.16*	
Total		0.42	0.06	0.08	0.04	0.40	1.00

*Category of stenosis: 1 = 0-24%; 2 = 25-49%; 3 = 50-74%; 4 = 75-99%; 5 = 100%
1 Obs. = observed agreement; 2 Exp. = expected or calculated chance agreement (see 7.6.2.)

According to the formula $K = \frac{P_o - P_c}{1 - P_c}$

- observed agreement (Po) = 0.38 + 0.01 + 0.04 + 0.03 + 0.39 = 0.85
(counting along the diagonal = underlined values),
- calculated chance (expected) agreement (Pc) = 0.18 + 0.00 + 0.01 + 0.00 + 0.16 = 0.35
(counting along the diagonal = underlined values)

$K = \frac{0.85 - 0.35}{1 - 0.35} = 0.77$ = good agreement.

In this study for example, there is a scale of increasing stenosis in the angioscore from 0 to 100% (0-24%, 25-49%, 50-74%, 75-99%, 100%), which the observers have to apply. If two observers disagree, in weighted kappa a disagreement between two observers of 75-99% stenosis versus 100% (occlusion) is considered less serious than a disagreement of 25-49% stenosis versus 100%. With kappa (K) however, both disagreements are considered equally serious. Although providing for partial credit, Kw is fully chance corrected and generally shows a slightly higher value than K.
In this study, therefore, weighted Kappa instead of Kappa was used as a measure of consistency for the Angioscore with five categories of stenosis.

It was also considered important in this study to test the consistency of the observers in distinguishing a 50% (significant) or higher stenosis or occlusion, because these are the pathological states which require operative therapy in clinical practice. The Kappa of 50% stenosis can be calculated by combining the markings of all four observers for the categories 0-49% stenosis versus the categories 50-100% stenosis. The Kappa of occlusion can be calculated by combining the markings of all four observers for categories 0-99% versus the last category 100%. In statistical analysis, the terms split Kappa and intraclass Kappa have been used for this aspect[S60], but because this is a dichotomous division, I use the simple term Kappa with 50% stenosis and occlusion, in order to avoid confusion through using too many different Kappa terms.

7.6.4. Kappa values

K = 0 if there is only chance agreement and K = 1 if complete agreement exists. A value of kappa (or weighted kappa) between 0 and 1 indicates that there is more agreement than is to be expected from chance alone. For most purposes, values of Kappa (or Kw) greater than 0.75 may be taken to represent excellent agreement beyond chance, values below 0.40 may be taken to represent poor agreement beyond chance, and values between 0.40 and 0.75 may be taken to represent fair to good agreement beyond chance[F26].
Landis and Koch[L6] suggested the following guidelines for level of agreement:

< 0.00	bad
0.00 - 0.20	low
0.21 - 0.40	poor
0.41 - 0.60	fair
0.61 - 0.80	good
0.81 - 1.00	excellent

In medical practice, kappa values between 0.60 and 0.80 are regarded as acceptable.

7.6.5. This study

In this study the arteriograms were scored by four different observers. Statistical calculations can be made for all six paired combinations of these observers, i.e. Observer 1 versus (vs) Observer 2; Observer 1 vs Observer 3; Observer 1 vs Observer 4; Observer 2 vs Observer 3; Observer 2 vs Observer 4; and Observer 3 vs Observer 4. However, the most representative values are those which use the combined calculations of all four observers, a so-called group Kappa. The group Kappa coefficient is a measure of agreement between two (random) observers and may be considered a group measure of agreement for all six pairwise observer combinations within a group[S33].

In the results, the group Kappa or group weighted Kappa values are presented for the popliteal, posterior tibial, anterior tibial and peroneal arteries after listwise deletion of non-interpretable arteries.
Listwise deletion means that only the interpretable arteries of both CA and IADSA for each arteriographic examination were compared with each other. The statistical significance of the different kappa values for CA and IADSA for each artery was calculated using the paired t-test.

8. CONSISTENCY STUDY:

Results

8.1. ARTERIOGRAMS

In a 12-month period, from November 1987 to November 1988, 145 lower extremity arteriograms were requested which fulfilled the requirements for inclusion in the study protocol, using CA and adjunctive IADSA of the lower leg. At the time of the film reading session, approximately three to six months after the examinations, a number of examinations were excluded from the review for the following reasons:

- non-retrievable from X-ray archive:	12
- no IADSA of knee and lower leg:	20
recorded as:	
- due to groin needle puncture problem after CA:	4
- technical problem DSA equipment:	3
- unknown/not recorded:	13
- no CA of lower leg:	13
recorded as:	
- technical problem Xray-tube stepping:	1
- unknown/not recorded:	12

Therefore, with a dropout of 45 patients (12+20+13), the total number of patients with angiographic examinations available for judging was 100. Patients varied in age from 37 to 91 years, and included 54 males (mean age 67.5 ± 11.7 years) and 46 females (mean age 71.7 ± 11.9 years). More than 90% of the patients were older than 50 years (Figure 8.1).

Of the **100** patients with arteriograms available for film reading, **60** underwent examination of only one leg (right or left) by a percutaneous needle puncture in the groin, while **40** underwent examination by TLA or Seldinger catheterisation (Figure 8.2).
With these last two techniques, both the right and left leg were generally examined at the same time, although in a small number of cases, mostly with the Seldinger catheterization, only one leg was studied. No major non-fatal or fatal complications caused by injection of contrast medium were observed in the 100 angiographic examinations included in this study, according to the

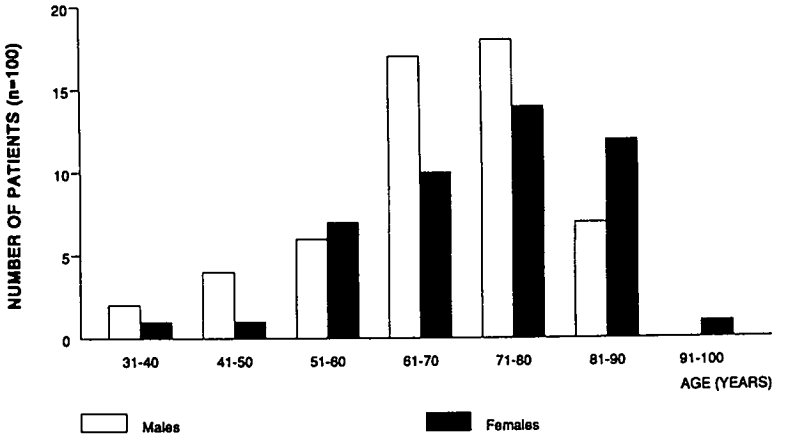

FIGURE 8.1
Age and sex distribution of the 100 patients whose arteriograms were available for interpretation.

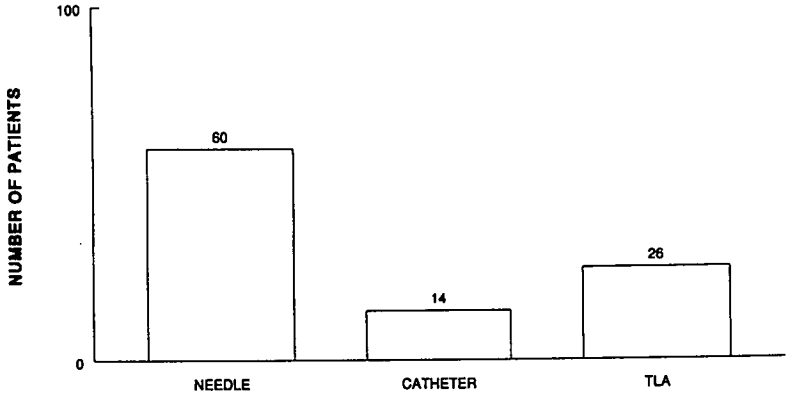

FIGURE 8.2.
Injection methods used: a) percutaneous needle puncture (NEEDLE), b) Seldinger catheterization with pigtail catheter (CATHETER), c) Translumbar aortography (TLA).

angiographic log book. Also, according to the angiographic logbook, the CA stepping procedure with a single bolus injection of contrast medium was repeated a second time in ten patients. The examinations of knee and lower leg/ankle regions with IADSA could be performed with a single bolus injection per region per examination.

In this study, each leg examination of CA and IADSA was judged separately by each observer, and in each leg the popliteal, posterior tibial, anterior tibial, and peroneal arteries were judged separately.
In the evaluation of the multicategorical Angioscore and collaterals, judging was performed in 65 right legs and 70 left legs, giving a total of **135** popliteal, posterior tibial, anterior tibial and peroneal arteries, each of which had to be judged separately.
The "group" Kappa or "group" weighted Kappa values were calculated for those arteries which were judged interpretable by both examination techniques by all four observers.

8.2. INTERPRETABILITY

The total number of arteries judged were 135 popliteal, posterior tibial, anterior tibial and peroneal arteries.

8.2.1. Total number of interpretable arteries

Interpretations of all four observers together showed a difference in the number of interpretable arteries for CA and IADSA separately: 107 CA and 134 IADSA popliteal, 73 CA and 119 IADSA posterior tibial, 58 CA and 110 IADSA anterior tibial, and 63 CA and 107 IADSA peroneal arteries.
In each artery group, CA showed a significantly higher number of non-interpretable arteries than IADSA ($p<0.05$). The statistical significance of the difference between CA and IADSA was calculated using the Fisher exact probability test (Figure 8.3).
Interpretations of all four observers together showed the following number of arteries which were judged interpretable for both CA and IADSA in the same leg: 107 popliteal, 68 posterior tibial, 53 anterior tibial and 54 peroneal arteries (Figure 8.3).
The (weighted) Kappa values were computed only for this last group of interpretable arteries for both CA and IADSA.

8.2.2. Interpretability of each artery

Because the above-mentioned list-wise deletion method of non-interpretable arteries causes an artery to be removed from the group for statistical analysis if it is considered non-interpretable by any one of the observers, a review was performed to see how many observers judged an artery non-interpretable. It is obvious that if an artery is judged non-interpretable by two or more observers, it most probably is non-interpretable, and the exclusion of this artery for statistical analysis is not solely based on the judgement of one observer.

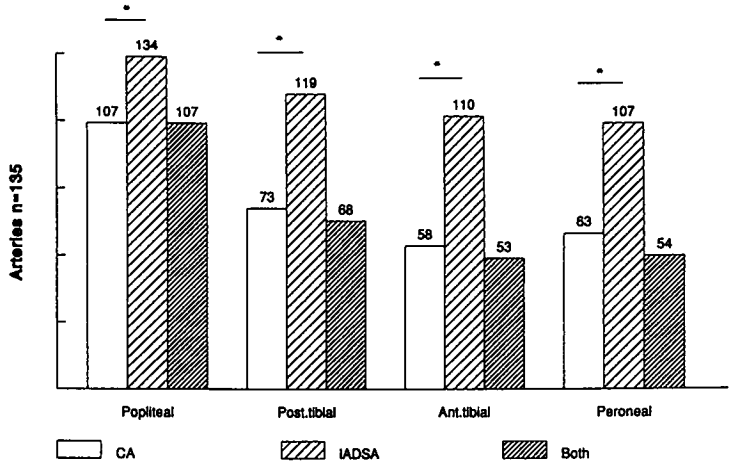

FIGURE 8.3.
Number of interpretable arteries judged by all four observers for the total study group of 135 angiograms. CA = conventional arteriography, IADSA = intraarterial digital subtraction angiography. Statistical significance of difference * = $p<0.05$. Both = arteries judged interpretable with CA as well as IADSA in the same extremity: only these arteries were used in the consistency calculation.

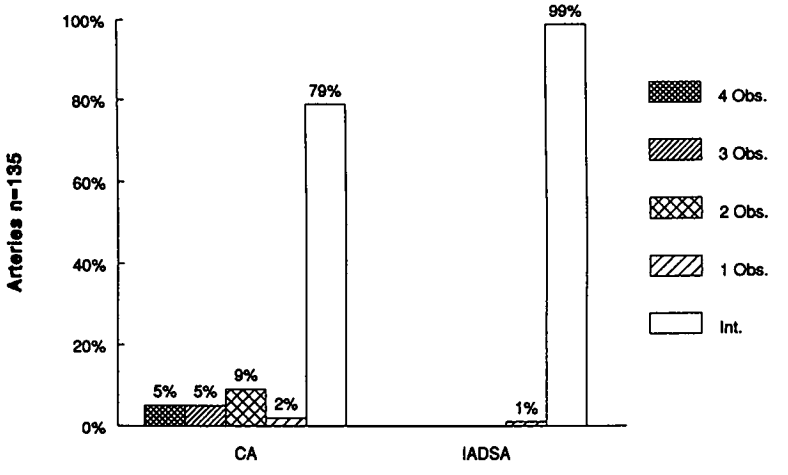

FIGURE 8.4.
Percentage of popliteal arteries judged interpretable (Int) by all four observers, and the percentage of arteries which were judged non-interpretable by one observer (1 Obs.), two observers (2 Obs.), three observers 3 Obs.), or all four observers (4 Obs.) with CA and IADSA. CA = conventional arteriography, IADSA = intraarterial digital subtraction angiography.

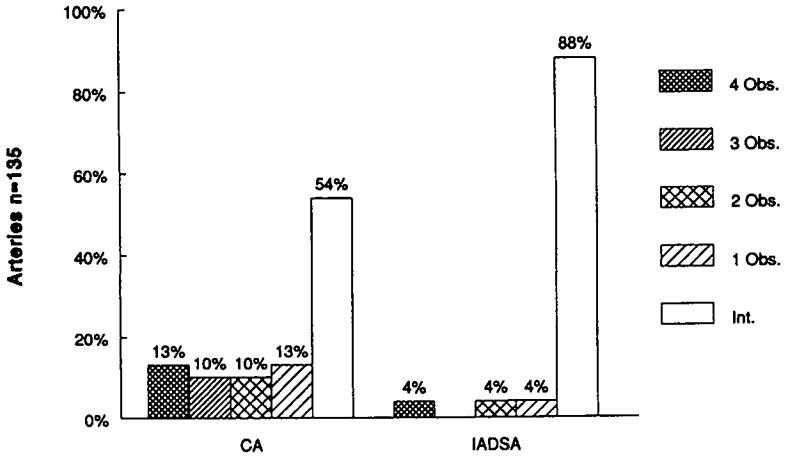

FIGURE 8.5.
Percentage of posterior tibial arteries judged interpretable by all four observers, or non-interpretable by one, two, three, or all four observers. Explanation of abbreviations: see Figure 8.4.

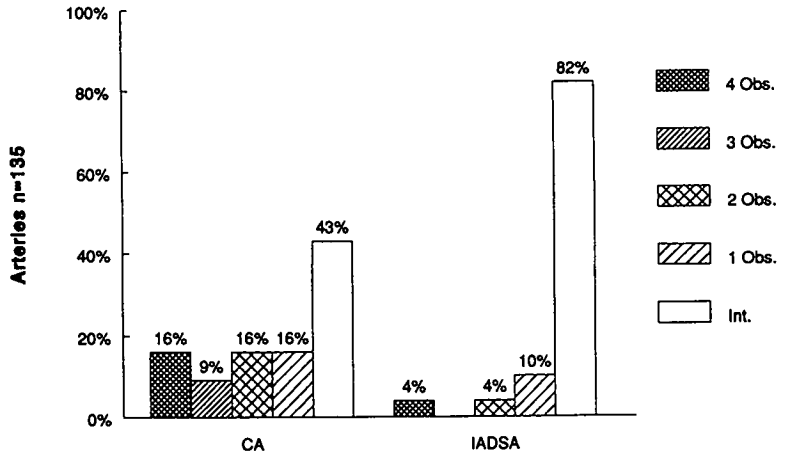

FIGURE 8.6.
Percentage of anterior tibial arteries judged interpretable by all four observers, or non-interpretable by one, two, three, or all four observers. Explanation of abbreviations: see Figure 8.4.

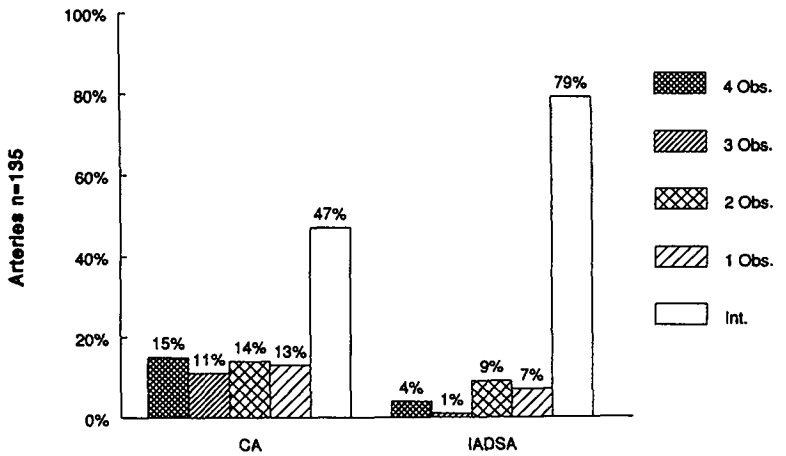

FIGURE 8.7.
Percentage of peroneal arteries judged interpretable by all four observers, or non-interpretable by one, two, three, or all four observers. Explanation of abbreviations: see Figure 8.4.

Table 8.1: Comparison of Quality of CA and IADSA (n=70)

	CA (%)	IADSA (%)
Popliteal artery		
interpretable	86	100
low contrast	13	
bone superposition	0	
other factors	1	
Posterior tibial artery		
interpretable	66	98
low contrast	25	1
bone superposition	6	0
other factors	3	1
Anterior tibial artery		
interpretable	61	96
low contrast	24	2
bone superposition	10	0
other factors	5	2
Peroneal artery		
interpretable	64	93
low contrast	23	4
bone superposition	8	1
other factors	5	2



FIGURE 8.8.
Interpretation of the quality of the arteriographic examination for the popliteal artery. Int. = interpretable, LC = low contrast non-interpretable, B = bone superposition or other factors precluding interpretation.

The popliteal artery was judged non-interpretable by two or more observers in 19% of cases with CA and in 1% of cases by one observer with IADSA (Figure 8.4).
The posterior tibial artery was judged non-interpretable by two or more observers in 33% of cases with CA and 8% of cases with IADSA (Figure 8.5).
The anterior tibial artery was judged non-interpretable by two or more observers in 41% of cases with CA and 8% of cases with IADSA (Figure 8.6).
The peroneal artery was judged non-interpretable by two or more observers in 40% of cases with CA and 14% of cases with IADSA (Figure 8.7).

These results showed that especially in the lower leg arteries, more CA examinations were considered non-interpretable by at least two observers, as well as by all four observers, as compared to IADSA examinations.

8.3. QUALITY

The evaluation of quality (52 patients) was based on 34 arteriograms of right leg and 36 arteriograms of left leg, with a total of 70 popliteal, posterior tibial, anterior tibial and peroneal arteries available for judging. At film interpretation all four observers had to judge whether the artery was interpretable (Int.) or non-interpretable due to low contrast (LC), bone superposition or other factors (B).
In this section the results of the combined agreement score for all four observers for each artery (n=70) for CA and IADSA are presented (see also Table 8.1). To facilitate graphic presentation, the values for bone superposition and other factors have been combined (=B) in the figures.

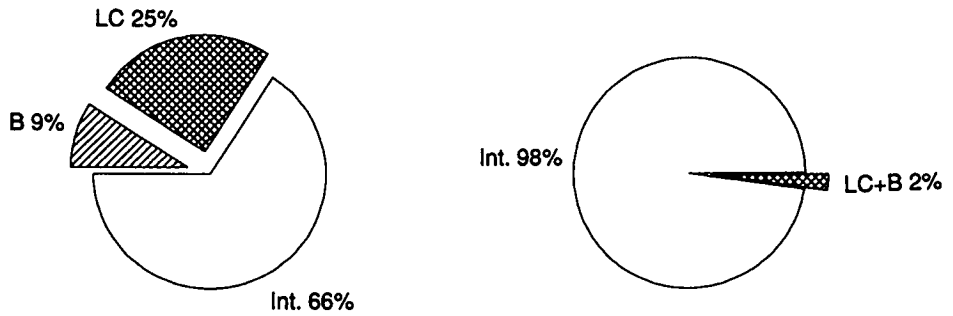

FIGURE 8.9.
Interpretation of the quality of the arteriographic examination for the posterior tibial artery. Explanation of abbreviations: see Figure 8.8.

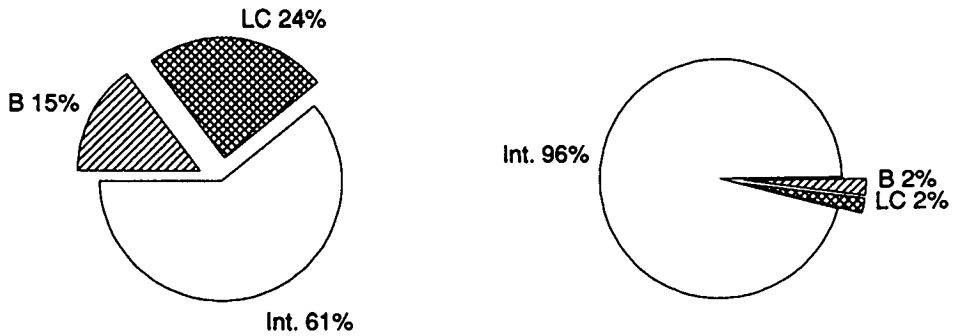

FIGURE 8.10.
Interpretation of the quality of the arteriographic examination for the anterior tibial artery. Explanation of abbreviations: see Figure 8.8.



FIGURE 8.11.
Interpretation of the quality of the arteriographic examination for the peroneal artery. Explanation of abbreviations: see Figure 8.8.

8.3.1. *Popliteal artery*

The popliteal artery was judged interpretable in all angiograms of IADSA, and in 86% angiograms of CA. The noninterpretable popliteal arteries in CA were mainly due to low enhancement of the artery by the contrast medium (13%) (Figure 8.8).

8.3.2. *Posterior tibial artery*

The posterior tibial artery was judged interpretable in practically all of IADSA (98%), but in only 2/3 of CA (66%).
The main cause of non-interpretability in CA was low contrast (25%) (Figure 8.9).

8.3.3. *Anterior tibial artery*

The anterior tibial artery was judged interpretable in most of the IADSA examinations (96%), but less than 2/3 of the CA examinations. The main cause of non-interpretability was again low contrast (24%) (Figure 8.10).

8.3.4. *Peroneal artery*

The peroneal artery was also judged interpretable in most of the IADSA examinations (93%). Non-interpretability was caused by low contrast (4%) as well as bone superposition or other factors (3%). Slightly less than 2/3 of CA examinations were judged non-interpretable, the main cause again being low contrast (23%) (Figure 8.11).

8.3.5. *Conclusion*

Posterior tibial, anterior tibial, and peroneal artery were judged interpretable in more than 90% of IADSA angiograms and in approximately two thirds of CA angiograms. The non-interpretable lower leg arteries in IADSA were equally due to low enhancement of artery by contrast medium, bone superposition or other factors.
It is striking that approximately a quarter of lower leg arteries in CA angiograms were considered non-interpretable due to low enhancement by contrast medium, while approximately 10% were due to bone superposition. In a small number of cases, arteries were judged non-interpretable as a result of other factors.

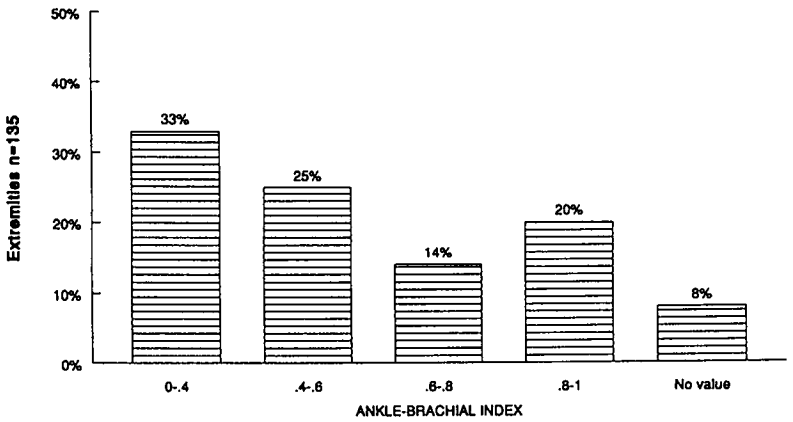

FIGURE 8.12.
Hemodynamic evaluation of 135 arteriograms in 100 patients (each extremity examined was regarded as a separate arteriogram). The ankle-brachial index was 0.6 or lower in 58% of the arteriograms.

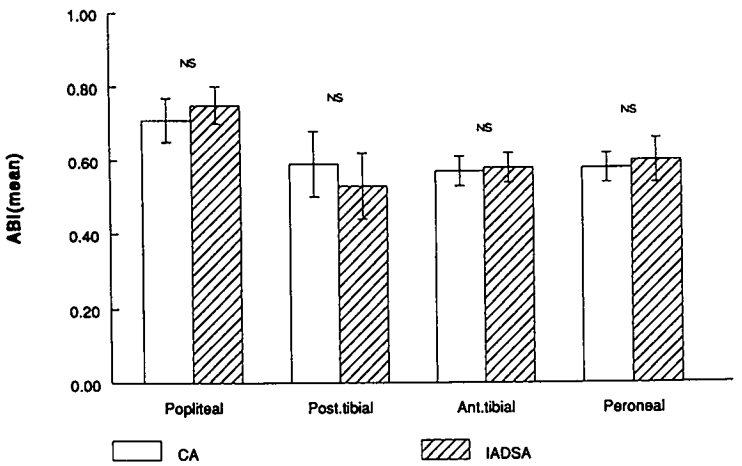

FIGURE 8.13.
Mean ABI for non-interpretable arteries was not extremely low, as might be expected, but generally situated around the 0.6 mark, which indicates significant arterial occlusive disease. Error bars represent standard errors. The differences between CA and IADSA were not statistically significant (NS).

8.4. HEMODYNAMIC EVALUATION

8.4.1. Total study group

In the total study group of 100 patients, with 135 lower extremities examined, the following grading could be made: 45 (33%) extremities with an ABI of 0-.40, 33 (25%) extremities with ABI of .41-.60, 19 (14%) extremities with ABI of .61-.80, 27 (20%) extremities with ABI of .81-1.00. Nine extremities were non-measurable and of two extremities the ABI was not measured (8% with no ABI values). Hence the hemodynamic evaluation using a noninvasive technique showed that in 78 extremities (58%), the ABI was significantly reduced, i.e. below 0.6 (Figure 8.12).

8.4.2. Hemodynamic evaluation of non-interpretable arteries

All non-interpretable crural arteries, with the exception of the popliteal artery, were found in extremities with a mean ankle-brachial index value of approximately 0.6. The mean ABI of extremities with noninterpretable popliteal arteries was slightly higher, in the range of 0.7. The differences between CA and IADSA were not statistically significant (Figure 8.13). This illustrates the fact that the noninterpretability is not necessarily related to a very low ABI (e.g. <0.4).

8.4.3. Correlation between interpretability of CA and ABI

Of the total number of extremities (n=135), ABI values were recorded for 124 extremities. The ABI of nine extremities was nonmeasurable, while no values were recorded in two extremities (see 8.4.1).
From Figure 8.3 the number of interpretable arteries of CA can be derived, but for only a certain number of these arteries ABI values were available (Table 8.2)

TABLE 8.2 Extremities with ABI

Extremities with ABI values	124
-nonmeasurable	9
-not measured	2
Total number of extremities	135

Accordingly, 63% (78/124) of these extremities had an ABI<.6 and 37% (46/124) an ABI>.6 (Table 8.3).

This table actually suggests that the arteries in extremities with an ABI<.6 are more interpretable than those extremities with an ABI>.6.

TABLE 8.3 Interpretable (Int.) CA with ABI values

Artery	Total Int.	Total with ABI	ABI	
			<.6 n=78	>.6 n=46
Popliteal	107	97	66 (85%)	31 (67%)
Posterior tibial	73	72	50 (64%)	22 (48%)
Anterior tibial	58	51	34 (44%)	17 (37%)
Peroneal	63	53	36 (46%)	17 (37%)

TABLE 8.4 Correlation interpretabilty of CA and ABI<.6 (n=78) or ABI>.6 (n=46)

Artery		Interpretable	Noninterpretable	
Popliteal	<.6	66 (85%)	12 (15%)	*
	>.6	31 (67%)	15 (33%)	
Posterior tibial	<.6	50 (64%)	28 (36%)	NS
	>.6	22 (48%)	24 (52%)	
Anterior tibial	<.6	34 (44%)	44 (56%)	NS
	>.6	17 (37%)	29 (63%)	
Peroneal	<.6	36 (46%)	42 (54%)	NS
	>.6	17 (37%)	29 (63%)	

* $p<0.05$; N.S.= not significant

Finally, it was assessed whether the interpretability of an artery in CA was influenced by the value of the ABI below or above .6 (Table 8.4). For each artery, it was attempted to relate the number of arteries considered interpretable or noninterpretable to the value of ABI (<.6 or >.6). The significance of the correlation was calculated with the x^2 test.
The differences in interpretability for ABI below or above 0.6 were not statistically significant for the crural arteries. The popliteal artery did show a significant difference and suggests better interpretability of the artery at an ABI<.6

8.5. CONSISTENCY OF INTERPRETABLE ARTERIES FOR THE TOTAL STUDY GROUP

This section presents, in graph form, for easier comprehension and comparison, the results of the weighted Kappa values of the multicategorical Angioscore, and the Kappa values of 50% stenosis and occlusion. For an explanation of the legends of each graph in sections 8.5, 8.6, and 8.7 see Figure 8.14. The numeric Kappa values can be found in the tables. All Kappa or weighted Kappa

values in the following graphs of this chapter actually represent "group" Kappa values (see 7.6.5).
Error bars represent standard errors. An asterisk indicates statistical significance (p-value). NS = not significant.

8.5.1. Multicategorical Angioscore

A comparison of interobserver agreement between CA and IADSA using weighted Kappa values showed good to excellent agreement for all arteries (K ≥0.61, see 7.6.4). For each artery, weighted Kappa was higher for IADSA, but there was no statistically significant difference. (Table 8.5; Figure 8.14).

8.5.2. 50% Stenosis

A comparison of interobserver agreement between CA and IADSA in the interpretation of 50% stenosis (hemodynamically significant) showed good to excellent agreement for all arteries (K ≥0.61). For each of the crural arteries the Kappa value was higher for IADSA than for CA, but there was no statistically significant difference. The Kappa values of CA and IADSA for the popliteal artery were the same (Table 8.6; Figure 8.15).

Table 8.5 Comparison of Angioscore for CA and IADSA

	CA		IADSA	
Artery	Kw	SE	Kw	SE
Popliteal	0.94	0.02	0.95	0.02
Posterior tibial	0.85	0.05	0.88	0.04
Anterior tibial	0.75	0.06	0.88	0.04
Peroneal	0.68	0.06	0.70	0.07

(Kw=group weighted kappa, SE=standard error)

Table 8.6 Comparison of 50% stenosis for CA and IADSA

	CA		IADSA	
Artery	K	SE	K	SE
Popliteal	0.87	0.04	0.87	0.03
Posterior tibial	0.76	0.07	0.79	0.07
Anterior tibial	0.69	0.08	0.70	0.09
Peroneal	0.63	0.07	0.68	0.07

(K=group kappa, SE=standard error)

Table 8.7 Comparison occlusion CA and IADSA

	CA		IADSA	
Artery	K	SE	K	SE
Popliteal	0.95	0.02	0.94	0.02
Posterior tibial	0.85	0.05	0.88	0.05
Anterior tibial	0.67	0.08	0.92	0.04*
Peroneal	0.63	0.07	0.68	0.07

(K=group Kappa, SE=standard error); * $p < 0.005$

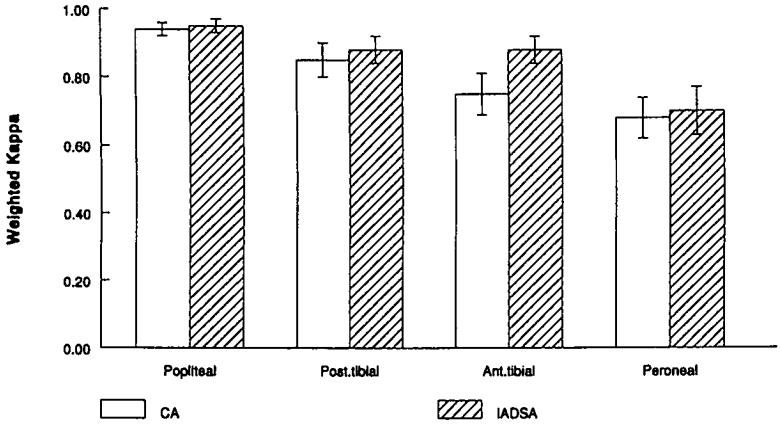

FIGURE 8.14.
Interobserver agreement for the total study group for the multicategorical Angioscore. The differences between CA and IADSA for all four arteries were not statistically significant. CA = conventional arteriography, IADSA = intraarterial digital subtraction angiography, popliteal = popliteal artery, post.tibial = posterior tibial artery, ant.tibial = anterior tibial artery, peroneal = peroneal artery. Error bars represent standard errors.

8.5.3. Occlusion

A comparison of interobserver agreement between CA and IADSA in the interpretation of occlusion showed good to excellent agreement for all arteries with CA and IADSA (K ≥0.61). For each crural artery the Kappa value was higher for IADSA, with a statistically significant difference for the anterior tibial artery ($p < 0.005$) (Table 8.7; Figure 8.16). The Kappa value of the popliteal artery was slightly higher for CA (0.95) than for IADSA (0.94). The differences between CA and IADSA for popliteal, posterior tibial and peroneal arteries were not statistically significant.

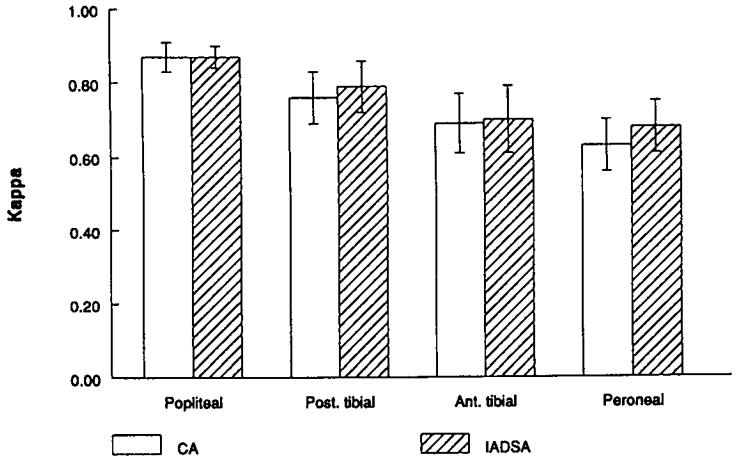

FIGURE 8.15.
Interobserver agreement for the total study group for a hemodynamically significant stenosis (50%). The differences between CA and IADSA were not statistically significant.

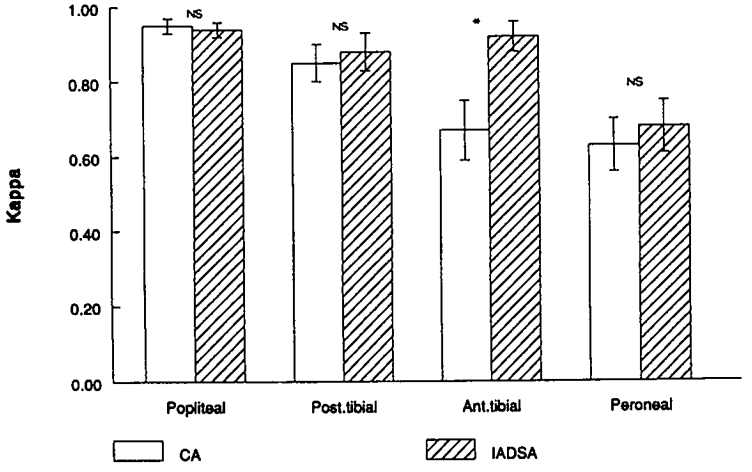

FIGURE 8.16.
Interobserver agreement for the total study group for arterial occlusion. The difference between CA and IADSA for the anterior tibial artery was statistically significant *p<0.005. The differences between CA and IADSA for the popliteal, posterior tibial and peroneal arteries were not statistically significant (NS).

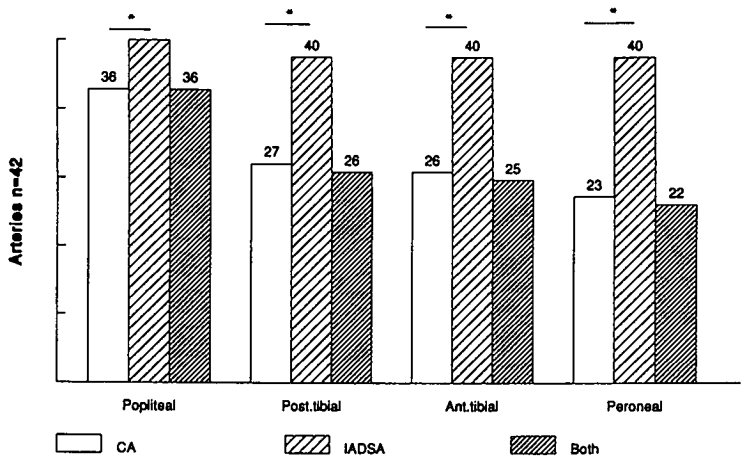

FIGURE 8.17
Number of interpretable arteries judged by all four observers for the subgroup CA-IADSA. CA = conventional arteriography, IADSA = intraarterial digital subtraction angiography, statistical significance of difference * = $p<0.05$. Both = arteries judged interpretable in CA and IADSA in the same extremity: only these arteries were used in the consistency calculation.

Table 8.8 Comparison of Angioscore for CA prior to IADSA

	CA		IADSA	
Artery	K	SE	K	SE
Popliteal	0.95	0.02	0.96	0.02
Posterior tibial	0.75	0.10	0.89	0.06
Anterior tibial	0.80	0.08	0.91	0.04
Peroneal	0.69	0.10	0.77	0.09

(Kw=group weighted kappa, SE=standard error)

8.6. VASODILATORY INFLUENCE; Consistency of Percutaneous Needle Puncture Group: CA prior to IADSA

In the first 42 patients who underwent arteriography by percutaneous needle puncture of the femoral artery, CA was first performed according to routine procedure, followed by adjunctive IADSA of knee and lower leg/ankle region. The total number of arteries judged was 42 popliteal, posterior tibial, anterior tibial and peroneal arteries. This section presents the results with regards to the interpretability of the arteries, and the consistency (Kappa values) in judging

the multicategorical Angioscore, 50% stenosis and occlusion. The results are presented in graph form for easier comparison; the numeric Kappa values can be found in the tables.

8.6.1. Number of interpretable arteries

Interpretations of all four observers together showed a difference in the number of interpretable arteries for CA and IADSA separately: 36 CA and 42 IADSA popliteal, 27 CA and 40 IADSA posterior tibial, 26 CA and 40 IADSA anterior tibial, 23 CA and 40 IADSA peroneal arteries (Figure 8.17). In each artery group, CA showed a significantly higher number of non-interpretable arteries than IADSA ($p<0.05$). The statistical significance of the difference between CA and IADSA was calculated with the Fisher exact probability test.
Interpretations of all four observers together showed the following number of arteries which were judged interpretable for CA as well as IADSA: 36 popliteal, 26 posterior tibial, 25 anterior tibial, and 22 peroneal arteries (Figure 8.17).
The (weighted) Kappa values were computed only for this last group of interpretable arteries for both CA and IADSA.

8.6.2. Multicategorical Angioscore

A comparison of interobserver agreement between CA and IADSA using group weighted Kappa values showed good to excellent agreement for all arteries ($K \geq 0.61$, see 7.6.4).
For each artery, weighted Kappa was higher for IADSA, but the difference between CA and IADSA was not statistically significant (Table 8.8; Figure 8.18).

8.6.3. 50% Stenosis

A comparison of interobserver agreement between CA and IADSA in the interpretation of a hemodynamically significant stenosis (50%) showed good to excellent agreement ($K \geq 0.61$) for all arteries in IADSA and for three arteries in CA. In CA, there was fair agreement ($K = 0.55$) for the posterior tibial artery.
For each artery the Kappa value was higher for IADSA than for CA, but the difference between CA and IADSA was not statistically significant (Table 8.9; Figure 8.19).

8.6.4. Occlusion

A comparison of interobserver agreement between CA and IADSA in the interpretation of occlusion showed good to excellent agreement ($K \geq 0.61$) for all arteries.
The kappa value was higher for CA ($K = 0.96$) than for IADSA ($K = 0.94$) of the popliteal artery, higher for IADSA ($K = 0.87$) than for CA ($K = 0.73$) of the

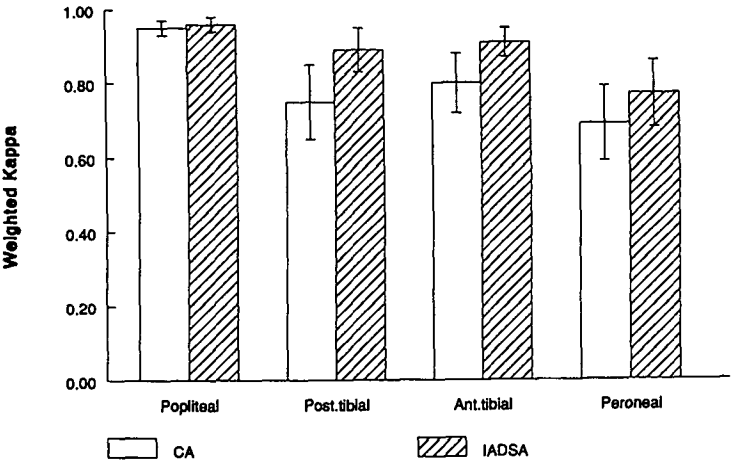

FIGURE 8.18.
Interobserver agreement for the subgroup in which CA was performed before IADSA (CA-IADSA) for the multicategorical Angioscore. The differences between CA and IADSA were not statistically significant.

Table 8.9. Comparison of 50% stenosis for CA prior to IADSA

	CA		IADSA	
Artery	K	SE	K	SE
Popliteal	0.82	0.08	0.85	0.07
Posterior tibial	0.55	0.17	0.76	0.22
Anterior tibial	0.69	0.11	0.70	0.13
Peroneal	0.61	0.11	0.70	0.11

(K=group kappa, SE=standard error)

posterior tibial artery and higher for IADSA (K = 0.96) than for CA (K = 0.83) of the anterior tibial artery. The kappa values for the peroneal artery were equal. The differences between CA and IADSA were not statistically significant (Table 8.10; Figure 8.20).

8.7. VASODILATORY INFLUENCE; Consistency of Percutaneous Needle Puncture Group: IADSA prior to CA

In a group of 18 consecutive patients who underwent arteriography with a percutaneous needle puncture of the femoral artery, IADSA was first per-

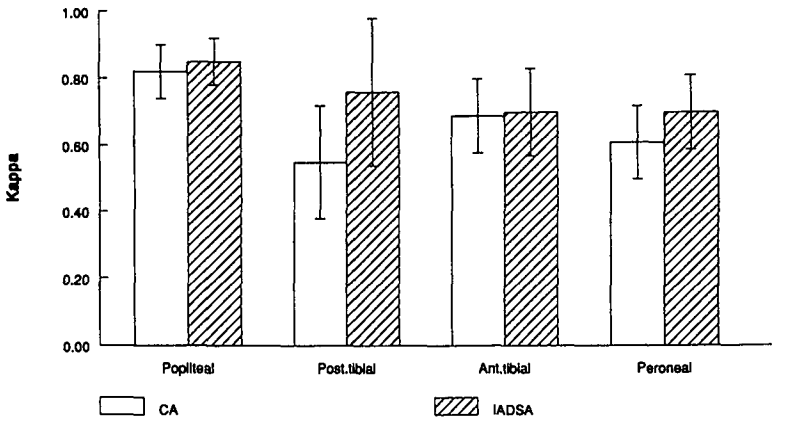

FIGURE 8.19.
Interobserver agreement for the subgroup CA-IADSA for a hemodynamically significant stenosis (50%). The differences between CA and IADSA were not statistically significant.

Table 8.10. Comparison of occlusion for CA prior to IADSA

	CA		IADSA	
Artery	K	SE	K	SE
Popliteal	0.96	0.04	0.94	0.04
Posterior tibial	0.73	0.10	0.87	0.08
Anterior tibial	0.83	0.08	0.96	0.04
Peroneal	0.73	0.10	0.73	0.10

(K=group kappa, SE=standard error)

formed for the knee and lowerleg/ankle region, followed by routine CA with stepping procedure. The total number of arteries judged was 18 popliteal, posterior tibial, anterior tibial, and peroneal arteries. This section presents the results with regards to the interpretability of the arteries, and the consistency (Kappa values) in judging the multicategorical Angioscore, 50% stenosis and occlusion. The results are presented in graph form for easier comparison; the numeric Kappa values can be found in the tables.

8.7.1. Number of interpretable arteries

Interpretations of all four observers together after listwise deletion of non-interpretable arteries showed a difference in the number of interpretable arteries for

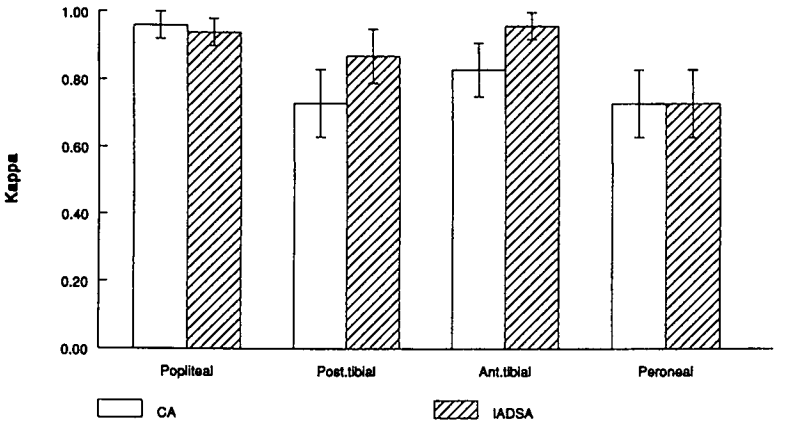

FIGURE 8.20.
Interobserver agreement for the subgroup CA-IADSA for an arterial occlusion. The differences between CA and IADSA were not statistically significant.

CA and IADSA separately: 18 CA and 18 IADSA popliteal, 13 CA and 17 IADSA posterior tibial, 10 CA and 18 IADSA anterior tibial, 14 CA and 17 IADSA peroneal arteries (Figure 8.21). The popliteal was equally interpretable for CA as for IADSA. In the crural arteries, CA showed a higher number of non-interpretable arteries than IADSA, but only the difference for the anterior tibial artery was statistically significant ($P<0.05$).
Interpretations of all four observers together showed the following numbers of arteries judged interpretable for CA as well as IADSA: 18 popliteal, 13 posterior tibial, 10 anterior tibial, and 14 peroneal arteries (Figure 8.21).
The (weighted) Kappa values were computed only for this last group of interpretable arteries, for both CA and IADSA.

8.7.2. Multicategorical Angioscore

A comparison of interobserver agreement between CA and IADSA using weighted Kappa values showed good to excellent agreement ($K \geq 0.61$) for all arteries with IADSA and excellent agreement ($K \geq 0.81$, see 7.6.4) for two arteries with CA i.e. the popliteal and posterior tibial arteries. Fair agreement was found for the anterior tibial ($K = 0.44$) and peroneal arteries ($K = 0.56$) of CA.
Weighted Kappa was higher for CA than for IADSA of the posterior tibial artery, but there was no statistically significant difference. Weighted Kappa was higher for IADSA (0.78) than for CA ($K = 0.44$) of anterior tibial artery and the difference was statistically significant ($p<0.05$) (Table 8.11; Figure 8.22).

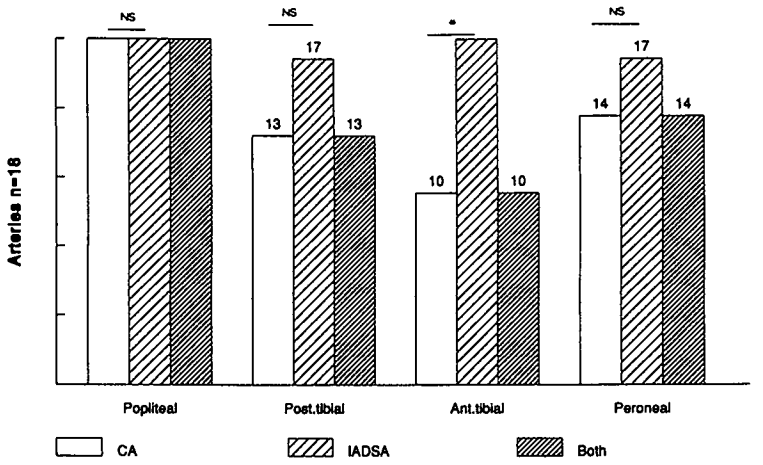

FIGURE 8.21
Numbers of interpretable arteries judged by all four observers for the subgroup IADSA-CA. CA = conventional arteriography, IADSA = intraarterial digital subtraction angiography, statistical significance of difference * = $p<0.05$, NS = not significant. Both = arteries judged interpretable in CA and IADSA in the same extremity: only these arteries were used in the consistency calculation.

Table 8.11: Comparison of Angioscore for IADSA prior to CA

	CA		IADSA	
Artery	Kw	SE	Kw	SE
Popliteal	0.83	0.11	0.85	0.10
Posterior tibial	0.99	0.01	0.96	0.03
Anterior tibial	0.44	0.11	0.78	0.06*
Peroneal	0.56	0.11	0.67	0.15

(Kw=group weighted kappa, SE=standard error); *$p<0.05$

8.7.3. 50% Stenosis

A comparison of interobserver agreement between CA and IADSA in the interpretation of a hemodynamically significant stenosis (50%) showed good to excellent agreement (K 0.61) for the popliteal, posterior tibial and peroneal arteries with IADSA and for the popliteal and posterior tibial arteries with CA. Kappa was higher for CA (K = 0.71) than for IADSA (K = 0.63) of the popliteal artery, and higher for CA (K = 1.00) than for IADSA (K = 0.89) of the posterior tibial artery, but there was no statistically significant difference. Both CA and IADSA showed fair agreement (K = 0.48) for the anterior tibial artery, while

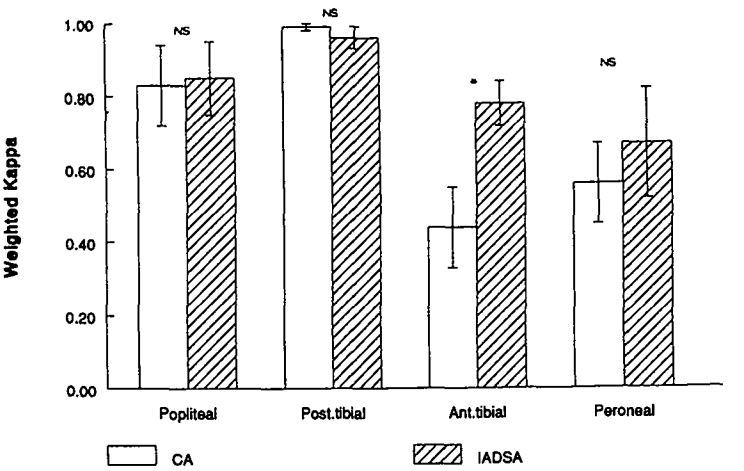

FIGURE 8.22.
Interobserver agreement for the subgroup in which IADSA was performed before CA (IADSA-CA) for the multicategorical Angioscore. The difference between CA and IADSA of the anterior tibial artery was statistically significant *$p<0.05$; the differences with regard to the other arteries were not statistically significant (NS).

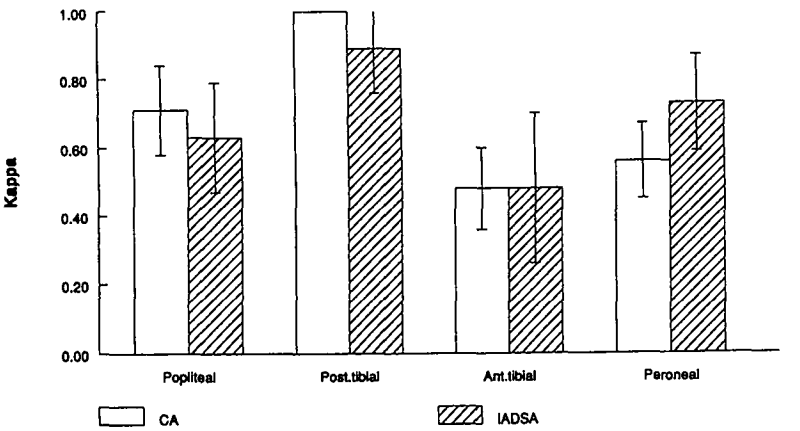

Figure 8.23.
Interobserver agreement for the subgroup IADSA-CA for a hemodynamically significant stenosis (50%). The differences between CA and IADSA were not statistically significant.

Table 8.12. Comparison of 50% stenosis for IADSA prior to CA.

	CA		IADSA	
Artery	K	SE	K	SE
Popliteal	0.71	0.13	0.63	0.16
Posterior tibial	1.00	-	0.89	0.13
Anterior tibial	0.48	0.12	0.48	0.22
Peroneal	0.56	0.11	0.73	0.14

(K=group kappa, SE=standard error)

Kappa for IADSA (K = 0.73) was higher than for CA (K = 0.56) of the peroneal artery, but there was no statistically significant difference (Table 8.12; Figure 8.23).

8.7.4. Occlusion

A comparison of interobserver agreement between CA and IADSA showed good to excellent agreement agreement (K ≥0.61) for all arteries with IADSA and excellent agreement (K 0.81) for the popliteal and posterior tibial arteries with CA. Poor to fair agreement (K = 0.21-0.60) was found for the anterior tibial and peroneal arteries with CA.
Kappa was equal for IADSA and CA of the posterior tibial artery (K = 1.00), but higher for IADSA than for CA of the other three arteries. The difference between CA (K = 0.38) and IADSA (K = 0.89) for the anterior tibial artery was statistically significant ($p<0.05$), while the differences between the posterior tibial and peroneal arteries were not significant (NS) (Table 8.13; Figure 8.24).

8.8. COLLATERALS

Evaluation of collaterals to or from each of the arteries mentioned was performed from the start of the study in the arteriograms described in 8.1. Judging was therefore performed for 65 right legs and 70 left legs, with a total of 135 popliteal, posterior tibial, anterior tibial and peroneal arteries.

8.8.1. Interpretable arteries

Interpretations of all four observers together showed the numbers of interpretable arteries for CA and IADSA separately as described in 8.2.1 and Figure 8.3. Interpretations of all four observers together showed the following number of arteries which were judged interpretable for CA as well as IADSA: 107 popliteal, 68 posterior tibial, 53 anterior tibial and 54 peroneal arteries (Figure

Table 8.13. Comparison of Occlusion for IADSA prior to CA.

	CA		IADSA	
Artery	K	SE	K	SE
Popliteal	0.92	0.08	0.94	0.06
Posterior tibiaL	1.00	-	1.00	-
Anterior tibial	0.38	0.17	0.89	0.11*
Peroneal	0.50	0.11	0.65	0.16

(K = group Kappa, SE=Standard error); *p< 0.05

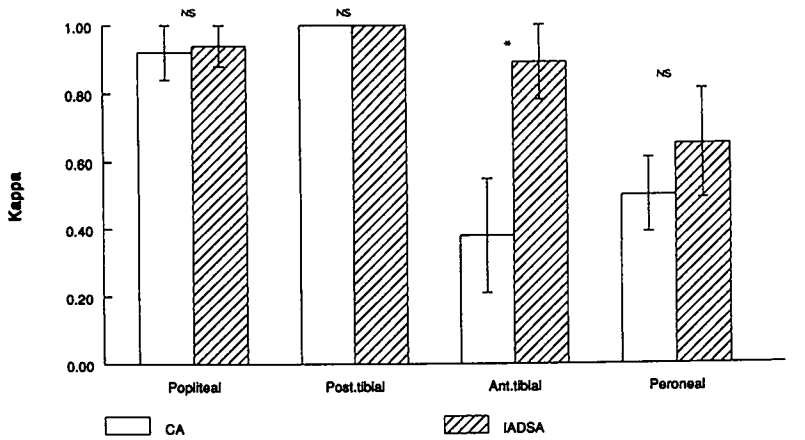

FIGURE 8.24.
Interobserver agreement for the subgroup IADSA-CA for an arterial occlusion. The difference between CA and IADSA of the anterior tibial artery was statistically significant (p<0.05). NS = not significant.

8.3). The Kappa values were computed only for this last group of interpretable arteries for both CA and IADSA.

8.8.2. Consistency of collaterals with CA and IADSA

A comparison of interobserver agreement between CA and IADSA in the interpretation of collaterals showed fair agreement with regard to the popliteal artery (K = 0.49) and poor agreement for the three lower leg arteries with CA (K = 0.21-0.40, see 7.6.4) With IADSA there was fair agreement with regard to the popliteal, anterior tibial, and peroneal arteries (K = 0.41 -0.60), but poor agreement with regard to the posterior tibial artery (K = 0.37). Kappa was

Table 8.14. Comparison Collaterals CA and IADSA

	CA		IADSA	
Artery	K	SE	K	SE
Popliteal	0.49	0.06	0.51	0.06
Posterior tibial	0.28	0.06	0.37	0.07
Anterior tibial	0.38	0.08	0.53	0.08
Peroneal	0.33	0.07	0.49	0.07

(K=group kappa, SE=standard error)

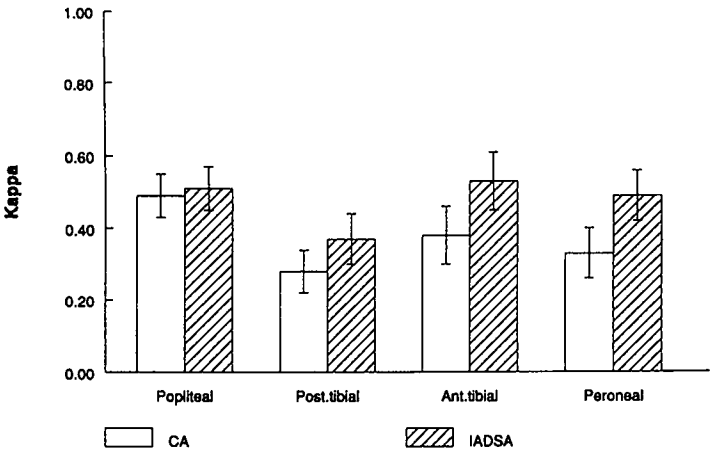

FIGURE 8.25.
Interobserver agreement for the total study group for the observation of collaterals. The differences between CA and IADSA were not statistically significant.

higher for IADSA than for CA of all four arteries, but the difference was not statistically significant (Table 8.14; Figure 8.25).

8.9. GRAFTABILITY

The evaluation of graftability (52 patients) was based on 34 arteriograms of right legs and 36 angiograms of left legs, with a total of 70 popliteal, posterior tibial, anterior tibial, and peroneal arteries available for judging. This was the same group of patients on whom the quality assessment was based.

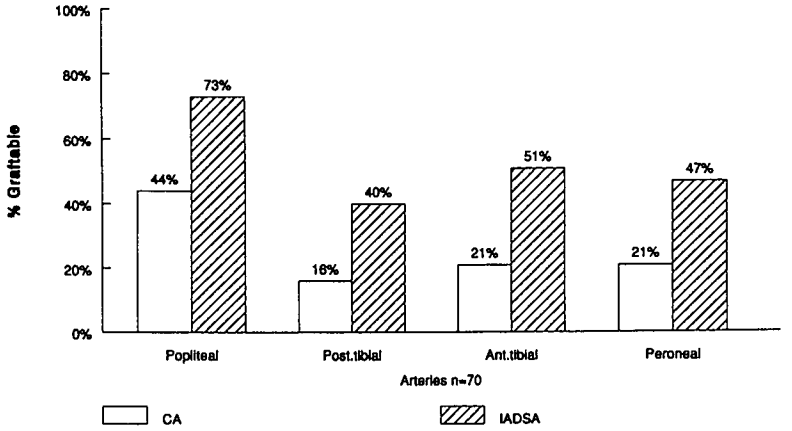

FIGURE 8.26.
Interpretation of the graftability of arteries by two vascular surgeons. The % graftable indicates arteries judged graftable by both surgeons.

Table 8.15: Graftability Score for CA vs IADSA

Arteries (n=70)	CA	IADSA
Popliteal	31 (44%)	51 (73%)
Posterior tibial	11 (16%)	28 (40%)
Anterior tibial	15 (21%)	51 (51%)
Peroneal	15 (21%)	33 (47%)

8.9.1. Graftability score

At the film reading sessions the two vascular surgeons had to judge whether they considered the popliteal, posterior tibial, anterior tibial, and peroneal arteries amenable to grafting, non-graftable or non-interpretable (see 7.5.6).
Both surgeons in consensus judged a greater number of arteries graftable with IADSA than with CA, in all of the lower leg arteries. In the crural arteries specifically, more than twice as many arteries were judged graftable with IADSA than with CA (Table 15, Figure 8.26).
One must remember that this judgement indicates only a suggestion of graftability on blinded films, without knowledge of patient history or noninvasive test results. In the actual clinical setting, these last two factors also play an important role in accepting patients for a vascular bypass or angioplasty. Nevertheless, the arterial "road-map" on the angiogram still plays a decisive role in planning the best therapeutical procedure.

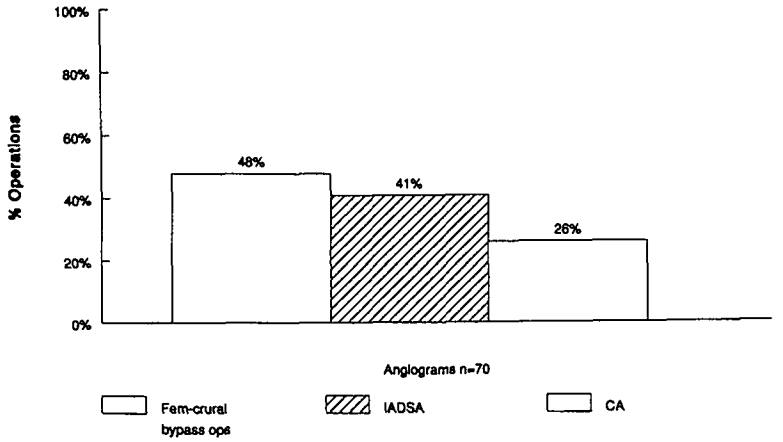

FIGURE 8.27.
Correlation of judged graftability on angiogram with the actual femoro-crural bypass (Fem-crural bypass ops).

Table 8.16: Correlation of judged graftability with actual grafting

Total number of angiograms:	70
Total number of operations:	42/70 (60%)
Femoro-crural bypass operations	20/42 (48%)
Other operations:	22/42 (52%)
(amputations, aortic grafts, etc)	
Judged graftability of crural arteries	
compared with actual femoro-crural bypass operation	
- positive correlation with CA:	11/42 (26%)
- positive correlation with IADSA:	17/42 (41%)

8.9.2. Correlation between judged graftability and actual grafted artery (see 7.5.6)

Of the 70 legs for which an arteriogram had been made, only 42 underwent an operation (no angioplasty) according to the operation records. Twenty of these 42 legs (48%) underwent a femoro-crural bypass operation, with a venous graft to a patent posterior tibial, anterior tibial or peroneal artery (Table 16, Figure 8.27).
On comparing these twenty femoro-crural bypass legs (48% of the total operations performed) with the scores of judged graftability of this study, the following results were found.

In IADSA: 17 (41%) of the 20 crural arteries which were actually grafted, had also been considered amenable to grafting by the two surgeons. This value closely approximates the 48% of the actual number of femoro-crural bypasses. In CA: 11 (26%) of the crural arteries which were actually grafted, had also been considered amenable to grafting in this study. This value is considerably lower than the 48% actually grafted arteries.

In surgical practice, this could mean that more arteries will be found amenable to grafting with IADSA than with CA.

9. CONSISTENCY STUDY:

Discussion of results

The necessity to visualize the arterial system of the lower leg has increased with the advent of microvascular surgical techniques and small-vessel angioplasty. The surgical literature contains numerous references to poor visualization of the lower leg with CA[K1,M29,O4]. According to recent literature reports, it seems possible to use IADSA to visualize flow in crural arteries in obstructive arterial disease, which were not visualized with CA[A7,T9]. An important implication of this possibility is that limbs which used to be candidates for an amputation, could now be candidates for a vascular bypass operation[S5] or percutaneous transluminal angioplasty[S31]. The purpose of this study was therefore to compare CA, as performed routinely in our clinic, with the new technique of IADSA, by determining the relative difference in the evaluation of vessel visualization (interpretability) and stenoses. One should not interpret this study as one in which CA is used as the gold standard for aorto-iliac and lower extremity arteriography. Important problems arise if the reference examination, or "gold standard", is itself subject to significant error, as suggested by the literature concerning CA. Any diagnostic method that is then compared to the reference examination will always be shown to produce inferior results if the reference examination is considered infallible[B32,G15]. During this study, no serious complications were ascribed to the use of IADSA. As an imaging modality, IADSA is reckoned to be safe, with a low rate of systemic and neurologic complications[W15].

The most striking observation in this study was the number of non-interpretable examinations with CA compared to IADSA after a first single bolus contrast injection, in the assessment of the crural arteries (Figures 8.5, 8.6, 8.7). This assessment was in most cases not based on the interpretation of one observer, but on that of two or more observers. This applied to the total study group as well as the group in which CA was performed before IADSA, or that in which IADSA was performed before CA (Figures 8.3, 8.17, 8.21). The popliteal artery was judged non-interpretable in far fewer cases (Figure 8.4).

The causes mentioned in the literature for these non-interpretable examinations with CA, have been described in chapter 4, and are mainly related to problems relating to blood flow (low contrast resolution) and bone superposition, especially in crural arteries. They are confirmed in this study by the results of our quality evaluation (Figure 8.8, 8.9, 8.10, 8.11). Campbell et al[C28] demon-

strated Doppler signals in 82% of vessels that had not been demonstrated by their standard conventional angiograms. Dardik et al[D5] noted in their paper that two thirds of patients with failure of crural vasculature on the basis of CA, could be further assessed by IADSA with qualitative interpretation comparable to CA.

As mentioned previously in chapter 6, a number of studies have attempted to compare IADSA with CA of the lower limb in patients with vascular insufficiency[F28,G2,H24,S17,S32]. However, all such studies have, at least in part, compared IADSA and CA in different patients. A recent report by Smith et al[S46] was based on a study approach similar to the present one, comparing vessel visualization and grade of stenosis between CA and IADSA in the same patients. These authors attribute the problem of noninterpretable CA to the poor quality of CA, and not to the superior quality of IADSA. In their opinion, suboptimal CA examinations mentioned in other studies are caused by using "aortic flush angiography" (= Seldinger catheterization with pigtail catheter or TLA), which usually does not optimally opacify vessels below the knee in patients with atherosclerotic lower limb insufficiency.

Smith et al[S46] prospectively compared IADSA and CA of the lower limb in fifty patients for an evaluation of arterial stenosis and the degree of arterial visualization of specific anatomic sites. These sites consisted of the common femoral, superficial femoral, popliteal, anterior tibial, posterior tibial, peroneal, and dorsal pedal arteries and bypass grafts. In their study, contrast medium was injected into the external iliac artery with a catheter, similar to our percutaneous needle puncture (PNP) technique, the initial angiogram being alternated between studies. However, all patients were given intravenous sedation[C14], and reactive hyperemia was induced in the lower limb, two techniques which were not used in our study. The films were reviewed blindly by two different experienced angiographers (observers), as opposed to four observers in our study.

They found no significant differences in vessel visualization for examiner selected sites or for either observer for the entire lower limb or at specific anatomic sites. They concluded that optimal-quality CA and IADSA produced virtually equivalent results for angiography of the lower limb for both grade of stenosis/occlusion and vessel visualization.

Their results do not quite coincide with our findings of vessel visualization in PNP angiograms (figure 8.17 and 8.21), in which vessel visualization was significantly inferior with CA as compared to IADSA. It is true that not all our CA's were of an optimal quality, but we compared single bolus CA with single bolus IADSA. An optimal CA often requires repeat examinations with large amounts of contrast medium and film material and is time consuming[A12, S39,S46]. Overall, we also found inferior vessel visualization with CA as compared to IADSA in aortic-flush angiography (TLA and aortic catheter) with a first single bolus injection of contrast medium.

After a single bolus injection of contrast medium, more crural vessels were interpretable with IADSA in this study, because this resulted in a higher contrast resolution, immediate subtraction and real-time imaging, i.e. it was possible to follow the flow of contrast medium on the monitor and select optimal images (with the help of post-processing) for hard-copies. It is important to note that one of the determinants for the vascular surgeon to request a lower extremity angiogram is an A.B.I.<0.6., which in this study was the case in 58% of the lower extremities (figure 8.12). All the non-interpretable crural arteries (CA and IADSA) in this study were found in extremities with a critical mean ankle-brachial index <0.6, indicating severe occlusive arterial disease, and these are precisely the legs for which optimal visualization of vessels is required (Figure 8.13). From Figure 8.3 it is evident that a much larger number of arteries was noninterpretable with CA as compared to IADSA. In comparing the number of noninterpretable crural arteries with CA in legs with an A.B.I. <0.6 with the number of noninterpretable crural arteries with CA in legs with A.B.I.>0.6, no significant difference could be found. The slight differences actually suggest more noninterpretable crural arteries with A.B.I. >0.61, and especially more noninterpretable popliteal arteries. This finding is difficult to explain. A possible explanation could be that in bilateral CA a more rapid bloodflow is present in the leg with less serious disease with A.B.I. >0.6, and the moment of film exposure is too late to capture optimal contrast vizualisation of the artery.

In a situation outside the protocol of this study, the angiographer would have repeated the examination with a second or perhaps even a third bolus injection in order to achieve optimal visualization of the crural vessels with CA. This would make it necessary to alter the time delay between injection and films, or perhaps to perform conventional subtraction. This would require a fair amount of extra contrast medium, time, film material, and radiation exposure, and even then, an optimal or successful visualization of crural arteries is not guaranteed.

A flaw in the present study is the fact that CA and IADSA were performed by the same angiographer on the one patient, instead of using a different angiographer for CA and IADSA. This has, without doubt, caused bias during the angiographic examinations. The reason for using one angiographer for both examinations has been explained in chapter 7.

In order to exclude bias in the film interpretation as much as possible, the films were blinded as to name and date of birth of patients, and no information was given on patient history or noninvasive test results. Film reading sessions were performed at least three months after angiography in order to prevent observer recall, and four observers independently judged the films. These are accepted methods for minimising bias in comparing imaging procedures[B1,B32].

Statistical analysis of interobserver agreement was only performed on interpretable arteries scored by all four observers, for CA as well as IADSA of the same lower leg. The relative difference in the evaluation of stenoses was determined on the basis of a standard grading scale (Angioscore). Grading the

degree of stenosis on the basis of arteriography has been the subject of much controversy in both radiology, surgery and cardiology literature[B42,K2,Z6]. The stenosis grading system chosen in this study is similar to the categories proposed by Morton et al[M16], and is also based on research by Thiele and Strandness-[T5]. The observers were asked to pick the most stenotic areas in each vessel and mark these on a scoring form.

The consistency of both techniques in imaging atherosclerotic disease of arteries of the lower leg was evaluated by comparing the interobserver agreement for CA with that for IADSA. As was mentioned in chapter six, the literature decribing comparisons between CA and DSA of peripheral vasculature is very scanty, and it is therefore difficult to compare these results with those of other studies.

Kappa statistics have been used to express the consistency of several radiologic diagnoses, other than vascular diseases. Kappa values higher than 0.80 indicate excellent agreement, and 0.40-0.80 fair to good agreement. Values of around 0.84 have been found in mammographic demonstration of breast carcinoma-[M32], and values of 0.73 in gastric ulcer by double-contrast examinations[G3]. Agreement on the possible malignancy of a gastric ulcer has been found to be as low as -0.04[G26]. Kappa values for signs on abdominal radiographs[M33] and for chest radiographic signs of aortic rupture[M34] vary from 0.04 to 1. The detection of pulmonary venous hypertension on chest radiographs showed only moderate agreement, with an average Kappa value of 0.55[N9]. Moderate interobserver agreement was also found in the assessment of ocular signs in coma[B43].

In vascular disease, the study of observer variability has mainly concentrated on carotid angiograms[C9,L2,M35,V11]. Langlois et al.[L2] noted an interobserver agreement of Kappa = 0.57 when two different angiographers read the same 128 carotid angiograms. Moll et al.[M35] divided carotid artery lesions into five categories of stenosis, similar to our study, and found kappa values ranging from 0.53 to 0.91.

Marked interobserver variability was also noted in the evaluation of coronary angiograms[D14,D15,G7,Z6], although no exact comparison with these studies is possible due to different statistical methods and radiological techniques.

In a study of single plane aortography (CA), poor interobserver agreement was found on the degree of arterial stenosis from aorta to ankle level, but the author also mentioned the inadequate visualization of the lower leg due to inadequate timing and dilution of contrast material as a reason[B42]. This comment coincides with our results on the interpretation of the quality of the angiograms (see 8.3).

In the present study, interobserver agreement, expressed as a weighted kappa or kappa value, was calculated for the interpretation of a multicategorical Angioscore, 50% stenosis, occlusion, and collaterals in the total group of angiograms. Popliteal arteries showed no significant difference in interobserver agreement between CA and IADSA. Crural arteries showed a trend of slightly higher interobserver agreement for IADSA than for CA. The majority of Kappa

values showed a higher value for IADSA than for CA, but only three differences were statistically significant (figures 8.16, 8.22, 8.24) for the anterior tibial artery. For the crural ateries, two Kappa values were higher for CA than for IADSA (figure 8.22, 8.23), but the differences were not statistically significant. Three Kappa values were equal for CA and IADSA (figures 8.20, 8.23, 8.24).
Smith et al.[S46] found that IADSA sites were judged to be slightly more narrowed ($p<0.05$) in the superficial femoral artery by two observers and in the common femoral artery, bypass graft, and overall by a single observer. No other significant differences were found in the grade of stenosis for examiner selected sites. For observer selected sites, observers agreed on the location of the most stenotic site 76% of the time for CA and 69% of the time for IADSA. No significant difference was found in the grade of stenosis for either observer for the entire lower limb or at specific anatomic sites.
Smith et al. concluded that optimal quality CA and IADSA produced virtually equivalent results for angiography of the lower limb for both the grade of stenosis/occlusion and vessel visualization in single limb arteriography. Their study did, however, use a different statistical analysis method than Kappa.
In our study no evaluation was performed of upper leg arteries and we performed aortic flush as well as single limb angiography. Assessment of the possible influence of vasodilatation by contrast medium on film interpretation was performed in our study in two subgroups of patients in whom IADSA was performed before or after CA. These two groups only underwent single limb arteriography, which allows some comparison to be made with the results of Smith et al[S63] (see 8.6 and 8.7).
In our study the consistency of stenosis/occlusion grading in single limb angiography was significantly higher ($p<0.05$) for IADSA than CA of the anterior tibial artery (figure 8.22, 8.24), if IADSA was performed before CA. The other results of stenosis/occlusion grading of the crural arteries were not significantly different, but did show a general trend in favour of IADSA (figure 8.18, 8.19, 8.20, 8.22, 8.23, 8.24). A general trend of higher consistency for IADSA was also noted in the interpretation of collaterals, but the differences were not statistically significant. The consistency was evaluated only for those patients who had interpretable examinations for CA as well as IADSA of the same lower leg. Compared to Smith et al, our results show a slight advantage for IADSA as compared to CA. On the basis of these results it is also safe to say that if any vasodilatation has been caused by contrast medium, it has had little or no influence on the interpretation of the arteries in the study.
Comparison studies between multiformat matrix camera images, Laser electronic image recording and conventional radiographs are very scanty. In one paper, the receiver operating characteristic (ROC) analysis showed little difference in radiologists' responses, whether they were reading conventional chest X-rays or 1024x1024 laser-printed digital radiographs for the detection of lung nodules[T13]. Discussions with the observers during the film reading sessions showed that the Laser Imager films were regarded as very easy to

interpret, more so than the matrix camera films. Because of its many advantages, like low optical distortion, high spatial and contrast resolution, and the sharing of a single Imager between several systems for recording digital data, it is anticipated that Laser Imagers will be commonplace in future radiology departments.

Although the decision to perform a bypass graft in the extremity of a patient is not made solely on the basis of angiography in daily surgical practice, an interpretation was performed by the vascular surgeons in judging which vessel was considered amenable to grafting on the basis of the arteriogram alone. In practice, the visualization of a graftable artery can be a decisive factor to go ahead with a bypass operation, especially in limb salvage cases if an amputation is to be prevented[S5].

In this study, a greater number of arteries, popliteal as well as crural arteries, were judged amenable to grafting with IADSA than with CA (Figure 8.26). According to the operation records, 48% of the operations performed were femoro-crural bypasses. In correlating the actually grafted artery with the arteries judged graftable by CA in this study, CA would theoretically have suggested only 26% femoro-crural bypasses. However, in correlating the actually grafted artery with the arteries judged graftable by IADSA, 41% femoro-crural bypasses would have been performed for the same artery, which approaches the percentage of bypasses actually performed (Figure 8.27).

This coincides with findings in other studies, in which adjunctive IADSA showed graftable arteries which were not visualized by CA[B44,D5,T9]. In one report, 70% of the patients underwent distal artery bypass because of additional information provided by IADSA only[T9]. In another report[D5], successful revascularization was subsequently obtained in 75% (40 of 53 patients).

In the present study more bypasses were performed on the basis of IADSA film findings compared to CA film findings.

10. PATIENT RADIATION DOSES IN LOWER EXTREMITY ARTERIOGRAPHY

Comparison between IADSA and CA

10.1. INTRODUCTION

The total radiation dose to the patient is a result of patient exposure to X-rays during the use of all imaging techniques. The contribution of each imaging mode depends on many factors, such as tube voltage, field size, beam position and direction, and beam filtration. So far, published dose data related to peripheral angiography and patient exposure has been scarce[H30,M9,L8,P2]. The introduction of DSA produced little extra data on radiation dose to e.g. water phantoms[H23] and cranial vessels[P8,P20]. This lack of data is probably related to the complex nature of angiographic examination. Similarly, very little recent data is available on radiation exposure of the radiologist during angiography-[B46,R8,S2,T7], especially as regards DSA[B11].
The purpose of this part of the study is to report the entrance dose of radiation exposure of the patient in lower extremity arteriography and to compare the two techniques. In radiological protection the effective dose is now generally used as the measure of objective health detriment[U1]. In dosimetric studies, the entrance dose is used to calculate organ doses and the effective dose[H30,M9]. The calculation of these latter values is beyond the scope of this thesis.

10.2. DOSE-AREA PRODUCT (DAP) AND ENTRANCE DOSE

The concept of dose-area product (DAP) or exposure-area product was first introduced in the late 1950s. Experimentally it has been demonstrated that in general diagnostic X-ray applications, the DAP is proportional to the energy absorbed by the patient[P19]. Later studies demonstrated that the DAP can be used to determine the energy imparted to the patient with accuracies of 5-10%[H17,S51]. The DAP is particularly useful in determining the total energy imparted to the patient in procedures in which the position of the X-ray beam and the field size vary, such as in fluoroscopic and cine procedures. Since the

total energy imparted and the effective dose are related, DAP can be related to the quantitative effective dose as well. Studies using DAP measurements for comparison purposes have been reported[B41,K22,L14]. In this study DAP has been used to estimate the entrance dose.
The entrance dose ($D_{entrance}$), which is the absorbed dose free in air at the beam entrance position, is derived from measurement results for the dose-area product, diaphragm opening and focus-to-skin distance, according to[K36]:

$$D_{entrance}\,(mGy)^{*} = 10 \times DAP \times \frac{1}{area} \times \left(\frac{1}{FSD}\right)^{2}$$

DAP: dose-area product (cGy.cm^2).
area: field size (cm^2) at 1 meter (m) distance from the focus derived from the diaphragm opening.
FSD: focus-to-skin distance (m). In this study, FSD is derived from the focus-to-image receptor distance, the geometrical enlargement factor and the isocentre position.

* The old unit of absorbed dose is the rad, which is the absorption of 10^{-2} joules of energy per kilogram of tissue. The SI unit for absorbed dose is the gray (Gy), which is one joule per kilogram. One Gy is the equivalent of 100 rad. One centigray (cGy), or 10^{-2} Gy, is the equivalent of one rad[C11]. Roentgen is the old unit of exposure, often quoted in early literature. The conversion factor for Roentgen to rad when using X-rays is 0.873[G20].

10.3. MATERIALS AND METHODS

To obtain the information needed for dose estimates of patients undergoing angiographic examinations, a dedicated system was developed for digital real-time recording of the dose-area product and relevant parameters of the X-ray systems in the angiographic suite (automated monitoring system). Although development is still going on, this system was first put into clinical practice in 1990 to obtain characteristic data on patient exposure conditions in lower extremity angiography[K36]. The first dose measurements as part of this study were carried out on 63 consecutive patients from September to December 1990 in the angiographic suite of the Department of Radiology of the University Hospital of Maastricht. In all, approximately 2,000 angiographic examinations are performed there each year. Approximately 15% of these examinations are classified as lower extremity arteriography. In the period of data collection, angiography was performed by seven radiologists.
For a detailed description of the angiography X-ray system and DSA add-on apparatus, see section 7.3 in chapter 7. From September to December 1990, the following data were recorded for fluoroscopy, DSA and CA separately: dose-area product (DAP), tube voltage and diaphragm settings. For each anatomical

position, fluoroscopy time, the number of DSA-frames, and the number of radiographs were recorded automatically as well. In addition, the patient's age and sex, radiologist, beam filtration and the anatomical position of the diagnostic images were taken from data sheets filled in by the technical staff.
Measurement data were collected by sampling electronic signals of the X-ray system (sampling frequency 3^{-1}s). Patient exposure conditions were recorded in a number of time intervals in which deviations of technical parameters were less than 10% of the current averages. Full details of this monitoring system have been published elsewhere[K36].
In the angiography suite four different imaging techniques are applied: fluoroscopy, conventional serial cut-film arteriography (CA), intravenous digital subtraction angiography (IVDSA) and intraarterial digital subtraction angiography (IADSA). Patients referred to the radiologist for a problem concerning only abdominal aorta, aorto-iliac vessels, femoral artery bifurcation, aortoprosthesis or femoro-popliteal bypass are generally examined with IVDSA (see 7.2). All other patients with problems concerning the aorto-iliac and peripheral vessels, or only peripheral vessels (femoro-popliteal and crural arteries) are examined with CA, followed by IADSA of the pelvis, knee and lower leg/ankle regions via the same arterial puncture site.
In most cases, lower extremity arteriographic procedures are performed via an intraarterial injection using percutaneous needle puncture (PNP) of the femoral artery, Seldinger catheterisation (of the femoral artery), or translumbar aortography. Standard projections consist of posterior-anterior views for the whole CA procedure, and right and/or left oblique views of the pelvis, followed by posterior-anterior views of the knee, and lower leg/ankle in IADSA. In some cases, views of the foot are also obtained.

10.4. RESULTS

Data of the 1990 examinations were collected for three common types of angiography of aorto-iliac and peripheral vessels: percutaneous needle puncture (PNP), Seldinger catheterisation and IVDSA. PNP and Seldinger catheterisation involve fluoroscopy, CA and IADSA. IVDSA involves fluoroscopy and IVDSA. Installation of the automated monitoring system for dosimetric studies took place during this year, and as was already mentioned above, dosimetric data could be recorded from September to December 1990 on 63 consecutive patients as part of this study.

10.4.1. Sex and Age

Statistics on patients' sex and age are given in table 10.1. Statistical data on examination type and patients' sex and age have been derived from a subset of 287 examinations (96%) of the 299 examinations performed in 1990. In 12

examinations, the patients' sex and age were not recorded in the monitoring system.
In 1990, 79% (226/287) of all lower extremity arteriographic examinations were carried out on males and 21% (61/287) on females. In the total PNP group, the ratio of males to females was comparable, with 76% (71/94) males and 24% 23/94) females.
In the dosimetric study group of PNP, the ratio of males to females was also comparable, with 76% (48/63) males and 24% (15/63) females.
In 1990, the mean ages of males and females in lower extremity arteriography were nearly equal. The average of the females was 66 and that of the males 64. These data show that patients referred to the radiologist for lower extremity arteriography are relatively old. This phenomenen has been found for all types of X-ray diagnostic examinations[B45], as well as lower extremity arteriography-[W11].
As is demonstrated in Table 10.1, the age distribution of the patients included in this dosimetric study was nearly equal to the corresponding distributions derived for 287 patients.

10.4.2. Frequency of lower extremity arteriography

The frequency of each examination type is given in Table 10.2. In 1990, IVDSA examinations were performed in 48%, PNP examinations in 34% and Seldinger catheterisations in 18% of patients. The relative frequency of PNP examinations in the dosimetric study is relatively high (54%). Because the purpose of this study was to compare CA and IADSA and not IVDSA, and because the majority of arterial examinations were PNP, the presentation of dosimetric results of lower extremity arteriography will concentrate on those of PNP procedures.

10.4.3. Diagnostic projections, images, fluoroscopy time

The number of different diagnostic projections and the total number of CA- and DSA-images in PNP angiography are given separately in Table 10.3. Typical values for the fluoroscopy time are included as well. On average, 3 to 4 different DSA projections were used, resulting in approximately 50 DSA-frames for a PNP examination.
The number of different projections in CA was almost always equal to five, in a posterior-anterior view. In most cases, 3 films were exposed in each projection, except for the foot, where sometimes only two films were exposed. Theoretically, the total number of films in CA is 14 to 15 per patient. As shown in Table 10.3, the average number of films was 12. The average fluoroscopy time was approximately 3 minutes.

Table 10.1. Mean age of patients for both males and females (fem.) in lower extremity arteriography in 1990 (data derived from 287 examinations)

	all examations			PNP		dosimetric study Sep-Dec		
	female	male	all	female	male	female	male	all
Mean age	66	64	64	70	66	67	63	64
Sample size	61	226	287	23	71	15	48	63

Table 10.2. Frequency of lower extremity arteriography in the University Hospital of Maastricht

Examination type	Exam. in dosimetric study	Exam. in 1990
PNP	34 (54%)	101 (34%)
Seldinger cath.	7 (11%)	53 (18%)
IVDSA	22 (35%)	145 (48%)
	+	+
	63	299

Table 10.3. Number of diagnostic projections (n_{DSA}, n_{CA}), diagnostic images ($n_{DSA\text{-}frames}$, $n_{CA\text{-}films}$) and fluoroscopy time (T) (mean $\pm$ ^{n}SD (median))

Procedure	#	nDSA	nDSA-frames	nCA	nCA-films	Tfluor (min)
PNP	34	3.2 ± 1.2 (3)	53 ± 30 (48)	5	12 ± 8 (13)	2.9 ± 1 (2.8)

= number of examinations

10.4.4. DSA-frames

Arteriography of one leg by PNP includes IADSA of the pelvis, thigh, knee, lower leg and sometimes the foot. The selection of DSA projections is based upon the anatomical findings in the course of the arteriographic procedure and upon the patient status. The number of DSA frames taken for each projection site is given in Table 10.4. These data show that an average of 12 to 15 DSA frames were taken per location. Each DSA run required a minimum value of approx. 6 DSA frames and a maximum of approx. 24 frames. The exception was the lower leg projection, which showed a much larger dispersion between minimum and maximum numbers of frames.

10.4.5. Frequency of DSA projections

As illustrated in Table 10.5, the relative frequency of specified projections differed significantly from 100%. This means that the procedure was not well standardized; the choice of DSA projections depended on patients' characteristics. This approach may be justified with respect to patient exposure since the total radiation dose resulting from "adjusted" examinations is smaller than the patient dose in a highly standardized procedure, in which unnecessary diagnostic views may be applied.
However, results of dose assessments for less standardized procedures are inaccurate if dose calculations are based on cumulative data related to the completed examination only. One should also keep in mind that individual patient exposure may deviate from typical values derived for groups of patients.
In the PNP group of 34 examinations from September to December 1990 (Table 10.2), a completely accurate match of DSA projections was found in **24** examinations, according to the dedicated monitoring system and the angiographic logbook. The logbook registration was incomplete in 10 examinations.

10.4.6. Dose-area product per imaging technique

Results of dose-area product measurements (DAP) per examination and per imaging technique are summarized in Table 10.6. These data show that the DAP value per examination varied considerably. The DAP value for a single examination might vary between a minimum of 200 and a maximum of 5200 cGy.cm2. The relative DAP contributions of fluoroscopy, DSA and CA varied considerably as well. On average, CA contributed ± 25% to the total DAP per examination, while IADSA and fluoroscopy each contributed 35-40% in the intraarterial approach by percutaneous needle puncture (PNP).

10.4.7. Dose-area product per diagnostic projection

Mean dose-area product (DAP) values for different projection sites during PNP arteriography are given in Table 10.7. DAP contributions of fluoroscopy (fluoro), DSA and CA are included separately for each site. In the PNP group of **34** examinations from September to December 1990, a complete accurate registration of DSA projections was found in only **24** examinations (see also Table 10.5). However, only **15** of these 24 examinations could be used to derive DAP for different projections.
It must be noted that the total number of examinations was quite small and that the variance in several measurement results was relatively large. This means that the uncertainty in the mean values derived is large and the representative value of these data is limited.

Table 10.4 Number of DSA frames at different anatomical locations during arteriography of one leg by PNP.

	Region				
IADSA	pelvis (obl.)	thigh (PA)	knee (PA)	lower (PA)	foot leg (PA+obl.)
mean	12	12	15	16	15
sd	5		5	10	5
minimum	7	8	7	9	6
maximum	19	15	24	43	23
sample size	11	3	10	10	22

obl. = oblique projection (30°); PA= posterior anterior projection; PNP = percutaneous needle puncture

Table 10.5 DSA-views in lower extremity arteriography (relative frequency per examination) by PNP.

		Region					
Procedure	#	iliac[1] (OBL)	thigh (PA)	knee (PA)	leg (PA)	foot (PA)	foot (LAT)
PNP	24	35%	15%	65%	80%	85	50%

= number of examinations; 1 = iliac: 65% two oblique views (left and right); 35% one oblique view (left or right); PNP = percutaneous needle puncture; LAT = lateral

Table 10.6 Distribution of Dose-area product (DAP; cGy.cm2) per examination and mean relative contribution of fluoroscopy (DAP-flu), DSA (DAP-DSA), conventional arteriography(DAP-CA) in lower extremity arteriography by PNP.

	DAP* ($cGy.cm^2$)	DAP-flu	DAP-DSA	DAP-CA
mean	1300.	34%	39%	27%
sd	1000	15%	25%	18%
median	1000	31%	42%	25%
minimum	200	13%	4%	0%**
maximum	5200	78%	84%	58%

* number of examinations = 34; ** no Puck films were taken in 6 out of 34 examinations; minimum value for DAP-CA of the subset of 28 examinations with Puck films is 14%

10.4.8. Field size of X-ray beam

Table 10.8 gives the average field sizes of the primary X-ray beam (in cm^2) at 1 meter distance to the focus for fluoroscopy (fluoro), CA and DSA. As shown in this table, relatively expanded field sizes were used for views of the pelvis region in all three imaging modes. The field size decreased if images were taken of smaller parts of the patient's body (thigh, knee, lower leg). Because of its anatomical shape, expanded field sizes were used for (oblique) images of the foot. Also, it was observed in clinical practice that, compared to X-ray projections of body parts adjacent to the trunk, less attention was paid to "fine" adjustment of the X-ray field for diagnostic images of the foot.

Significant variations in the percentage of the useful beam may require additional corrections if dose-area product data of "small" body parts are used for dose assessments, since a substantial part of the X-ray beam is not used for anatomical imaging. In general, large body parts require few corrections or no correction at all, whereas small body parts (foot, knee) may require an additional correction, depending on the settings of the X-ray beam diaphragm. For example, non-corrected DAP-values for the foot may overestimate the exposure of the foot by up to approximately 50%.

10.4.9. Entrance Dose in lower extremity arteriography

As was stated at the beginning of this chapter, the purpose of this part of the study was to report and compare the entrance dose of radiation exposure in CA and IADSA of the lower extremities (see 10.2).
From the data in Table 10.7 and Table 10.8, one can now calculate the mean dose at 1 meter distance from the focus, according to:

$$10 \times DAP \times \frac{1}{area}$$

Finally, the mean entrance dose ($D_{entrance}$) can be calculated by multiplying the mean dose at 1 meter from the focus with the factor $(1/FSD)^2$. The focus-to-skin distance (FSD) for DSA and Fluoroscopy is 65 cm, resulting in a factor 2.4. The average focus-to-skin distance for CA is estimated at 70 cm, resulting in a factor 2 (Table 10.9).

Table 10.7 Mean DAP values (cGy.cm^2) for different projections during lower extremity arteriography of one leg by PNP[1]

	Region						
Imaging mode	abdomen	pelvis	thigh	knee	lower leg	foot	all
fluoro	250	95	?	20	34	21	420 (27%)
DSA	-	598	100	50	38	41	827 (52%)
CA	-	136	83	50	30	30	329 (21%)
total	250 (16%)	829 (53%)	183 (12%)	120 (8%)	102 (6%)	92 (6%)	1576

(1): since measured data have been derived from a subset of 15 examinations, the total average value (1576) and the relative contributions of the imaging modes differ from the data presented in Table 10.6.

Table 10.8 Mean field size of the primary beam (in cm^2) at 1 meter distance from the focus for different projections during lower extremity PNP arteriography of one leg.

	Region					
Imaging mode	abdomen	pelvis	thigh	knee	lower leg	foot
fluoro	780	860	?	650	580	680
DSA	na*	800	640	680	600	730
CA	na*	880	740	700	680	770

* na = not applicable

Table 10.9. Mean entrance dose (in mGy) for different projections during lower extremity PNP arteriography.

	Region						
Imaging mode	abdomen	pelvis	thigh	knee	lower leg	foot	all
fluoro	8.4	2.9	?	.79	1.1	.79	14.0
DSA	-	18.0	3.8	2.0	1.8	1.4	27.0
CA	-	3.0	2.2	1.4	.86	.80	8.3
total	8.4	23.9	6.0	4.2	3.8	3.0	

10.5. DISCUSSION

Arteriography of vessels of one lower extremity involved fluoroscopy, radiography and IADSA for several parts of the patient's body. In CA, posterior-anterior radiographs were taken of regions of the pelvis, thigh, knee, lower leg and foot. Following the previous CA examination, posterior-anterior IADSA was performed of the knee, lower leg and foot. Additionally, oblique IADSA projections of the left or right pelvis region were performed.
From Table 10.7 one can see that the X-ray energy emitted (expressed as the quantity Dose Area Product) to produce images of the lower extremity (thigh: 12%, knee: 8%,lower leg: 6% and foot: 6%) for the whole examination was roughly estimated to be 1/3 (32%) of the total emitted energy. A larger part of the energy emitted was used for fluoroscopy and exposures of abdomen and pelvis region. From Table 10.9 one can see that the average entrance dose for the lower extremity varied between 3 mGy (foot) and 6 mGy (thigh) mGy, whereas the skin dose to the pelvis was estimated to be approximately 24 mGy. This means that the estimated entrance dose was one and a half to two times higher for IADSA than for CA per exposed region in the lower extremity. For the total examination, the mean entrance dose was approximately three and a half times higher for IADSA (27.0 mGy) than for CA (8.3 mGy), and a sizeable dose was also caused by fluoroscopy.
A comparison with results in the literature is practically impossible, because, as was already mentioned in the introduction, similar studies with comparable methodology and using CA and IADSA are extremely rare. The findings of the present study, however, do show a contradiction. In their evaluation of upper and lower extremity tumors, Lee et al.[L8] reported a slightly lower entrance dose for IADSA (5.4 Roentgen (R) = 47 mGy per examination) as compared to CA (5.6 R = 49 mGy per examination).
Another study by Passariello et al.[P2] using dosimeters based on thermoluminescence, simulated with an anthropomorphic phantom, reported a lower skin dose of 33% to 49% for IVDSA as compared to CA for lower extremity arteriography. Their report, however, did not specify entrance dose values but only gave a dose ratio value for DSA and CA. A few comparison studies of carotid angiography[P8,P20] also reported lower radiation doses for IVDSA as compared to CA.
A significant part of the X-ray examination (approximately two thirds) involves imaging of the abdomen and pelvis region. The emitted X-ray energy absorbed in the pelvis alone is approximately half (53%) of the total energy emitted (Table 10.7). In the pelvis region the entrance dose for IADSA was six times greater than for CA (Table 10.9). These values are not quite comparable, however, because in IADSA oblique projections of the pelvis are performed, while in CA the exposure is made in a posterior-anterior direction (see figure 7.4).
It is important to remember that the abdomen and pelvis region do contain a number of radiosensitive organs and tissues, and the radiological risk during

lower extremity arteriography is greater for these regions than for the lower extremity itself, whether it is CA or IADSA. In comparison with other diagnostic X-ray procedures, lower extremity arteriography does show one of the highest values for the effective dose equivalent[M9], and the radiologist should attempt to reduce fluoroscopy time, preliminary test exposures and image acquisition runs to a minimum.

Apart from the bone surface tissue of the legs and the red bone marrow in the end sections of the leg bones and in some foot bones, the lower extremities are relatively insensitive to ionising radiation. As shown in this study, lower extremity arteriography is mainly performed in older patients (> 60 years). Therefore, if additional IADSA images do reveal significant pathological abnormalities which could influence therapy, the use of IADSA in lower extremity arteriography, especially in the lower leg, may be justified.

11. A COST ANALYSIS OF CA AND IADSA

11.1. INTRODUCTION

In the past 20 years, medical technology has gone through a revolutionary development, which has resulted in an enormous increase in health care costs. In industrialized countries, diagnostic imaging makes up at least 5% or more of the national health expenditure[B17,F27,P17]. Social concern about the control of these costs makes the evaluation of medical technology effects inevitable[P17]. In a broad sense, cost-effectiveness analysis can be used to compare resources invested in a technology with allocations in other technologies. However, formal cost-effectiveness and cost-benefit analysis requires the creation of a complex decision tree that includes a variety of clinical as well as many types of cost data[P6,T6], and that is beyond the scope of this study. The literature is very scanty on cost data specifically concerning IADSA[G2,L8,N3]. Although DSA was originally introduced as a new method of intravenous angiography, studies on cost data of IVDSA are also very scarce[D9,F9,F18]. The argument that DSA is less costly because it can be performed on outpatients is not valid because outpatient CA has also been reported as a safe and economical procedure[A2,W5].
The purpose of this part of the study is an attempt to evaluate and compare the direct costs of IADSA which could show a difference with those of CA in lower extremity arteriography. A prospective study of those arteriographic costs was performed over a 12-month period in 1990 (January 1st - December 31st) on all aorto-iliac and lower extremity arteriographic procedures.

11.2. MATERIALS AND METHODS

The angiography apparatus for CA and for IADSA and the methods of catheterisation have already been described in chapter 7. All hardcopies of IADSA were obtained with a Laser Imager (3M®), also described in chapter 7. In all examinations of CA and IADSA, an ionic low-osmolar contrast medium (Hexabrix®) was injected.

The specific costs which were examined in this study were those costs which probably would be different for CA and IADSA. All prices mentioned include VAT (Value-added-tax), expressed to the nearest guilder (*f*). These costs were:
a. the 10-year depreciation and interest on equipment capital costs;
b. maintenance of equipment;
c. contrast medium;
d. films.
Personnel salary costs and time differences for each procedure were not analysed, because according to a survey previously held among angiographic personnel, there was no real difference in these factors between the two procedures. Energy costs were initially analysed, but differences between CA and IADSA were found to be negligible.

11.3. RESULTS

During the 12 months of 1990, 298 CA's and 277 IADSA's were performed of aorto-iliac and lower extremity arteries (Table 11.1). The total number of angiographic procedures performed in 1990, including CA, IADSA, and IVDSA amounted to 1815 (Table 11.2).

11.3.1. Capital costs of equipment, depreciation, interest

11.3.1.1. Capital costs

In order to perform angiography, an initial investment of high quality angiographic equipment was necessary, which was very expensive. For CA a Diagnost C Arc angiographic table with X-ray tube, a generator and a developing machine were necessary. IADSA needed the same plus additional equipment, including a laser imager and DSA apparatus (image intensifier and computer). In order to calculate the interest and depreciation, it was necessary to know the capital costs (Table 11.3).

The total expenditure for CA apparatus was *f* 2,417,400 (1 + 2), while the total expenditure for DSA amounted to *f* 4,254,150 (1 + 2 + 3 + 4).

NB. Author's note: the above-mentioned capital costs are the purchasing costs as specified in 1986. According to price specifications in 1992, the purchasing cost of a complete integrated DSA system would now be approximately 30% lower. The reason for this is related to the fact that earlier DSA systems were mainly an add-on apparatus (software etc) onto existent X-ray fluoroscopy tables, while nowadays an angiographic system is a fully integrated digital unit (see 5.3). The price for a CA system in 1992 has shown little change.

Table 11.1. Aorto-iliac and lower extremity angiographic procedures performed in University Hospital Maastricht in 1990.*

	Hospital	Outpatient	Total
CA	295	3	298 (33%)
IVDSA	74	254	328 (36%)
IADSA	264	13	277 (31%)
Total	633	270	903

*Source: Financial administration, Department of Radiology.

Table 11.2. Total number of angiographic procedures performed in University Hospital Maastricht in 1990.*

	Hospital	Outpatient	Total
CA	915	41	956 (53%)
IVDSA	91	324	415 (23%)
IADSA	428	16	444 (24%)
Total	1434	381	1815

*Source: Financial administration, Department of Radiology.

Table 11.3. Capital costs of angiographic equipment*

1) Developing machine	*f*	47,400
2) ARC C + generator	*f*	2,370,000
3) Laser Imager	*f*	414,750
4) DSA-apparatus	*f*	1,422,000

*Source: Technical instrument and service department, University Hospital Maastricht.

In this cost analysis, a lineair depreciation method has been applied. The general policy in this hospital has been to apply a 10-year depreciation period for X-ray and developing equipment, including the DSA apparatus and the laser imager.

In order to calculate the depreciation period, the following assumptions play an important role:

- the ARC C angiography table and generator are used for all angiographic procedures (1815 procedures in 1990) and a small number of percutaneous transhepatic cholangiographies (PTC). Because the number of PTC's per year is low (less than 30), these have been excluded from the calculations;
- the developing machine situated next to the angiography suite is used solely for CA;

- the laser imager with attached developer is used for CT, Ultrasound, DSA and fluoroscopy; DSA accounts for approximately 15% of Laser Imager usage;
- the various kinds of angiographic procedures performed in the angiographic suite take approximately the same amount of time as arteriography of the aorto-iliac and lower extremity arteries.

11.3.1.2. Depreciation

With this information, the figures of the total number of angiographies (Table 11.1) and the number of aorto-iliac and lower extremity arteriographies (Table 11.2), the depreciation per year can be calculated. This will be illustrated by an example, followed by Table 11.4 with the depreciation amounts for each modality.

Example: The Laser Imager is used for DSA for 15% of the time. The depreciation period is 10 years, and the cost price of the Laser imager is *f* 414.750. The depreciation per year is then: *f* 414,750 / 10 x 15% = *f* 6,221.
IADSA of aorto-iliac and lower extremity areas as part of the total DSA usage (IVDSA + IADSA = 859 procedures, see Table 11.2) amounts to 277 / 859 x 100% = 32.25% The depreciation per year for the laser imager for IADSA of aorto-iliac and lower extremity angiographic procedures thus amounts to 32.25% x *f* 6,221 = *f* 2,006.

11.3.1.3. Interest

Interest costs also play a role because the X-ray and DSA equipment are financed with borrowed capital. The average interest rate on the financial market in 1990 was 10%. There are different methods to calculate interest on invested capital. In our study interest was calculated on one half of the cost price. This method means that the interest costs remain equal for each period.

Example: The average invested capital in 10 years for the laser imager is *f* 414,750 / 2 = *f* 207,375. The interest costs per year are 10% x 207,375 = *f* 20,738. However, DSA usage of the laser imager is only 15%, and the fraction used by the aorto-iliac and lower extremity procedures 277 / 859. The interest costs per year are therefore (15% x *f* 20,738) x 277 / 859 = *f* 1,003. The interest costs for the other modalities are calculated in a similar fashion (Table 11.5).

The depreciation and interest costs can be added up. This then gives a clear picture of the difference in depreciation and interest costs for one aorto-iliac and lower extremity arteriographic procedure between CA and IADSA.
For CA: *f* 135 + *f* 67 = *f* **202**
For IADSA: *f* 304 + *f* 153 = *f* **457**

Table 11.4. Depreciation per year for aorto-iliac and lower extremity arteriographic procedures (1990).

IADSA:	Developer	*f*	229	
	ARC C + generator	*f*	36,166	
	Laser Imager	*f*	2,006	
	DSA-apparatus	*f*	45,860	
	Total	*f*	84,261	+
CA:	Developer	*f*	1,477	
	ARC C + generator	*f*	38,915	
	Total	*f*	40,392	+

Table 11.5. Interest per year for aorto-iliac and lower extremity arteriographic procedures (1990).

IADSA:	Developer	*f*	362	
	ARC C + generator	*f*	18,085	
	Laser Imager	*f*	1,003	
	DSA-apparatus	*f*	22,928	
	Total	*f*	42,378	+
CA:	Developer	*f*	389	
	ARC C + generator	*f*	19,456	
	Total	*f*	19,845	+

The cost difference is *f* 255. In other words, the depreciation and interest costs per arteriographic procedure caused by, are at least 2 times higher for IADSA than for CA. The cause of this large difference must be sought in the use of additional high technology equipment (hardware and software) in IADSA.

11.3.2. Maintenance of equipment

The cost of equipment maintenance paid anually by the Department of Radiology, is a fixed amount laid down in contracts which have been made with the suppliers of the medical equipment (Table 11.6).

With the help of Tables 11.1 and 11.2, the maintenance costs for aorto-iliac and lower extremity arteriographic procedures can be calculated. Most of the equipment is used for angiography, but only 15% use of the use of the laser imager with its coupled developer is ascribed to DSA (Table 11.7).

Example: the maintenance costs for the ARC C and generator are *f* 59,250 per year. In 1990 a total of 1815 angiographies were performed, of which 298 were CA aorto-iliac and lower extremity procedures. Therefore the annual maintenance costs which can be related to the CA procedures amount to: 298/1815 x *f* 59,250 = *f* 9,728.

The maintenance costs for one aorto-iliac and lower extremity procedure in 1990 were:

CA: *f* 10,282 / 298 = *f* **35**
IADSA: *f* 36,259 / 277 = *f* **131**

As in the case of the depreciation, the cause of the higher maintenance costs for IADSA must be sought in the additional equipment which is necessary to perform the procedure. The maintenance costs per examination are approximately 4 times higher for IADSA than for CA.

The total costs of the equipment necessary for aorto-iliac and lower extremity arteriography are formed by the depreciation, interest, and maintenance costs:

CA: *f* 202 + *f* 35 = *f* **237**
IADSA; *f* 457 + *f* 131 = *f* **588**

In 1990 the cost of equipment for an IADSA aorto-liac and lower extremity procedure was approximately 2.5 times higher than the same CA procedure.

11.3.3. X-ray contrast media

There are very few concrete figures about the amounts of contrast media which are used in the different angiographic examinations of the cardiovascular system in this hospital. The financial administration of the department of Radiology only registers the total consumption of X-ray contrast media per year. In this study, the information necessary to calculate the mean use of contrast media has been acquired from questionnaires filled in by the radiographers after the examinations.
However, on reviewing the questionnaires it was noticed that there had been a certain neglicence in filling in all the data, which meant that not all the aortoiliac and lower extremity procedures could be used for calculating the mean contrast media consumption. In order to make a proper comparison between CA and IADSA, certain selection criteria had to be applied.
First, aortoiliac and lower extremity procedures could only be included in the cost analysis if they had been performed according to the protocol, if CA and IADSA had been performed in the same patient. Secondly, both procedures had to have used the standard contrast medium, because otherwise patients who were injected with another contrast medium could influence the cost

Table 11.6. Costs of equipment maintenance per year.

DSA:	Developer	*f* 1,778	
	ARC C + generator	*f* 59,250	
	Laser Imager	*f* 23,700	
	DSA-apparatus	*f* 80,580	
	Total	*f* 165,128	+
CA:	Developer	*f* 1,778	
	ARC C + generator	*f* 59,250	
	Total	*f* 61,028	+

*Source: Technical instrument and service department, University Hospital Maastricht.

Table 11.7. Maintenance costs for aorto-iliac and lower extremity arteriography, 1990.

IADSA:	Developer	*f* 86	
	Arc C + generator	*f* 9,043	
	Laser Imager	*f* 1,146	
	DSA-apparatus	*f* 25,984	
	Total	*f* 36,259	+
CA:	Developer	*f* 544	
	ARC C + generator	*f* 9,728	
	Total	*f* 10,282	+

analysis of the standard examination. The last selection criterion was that the amount of contrast medium used had to have been filled in on the question form. In 11% of patients (not legs), a different contrast medium was used or the type of contrast medium had not been specified on the question form.
The standard contrast medium used in angiography in our hospital is an ionic low-osmolar meglumine/sodium ioxoglate solution (Hexabrix 320® for CA, and Hexabrix 160® for IADSA). After many years of using different contrast media, it has been found to be well tolerated by patients, and to carry a competitive price per 100cc. The difference between the two types lies in their Iodine concentration, which is twice as high in Hexabrix 320® as in Hexabrix 160®. This is reflected in the price:

Hexabrix 320: *f* 90 per 100cc
Hexabrix 160: *f* 50 per 100cc
(Source: Central Hospital Pharmacy)

The Iodine concentration necessary to perform an adequate IADSA can be halved, because the contrast resolution of the digital apparatus is much higher (see 5.3.3.).
In 1990 there were 107 patients who passed the selection criteria of Hexabrix® being used as the contrast medium and data on the amounts used being provided (Table 11.8). The bottom line in this table shows the mean consumption of contrast medium per examined leg. The mean costs of contrast medium consumption are calculated as follows:

CA: $34 \times f\ 90/100 = f\ \mathbf{31}$
IADSA: $84 \times f\ 50/100 = f\ \mathbf{42}$

According to the questionnaire, this difference can be explained by the fact that an aortoiliac and lower extremity procedure by IADSA requires a number of runs at different positions. One DSA run allows only a restricted view of vasculature, related to the monitor size, to be visualized. A complete examination by IADSA, comparable to CA, requires four runs, and this means four injections of contrast medium. In conclusion, although the price of the contrast medium used for IADSA is lower, the cost of contrast medium consumption for this modality is higher than for CA.

11.3.4. Film costs
Before this study was undertaken, no specific information was available from the financial administration on the consumption of hard copy (film) material. The logbook in the angiographic suite did not specifically register the number of films per examination. The only immediate information available was the type of films which were used to generate hardcopies in the angiographic procedure.
In CA the exposures are made directly on 35x35 cm conventional photographic films and all films are processed via a film developer. In IADSA the exposures are made with an image intensifier and the images are presented on a video monitor of the DSA apparatus. These images can then be exposed on special 35 x 43 cm films via a laser imager. However, in DSA the images are first manipulated electronically (post-processing, see 5.3.5.) in order to obtain optimally interpretable images, after which only a few representative images are selected for hardcopies. Six of these representative images are then exposed on one Laser Imager film. The exposures made on CA film cannot be manipulated electronically beforehand, and each exposure of CA fits on one film.

The data obtained concerning film consumption in this study were obtained as follows.
First, the radiographers were requested to note on the special questionnaire how many exposures/images were used, on average, for aortoiliac and lower

Table 11.8. Mean consumption (MC) of X-ray contrast media in aortoiliac and lower extremity arteriography, 1990.

Examination	Number of patients	MC IADSA	MC CA
1 leg	62	101.8 cc	41.5 cc
aorto-iliac + 2 legs	32	117.0 cc	66.9 cc
aorto-iliac + 1 leg	11	157.5 cc	63.6 cc
2 legs	2	132.5 cc	32.5 cc
mean per leg	107	84.4 cc	34.1 cc

extremity CA and IADSA. The answers ranged from 13 to 14 for CA and from 10 to 18 for IADSA. The mean numbers were:
CA: 14 exposures
IADSA: 12 images

Secondly, verification of these numbers was obtained from the radiologists, and a consensus was formed on the following numbers:
CA: 14 exposures i.e. 14 films
IADSA: 12 images i.e 2 films in four runs
The cost price of film is:
CA: one 35 x 35 cm film = *f* 2.60
IADSA: one 35 x 43 cm film = *f* 4.30
(Source: Central Purchasing Office, University Hospital Maastricht).

The costs of film consumption for an aorto-iliac and lower extremity procedure are therefore:
CA: 14 x *f* 2.60 = *f* **36**
IADSA: 2 x *f* 4.30 = *f* **9**

In conclusion, although IADSA requires more expensive film material and more runs have to be made, the cost of film consumption with IADSA is about four times lower than with CA. This low cost factor is a result of the DSA apparatus being able to select images and expose six on one film.

11.3.5. Total costs per examination
We can now present an overview of the costs per aortoiliac and lower extremity examination. The costs which are described here are those which might differ directly between CA and IADSA. These costs include: depreciation and interest, maintenance of equipment, amount of contrast medium and film material. Differences have been found in all these cost factors, though more so in some

Table 11.9. Total costs per aortoiliac and lower extremity arteriogram, 1990

	CA	IADSA
depreciation and interest	*f* 202	*f* 457
maintenance	*f* 35	*f* 131
contrast medium	*f* 31	*f* 42
film	*f* 36	*f* 9 +
Total Cost Price	*f* 304	*f* 639

than in others (Table 11.9). The total cost price is a simple addition of the different cost factors specified in the previous paragraphs.

Assuming that approximately 300 aortoiliac and lower extremity arteriographies are performed per year, IADSA is found to be *f* 100,500 (300 x *f* 335) more expensive than CA annually with regard to the costs examined here.

11.4. DISCUSSION

In conclusion, the specified costs of an aortoiliac and lower extremity IADSA were 2 times higher than those of CA, assuming that the depreciation takes place over 10 years and equipment is 100% occupied. The greatest differences were found in the equipment costs, i.e. the depreciation, interest, and maintenance. These costs accounted for 92% (*f* 588/639) of costs in IADSA and 78% (*f* 237/304) of costs in CA. As was mentioned above, the higher equipment costs for DSA are related to 1986 purchasing prices. If one would compare the costs between CA and IADSA in 1992, the difference would be approximately 30% lower. As was noted at the beginning of this chapter, very little information is available in the literature on comparison of costs between CA and IADSA. Only one report mentioned that IADSA resulted in a 12% reduction of overall costs if costs included depreciation and interest over 5 years and capital costs of CA and DSA apparatus[N3]. This contradicts our findings, but these results are not entirely comparable because their study concerned 400 angiograms of neuroangiographic procedures with different CA and DSA apparatus.
In the same report[N3], a 25% reduction in staffing costs was noted, as well as a 19% reduction in the time required per examination and a 30% reduction in the time required per run. Overall operating cost savings were 43%. Although our study did not formally determine time limits and personnel capacity, a questionnaire completed by radiographers in the angiographic suite showed that no major time difference was experienced between CA and IADSA.

The savings in staffing costs were caused by the absence of a dark-room technician because of the marked reduction in the number of films required with DSA[N3]. Our angiographic unit does not have its own dark-room technician, but considerable savings are attained on developing time and film costs by the use of a laser imager.

It is interesting to note that the cost of film material for CA is four times as high as for IADSA per examination. This finding has also been reported in other studies of angiography[G2,L8,N3]. The difference in film costs is caused by the fact that in DSA only a few selected images with optimal information on the video monitor are processed as hardcopies, while in CA all exposed films are developed. Viewing of subtracted images with DSA can be performed immediately during and after the run, making the decision making process shorter. Viewing of subtracted images of a CA run requires extra film material and radiographer time, leading to higher costs.

The average cost of contrast medium in our study was higher with IADSA than with CA. This is caused by the fact that to visualizing the entire leg with IADSA requires approximately four runs at different leg positions, each with a separate injection of contrast medium. CA allows the entiree leg to be visualized with one injection. Hence, although the cost price of contrast medium for IADSA is lower (lower Iodine content), the necessity of multiple runs results in a higher price per examination. With the advent of new large screen monitors, this difference can be minimised in the future by reducing the number of runs. These findings contrast with earlier reports[G2,K4,L8,N3] which suggest savings in the costs of contrast medium with the use of IADSA.

In conclusion, assuming that approximately 300 aortoiliac and lower extremity angiographies are performed per year, there is a difference in specified costs between CA and IADSA of *f*100,500 to the disadvantage of IADSA. In reality, this difference may well be less, if the CA has to be repeated for optimal interpretation of lower leg arterial pathology. The previous chapter has shown that CA films of the lower leg are often not interpretable after a first single bolus of contrast medium, due to incorrect timing of the contrast flow in the leg. The costs of contrast medium and film material for CA then become twice as high, and the difference with IADSA would then become *f* 67,— less per examination. In addition, there would be a slight increase in personnel costs.

12. CONCLUSIONS AND RECOMMENDATIONS

12.1. CONCLUSIONS

In conclusion, the results of the present study allow the following answers to the questions posed in the introduction of this thesis (see 1.2):

1. Does the application of IADSA in arterial occlusive disease improve the visualization (interpretability) of lower leg arteries in comparison with CA?
   - After a first single bolus injection of contrast medium, a significantly larger number of lower leg arteries are visualized by IADSA than by CA. A large number of CA films are non-interpretable after a single bolus contrast injection because of low contrast medium concentration in the artery due to chance timing with stepping X-ray tube technique and due to bone superposition. This hardly applies to IADSA, due to the higher contrast resolution and instantaneous bone subtraction performed electronically during the examination. Technical factors are a minor cause of noninterpretability in CA and IADSA.
2. Is IADSA more consistent than CA in interpreting a multi-categorical Angioscore, 50% stenosis, occlusion or collateral blood flow?
   - IADSA tends to be slightly more consistent in the interpretation of significant stenoses or occlusion in arteries below the knee in comparison with CA after a first single contrast bolus injection. In most cases a higher degree of interobserver agreement was observed for IADSA in comparison with CA, but this difference was only statistically significant for the anterior tibial artery. Vasodilatation caused by contrast medium has not been found to have had any influence on film interpretation, whether IADSA is performed before or after CA.
3. Are more arteries assessed graftable with IADSA than with CA?
   - A much larger percentage of lower leg vessels are judged graftable by IADSA than by CA. This may influence the limb salvage rate in patients who are threatened with a primary leg amputation, because more lower legs will be grafted as a primary procedure instead of being amputated. If the femoro-crural bypass procedure is successful, high costs caused by the

purchase of a leg prosthesis and subsequent rehabilitation of the patient can be avoided. The quality of life for the patient is markedly improved.

4. Does the application of IADSA of the lower extremity cause a reduction of patient radiation doses in comparison with CA?
   - The use of IADSA does not result in lower radiation exposure but in fact causes a one and a half to two times greater entrance dose of the leg in comparison with CA. A significant part of the emitted energy during lower extremity arteriography is absorbed in the abdomen and pelvis, resulting in an entrance dose for IADSA which is six times greater than that for CA.
5. Is lower extremity arteriography less expensive if performed by IADSA in comparison with CA?
   - Lower extremity arteriography is more expensive by IADSA than by CA, mainly due to equipment costs. Adequate visualization of lower leg arteries is obtained with IADSA by using 50% less iodine concentration and volume of contrast medium than in CA. This could have an influence on examination costs (the price of contrast medium is related to the amount of Iodine), but due to multiple projections, IADSA is not cheaper in this aspect. The only savings occur in the use of less film material.

12.2. RECOMMENDATIONS

DSA represents a major contribution to vascular radiology and surgery. CA still has the advantage, that with an optimal arteriographic examination, the entire vascular tree can be examined from aorta to feet with a single bolus injection of contrast medium[S39]. With IADSA alone, five separate injections would be necessary to show the entire region from aorta to feet.
It is therefore recommended to perform CA as an overview of the entire vasculature from aorta to ankle/feet, followed by IADSA of the popliteal and lower leg/ankle regions in order to achieve optimal visualization of these regions.
Conventional arteriography with adjunctive IADSA of the lower leg is then an efficient method to visualize the peripheral vascular system in occlusive arterial disease with the present angiography apparatus. A lower concentration of contrast medium can be used to define proximal inflow and distal runoff circulatory beds with lower contrast volume loads, which is an advantage in patients with compromised renal and cardiac function. It can be predicted that in the near future the overview CA will be replaced by a digital arteriogram (without subtraction), when the entire stepping technique is combined with digital imaging[F14,F16]. A further perfection of this technique will probably result in a stepping digital arteriogram with subtraction. Film costs can be cut dramatically by using IADSA, because the real-time imaging effect of sunsequent images on the video monitor, allows the angiographer to select optimal images for hard-copy processing, preferably with a laser imager.

The important point is that the radiologist can no longer be satisfied with anything less than complete visualization of the lower extremity vasculature and should be able to tailor the arteriographic examination to this goal.
If optimal visualisation of lower leg arteries results in a femoro-crural bypass instead of leg amputation, high costs of leg prosthesis and patient rehabilitation can be avoided and the quality of life for the patient is improved.

13. SUMMARY

A clinical study on the interpretability, consistency, graftability, radiation exposure and costs of conventional arteriography and intra-arterial digital subtraction angiography in the diagnosis of arterial occlusive disease in lower leg arteries is described. It was performed in patients who were candidates for a vascular operation, after prior clinical and non-invasive diagnostic tests had been performed.

CHAPTER 1

The aim of the study described in this thesis was fivefold:

1. to compare the interpretability of CA with IADSA of lower leg arteries;
2. to compare the consistency of readings of conventional arteriograms with those of intraarterial digital subtraction arteriograms of lower leg arteries;
3. to compare the assessment of graftability on the basis of CA and IADSA of lower leg arteries, and, retrospectively, after the operation has been performed;
4. to compare the the radiation doses for CA and IADSA of the lower extremities;
5. to compare costs of CA and IADSA of the lower extremities.

CHAPTER 2

General aspects of arterial occlusive disease are outlined in this chapter. It includes the etiology, pathology and significance of a hemodynamic critical stenosis with the development of collateral circulation. A description is given of the Fontaine classification, used in the clinical grading of arterial obstructive disease. The chapter also pays special attention to the therapeutic aspects, surgical as well as radiological. The problems encountered with arteriography of the lower leg are briefly noted. A review of the normal and variant anatomy of knee and lower leg region is given.

CHAPTER 3

A review of current non-invasive diagnostic methods used in the assessment of arterial disease is given, including a short note on the value of direct intra-arterial pressure recording.

CHAPTER 4
This chapter deals with the history of conventional arteriography in general, and more specifically with the development of arteriography of the extremities. Techniques of arterial puncture, methods of contrast injection and filming techniques are decribed. A review is given of the different complications which may occur during or after arteriography. The use of intraoperative arteriography as an extra diagnostic tool is discussed. In this chapter special attention is paid to the pitfalls which can influence the correct interpretation of films.

CHAPTER 5
This chapter describes the discovery of photographic subtraction by Ziedses des Plantes and reviews the literature on all aspects of DSA. The four different types of electronic (digital) subtraction are explained, viz., first order subtraction in time, energy, or depth, and second order subtraction using a combination of parameters. A brief overview is given of the technical aspects of DSA and a description of the components which are combined to form a DSA system.
The importance of spatial and contrast resolution in relation to the images formed by CA and DSA is explained in this chapter. The possibilities of image manipulation using DSA are discussed, as well as the possibility of studying circulatory dynamics (parametric imaging).
Present methods of image display are also described, including matrix camera and laser imager recording, and a view is given of the methods of image storage with digital optical disks.
The introduction of intravenous DSA and the shortcomings of this technique discovered later are described here, as well as the subsequent application of intraarterial DSA in general, and its specific application to intervention, trauma and tumors. The development of intraoperative DSA and outpatient DSA is also described.

CHAPTER 6
This chapter reviews results from the literature which advocate an aggressive approach for limb salvage therapy instead of limb amputation. This necessitates a reliable method to obtain preoperative diagnostic information on the status of the vascular tree. IADSA is introduced as a new method with supposed extra diagnostic qualities as compared to CA. Comparative studies of CA and DSA in general and specifically related to the lower extremities are discussed. Advantages of IADSA over CA recorded in the literature are listed here.

CHAPTER 7
The patient population which entered the consistency study, the noninvasive tests and the use of the ankle-brachial index as a measure of grading the severity of arterial disease are explained in this chapter. Specifications of diag-

nostic imaging equipment for CA and DSA, the method of arteriography and subsequent method of film interpretation are described. The arteriograms which were eventually included in this study and the principles of the Kappa statistical analyses of data obtained are also described.
The patient population which entered this study was 145, but after preview, the arteriograms of only 100 patients were found to be eligible for an independent, blinded reading by four observers.
This group of 100 patients varied in age from 37 to 91 years, and consisted of 54 males and 46 females. More than 90% of the patients were older than 50.
Film interpretation was performed by four observers three to six months after angiography in two phases. In phase one all observers had to score on a data form whether the film was judged interpretable or non-interpretable. If the film was judged interpretable, a multicategorical stenosis grading (Angioscore) of the popliteal, posterior tibial, anterior tibial and peroneal arteries, and the presence of collaterals had to be marked.
In phase two, the above interpretation was extended by an assessment of the quality of the film by all four observers. If the film was judged non-interpretable, the observer had to score whether this was caused by low contrast, bone superposition or other factors. In this phase, the two observers who were vascular surgeons also assessed whether a vessel was considered amenable to grafting.
The chapter ends with an example of the Kappa statistical analysis used to measure the degree of interobserver agreement.

CHAPTER 8
100 patients had arteriograms suitable for observer interpretation. Because some patients had undergone examination of two legs simultaneously by TLA or Seldinger catheterization, each leg was considered as a separate arteriogram, resulting in 135 arteriograms for interpretation. Five major parts can be distinguished in this chapter, containing the results of this study.
In the first part the values of the ankle-brachial index (ABI) are shown, in relation to the total number of arteriograms interpreted and in relation to the non-interpretable arteries, separately for CA and IADSA.
Th second part discusses the interpretability of the popliteal, posterior tibial, anterior tibial, and peroneal arteries in relation to the number of observers who considered an artery non-interpretable with CA or with IADSA.
The third and most important part shows the interobserver agreement, expressed as Kappa or weighted Kappa values, in interpreting a multicategorical Angioscore, 50% stenosis or occlusion in the total study group of arteriograms and the needle puncture group of arteriograms.
The fourth part attempts an assessment of film quality. A major cause of non-interpretable films in CA seems to be low contrast of the blood vessel, followed by bone superposition.

In surgical practice, the graftability of a vessel is partly attributed to the interpretation of the film. The last and fifth part discusses the difference between CA and IADSA when two vascular surgeons judge whether a vessel is considered amenable to grafting, on the basis of film interpretation alone, without prior knowledge of clinical information or results of non-invasive tests. A retrospective comparison is made with the actual operation performed.

CHAPTER 9

This chapter contains a summarizing discussion of the final results of interpretability, consistency and graftability. Special attention is also paid to the reason for non-interpretability of examinations. The use of Kappa statistics in the assessment of consistency of various other radiodiagnostic procedures, other than angiography, is highlighted.

CHAPTER 10

Dose measurements were carried out on patients undergoing aorto-iliac and lower extremity arteriography. Evaluation of the entrance dose to skin showed a higher value for IADSA in comparison with CA. A significant amount of emitted energy was found to be absorbed by the abdomen and pelvis.

CHAPTER 11

A comparative study was made of certain costs which could differ between CA and IADSA. In this chapter results show that specified costs are two times higher for IADSA than for CA, mainly as a result of equipment costs. The only savings occurred in film costs.

CHAPTER 12

The conclusions of this study regarding angiography of the lower leg are:

- After a first bolus injection of contrast medium, a significantly higher number of lower leg arteries are visualized by IADSA than by CA. Non-interpretable examinations with CA after a single bolus injection are often caused by low contrast of the artery or by bone superposition.
- The consistency of film interpretation for arterial obstruction is high for CA as well as IADSA in comparison with the literature, with a slightly better result for IADSA. Vasodilation by circulating contrast medium does not influence the consistency of film interpretation.
- more lower leg arteries are judged amenable to grafting on the basis of film interpretation with IADSA than with CA.
  This may decrease the primary amputation rate in obstructive arterial disease by indicating the possibility of a femorocrural bypass. A successful femorocrural bypass instead of a leg amputation can save the high costs of a leg prosthesis followed by rehabilitation, and can improve the quality of life for the patient.

- The use of IADSA does not result in lower radiation exposure but in fact causes a greater entrance dose to the skin of the leg in comparison with CA. A significant part of the emitted energy during lower extremity arteriography is absorbed in the abdomen and pelvis leading to a higher entrance dose for IADSA than for CA.
- Lower extremity arteriography by IADSA is more expensive than by CA, mainly due to equipment costs. The only savings occur in the use of film material.

A recommendation on how to perform aorto-iliac and lower extremity angiography with present apparatus is given.

SAMENVATTING

In dit proefschrift worden conventionele arteriografie (CA) en intraarteriële digitale subtractie angiografie (IADSA) van het onderbeen vergeleken voor wat betreft de beoordeelbaarheid van de verkregen beelden, de consistentie van de interpretatie met betrekking tot de mate van arteriële obstructie, de stralingsbelasting voor de patiënt en de kosten.

De concrete vraagstellingen worden in **hoofdstuk 1** beschreven evenals de aanleiding tot dit onderzoek. **Hoofdstuk 2** geeft informatie over de aetiologie, pathologie en therapie van haemodynamische kritische stenosen in de bloedvaten van het onderbeen. In **hoofdstuk 3 en 4** worden de momenteel beschikbare methoden van respectivelijk noninvasief en invasief vaatonderzoek beschreven. De techniek en mogelijkheden van subtracties en met name van de digitale subtractie angiografie komen in **hoofdstuk 5** aan bod waarna in **hoofdstuk 6** de literatuur wat betreft de vergelijking van CA met DSA besproken wordt.

In **hoofdstuk 7** wordt beschreven hoe de patiënten voor het onderzoek werden geselecteerd en hoe het angiografisch onderzoek werd uitgevoerd en de beelden werden beoordeeld. Ook wordt hier de statistische analyse uitgelegd. In **hoofdstuk 8** worden de resultaten van dit deel van het onderzoek gepresenteerd waarna in **hoofdstuk 9** een discussie volgt.
Van de arteriogrammen (CA & IADSA) van 145 achtereenvolgende patiënten waren er 100 beschikbaar voor beoordeling op beoordeelbaarheid, de mate van arteriële obstructie (uitgedrukt in een Angioscore) en de aanwezigheid van collateralen. De onderbeens arteriën bleken met IADSA beduidend beter beoordeelbaar ($p<.05$) dan met CA. Dit verschil in beoordeelbaarheid was vooral groot bij de arteriën distaal van de trifurcatie.

Bij een subgroep van 52 patiënten werd bovendien onderzocht waarom in voorkomende gevallen de kwaliteit van de beelden als onvoldoende voor interpretatie beschouwd werd. Dit bleek meestal veroorzaakt te worden door een te gering contrastaanbod in het betreffende bloedvat en soms door hinderlijke botsuperpositie. CA werd om deze reden veel vaker als niet te beoordelen beschouwd dan IADSA. De interwaarnemervariatie (4 waarnemers) bij beoordeling van de mate van arteriële obstructie bleek slechts gering te zijn in

vergelijking met de gegevens uit de literatuur en was voor CA en IADSA vrijwel gelijk. Het grootste verschil in interwaarnemer variatie werd geconstateerd bij interpretatie van de CA en IADSA beelden van arteria tibialis anterior op occlusie. Alleen dit verschil was statistisch significant ($p<.005$). De interwaarnemervariatie bij de beoordeling van collateralen was beduidend groter en ook hier waren de beoordelingen van de CA en IADSA beelden ongeveer even consistent. Twee chirurgen beoordeelden zowel de CA als de IADSA beelden van 52 patiënten opnieuw maar nu op de mogelijkheid tot het aanleggen van een bypass. Hierbij bleek dat met behulp van IADSA beduidend vaker tot het aanleggen van een bypass besloten werd.
In **hoofdstuk 10** wordt beschreven hoe de stralingsbelasting (intreedosis [mGy]) bij zowel CA als bij IADSA wordt gemeten en wat de resultaat van die metingen is. Voor het onderzoek van het onderbeen blijkt IADSA altijd iets stralenbelastender dan CA. Het verschil is echter niet groot. De kosten van beide onderzoeken worden vergeleken in **hoofdstuk 11.** Ervan uitgaande dat beide onderzoeken evenveel tijd kosten, is IADSA ongeveer twee maal zo duur als CA. Dit verschil wordt vooral veroorzaakt door de afschrijvings- en onderhoudskosten. De daarbij gehanteerde bedragen zijn echter gebaseerd op het prijspeil (en prijsverschil) van eind jaren tachtig.

In **hoofdstuk 12** wordt geconcludeerd dat:

- na een eerste bolus-contrastinjectie meer arteriën van het onderbeen beoordeelbaar worden afgebeeld indien gebruik gemaakt wordt van IADSA dan wanneer gewerkt wordt met de conventionele arteriografie techniek.
- de interwaarnemer variaties bij beoordeling van de mate van obstructie voor IADSA en CA ongeveer gelijk zijn en beduidend lager dan in de literatuur wordt aangegeven.
- de chirurg op basis van de IADSA beelden vaker besluit tot het aanleggen van een bypass dan wanneer hij bij die beslissing alleen de beschikking heeft over CA beelden.
- het gebruik van IADSA bij het afbeelden van de onderbeensvaten in vergelijking met CA geen lagere stralingsdosis voor de patiënt tot gevolg heeft.
- onderbeensarteriografie met behulp van IADSA duurder is dan bij gebruik van CA.

APPENDIX

ANGIOGRAPHY REPORT -- DSA PROJECT

Observer: CA / IA-DSA:

Patiënt no.: Male / female:

Date of birth: Examination date:

Injection method: (1=needle puncture groin,
2=Seldinger catheterisation,
3=translumbar aortography)

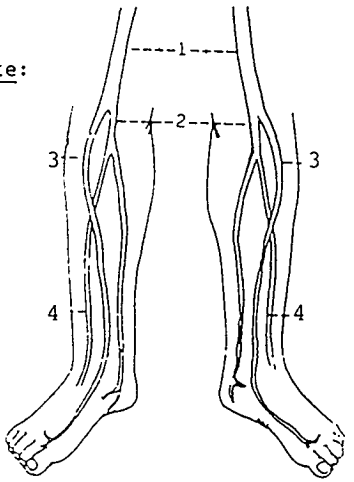

1. Popliteal artery
2. Posterior tibial artery
3. Anterior tibial artery
4. Peroneal (fibular) artery

Angioscore:	Right leg				Left leg			
	1	2	3	4	1	2	3	4
1. Stenosis: 0 - 24%	0	0	0	0	0	0	0	0
2. Stenosis: 25 - 49%	0	0	0	0	0	0	0	0
3. Stenosis: 50 - 74%	0	0	0	0	0	0	0	0
4. Stenosis: 75 - 99%	0	0	0	0	0	0	0	0
5. Occlusion: 100%	0	0	0	0	0	0	0	0
9. Non-interpretable (n.i.)	0	0	0	0	0	0	0	0
Collateral Bloodflow								
1. Collaterals - yes	0	0	0	0	0	0	0	0
2. Collaterals - no	0	0	0	0	0	0	0	0
9. Non-interpretable	0	0	0	0	0	0	0	0
Quality								
1. Interpretable	0	0	0	0	0	0	0	0
2. Low contrast (n.i.)	0	0	0	0	0	0	0	0
3. Bone superposition (n.i.)	0	0	0	0	0	0	0	0
4. Other factors(n.i.)	0	0	0	0	0	0	0	0
Graftability								
1. Graftable - yes	0	0	0	0	0	0	0	0
2. Graftable - no	0	0	0	0	0	0	0	0
9. Non-interpretable	0	0	0	0	0	0	0	0

REFERENCES

A

1. ABRAMS HL, HESSEL S. Health technology assessment: problems and challenges. AJR 1987; 149: 1127-1132.
2. ADAMS PS, ROUB LW. Outpatient angiography and interventional radiology: safety and cost benefits. Radiology 1984; 151: 81-82.
3 ALFIDI RJ, MASARYK TJ, HAACKE EM, et al. MR Angiography of peripheral, carotid and coronary arteries. AJR 1987; 149: 1097-1109.
4. AMPLATZ K. Translumbar catheterization of the abdominal aorta. Radiology 1963; 81: 927-931.
5. AMPLATZ K. Disposable catheter needles. Invest Radiol 1966; 1: 262-263.
6. ALART IP, HUTSCHENREITER S. Intravenous digital subtraction angiography in patients with femoral arteriovenous fistulas and ilio-iliac crossover graft. Cardiovasc Intervent Radiol 1985; 8: 64-67.
7. ASCER E, VEITH FJ, GUPTA SK. Bypasses to plantar arteries and other tibial branches: an extended approach to limb salvage. J Vasc Surg 1988; 8: 434-441.
8. AMPLATZ K, CRASS J, MOORE R, KORBULY D, KOTULA F, CASTANEDA-ZUNIGA WR. Changerless peripheral angiography: a new concept. Radiology 1980; 137: 213-215.
9. AXELBAUM SP, SCHELLING ER, GOMES MN. Computed tomographic evaluation of aortic aneurysms. AJR 1976; 127: 75-78.
10. ANGUS W. Diagnostic image management: today and the future. In: Mistretta CA, Crummy AB, Strother CM, Sackett JF, eds. Digital Subtraction arteriography: an application of computerized fluoroscopy. Chicago, Year Book Medical 1982: 151-157.
11. ALCORN JM, STANSON AW, JOHNSON CM, STEARS JG. Beam-shaping device for long-film angiography. Radiographics 1992; 12: 323-328.
12. AGEE O, KAUDE J. Arteriography of the pelvis and lower extremities with moving table technique. AJR 1969; 860-865.
13. AMPLATZ K. Rapid film changers. In: Abrams HL, ed. Abrams Angiography, 3rd ed. Boston: Little, Brown & Company, 1983: 106-124.
14. AMENDOLA MA, TISNADO J, FIELDS WR, et al. Evaluation of retroperitoneal hemorrhage by computed tomography before and after translumbar aortography. Radiology 1979; 133: 401-404.
15. ANDROS G, HARRIS RW, SALLES-CUNHA SX, et al. Bypass grafts to the ankle and foot. J Vasc Surg 1988; 7: 785-794.
16. ASCER E, WHITE SA, GUPTA SK, VEITH FJ. Amputation versus revascularisation. In: Rutherford RB, ed. Vascular Surgery, 3rd ed. Philadelphia: WB Saunders, 1989: 1757-1768.

B

1. BEGG CB, McNEIL BJ. Assessment of radiologic tests: control of bias and other design considerations. Radiology 1988; 167: 565-569.
2. BALTER S, ERGUN D, TSCHOLL E, BUCHMANN F, VERHOEVEN L. Digital subtraction angiography: fundamental noise characteristics. Radiology 1984; 152: 195-198.
3. BALTER S. On the work of the radiologist - separation of image capture from image display. Acta Radiol 1988; 29: 257-265.

4. BARBARIC ZL, GOMES AS, DECKARD ME, NELSON RS, MOLER CL. Digital subtraction angiography with an Isocon camera system: cinical applications. AJR 1984; 142: 143-147.
5. BARNES RW, BONE GE, REINERTSON J, SLAYMAKER EE, HOKANSON DE, STRANDNESS DE. Noninvasive ultrasonic carotid angiography: prospective validation by contrast arteriography. Surgery 1976; 80: 328-335.
6. BECKER GJ, HICKS ME, HODEN RW, EDWARDS MK, JACKSON VP, BENDICK PJ. Screening for occlusive vascular disease with intraarterial DSA: preliminary experience with a high flow 4-F catheter. Radiology 1984; 153: 823.
7. BOIJSEN E, DAHN I, HALLBÖÖK T. Hemodynamic effects of contrast medium in arteriography of legs. Acta Radiol Diagn 1971; 11: 295-309.
8. BOXT LM, MURRAY PD, PERLMUTT LM, et al. Comparison of intravenous digital subtraction angiography to conventional angiography in patients with abdominal aortic aneurysm. Cardiovasc Intervent Radiol 1985; 8: 76-82.
9. BOXT LM, MURRAY PD, PERLMUTT LM, et al. Intravenous digital subtraction angiography in diagnosis of vascular graft occlusion. Cardiovasc Intervent Radiol 1985; 8: 59-63.
10. BRESLAU PJ, JÖRNING PJG, GREEP JM. De klinische betekenis van haemodynamisch, niet-invasief onder zoek bij patienten met arteriële vaatziekten van de benen. Ned Tijdschr Geneesk 1984; 128 (21): 996-998.
11. BRITTON CA, WHOLEY MH. Radiation exposure of personnel during digital subtraction angiography. Cardiovasc Intervent Radiol 1988; 11: 108-110.
12. BRANT-ZAWADSKI M, GOULD M, NORMAN D, NEWTON TH, LANE B. Digital subtraction cerebral angiography by intraarterial injection: comparison with conventional angiography. AJR 1983; 140: 347-353.
13. BRESLAU PJ, JÖRNING PJG, GREEP JM. Assessment of aortoiliac diseases using hemodynamic measures. Arch Surg 1985; 120: 1050-1052.
14. BRAUN SD, ILLESCAS FF, FAGERT T, DUNNICK NR. Measuring abdominal aortic aneurysms on digital subtraction arteriograms. AJR 1985; 144: 997-998.
15. BUNKER SR, CUTAIA FI, FRITZ AL, et al. Femoral intraarterial digital angiography: an outpatient procedure. AJR 1983; 141: 593-596.
16. BUONOCORE E, MEANEY TF, GREGORY P, BORKOWSKI GP, PAVLICECK W, GALLAGHER J. Digital subtraction angiography of the abdominal aorta and renal arteries. Radiology 1981; 139: 281-286.
17. BANTA HD. Technology assessment and diagnostic imaging. Eur J Radiol 1992; 14: 141-146.
18. BÜRSCH JH. Use of digitized functional angiography to evaluate arterial blood flow. Cardiovasc Intervent Radiol 1983; 6: 303-310.
19. BÜRSCH JH, HAHNE HJ, BRENNECKE R, GRÖNEMEIR D, HEINTZEN PH. Assessment of arterial blood flow measurements by digital angiography. Radiology 1981; 141: 39-47.
20. BUSCH HP, PRAGER P, STORZ LW, MENGES HW, GEORGI M. Intra-arterielle DSA der Becken-Bein gefässe mit einem 57-cm Bildverstärker. ROFO 1986; 145: 14-20.
21. BUSCH HP, HOEVELS J, PRAGER P, GEORGI M. Möglichkeiten der Fehldiagnose mit der DSA und ihre Ursachen. ROFO 1985; 143: 521-526.
22. BUTLER P, WILLIAMSON B. Intravenous digital subtraction angiography in patients with suspected bypass graft occlusion following surgery for peripheral vascular disease. Br J Radiol 1986; 59: 329-332.
23. BÜRSCH JH, HEINTZEN PH. Parametric imaging. Radiol Clin North Am 1985; 23: 321-333.
24. BREWER ML, KINNISON ML, PERLER A, WHITE RI. Blue toe syndrome: treatment with anticoagulants and delayed percutaneous transluminal angioplasty. Radiology 1988; 166: 31-36.

25. BROWN KT, SCHOENBERG NY, MOORE ED, SADDEKNI S. Percutaneous transluminal angioplasty of infrapopliteal vessels: preliminary results and technical considerations. Radiology 1988; 169: 75-78.
26. BAKAL CW, SPRAYREGEN S, SCHEINBAUM K, CYNAMON J, VEITH FJ. Percutaneous transluminal angioplasty of the infrapopliteal arteries: results in 53 patients. AJR 1990; 154: 171-174.
27. BRON KM. Femoral arteriography. In: Abrams HL, ed. Abrams Angiography, 3rd ed. Boston: Little, Brown & Company, 1983: 1835-1875.
28. BARNES RW. Noninvasive diagnostic techniques in peripheral vascular disease. Am Heart J 1979; 97: 241-258.
29. BYRNE P, PROVAN JL, AMELI FM. The use of transcutaneous oxygen tension measurements in the diagnosis of peripheral vascular insufficiency. Ann Surg 1984; 200: 159-165.
30. BARDSLEY JL, STAPLE TW. Variations in branching of the popliteal artery. Radiology 1970; 94: 581-587.
31. BUSCH HP, STRAUSS LG. Comparison of performance characteristics of different DSA-installations. Eur J Radiol 1987; 7: 56-59.
32. BLACK WC. How to evaluate the radiology literature. AJR 1990; 154: 17-22.
33. BAKER AR, MACPHERSON DS, EVANS DH, BELL PRF. Review article: Pressure studies in arterial surgery. Eur J Vasc Surg 1987; 1: 273-283.
34. BERGUER R, HWANG NHC. Critical arterial stenosis: a theoretical and experimental solution. Ann Surg 1974; 180: 39-50.
35. BRODY WR. Hybrid subtraction for improved arteriography. Radiology 1981; 141: 828-831.
36. BRODY WR, CASSEL DM, SOMMER FG, et al. Dual energy projection radiography: initial clinical experience. AJR 1981; 137: 201-205.
37. BROOKS B. Intraarterial injection of Sodium-Iodide. JAMA 1924; 82: 1016-1019.
38. BERBERICH J, HIRSCH S. Die röntgenographisch Darstellung der Arteriën und Venen am lebenden Menschen. Klin Wchnschr 1923; 2: 2226-2228.
39. BLEICHRODER F. Intra-arterielle Therapie. Berlin Klin Wchnschr 1912; 32: 1503-1505.
40. BYRD L, SHERMAN RL. Radio-contrast induced acute renal failure: a clinical and pathophysiologic review. Medicine 1979; 58: 270-279.
41. BEDNAREK DR, RUDIN S, WONG R. Assessment of patient exposure for barium enema examinations. Invest Radiol 1983; 18: 453-458.
42. BRUINS SLOT H, STRIJBOSCH L, GREEP JM. Interobserver variability in single plane aortography. Surgery 1981; 90: 497-503.
43. BERGE VAN DEN JH, SCHOUTEN HJA, BOONSTRA S, DRUNEN LITTEL VAN S, BRAAKMAN R. Interobserver agreement in assessment of ocular signs in coma. J Neurol Neurosurg Psychiatry 1979; 42: 1163-1168.
44. BLAKEMAN BM, LITTOOY FN, BAKER WH. Intraarterial digital subtraction angiography as a method to study peripheral vascualr disease. J Vasc Surg 1986; 4: 168-173.
45. BEENTJES LB, TIMMERMANS CWM. Patient doses in the Netherlands. Radiation Protection Dosimetry 1991; 36: 265-268.
46. BOONE JM, LEVIN DC. Radiation exposure to angiographers under different fluoroscopic imaging conditions. Radiology 1991; 180: 861-865.

C

1. CAMPBELL DR. Digital subtraction angiography (DSA) in re-evaluation of angioplasties. J Canad Assoc Radiol 1983; 34: 258-260.
2. CARLIN RA, AMPLATZ K. Downstream aortography. AJR 1970: 109: 536-540.

3. CARMODY RF, YANG PJ, SEEGER JF, CAPP MP. Digital subtraction angiography update, 1986. Invest Radiol 1986; 21: 899-905.
4. CUNNINGHAM IA, HOBBS BB, FENSTER A. A new system for quantitative arterial imaging and blood flow measurement. Invest Radiol 1986; 21: 465-471.
5. CHAKRABORTY JP, GUPTA KL, BARNES GI, VITEK JJ. Digital subtraction angiography apparatus. Radiology 1985; 157: 547.
6. CHAMBERLAIN J, HOUSLEY E, MACPHERSON AIS. The relationship between ultrasound assessment and angiography in occlusive arterial disease of the lower limb. Br J Surg 1975; 62: 64-67.
7. CHANG R, KAUFMAN SL, KADIR S, MITCHELL SE, WHITE RI. Digital subtraction angiography in interventional radiology. AJR 1984; 142: 363-366.
8. COHEN J. A coefficient of agreement for nominal scales. Educ Psych Meas 1960; 20: 37-46.
9. CHIKOS PM, FISHER LD, HIRSCH JH, HARLEY JD, THIELE BL, STRANDNESS DE. Observer variability in evaluating carotid stenosis. Stroke 1983; 14: 885-892.
10. COSSMAN DV, ELLISON JE, WAGNER WH, et al. Comparison of contrast arteriography to arterial mapping with color-flow duplex imaging in the lower extremities. J Vasc Surg 1989; 10: 522-529.
11. CURRY TS, DOWDEY JE, MURRY RC. Christensen's Physics of Diagnostic Radiology. Philadelphia: Lea & Febiger, 4th ed, 1990: 372-391.
12. COHEN G, WAGNER LR, RAUSCHKOLB EN. Evaluation of a digital subtraction angiography unit. Radiology 1982; 144: 613-617.
13. CAPUTO GR, MASUI T, GOODING GAW, CHANG JM, HIGGINS CB. Popliteal and tibioperoneal arteries: feasability of two-dimensional time-of-flight MR angiography and phase velocity mapping. Radiology 1992; 182: 387-392.
14. CRAGG AH, SMITH TP, BERBAUM KS, NAKAGAWA N. Randomised double-blind trial of midazolam/placebo and midazolam/fentanyl for sedation and analgesia in lower extremity angiography. AJR 1991; 157: 173-176.
15. CRUMMY AB, RANKIN RS, TURNIPSEED WD, BERKOFF HA. Biplane arteriography in ischemia of the lower extremity. Radiology 1978; 126: 111-115.
16. CRUMMY AB, STROTHER CM, SACKETT JF, et al. Computerized fluoroscopy: digital subtraction for intravenous angiocardiography and arteriography. AJR 1980; 135: 1131-1140.
17. CRUMMY, STIEGHORST MF, TURSKI PA, et al. Digital subtraction angiography: current status and use of intraarterial injection. Radiology 1982; 145: 303-307.
18. CRUMMY AB, STRATHER CM, LIEBERMAN RP, et al. Digital video subtraction angiography for evaluation of peripheral vascular disease. Radiology 1981; 141: 33-37.
19. CRUMMY AB. Intravenous digital subtraction arteriography in the evaluation of peripheral vascular disease. Ann Radiol 1983; 26: 581-584.
20. CRUMMY AB. Peripheral angiography: some current considerations. In: Strandness DE, Didisheim P, Clowes AW, Watson JT, eds. Vascular diseases: current research and clinical applications. Orlando: Grune & Stratton, Inc; 1987: 85-90.
21. CUNNINGHAM JJ, THURBER B. The abdominal aortogram. AJR 1972; 116: 441-444.
22. CAPP MP, ROEHRIG H, SEELEY GW, FISHER HD, OVITT TW. The digital radiology department of the future. Radiol Clin North Am 1985; 23: 349-355.
23. CASARELLA WJ. Percutaneous transluminal angioplasty below the knee: new techniques, excellent results. Radiology 1988; 169: 271-272.
24. CRAGG AH, GARDNER GA, SMITH TP. Vascular applications of laser. Radiology 1989; 172: 925-935.
25. CHERMET J. Arteriography of lower limbs with blocked circulation ("dry limb" arteriography). Radiology 1981; 140: 826-830.
26. COHEN MI, VOGELZANG RL. A comparison of techniques for improved visualization of the arteries of the distal lower extremity. AJR 1986; 147: 1021-1024.

27. CARDELLA JF, SMITH TP, DARCY MD, HUNTER DW, CASTANEDA-ZUNIGA W, AMPLATZ K. Balloon occlusion femoral angiography prior to in-situ saphenous vein bypass. Cardiovasc Intervent Radiol 1987; 10: 181-187.
28. CAMPBELL WB, FLETCHER EL, HANDS LJ. Assessment of the distal lower limb arteries: a comparison of arteriography and Doppler ultrasound. Ann R Coll Surg Engl 1986; 68: 37-39.
29. CAPP MP. Radiological imaging - 2000 AD. Radiology 1981; 138: 541-550.
30. CRUMMY AB. Digital subtraction imaging in peripheral vascular disease. In: Mistretta CA, Crummy AB, Strother CM, Sackett JF, eds. Digital subtraction angiography: an application of computerized fluoroscopy. Chicago: Year Book Medical, 1982: 58-64.
31. COFFMAN JD, MANNICK JA. Failure of vasodilator drugs in arteriosclerosis obliterans. Ann Intern Med 1972; 76: 35-39.
32. CODMAN EA. Experiments on application of roentgen rays to the study of anatomy. J Exper Med 1898; 3: 383-392.
33. COCHRAN ST, WONG WS, ROE DJ. Predicting angiography induced acute renal function impairment: clinical risk model. AJR 1983; 141: 1027-1033.
34. COPE L. Minipuncture angiography. Radiol Clin North Am 1986; 24: 359-367.
35. COHEN J. Weighted kappa: a nominal scale agreement with provision for scaled disagreement or partial credit. Psychological Bulletin 1968; 70: 213-220.

D

1. DAVIS PC, HOFFMAN JC. Work in progress: intraarterial digital subtraction angiography: evaluation in 150 patients. Radiology 1983; 148: 9-15.
2. DAWSON P. Digital subtraction angiography - a critical analysis. Clin Radiol 1988; 39:474-477.
3. DONGEN VAN RJAM. Aorto-arteriografie en viscerale aortografie: instrumentarium en techniek. Ned Tijdschr Geneesk 1959; 103: 1372-1381.
4. DORPH S, FOLKE K. Complications in translumbar aortography. A comparison of direct needle puncture and aortic catheterization. Acta Radiol Diagn 1972; 12: 750-756.
5. DARDIK H, MILLER N, ADLER J, et al. Primary and adjunctive intra-arterial digital subtraction arteriography of the lower extremities. J Vasc Surg 1986; 3: 599-604.
6. DOLMATCH BL, RHOLL KS, MOSKOWITZ LB, et al. Blue toe syndrome: treatment with percutaneous atherectomy. Radiology 1989; 172: 799-804.
7. DANIEL TB, AKINS EW, HAWKINS IF. A solution to the problem of high-flow jets from miniature angiographic catheters. AJR 1990; 154: 1091-1095.
8. DWYER SJ III, TEMPLETON AW, MARTIN NL, et al. The cost of managing digital diagnosis images. Radiology 1982; 144: 313-318.
9. DETMER DE, FRYBACK D, STROTHER CM. Cost effectiveness of digital subtraction arteriography. In: Mistretta CA, Crummy AB, Strother CM, Sackett JF, eds. Digital subtraction arteriography: an application of computerized fluoroscopy. Chicago: Year Book Medical, 1982: 91-95.
10. DOTTER CT, JUDKINS MP. Transluminal treatment of arteriosclerotic obstruction. Description of a new technique and preliminary report of its application. Circulation 1964; 30: 654-670.
11. DAWOOD R. Editorial: Digital radiology - A realistic prospect? Clin Radiol 1990; 42: 6-11.
12. DAWSON P. Chemotoxicity of contrast media and clinical adverse effects: a review. Invest Radiol 1985; 20: S84-S91.
13. DARCY MD. Lower extremity arteriography: current approach and techniques. Radiology 1991; 178: 615-621.

14. DETRE KM, WRIGHT PHE, MURPHY ML, TAKARO T. Observer agreement in evaluating coronary angiograms. Circulation 1975; 52: 979-986.
15. DETRE KM, WRIGHT PHE, MURPHY ML, TOKARO T. Reliability of assessing change with sequential coronary angiography. Am H J 1982; 104: 816-823.

E

1. EDELMAN RR, MATTLE HP, ATKINSON DJ, HOOGEWOUD HM. MR Angiography. AJR 1990; 154: 937-946.
2. ENZMANN DR, DJANG WT, RIEDERER SJ, et al. Low dose, high-frame rate versus regular dose, low-frame rate digital subtraction angiography. Radiology 1983; 146: 669-676.
3. ENZMANN DR, RIEDERER SJ, HALL AL, BRODY WR, DJANG WT. Integration methods in post-process image manipulation in digital fluoroscopy. Ann Radiol 1983; 26: 557-563.
4. ERGUN DL, MISTRETTA CA, KRUGER RA, RIEDERER SJ, SHAW CG, CARBONE DP. A hybrid computerised fluoroscopy technique for noninvasive cardiovascular imaging. Radiology 1979; 132:739-742.

F

1. FELIX, SIGEL B, POPKY GL. Doppler ultrasound in the diagnosis of peripheral vascul;ar disease. Semin Roentgenol 1975; 10: 315-321.
2. FITZGERALD DE, CARR J. Peripheral arterial disease: Assessment by arteriography and alternative non-invasive measurements. AJR 1977; 128: 385-388.
3. FOLEY WD, KEYES GS, SMITH DF, et al. Work in progress: temporal energy hybrid subtraction in intravenous digital subtraction angiography. Radiology 1983; 148: 265-271.
4. FOLEY WD, MILDE MW. Intraarterial digital subtraction angiography. Radiol Clin North Am 1985; 23: 293-319.
5. FOLEY WD, McDANIEL D, MILDE MW, BELL R. Digital subtraction angiography of the extremities using table translation. Radiology 1985; 157: 255-258.
6. FOLEY WD, BERES J, SMITH DF, et al. IV and intraarterial hybrid subtraction angiography: clinical evaluation. AJR 1986; 147: 613-620.
7. FONTAINE R, HUBINONT J. Les traitement des oblitérations artérielles par autogreffes fraiches et segmentaires de veines. Acta Chir Belg 1950; 49: 397-428.
8. FONTAINE R, KIENY R, GANGLOFF JM, et al. Long term results of restorative arterial surgery in obstructive diseases of the arteries. J Cardiovasc Surg 1964; 5: 463-472.
9. FORD KK, HEINZ ER, JOHNSON GA, DRAYER BD, DUBOIS PJ. Low cost digital subtraction angiography. AJNR 1982; 3: 448-451.
10. FRANK T, VOIGT W. Venöse digitale subtraktions arteriographie der Becken-Bein-Region mit Schritt verschiebung. Röntgen Bl 1984; 37: 373-376.
11. FREEDMAN LS. Evaluating and comparing imaging techniques: a review and classification of study designs. Br J Radiol 1987; 60:1071-1081.
12. FLANIGAN BD, GOMES AS, STAMBUK EC, LOIS JF, PAIS SO. Intraarterial digital subtraction angiography: comparison with conventional hepatic arteriography. Radiology 1983; 148: 17-21.
13. FUJITA H, DOI K, CHAN HP, GIGER ML, DUDA EE. Dynamic and static phantoms for evaluation of digital subtraction angiographic systems. Radiology 1985; 155: 799-803.
14. FINK U, HEYWANG S, MAYR B, BERGER H. Subtracted versus non-subtracted imaging in peripheral angiography. Eur J Radiol 1989; 9: 236-240.
15. FEINSTEIN AR. Clinical Epidemiology: The architecture of clinical research. Philadelphia: W.B. Saunders Company, 1985: 57-58.

16. FINK U, HEYWANG SH, HILBERTZ T, FISCHER K, JENNER E, BUCHSTEINER W. Peripheral DSA with automated stepping. Eur J Radiol 1991; 13: 50-54.
17. FLANIGAN DP, WILLIAMS LR, KEIFER T, SCHULER JJ, BEHREND AJ. Prebypass operative arteriography. Surgery 1982; 92: 627-633.
18. FREEDMAN GS. Economic analysis of outpatient digital angiography. Appl Radiol 1982; 11: 29-38.
19. FLANIGAN DP. Direct measurement of arterial pressure: clinical applications. In: Rutherford RB, ed. Vascular Surgery. Philadelphia: WB Saunders, 1989: 112-119.
20. FUSTER V, KOTTKE BA, JUERGENS JL. Atherosclerosis. In: Allen-Barker-Hines, Peripheral Vascular Diseases. Juergens JL, Spitell JA, Fairbairn II, eds. Philadelphia: WB Saunders, 1980: 219-235.
21. FLANIGAN DP, TULLIS JP, STREETER U, WHITEHOUSE WM, FREY WJ, STANLEY JC. Multiple subcritical arterial stenoses: effect on post-stenotic pressure and flow. Ann Surg 1977; 186: 663-668.
22. FAIRBAIRN II JF. Clinical manifestations of peripheral vascular disease. In: Allen-Barker-Hines Peripheral vascular Diseases. Juergens JL, Spitell JA, Fairbairn II JF, eds. Philadelphia: WB Saunders, 1980: 3-49.
23. FRIEDMAN J, ZEIT RM, COPE C, BERNHARD VM. Optimal use of tolazoline in arteriography. AJR 1984; 142: 817-820.
24. FARIÑAS PL. A new technique for the arteriographic examination of the abdominal aorta and its branches. AJR 1941; 46: 641-645.
25. FELLMETH BD, BOOKSTEIN JJ, LURIE AL, DILLARD JP. Rapid progression of peripheral vascular disease after diagnostic angiography. Radiology 1990; 175: 71-74.
26. FLEISS JL. Statistical methods for rates and proportions. 2nd ed. New York: John Wiley & Sons; 1981: 212-236.
27. FIGLEY MM, MARGULIS AR. The impact of new imaging technology on health care, research and teaching: an international symposium. AJR 1987; 149: 1111-1126.
28. FRIEDMAN SG, MOCCIO CG. A prospective comparison of intraarterial digital subtraction angiography and conventional angiography prior to lower extremity revascularisation. J Cardiovasc Surg 1989; 30: 462-466.

G

1. GAMILL S, CRAIGHEAD C. Translumbar aortography updated. Surg Gyn Obstet 1975; 140: 59-64.
2. GARVEY CJ, WILKINS RA, LEWIS JD. Peripheral vascular disease: prospective study of intraarterial digital subtraction angiography using a 9-inch intensifier. Radiology 1986; 159: 423-427.
3. GJØRUP T, NIELSEN H, BORDIN G, JENSEN L, MØRUP A, JENSEN. Interobserver variation in the radiographic diagnosis of gastric ulcer. Acta Radiol Diag 1985; 26: 289-291.
4. GERSTEN K, PILLARI G, GREENSPAN B, ROSEN B, ZITO J. Crossed-leg technique for digital subtraction angiography. AJR 1986; 146: 843-844.
5. GMELIN E, LIEPE B, BORGIS KJ, TÄNSER B, WEISS HD. Intra-arterielle DSA der Femoralis gabel als Ergänzung zür konventionellen Becken-Bein-Arteriographie. Röntgen-Bl 1984; 37: 377-380.
6. GMELIN E. Schleusintechnik für die translumbale Katheterangiographie. ROFO 1986; 144: 523-525.
7. GALBRAITH JE, MURPHY ML, SOYZA N. Coronary angiogram interpretation - interobserver variability. JAMA 1978; 19: 2053-2056.
8. GOMES AS, PAPIN PJ, MANKOVICH NJ, LOIS JF. Digital subtraction angiography: a comparison of 512^2 and 1024^2 imaging. AJR 1986; 146: 835-838.

9. GOODMAN PC, JEFFREY RB, BRANT-ZAWADSKI M. Digital subtraction angiography in extremity trauma. Radiology 1984; 153: 61-64.
10. GOODSITT MM, ABBATE L, HESSELINK JR. Digital subtraction angiography systems: assessing performance with phantoms. Radiology 1985; 156: 811-815.
11. GRAY'S ANATOMY, 36th ed. Warwick R, Williams PL eds. Edinburgh: Churchill Livingstone, 1980: 729-735.
12. GREEN JD. Compensating collimator for digital subtraction angiography. AJR 1984; 143: 899.
13. GRITTER KJ, LAIDLAW WW, PETERSON NT. Complications of outpatient transbrachial intraarterial digital subtraction angiography. Radiology 1987; 162: 125-127.
14. GROLLMAN JH, MARCUS R. Antegrade translumbar aortography. Radiology 1984; 153: 249-250.
15. GELFLAND DW, OTT DJ. Methodologic considerations in comparing imaging modalities. AJR 1985; 144: 1117-1121.
16. GUTHANER DF, BRODY WR, LEWIS BD, KEYES GS, BELANGER BF. Clinical application of hybrid subtraction digital angiography: preliminary results. Cardiovasc Intervent Radiol 1983; 6: 290-294.
17. GUTHANER DF, WEXLER L, ENZMANN DR. Evaluation of peripheral vascular disease using digital subtraction angiography. Radiology 1983; 147: 393-398.
18. GIUSTRA PE, KILLORAN PJ. Outpatient arteriography at a small community hospital. Radiology 1975; 116: 581-583.
19. GOSLING RG, DUNBAR G, KING DM, et al. The quantitative analysis of occlusive peripheral arterial disease by a nonintrusive ultrasonic technique. Angiology 1971; 22: 52-55.
20. GREENING JR. Fundamentals of radiation dosimetry. 2nd ed. Bristol: Hilger A. Ltd, 1985: 78.
21. GRANT EG. Duplex ultrasonography: its expanding role in noninvasive vascular disease. Radiol Clin North Am 1985; 23: 563-582.
22. GLOVER JL, BENDICK PJ, JACKSON VP, BECKER GJ, DILLEY RG, HOLDEN RW. Duplex ultrasonography, digital subtraction angiography and conventional angiography in assessing carotid atherosclerosis. Archives of Surgery 1984; 119: 664-669.
23. GREINACHER CFC, BACH EF. Computer-assisted radiology: features and economics of PACS. Eur J Radiol 1990; 10: 223-226.
24. GOLDSTONE J. Vascular imaging techniques. In: Rutherford RB, ed. Vascular Surgery. Philadelphia: WB Saunders, 1989: 119-128.
25. GARDNER E, GRAY DJ, O'RAHILLY R. Anatomy: a regional study of human structure, 4th ed. Philadelphia: WB Saunders, 1975: 219-220; 228-229; 234.

H

1. HALDEN WJ, WHITE RI, BRIGHT J, MITCHELL SE, CHANG R. Vessel sizing wire: accurate vessel measurement using digital subtraction arteriography. Radiology 1986; 161: 556-557.
2. HALL JR, HACKING PH, LAYZELL T. Comparison of venous digital subtraction angiography and aortography in patients with peripheral vascular disease of the lower limbs. Clin Radiol 1985; 36: 315-319.
3. HARDER VON Th, JANSON R, LACKNER K, FRANKEN Th, FISCHER P. Digitale Videosubtraktions angiographie (DVSA) der Bauchaorta, der Becken- und Beinarterien. ROFO 1983; 138: 301-309.
4. HARDER VON Th, NICOLAS V, KERSJES W, KÖSTER O. Arterielle DSA mit transbrachialen 4-French Katheter. ROFO 1988; 149: 35-38.

5. HARRINGTON DP, BOXT LM, MURRAY PD. Digital subtraction angiography: overview of technical principles. AJR 1982; 139: 781-786.
6. HOLMAN CB, BULLARD FE. The application of closed-circuit television in diagnostic roentgenology. Proc Mayo Clin 1963; 38: 67-72.
7. HARRINGTON DP, KANDARPA K. Quantification in peripheral angiography. Cardiovasc Intervent Radiol 1987; 10: 400-407.
8. HARRIS PL, TAYLOR LA, CAVE FD, CHARLESWORTH D. The relationship between Doppler ultrasound assessment and angiography in occlusive arterial disease of the lower limbs. Surg Gyn Obstet 1974; 138: 911-914.
9. HAUT G, AMPLATZ K. Complication rates of transfemoral and transaortic catheterization. Surgery 1968; 63: 594-596.
10. HAENDLE J, MARHOFF P. Current methods of digital imaging in conventional X-ray diagnosis. Eur J Radiol 1990; 10: 218-222.
11. HAWKINS IF, WERTMAN DE. A new fine needle for translumbar aortography. Radiology 1981; 139: 744-746.
12. HORVATH W, OERTL M, HAIDINGER D. Percutaneous transluminal angioplasty of crural arteries. Radiology 1990; 177: 565-569.
13. HAHN D, KUFFER G, ZIEGLER L, PFLUGER Th. Diagnostic value of high-resolution DSA in peripheral vascular diseases. Radiology 1989; 173 (P): 177.
14. HENDRICKX PJ, LUSKA G, FISCHER M, STEGMAN T. Peripherven̈öse DSA der Unterschenkel arterien bei AVK-Patienten. ROFO 1985; 143: 341-346.
15. HERTER VON M, LACKNER K. Quantifiziering von Gefässtenosen mit der DSA. ROFO 1985; 143: 650-655.
16. HESSEL SJ, ADAMS DF, ABRAMS HL. Complications of angiography. Radiology 1981; 138: 273-281.
17. HARRISON RM. A re-evaluation of the "saturated scatter" method for estimating the energy imparted to patients during diagnostic radiology examinations. Phys Med Biol 1983; 28: 701-707.
18. HESSELINK JR, HAYMAN LA, CHUNG KJ, McGINNIS BD, DAVIS KR, TAVERAS JM. Myocardial ischaemia during intravenous DSA in patients with cardiac disease. Radiology 1984; 153: 577-582.
19. HESSELINK JR, CHANG KH, CHUNG KJ, ABBATE L. Flow analysis with digital subtraction angiography: 1) description of a simplified flow model. AJNR 1986; 7: 423-426.
20. HOL PK, HELDAAS J, SKJENNALD A. Demonstration of pedal arterial arcades in occlusive arteriosclerotic disease. Acta Radiol Diagn 1989; 30: 61-63.
21. HOLLAND BA, JEFFREY RB, BRANT-ZAWADSKI M. Intravenous digital subtraction angiography in the demonstration of femoral pseudo-aneurysms. AJR 1983; 141: 607-608.
22. HUNTER GJS, HUNTER JV, BROWN NJG. Parametric imaging using digital subtraction angiography. Br J Radiol 1986; 59: 7-11.
23. HYNES DM, GERSHATER R, EDMONDS EW, ROWLANDS JA, BARANOSKI D, TUROW DG. Radiation dose implications of digital angiographic systems. AJR 1984; 143: 307-312
24. HEMINGWAY AP. Contrast media in angiography and digital subtraction angiography. In: CARR DH, ed. Contrast media. Edinburgh, Churchill Livingstone,1988:104-111.
25. HILAL SK. Hemodynamic changes associated with the intraarterial injection of contrast media. Radiology 1966; 86: 615-633.
26. HOWARD LA, THAL ER, REDMAN HC, GIBSON P. Intraarterial digital subtraction angiography in the evaluation of peripheral vascular trauma. Ann Surg 1989; 210: 108-111.
27. HINDEL R. Review of optical storage technology for archiving digital medical images. Radiology 1986; 161: 257-262.
28. HAWKINS IF, AKINS EW. Miniaturization of catheter systems for angiography. Radiology 1989; 172:1015-1021.

29. HASSON JE, GOULD SA, MOSS GS. Blood flow laboratory techniques of the arteries. In: Pinsky S, Moss GS, Srikantaswamy S, Ryo UY, Gould SA, Pond GD, eds. Imaging of the peripheral vascular system. Orlando: Grune & Stratton 1984: 3-18.
30. HOWE D, OSTROLENK D, ADCOCK D, FARELL J. Patient effective dose equivalent from selected arteriograms. 36th Annual meeting Health Physics Society; 1991, July 21-26, Washington, USA.
31. HAACKE EM, MASARYCK J. The salient features of MR Angiography. Radiology 1989; 173: 611-612.
32. HASCHEK VON E, LINDENTHAL OT. Ein Beitrag zur praktischen Verwerthung der Photographie nach Röntgen. Wien Klin Wschr 1896; 9: 63-64.
33. HENDEE WR. Technology assessment: the contribution of professional organisations. AJR 1990; 154:647-651.
34. HILLMAN BJ. The value of imaging technology to patients health. AJR 1988; 150:1191-1192.
35. HANAFEE W, STOUT P. Subtraction technic. Radiology 1962; 79: 658-661.
36. HOUNSFIELD GN. Computerised transverse axial scanning (tomography): 1) description of system. Br J Radiol 1973; 46:1016-1022.
37. HOOFWIJK AGM. Kritieke ischemie van het been. (Severe lower limb ischemia). Thesis.Utrecht: University of Utrecht, 1990. 179p.
38. HARDER T, LACKNER K, HERTER M, LEIPNER N. Digitale Subtractionsangiographie (DSA) und Blattfilmangiographie der Becken- und Beinarterien. (English summary). ROFO 1987; 146: 438-446.

I

1. ILLESCAS FF, FORD KK, BRAUN SD, DUNNICK NR. Intraarterial digital subtraction angiography in hypertensive azotemic patients. AJR 1984; 143: 1065-1067.
2. IMPARATO AM, KIM GE, MADAYAG M, HAVESON SP. Angiographic criteria for successful tibial arterial reconstructions. Surgery 1973: 74: 830-838.
3. IMPARATO AM, KIM GE, DAVIDSON T, CROWLEY JG. Intermittent claudication: its natural cause. Surgery 1975; 78: 795-799.

J

1. JEANS WD. Comparison of advantages and disadvantages of different methods of obtaining images. (Letter to the editor). Br J Radiol 1987; 60: 1237-1238.
2. JOHNSON GA, SUDDARTH S, DANIELY ND. Standards for performance in digital radiography. In: James Jr AE, Anderson JA, Higgins CB, eds. Digital Image Processing in Radiology. Baltimore/London: Williams & Wilkins, 1985: 190-201.
3. JOHNSTON KW, TARASCHUK I. Validation of the role of pulsatiltiy index in quantitation of the severity of peripheral arterial occlusive disease. Am J Surg 1976; 131: 295-297.
4. JANEVSKI BK. Arteriography of the peripheral vessels of the extremities: technique and essentials of interpretation. J Med Imaging 1989; 3: 197-202.
5. JEANS WD, ARMSTRONG S, COLE SEA, HORROCKS M, BAIRD RN. Fate of patients undergoing transluminal angioplasty for lower limb ischemia. Radiology 1990; 177: 559-564.
6. JOHN HT, WARREN R. The stimulus to collateral circulation Surgery 1961; 49: 14-25.
7. JEANS WD. The development and use of digital subtraction angiography. Br J Radiol 1990; 63: 161-168.
8. JANEVSKI BK. The history of the angiography of the upper extremity. In: Angiography of the upper extremity. The Hague, Martinus Nijhoff. 1982: 3-5.

9. JACOBS MJHM. Capillary micoscopy and haemorheology in vasospastic and occlusive vascular diseases (Thesis). Maastricht, The Netherlands: Universty of Limburg, 1985. 125p.
10. JÖRNING P. De veneuze overbruggingsplastiek in het femoro-popliteale traject (Thesis with summary in Dutch). Maastricht, The Netherlands. University of Limburg, 1981. 131p.
11. JANSSEN JHA. Clinical application of video image processing in cardiac angiology (Thesis). Maastricht, The Netherlands. University of Limburg, 1989; 129p.
12. JAGER KA, PHILLIPS DJ, MARTIN RL, et al. Noninvasive mapping of lower limb arterial lesions. Ultrasound in Med & Biol 1985; 11: 515-521.
13. JUERGENS JL, BERNATZ PE. Atherosclerosis of the extremities. In: Allen-Barker-Hines Peripheral Vascular Diseases, 5th ed. Juergens JL, Spitell JA, Fairbairn II JF, eds. Philadelphia: WB Saunders, 1980: 253-293.

K

1. KARACAGIL S, ALMGREN B, BOWALD S, ERIKSSON I. Angiographic criteria for prediction of early graft failure of secondary infrainguinal bypass surgery. J Vasc Surg 1990; 12: 131-138.
2. KARKOW WS, CRANLEY JJ. Variations in interpretation of arterial stenosis. J Cardiovasc Surg 1989; 30: 826-832.
3. KAUFMAN SL, CHANG R, KADIR S, MITCHELL SE, WHITE RI. Intraarterial digital subtraction angiography: a comparative view. Cardiovasc Intervent Radiol 1983; 6: 271-279.
4. KAUFMAN SL, CHANG R, KADIR S, MITCHELL SE, WHITE RI. Intraarterial digital subtraction angiography in diagnostic arteriography. Radiology 1984; 151: 323- 327.
5. KELLY WM, BRANT-ZAWADSKI M, NORMAN D, GOULD R. Beam attenuation devices for digital subtraction angiography. Radiology 1984; 153: 817-818.
6. KEY H, JACKSON PC, THOMAS EA, JEANS WD, DAVIES ER. The accuracy of digital subtraction angiography for the quantification of atherosclerosis. Br J Radiol 1987; 60: 1083-1088.
7. KINNISON M, PERLER BA, WHITE RI, et al. Tailored approach for evaluation of peripheral vascular disease: intravenous digital subtraction angiography. AJR 1984; 142: 1205-1209.
8. KITSLAAR PJEHM. Bloeddrukmeting aan de enkel bij obstruerend arterieel vaatlijden. Ned Tijdschr Geneesk 1981; 125 (44): 1781-1785.
9. KRUGER RA, NELSON JA, ROY DG, MILLER FJ, ANDERSON RE, LIU P. Dynamic tomographic digital subtraction angiography using temporal filtration. Radiology 1983; 147: 863-867.
10. KRUGER RA. Image data acquisition, processing, storage and display. Cardivasc Intervent Radiol 1983; 6: 183-186.
11. KRUGER RA, BATEMAN W, LIU P, NELSON JA. Bloodflow determination using recursive processing: a digital radiographic method. Radiology 1983; 149: 293-298.
12. KRUGER RA, SEDAGHATI M, ROY DG, LIU P, NELSON JA, et al. Tomosynthesis applied to digital subtraction angiography. Radiology 1984; 152: 805-808.
13. KUBAL WS, CRUMMY AB, TURNIPSEED WD. The utility of digital subtraction arteriography in peripheral vascular disease. Cardiovasc Interv Radiol 1983; 6: 241-249.
14. KEHLER M, ALBRECHTSSON U, ALWMARK A, et al. Intra-operative digital angiography as a control of the in-situ saphenous vein bypass grafts. Acta Radiol Diagn 1988; 29: 645-648.
15. KOZAK BE, BEDFELL JE, ROSCH J. Small vessel leg angiography for distal vessel bypass grafts. J Vasc Surg 1988; 8: 711-715.

16. KATZEN BT. Peripheral abdominal and interventional applications of DSA. Radiol Clin North Am 1985; 23: 227-241.
17. KITSLAAR PJEHM. Doppler ultrasound tests in the diagnosis of chronic aortoiliac obstruction (Thesis). Maastricht, The Netherlands: University of Limburg, 1982. 179p.
18. KRUGER RA, RIEDERER SJ. Basic concepts of digital subtraction angiography. Boston: GK Hall Medical Publishers, 1984.
19. KETONEN P, HARJOLA PT, ALA-KULJU K. Femoral-tibial bypass for limb salvage. VASA 1989; 18: 9-11.
20. KITSLAAR PJEHM, JÖRNING PJG, KÖHLEN JPFM. Assessment of aortoiliac stenosis by femoral artery pressure measurement and Doppler wave-form analysis. Eur J Vasc Surg 1988; 2: 35-40.
21. KING JN, ORRISON WW, KECK GM, DEMAREST GB, HINSON JE, SELL JJ. Arteriography with portable DSA equipment. Radiology 1989; 172: 1023-1025.
22. KICKEN PJ, JANSSEN JHA, MICHELS HR, HUYSKENS CJ. Radiation exposure during cardiac catheterization procedures. International Radiation Protection Association (IRPA 7), 1988; 2: 737-740.
23. KAHN PC, BOYER DN, MORAN JM, CALLOW AD. Reactive hyperemia in lower extremity arteriography: an evaluation. Radiology 1968; 90: 975-980.
24. KIM D, ORRON DE, SKILLMAN JJ. Surgical significance of popliteal arterial variants. Ann Surg 1989; 210: 776-781.
25. KADIR S. Arteriography of the lower extremity vessels. In: Kadir S, Diagnostic Angiography. Philadelphia: WB Saunders, 1986: 254-307.
26. KUTHAN F, BURKHALTER A, BAITSCH R, et al. Development of occlusive arterial disease in the lower limbs. Arch Surg 1971; 103: 545-547.
27. KRAM HB, APPEL PL, SHOEMAKER WC. Multisensor transcutaneous oximetric mapping to predict below-knee amputation wound healing: use of critical pO_2. J Vasc Surg 1989; 9: 796-800.
28. KADIR S. Basic catheterization techniques. In: Kadir S, Diagnostic Angiography. Philadelphia: WB Saunders, 1986: 34-77.
29. KRUGER RA, MISTRETTA CA, HOUK TL, et al. Computerised fluoroscopy in real time for non-invasive visualisation of the cardiovascular system - preliminary studies. Radiology 1979; 130: 49-57.
30. KADIR S. Complications of angiography. In: Kadir S, Diagnostic Angiography. Philadelphia: WB Saunders, 1986: 679-689.
31. KRUGER RA, MILLER FJ, NELSON JA, LIU P-Y, BATEMAN W. Digital subtraction angiography using a temporal bandpass filter: associated patient motion properties. Radiology 1982; 145: 315-320.
32. KRUGER RA. Basic physics of computerized fluoroscopy difference imaging. In: Mistretta CA, Crummy AB, Strother CM, Sackett JF, eds. Digital subtraction angiography: an application of computerized fluoroscopy. Chicago: Year Book Medical, 1982: 16-22.
33. KAMINSKI DL, BARNER HB, DORIGIM JA, KAISER CC, WILLMAN VL. Femoro-tibial bypass grafting. Arch Surg 1972; 104: 527-530.
34. KADIR S. Pressure measurements and hemodynamics. In: Kadir S, Diagnostic Angiography. Philadelphia: WB Saunders, 1986: 82-92.
35. KORAN LM. The reliability of clinical methods, data and judgements. N Engl J Med 1975; 642-646 (Part 1),695-701 (Part2).
36. KICKEN PJ, KEMERINK GJ, VAESSEN PJ, ACKERMANS JJ. An automated measurement system for the characterisation of patient exposure during angiography. CEC: Seminar on dosimetry in diagnostic radiology. 1991: March 19-21, Luxembourg.

L

1. LACKNER VON K, HARDER Th, HERTER M, LEIPNER N. Vergleich der intra-arteriellen digitalen Subtraktionsangiographie mit der konventionellen Arteriographie. ROFO 1984; 141: 616-624.
2. LANGLOIS Y, ROEDERER GO, CHAN A, et al. Evaluating carotid artery disease - the concordance between pulsed Doppler/ spectrum analysis and angiography. Ultrasound in Med and Biol 1983; 9: 51-63.
3. LACKNER K, DOLKEN W, EICHELKRANT W, HAHN N. Messung der absoluten intravasalen Strömungsgeschwindigkeit mit der digital Subtraktionsangiographie. ROFO 1986; 144: 25-29.
4. LAMORTE WW, MENZOIAN JD, SIDAWY A, HEEREN T. A new method for the prediction of peripheral vascular resistance from the preoperative angiogram. J Vasc Surg 1985; 2: 703-708.
5. LANDRENAU MD, RAJU S. Infections after elective bypass surgery for lower limb ischemia: the influence of preoperative transcutaneous arteriography. Surgery 1981; 90: 956-960.
6. LANDIS RJ, KOCH GG. The measurement of observer agreement for categorical data. Biometrics 1977; 159-174.
7. LEE KR, COX GG, PRICE HI, BATNITZKY S, DWYER SJ. A metric ruler for digital subtraction angiography. Radiology 1983; 148: 296.
8. LEE KR, COX GG, PRICE HI, JOHNSON JA, NEFF JR. Intraarterial digital subtraction arteriographic evaluation of extremity tumors: comparison with conventional arteriography. Radiology 1986; 158: 255-258.
9. LEVIN DC. Digital subtraction angiography; myths and reality. Radiology 1984; 151: 803.
10. LEVIN DC, SCHAPIRO RM, BOXT LM, DUNHAM L, HARRINGTON DP, ERGUN DL. Digital subtraction angiography: principles and pitfalls of image improvement techniques. AJR 1984; 143: 447-454.
11. LEWIS BD, ENZMANN DR, GUTHANER DF, BRODY WR. A high frame-rate digital subtraction angiography imaging technique for evaluation of aorta-femoral runoff. Radiology 1984; 151: 789-790.
12. LIU P, KRUGER RA, NELSON JA, MILLER FJ, OSBORN AG, WOJTOWYCZ M. Digital angiography: matched filtration versus mask-mode subtraction. Radiology 1985; 1554: 217-220.
13. LANDIS JR, KOCH GG. A review of statistical methods in the analysis of data arising from reliability studies. Stat Neerland 1975; 29:101-123 (Part1), 29:151-161 (Part 2).
14. LEIBOVIC SJ, FELLOWS KE. Patient radiation exposure during pediatric cardiac catheterisation. Cardiovasc Intervent Radiol 1983; 6: 150-153.
15. LALLY ME, JOHNSTON KW, ANDREWS D. Percutaneous transluminal dilatation of peripheral arteries: an analysis of factors predicting early success. J Vasc Surg 1984; 1: 704-709.
16. LUSZA G. X-ray anatomy of the vascular system. London: Butterworth & Co, 1974: 298-304.
17. LYSEL VAN MS, DOBBINS JT, PEPPLER W, et al. Work in progress: Hybrid temporal energy subtraction in digital fluoroscopy. Radiology 1983; 147: 869-874.
18. LEE KR, ANDERSON WF, WETZEL LH. Hardcopy recordings of analog and digital images. Invest Radiol 1988; 23: 933-939.
19. LO SB, TAIRA RK, MANKOVICH NJ, HUANG HR, TAKEUCHI H. Performance characteristics of a laser scanner and laser printer system for radiological imaging. Computerized Radiol 1986; 10: 227-237.

20. LEATHER RP, SHAH DM, KARMODY AM. Infrapopliteal arterial bypass for limb salvage: increased patency and utilization of the saphrenous vein in situ. Surgery 1981; 90: 1000-1008.
21. LEA THOMAS M, TREWEEKE PS. Intravenous digital subtraction arteriography: a comparison of peripheral versus central contrast injection. Br J Radiol 1986; 59: 241-244.
22. LEA THOMAS M, LINTOTT DJ. Large volume aortography in atherosclerotic peripheral vascular disease. A comparative investigation with conventional aortography. Acta Radiol Diagn 1973; 14: 56-64.
23. LUDBROOK J. Collateral artery resistance in the human lower limb. J Surg Research 1966; 6: 423-434.
24. LEEDS NE. Image enhancement with magnification and subtraction. Radiol Clin North Am 1974; 12: 241-256.
25. LASSEN NA. Muscle blood flow in normal man and in patients with intermittent claudication evaluated by simultaneous Xe-133 and Na-124 clearances. J Clin Invest 1964; 43: 1805-1812.
26. LINDGREN P. Hemodynamic responses to contrast media. Invest Radiol 1970; 5: 424-435.
27. LOSSEF SV, RAJAN SS, PATT RH, et al. Gadolinium-enhanced magnitude contrast MR angiography of popliteal and tibial arteries. Radiology 1992; 184: 349-355.
28. LONGLAND LJ. The collateral circulation of the limb. Ann R Coll Surg Engl 1953; 13: 161-176.
29. LIE JT. The structure of the normal vascular system and its reactive changes. In: Allen-Barker-Hines. Peripheral Vascular Diseases. Juergens JL, Spitell JA, Fairbairn II JF, eds. Philadelphia: WB Saunders; 1980: 51-81.

M

1. MACINTYRE WJ, PAVLICEK W, GALLAGHER JH, MEANEY TF, BUONOCORE E, WEINSTEIN MA. Imaging capability of an experimental digital subtraction angiography unit. Radiology 1981; 139: 307-313.
2. MANCINI GBJ, OSTRANDER DR, SLUTSKY RA, SHABETAI R, HIGGINS CB. Intravenous versus left ventricular injection of ionic contrast material: hemodynamic implications for DSA. AJR 1983; 190: 425-430.
3. MARSMAN JWP, UNNIK VAN JG, GEENEN G, BARWEGEN MGMH. Digital subtraction angiography as an adunct to conventional arteriography. VASA 1985; 14: 62-65.
4. MAURO MA, JAQUES PF, MOORE M. The popliteal artery and its branches: embyologic basis of normal and variant anatomy. AJR 1988; 150: 435-437.
5. MAY AG, WEESE DE JA, ROB CG. Hemodynamic effects of arterial stenosis. Surgery 1963; 53: 513-524.
6. MAY AG, BERG VAN DE L, WEESE DE JA, ROB CG. Critical arterial stenosis. Surgery 1963; 54: 250-257.
7. MEANEY TF, WEINSTEIN MA, BUONOCORE E, et al. Digital subtraction angiography of the human cardiovascular system. AJR 1980; 135:1153-1160.
8. MENZOIAN JD, LAMORTE WW, CANTELMO NL, DOYLE J, SIDAWY AN, SAVENOR A. The preoperative angiogram as a predictor of peripheral vascular resistance. Am J Surg 1985; 150: 346-352.
9. MACCIA C, BENEDITTINI M, LEFAURE C. Doses to patients from diagnostic radiology in France. Health Physics 1988; 54: 397-408.
10. MIKKELSON K, MADSEN EH, SORENSEN HB, KRISTENSEN LH. Complications by translumbar aortography. ROFO 1976; 125: 371-373.
11. MILLER FJ, MINEAU DE, KOEHLER PR, et al. Clinical intraarterial digital subtraction imaging: use of small volumes of iodinated contrast material or carbon dioxide. Radiology 1983; 148: 273-278.

12. MISTRETTA CA, CRUMMY AB, STROTHER CM. Digital angiography: a perspective. Radiology 1981; 139:273-276.
13. MENANTEAU BP, TREUTENAERE JM, MARCUS C, LADAM V, GAUSSERAND F. Imaging of the digital arteries: digital subtraction angiography versus conventional arteriography. J Can Assoc Radiol 1989; 40: 34-37.
14. MODIC MT, WEINSTEIN MA, PAVLICECK W, et al. Intravenous digital subtraction angiography: peripheral versus central injection of contrast medium. Radiology 1983; 147: 711-715.
15. MODIC MT, WEINSTEIN MA, DUCHESNEAU PM, BUONOCORE E. Comparative value of digital subtraction angiography. In: James AE, Anderson JH, Higgins CB, eds. Digital Image Processing In Radiology. Baltimore: Williams & Wilkins; 1985: 210-218.
16. MORTON DL, EHRENFELD WK, WYLIE EJ. Significance of outflow obstruction after femoropopliteal endarterectomy. Arch Surg 1967; 94: 592-599.
17. MORIN JF, JOHNSTON KW, WASSERMAN L, ANDREWS D. Factors that determine the long-term results of percutaneous transluminal dilatation for peripheral arterial occlusive disease. J Vasc Surg 1986; 4: 68-72.
18. MISTRETTA CA, ORT MG, CAMERON JR, CRUMMY AB, MORAN PR. A multiple image subtraction technique for enhancing low contrast, periodic objects. Invest Radiol 1973; 8: 43-49.
19. MULLIGAN SA, MATSUDA T, LANZER P, et al. Peripheral arterial occlusive disease: prospective comparison of MR angiography and color duplex US with conventional angiography. Radiology 1991; 178: 695-700.
20. MORRIS PE, HESSEL SJ, COUCH NP, et al. Surgery and the progression of the occlusive process in patients with peripheral vascular disease. Radiology 1977; 124: 343-348.
21. MISTRETTA CA, PEPPLER WW, LYSEL VAN M, et al. Recent advances in digital radiography. Ann Radiol 1983; 26: 537-542.
22. MONIZ E. Arterial encephalography; its importance in the location of cerebral tumors. Revue Neurologique 1927; 48:72.
23. MAVOR GE. The pattern of occlusion in atheroma of the lower limb arteries: the correlation of clinical and arteriographic findings. Br J Surg 1956; 43: 352-364.
24. MEYERS PH, BECKER HC, SWEENEY JW, NICE CM, NETTLETON WJ. Evaluation of a computer-retrieved radiographic image. Radiology 1963; 81:201-206.
25. MILLER ER, McCURRY EM, HRUSKA B. An infinite number of laminograms from a finite number of radiographs. Radiology 1971; 98: 249-255.
26. MADDISON FE, KUMPE DA, RUTHERFORD RB, REDMOND PL. Contrast arteriography. In: Rutherford RB, ed. Vascular Surgery. Philadelphia: WB Saunders, 1989: 157-177.
27. MEANEY TF. Comparison of digital subtraction arteriography and conventional angiography in the extracranial, cerebral and renal circulations. In: Mistretta CA, Crummy AB, Strother CM, Sackett JF, eds. Digital subtraction arteriography: an application of computerized fluoroscopy. Chicago: Year Book Medical, 1982: 96-100.
28. MISTRETTA CA. Development of digital subtraction angiography. In: Mistretta CA, Crummy AB, Strother CM, Sackett JF, eds. Digital subtraction angiography: an application of computerized fluoroscopy. Chicago; Year Book Medical 1982: 7-15.
29. McCURDY JR, LAIN KC, ALLGOOD RJ, GREENFIELD LJ, WILLIAMS GR. Angiographic determinants of femoropopliteal bypass graft patency. Ten year experience. Am J Surg 1972; 124: 789-793.
30. MOLNAR W, PAUL DJ. Complications of axillary arteriotomies. An analysis of 1762 consecutive studies. Radiology 1972; 104: 269-276.
31. MISTRETTA CA, CRUMMY AB. Diagnosis of cardiovascular disease by digital subtraction angiography. Science 1981; 214: 761-765.

32. MYGIND T, DORPH S, BLICHERT TOFT M, PEDERSEN ML, SIEMSEN O, JACOBSEN GK. Mammography is an objective diagnostic method. Acta Radiol Diag 1984; 25: 189.
33. MARCUS JB, SOMERS S, FRANIC SE, MODA G, STEVENSON GW. Interobserver variation in the interpretation of abdominal radiographs. Radiology 1989 171: 69-71.
34. MIRVIS SE, BIDWELL KJ, BUDDEMEYER EU, et al. Value of chest radiography in excluding traumatic aortic rupture. Radiology 1987; 163: 487-493.
35. MOLL FL. Observer variabilty with conventional and digital subtraction carotid angiograms. Eur J Vasc Surg 1987; 1: 297-230.

N

1. NEUFANG KFR, FRIEDMANN G, PETERS PE, MÖDDER CC. Indikationen zur intraarteriellen digitalen Subtraktionsangiographie (IA-DSA) bei Gefässprozessen. ROFO 1983; 139: 160-166.
2. NITATORI T, HACHIYA J, KORENAGA T, FURUYA Y. Whole body intravenous digital subtraction angiography. Radiology 1985; 156: 829-830.
3. NORMAN D, ULLOA N, BRANT-ZAWADSKI M, GOULD RG. Intraarterial digital subtraction imaging cost considerations. Radiology 1985; 156: 33-35.
4. NUDELMAN S. Historical perspectives on photo-electronic ddigital radiology. In: James AE, Anderson JH, Higgins CB, eds. Digital Image Processing in Radiology. Baltimore: Williams & Wilkins; 1985: 1-27.
5. NOER I, PRAESTHOLM J, TØNNESEN KH. Supplementary angiography when lumbar angiograms fail to demonstrate the vessels to the leg. Cardiovasc Intervent Radiol 1981; 4: 77-79.
6. NELSON JA. Newer subtraction and filtration techniques. Radiol Clin North Am 1985; 23: 185-192.
7. Nilsson GE, Tenland T, Öberg PA. A new instrument for continuous measurement of tissue blood flow by light beating spectroscopy. IEEE Trans Biomed Eng 1980; 27 (1): 12-19.
8. NELSON JA, MILLER FJ, KRUGER RA, LIU PY, BATEMAN W. Digital subtraction angiography using a temporal bandpass filter: initial clinical results. Radiology 1982; 145: 309-313.
9. NØRGAARD H, GJØRUP T, BREMS-DALGAARD E, HARTELIUS H, BRUN B. Interobserver variation in the detection of pulmonary venous hypertension in chest radiographs. Eur J Radiol 1990; 11: 203-206.
10. NICHOLAS GG, LATSHAW RF. Femoropopliteal bypass grafting. Predictive value of preoperative angiography. Am J Surg 1979; 138: 672-674.

O

1. OVITT TW, CHRISTENSON PC, FISHER HD, FROST NM, NUDELMAN S, ROEHRIG H, SEELEY G. Intravenous angiography using digital video subtraction X-ray imaging system. AJR 1980; 135:1141-1144.
2. OVITT TW, FISHER HD. Ideal configuration for intravenous digital subtraction angiography machine. Cardiovasc Intervent Radiol 1983; 6: 300-302.
3. OVITT TW, NEWELL JD. Digital subtraction angiography: technology, equipment, and techniques. Radiol Clin North Am 1985; 23: 177-192.
4. O'MARA CS, FLINN WR, NEIMAN HL. Correlation of foot arterial anatomy with early tibial bypass patency. Surgery 1981; 89: 743-752.
5. O'LEARY DH. Vascular ultrasonography. Radiol Clin North Am 1985; 23: 39-56.

6. OVITT T, CAPP MP, CHRISTENSON P, et al. Development of a digital video subtraction system for intravenous angiography. Recent and future developments in medical imaging II. Pros SPIE 1979; 206: 73-76.
7. OVITT TW. Intravenous angiography using digital subtraction methods. In: Mistretta CA, Crummy AB, Strother CM, Sackett JF, eds. Digital subtraction angiography: an application of computerized fluoroscopy. Chicago: Year Book Medical, 1982: 31-35.
8. OWEN RS, CARPENTER JP, BAUM RA, PERLOFF LJ, COPE C. Magnetic resonance imaging of angiographically occult runoff vessels in peripheral arterial occlusive disease. N Engl J Med 1992; 326: 1577-1581.

P

1. PASSARIELLO R, ROSSI P, SIMONETTI G, et al. Digital subtraction angiography for examination of vessels of the leg: use of a 40cm image intensifier. Radiology 1983; 149: 699-674.
2. PASSARIELLO R, PAVONE P, SIMONETTI G, et al. Radiation exposure of the patient in conventional and digital intravenous angiography. Ann Radiol 1983; 26: 548-550.
3. PAUSHTER DM, BORKOWSKI GP, BUONOCORE E, BELHOBEK GH, MARKUS KE. Digital subtraction angiography for preoperative evaluation of extremity tumors. AJR 1983; 141: 129-133.
4. PEARCE WH, YAO JST, BERGAN JJ. Non-invasive vascular testing. Curr Prob Surg 1983; 20: 464-537.
5. POLAK JF, KARMEL MI, MANNICK JA, O'LEARY DA, DONALDSON MC, WHITTEMORE AD. Determination of the extent of lower extremity peripheral arterial disease with color-assisted duplex sonography: comparison with angiography. AJR 1990; 155: 1005-1089.
6. PATTON DD, WOOLFENDEN JM. A utility-based model for comparing the cost-effectiveness of diagnostic studies. Invest Radiol 1989; 24: 263-271.
7. PICUS D, TOTTY WG. Iatrogenic femoral arteriovenous fistulae evaluation by digital vascular imaging. AJR 1984; 142: 567-570.
8. PLUNKETT MB, GRAY JE, KISPERT DB. Radiation exposure from conventional and digital subtraction angiography of cerebral vessels. AJNR 1986; 7: 665-668.
9. POND GD, OSBORNE RW, CAPP MP, et al. Digital subtraction angiography of peripheral vascular bypass procedures. AJR 1982; 138: 279-281.
10. POND GD, SMITH JRL. Digital subtraction angiography: technical aspects. In: Pinsky S, Moss GS, Srikantaswamy S, Ryo UY, Gould SA, Pond GD, eds. Imaging of the peripheral vascular system. Orlando: Grune & Stratton, 1984: 153-164.
11. POND GD, SMITH JRL. Digital subtraction angiography of the extremities. In: Pinsky S, Moss GS, Srikantaswamy S, Ryo UY, Gould SA, Pond GD, eds. Imaging of the peripheral vascular system. Orlando: Grune & Stratton, 1984: 3-18.
12. POPKY GL, SALUK PH, GRISKA LB, PARKER JA, CONIGNY PM. Comparison of superior vena cava and antecubital vein as DSA injection site. AJR 1984; 143: 317-319.
13. PAVOORDT VAN DE HDWM, BAST TJ, EIKELBOOM BC, et al. A comparison of conventional and digital intravenous arteriography in the follow-up of femoro-crural bypass operations. J Cardiovasc Surg 1983; 24: 641-645.
14. PRICE RR, PICKENS DR, SMITH CW, et al. Simultaneous biplane digital video-fluoroscopy. Radiology 1982; 143: 255-257.
15. PRICE RR, JAMES AE, ERICKSON JJ, et al. Digital radiography instrumentation and principles of operation: research for the future. In: James AE, Anderson JM, Higgins CB, eds. Digital Image Processing in Radiology. Baltimore: Williams & Wilkins. 1985: 28-42.

16. PUYLAERT CBAJ. Fatal and nearly fatal mesenteric infarction caused by intramural injection in translumbar biphasic aortography. J Belge Radiol 1965; 48: 671-694.
17. PRIESTER R, CAPLAN AL. Ethics, cost containment, and the allocation of scarce resources. Invest Radiol 1989; 24: 918-926.
18. PATEL KR, SEMEL L, CLAUSS RH. Extended reconstruction rate for limb salvage with intra-operative prereconstruction angiography. J Vasc Surg 1988; 7: 531-537.
19. PYCHLAU P, BUNDE E. The absorption of X-rays in a body equivalent phantom. Br J Radiol 1965; 38: 875-877.
20. PAVLICEK W, WEINSTEIN MA, MODIC MT, BUONOCORE E, DUCHESNEAU PM. Patient doses during digital subtraction angiography of the carotid arteries: comparison with conventional angiography. Radiology 1982; 145: 683-685.
21. PICUS D. Angiography in the 1990's: diagnosis and therapy. Radiology 1990; 175:33.
22. PIERCE EC. Percutaneous femoral artery catheterization in man with special reference to aortography. Surg Gyn Obstet 1951; 93: 56-74.
23. POLLOCK AV, Historical evolution: methods, attitudes, goals. In: Troidl H, Spitzer WO, McPeek B, Mulder DS, McKneally MF, eds. Principles and practice of research strategies for surgical investigators. Berlin: Springer-Verlag 1986: 7-17

R

1. ROSENQUIST CJ. Implications of technology assessment for the radioogist. AJR 1990; 154: 652-653.
2. RAUBER K, KOLLATH J, RIEMANN H. Intra-arterielle Feinnadel-DSA der Extremitäten. Digit Bilddiagn 1987; 7: 86-89.
3. REUTER SR. On behalf of translumbar aortography (Editorial). AJR 1978; 131: 733.
4. RIEDERER SJ, ENZMANN DR, HALL AL, PELL NJ, DJANG WT. The application of matched filtering for x-ray exposure reduction in digital subtraction angiography: clinical results. Radiology 1983; 146: 349-354.
5. RIEDERER SJ, KRUGER RA. Intravenous digital subtraction: a summary of recent developments. Radiology 1983; 147: 633-638.
6. RIEDERER SJ, ENZMANN DR, BRODY WR, HALL AL. The application of matched filtering to contrast material dose reduction in digital subtraction angiography. Radiology 1983; 147: 853-858.
7. RIEDERER SJ, BRODY WR, ENZMANN DR, HALL AL, MAIER JK. Work in progress: the application of temporal filtering techniques to hybrid subtraction in digital subtraction angiography. Radiology 1983; 147: 859-862.
8. RILEY RC, BIRKS JW, PALACIOS E, TEMPLETON AW. Exposure of radiologists during special procedures. Radiology 1972; 104: 679-683.
9. ROBICSEK F. The safety of lumbar aortography (Editorial). Surgery 1978; 83: 489-490.
10. ROSEN RJ, ROVEN SJ, TAYLOR RF, IMPARATO AM, RILES TS. Evaluation of aorto-iliac occlusive disease by intravenous digital subtraction angiography. Radiology 1983; 148: 7-8.
11. REICHLE FA, MARTINSON MW, RANKLIN KP. Infrapopliteal arterial reconstruction in the severely ischemic lower extremity: a comparison of longterm results of peroneal and tibial bypasses. Ann Surg 1980; 191: 59-65.
12. RUBIN DL, BURBANK FH, BRADLEY BR, BRODY WR. Experimental evaluation of central vs peripheral injection for intravenous digital subtraction angiography. Invest Radiol 1984; 19: 30-35.
13. RAINES JK, DARLING RC, BUTH J, BREWSTER DC, AUSTIN WG. Vascular laboratory criteria for the management of peripheral vascular disease of the lower extremity. Surgery 1976; 79: 21-29.

14. RUTHERFORD RB, FLANIGAN DP, GUPTA SK, et al. Suggested standards for reports dealing with lower extremity ischemia. J Vasc Surg 1986; 4: 80-94.
15. RADNER S. Technical equipment for vasal catheterization. Acta Radiol Diagn 1949; 31: 152-154.
16. ROGERS W, MOOTHART RW. Outpatient arteriography and cardiac catheterization: effective alternative to inpatient procedures. AJR 1985; 144: 233-234.
17. RYO UY. Radionuclide studies in arterial disease. In: Pinsky S, Moss GS, Srikantaswamy S, Ryo UY, Gould SA, Pond GD, eds. Imaging of the peripheral vascular system. Orlando: Grune & Stratton, 1984: 19-37.
18. RUTHERFORD RB. Evaluation and selection of patients for vascular surgery. In: Rutherford RB, ed. Vascular Surgery. Philadelphia, WB Saunders, 1989: 10-16.
19. RICCO JB, PEARCE WH, YAO JST, FLINN WR, BERGAN JJ. The use of operative prebypass arteriography and Doppler ultrasound recordings to select patients for extended femoro-distal bypass. Ann Surg 1983; 198: 646-653.
20. ROSS R. The pathogenesis of atherosclerosis, an update. N Engl J Med 1986; 314: 488-497.
21. RÖNTGEN WC. On a new kind of rays (preliminary communication). Nature 1896; 53:274-276. (Originally published in Germany: Sitzungberichte der Wurzburger Physikmed Gesellschaft. 1895; 17:132-141).
22. REDMOND PL, KILCOYNE RF, ROSE JS. Principles of angiography. In: Rutherford RB, ed. Vascular Surgery. Philadelphia: WB Saunders, 1989: 143-156.
23. RUTHERFORD RB. The vascular consultation. In: Rutherford RB, ed. Vascular Surgery. Philadelphia: WB Saunders, 1989: 1-10.
24. RUZICKA FF. The history of intravenous angiography. In: Mistretta CA, Crummy AB, Strother CM, Sackett JF, eds. Digital Subtraction Arteriography: an application of computerized fluoroscopy. Chicago: Year Book Medical, 1982: 1-6.
25. ROBB GP, STEINBERG I. Visualization of the chambers of the heart, the pulmonary circulation and the great blood vessels in man: A practical method. AJR 1939; 41: 1.

S

1. SALDEKNI S, SOS TA, SNIDERMAN KW, et al. Optimal injection technique for intravenous digital subtraction angiography. Radiology 1984; 150: 655-659.
2. SANTEN BC, KAN K, VELTHUYSE HJM, JULIUS HW. Exposure of the radiologist to scattered radiation during angiography. Radiology 1975; 115: 447-450.
3. SANTOS DOS R, LAMAS AC, CALDAS JP. Arteriography of the extremities (in Portuguese). Portuguese Med Contemp 1929; January 6.
4. SANTOS DOS R, LAMAS AC, CALDAS JP. L'arteriographie des membres, de l'aorte et de ses branches adominales. Bull et Mem de la Soc Nat de Chir 1929; 14: 587-601.
5. SOUREN RL, TYSON RR, REICHLE FA, et al. Angiographic criteria for small-vessel bypass. Radiology 1973; 107: 513-519.
6. SELDINGER SI. Catheter replacement of needle in percutaneous arteriography: new technique. Acta Radiol Diagn 1953; 39: 368-376.
7. SEYFERTH VON W, MARHOFF P, ZEITLER E. Transvenöse and arterielle digitale Videosubtraktions Angiographie (DVSA). ROFO 1982; 136: 301-309.
8. SENIOR HD. Abnormal branching of the popliteal artery. Am J Anat 1929; 44: 111-120.
9. SHAW CG, ERGUN DL, MYEROWITZ PD, et al. A technique of scatter and glare correction for video densitometric studies in digital subtraction video-angiography. Radiology 1982; 142: 209-213.
10. SHAW CG, PLEWES DB. Quantitative DSA: two scanning techniques for correction of scattered radiation and veiling glare.

11. SHAW CG, PLEWES DB. Pulsed injection method for bloodflow velocity measurement in intraarterial digital subtraction angiography. Radiology 1986; 160: 556-559.
12. SHETTY PC, KRASICKY GA, SHARMA RP, VEMURI RR, BURKE MM. Mycotic aneurysms in intravenous drug abusers: the utility of intravenous digital subtraction angiography Radiology 1985; 155: 319-321.
13. SIBBITT RR, PALMAZ JC, GARCIA F, REUTER SR. Trauma of the extremities: prospective comparison of digital and conventional angiography. Radioogy 1986; 160: 179-182.
14. SPIGOS DG, AKKINENI G, TAN W, et al. Epidural anesthesisa: effective analgesia in aortofemoral arteriography. AJR 1980; 134: 335-337.
15. SIMONETTI G, PASSARIELLO R, ROSSI P, et al. Digital angiography in evaluation of orthopedic tumors. Cardiovasc Intervent Radiol 1985; 8: 83-88.
16. SHEHADI WH, TONIOLO G. Adverse reactions to contrast media. Radiology 1980; 137: 299-302.
17. SNIDERMAN KW, MORSE SS, STRAUSS EB. Comparison of intraarterial digital subtraction angiography and conventional angiography in peripheral vascular disease. J Canad Assoc Radiol 1986; 37: 76-82.
18. SHEHADI WH. Contrast media adverse reactions: occurence, recurrence, and distribution patterns. Radiology 1982; 143: 11-17.
19. SRIKANTASWAMY S. In: Pinsky S, Moss GS, Srikantaswamy S, Ryo UY, Gould SA, Pond GD, eds. Imaging of the peripheral vascular system. Orlando: Grune & Stratton, 1984: 81-141.
20. SCHOUTEN HJA. Measuring pairwise agreement among many observers. Biom J 1980; 22: 497-504.
21. SCHOUTEN HJA. Measuring pairwise agreement among many observers. II. Some improvements and additions. Biom J 1982: 431-435.
22. STEUDEL VON A, HARDER T, LACKNER K, SCHNEIDER B, ORELLANO L. Digitale Subtraktionsangiographie in der Traumatologie. ROFO 1986; 144: 30-35.
23. SUMNER DS, PORTER DJ, MOORE DJ, WINDERS RE. Digital subtraction angiography: intravenous and intraarterial techniques. J Vasc Surg 1985; 2: 344-353.
24. SUMNER DS. Noninvasive diagnostic approaches. In: Strandness DE, Didisheim P, Clowes AW, Watson JT, eds. Vascular diseases: current research and clinical applications. Orlando: Grune & Stratton, 1987: 91-104.
25. SZILAGYI DE, SMITH RF, ELLIOT JP, HAGEMAN JH. Translumbar aortography - a study of its safety and usefulness. Arch Surg 1977; 112: 3399-408.
26. SAINT-GEORGE, AUBE M. Safety of outpatient angiography: a prospective study. AJR 1985; 144: 235-236.
27. SIGSTEDT B, LUNDERQUIST A. Complications of angiographic examinations. AJR 1978; 130: 455-460.
28. SADDEKNI S, SOS TA, SRUR M, COHN DJ. Contrast administration and techniques of digital subtraction angiography performance. Radiol Clin North Am 1985; 23: 275-291.
29. STRANDNESS DE, SUMNER DS. The effect of geometry on arterial blood flow: critical stenosis. In; Strandness DE, Sumner DS, eds. Hemodynamics for Surgeons. New York: Grune & Stratton, 1975: 108-119.
30. SEELEY GW, NEWELL JD. The use of psychophysical principles in the design of a total digital radiology department. Radiol Clin North Am 1985; 23: 341-348.
31. SCHWARTEN DE, CUTCLIFF WB. Arterial occlusive disease below the knee: treatment with percutaneous transluminal angioplasty performed with low-profile catheters and steerable guide wires. Radiology 1988; 169: 71-74.
32. SKAU T, BOLIN T, KARNER G. Digital subtraction angiography versus standard contrast arteriography in evaluation of peripheral vascular disease. Inter Angiol 1988; 7: 42-45.

33. SCHOUTEN HJA. Statistical measurement of interobserver agreement (Thesis). Rotterdam, The Netherlands: Erasmus University of Rotterdam, 1985.
34. SANBORN TA, MITTY HA, TRAIN JS, DAN SJ. Infrapopliteal and below-knee popliteal lesions: treatment with sole laser thermal angioplasty. Radiology 1989; 172: 89-93
35. SRIKANTASWAMY S, LELAND J. Plain film, Ultrasound and Computed tomographic studies of arteries. In: 1984: 39-79.
36. SCHOUTEN HJA. Measuring pairwise interobserver agreement when all sujects are judged by the same observers. Stat Neerl 1982; 36: 45-61.
37. SACKETT DL, HAYNES RB, TUGWELL P. Clinical epidemiology: a basic science for clinical medicine. Boston: Little, Brown & Co. 1985: 22-31.
38. SAKO Y. Hemodynamic changes during arteriography. JAMA 1963; 183: 253-256.
39. SMITH TP, CRAGG AH, BERBAUM KS, RYALS TJ, SATO Y. Techniques for lower limb angiography: a comparative study. Radiology 1990; 174: 951-955.
40. SCARPATO R, GEMBAROWICZ R, FARBER S, et al. Intra-operative prereconstruction arteriography. Arch Surg 1981; 116: 1053-1055.
41. SMATHERS RL, BRODY WR. Digital radiography: current and future trends. Br J Radiol 1985; 58:285-307.
42. STEINBERG I, FINBY N, EVANS JA. A safe and practical intravenous method for abdominal aortography, peripheral arteriography, and cerebral angiography. AJR 1959; 82: 758-772.
43. STELZER G, BERGE HENEGOUWEN VAN DP. Flow determination by DSA in bypasses with or without a distal arteriovenous fistula. Eur J Vasc Surg 1987; 1: 227-234.
44. SEPPÄNEN S. Image intensifier tomofluorography: experimental evaluation and clinical potentialities. Acta Radiol Oncol 1978; 17: 235-256.
45. SIEGEL ME, GIARGIANA FA Jr, RHODES BA, WILLIAMS GM, WAGNER NN Jr. Perfusion of ischemic ulcers of the extremity: a prognostic indicator. Arch Surg 1975; 110: 265.
46. SMITH TP, CRAGG AM, BERBAUM US, NAKAGAWA N. Comparison of the efficacy of digital subtraction and film-screen angiography of the lower limb: prospective study in 50 patients. AJR 1992; 158: 431-436.
47. SUMNER DS. Essential hemodynamic principles. In: Rutherford RB,ed. Vascular Surgery. Philadelphia: WB Saunders, 1989: 17-40.
48. SUMNER DS. Objective diagnostic techniques: role of the vascular laboratory. In: Rutherford RB, ed. Vascular Surgery. Philadelphia: WB Saunders, 1989: 41-60.
49. SUMNER DS. Noninvasive assessment of peripheral arterial occlusive disease. In: Rutherford RB, ed. Vascular Surgery. Philadelphia: WB Saunders, 1989: 61-111.
50. SPENCER MP, REID JM. Quantitation of carotid stenosis with continuous wave Doppler ultrasound. Stroke 1979; 10: 326-330.
51. SHRIMPTON PC, WALL BF. Comparison of methods for estimating the energy imparted to patients during diagnostic radiological examinations. Phys Med Biol 1983; 28: 1160-1162 (letter).
52. SIEGEL EL, TEMPLETON AW, COOK LT, ECKARD DA, HARRISON LA, DWYER III SJ. Image calibration of laser digitizers, printers, and grayscale displays. Radiographics 1992; 12: 329-335.

T

1. TEEUWEN C, EIKELBOOM BC, LUDWIG JW. Clinically unsuspected complications of arterial surgery shown by post-operative digital subtraction angiography. B J Radiol 1989; 62: 13-19.

2. TAKAHASHI M, KOGA Y, BUSSAKA H, MIYAKAWA M. The value of digital subtraction angiography in peripheral vascular disease. Br J Radiol 1984; 57: 123-132.
3. TAKAHASHI M, BUSSAKA H, MIYAWAKI M, HIGASHIDA Y. Stereoscopic technique in digital subtraction angiography. Radiology 1985; 157: 546.
4. TAKAHASHI K, FURUSE M, SAITO K, et al. Intraarterial digital subtraction angiography in detection of hepatocellular carcinoma. Cardiovasc Intervent Radiol 1989; 12: 61-65.
5. THIELE BC, STRANDNESS JR. Accuracy of angiographic quantification of peripheral atherosclerosis. Prog Cardiovasc Dis 1983; 26: 223-236.
6. THORNBURY JR, FRYBACK DG. Technology assessment - an American view. Eur J Radiol 1992; 14: 147-156.
7. TRYHUS M, METTLER FA, KELSEY C. The radiologist and angiographic procedures: absorbed radiation dose. Invest Radiol 1987; 2: 747-750.
8. TURNIPSEED WD, CRUMMY AB, STROTHER C, et al. Computerized intravenous arteriography: a technique for visualizing the peripheral vascular system. Surgery 1981; 89: 118-123
9. TURNIPSEED WD, DETMER DE, BERKOFF HA, ACHER CW, CRUMMY AB, BELZER FO. Intraarterial digital arteriography: a new diagnostic method for determining limb salvage bypass candidates. Surgery 1982; 92: 322-327.
10. TURNIPSEED WD, ARCHER CW, DETMER DE, et al. Digital subtraction angiography and B-mode ultrasonography for abdominal and peripheral aneurysms. Surgery 1982; 92: 619-626.
11. TURSKI PA, ZWIEBEL WJ, STROTHER CM, CRUMMY AB, CELESA GG, SACKETT JF. Limitations of intravenous digital subtraction angiography. AJNR 1983; 4: 271-273.
12. TEMPLETON AW, DWYER III SJ. Displays: contrast and special requirements. Invest Radiol 1989; 24: 95-98.
13. TEMPLETON AW, DWYER III SJ, COX GG, et al. A digital radiology imaging system: description and clinical evaluation. AJR 1987; 149: 847-851.
14. TILLGREN C, STENSON S, LUND F. Obliterative arterial disease of the lower limbs studied by means of repeated femoral arteriography. Acta Radiol Diagn 1963; 1: 1161-1178.
15. TURSKI PA, STIEGHORST MF, STROTHER CM, CRUMMY AB, LIEBERMAN RP, MISTRETTA CA. Digital subtraction angiography "roadmap". AJR 1982; 139: 1233-1234.
16. TURNIPSEED WD. A vascular surgeon's perspective of digital subtraction arteriography in peripheral vascular disease. In: Mistretta CM, Crummy AB, Strother CM, Sackett JF, eds. Digital subtraction arteriography: an application of computerized fluoroscopy. Chicago: Year Book Medical, 1982: 65-68.
17. TAYLOR LM, EDWARDS JM, PORTER JM, PHENEY ES. Reversed vein bypass to infrapopliteal arteries. Ann Surg 1987; 205: 90-97.

U

1. UNSCEAR Report No. 10; 1986-1988. (Report of the United Nations Committee on the Effects of Atomic Radiation to the General Assembly). United Nations Publications, Sales No. E.88.1X.7.

V

1. VIZY KN. Electronic imaging fundamentals: basic theory. Cardiovasc Intervent Radiol 1983; 6: 174-182.
2. VRIES DE N, MILLER FJ, WOJTOWYCZ MM, et al. Tomographic digital subtraction angiography: initial clinical studies using tomosynthesis. Radiology 1985; 157: 239-241.

3. VIZY KN. The roles of film in an increasingly computerized world. Invest Radiol 1989; 24: 503-505.
4. VEIGA-PIRES JA, GRAINGER RG, eds. Pioneers in angiography. The Portuguese school of angiography. 2nd ed: Lancaster: MTP Press Ltd. 1987: 87-103.
5. VEIGA-PIRES JA, GRAINGER RG, eds. Pioneers in angiography. The Portuguese school of angiography. 2nd ed. Lancaster: MTP Press Ltd. 1987: 47-60.
6. VERHOEVEN LAJ. Digital subtraction angiography (DSA). Thesis. Delft, The Netherlands: University of Delft 1985, 209p.
7. VEITH FJ, GUPTA SK, SAMSON RH, et al. Progress in limb salvage by reconstructive arterial surgery combined with new or improved adjunctive procedures. Ann Surg 1981; 194: 386-401.
8. VEITH FJ, ASCER E, GUPTA SK, et al. Tibiotibial vein bypass grafts: a new operation for limb salvage. J Vasc Surg 1985; 21: 552-557.
9. VEITH FJ, GUPTA SK, WENGERTER KR, et al. Changing arteriosclerotic disease patterns and management strategies in lower-limb threatening ischemia. Ann Surg 1990; 212: 402-414.
10. VELDHUYZEN VAN ZANTEN SJ, HYDRA O. Onderzoek naar variatie tussen waarnemers met behulp van kappa. Ned Tydschr Geneeskd 1988; 132: 199-202.
11. VRIES DE AR. Digitale subtractie angiographie van de carotis bifurcatie (Thesis). Amsterdam, Netherlands: University of Amsterdam, 1984. 140p. (with English summary).

W

1. WYLIE EJ, GOLDMAN L. The role of aortography in the determination of operability in arteriosclerosis of the lower extremities. Ann Surg 1958; 148: 325-342.
2. WENSTRUP RS, SWEENEY KP, SCHOLZ FJ. Digital subtraction angiography system evaluation with phantoms. Radiology 1985; 155: 805-809.
3. WHITE RI. Angiography of the abdominal aorta and its branches. In: Fundamentals of Vascular Radiology. Philadelphia: Lea & Febiger, 1976: 53-66.
4. WOOD GW, LUKIN RR, TOMSICK TA, CHAMBERS AA. Modified venous catheter technique for digital angiography. Radiology 1983; 147: 272.
5. WOLFEL DA, LOVETT BP, ORTENBURGER AI, JOHSON LS, SOMMERVILLE DL. Outpatient arteriography: its safety and cost effectiveness. Radiology 1984; 153: 363-364.
6. WHOLEY MH, JARMOLOWSKI CR. New reperfusion devices: the Kensey catheter, the atherolytic reperfusion wire device, and the transluminal extraction catheter. Radiology 1989; 172: 947-952.
7. WEDTH AJ. Peripheral arteriography. An overview of its origin and present status. CRC Crit Rev Diagn Imaging 1975; 6: 369-372.
8. WARREN R, GOMEZ RL, MARSTON JAP. Femoropopliteal arteriosclerosis obliterans. Arteriographic patterns and rates of progression. Surgery 1964; 55: 135-143.
9. WHITE RA, WHITE GF, MEHRINGER MC, CHAING FL, WILSON SE. A clinical trial of laser thermal angioplasty in patients with advanced peripheral vascular disease. Ann Surg 1990; 212: 257-265.
10. WALSTRA R, ENGELSHOVEN VAN J, JANEVSKI B, JÖRNING P, KITSLAAR P, SCHOUTEN H. Angiography of the lower leg: comparative study of conventional angiography and intraarterial DSA. Radiology 1989; 173 (P): 428.
11. WALL BF, RUSSELL JGB. The application of cost-utility analysis to radiological protection in diagnostic radiology. J Radiol Prot 1988; 8: 221-229.
12. WEIR J, ABRAHAMS P. An atlas of radiological anatomy. 2nd ed. Edinburgh: Churchill Livingstone, 1986: 168-171.

13. WHITE RA, WHITE GH, MEHRINGER MC, CHAING FL, WILSON SE. A clinical trial of laser thermal angioplasty in patients with advanced peripheral vascular disease. Ann Surg 1990; 212: 257-265.
14. WIEBE V, STRAUB H. Hemodynamic side effects of meglumine ioglicate, meglumine sodium ioxoglate and iohexol in aortofemoral angiography: comparison of a high-osmolar and two low-osmolar radiological contrast media. In: Taenzer V, Zeitler E, eds. Contrast media in Urography, Angiography and Computerized Tomography. New York, Georg Thieme Verlag, 1983: 78-84.
15. WAUGH JR, SACHARIAS N. Arteriographic complications in the DSA era. Radiology 1992; 182: 243-246.

Z

1. ZIEDSES DES PLANTES BG. Een methode om bepaalde onderdelen van het roentgenologisch te onderzoeken voorwerp afzonderlijk in beeld te brengen (English summary). Ned Tijdschr Geneesk 1934; 78: 762-769.
2. ZIEDSES DES PLANTES BG. Subtraktion. Eine röntgenographische Methode zur separaten Abbildung bestimmten Teile des Objekts. ROFO 1935; 52: 69-79.
3. ZIEDSES DES PLANTES BG. De toepassing van subtractie bij het röntgen onderzoek van het hart en de grote bloedvaten (English summary). Ned Tijdschr Geneesk 1959; 103: 2554-2561.
4. ZIEDSES DES PLANTES BG. Radiographic subtraction. In: McLaren JW, ed. Modern Trends in Radiology; London: 1970: 226-241.
5. ZARINS CK, GLAGOV S. Artery wall pathology in atherosclerosis. In: Rutherford RB, ed. Vascular Surgery. Philadelphia: WB Saunders, 1989: 178-193.
6. ZIR LM, MILLER SW, DINSMORE RE, GILBERT JP, HARTHORNE JW. Interobserver variability in coronary angiography. Circulation 1976; 53: 627-632.

ACKNOWLEDGEMENT

Dit proefschrift kwam tot stand in de afdeling Radiodiagnostiek van het St. Annadal ziekenhuis te Maastricht, later genoemd Academisch Ziekenhuis Maastricht.
Het idee voor dit proefschrift werd geboren door de installatie en toepassing van nieuw apparatuur voor het verrichten van bloedvaat onderzoek z.g. digitale subtractie angiografie.
Pas door de bewerking van een proefschrift leert men dat het volbrengen ervan mogelijk is middels intensieve samenwerking met anderen, die ieder op eigen wijze hun bijdrage leverden, zowel wetenschappelijk als mentaal. Het is voor mij onmogelijk al deze mensen persoonlijk te bedanken. Zonder iemand te kort te willen doen, wil ik toch een aantal personen met name vermelden wegens hun bijzondere inzet tijdens de bewerking van dit proefschrift.

Prof. dr B.K. Janevski. Zeer geachte eerste promotor. Als mijn opleider in de radiodiagnostiek heeft U een belangrijke rol gespeeld bij het tot stand komen van dit proefschrift. Ten eerste ben ik U erg dankbaar dat U mij de kans heb gegeven deze opleiding te volgen. Uw internationaal gewaardeerde proefschrift, later als boek gepubliceerd, over angiografie van de bovenste extremiteiten, heeft mij gestimuleerd om een proefschrift te schrijven over (een deel van) de onderste extremiteiten. De beginselen van de radiodiagnostiek, en met name van de angiografie, heb ik voortreffelijk van U geleerd, en na het begin van mijn onderzoek, hebt U ervoor gezorgd dat de uitvoering van het bloedvaatonderzoek volgens protocol continu kon plaats vinden. Onze samenwerking heb ik enorm gewaardeerd, het resultaat ligt voor U.
Prof. dr J.M.A. van Engelshoven. Zeer geachte tweede promotor. Vanaf het eerste uur van de voorbereidingen en het uitvoeren van dit proefschrift bent U er intensief betrokken bij geweest. Vooral in de latere stadia bij het statistisch bewerken van de gegevens, hebt U mij kunnen helpen de onoverkomelijke moeilijkheden die men tegenkomt te kunnen gladstrijken. Daar U niet tevreden was om alleen de beeldkwaliteit van angiografie te laten onderzoeken, maar ook de stralingseffecten en het kosten aspect, is dit proefschrift meer compleet geworden. Ondanks Uw betrokkenheid bij de organisatie van de gehele afdeling radiodiagnostiek, de bouwplannen van het nieuwe ziekenhuis, de verhuizing ernaar toe, en het opzetten van de nieuwe afdeling radiodiagnostiek, hebt

U steeds tijd gevonden mijn onderzoek kritisch te beoordelen. Hiervoor ben ik U zeer erkentelijk.
De beoordelingscommissie van het proefschrift bestaande uit Prof. dr P.J.E.H.M. Kitslaar, Prof. P.J.C. van Breda Vriesman, Prof. dr A.H. Keijser, Prof. dr A.J. van der Linden en Prof. dr W.P.T.M. Mali, wil ik allen graag danken voor de tijd besteed om dit proefschrift aan een kritisch onderzoek te onderwerpen. Vooral Prof. dr P.J.E.H.M. Kitslaar, de voorzitter, wil ik bedanken voor de waardevolle kritiek die U geleverd heeft. Als vaatchirurg heeft U duidelijk kunnen aangeven wat essentieel is voor de chirurg voor het preoperatief vaat onderzoek. Vooral bij arteriografie van de onderste extremiteiten, is samenwerking tussen radiodiagnost en vaatchirurg onontbeerlijk.
Dr P.J.G. Jörning, vaatchirurg te Zwolle. Beste Paul, jouw betrokkenheid vooral in het begin van dit onderzoek toen je nog in Maastricht werkte, ben ik je zeer erkentelijk. Zonder probleem was jij bereid om na een zware werkdag nog ettelijke röntgen foto's te beoordelen voor dit onderzoek en daarbij ook kritische aanmerkingen te geven. Zelfs toen jij naar Zwolle verhuisde om in een nieuw praktijk te beginnen, was het geen probleem om daar een beroep op je te doen. Heel veel dank voor alles.
Dr H.J.A. Schouten, statisticus, Vakgroep Medische Informatica en Statistiek, Rijksuniversiteit Limburg. Beste Hubert, als leek op het gebied van statistiek, werd ik door Prof. dr J.M.A. van Engelshoven naar jou gestuurd helemaal voor het begin van mijn onderzoek met de mededeling: "wetenschappelijk onderzoek is erg leuk, maar vooraf moet je wel weten wat je met je gegevens gaat doen". Na het lezen van jou proefschrift en de gesprekken die we gehad hebben, heb je mij de sleutel gegeven om dit onderzoek te beginnen en gegevens te verwerken op de computer. Heel veel dank daarvoor.
Drs E.S. van der Linden en Drs G. Snoep, medewerkers van de afdeling radiodiagnostiek, Academisch Ziekenhuis Maastricht. Beste Ed en Riël, bij het verwerken van gegevens is een computer niet meer weg te denken. Jullie kennis van het omgaan met computers heeft mij zeer geholpen. Telkens wanneer ik gefrustreerd raakte op het Rekencentrum in het oude Biomedisch Centrum, omdat de mainframe computer niet wou uitrekenen wat ik invoerde, konden jullie het probleem oplossen. Heel veel dank voor jullie hulp.
De heer J. Schellekens, computer programmeur te Maastricht. Beste Jos, het aanschaffen van een personal computer en ermee leren omgaan is met jouw hulp gebeurd. Dankzij een door jouw ontworpen database programma, was het mogelijk om de duizenden waarnemer gegevens op te slaan en vervolgens te verwerken. Tot 's avonds laat kon ik altijd bij jou terecht als er een probleem was met de computer. Zeer veel dank voor jouw tijd.
Ir P.J.H. Kicken, klinisch fysicus aan de afdeling radiodiagnostiek van het Academisch Ziekenhuis Maastricht. Beste Pierre, jou wil ik vooral danken voor jouw kennis en medewerking aangaande het deel handelend over de röntgen stralen risico bij arteriografie van bekken en benen. In recente jaren is hierover weinig gepubliceerd. Ondanks jou druk bestaan met het onderzoek voor je

eigen proefschrift, vond je altijd tijd om mij te helpen, en dankzij jouw hulp is hoofdstuk X tot stand gekomen. Heel veel dank hiervoor.
Drs K. Pijnenburg en dr A.J.H.A. Ament, Vakgroep Economie van de Gezondheidszorg, Rijksuniversiteit Limburg. Beste Karen en André, de financiële bestedingen in de gezondheidszorg worden steeds beperkter en medici worden steeds vaker geconfronteerd met budgettering. Bij het aanwenden van nieuwe onderzoeksmethoden speelt tegenwoordig, behalve de medische effectiviteit, ook het kostenplaatje een rol. Dankzij de hulp van jou, Karen, bijgestaan door André, is het gelukt enigszins een indruk te krijgen van de kosten veroorzaakt door de digitalisering van angiografie, verwoord in hoofdstuk XI. Heel veel dank voor de tijd hieraan gegeven.
Hetty Nelissen en andere radiologische laboranten, werkzaam geweest in de angiografie kamer van het oude ziekenhuis. Het is natuurlijk even wennen als een nieuwe assistent met een nieuw idee komt hoe arteriografie van bekken en benen moet plaats vinden volgens een vast protocol. Dankzij jullie is het gelukt om het materiaal voor dit proefschrift te verkrijgen. Wel bedankt voor jullie inzet.
Collegae radiodiagnosten, assistenten en andere medewerkers in Maastricht, die in enigerlei opzet mee hebben geholpen bij het tot stand komen van dit proefschrift, wil ik heel hartelijk bedanken.
Mijn maatschapsleden in het Willem Alexander ziekenhuis, Daan Piers en Tex Zwemmer, jullie hebben mij de ruimte en stimulans gegeven om het proefschrift op tijd af te krijgen, ondanks de werkdruk. Wel bedankt.
Dr Ph.J. de Korte, radiodiagnost in het De Wever Ziekenhuis te Heerlen. Beste Philip, ruim zeventien jaar geleden hebben we elkaar voor het eerst ontmoet aan de andere kant van de wereld in Nieuw Zeeland. Jij was bezig weg te gaan en ik kwam net aan, niet wetende of onze levenswegen elkaar weer zouden kruisen. We kwamen elkaar weer tegen toen ik met de opleiding radiodiagnostiek begon in Maastricht, en belangeloos heb jij mij geholpen in het eerste jaar door wekelijks basale radiodiagnostiek door te nemen. Later bleek dat we beide begonnen waren aan een promotie-onderzoek en begin dit jaar heb jij al het genoegen gehad om het te mogen verdedigen. We weten allebei wat het schrijven van een proefschrift kost. Jouw adviezen en hulp blijven van onschatbare waarde, vriendschap kent geen afstand of tijd.
Mijn schoonouders, Jan en Ties Boevé. Jullie zijn altijd een zeer grote steun tot mij geweest. Hoewel mijn carrière geen rechte lijn is geweest, hebben jullie mij steeds het volste vertrouwen geschonken en gestimuleerd het proefschrift te voltooien. Voor alle investeringen en geduld, dank ik jullie zeer.
Mijn echtgenote. Lieve Sabine, een speciaal dankwoord voor jou, die accepteerde dat ik aan een nieuwe opleiding begon en daarna ook nog aan een proefschrift. Desondanks, hielp je mij beseffen dat er ook nog andere prioriteiten in het leven zijn. Onze dochters, Frances en Sascha, en ik, hebben veel aan jou te danken.

Curriculum vitae

2 februari 1946	geboren te Haarlem
1952 - 1960	Primary School and High School in Adelaide, Australië
1961 - 1964	Het Nieuwe Lyceum te Hilversum, eindexamen HBS-B
1965 - 1975	studie geneeskunde, Gemeente Universiteit te Amsterdam
sept. - dec. 1972	doctoraal assistent Pathologische Anatomie Wilhelmina Gasthuis te Amsterdam
maart 1975	arts examen
april - dec. 1975	assistent algemene chirurgie, Binnen Gasthuis te Amsterdam, opleider prof. dr. W.H. Brummelkamp.
1976 - 1981	opleiding tot algemeen chirurg, Auckland, New Zealand, (rotating residency in Auckland, Greenlane and Middlemore hospitals)
1982 - 1884	vervolg-opleiding cardiopulmonale chirurgie, Thoraxcentrum, Academisch Ziekenhuis Dijkzigt te Rotterdam, opleider prof. dr. J. Nauta.
aug. 1984 - 1988	opleiding tot radiodiagnost, St. Annadal ziekenhuis (later Academisch Ziekenhuis) te Maastricht, opleider prof. dr. B.K. Janevski
augustus 1988	ingeschreven in register SRC
1988 - 1989	chef de clinique, afd. radiodiagnostiek, Catharina Ziekenhuis te Eindhoven
okt.1989 - 1990	staf radiodiagnost, afd radiodiagnostiek, Academisch Ziekenhuis Maastricht (vroeger St. Annadal Ziekenhuis)
nov.1989	voordracht: "Angiography of the lowerleg: comparative study of conventional angiography and intraarterial DSA" in de 75th Anniversary and Annual meeting of the Radiological Society of North America te Chicago, U.S.A.
1991 - heden	radiodiagnost in maatschap radiodiagnostiek met collegae D.B. Piers en A. Zwemmer, Bosch Medicentrum, locatie Willem Alexander Ziekenhuis te Den Bosch