

# Advances in minimally invasive abdominal wall surgery

Citation for published version (APA):

Dewulf, M. (2022). *Advances in minimally invasive abdominal wall surgery: Entering the robotic era*. [Doctoral Thesis, Maastricht University]. Maastricht University. <https://doi.org/10.26481/dis.20221111md>

## Document status and date:

Published: 01/01/2022

## DOI:

[10.26481/dis.20221111md](https://doi.org/10.26481/dis.20221111md)

## Document Version:

Publisher's PDF, also known as Version of record

## Please check the document version of this publication:

- A submitted manuscript is the version of the article upon submission and before peer-review. There can be important differences between the submitted version and the official published version of record. People interested in the research are advised to contact the author for the final version of the publication, or visit the DOI to the publisher's website.
- The final author version and the galley proof are versions of the publication after peer review.
- The final published version features the final layout of the paper including the volume, issue and page numbers.

[Link to publication](#)

## General rights

Copyright and moral rights for the publications made accessible in the public portal are retained by the authors and/or other copyright owners and it is a condition of accessing publications that users recognise and abide by the legal requirements associated with these rights.

- Users may download and print one copy of any publication from the public portal for the purpose of private study or research.
- You may not further distribute the material or use it for any profit-making activity or commercial gain
- You may freely distribute the URL identifying the publication in the public portal.

If the publication is distributed under the terms of Article 25fa of the Dutch Copyright Act, indicated by the "Taverne" license above, please follow below link for the End User Agreement:

[www.umlib.nl/taverne-license](http://www.umlib.nl/taverne-license)

## Take down policy

If you believe that this document breaches copyright please contact us at:

[repository@maastrichtuniversity.nl](mailto:repository@maastrichtuniversity.nl)

providing details and we will investigate your claim.

# **Advances in minimally invasive abdominal wall surgery**

Entering the robotic era

Maxime J.L. Dewulf

**Cover design** Frederic Tilleman

**Printed by** Ridderprint

**ISBN** 978-94-6458-467-7

**Copyright** © Maxime Dewulf

All rights reserved. No part of this dissertation may be reproduced, distributed, or transmitted in any form or by any means, including photocopying, recording, or other electronic or mechanical methods, without the prior written permission of the author or publisher, except in case of brief quotations embodied in critical reviews and certain other non-commercial uses permitted by copyright law.

# **Advances in minimally invasive abdominal wall surgery**

Entering the robotic era

ACADEMISCH PROEFSCHRIFT

Ter verkrijging van de graad van doctor aan de Universiteit Maastricht,  
op gezag van de Rector Magnificus, Prof. dr. Pamela Habibović  
volgens het besluit van het College van Decanen,  
in het openbaar te verdedigen  
op 11 november 2022 om 10 uur

door

Maxime J.L. Dewulf



**Promotor**

Prof. dr. N.D. Bouvy

**Copromotores**

Dr. F.E. Muysoms

*AZ Maria Middelaes Gent*

Dr. S.A.W. Bouwense

**Beoordelingscommissie**

Prof. dr. S.W.M. Olde Damink

Prof. dr. D. Keszthelyi

Prof. dr. J.L. Lange

*Erasmus MC Rotterdam*

Dr. J. Melenhorst

Dr. M.M. Poelman

*Franciscus Gasthuis en Vlietland Rotterdam*

*Voor Kees*



## Table of contents

Chapter 1	General introduction, aims and outline of this thesis	9
<b>Part I</b>	<b>Inguinal hernia</b>	
Chapter 2	Laparoscopic bilateral groin hernia repair with one large self-fixating mesh: prospective observational study with patient related outcome of urological symptoms	27
Chapter 3	Robotic-assisted laparoscopic inguinal hernia repair after previous transabdominal prostatectomy	49
<b>Part II</b>	<b>Ileal conduit parastomal hernia</b>	
Chapter 4	Parastomal hernias after cystectomy and ileal conduit urinary diversion: surgical treatment and the use of prophylactic mesh. A systematic review	69
Chapter 5	How-I-do-it: minimally invasive repair of ileal conduit parastomal hernias. Technical note and preliminary results	93
<b>Part III</b>	<b>Ventral hernia</b>	
Chapter 6	Three years of adopting robotic abdominal wall surgery in a European hospital: the ROBUST hernia project	115
Chapter 7	Too limited use of prophylactic mesh after open AAA repair in Belgium and The Netherlands?	129
Chapter 8	Prevention of incisional hernias by prophylactic mesh-augmented reinforcement of midline laparotomies for abdominal aortic aneurysm treatment: 5-year results of a randomized controlled trial	137
Chapter 9	Open versus robotic-assisted laparoscopic posterior component separation in the treatment in complex abdominal wall repair	155

Chapter 10	Comment to: Transversus abdominis release for ventral hernia repair: open or robotic? Short-term outcomes from a systematic review and meta-analysis	169
Chapter 11	Robotic versus open component separation by transversus abdominis release in the treatment of ventral incisional hernia: study protocol for an open-label multicenter randomized controlled trial (the ROCSTAR trial)	175
Chapter 12	General discussion and future perspectives	199
Chapter 13	Summary	215
Addendum	Samenvatting	221
	Impact	227
	Dankwoord	233
	Curriculum Vitae	239
	List of publications	243

# Chapter I

General introduction



## **General introduction, aims and outline of this thesis**

Abdominal wall surgery represents a significant proportion of surgical procedures, both historically and in the present. The lifetime risk for developing an inguinal hernia is estimated to be between 27-43% in men, and 3-6% in women. Worldwide, this accounts for over 20 million inguinal hernia repairs performed annually<sup>1,2</sup>. The reported incidence of parastomal hernias (PH) varies between 17.1% and 68.2% during a 2-year follow-up<sup>3-5</sup>. In a general population, the incidence of incisional hernias (IH) after laparotomy is estimated around 23% within 3 years after surgery<sup>6,7</sup>. In high-risk patients, these numbers are even higher. For example, reported incidence of IH after open repair of an abdominal aortic aneurysm (AAA) through a midline laparotomy varies between 21-38% during the first two years of follow-up<sup>8</sup>, and up to 69% five years after surgery<sup>9</sup>. It is estimated that around 348,000 incisional hernia repairs are performed in the United States (US) per year<sup>6,10</sup>. It is obvious that abdominal wall surgery represents a major economic burden on health care systems. For example, the costs for the surgical treatment of incisional hernias in the US alone are estimated around 3.2 billion annually<sup>10</sup>.

Traditionally, the surgical treatment of abdominal wall defects was performed by general surgeons, mainly by open surgery. However, high incidence of both primary and incisional hernias, with significant impact on both quality of life and health care systems, induced an increased interest in this field of surgery. Nowadays, abdominal wall surgery is increasingly being performed by dedicated hernia surgeons. This has led to a major increase in novel techniques in both the prevention and treatment of hernias, along with a rapid increase in communications reporting on outcomes. Besides the use of mesh, the introduction of minimally invasive surgery completely changed current practice in hernia surgery<sup>1</sup>. During the last two decades, a shift towards minimally invasive techniques was seen. With the introduction of robotic-assisted techniques to the field of abdominal wall surgery, even the most complex hernia repairs are currently being performed in a minimally invasive way<sup>11</sup>.

### ***Advances in inguinal hernia repair***

Until recently, the tension-free mesh repair described by Lichtenstein (introduced in the 1980s) has been considered as the golden standard in the surgical treatment of inguinal hernias<sup>2,12</sup>. This open transinguinal surgical technique results in low recurrence rates, even on the long term<sup>13,16</sup>. However, several minimally invasive techniques are



increasingly being used, and current guidelines advise a laparoscopic posterior approach in the treatment of inguinal hernias provided specific surgical expertise is available<sup>2</sup>. In many centers, this has become standard practice. When compared to open surgery, both the transabdominal preperitoneal (TAPP) and the totally extraperitoneal (TEP) technique have proven to be non-inferior regarding complications and recurrence rates, and superior regarding postoperative and chronic pain<sup>15,16</sup>. Recent meta-analysis has reported on a significant decrease of the number of return-to-work days after TAPP or TEP, when compared to open surgery<sup>16</sup>. Current evidence fails to demonstrate any advantage of TAPP over TEP, or vice versa<sup>17,18</sup>.

In case of bilateral disease, current guidelines strongly advise the use of these minimally invasive techniques<sup>2</sup>. In laparoscopic surgery, comparable outcomes have been reported for unilateral and bilateral inguinal hernia repairs (IHRs), and a bilateral repair can be performed without the need for additional incisions<sup>19</sup>. Obtaining a critical view of the myopectineal orifice, which is considered paramount when performing laparoscopic IHR, involves an extensive dissection of the retropubic space, and these techniques implicate close contact of a mesh with the bladder<sup>20</sup>. Despite this, outcomes regarding urological symptoms after minimally invasive IHR remain grossly underreported. Furthermore, optimal mesh configuration and whether one large or two separate meshes should be used in case of bilateral IHR remains to be determined<sup>21</sup>.

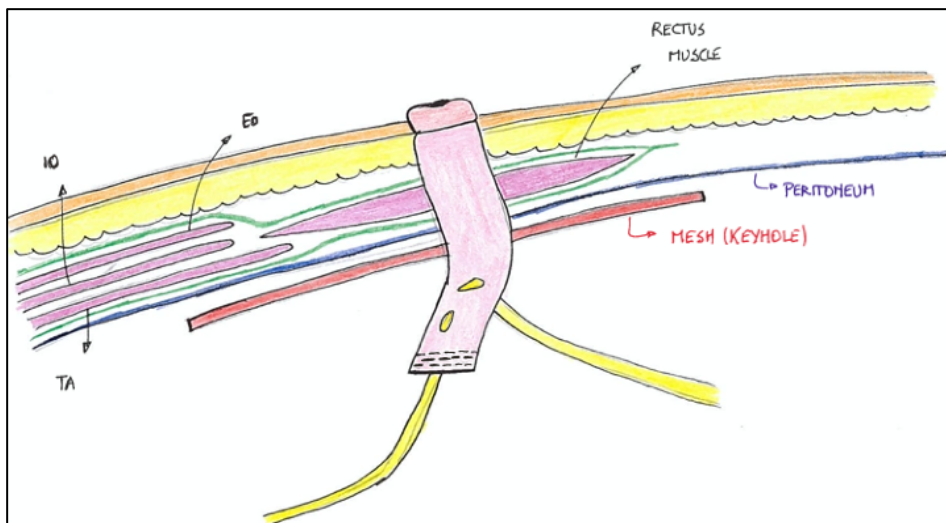
In some cases, current guidelines still advocate an open anterior IHR. For instance, previous prostatectomy - which results in extensive scarring of the Retzius space - is considered a relative contra-indication for a minimally invasive posterior approach<sup>2</sup>. Despite these recommendations, some authors still use a laparoscopic approach after prostatectomy, given the advantages of minimally invasive over open surgery. Robotic-assisted surgery may offer an additional advantage in these complex cases. Until now, evidence on the use of minimally invasive surgery in this specific setting is scarce and of limited quality<sup>22-26</sup>.

### ***Challenges in ileal conduit parastomal hernia repair***

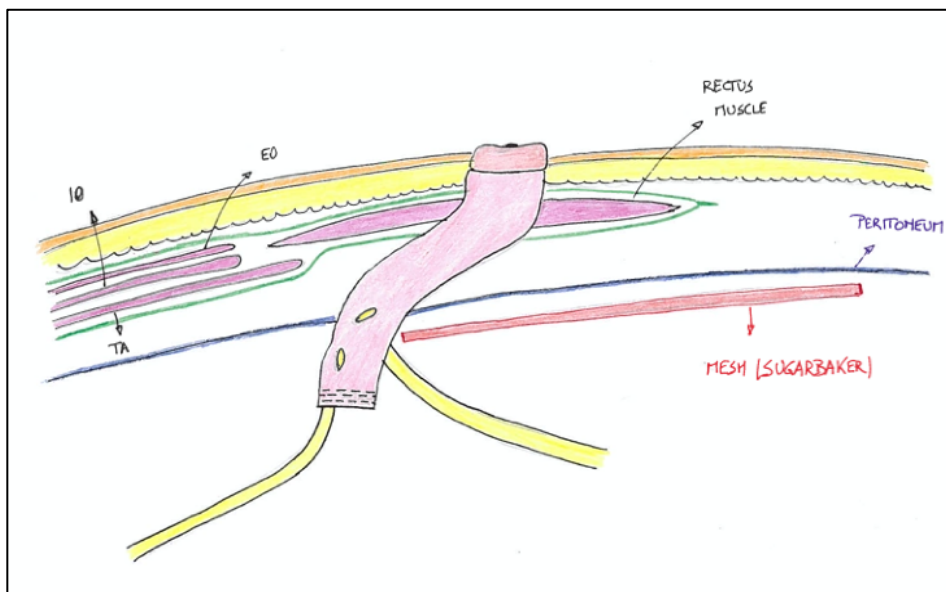
In 2014, parastomal hernias were defined as ‘an abnormal protrusion of the contents of the abdominal cavity through the abdominal wall defect created during placement of a colostomy, ileostomy or ileal conduit stoma’ by the European Hernia Society<sup>27</sup>. Generally, the surgical treatment of a PH is considered complex, and has proven to be prone to complications<sup>28,29</sup>. As the local treatment of these hernias involves extensive dissection of the stomal loop and mesh placement in a close relation to colon or small

bowel, surgeons are often reluctant to perform this type of surgery. Besides relocation of the stoma<sup>30</sup>, several techniques in the local repair of a PH have been proposed. Currently available literature advocates the use of a mesh when treating these hernias, and suture repairs are considered obsolete<sup>28</sup>. Traditionally, a keyhole (where the stomal loop runs through the mesh) or Sugarbaker repair (in which the stomal loop is lateralized and an intraperitoneal mesh is placed to cover the PH site) were used to treat these hernias<sup>31,32</sup>. Several pre-shaped meshes have been evaluated in the surgical treatment of PH, which are mostly used in an intraperitoneal position<sup>33</sup>. More recently, Eric Pauli described a modification of the Sugarbaker technique, in which the stomal loop is lateralized in the retromuscular plane, and an extraperitoneal mesh is used<sup>34</sup>. This technique requires a posterior component separation by release of the transversus abdominis muscle to allow adequate lateralization of the stomal loop<sup>35</sup>. Despite an initial report from the group of Michael Rosen raising concerns on the safety of this technique<sup>29</sup>, it is increasingly being used<sup>36</sup>. With the increased adoption of robotic-assisted and component separation techniques, and increasing evidence on the safety and feasibility of this technique, it is rapidly gaining popularity. Furthermore, it offers an additional advantage when a concomitant midline incisional hernia is present, as it allows a simultaneous repair of both hernias using one large extraperitoneal mesh.

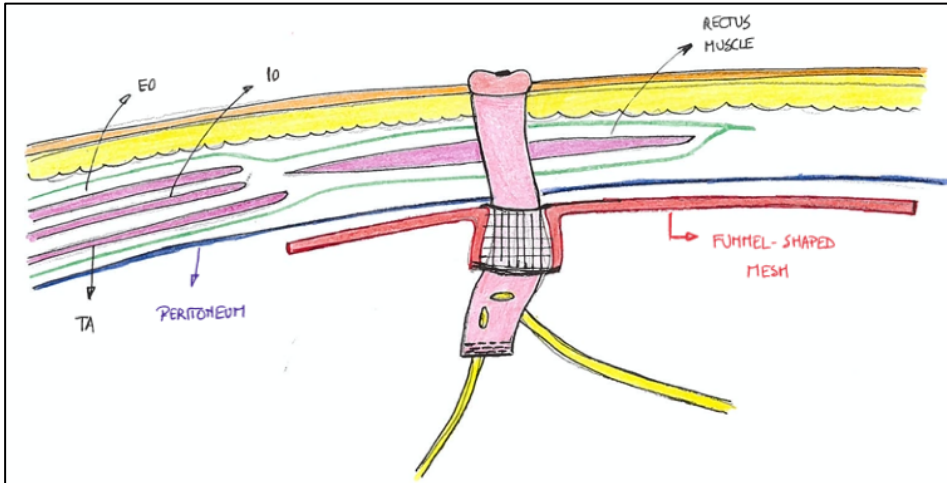
In the curative treatment of bladder neoplasms, a radical cystectomy with an ileal conduit urinary diversion, performed through a midline laparotomy, is still the standard of care. Despite the introduction of minimally invasive surgery and alternative techniques of urinary diversion, around 5000 ileal conduits are still being constructed in the US each year<sup>37</sup>. When compared to ileo- or colostomy, a local surgical repair of an ileal conduit PH poses additional technical challenges. First, these patients often have significant morbidity, and remain at risk for recurrent or metastatic disease. Second, in almost half of the patients that present with an ileal conduit PH, a midline incisional hernia is present. Third, the presence of the ureters close to the stomal loop, absence of peritoneum below the arcuate line after radical cystectomy, and the difficult lateralization of the stomal loop due to a short mesentery complicate the surgical treatment of this specific type of hernia. So far, evidence on the surgical treatment of this specific entity is limited<sup>5,38</sup>. Different surgical techniques in the local treatment of ileal conduit PHs are illustrated in Figures 1-4.



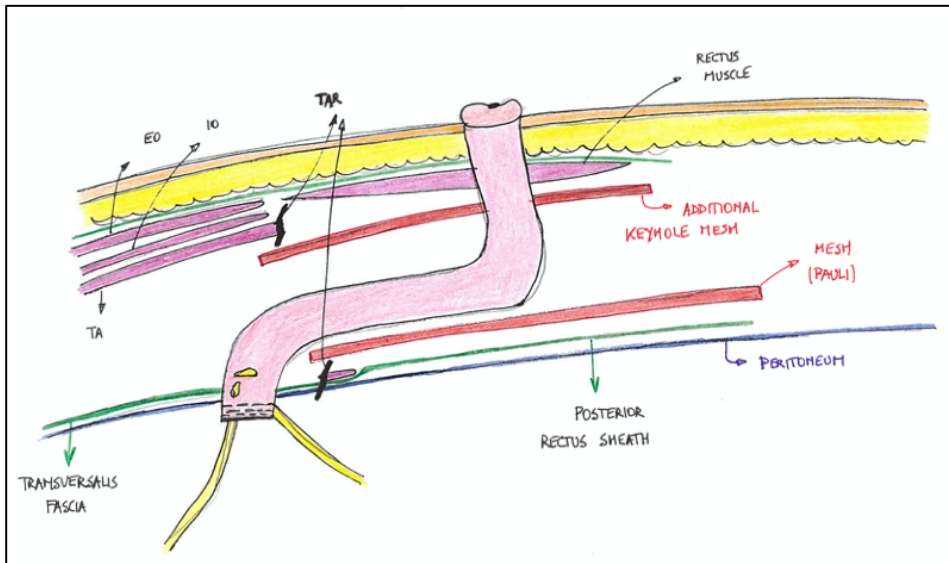
**Figure 1** - Illustration of an intraperitoneal keyhole mesh in the treatment of an ileal conduit parastomal hernia  
IO=internal oblique muscle; EO=external oblique muscle; TA=transversus abdominis muscle



**Figure 2** - Illustration of an intraperitoneal Sugarbaker mesh in the treatment of an ileal conduit parastomal hernia  
IO=internal oblique muscle; EO=external oblique muscle; TA=transversus abdominis muscle



**Figure 3** - Illustration of an intraperitoneal funnel-shaped mesh in the treatment of an ileal conduit parastomal hernia  
 IO=internal oblique muscle; EO=external oblique muscle; TA=transversus abdominis muscle



**Figure 4** - Illustration of the extraperitoneal Sugarbaker technique in the treatment of an ileal conduit parastomal hernia (often referred to as 'Pauli technique')  
 IO=internal oblique muscle; EO=external oblique muscle; TA=transversus abdominis muscle; TAR=transversus abdominis release

**Prevention and treatment of ventral incisional hernias**

Regarding the prevention of incisional hernias after laparotomy, current literature provides several clear insights on the optimal technique to close the abdominal wall. For the primary closure of laparotomies, guidelines advise the use of a slowly absorbable running suture, 'small bites' technique, and adherence to a 4 to 1 suture to wound length ratio<sup>6,39</sup>. Besides these recommendations, the use of a prophylactic mesh in the prevention of IHs has been proposed. There is evidence that a prophylactic mesh safely and effectively reduces the incidence of incisional hernias after midline laparotomy, and several guidelines state that its use should be considered in high-risk patients<sup>39,40</sup>. The presence of an AAA has been identified as an independent risk factor for the development of an IH, as they both illustrate the presence of an underlying connective tissue disorder<sup>9,41</sup>. Several randomized controlled trials have shown a significant decrease in the incidence of IHs after open AAA repair if a prophylactic mesh is used, without an increase in overall or mesh-related complications<sup>42</sup>. Reported follow-up of these trials is limited to a maximum of 3 years, so long-term data are still lacking. Despite these observations, surgeons remain reluctant to use a prophylactic mesh after midline laparotomy, even in high-risk patients<sup>43</sup>.

In the treatment of ventral IHs, a mesh-based repair using the retromuscular plane behind the rectus muscles (currently referred to as the retrorectus plane<sup>44</sup>) has been used for decades. This technique was originally proposed by Jean Rives<sup>45</sup>. However, in larger or more complex ventral hernias, component separation techniques are often required to allow medialization of fascial edges. Both anterior and posterior component separation techniques, either open or endoscopic, have been proposed as valuable options to avoid bridging of hernia defects. Anterior component separation techniques (ACST) consist of a division of the external oblique muscle lateral to the semilunar line. In open surgery, this implies the creation of large subcutaneous flaps, which adds significant morbidity to the procedure. Originally, posterior component separation techniques (PCST) consisted of extending the retrorectus dissection laterally between the internal oblique and the transversus abdominis muscle<sup>46</sup>. However, this technique has the disadvantage that neurovascular bundles to the rectus muscles have to be transected, which leads to significant atrophy. In 2012, the technique of transversus abdominis release (TAR) was described, which allows mesh placement in the retrorectus and retromuscular position behind all three lateral abdominal wall muscles, after the creation of a large retromuscular and preperitoneal space<sup>47</sup>. When compared to both open and endoscopic ACST, PCST have the advantage that a much wider mesh can be placed, beyond the lateral borders of the rectus muscles<sup>48,49</sup>. Complex abdominal wall

reconstructions requiring TAR are technically challenging to perform with conventional laparoscopic instruments, because of the limited workspace and the lack of angulation of instruments<sup>50</sup>. These limitations have been overcome by the introduction of robotic-assisted surgery<sup>35,51</sup>. Robotic-assisted TAR (rTAR) is similar to open TAR (oTAR) in terms of defect closure and retromuscular mesh position, but adds the benefits of minimally invasive surgery. The technique of rTAR has rapidly gained popularity in recent years, yet available evidence consists merely of observational data, and generally only short-term results have been described. Furthermore, a recently published pooled analysis of available data is subject to several statistical and methodological flaws<sup>52</sup>.

## **Aims of this thesis**

This thesis aims to report on both the technical aspects and outcomes of several recent advances in abdominal wall surgery. Techniques in both the treatment and prophylaxis of abdominal wall defects are studied in the field of inguinal, parastomal and ventral hernias. Two recent developments are evaluated throughout the chapters. First, outcomes of minimally invasive surgery (and mainly robotic-assisted surgery) in the field of hernia surgery are reported. Second, in the prevention of IHs after open AAA repair, both current practice and long-term results regarding the use of a prophylactic mesh are being investigated.

## **Outline of this thesis**

In **Part I**, outcomes of two novel techniques in the minimally invasive treatment of inguinal hernias are presented. **Chapter 2** describes the quality of life and lower urinary tract symptoms after the treatment of bilateral inguinal hernias in male patients, using one large self-gripping mesh covering both groins. In **Chapter 3**, the feasibility and short-term outcomes of robotic-assisted transabdominal repair of inguinal hernias after prostatectomy are reported.

**Part II** focuses on the minimally invasive treatment of ileal conduit parastomal hernias. **Chapter 4** includes a systematic review of currently available evidence regarding this complex clinical problem. In **Chapter 5**, technical considerations and short-term outcomes of the robotic-assisted treatment of this type of hernias are described.

**Part III** consists of 6 chapters that report on recent advances in the prevention and treatment of ventral (incisional) hernias. **Chapter 6** describes the stepwise introduction

of the robotic platform to the field of abdominal wall surgery in a general hospital in Belgium (Maria Middelaers Hospital, Gent). Besides a description of logistic and economic implications, clinical outcomes and major changes in clinical practice are reported. The two following chapters describe the use and outcomes of a prophylactic mesh after open AAA repair in the prevention of IHs, by evaluating the current practice among vascular surgeons in Belgium and The Netherlands (**Chapter 7**) and the long-term outcomes in the setting of a randomized controlled trial (**Chapter 8**). The last three chapters of this thesis focus on the use of robotic-assisted component separation techniques in the treatment of complex ventral incisional hernias. **Chapter 9** reports on the short-term outcomes of rTAR when compared to oTAR, in a multicenter retrospective design. In **Chapter 10**, a word of caution to facilitate interpretation of a pooled analysis of available outcomes in rTAR is written down. To conclude, **Chapter 11** includes a study protocol for a multicenter randomized controlled trial to prospectively evaluate both short- and long-term outcomes of rTAR, in a comparison to oTAR.

## References

1. Kingsnorth A, LeBlanc K. Hernias: inguinal and incisional. *Lancet* 2003; 362(9395): 1561-71.
2. The HerniaSurge Group. International guidelines for groin hernia management. *Hernia* 2018; 22(1): 1-165.
3. Rezaee M, Goldwag J, Goddard B, Bihle W, Viazmenski A, Wilson M et al. Parastomal hernia development after cystectomy and ileal conduit for bladder cancer: results from the Dartmouth ileal conduit enhancement (DICE) project. *Can J Urol* 2020; 27(5):10369-77.
4. Su J, Hoy N, Fafaj A, Tastaldi L, Strong A, Rosen M et al. The European Hernia Society classification applied to the rare cases of parastomal hernia after ileal conduit urinary diversion: a retrospective cohort of 96 patients. *Hernia*. 2021; 25(1): 125-131.
5. Narang S, Alam N, Campain N, Pathak S, McGrath J, Daniels I et al. Parastomal hernia following cystectomy and ileal conduit urinary diversion: a systematic review. *Hernia* 2017; 21(2): 163-175.
6. Deerenberg E, Harlaar J, Steyerberg E, Lont H, van Doorn H, Heisterkamp J et al. Small bites versus large bites for closure of abdominal midline incisions (STITCH): a double-blind, multicentre, randomised controlled trial. *Lancet* 2015; 386(10000): 1254-1260.
7. Fink C, Baumann P, Wente M, Knebel P, Bruckner T, Ulrich A et al. Incisional hernia rate 3 years after midline laparotomy. *Br J Surg* 2014; 101(2): 51-4.
8. De Bruin J, Baas A, Buth J, Prinssen M, Verhoeven EL, Cuypers P et al; DREAM Study Group. Long-term outcome of open or endovascular repair of abdominal aortic aneurysm. *N Engl J Med* 2010; 362(20): 1881-9.
9. Alnassar S, Bawahab M, Abdoh A, Guzman R, Al Tuwajjiri T, Louridas G. Incisional hernia postrepair of abdominal aortic occlusive and aneurysmal disease: five-year incidence. *Vascular* 2012; 20(5): 273-7.
10. Poulouse B, Shelton J, Phillips S, Moore D, Nealon W, Penson D et al. Epidemiology and cost of ventral hernia repair: making the case for hernia research. *Hernia* 2012; 16(2): 179-83.



11. Köckerling F, Sheen A, Berrevoet F, Campanelli G, Cuccurullo D, Fortelny R et al. The reality of general surgery training and increased complexity of abdominal wall hernia surgery. *Hernia* 2019; 23(6): 1081-91.
12. Lichtenstein I, Shulman A, Amid P, Montllor M. The tension-free hernioplasty. *Am J Surg* 1989; 157(2): 188-93.
13. Bökkerink W, van Meggelen M, van Dijk J, Čadanová D, Mollen R. Long-term results of the SOFTGRIP trial: TIPP versus ProGrip Lichtenstein's inguinal hernia repair. *Hernia* 2022 Jan 13. doi: 10.1007/s10029-021-02542-1. Epub ahead of print.
14. Bakker W, Aufenacker T, Boschman J, Burgmans J. Lightweight mesh is recommended in open inguinal (Lichtenstein) hernia repair: A systematic review and meta-analysis. *Surgery* 2020; 167(3): 581-89.
15. Lockhart K, Dunn D, Teo S, Ng J, Dhillon M, Teo E et al. Mesh versus non-mesh for inguinal and femoral hernia repair. *Cochrane Database Syst Rev* 2018; 9(9): CD011517.
16. Lyu Y, Cheng Y, Wang B, Du W, Xu Y. Comparison of endoscopic surgery and Lichtenstein repair for treatment of inguinal hernias: A network meta-analysis. *Medicine (Baltimore)*. 2020; 99(6): e19134.
17. Aiolfi A, Cavalli M, Del Ferraro S, Manfredini L, Lombardo F, Bonitta G et al. Total extraperitoneal (TEP) versus laparoscopic transabdominal preperitoneal (TAPP) hernioplasty: systematic review and trial sequential analysis of randomized controlled trials. *Hernia* 2021; 25(5): 1147-57.
18. Köckerling F, Bittner R, Jacob D, Seidelmann L, Keller T, Adolf D et al. TEP versus TAPP: comparison of the perioperative outcome in 17,587 patients with a primary unilateral inguinal hernia. *Surg Endosc* 2015; 29(12): 3750-60.
19. Feliu X, Clavería R, Besora P, Camps J, Fernández-Sallent E, Viñas X et al. Bilateral inguinal hernia repair: laparoscopic or open approach? *Hernia* 2011; 15(1): 15-8.
20. Marmolejo A, Farell J, Ruiz Funes A, Ayala S, Sánchez A, Navarro C et al. Critical view of the myopectineal orifice: a scoring system to objectively evaluate transabdominal preperitoneal inguinal hernia repair. *Surg Endosc* 2021 Nov 30. doi: 10.1007/s00464-021-08874-4. Epub ahead of print.
21. Halm J, Heisterkamp J, Boelhouwer R, den Hoed P, Weidema W. Totally extraperitoneal repair for bilateral inguinal hernia: does mesh configuration matter? *Surg Endosc* 2005; 19(10): 1373-6.

22. Dulucq J-L, Wintringer P, Mahajna A. Totally extraperitoneal (TEP) hernia repair after radical prostatectomy or previous lower abdominal surgery: is it safe? A prospective study. *Surg Endosc* 2006; 20(3): 473-6.
23. Le Page P, Smialkowski A, Morton J, Fenton-Lee D. Totally extraperitoneal inguinal hernia repair in patients previously having prostatectomy is feasible, safe, and effective. *Surg Endosc* 2013; 27(12): 4485-90.
24. Sakon M, Sekino Y, Okada M, Seki H, Munakata Y. Laparoscopic inguinal hernioplasty after robot-assisted laparoscopic radical prostatectomy. *Hernia* 2017; 21: 745-8.
25. Wauschkuhn C, Schwarz J, Bittner R. Laparoscopic transperitoneal inguinal hernia repair (TAPP) after radical prostatectomy: is it safe? Results of prospectively collected data of more than 200 cases. *Surg Endosc* 2009; 23(5): 973-7.
26. Claus C, Coelho J, Campos A, Filho A, Loureiro M, Dimbarre D et al. Laparoscopic inguinal hernioplasty after radical prostatectomy: is it safe? Prospective clinical trial. *Hernia* 2014; 18(2): 255-9.
27. Śmietański M, Szczepkowski M, Alexandre J, Berger D, Bury K, Conze J et al. European Hernia Society classification of parastomal hernias. *Hernia* 2014; 18(1): 1-6.
28. Hansson B, Slater N, van der Velden A, Groenewoud H, Buyne O, de Hingh IH et al. Surgical techniques for parastomal hernia repair: a systematic review of the literature. *Ann Surg* 2012; 255(4): 685-95.
29. Tastaldi L, Haskins I, Perez A, Prabhu A, Rosenblatt S, Rosen M. Single center experience with the modified retromuscular Sugarbaker technique for parastomal hernia repair. *Hernia* 2017; 21(6): 941-49.
30. Raigani S, Criss C, Petro C, Prabhu A, Novitsky Y, Rosen M. Single-center experience with parastomal hernia repair using retromuscular mesh placement. *J Gastrointest Surg* 2014; 18(9): 1673-7.
31. Safadi B. Laparoscopic repair of parastomal hernias: early results. *Surg Endosc* 2004; 18(4): 676-80.
32. Mäkäräinen-Uhlbäck E, Vironen J, Falenius V, Nordström P, Välikoski A, Kössi J et al. Parastomal Hernia: A Retrospective Nationwide Cohort Study Comparing Different Techniques with Long-Term Follow-Up. *World J Surg* 2021; 45(6): 1742-49.

33. Fischer I, Wundsam H, Mitteregger M, Köhler G. Parastomal Hernia Repair with a 3D Funnel Intraoperative Mesh Device and Same-Sided Stoma Relocation: Results of 56 Cases. *World J Surg* 2017; 41(12): 3212-17.
34. Pauli E, Juza R, Winder J. How I do it: novel parastomal herniorrhaphy utilizing transversus abdominis release. *Hernia* 2016; 20(4): 547-52.
35. Grossi J, Lee B, Belyansky I, Carbonell A, Cavazzola L, Novitsky Y et al. Critical view of robotic-assisted transverse abdominal release (r-TAR). *Hernia* 2021. doi: 10.1007/s10029-021-02391-y. Epub ahead of print.
36. Lambrecht J. Endoscopic preperitoneal parastomal hernia repair (ePauli repair): an observational study. *Surg Endosc* 2021; 35(4): 1903-7.
37. Gore J, Litwin M. Urologic Diseases in America Project. Quality of care in bladder cancer: trends in urinary diversion following radical cystectomy. *World J Urol* 2009; 27(1): 45-50.
38. Mäkäräinen-Uhlbäck E, Vironen J, Vaarala M, Nordström P, Välikoski A, Kössi J et al. Keyhole versus Sugarbaker techniques in parastomal hernia repair following ileal conduit urinary diversion: a retrospective nationwide cohort study. *BMC Surg* 2021; 21(1): 231.
39. Muysoms F, Antoniou S, Bury K et al. European Hernia Society guidelines on the closure of abdominal wall incisions. *Hernia* 2015; 19: 1–24.
40. Wanhainen A, Verzini F, Van Herzele I, Allaire I, Bown M, Cohnert T et al. Editor's Choice - European Society for Vascular Surgery (ESVS) 2019 Clinical Practice Guidelines on the Management of Abdominal Aorto-iliac Artery Aneurysms. *Eur J Vasc Endovasc Surg* 2019; 57: 8-93.
41. Antoniou G, Georgiadis G, Antoniou S, Grandrath F, Giannoukas A, Lazarides M. Abdominal aortic aneurysm and abdominal wall hernia as manifestations of a connective tissue disorder. *J Vasc Surg* 2011; 54(4): 1175-81.
42. Nicolajsen C, Eldrup N. Abdominal Closure and the Risk of Incisional Hernia in Aneurysm Surgery - A Systematic Review and Meta-analysis. *Eur J Vasc Endovasc Surg* 2020; 59(2): 227-36.
43. Depuydt M, Allaeyns M, de Carvalho L, Vanlander A, Berrevoet F. Prophylactic Mesh After Midline Laparotomy: Evidence is out There, but why do Surgeons Hesitate? *World J Surg* 2021; 45(5): 1349-61.

44. Parker S, Halligan S, Liang M, Muysoms F, Adrales G, Boutall A et al. International classification of abdominal wall planes (ICAP) to describe mesh insertion for ventral hernia repair. *Br J Surg* 2020; 107(3): 209-17.
45. Rives J, Pire J, Flament J, Convers G. Le traitement des grandes éventrations a propos de 133 cas [Treatment of large eventrations (apropos of 133 cases)]. *Minerva Chir* 1977; 32(11): 749-56.
46. Carbonell A, Cobb W, Chen S. Posterior components separation during retromuscular hernia repair. *Hernia* 2008; 12(4): 359-62.
47. Novitsky Y, Elliott H, Orenstein S, Rosen M. Transversus abdominis muscle release: a novel approach to posterior component separation during complex abdominal wall reconstruction. *Am J Surg* 2012; 204(5): 709-16.
48. Sneider D, Yurtkap Y, Kroese L, Jeekel J, Muysoms F, Kleinrensink G et al. Anatomical study comparing medialization after Rives-Stoppa, anterior component separation, and posterior component separation. *Surgery* 2019; 165(5): 996-1002.
49. Balla A, Alarcón I, Morales-Conde S. Minimally invasive component separation technique for large ventral hernia: which is the best choice? A systematic literature review. *Surg Endosc* 2020; 34(1): 14-30.
50. Belyansky I, Daes J, Radu V, Balasubramanian R, Reza Zahiri H, Weltz A et al. A novel approach using the enhanced-view totally extraperitoneal (eTEP) technique for laparoscopic retromuscular hernia repair. *Surg Endosc* 2018; 32(3): 1525-32.
51. Dietz U, Kudsi O, Garcia-Ureña M, Baur J, Ramser M, Maksimovic S et al. Robotic hernia repair III. English version: Robotic incisional hernia repair with transversus abdominis release (r-TAR). Video report and results of a cohort study. *Chirurg* 2021; 92: 28-39.
52. Bracale U, Corcione F, Neola D, Castiglioni S, Cavallaro G, Stabilini C et al. Transversus abdominis release (TAR) for ventral hernia repair: open or robotic? Short-term outcomes from a systematic review with meta-analysis. *Hernia* 2021; 25(6): 1471-80.



# **Part I**

## Inguinal hernia



# Chapter 2

## Laparoscopic bilateral groin hernia repair with one large self-fixating mesh: prospective observational study with patient reported outcome of urological symptoms and EuraHS-QoL scores

Filip Muysoms  
Maxime Dewulf  
Iris Kyle-Leinhase  
Rita Baumgartner  
Filip Ameye  
Barbara Defoort  
Pieter Pletinckx

*Surgical Endoscopy* 2020; 34(2): 920-9.



## Abstract

**Background.** Laparoscopic bilateral inguinal hernia repair may be completed with one large self-fixating mesh crossing the midline. No studies have investigated in detail whether preperitoneal mesh placement induces temporary or more lasting urinary symptoms.

**Methods.** Urinary and hernia related symptoms were evaluated preoperatively and postoperatively at 1, 3 and 12 months using the ICIQ-MLUTS questionnaire and EuraHS-QoL score in patients undergoing bilateral inguinal hernia repair.

**Results.** One hundred patients were included. Voiding symptoms and bother scores were unchanged at 1 or 3 months, but there was significant improvement at 12 months compared with preoperative findings (symptoms  $P<0.001$ ; bother score  $P<0.01$ ). Incontinence symptoms improved at 1 month ( $P<0.05$ ) but not at 3 or 12 months, with a bother score significantly improved at 1 month ( $P<0.01$ ) and 12 months ( $P<0.01$ ). Diurnal and nocturnal frequency did not change significantly postoperatively, but 12 months nocturnal bother score was decreased ( $P<0.05$ ).

EuraHS-QoL scores showed statistically significant improvement in all 3 domains for all measurements at the different follow-up moments compared to previous measurements. Postoperative symptoms were improved at 12 months, compared with preoperative pain scores (-6.1), restriction of activity (-10.1) and cosmetic scores (-4.7) These findings were statistically significant ( $P<0.001$ ). At 12 months, there were no patients with severe discomfort (score  $\geq 5$ ) for any of 3 domains. No recurrences were diagnosed with 95% clinical follow-up at 12 months.

**Conclusion.** Laparoscopic bilateral groin hernia repair with one large preperitoneal self-fixating mesh did not cause new urinary symptoms and demonstrated significant improvement in voiding symptoms at 12 months. Incontinence and nocturnal bother score were significantly improved.

**Keywords.** Inguinal hernia - Groin hernia - Laparoscopic surgery - Urinary symptoms - Quality of Life - Self-fixating mesh - ICIQ-MLUTS - EuraHS-QoL score

## Introduction

### **Background and rationale**

Laparoscopic surgery for the treatment of groin hernias has become standard of care for many surgeons. It has been one of the recommended treatment options when local expertise is available<sup>1-3</sup>. No advantage has been identified between the laparoscopic techniques, either transabdominal preperitoneal (TAPP) or totally extraperitoneal repair (TEP)<sup>4,5</sup>. For bilateral groin hernia repair, the recent updated international groin hernias guidelines (Herniasurge) strongly recommend laparoscopic repair, provided that surgical expertise and sufficient resources are available<sup>3</sup>.

Fixation of the mesh in laparoscopic groin hernia repair was originally performed with penetrating fixation, using staples or tackers. Alternatives to penetrating fixation using glue or self-fixating meshes, or no fixation at all have been proposed to avoid postoperative pain<sup>6,7</sup>. The Herniasurge guidelines suggest that penetrating fixation can be omitted in laparoscopic groin hernia repair, except for large medial (direct) hernias (EHS classification, type M3) where mesh fixation is recommended to avoid recurrences<sup>3</sup>. The EAES consensus conference on laparoscopic groin hernia repair stated that sufficient overlap of mesh is more important than fixation of the mesh and that tack and suture fixation of mesh should be avoided, with the exception of large medial inguinal hernias<sup>8</sup>.

Rene Stoppa described a technique for treatment of bilateral or multi-recurrent groin hernias by placing a large mesh in the preperitoneal position through a midline incision in 1973<sup>9,10</sup>. In this technique, a large mesh without fixation is placed in the preperitoneal position. During a laparoscopic bilateral groin hernia repair, a similar preperitoneal mesh repair is performed via an endoscopic approach. For the laparoscopic approach, two separate unilateral meshes are most commonly used. The EAES consensus states that the mesh size for laparoscopic repair of a unilateral groin hernia should be at least 15 cm in width and 10 cm in length<sup>8</sup>. There is no data to guide us regarding whether one large mesh covering both groins might be beneficial over the use of two separate meshes.

The first report on the use of one large mesh in bilateral minimally invasive groin hernia repair was by Geis et al. in 1994<sup>11</sup>. Deans et al. introduced the term 'bikini mesh' to describe their large mesh covering the Fruchaud's MyoPectineal Orifice (MPO) on both sides<sup>12</sup>. Subsequently, Knook et al. reported on the use of one giant 'slipmesh' to cover both groins<sup>13</sup>. In the largest patient series to date comparing the use of two separate

meshes with one large mesh in laparoscopic bilateral groin hernia repair, no difference in recurrence rates was seen<sup>14</sup>. Regarding urinary symptoms, one bladder perforation was reported in the single mesh group, and there was no significant difference in postoperative urinary retention. Recently, Kohler et al. reported on the early results of a mesh designed specifically for bilateral groin hernia repair in a small case series<sup>15</sup>. They found a high recurrence rate which they attributed to the design of the mesh with a central slit on the midline.

We have been using self-fixating mesh for laparoscopic groin hernia repair since 2009 and have published a favorable patient reported outcome evaluated with the EuraHS-QoL score after unilateral repairs<sup>16</sup>. We initially used two separate meshes of 15 x 13 cm for bilateral laparoscopic groin hernia repairs. When the larger 30x15 cm mesh became available, we started using one large mesh for bilateral laparoscopic groin hernia repair as our standard approach. Laparoscopic bilateral groin hernia repair includes the placement of mesh in the retro-pubic plane in front of the bladder. Studies have not investigated whether a large mesh, in this position, causes temporary or more lasting urinary symptoms.

### **Objectives**

To evaluate the presence of urinary symptoms preoperatively and until 12 months postoperatively using a validated urinary quality of life score in a prospective cohort study of 100 patients undergoing a bilateral laparoscopic groin hernia repair with one large self-fixating mesh.

### **Methods**

#### **Study design**

The study is a prospective single center observational cohort study of laparoscopic bilateral groin hernia repair using one large self-fixating mesh.

#### **Setting**

The study was performed at the Department of Surgery at the Maria Middelaers Hospital in Gent, Belgium. Operations were performed by three surgeons with extensive experience in laparoscopic groin hernia repair. The study was approved by the ethics committee at the University of Antwerp and by the local ethics committee at Maria

Middelares Gent hospital with the Belgian trial number B300201525248. The study protocol was submitted at ClinicalTrials.gov (NCT02525666) before the start of the study.

### ***Inclusion criteria***

Adult male patients scheduled for treatment of bilateral groin hernias with a laparoscopic technique were eligible.

### ***Exclusion criteria***

Excluded from participation in the study were: unilateral hernias, recurrent hernias, hernia repair combined with another surgical procedure, female gender, patients under 18 years or above 80 years of age, ASA score 4 or higher, emergency operations, patients unable to perform the QoL assessment because of language barriers or intellectual incapacity, and patients preferring not to participate in the study.


### ***Follow-up***

All patients were invited to a standard clinical outpatient follow-up visit with the surgeon at 4 weeks and at 12 months postoperatively. Preoperatively and during the control visits, patients were asked to complete the EuraHS-QoL questionnaire (European registry of abdominal wall hernias Quality of Life score) and the ICIQ-MLUTS (International Consultation on Incontinence modular Questionnaire - Male Lower Urinary Tract Symptoms). During the clinical outpatient follow-up visit at 1 month, patients were provided with additional questionnaires to be completed at 3 months postoperatively and returned by mail with envelopes provided with adequate postage.

### ***Surgical technique***

Patients were operated with a laparoscopic approach either by TAPP or TEP according to the surgeons' preference. Groin hernia repair was performed according to the standard surgical principles, with mesh placement after appropriate preperitoneal dissection and critical view of the myopectineal orifice, as described by Jorge Daes and Edward Felix<sup>17</sup>. One large self-fixating mesh (Parietex Progrid<sup>TM</sup> Self-Fixating Mesh, Medtronic, Minneapolis, MN, US) with a width of 28 cm and a length of 13 cm was tailored as shown in Figure 1. The mesh is folded, introduced, unfolded and positioned in the dissected preperitoneal plane with no additional fixation. Care was taken to properly close the peritoneum after mesh placement in TAPP patients using a barbed

suture (V-Loc™ 90, Medtronic, Minneapolis, MN, US). A video of the technique is available at <https://www.youtube.com/watch?v=ZpwYdzE5AY0>.



**Figure 1** -Configuration of the mesh, tailored from a 30x15 cm out-of-the-box rectangular configuration (Parietex Progrid™ Self-Fixating Mesh, Medtronic, Minneapolis, MN, US) to a width of 28 cm and a length of 13 cm. The two lateral corners are cut to position the mesh over the iliac vessels and the cord structures.

We did not use a urinary catheter during surgery. The patients were asked to void prior to surgery. In patients who experienced postoperative urinary retention, in-and-out bladder catheterization was used.

### **Variables**

Primary endpoints of the study were the level of urinary symptoms and bother scores according to the ICIQ-MLUTS at 12 months postoperative compared to the preoperative levels. Secondary endpoints were recurrence rate, assessment of urinary symptoms at 1 month and 3 months, assessment of the Quality of life with the EurHS-QoL score at 1 month, 3 months and 12 months, intraoperative and postoperative complications,

postoperative hospital stay, and skin to skin operating time. All patients and surgical variables were entered prospectively in the EuraHS online database (European Registry for Abdominal Wall Hernias)<sup>18</sup>.

### **Data measurement**

During the preoperative consultation, patients were instructed about the study and invited to participate. Informed consent forms together with the ICIQ-MLUTS questionnaire and the EuraHS-Qol score questionnaire were given to the patients. At the time of admission, patients were asked if they had any further questions and if they wanted to participate in the study. The questionnaires filled out prior to admission were collected. At the 1 month postoperative visit, patients completed the questionnaire independently, and were assessed clinically. A self-addressed envelope was given to patients with questionnaires to complete at 3 months. At 12 months, the same procedure with clinical examination followed by independent completion of the questionnaires was performed. All data, including the EuraHS-Qol scores, were entered into the prospective online EuraHS database we maintain in the department for all abdominal wall surgeries, and extracted at the end of the study in an excel file. The European Hernia Society classification for groin hernias was used<sup>19</sup>. The data of the ICIQ-MLUTS questionnaires were entered in a separate excel file from the patient case report forms. The database was closed July 30th 2018 after the last 12 months follow-up was scheduled. The database was completely double-checked by two co-authors who were not involved in the original data input. The database was given to an independent statistician who chose the most appropriate statistical methods to analyze the results.

### **Quantitative variables**

The ICIQ-MLUTS has been constructed and validated by the International Consultation on Incontinence<sup>20-22</sup>. In this study, a Dutch version for Belgium was used. An English version of the questionnaire is available online. The questionnaire has 13 questions and relates to the symptoms experienced in the last 30 days. Each question consists of two items, Xa and Xb in a specific format. An example of the questionnaire format is shown in figure 2 for Q4. The QXa answer to the question relates to the frequency or the intensity of the symptoms to be answered in a five-point scale from 0 to 4. For analysis, we grouped questions in a *voiding symptoms subscale* (Q2a+Q3a+Q4a+Q5a+Q6a) with a range from 0 to 20 and an *incontinence symptoms subscale* (Q7a+Q8a+Q9a+Q10a+Q11a+Q12a) with a range from 0 to 24. Questions 13 and 14 have a similar format, but relate to the number of times a patient has to urinate during daytime

(*diurnal frequency*, Q13a) and during nighttime (*nocturnal frequency*, Q14a). The QXb answer is an eleven-point numeric rating scale from 0 to 10 where the patient is asked to answer how much the symptoms bother him (bother scale). When QXa was answered with "never" or "normal", the QXb often was not answered by the patients and those answers were considered as having a bother score of 0. For analysis we also grouped questions in a voiding bother score (Q2b+Q3b+Q4b+Q5b+Q6b) with a range from 0 to 50 and an incontinence bother score (Q7b+Q8b+Q9b+Q10b+Q11b+Q12b) with a range from 0 to 60. The *diurnal frequency bother score* (Q13b) and the *nocturnal frequency bother score* (Q14b) have a range from 0 to 10. (methodology of ICIQ-MLUTS analysis can be found online as a supplementary file).

**Example of the format (Q4) used for the ICIQ-MLUTS questions**

DUTCH for  
Belgium

4a. Hoe zou u de kracht van uw urinestraal omschrijven?

normaal	<input type="checkbox"/>	0
zelden zwak	<input type="checkbox"/>	1
soms zwak	<input type="checkbox"/>	2
meestal zwak	<input type="checkbox"/>	3
altijd zwak	<input type="checkbox"/>	4

4b. Hoeveel last hebt u hiervan?  
*Omcirkel een getal van 0 (helemaal geen last) tot 10 (heel veel last)*

0	1	2	3	4	5	6	7	8	9	10
helemaal geen last										heel veel last

ENGLISH

4a. Would you say that the strength of your urinary stream is...

Normal	<input type="checkbox"/>	0
Occasionally reduced	<input type="checkbox"/>	1
Sometimes reduced	<input type="checkbox"/>	2
Reduced most of the time	<input type="checkbox"/>	3
Reduced all of the time	<input type="checkbox"/>	4

4b. How much does this bother you?  
*Please ring a number between 0(not at all) and 10 (a great deal)*

0	1	2	3	4	5	6	7	8	9	10
---	---	---	---	---	---	---	---	---	---	----

**Figure 2** - Example of the format of question Q4a and Q4b of the ICIQ-MLUTS questionnaire. The questionnaire has 13 questions and each question consists of two items, Xa and Xb. In this study the Dutch version for Belgium was used.

The results of the EuraHS-QoL score were analyzed as described in our previous validation study for groin hernia repair<sup>16</sup>. Data were analyzed overall for all 9 questions (range 0-90) and for the 3 domains: pain (range 0-30), restriction of activity (range 0-40),

and cosmetic (range 0-20). The methodology of the EuraHS-QoL score assessment can be found online as a supplementary file.

### **Bias**

Care was taken to explain the questionnaires to the patients at time of obtaining the informed consent, but the actual filling out of the questionnaires was performed independently in absence of the surgeon. Often patients arrived at outpatient visits accompanied by a family member, who might have assisted the patients in completing the questionnaires. No interim analysis was performed and no completed ICIQ-MLUTS questionnaires were seen or handled by the participating surgeons. Until the completed result came back from the statistician, the participating surgeons were completely unaware of any result of the patient reported outcomes on urinary symptoms.

### **Study size**

Because no published data on the frequency of urinary symptoms postoperatively after laparoscopic preperitoneal groin hernia repair were available at the start of the study, a sample size of 100 patients was empirically chosen as being large enough to evaluate the effect of a preperitoneal mesh on urinary symptoms and small enough to be performed within a reasonable time frame.

### **Statistical methods**

The statistical methodology was chosen and performed by an independent statistician. The distributions of patient characteristics, operative data and postoperative complications were summarized using proportions (%),  $n/N$  or means with standard deviations (SD). The ICIQ-MLUTS scores were summarized using means, medians and interquartile ranges (IR=P25-P75) for the symptoms scores and the bother scores separately. Changes over time during follow-up in comparison to preoperative baseline measurements were analyzed according to linear mixed models with unstructured covariance structure. For the EuraHS-QoL domain scores, average scores were graphically displayed using bar charts and a spider web chart using average values normalized to 100. P-values < 0.05 were considered as indicating statistical significance. Results graphically shown in the bar chart depict the mean scores of the 3 domains. All analyses were performed using SAS software (release 9.4, Cary, NC, US).



## **Results**

### ***Participants***

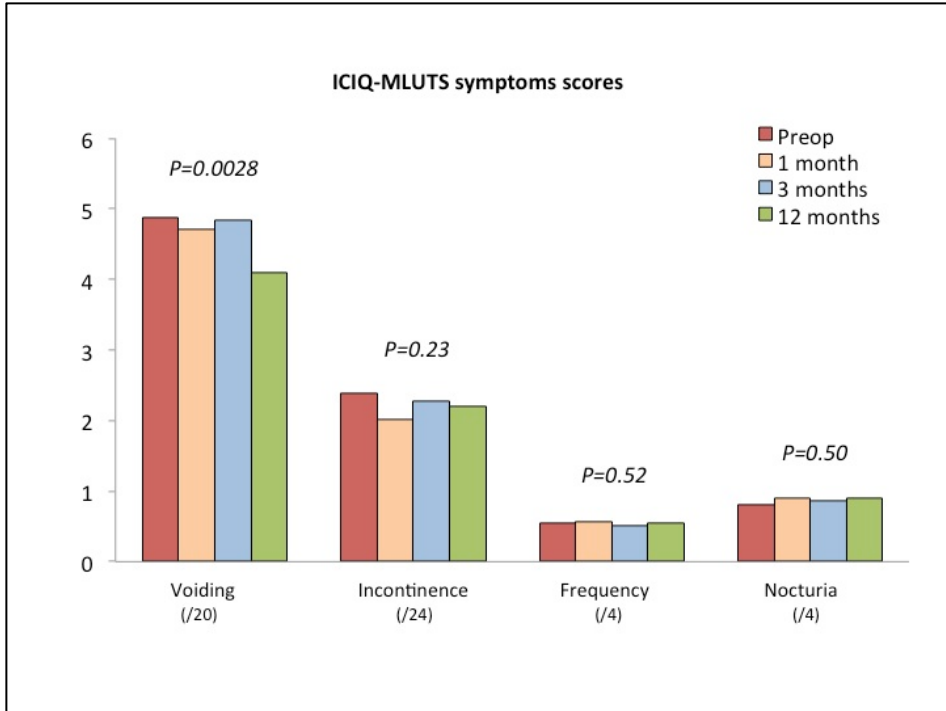
Between September 2015 and June 2017, 100 patients were prospectively enrolled in the study and operated by 3 surgeons. Distribution amongst surgeons was 61, 25 and 14 cases, with 75 patients undergoing TAPP and 25 patients TEP. Clinical outpatient follow-up at 1 month was 100%, questionnaires received at 3 months was 89% and clinical follow-up at 12 months was 95%. Two patients did not want to participate at 12 months and three patients only wanted to fill out the questionnaire. Overall follow-up with the questionnaire at 12 months was 98%.

### ***Descriptive data***

Patient characteristics at baseline, operative data, and postoperative complications are shown in Table 1. The operation was performed with less than 24 hours admission in 98%, in day clinic in 68% and one-night stay in 30% of patients. Postoperative complications consisted of urinary retention in 3%, readmission in 2 patients and seroma at 1 month follow-up in 8% of patients. No long-term complications or recurrences were seen at 12 months clinical follow-up (n=95).

### ***Outcome data***

The outcome data for our primary endpoint, ICIQ-MLUTS scores preoperatively and postoperatively are shown in Table 2. Time effect during follow-up is graphically depicted using the mean scores in Figure 3 for the ICIQ-MLUTS symptom scores and in Figure 4 for the ICIQ-MLUTS bother scores.



**Figure 3** - Evolution of symptoms scores using the ICIQ-MLUTS score at baseline, 1 month, 3 months and 12 months follow-up. P-values indicate the statistical significance of changes over time.

**Table 1 - Patient data at baseline, operative data and postoperative complications**

Variable	% (n/N) or mean (SD)	
<b>Age at the time of surgery (years)</b>	57 (13.4)	
<b>Body Mass Index (kg/m<sup>2</sup>)</b>		
< 25	57% (57/100)	
25-30	33% (33/100)	
≥ 30	10% (10/100)	
Mean (SD)	25 (3.5)	
<b>Daily smoker</b>	16% (16/100)	
<b>Hemodialysis</b>	2% (2/100)	
<b>EHS Hernia classification<sup>a</sup></b>		
Right side		
Lateral	54/100	
Medial	51/100	
Femoral	3/100	
Obturator	1/100	
Left side		
Lateral	70/100	
Medial	35/100	
Femoral	2/100	
Obturator	0/100	
<b>Duration of surgery (minutes (range))</b>	76 (40-168)	
<b>Intraoperative complications</b>		
Bleeding from epigastric vessels	1% (1/100)	
Conversion to open surgery	0% (0/100)	
<b>Intrahospital complications</b>		
Urinary retention	3%	
<b>Re-admissions</b>		
	2% (2/100)	
Hematoma: laparoscopic drainage	1	
Ileus requiring nasogastric tube	1	
<b>Hospital stay</b>		
Day clinic	68 % (68/100)	
One night stay	30 % (30/100)	
> 24 hours	2 % (2/100)	
<b>Postoperative complications</b>		
	1 month	12 months
Seroma	8	0
Hematoma	2	0
Surgical site infection	0	0
Recurrence	0	0

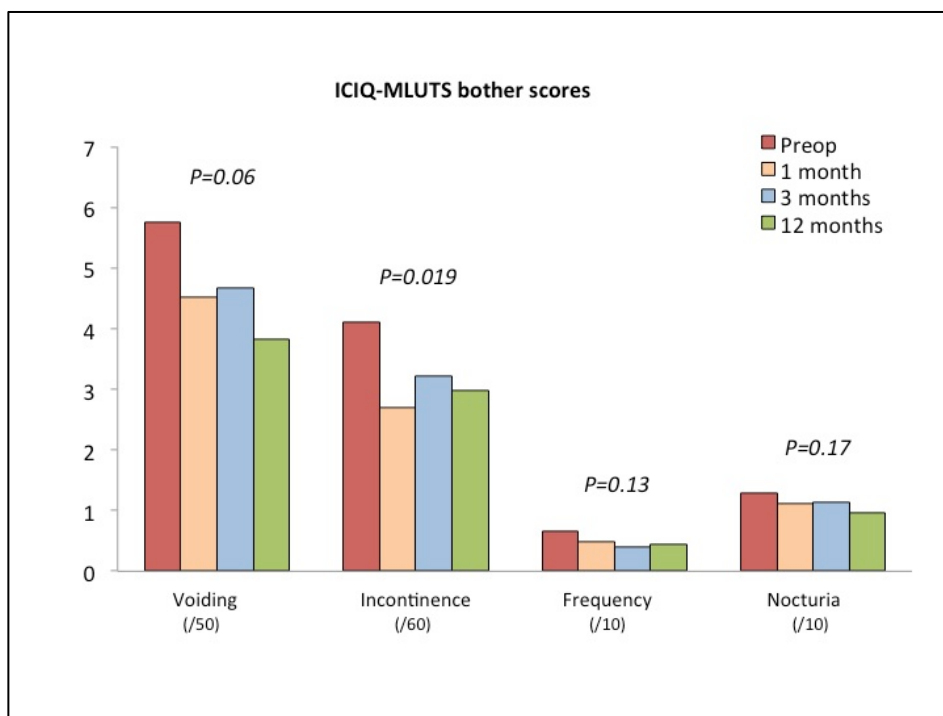
<sup>a</sup>According to the European Hernia Society classification<sup>19</sup>

n=number of patients; N=total number of patients; SD=standard deviation

**Table 2 - Patient reported outcome data using the ICIQ-MLUTS score**

		Preoperatively (N=100)	1 month (N=100)	3 months (N=89)	12 months (N=98)
<b>Voiding</b>	/20				
	Mean	4.88	4.71	4.83	4.09
	Median (IR)	4.5 (2.0 to 7.0)	4.0 (2.0 to 7.0)	4.0 (2.0 to 8.0)	3.0 (2.0 to 7.0)
<b>Voiding bother</b>	/50				
	Mean	5.74	4.52	4.67	3.82
	Median (IR)	3.0 (0.0 to 7.0)	3.0 (0.0 to 7.0)	2.0 (0.0 to 6.0)	2.0 (0.0 to 6.0)
<b>Incontinence</b>	/24				
	Mean	2.38	2.02	2.27	2.20
	Median (IR)	2.0 (1.0 to 4.0)	1.0 (0.0 to 3.0)	2.0 (1.0 to 3.0)	2.0 (0.0 to 4.0)
<b>Incontinence bother</b>	/60				
	Mean	4.10	2.69	3.22	2.99
	Median (IR)	2.0 (0.0 to 5.0)	1.0 (0.0 to 4.0)	2.0 (0.0 to 4.0)	1.0 (0.0 to 5.0)
<b>Diurnal frequency</b>	/4				
	Mean	0.55	0.56	0.51	0.54
	Median (IR)	0.0 (0.0 to 1.0)	0.0 (0.0 to 1.0)	0.0 (0.0 to 1.0)	0.0 (0.0 to 1.0)
<b>Diurnal frequency bother</b>	/10				
	Mean	0.66	0.48	0.39	0.45
	Median (IR)	0.0 (0.0 to 0.0)	0.0 (0.0 to 0.0)	0.0 (0.0 to 0.0)	0.0 (0.0 to 0.0)
<b>Nocturnal frequency</b>	/4				
	Mean	0.80	0.90	0.87	0.89
	Median (IR)	1.0 (0.0 to 1.0)	1.0 (0.0 to 1.0)	1.0 (0.0 to 1.0)	1.0 (0.0 to 1.0)
<b>Nocturnal frequency bother</b>	/10				
	Mean	1.29	1.11	1.14	0.97
	Median (IR)	1.0 (0.0 to 2.0)	0.0 (0.0 to 2.0)	1.0 (0.0 to 2.0)	0.0 (0.0 to 2.0)

P-values according to a linear mixed modeling with unstructured covariance structure (time-effect): Voiding P=0.0028; Voiding bother P=0.06; Incontinence P=0.23; Incontinence bother P=0.019; Diurnal frequency P=0.52; Diurnal frequency bother P=0.13; Nocturnal frequency P=0.50; Nocturnal frequency bother P=0.17  
 IR=Interquartile range; N=number of patients at follow-up



**Figure 4** - Evolution of bother scores using the ICIQ-MLUTS score at baseline, 1 month, 3 months and 12 months follow-up. P-values indicate the statistical significance of changes over time.

### Main results

Table 3 shows the average change in ICIQ-MLUTS scores at follow-up compared to the preoperative scores, with the change at 12 months being our primary endpoint. Significant lower scores were measured for voiding symptoms ( $P < 0.001$ ), voiding bother ( $P < 0.01$ ), incontinence bother ( $P < 0.01$ ) and nocturnal frequency bother ( $P < 0.05$ ). Importantly, no significant worsening of any of the scores was seen at any time point in follow-up.

### Other analyses

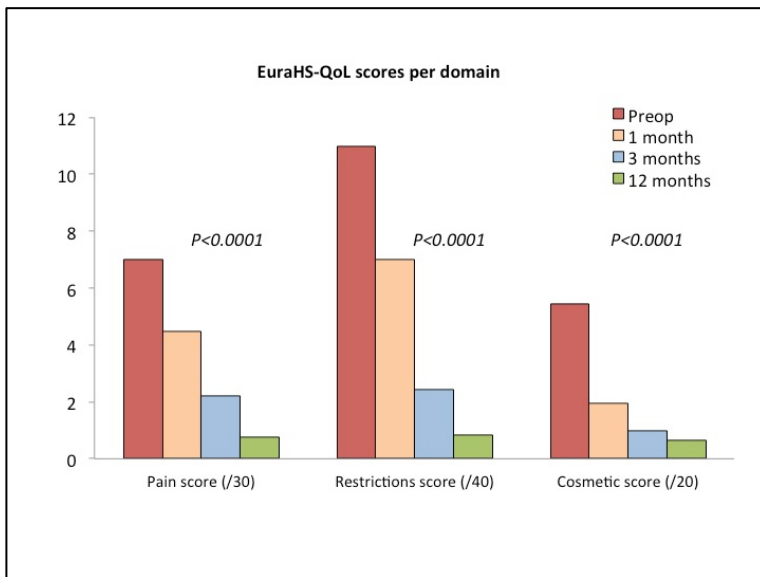
Table 4 shows the result for the EuraHS-QoL evaluation preoperatively and postoperatively. Time effect during follow-up is graphically depicted using the mean scores of EuraHS-QoL for the 3 domains in Figure 5. There was a significant decrease for the overall score and for the 3 domains individually (all  $P < 0.0001$ ). When analyzing the

EuraHS-QoL score, between 75% and 98% of patients noted a score = 0 (% no discomfort) for the 9 QoL questions at 12 months. Looking at the patients with a score  $\geq 5$  (% severe discomfort) this was 0% for all of the 9 QoL questions at 12 months.

**Table 3 - Change from the preoperative score of patient reported outcome data using the ICIQ-MLUTS score**

	1 month vs preop	3 months vs preop	12 months vs preop
Voiding	-0.21 (0.27)	-0.07 (0.26)	<b>-0.81 (0.23)<sup>a</sup></b>
Voiding bother	-1.28 (0.67)	-1.14 (0.65)	<b>-1.93 (0.68)<sup>b</sup></b>
Incontinence	<b>-0.36 (0.18)<sup>c</sup></b>	-0.08 (0.17)	-0.20 (0.18)
Incontinence bother	<b>-1.40 (0.44)<sup>b</sup></b>	-0.83 (0.59)	<b>-1.14 (0.42)<sup>b</sup></b>
Diurnal frequency	-0.00 (0.06)	-0.08 (0.07)	-0.03 (0.06)
Diurnal frequency bother	-0.18 (0.13)	<b>-0.31 (0.13)<sup>c</sup></b>	-0.22 (0.13)
Nocturnal frequency	+0.09 (0.06)	+0.02 (0.06)	+0.06 (0.06)
Nocturnal frequency bother	-0.18 (0.15)	-0.21 (0.16)	<b>-0.35 (0.16)<sup>c</sup></b>

Numbers are reported as mean (standard deviation)  
 Significances according to linear mixed models: <sup>a</sup>P<0.001; <sup>b</sup>P<0.01; <sup>c</sup>P<0.05  
 vs preop=versus preoperatively



**Figure 5 - Evolution of domain scores using the EuraHS-QoL instrument at baseline, 1 month, 3 months and 12 months follow-up. P-values indicate the statistical significance of changes over time.**

**Table 4 - Patient reported outcome data using the EuraHS-QoL score at baseline, 1 month, 3 months and 12 months follow-up**

	Preoperatively (N=95)	1 month (N=100)	3 months (N=89)	12 months (N=98)
<b>Total score</b> /90				
Mean	23.17	13.44	5.65	2.26
Median (IR)	20.2 (11.0 to 31.5)	10.7 (4.5 to 20.0)	3.0 (1.0 to 9.0)	1.0 (0.0 to 3.0)
<b>Pain domain</b> /30				
Mean	7.01	4.49	2.21	0.76
Median (IR)	5.0 (2.0 to 11.0)	3.5 (1.5 to 6.0)	1.0 (0.0 to 4.0)	0.0 (0.0 to 0.0)
<b>Restriction of activity</b> /40				
Mean	10.98	7.00	2.45	0.83
Median (IR)	8.0 (4.0 to 18.0)	4.7 (1.0 to 10.8)	1.0 (0.0 to 4.0)	0.0 (0.0 to 1.0)
<b>Cosmetic</b> /20				
Mean	5.44	1.95	0.99	0.66
Median (IR)	4.0 (2.0 to 8.0)	1.0 (0.0 to 3.0)	0.0 (0.0 to 2.0)	0.0 (0.0 to 1.0)

P-values according to a linear mixed modeling with unstructured covariance structure (time-effect): total score  $P<0.0001$ ; pain score  $P<0.0001$ ; restriction of activity score  $P<0.0001$ ; cosmetic score  $P<0.0001$

IR=Interquartile range; N=number of patients at follow-up

## Discussion

### Key results

The placement of one large self-fixating mesh in the preperitoneal plane in front of the bladder during laparoscopic repair of bilateral hernias did not produce urinary symptoms, either in the short term, nor at 12 months follow-up. There was a significant improvement at 12 months in voiding symptoms, the voiding bother score, the incontinence bother score and the nocturia bother score.

### Limitations

The ICIQ-MLUTS is designed for follow-up of patients with urinary pathology and was not designed specifically for hernia patients. Nevertheless, we found it to be an interesting tool to investigate our concerns about the potential impact of a preperitoneal mesh on urinary symptoms. No description or recommendation on how to analyze the results of the ICIQ-MLUTS data is available in current literature, therefore the methodology for the analysis was suggested by an independent statistician.

## **Interpretation**

Placement of a mesh in the preperitoneal position during laparoscopic groin hernia repair might raise concerns about the development of urinary symptoms because of the position of the mesh in front of the bladder. Our study suggests that these concerns may be unwarranted, even when using one large self-fixating mesh for bilateral repairs.

Others have reported the use of one mesh to cover both groins during laparoscopic groin hernia repair<sup>11-15</sup>. It seems that the configuration of the mesh and the size of the mesh is important, since Köhler et al. have found recurrences in 5.6% (2/36) at 12 months, likely related to the mesh configuration with a slit in the middle on the cranial part of the mesh<sup>15</sup>. The configuration of the mesh used in this study, as shown in Figure 1, is similar to the mesh configuration suggested as most effective by Knook et al, which they called the "slipmesh"<sup>13</sup>. They found a high recurrence rate in a rectangular mesh configuration with a width of 30 cm and a length of 10 cm in a first series of 17 patients (6 recurrences; 35%), which was remediated by using a "slipmesh" configuration with a width of 30 cm and a length of 15 cm in 81 patients (2 recurrences; 2.5%). Thus, it does seem important to have a mesh overlapping the pubic bone caudally for several cm to allow enough overlap of medial hernias and avoid recurrences. Halm et al. described a mesh configuration of 30x30 cm in a similar configuration with a recurrence rate of 3.7% (1/27)<sup>14</sup>. They did not find a difference with a group of patients receiving two separate meshes, who had a recurrence rate of 3.5% (3/86). We did not detect any recurrence at 12 months by clinical examination. This suggests that the 1-year recurrence rate is low. We have sporadically observed recurrences after this type of bilateral groin hernia repair with one large self-fixating mesh in patients outside of this study.

Urological symptoms after groin hernia repair have not often been investigated in detail. In a prospective cohort study of 101 patients undergoing elective groin hernia repair (67 open and 34 laparoscopic) the American Urological Association Symptom Score (AUASS) was used to document the impact of groin hernia repair on LUTS<sup>23</sup>. When compared to preoperative values, a reduction in urinary symptoms was seen 30 days postoperatively, provided no intra-operative catheter was used. Reis et al. compared the presence of LUTS in patients with a groin hernia (n=32) to patients without a groin hernia (n=20) using the International Prostate Symptom Score (IPSS)<sup>24</sup>. Higher scores were seen in patients with a groin hernia. Looking for a patient reported outcome score to use in our prospective study, we chose the ICIQ-MLUTS score that has been extensively investigated and used in the urological literature<sup>20-22</sup>. We have found the questionnaire to be user friendly and believe that it addresses our concerns on the use of a large



preperitoneal mesh in front of the bladder. We were pleased to note that there did not seem to be any negative impact of the bilateral groin hernia repair when evaluating urological symptoms with this questionnaire. Moreover, we did detect some improvement at 12 months compared with preoperative assessment. The presence of a groin hernia is known to have an impact on LUTS<sup>23</sup>. Our data suggests that the treatment of the groin hernias might alleviate some of these LUTS. We were unable to identify any literature on the outcome of the ICIQ-MLUTS in a normal population without groin hernias or urological pathology, which could have been used for baseline comparison.

Similar to our previously published study on unilateral groin hernia repair with a self-fixating mesh, this study demonstrated improvement of pain, restriction of activity and cosmetic concerns by treating the hernias<sup>16</sup>. At 12 months, there were no patients who reported a score higher than 5/10 for any of the nine questions of the EuraHS-QoL questionnaire. We believe that this study supports the value of the EuraHS-QoL questionnaire as a useful tool for patient reported outcome measurement before and after groin hernia repair.

### **Generalizability**

Our study suggests that urological symptoms are not produced by placing a mesh in the preperitoneal position during laparoscopic groin hernia repair with a self-fixating mesh. This finding is probably also valid with the use of other meshes where no penetrating fixation is used. This may not be valid when mesh is fixed to the pubic bone.

### **Conclusion**

The laparoscopic treatment of bilateral groin hernias with the placement of one large self-fixating mesh in the preperitoneal plane did not produce temporary or more permanent urological symptoms. This technique has demonstrated favorable 12-months results with a low recurrence rate and without significant chronic pain.

## Funding

This study is investigator initiated and was funded with a research grant from the Committee for Innovation of Maria Middelaers Hospital (Gent, Belgium). The authors report no other personal conflict of interest in relation to this study.

## References

1. Simons M, Aufenacker T, Bay-Nielsen M, Bouillot J, Campanelli G, Conze J et al. European Hernia Society guidelines on the treatment of inguinal hernia in adult patients. *Hernia* 2009; 13: 343–403.
2. Miserez M, Peeters E, Aufenacker T, Bouillot J, Campanelli G, Conze J et al. Update with level 1 studies of the European Hernia Society guidelines on the treatment of inguinal hernia in adult patients. *Hernia* 2014; 18: 151-63.
3. Herniasurge group. International guidelines for groin hernia management. *Hernia* 2018; 22: 1-165.
4. Bittner R, Montgomery M, Arregui E, Bansal V, Bingener J, Bisgaard T et al. Update of guidelines on laparoscopic (TAPP) and endoscopic (TEP) treatment of inguinal hernia (International Endohernia Society). *Surg Endosc* 2015; 29: 289-321.
5. Köckerling F, Bittner R, Jacob D, Seidelmann L, Keller T, Adolf D et al. TEP versus TAPP: comparison of the perioperative outcome in 17,587 patients with a primary unilateral inguinal hernia. *Surg Endosc* 2015; 29: 3750-60.
6. Kaul A, Hutfless S, Le H, Hamed S, Tymitz K, Nguyen H et al. Staple versus fibrin glue fixation in laparoscopic total extraperitoneal repair of inguinal hernia: a systematic review and meta-analysis. *Surg Endosc* 2012; 26: 1269–78.
7. Antoniou S, Köhler G, Antoniou G, Muysoms F, Pointner R, Granderath F. Meta-analysis of randomized trials comparing nonpenetrating vs mechanical mesh fixation in laparoscopic inguinal hernia repair. *Am J Surg* 2016; 211: 239-49.
8. Poelman M, van den Heuvel B, Deelder J, Abis G, Beudeker N, Bittner R et al. EAES Consensus Development Conference on endoscopic repair of groin hernias. *Surg Endosc* 2013; 27: 3505–19.
9. Stoppa R, Petit J, Abourachid H, Henry X, Duclaye C, Monchaux G et al. [Original procedure of groin hernia repair: interposition without fixation of Dacron tulle

- prosthesis by subperitoneal median approach]. *Ann Chir* 1973; 99: 199-223. [Article in French]
10. Wantz G. Giant prosthetic reinforcement of the visceral sac. The Stoppa groin hernia repair. *Surg Clin North Am* 1998; 78: 1075-87.
  11. Geis W, Malago M. Laparoscopic bilateral inguinal herniorrhaphies: use of a single giant preperitoneal mesh patch. *Am Surg* 1994; 60: 558-63.
  12. Deans G, Wilson M, Royston C, Brough W. Laparoscopic 'bikini mesh' repair of bilateral inguinal hernia. *Br J Surg* 1995; 82: 1383-5.
  13. Knook M, Weidema W, Stassen L, Boelhouwer R, Van Steensel C. Endoscopic totally extraperitoneal repair of bilateral inguinal hernias. *Br J Surg* 1999; 86: 1312-6.
  14. Halm J, Heisterkamp J, Boelhouwer R, den Hoed P, Weidema W. Totally extraperitoneal repair for bilateral inguinal hernia: does mesh configuration matter? *Surg Endosc* 2005; 19: 1373-6.
  15. Köhler G, Fischer I, Kaltenböck R, Mitteregger M, Seitinger G, Szyszkowicz A. Critical evaluation of an innovative mesh for bilateral transabdominal preperitoneal (TAPP) repair of inguinal hernias. *Hernia* 2018; 22: 857-62.
  16. Muysoms F, Vanlander A, Ceulemans R, Kyle-Leinhase I, Michiels M, Jacobs I et al. A prospective, multicenter, observational study on quality of life after laparoscopic inguinal hernia repair with ProGrip laparoscopic, self-fixating mesh according to the European Registry for Abdominal Wall Hernias Quality of Life Instrument. *Surgery* 2016; 160: 1344-57.
  17. Daes J, Felix E. Critical View of the Myopectineal Orifice. *Ann Surg* 2017; 266: e1-e2.
  18. Muysoms F, Campanelli G, Champault G, DeBeaux A, Dietz U, Jeekel J et al. EuraHS: the development of an international online platform for registration and outcome measurement of ventral abdominal wall hernia repair. *Hernia* 2012; 16: 239-50.
  19. Miserez M, Alexandre J, Campanelli G, Corcione F, Cuccurullo D, Pascual M et al. The European Hernia society groin hernia classification: simple and easy to remember. *Hernia* 2007; 11: 113-6.
  20. Abrams P, Avery K, Gardener R, Donovan J, ICIQ Advisory Board (2006) The International Consultation on Incontinence modular Questionnaire: [www.iciq.net](http://www.iciq.net). *J Urol* 175: 1063-6.

21. Coyne K, Kelleher C. Patient reported outcomes: the ICIQ and the state of the art. *Neurourol Urodyn* 2010; 29: 645–51.
22. Donovan J, Bosch R, Gotoh M, Jackson S, Naughton M, Radley S. Symptom and quality of life assessment. Proceedings of the 3rd International Consultation on Incontinence, Monaco 2004. Available at: <https://www.ics.org/> Accessed June 1, 2018.
23. Reed R, Poston T, Kerby J, Richman J, Colli J, Hawn M. Effect of elective inguinal hernia repair on urinary symptom burden in men. *Am J Surg* 2014; 208: 180-6.
24. Reis R, Rodrigues Neto A, Reis L, Machado R, Kaplan S. Correlation between the presence of inguinal hernia and the intensity of lower urinary tract symptoms. *Acta Cir Bras* 2011; 26: 125-8.



# Chapter 3

## Robotic-assisted laparoscopic inguinal hernia repair after previous transabdominal prostatectomy

Maxime Dewulf

Lore Aspeslagh

Femke Nachtergaele

Pieter Pletinckx

Filip Muysoms

*Surgical Endoscopy* 2022; 36(3): 2105-12.

## Abstract

**Background.** Transabdominal prostatectomy results in scarring of the retropubic space and this might complicate subsequent preperitoneal dissection and mesh placement during minimally invasive inguinal hernia repair. Therefore it is suggested that an open anterior technique should be used rather than a minimally invasive posterior technique in these patients.

**Methods.** In this single center study, a retrospective analysis of a prospectively maintained database was performed. All patients undergoing inguinal hernia repair after previous transabdominal prostatectomy were included in this analysis, and the feasibility, safety and short-term outcomes of open and robotic-assisted laparoscopic inguinal hernia repair were compared.

**Results.** From 907 inguinal hernia operations performed between March 2015 and March 2020, 45 patients met the inclusion criteria. As the number of patients treated with conventional laparoscopy was very low (n=2), their data were excluded from statistical analysis. An open anterior repair with mesh (Lichtenstein) was performed in 21 patients and a robotic-assisted laparoscopic posterior transabdominal repair (rTAPP) in 22. Patient characteristics between groups were comparable. A transurethral urinary catheter was placed during surgery in 17 patients, most often in the laparoscopic cases (15/22, 68.2%). In the rTAPP group, a higher proportion of patients was treated for a bilateral inguinal hernia (50% vs 19% in the Lichtenstein group). There were no intraoperative complications and no conversions from laparoscopy to open surgery. No statistically significant differences between both groups were observed in the outcome parameters. At 4 weeks follow-up, more patients who underwent rTAPP had an asymptomatic seroma (22.7% vs 5% in the Lichtenstein group) and 2 patients were treated postoperatively for a urinary tract infection (4.7%).

**Conclusion.** A robotic-assisted laparoscopic approach to inguinal hernia after previous transabdominal prostatectomy seems safe and feasible, and might offer specific advantages in the treatment of bilateral inguinal hernia repairs.

**Keywords.** Inguinal hernia - Groin hernia - Robotic-assisted surgery - Prostatectomy

## Introduction

With an estimated 1.1 million diagnoses worldwide in 2012, prostate cancer is one of the most common cancers in men, accounting for 15% of all cancers diagnosed in the male population. Partly due to the widespread use of prostate-specific antigen (PSA) screening, its incidence is still on the rise<sup>1,2</sup>. Surgery remains the cornerstone in its treatment, and can be performed by open retropubic radical prostatectomy (RRP), laparoscopic radical prostatectomy (LRP) or robotic-assisted laparoscopic prostatectomy (RALP). Regardless of the technique used, the surgical treatment of prostate cancer traditionally involves an extensive dissection of the retropubic space. This results in scarring of the Retzius space, which complicates subsequent minimally invasive posterior inguinal hernia repair (IHR) in the preperitoneal plane<sup>1,3,4</sup>. For this reason, current guidelines advocate an open anterior inguinal hernia repair in these patients<sup>4</sup>.

Transabdominal surgery for prostate cancer has been identified as an independent risk factor for the development of an inguinal hernia, with an estimated incidence of 15.9% after RRP, and 6.7% after LRP<sup>2,5,6</sup>. A nation-wide Swedish population study in 28,608 patients observed an almost 4-fold increase in inguinal hernia repair after radical prostatectomy<sup>7</sup>. The exact mechanism remains under debate, and probably is multifactorial<sup>8,9</sup>. Recent meta-analysis identified increasing age, low body-mass index (BMI), presence of a subclinical inguinal hernia, previous hernia repair and an anastomotic stricture as risk factors for the development of an inguinal hernia after radical prostatectomy<sup>5</sup>.

In the treatment of a primary inguinal hernia, a minimally invasive posterior repair is now suggested as the gold standard, provided a surgeon with specific expertise is available. Both a transabdominal preperitoneal (TAPP) and a totally extraperitoneal (TEP) repair involve a dissection of the preperitoneal and retropubic space, and result in a lower incidence of postoperative and chronic pain, when compared to open surgery<sup>1,4</sup>. Furthermore, these techniques offer specific advantages in the treatment of bilateral inguinal hernias, and current guidelines strongly recommend their use in case of bilateral disease<sup>4</sup>. Extensive experience in minimally invasive inguinal hernia repair, along with the introduction of robotic surgery, has led to a dramatic increase in the indications for minimally invasive abdominal wall and inguinal hernia surgery. However, evidence on laparoscopic inguinal hernia repair after previous transabdominal prostatectomy is still lacking, and only 5 patient series on the topic have been published<sup>1,3,10-13</sup>.



## **Objectives**

This study aims to investigate the safety, feasibility and short-term outcomes of a minimally invasive posterior approach in patients after previous transabdominal prostatectomy. In this retrospective analysis of a prospectively maintained database, the intraoperative characteristics and short-term outcomes of laparoscopic IHR (both conventional and robotic-assisted) are examined, and compared with open surgery in these patients.

## **Methods**

### **Setting**

This study was conducted at the surgical department of Maria Middelaers Hospital (Gent, Belgium). In a single center observational case-control design, data of a prospectively maintained database were retrospectively analyzed. Included patients were treated between March 2015 and March 2020. Surgery was performed by one surgeon with extensive experience in both open and minimally invasive IHR. The study protocol was approved by the local ethics committee on October 7<sup>th</sup> 2020, before the start of inclusions, with reference number MMS.2020.067. All patient and surgical data were prospectively entered in the EuraHS (European registry for abdominal wall hernias) database at the time of surgery and at the 4 weeks follow-up visit<sup>14</sup>. For analysis, data were extracted in an anonymized manner. Before closure of the database, data and missing values were double checked.

### **Patients**

All patients with a history of transabdominal prostatectomy scheduled to undergo uni- or bilateral IHR during the period March 1st 2015 - March 31st 2020 were eligible for inclusion. Exclusion criteria were: age under 18, inguinal hernia repair without mesh placement and open inguinal hernia repair with a technique other than Lichtenstein. All patients were scheduled for a standard clinical outpatient follow-up visit with the surgeon at 4 weeks postoperatively.

### **Surgical technique**

All operations were performed under general anesthesia. A single prophylactic dose of 2 grams of cefazoline (Cefacidal, Bristol-Myers Squibb, Braine-l'Alleud, Belgium) was

administered in case of open surgery, no prophylactic antibiotics were given in case of minimally invasive IHR. Patients were instructed to void prior to surgery, and a transurethral urinary catheter was placed during surgery in 17 patients, most often in the laparoscopic cases (15/22, 68.2%), according to the surgeon's preference. Hernia repair was performed according to the standard surgical principles, and mesh placement occurred after achieving the critical view of the myopectineal orifice (MPO) in posterior repairs<sup>15</sup>.

### *Open surgery*

In open surgery, an iodine-impregnated drape was used to cover the surgical field. Surgery was performed using a 6-cm long incision, and a standard Lichtenstein technique was used. A self-gripping monofilament polyester mesh (Parietex Progrid™ Self-Fixating Mesh, Medtronic, Minneapolis, MN, US) of 15 by 15 cm was tailored to a mesh with a slit for the cord and a width of 14 cm and a length of 9 cm. No additional sutures were used for fixation of the mesh.

### *Robotic-assisted laparoscopic IHR*

Robotic operations were performed using the daVinci Xi system (Intuitive, Sunnyvale, CA, US) with a 0° scope. Three robotic 8 mm trocars were placed on a horizontal line at the umbilicus and on both sides with 7 cm between trocars. Blind entry of the blunt first trocar at the umbilicus was performed to create the pneumoperitoneum at 12 mmHg. Self-gripping monofilament polyester mesh (Parietex Progrid™ Self-Fixating Mesh, Medtronic, Minneapolis, MN, US) was used, with a width of 16 cm and a length of 12 cm for unilateral hernias, and with a width of 28 cm and a length of 13 cm for bilateral hernias. Care was taken to properly close the peritoneum after mesh placement using a barbed suture (V-Loc™ 90, Medtronic, Minneapolis, MN, US). Three robotic instruments were used (monopolar hot shears curved scissors, fenestrated bipolar forceps, and a large needle driver).

### **Endpoints and variables**

The rate of intrahospital complications (according to the Clavien-Dindo classification) was defined as the primary endpoint<sup>16</sup>. Postoperative complications within 4 weeks after surgery (stratified as none, readmission, seroma and urinary tract infection) were defined as the secondary endpoint. Furthermore, data on duration of surgery,

intraoperative complications, intraoperative urinary catheterization, postoperative urinary retention and postoperative hospital stay (stratified as ambulatory surgery, 1 night or 2 nights postoperative stay) were collected and analyzed. For classification of inguinal hernias, the European Hernia Society classification was used<sup>17</sup>.

### ***Statistical analysis***

For descriptive data on patient demographics and outcomes, mean and median values or proportions (n/N) were calculated. Data were checked for distribution and normality using the Kolmogorov-Smirnov and Shapiro-Wilk test. P-values were calculated using the Mann-Whitney U test or the Independent Samples T-test for continuous variables and the Fisher's exact test for categorical variables. P-values  $\leq 0,05$  were considered indicating statistical significance. Data analysis was carried out using Microsoft Excel (Redmond, WE, US) and SPSS Statistics (Northcastle, NY, US). As the number of patients treated with conventional laparoscopy was very low (n=2), their data were excluded from statistical analysis.

## **Results**

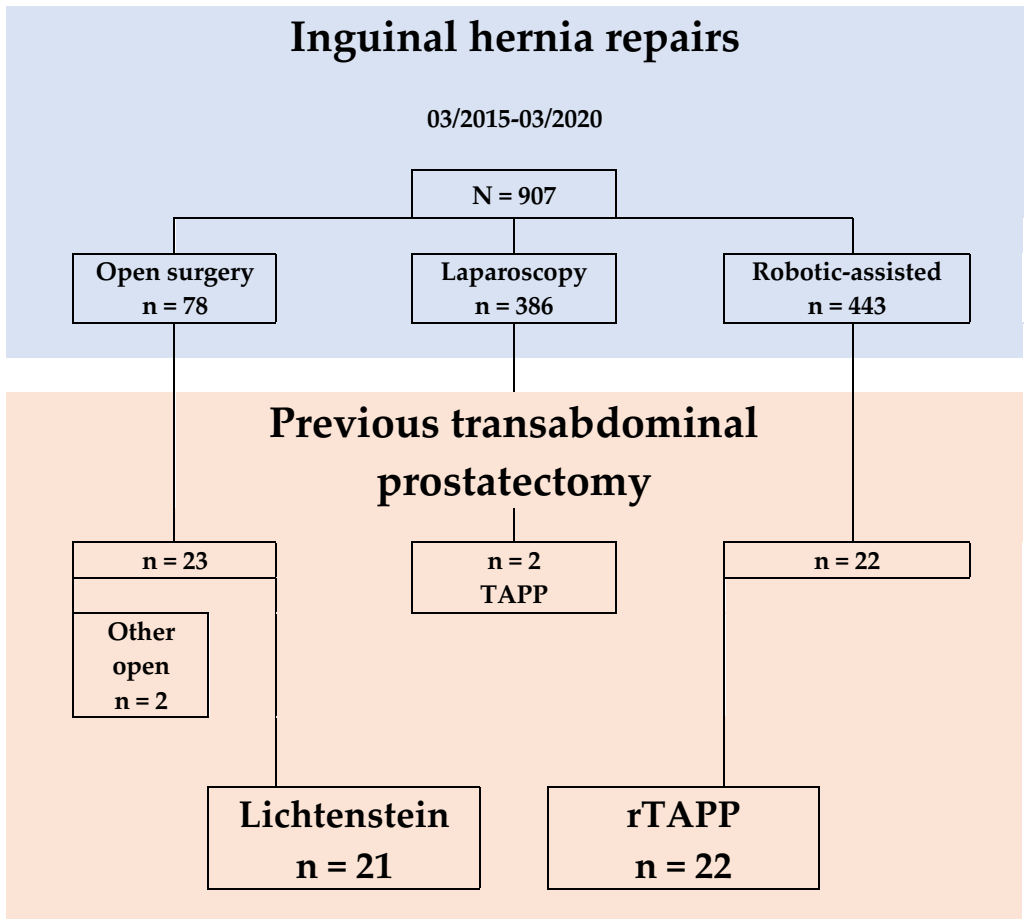
### ***Patient characteristics***

During the study period, 907 patients underwent IHR at our center. Among them, 47 patients had a history of transabdominal prostatectomy. Eventually, 43 patients met the inclusion criteria and were included for further analysis. Of the included patients, 21 were treated by open surgery, and 22 patients underwent minimally invasive IHR. A flowchart of patient numbers is depicted in Figure 1. The evolution in the technique used over time is shown in Figure 2. With the introduction of the robotic platform to our practice in September 2016, a clear evolution can be seen from open surgery towards robotic-assisted laparoscopic surgery.

### ***Outcomes***

Patient characteristics and surgical data are listed in Table 1. When comparing the Lichtenstein group with the group that underwent robotic-assisted TAPP (rTAPP), baseline characteristics were similar. Regarding age, years since prostatectomy, prostatectomy technique, comorbidities and BMI, no statistically significant differences were observed. In the rTAPP group, a higher proportion of patients was treated for a bilateral inguinal hernia (50%, vs 19% in the Lichtenstein group). Three patients in the

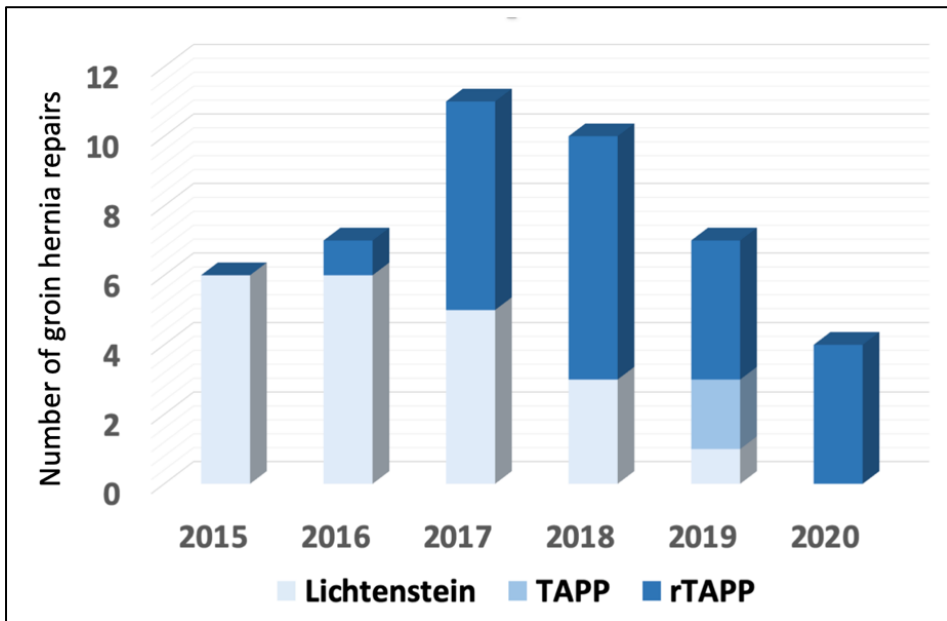
rTAPP group and 2 patients in the Lichtenstein group underwent previous IHR. Three patients with a femoral hernia after previous prostatectomy were all treated by minimally invasive approach. One patient underwent emergency surgery, and was treated with open surgery.



**Figure 1** - Flow chart for patients included in the analysis

TAPP=laparoscopic transabdominal preperitoneal inguinal hernia repair;  
rTAPP=robotic-assisted transabdominal preperitoneal inguinal hernia repair

Outcome data are listed in Table 2. Regarding intraoperative characteristics, both overall operative times and duration of surgery in unilateral hernias were significantly longer in the rTAPP group. This difference was no longer statistically significant in case of bilateral repair. There were no intraoperative complications and no conversions from laparoscopy to open surgery. A transurethral urinary catheter was placed during surgery in 17 patients, most often in the laparoscopic cases (15/22, 68.2%).



**Figure 2** - Evolution in inguinal hernia repair technique after prostatectomy  
 TAPP=laparoscopic transabdominal preperitoneal inguinal hernia repair;  
 rTAPP=robotic-assisted transabdominal preperitoneal inguinal hernia repair

No statistically significant differences between both groups were observed in the outcome parameters. Mean hospital stay in days was 1.1 (SD 0.7) for the open group and 1.0 (SD 0.8) for the laparoscopic group. Eighty-six percent of the patients were treated ambulatory or with one night stay. Urinary retention requiring catheterization in 1 patient was the only complication noted during hospitalization. One patient from the Lichtenstein group was readmitted due to diverticular bleeding.

At 4 weeks follow-up, more patients who underwent rTAPP had an asymptomatic seroma (22.7% vs 5.0% in the Lichtenstein group) and 2 patients were treated postoperatively for a urinary tract infection (4.7%).

**Table 1 - Baseline characteristics**

	Lichtenstein (N=21)	rTAPP (N=22)	p-value
<b>Age at time of surgery (years)</b>	73.6 (72.0)	73.8 (75.4)	0.304 <sup>a</sup>
<b>Years since prostatectomy</b>	5.6 (4.0)	7.7 (7.5)	0.212 <sup>b</sup>
<b>Prostatectomy approach</b>			1.000 <sup>c</sup>
Open prostatectomy	57.1% (12/21)	54.5% (12/22)	
Robotic-assisted prostatectomy	42.9% (9/21)	45.5% (10/22)	
<b>Hernia side</b>			
Bilateral	19.0% (4/21)	50.0% (11/22)	0.055 <sup>c</sup>
Left side	47.6% (10/21)	27.3% (6/22)	0.215 <sup>c</sup>
Right side	33.3% (7/21)	22.7% (5/22)	0.510 <sup>c</sup>
<b>EHS Hernia classification</b>			
Hernia size			
1	14.3% (3/21)	-	0.108 <sup>c</sup>
2	57.1% (12/21)	68.2% (15/22)	0.537 <sup>c</sup>
3	28.6% (6/21)	31.8% (7/22)	1.000 <sup>c</sup>
Hernia location			
Medial	33.3% (7/21)	45.5% (10/22)	0.537 <sup>c</sup>
Lateral	81.0% (17/21)	81.8% (18/22)	1.000 <sup>c</sup>
Femoral	-	13.6% (3/22)	0.233 <sup>c</sup>
<b>Recurrent hernia</b>	9.5% (2/21)	13.6% (3/22)	1.000 <sup>c</sup>
<b>Emergency surgery</b>	4.8% (1/21)	-	0.488 <sup>c</sup>
<b>Comorbidities</b>			
Anticoagulation	52.4% (11/21)	36.4% (8/22)	0.364 <sup>c</sup>
Previous hernia surgery	33.3% (7/21)	27.3% (6/22)	0.747 <sup>c</sup>
Smoker	-	13.6% (3/22)	0.233 <sup>c</sup>
<b>Body Mass Index (kg/m<sup>2</sup>)</b>			
< 25	57.1% (12/21)	63.6% (14/22)	0.760 <sup>c</sup>
25-30	28.6% (6/21)	36.4% (8/22)	0.747 <sup>c</sup>
≥ 30	14.3% (3/21)	-	0.108 <sup>c</sup>

Numbers are reported as proportions (%(n/N)) or mean (median)

<sup>a</sup>Difference between the two groups according to Independent Samples T-test

<sup>b</sup>Difference between the two groups according to Mann-Whitney U Test

<sup>c</sup>Difference between the two groups according to Fisher's Exact Test

rTAPP=robotic-assisted transabdominal preperitoneal inguinal hernia repair;

EHS=European Hernia Society

**Table 2 - Clinical outcome data**

	Lichtenstein (N= 21)	rTAPP (N= 22)	p-value <sup>a</sup>
<b>Duration of surgery (min)</b>			
Overall	43.2 (41.0)	78.7 (65.5)	<0.0001
Unilateral hernia	39.6 (35.0)	69.5 (64.0)	<0.0001
Bilateral hernias	58.5 (55.0)	87.8 (83.0)	0.078
<b>Intraoperative complications</b>	-	-	
<b>Perioperative urinary catheter</b>	9.5% (2)	68.2% (15)	<0.0001
<b>Intrahospital complications<sup>b</sup></b>			1.000
None	100% (21)	95.5% (21)	
Grade I-IIIa	-	4.5% (1)	
Grade IIIb-V	-	-	
<b>Postoperative urinary retention</b>	-	4.5% (1)	1.000
<b>Postoperative hospital stay</b>			
Ambulatory surgery	14.3% (3)	27.3% (6)	0.457
1 night	66.7% (14)	59.1% (13)	0.755
≥ 2 nights	19.0% (4)	13.6% (3)	0.698
<b>Postoperative complications<sup>c</sup></b>			
None	85.0% (17)	72.7% (16)	0.460
Readmission	5.0% (1) <sup>d</sup>	-	0.476
Seroma	5.0% (1)	22.7% (5)	0.187
Urinary tract infection	5.0% (1)	4.5% (1)	1.000
<b>Cases lost to follow-up</b>	4.8% (1)	-	0.488

Numbers are reported as proportions (%(n/N)) or mean (median)

<sup>a</sup> Difference between the two groups according to Fisher's exact test or Mann-Whitney U test

<sup>b</sup> According to the Clavien-Dindo classification

<sup>c</sup> During a follow-up period of 4 weeks

<sup>d</sup> Reason for readmission: diverticular bleeding

rTAPP=robotic-assisted transabdominal preperitoneal inguinal hernia repair

## Discussion

### Main results

No intraoperative complications or conversions were observed in our study. Operative times were significantly longer in the group treated with minimally invasive surgery when compared to open surgery. This observation seems to fade in case of bilateral hernia repair. Not surprisingly, these operative times are also considerably longer than duration of surgery by rTAPP in primary IHR in our center, even at the beginning of an observed learning curve<sup>18</sup>.

In this patient series, overall postoperative outcomes in open and robotic-assisted laparoscopic IHR after transabdominal prostatectomy are comparable. Although not statistically significant, there was a higher rate of seroma formation in the rTAPP group 4 weeks postoperatively (22.7%). This percentage of seroma formation is slightly higher when compared to IHR by rTAPP at our center in primary inguinal hernias (15%)<sup>19</sup>. We do not routinely plicate the hernia sac in minimally invasive surgery to reduce this 'dead space'. On the contrary, we do have a habit of resection and ligation of the hernia sac during open surgery, which could partly explain this difference in seroma formation. These findings suggest that a robotic-assisted IHR in these patients is safe and feasible.

### **Interpretation**

This is the first study to compare minimally invasive surgery to open surgery in IHR after transabdominal prostatectomy. To date, there are only 3 prospective and 2 retrospective patient series available on the topic<sup>1</sup>. Three of them use a control group of patients who did not have prostate surgery<sup>3,11,12</sup> and 2 of them have an uncontrolled design<sup>10,13</sup>. Besides design, there is large heterogeneity among them regarding sample size, applied technique and prostatectomy approach. The largest currently available study was published by the group of Reinhard Bittner in 2009, and reported on favourable results of TAPP after radical prostatectomy in 214 patients<sup>3</sup>. In the study of Sakon et al., no dissection of the retropubic space was performed and only patients with indirect hernias were included<sup>13</sup>. By avoiding this medial dissection, no critical view of the MPO was obtained before mesh placement, which highly complicates interpretation of their results and limits extrapolation to patients with direct hernias<sup>13,19</sup>. Generally, our observations are consistent with currently available literature.

Because of comparable outcomes between bilateral and unilateral IHR in laparoscopic surgery, and the possibility to perform a bilateral repair without the need for additional incisions, current guidelines strongly recommend minimally invasive surgery in case of bilateral primary inguinal hernias<sup>4,20</sup>. In our study, more patients with bilateral disease were treated by rTAPP, and although still longer, the difference in operative times was no longer statistically significant in patients who underwent bilateral IHR. In 4 patients who were preoperatively diagnosed with a unilateral inguinal hernia, the intraoperative diagnosis of a bilateral inguinal hernia was made and a bilateral repair was performed. This partially explains the higher rate of bilateral repairs in the rTAPP group, and highlights another advantage of the minimally invasive transabdominal approach. Furthermore, we believe that there is benefit in visualization and prelevation of lymph nodes along the iliac vessels during minimally invasive inguinal hernia repair in this



patient group. Most patients underwent prostatectomy for oncological reasons, and despite good follow-up and staging before the surgical treatment of an inguinal hernia, often enlarged lymph nodes are encountered during surgery. We have a habit of sending them for pathological examination, which could add information on their oncological situation. These observations, along with comparable complication rates between rTAPP and Lichtenstein, advocate the use of minimally invasive surgery, especially in patients with bilateral inguinal hernias or when there is doubt about the diagnosis of a contralateral inguinal hernia.

Regarding the increased incidence of inguinal hernia after prostatectomy, it is generally assumed that the exposure of the retropubic space results in damaging transversalis fascia, the posterior layer of the rectus sheath and the endopelvic fascia, thereby disrupting the integrity of the posterior wall of the inguinal canal. Furthermore, stretching of Hesselbach's ligament contributes to a decrease in strength of the internal ring<sup>2,8,9</sup>. Minimally invasive and Retzius-sparing techniques seem to decrease the risk of an inguinal hernia by minimizing damage to the region of the myopectineal orifice (MPO)<sup>6,9,21</sup>. Several prophylactic measures have been proposed to minimize the risk of inguinal hernia after transabdominal prostatectomy, including a ligation and transection of the processus vaginalis, blunt dissection of the peritoneum close to the internal ring with an isolation of the spermatic cord or the placement of additional stitches to close the internal ring<sup>6,22-24</sup>. Finley et al. reported on a concomitant repair of an inguinal hernia during RALP using prosthetic mesh in 36 patients<sup>25</sup>, whereas Lee et al. proposed a technique using plugs of hemostatic agents to repair incidentally found inguinal hernias during prostatectomy<sup>26</sup>. Given the high incidence of inguinal hernia after prostatectomy there is a need for further research on this topic to confirm effectiveness of available techniques. Thereby, continued awareness of this specific problem among urologists is needed to further minimize these numbers.

### **Limitations**

Besides the retrospective design, this study has several limitations. First, the choice of the surgical technique was not randomized, and highly dependent on the preference of the surgeon. One could presume that patient characteristics and BMI influenced the choice of the surgical technique, although BMI and comorbidities were comparable between groups.

Second, the length of follow-up in our study is limited to 4 weeks, as this comprises the standard follow-up in our center after IHR. One of the main advantages of minimally

invasive IHR over open surgery is a reduction in postoperative and chronic pain<sup>1,4</sup>. Due to the retrospective design of this study and the subsequent short follow-up, no data on the topic are available.

Third, minimally invasive surgery in this study was performed robotic-assisted. Currently, rTAPP is not a widespread practice in Europe, mainly due to cost-effectiveness and logistic issues. As observed in Figure 2, it is the availability of the robotic platform that caused a shift in our practice from open to laparoscopic surgery. This implicates the introduction of the robot to our practice during the inclusion period. Obviously, this also implicates a learning curve during the inclusion period of this study, although no intraoperative complications or conversion were observed. Whether our observations in robotic surgery, performed by surgeons with extensive experience in abdominal wall and robotic-assisted surgery, can be extrapolated to conventional laparoscopy is unclear.

### ***Indications for future research***

As mentioned above, evidence for minimally invasive IHR after transabdominal prostatectomy is scarce and of limited quality, and current guidelines still advocate open surgery in these patients. This stresses the need for prospective studies with a randomization for the surgical technique. Furthermore, outcome parameters indicating quality of life during a longer follow-up period are paramount to conclusively show an advantage of minimally invasive surgery. Along with the need for future studies on rTAPP in these patients, further evidence on conventional laparoscopic techniques is highly warranted.

### **Conclusion**

A robotic-assisted laparoscopic approach to inguinal hernia after previous transabdominal prostatectomy seems safe and feasible, and might offer specific advantages in the treatment of bilateral inguinal hernia repairs.

## Funding

The study is investigator initiated and received funding from a 'Medical writing support agreement for research' from Intuitive Surgical and the Maria Middelaers committee for innovation. The company, Intuitive Surgical, was not involved in the initiation, conduction, analysis or publication of the study.

## References

1. La Regina D, Gaffuri P, Ceppi M, Saporito A, Ferrari M, Di Giuseppe M et al. Safety, feasibility and clinical outcome of minimally invasive inguinal hernia repair in patients with previous radical prostatectomy: A systematic review of the literature. *J Minim Access Surg* 2019;15(4): 281-86.
2. Liu L, Xu H, Qi F, Wang S, Shadhu K, Ramlagun-Mungur D, Wang S. Incidence and risk factors of inguinal hernia occurred after radical prostatectomy – comparisons of different approaches. *BMC Surgery* 2020; 20: 218-25.
3. Wauschkuhn C, Schwarz J, Bittner R. Laparoscopic transperitoneal inguinal hernia repair (TAPP) after radical prostatectomy: is it safe? Results of prospectively collected data of more than 200 cases. *Surg Endosc* 2009; 23(5): 973-7.
4. International guidelines for groin hernia management. The HerniaSurge Group. *Hernia* 2018; 22(1): 1-165.
5. Zhu S, Zhang H, Xie L, Chen J, Niu Y. Risk factors and prevention of inguinal hernia after radical prostatectomy: a systematic review and meta-analysis. *J Urol* 2013; 189: 884-90.
6. Iwamoto Y, Morizane S, Hikita K, Honda M, Takenaka A. Postoperative inguinal hernia after robotic-assisted radical prostatectomy for prostate cancer: evaluation of risk factors and recommendation of a convenient prophylactic procedure. *Cent European J Urol* 2019; 72: 418-24.
7. Nilsson H, Stranne J, Stattin P, Nordin P. Incidence of groin hernia repair after radical prostatectomy. *Ann Surg* 2014; 259: 1223-7.
8. Nomura T, Mimata H, Kitamura H, Fujikura Y, Akita Y, Yamasaki M et al. Lower incidence of inguinal hernia: minilaparotomy radical retropubic prostatectomy compared with conventional technique. A preliminary report. *Urol Int* 2005; 74: 32-7.

9. Chang K, Abdel Raheem A, Santok G, Kim L, Lum T, Lee S et al. Anatomical Retzius-space preservation is associated with lower incidence of postoperative inguinal hernia development after robot-assisted radical prostatectomy. *Hernia* 2017; 21: 555-61.
10. Claus C, Coelho J, Campos A, Filho A, Loureiro M, Dimbarre D et al. Laparoscopic inguinal hernioplasty after radical prostatectomy: is it safe? Prospective clinical trial. *Hernia* 2014; 18(2): 255-9.
11. Dulucq J-L, Wintringer P, Mahajna. Totally extraperitoneal (TEP) hernia repair after radical prostatectomy or previous lower abdominal surgery: is it safe? A prospective study. *Surg Endosc* 2006; 20(3): 473-6.
12. Le Page P, Smialkowski A, Morton J, Fenton-Lee D. Totally extraperitoneal inguinal hernia repair in patients previously having prostatectomy is feasible, safe, and effective. *Surg Endosc* 2013; 27(12): 4485-90.
13. Sakon M, Sekino Y, Okada M, Seki H, Munakata Y. Laparoscopic inguinal hernioplasty after robot-assisted laparoscopic radical prostatectomy. *Hernia* 2017; 21: 745-8.
14. Muysoms F, Campanelli G, Champault G, DeBeaux A, Dietz U, Jeekel J et al. EuraHS: the development of an international online platform for registration and outcome measurement of ventral abdominal wall hernia repair. *Hernia* 2012; 16: 239-50.
15. Daes J, Felix E. Critical View of the Myopectineal Orifice. *Ann Surg* 2017; 266: e1-e2.
16. Dindo D, Demartines N, Clavien P-A. Classification of surgical complications. A new proposal with evaluation in a cohort of 6336 patients and results of a survey. *Ann Surg* 2004; 240(2): 205-13.
17. Miserez M, Alexandre J, Campanelli G, Corcione F, Cuccurullo D, Pascual M et al. The European Hernia society groin hernia classification: simple and easy to remember. *Hernia* 2007; 11: 113-16.
18. Muysoms F, Van Cleven S, Kyle-Leinhase I, Ballecer C, Ramaswamy A. Robotic-assisted laparoscopic groin hernia repair: observational case-control study on the operative time during the learning curve. *Surg Endosc* 2018; 32: 4850-9.
19. Bittner R. Invited comment to: Laparoscopic inguinal hernioplasty after robot-assisted laparoscopic radical prostatectomy. Sakon M, Sekino Y, Okada M, Seki H, Munakata Y. *Hernia* 2017; 21: 987-8.

20. Feliu X, Clavería R, Besora P, Camps J, Fernández-Sallent E, Viñas X et al. Bilateral inguinal hernia repair: laparoscopic or open approach? *Hernia* 2011; 15(1): 15–8.
21. Jiang Y, Zheng G, Jiang Z, Li Z, Zhou X, Zhou J et al. Comparison of Retzius-sparing robot-assisted laparoscopic radical prostatectomy vs standard robot-assisted radical prostatectomy: a meta-analysis. *BMC Urology* 2020; 20: 114.
22. Stranne J, Aus G, Bergdahl S, Damber J, Hugosson J, Kathami A et al. Post-radical prostatectomy inguinal hernia: a simple surgical intervention can substantially reduce the incidence – results from a prospective randomized trial. *J Urol* 2010; 184: 984-9.
23. Fuji Y, Yamamoto S, Yonese J, Kawakami S, Suyama T, Komai Y et al. A novel technique to prevent postradicalretropubic prostatectomy inguinal hernia: the processus vaginalis transection method. *Urology* 2010; 75: 713-7.
24. Sakai Y, Okuno T, Kijima T, Iwai A, Matsuoka Y, Kawakami S et al. Simple ProPIHylactic procedure of inguinal hernia after radical retropubic prostatectomy: isolation of the spermatic cord. *Int J Urol* 2009; 16: 848-51.
25. Finley D, Rodriguez E, Ahlering T. Combined inguinal hernia repair with prosthetic mesh during transperitoneal robot assisted laparoscopic radical prostatectomy: a 4-year experience. *J Urol* 2007; 178: 1296-9.
26. Lee D, Montgomery D, Porter J. Concurrent transperitoneal repair for incidentally detected inguinal hernias during robotically assisted radical prostatectomy. *Urology* 2013; 82: 1320-2.





## **Part II**

Ileal conduit parastomal hernia





# Chapter 4

## Parastomal hernias after cystectomy and ileal conduit urinary diversion: surgical treatment and the use of prophylactic mesh A systematic review

Maxime Dewulf\*

Nicole D. Hildebrand\*

Stefan A.W. Bouwense

Nicole D. Bouvy

Filip Muysoms

\*Shared first authorship

*BMC Surgery* 2022 March 29; 22(1): 118. *Epub ahead of print.*

*doi: 10.1186/s12893-022-01509-y.*

## Abstract

**Background.** Parastomal hernia after ileal conduit urinary diversion is an underestimated and undertreated clinical entity, which heavily impairs patients' quality of life due to symptoms of pain, leakage, application or skin problems. As for all gastrointestinal stomata the best surgical repair technique has yet to be determined. Thereby, surgery for ileal conduit parastomal hernias poses some specific perioperative challenges. This review aims to give an overview of current evidence on the surgical treatment of parastomal hernia after cystectomy and ileal conduit urinary diversion, and on the use of prophylactic mesh at index surgery in its prevention.

**Methods.** A systematic review was performed according to PRISMA-guidelines. The electronic databases Embase, PubMed, Cochrane Library, and Web of Science were searched. Studies were included if they presented postoperative outcomes of patients undergoing surgical treatment of parastomal hernia at the ileal conduit site, irrespective of the technique used. A search was performed to identify additional studies on prophylactic mesh in the prevention of ileal conduit parastomal hernia, that were not identified by the initial search.

**Results.** Eight retrospective case-series were included for analysis, reporting different surgical techniques. If reported, highest complication rate was 45%. Recurrence rates varied highly, ranging from 0 to 80%. Notably, lower recurrence rates were reported in studies with shorter follow-up. Overall, available data suggest significant morbidity after the surgical treatment of ileal conduit parastomal hernias. Data from five conference abstracts on the matter were retrieved, and systematically reported. Regarding prophylactic mesh in the prevention of ileal conduit parastomal hernia, 5 communications were identified. All of them used keyhole mesh in a retromuscular position, and reported on favorable results in the mesh group without an increase in mesh-related complications.

**Conclusion.** Data on the surgical treatment of ileal conduit parastomal hernias and the use of prophylactic mesh in its prevention is scarce. Given the specific perioperative challenges and the paucity of reported results, more high-quality evidence is needed to determine the optimal treatment of this specific surgical problem. Initial results on the use of prophylactic mesh in the prevention of ileal conduit parastomal hernias seem promising.

**Keywords.** Parastomal hernia - Ileal conduit - Cystectomy

## Background

Radical cystectomy with ileal conduit urinary diversion remains the cornerstone of curative treatment of patients with urothelial carcinoma of the bladder<sup>1</sup>. One possible long-term postoperative complication after this type of surgery is parastomal hernia at the ileal conduit site. Parastomal hernia is defined as the protrusion of contents of the abdominal cavity through the abdominal wall, in the direct proximity of a colostomy, ileostomy or ileal conduit stoma<sup>2</sup>. Overall, the incidence of parastomal hernia at any type of stoma site after 12 months is estimated to be around 30%<sup>3</sup>. For ileal conduit urinary diversion a systematic review reported an estimated incidence of parastomal hernia of 17%<sup>4</sup>.

To date, numerous surgical techniques to treat parastomal hernia have been described, such as local suture repair, relocation of the stoma or mesh repairs (with onlay, retromuscular, preperitoneal or intraperitoneal mesh position). Regarding mesh repairs, various configurations have been proposed (Keyhole, Sugarbaker or pre-shaped meshes)<sup>5,6</sup>. Recurrence rates after parastomal hernia repair of colo- and ileostomy remain high, up to 69% after one year<sup>5-8</sup>. Evidence remains limited and is mostly based on small retrospective case series. For end colostomy, prophylactic mesh placement has proven to be an effective technique in the prevention of parastomal hernia, and has gained acceptance in recent years<sup>3</sup>.

Regarding parastomal hernia after ileal conduit urinary diversion, evidence is lacking. This type of repair poses specific perioperative challenges including stripped peritoneum below the arcuate line, short mesentery of the conduit complicating lateralization of the stoma, difficult perioperative identification of the ileal conduit loop due to longstanding collapse, concomitant midline incisional hernias and presence of ureteric anastomoses. Furthermore, evidence on prophylactic mesh in this type of surgery is limited. This stresses the need to further evaluate and optimize the surgical treatment of this specific type of parastomal hernia.

## Objectives

Until now, systematic reviews on the surgical treatment of parastomal hernias have evaluated available evidence on all types of stomas. However, as mentioned, repair of ileal conduit parastomal hernias pose specific perioperative challenges. The aim of this systematic review is to collect all current evidence on the surgical treatment of parastomal hernia after ileal conduit urinary diversion. Furthermore, available literature

on the use of prophylactic mesh in the prevention of ileal conduit parastomal hernias is collected.

## Methods

### Search strategy

This systematic review was written according to the Preferred Reporting Items for Systematic Reviews and Meta-analysis (PRISMA) guidelines<sup>9</sup>, and was registered in the International Prospective Register of Systematic Reviews (PROSPERO) database on December 16, 2020. Considering the manuscript being a literature review, there was no obligation to seek approval by the Institutional Review Board. The electronic databases MEDLINE (through PubMed), Embase, Web of Science, and Cochrane Central Register of Controlled Trials (CENTRAL) were searched for eligible articles. ClinicalTrials.gov and the International Clinical Trials Registry Platform (ICTRP) portals were searched to identify ongoing research on the matter. Combining predefined search terms and operators 'OR' and 'AND' resulted in the following search: (((((cystectomy) OR urinary diversion) OR ileal conduit) OR urostomy)) AND ((hernia) OR parastomal hernia). Search filters were not applied. The search was conducted in January 2021 and repeated in November 2021. Reference lists of reviews on the topic and included full text articles were manually screened by two reviewers (NH, MD) to identify additional sources. Abstract books of annual meetings of the European Hernia Society, European Association of Endoscopic Surgery and American Hernia Society were screened for conference abstracts.

After exclusion of duplicates, results were screened by title, abstract and subsequently evaluation of full text. When no full text was available, authors were contacted to provide additional information. When only a subset of patients was eligible for inclusion, authors were contacted to provide specific data on the subgroup. The predefined study protocol can be found in appendix 1, a detailed description of the literature search is added as appendix 2 (both available online in the original publication). To identify additional sources on the use of prophylactic mesh in the prevention of parastomal hernia that were not identified by the initial search, a new search was performed in November 2021 by adding the terms '*prophylactic mesh*' and '*prevention*' to our initial search using the operator 'OR'.

## **Study selection**

Two reviewers (NH, MD) independently screened studies according to the predefined inclusion and exclusion criteria. Studies were considered eligible if they included patients that underwent surgical treatment of parastomal hernia at the ileal conduit site. No exclusions were made based on study design, type of surgical treatment, or language. Exclusion criteria were patients younger than 18, other types of urinary diversion besides ileal conduit stoma, animal studies, and case series reporting on less than 5 patients. Studies on the use of prophylactic mesh were collected separately.

## **Outcome measurements**

Primary outcome was the incidence of postoperative complications according to Clavien-Dindo classification<sup>10</sup> within 30 days after surgery. Secondary endpoints were recurrence rates after one year, length of hospital stay, and 30-day reoperation and readmission rates. For the studies on prophylactic mesh parastomal hernia rate was defined as the primary endpoint, incidence of mesh-related complications as the secondary endpoint.

## **Data extraction**

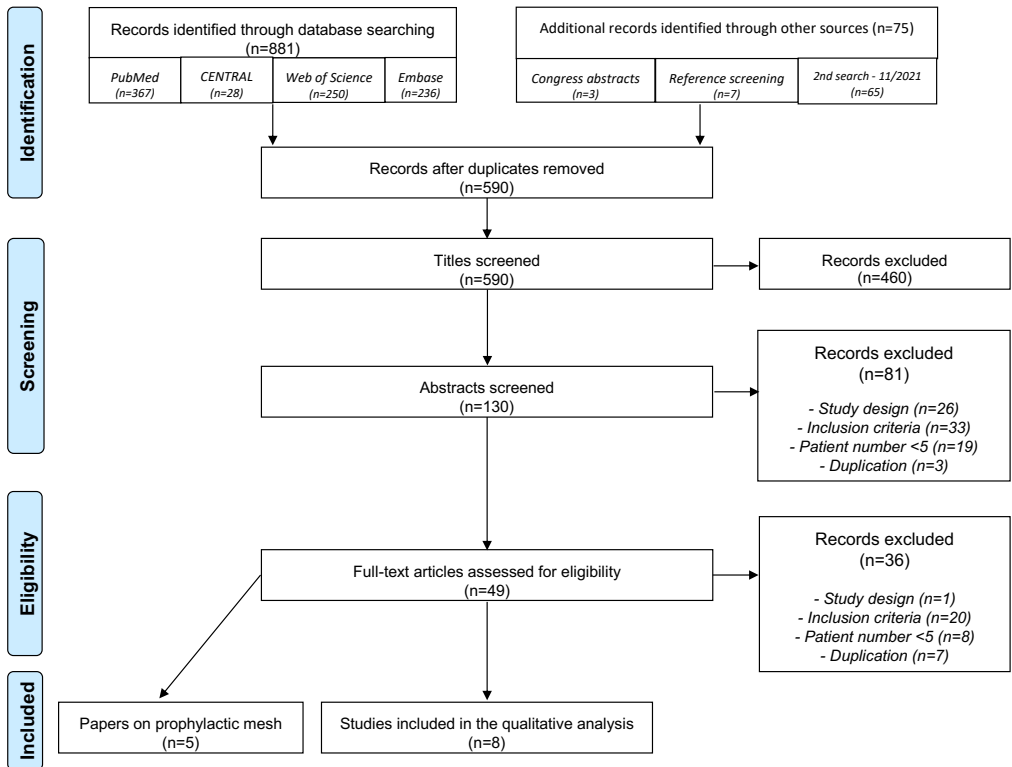
A data extraction sheet was developed using Microsoft Excel (Microsoft, Washington, USA). Data retrieved were baseline characteristics (study period, sample size, age, sex), surgical details (approach, technique, mesh position, type of mesh), perioperative data (operation time, estimated blood loss), and primary and secondary endpoints of postoperative outcomes. Given the variety of surgery techniques, a pooled analysis of results was not performed.

## **Assessment of methodological quality**

Our study protocol proposed the use of the Risk Of Bias in Non-randomized Studies - of Interventions (ROBINS-I)-tool<sup>11</sup> to assess methodological quality of included studies. However, given that none of the included studies were comparative, methodological quality was evaluated using the methodological index for non-randomized studies (MINORS)-tool<sup>12</sup>. Both reviewers (NH, MD) independently assessed the studies. Disagreement was dissolved through discussion, consultation of the senior authors was performed if necessary.

## Results

Search details and study selection are illustrated in a PRISMA flow diagram (Figure 1). Authors were contacted to provide additional data on 15 conference abstracts<sup>13-27</sup> and 9 full-text articles with subgroups of ileal conduit patients<sup>28-36</sup>. However, no additional data was available or provided. Eventually, 8 full-text articles met the inclusion criteria and were included in the qualitative analysis<sup>37-44</sup>. An overview of study characteristics, surgical details and postoperative outcomes is shown in Table 1. Details on five conference abstracts that met the inclusion criteria are depicted in Table 2<sup>23-27</sup>. Studies reporting on the use of prophylactic mesh in the prevention of ileal conduit parastomal hernia are summarized in Table 4.



**Figure 1** - PRISMA flow diagram of study selection

### ***Surgical treatment of ileal conduit parastomal hernias***

All included studies had a retrospective design. Most data comes from European<sup>25,26,37-39,45</sup> and North-American centers<sup>23,27,40-42</sup>. One conference abstract is from India<sup>24</sup>. A total of 124 patients are included in full-text articles and 46 patients in conference abstracts, with sample sizes ranging from 5 to 40.

Techniques described in the full-text papers were onlay mesh repair covering only the lateral part of the stoma (n=15)<sup>39</sup>, onlay mesh repair with a non-specified technique (n=20)<sup>44</sup>, relocation (n=38)<sup>37-41</sup>, keyhole technique (n=29)<sup>40,42,43</sup>, Sugarbaker repair (n=10)<sup>43</sup> and use of a 3D-funnel-shaped mesh (n=40)<sup>38</sup>. Additionally, in conference abstracts the keyhole-technique (n=7)<sup>27</sup>, and 3D-funnel-shaped mesh (n=13)<sup>26</sup> were presented. Two conference abstracts described their technique as 'intraperitoneal mesh' and 'laparoscopic repair', but did not further specify their technique<sup>23,25</sup>. Approaches used were predominantly open (n=137)<sup>26,37-41,43,44</sup>, laparoscopic (n=49)<sup>23,25,42-44</sup>, and robot-assisted (n=13)<sup>24,27</sup>. Mesh placement was performed in all studies, the mesh position was either onlay (n=60)<sup>39-41,44</sup> or intraperitoneally (n=99)<sup>24-27,37-39,42</sup>. Two groups did not specify the mesh position (n=39)<sup>23,43</sup>. Only synthetic, non-absorbable meshes were used. Three groups used small pore, heavy weight mesh (n=40)<sup>39-41</sup>, one used ePTFE (n=5)<sup>42</sup>, and two reported the use of large pore, light weight mesh (n=59)<sup>37,38</sup>.

Recurrence rates ranged from 0-80% in included full-text articles<sup>37-44</sup>, and from 0-22% within conference abstracts<sup>23-27</sup>. Length of follow-up varied from 12 to 55 months within full-text articles<sup>37-44</sup>, and from 90 days to 27 months for conference abstracts<sup>23-27</sup>. Follow-up, if reported, consisted of clinical examination, CT-scan or ultrasound<sup>25,26,38,40,42</sup>. Overall postoperative complications ranged from 0-45%<sup>25-27,37-39,42-44</sup>. Major complications (defined as Clavien-Dindo > II) occurred in 0-11% of the cases<sup>25,27,37-39,42-44</sup>. Length of stay in the hospital ranged from 2 to 7 days, with a maximum upper limit of 25 days<sup>23-25,27,37,39,40,42-44</sup>. Thirty-day reoperation rate was, if reported, 0-11%<sup>26,37-40,42,43</sup>. Thirty-day readmission rate was only reported within one study, where no readmissions occurred<sup>38</sup>.

### ***Prophylactic mesh in the prevention of ileal conduit parastomal hernias***

Available literature on the use of prophylactic mesh consists of 1 randomized controlled trial, 3 retrospective cohort studies, and 1 conference abstract. Our initial search identified the four published studies, additional search identified one conference abstract on the topic. All of them report on results of a retrorectus keyhole mesh. Three studies use it in open surgery, 2 of them report on robotic-assisted surgery. In none of



the reported data mesh-related complications were seen during a follow-up period between 5 months and 3 years, and favorable results regarding incidence of parastomal hernia in the mesh group were noted. In the Swedish randomized controlled trial, published by Liedberg et al. in 2020, a significant decrease in parastomal hernia rates was seen during the follow-up period of 3 years, without an increase in complications. A significant increase in operative times was noted in the patient group that was treated with prophylactic mesh at index surgery.

### **Quality assessment**

Results of the quality assessment of included full-text articles using the MINORS-tool<sup>12</sup> are shown in Table 3. Overall, the quality of evidence was poor, mainly due to the lack of prospective design, absence of study size calculation, and non-blinded assessment of results.

**Table I - Study characteristics, surgical details and postoperative outcomes of included full-text articles**

Author	Study period	Sample size	Technique	Surgical approach	Mesh position	Complication rate	C-D>II	Recurrence rate	Length of follow-up*	30-day reoperation rate
Franks 2001	NR	6	Keyhole	Open	Onlay	NR	NR	0%	26 (2-42)	0.0%
Helal 1997	1990-1996	19	Relocation	Open	Onlay	NR	NR	11.0%	23.4±15.25	NR
Ho 2004	1982-2001	15	Onlay mesh repair <sup>o</sup>	Open	Onlay	13.0%	13.0%	7.0%	15 (1-72)	13.0%
Lopez-Cano 2021	2012-2018	20	Onlay mesh repair	Open (16) Lap (4)	Onlay	45.0%	10.0%	NR	6	NR
Mäkäräinen-Uhlbäck 2021	2007-2017	18	Keyhole	Open (7) Lap (11)	NR	33.3%	11.1%	22.2%	49±34	5.6%
		10	Sugarbaker	Open (2) Lap (8)	NR	10.0%	0.0%	10.0%	27±21	0.0%
Rodriguez-Faba 2011	2000-2006	19	Relocation	Open	Intra-peritoneal	26.0%	5.0%	21.0%	55	5.0%
Safadi 2004	1998-2001	5	Keyhole	Lap	Intra-peritoneal	0.0%	0.0%	80.0%	11.6 (6-10)	0.0%
Tully 2019	2009-2015	40	Funnel-shaped mesh	Open	Intra-peritoneal	3.0%	3.0%	7.0%	29 (16-63)	0.0%

\*Reported numbers are mean±standard deviation or median (interquartile range) in months  
<sup>o</sup> a lateral approach was used, where only the lateral part of the parastomal hernia was covered with mesh  
 NR=not reported; Lap=laparoscopic

**Table 2 - Study characteristics, surgical details and postoperative outcomes of included conference abstracts**

Author	Sample size	Technique	Surgical approach	Mesh position	Complication rate	Recurrence rate	Length of follow-up*
Antor 2017	9	NR	Lap	Intraperitoneal	0.0%	22.0%	27 (7-106)
Davis 2012	11	NR	Lap	NR	NR	27.0%	19.1 (1-62)
Jaipuria 2020	6	Sugarbaker	RA	Intraperitoneal	NR	0.0%	10
Shakir 2020	7	Keyhole	RA	Intraperitoneal	29.0%	0.0%	3
Von Bodman 2012	13	Funnel-shaped mesh	Open	Intraperitoneal	31.0%	8.0%	23

\*Reported numbers are mean or median (interquartile range) in months  
NR=not reported; Lap=laparoscopic; RA=robotic-assisted

**Table 3 - Summary of MINORS-score\* for all included full-text articles**

Article	A clearly stated aim	Inclusion of consecutive patients	Prospective collection of data	Endpoints appropriate to the aim	Unbiased assessment of the study endpoint	Appropriate follow-up period	Loss to follow-up <5%	Prospective calculation of study size	Total
Franks 2001	2	0	0	1	0	2	0	0	5
Helal 1997	2	0	0	1	0	2	0	0	5
Ho 2004	2	1	1	1	0	2	0	0	7
Lopez-Cano 2021	2	1	2	2	0	2	1	0	10
Mäkäräinen-Uhlbäck 2021	2	0	0	2	0	2	1	0	7
Rodriguez-Faba 2011	2	2	1	1	0	2	0	0	8
Safadi 2004	2	1	1	1	0	2	2	0	9
Tully 2019	2	2	1	2	0	2	1	0	10

\*for each item a score of 0 (not reported), 1 (reported but inadequate), or 2 (reported and adequate) can be given. The ideal score for non-comparative studies is defined as 16  
MINORS=methodological index for non-randomized studies

**Table 4 - Study characteristics, surgical details and postoperative outcomes of literature on prophylactic mesh placement during radical cystectomy and ileal conduit urinary diversion**

Author	Study design	Sample size	Technique	Surgical approach	Mesh position	Length of follow-up	Type of follow-up	PSH rate	Complication rate	Mesh-related complications
Donahue 2016	RS	33	Keyhole	Open	Retrorectus	297 days	Clinical + CT	Clin: 3.0% CT: 18.2%	NR	None
Liedberg 2020	RCT	C:124 M:118	Keyhole	Open	Retrorectus	3 years	Clinical + CT	C: 29.3% M: 10.2%	C: 41.5% M: 43.1%	NR
Styrke 2015	RS	58	Keyhole	Open	Retrorectus	32 months	Clinical + CT	14.0%	NR	None
Tenzel 2018	RS	C: 20 M: 18	Keyhole	RA	Retrorectus	C: 21months M: 11months	CT	C: 5.0% M:0.0%	NR	None
Jian 2021 (CA)	RS	38	Keyhole	RA	Retrorectus	5 months	CT	5.0%	NR	None

PSH=parastomal hernia; CA=conference abstract; RS=retrospective; RCT=randomized controlled trial; C=control group; M=mesh group; RA=robotic-assisted; CT=computed tomography; NR=not reported

## Discussion

Numerous techniques have been proposed in the surgical treatment of parastomal hernias<sup>3,5,6</sup>. These can be grouped into local suture repairs, relocation of the stoma or mesh-based repairs. For mesh placement different anatomical positions can be used, being onlay, retromuscular, or intraperitoneal. Thereby, various configurations of the mesh in relation to the stoma have been presented, such as keyhole (stoma going through the mesh), Sugarbaker (lateralizing the stomal loop using an intraperitoneal mesh), or retromuscular Sugarbaker (lateralizing the stomal loop in the retromuscular plane)<sup>3</sup>. Surgical approach can be grouped into open, laparoscopic or robotic-assisted. Despite this variety of surgical techniques recurrence rates after parastomal hernia repair for colo- and ileostomy patients remain high, with rates of up to 69%<sup>5-8</sup>.

### **Main results**

Two studies reported their results on relocation for ileal conduit parastomal hernia treatment<sup>37,41</sup>. Intraperitoneal mesh was used at the previous stoma site either in all patients<sup>37</sup>, or in patients with a large defect<sup>41</sup>. Remarkably, Helal, who only used mesh in two out of 19 patients, reported lower recurrence rates at the old stoma site, when compared to mesh repair (11% vs 21%). However, follow-up was significantly longer in the paper by Rodriguez-Faba, which can attribute to this difference in recurrence rates. In case of ileal conduit urinary diversion, relocation poses some specific challenges due to ureteric anastomoses and short meso of the ileal conduit, when compared to colo- or ileostomies.

One study reported on the use of onlay mesh via lateral incision and subcutaneous dissection for ileal conduit patients<sup>39</sup>. In this technique, only the lateral part of the stoma was covered with mesh. Complication rates seemed acceptable with 11%, though all complications were major. Reported recurrence rates were lower compared to reported numbers in patients with colo- or ileostomy (6.7% vs 15.2-25.9%)<sup>6,30</sup>. Given the – in comparison – short follow-up period (15 months), small sample size, and partial coverage of the hernia, these findings must be taken with caution.

Regarding local mesh-based repairs, both keyhole (either flat mesh or 3D funnel-shaped mesh) and modified Sugarbaker techniques have been proposed. For keyhole repair, open, laparoscopic and robotic-assisted approaches were studied in our patient group of interest. Keyhole repair in general was presented within the nationwide cohort study by Mäkäräinen-Uhlbäck<sup>43</sup>. Overall complications were 33.3%, one third of which were

major (n=18). Recurrence rates were slightly lower (22.2%) than that presented by the same group for their national cohort of colo- and ileostomy patients (36.0% and 33.0%)<sup>7</sup>. Laparoscopic keyhole repair, by Safadi et al, showed no postoperative complications for ileal conduit patients, while this was 75.0% for gastrointestinal stomata operated on by the same group<sup>42</sup>. On the contrary, recurrence rates were 80% within 6 months after surgery, and 25% in colo- and ileostomy patients. This recurrence rate for ileal conduit patients is significantly higher than published data in a meta-analysis on laparoscopic repair of all types of stoma (27.9%)<sup>5</sup>. The two groups presenting a 'laparoscopic approach' without further clarification for mesh placement, had recurrence rates of 22.2-27.3%<sup>13,17</sup>.

Open keyhole repair as reported by Franks resulted in a recurrence rate of 0.0% after median follow-up of 26 months<sup>40</sup>. Complications are not described. Open keyhole repair of other types of parastomal hernias also had relatively low recurrence rates of 7.2% within a meta-analysis<sup>6</sup>. The use of funnel-shaped meshes, which can be considered as a specific type of keyhole repair, was presented by two German groups<sup>26,38</sup>. Tully actually had the biggest sample size of patient focusing on ileal conduit, consisting of 40 patients. Complications ranged from 2.5-30.8%. Existing literature on this type of mesh repair for all stoma types showed complications ranging from 8.3-20.6%<sup>31,46,47</sup>, so their findings can be considered proportionate. Recurrence rates were roughly in line with evidence for a mixed patient group (7.5-7.7% vs 9.3-12.5%)<sup>22,26,31,38</sup>.

Evidence on the use of the modified Sugarbaker repair is limited. A small patient series showed recurrence rates of 0.0% without any complications in 6 patients, though follow-up was only 10 months<sup>27</sup>. Another small group of patients within a nationwide cohort that was treated with Sugarbaker repair also suggested favorable results and low recurrence rates of 10.0%<sup>43</sup>. Preferable outcomes of Sugarbaker over Keyhole repair have been described elsewhere<sup>3,5-8</sup>. We found one other national cohort that also included a subgroup of ileal conduit parastomal hernia patients<sup>44</sup>. Even though the study period was 6 years, only 20 hernia repairs for ileal conduit patients were performed nationally. Recurrence was not reported for urostomy patients, but complications were relatively high with 45.0%. Overall, data on this type of repair in ileal conduit patients is too limited to retain this conclusion in this specific patient group.

### **Limitations**

This review is subject to several limitations. Firstly, the reported incidence of parastomal hernias in general<sup>8</sup>, and after ileal conduit urinary diversion specifically is low<sup>3,4</sup>. Even

nationwide cohort studies on parastomal hernia repair do not exceed 235 patients within 10 years<sup>7,8</sup>. This, in combination with a broad variety of techniques, compromises sample sizes for study groups. Likewise, in addition to the studies presented, we found 17 case reports and 16 small (n<5) case series on all types of stoma patients, where novel or partly modified techniques were presented. The results thereof were beyond the scope of this review. Secondly, the broad variety of techniques also made pooling of results impossible. None of the included studies mentioned size of the hernia, which might also influence complication and recurrence rates. This limits our possibilities to draw firm conclusions on the matter. Furthermore, the poor methodological quality of included full-text articles poses another limitation to this review. All included articles had a retrospective design and low MINORS-scores.

The surgical treatment of parastomal hernias after cystectomy and ileal conduit urinary diversion offers some specific challenges.

Firstly, in this condition often a concomitant midline incisional hernia is present. This may highly influence the technique of choice to repair the parastomal hernia. If repair of the midline incisional hernia requires component separation techniques<sup>48</sup>, we have a habit of treating both hernias with a retromuscular technique. This consists of a transversus abdominis release<sup>49</sup>, and a retromuscular Sugarbaker repair of the parastomal hernia, as described by Pauli in 2016<sup>50</sup>. In this repair, one large retromuscular mesh covers both the midline and parastomal hernia. If the midline incisional hernia does not require component separation techniques, we prefer an intraperitoneal repair covering both hernia sites after closure of the defects. This involves an intraperitoneal Sugarbaker repair for the parastomal hernia. Both techniques can be performed using minimally invasive (often robotic-assisted) surgery, or by open surgery<sup>5,51</sup>.

Second, a cystectomy for oncological reasons involves stripping of the peritoneum below the arcuate line. This complicates extraperitoneal mesh placement in the repair of ileal conduit parastomal hernias, and therefore, intraperitoneal techniques are more convenient if no concomitant midline incisional hernia is present. Obviously, this also makes closure of the posterior layer after transversus abdominis release more difficult, and may require protecting the peritoneal cavity from mesh in the retromuscular position using omentum, biological mesh or absorbable mesh. If no midline incisional hernia is present, an intraperitoneal Sugarbaker repair of the parastomal hernia is our treatment of choice, as current evidence from surgical repairs of colostomy parastomal hernias supports the use of Sugarbaker repair<sup>7</sup>.



A third element complicating repair of ileal conduit parastomal hernia, is that lateralization of the stomal loop (which is required to perform an adequate Sugarbaker repair) often is difficult. This is mainly due to the short mesentery of the ileal conduit loop, which is usually significantly shorter than in colostomies. In this case, often a keyhole repair is the only treatment possible<sup>6</sup>.

Furthermore, a difficult identification of the stomal loop due to longstanding collapse, and the presence of ureteric anastomoses with the stomal loop are some other elements that complicate repair of ileal conduit parastomal hernias. Perioperative catheterization and instillation of the stomal loop may help to identify these structures during surgery.

In conclusion, repair of these specific type of hernias is considered highly complex, and the treatment of choice should depend on the presence of a midline incisional hernia, need for component separation to repair the midline incisional hernia, and the perioperative characteristics of the ileal conduit parastomal hernia.

### ***Ongoing research and future perspectives***

Besides included full text articles, 16 conference abstracts, 17 case reports, and 16 small (n<5) case series were identified on the topic, representing a growing variety in operative techniques and mesh configurations. Upon request, two authors of the reported conference abstracts affirmed that more extensive full-text articles will follow in the near future<sup>24,45</sup>. One German group shared more insights on their promising experience on the retromuscular Sugarbaker procedure, which they made their standard approach for parastomal hernia repair at the ileal conduit site<sup>17</sup>.

Promising results of prophylactic mesh placement in end colostomies, and the specific challenges a surgical treatment of ileal conduit parastomal hernias offers, have recently raised interest in prophylactic mesh placement within this specific patient group<sup>3</sup>. For end colostomies there are several randomized controlled trials of good quality suggesting that placing mesh during the index operation reduces the risk of parastomal hernia while not increasing postoperative morbidity<sup>52</sup>. However, for urinary diversion, the evidence for prevention of parastomal hernia is as limited as literature on repair thereof. Currently there is one randomized controlled trial from Liedberg et al. They reported on a significant reduction of parastomal hernia in patients with prophylactic mesh (11% vs 23%) after 3 years of follow-up in a patient group of 181 patients<sup>53</sup>. Initial results seem promising, though the quality of evidence is poor<sup>54-57</sup>. Two other randomized trials on the topic are currently recruiting<sup>58,59</sup>.

## **Conclusion**

Generally, data on the surgical treatment of ileal conduit parastomal hernias is scarce and of poor quality. Furthermore, the absence of peritoneum below the arcuate line and a complicated identification and lateralization of the ileal conduit loop make surgical treatment of this condition complex. These limited data and perioperative challenges stress the need for prospective research on the matter including higher patient numbers. We believe that the surgical treatment of this condition requires dedicated surgical teams with adequate proficiency in this type of surgery. This systematic review does not allow to identify the optimal surgical treatment of this specific condition.

## References

1. Gakis G, Efstathiou J, Lerner S, Cookson M, Keegan K, Guru K et al. ICUD-EAU International Consultation on Bladder Cancer 2012: Radical cystectomy and bladder preservation for muscle-invasive urothelial carcinoma of the bladder. *Eur Urol* 2013; 63(1): 45-57.
2. Śmietański M, Szczepkowski M, Alexandre J, Berger D, Bury K, Conze J et al. European Hernia Society classification of parastomal hernias. *Hernia* 2014; 18(1): 1-6.
3. Antoniou S, Agresta F, Garcia Alamino J, Berger D, Berrevoet F, Brandsma H et al. European Hernia Society guidelines on prevention and treatment of parastomal hernias. *Hernia* 2018; 22(1): 183-98.
4. Narang S, Alam N, Campain N, Pathak S, McGrath J, Daniels IR et al. Parastomal hernia following cystectomy and ileal conduit urinary diversion: a systematic review. *Hernia* 2017; 21(2): 163-75.
5. DeAsis F, Lapin B, Gitelis M, Ujiki M. Current state of laparoscopic parastomal hernia repair: A meta-analysis. *World journal of gastroenterology* 2015; 21(28): 8670-7.
6. Hansson BM, Slater NJ, van der Velden AS, Groenewoud HM, Buyne OR, de Hingh IH, et al. Surgical techniques for parastomal hernia repair: a systematic review of the literature. *Ann Surg* 2012; 255(4): 685-95.
7. Mäkäräinen-Uhlbäck E, Vironen J, Falenius V, Nordström P, Välikoski A, Kössi J et al. Parastomal Hernia: A Retrospective Nationwide Cohort Study Comparing Different Techniques with Long-Term Follow-Up. *World J Surg* 2021; 45(6): 1742-9.
8. Odensten C, Strigård K, Dahlberg M, Gunnarsson U, Näsval P. Parastomal Hernia Repair; Seldom Performed and Seldom Reported: Results From a Nationwide Survey. *Scand J Surg* 2020; 109(2): 96-101.
9. Moher D, Liberati A, Tetzlaff J, Altman D, Group P. Preferred reporting items for systematic reviews and meta-analyses: the PRISMA statement. *PLoS Med* 2009; 6(7): e1000097.
10. Dindo D, Demartines N, Clavien P. Classification of surgical complications: a new proposal with evaluation in a cohort of 6336 patients and results of a survey. *Ann Surg* 2004; 240(2): 205-13.

11. Higgins J, Chandler J, Cumpston M, Li T, Page M, Welch V (editors) *Cochrane Handbook for Systematic Reviews of Interventions* version 6.0 (updated July 2019). Cochrane 2019; Available from [www.training.cochrane.org/handbook](http://www.training.cochrane.org/handbook).
12. Slim K, Nini E, Forestier D, Kwiatkowski F, Panis Y, Chipponi J. Methodological index for non-randomized studies (minors): development and validation of a new instrument. *ANZ J Surg* 2003; 73(9): 712-6.
13. Aldhaam N, Elsayed A, Durrani M, Jing Z, Hussein A, Guru K. Minimally invasive management of robot-assisted radical cystectomy related complications: 15 years of experience. *J Endourol* 2019; 33(1): A353.
14. Ypsilantis E, George M. Outcomes of parastomal hernia repair with a modified Sugarbaker technique. *Colorectal Dis* 2015; 17(2): 57.
15. Kotes S, Greenwell T, Wood D, Ockrim J. Is obstruction of ileal conduit after parastomal hernia repair with porcine derived tissue matrix Strattice™ a valid concern? *J Clin Urol* 2018; 11(1): 90.
16. Warren J, Grant A, Carbonell A, McFadden C, Rex J, Cobb W. Open retromuscular repair of parastomal hernias. *Dis Colon Rectum* 2015; 58(5): e243-e4.
17. Borshchigov M, Gröger, C. Laparoscopic treatment of parastomal hernias: a single center experience with the Pauli procedure. 41st Annual Congress of the European Hernia Society. September 11–14, 2019 Hamburg, Germany.
18. Faba O, Rosales A, Palou J, Huguet J, Pardo P, Parada R et al. Post-radical cystectomy parastomal hernia repair: long-term follow-up. *Eur Urol Supplements*. 2009; 8(4): 160.
19. Hussein A, Kozlowski J, Ahmed Y, Guru K. Revisiting the abdomen after robot-assisted radical cystectomy: Tips and tricks for robot-assisted repair. *J Urol* 2017; 197(1): e1373.
20. Miller H, Majumder A, Novitsky Y. Retromuscular Repair of Parastomal Hernias in the Setting of Ileal Conduit: Outcomes and Special Considerations. *J Am Coll Surg* 2016; 223(4): e110-e1.
21. Sharma D, Mishra V, Wood D, Woodhouse C. Long term outcome of parastomal hernia repair in patients treated for benign urological disease. *BJU International* 2009; 103(4): 39.

22. Martin-Cartes J. Parastomal hernias: a more and more surgical challenge. 41st Annual Congress of the European Hernia Society. September 11–14, 2019 Hamburg, Germany.
23. Davis P, Klassen D. Laparoscopic repair of parastomal hernias of ileal conduits: A case series. *Surg Endosc* 2012; 26(1): 329.
24. Jaipuria J, Rawal S, Singh A, Gupta S. Robotic modified Sugarbaker intraperitoneal onlay graft hernioplasty for ileal conduit urinary diversion associated parastomal hernia. *Eur Urol* 2020; 19(2): e2349.
25. Antor M, Schwarz L, Bridoux V, Tuech J, Sibert L, Khalil H. Laparoscopic repair of parastomal hernia after radical cystectomy. *Hernia* 2017; 21: 251-2.
26. Von Bodman C, Brock M, Roghmann F, Eggert T, Pastor J, Loeppenber B et al. Parastomal hernia repair following ileal conduit urinary diversion using a novel funnel mesh implant. *J Urol* 2012; 187(1): e474.
27. Shakir A, Ghoreifi A, Ashrafi A, Berger A, Aron M, Djaladat H. Feasibility, technique and perioperative outcomes of robotic parastomal hernia repair with biologic mesh after cystectomy and ileal conduit diversion. *J Urol* 2020; 203(4): e1113.
28. Ayuso S, Shao J, Deerenberg E, Elhage S, George M, Heniford B et al. Robotic Sugarbaker parastomal hernia repair: technique and outcomes. *Hernia* 2021; 25 (3): 809-15.
29. Craft R, Huguet K, McLemore E, Harold K. Laparoscopic parastomal hernia repair. *Hernia* 2008; 12(2): 137-40.
30. De Robles M, Young C. Parastomal hernia repair with onlay mesh remains a safe and effective approach. *BMC Surg* 2020; 20(1): 296.
31. Fischer I, Wundsam H, Mitteregger M, Kohler G. Parastomal Hernia Repair with a 3D Funnel Intraperitoneal Mesh Device and Same-Sided Stoma Relocation: Results of 56 Cases. *World J Surg* 2017; 41(12): 3212-7.
32. Fitzgerald M, Ullrich S, Singh K, Misholy O, Kingham P, Brady MS. Parastomal hernia repair using the "top hat" technique - An initial experience in 30 patients at Memorial Sloan Kettering Cancer Center. *Am J Surg* 2018; 216(3): 465-70.
33. Kroese L, Lambrichts D, Jeekel J, Kleinrensink G, Menon A, de Graaf E et al. Non-operative treatment as a strategy for patients with parastomal hernia: a multicentre, retrospective cohort study. *Colorectal Dis* 2018; 20(6): 545-51.

34. Olmi S, Oldani A, Uccelli M, Scotto B, Cesana G, Ciccarese F et al. Laparoscopic Modified Keyhole Technique with Coated Polyester Mesh for Treatment of Parastomal Hernia: Measures for Improving the Outcome. *J Laparoendosc Adv Surg Tech* 2019; 29(5): 681-4.
35. Raigani S, Criss C, Petro C, Prabhu A, Novitsky Y, Rosen M. Single-Center Experience With Parastomal Hernia Repair Using Retromuscular Mesh Placement. *J Gastrointest Surg* 2014; 18(9): 1673-7.
36. Tatay F, Anoro M, Manez J, Soto M, Fadrique A, Blasco A et al. New technique for parastomal hernia repair: "IVO technique". *Revista Hispanoamericana De Hernia*. 2017; 5(1): 13-22.
37. Faba O, Rosales A, Breda A, Palou J, Gaya JM, Esquena S, et al. Simplified Technique for Parastomal Hernia Repair After Radical Cystectomy and Ileal Conduit Creation. *Urology* 2011; 77(6): 1491-4.
38. Tully K, Roghmann F, Pastor J, Noldus J, von Bodman C. Parastomal Hernia Repair With 3-D Mesh Implants After Radical Cystectomy and Ileal Conduit Urinary Diversion - A Single-center Experience Using a Purpose Made Alloplastic Mesh Implant. *Urology* 2019; 131: 245-9.
39. Ho K, Fawcett D. Parastomal hernia repair using the lateral approach. *BJU Int* 2004; 94(4): 598-602.
40. Franks M, Hrebinko R. Technique of parastomal hernia repair using synthetic mesh. *Urology* 2001; 57(3): 551-3.
41. Helal M, Austin P, Spyropoulos E, Pow-Sang J, Persky L, Lockhart J. Evaluation and management of parastomal hernia in association with continent urinary diversion. *J Urol* 1997; 157(5): 1630-2.
42. Safadi B. Laparoscopic repair of parastomal hernias: early results. *Surg Endosc* 2004; 18(4): 676-80.
43. Makarainen-Uhlback E, Vironen J, Vaarala M, Nordstrom P, Valikoski A, Kossi J, et al. Keyhole versus Sugarbaker techniques in parastomal hernia repair following ileal conduit urinary diversion: a retrospective nationwide cohort study. *BMC Surg* 2021; 21(1): 231.
44. López-Cano M, Pereira J, Rodrigues-Gonçalves V, Verdaguer-Tremolosa M, Hernández-Granados P, Bravo-Salvá A. Parastomal hernia repair. Prospective

- observational study based on the Spanish Registry of Incisional Hernia (EVEREG). *Cir Esp (Engl Ed)* 2021; 99(7): 527-34.
45. Mäkäräinen-Uhlbäck E, Vironen, J. Keyhole versus sugarbaker techniques in parastomal hernia repair at bricker conduit: a retrospective nationwide cohort study with long-term follow-up. American Hernia Society Annual Meeting 2020.
  46. Köhler G, Fischer I, Wundsam H. A Novel Technique for Parastomal Hernia Repair Combining a Laparoscopic and Ostomy-Opening Approach. *J Laparoendosc Adv Surg Tech A* 2018; 28(2): 209-14.
  47. Steele S, Lee P, Martin M, Mullenix P, Sullivan E. Is parastomal hernia repair with polypropylene mesh safe? *Am J Surg* 2003; 185(5): 436-40.
  48. Love M, Warren J, Davis S, Ewing J, Hall A, Cobb W et al. Computed tomography imaging in ventral hernia repair: can we predict the need for myofascial release? *Hernia* 2021; 25(2): 471-7.
  49. Grossi J, Lee B, Belyansky I, Carbonell A, Cavazzola L, Novitsky Y et al. Critical view of robotic-assisted transverse abdominal release (r-TAR). *Hernia* 2021; 25(6): 1715-25.
  50. Pauli E, Juza R, Winder J. How I do it: novel parastomal herniorrhaphy utilizing transversus abdominis release. *Hernia* 2016; 20(4): 547-52.
  51. Bracale U, Corcione F, Neola D, Castiglioni S, Cavallaro G, Stabilini C et al. Transversus abdominis release (TAR) for ventral hernia repair: open or robotic? Short-term outcomes from a systematic review with meta-analysis. *Hernia* 2021; 25(6): 1471-80.
  52. McKechnie T, Lee J, Lee Y, Doumouras A, Amin N, Hong D et al. Prophylactic Mesh for Prevention of Parastomal Hernia Following End Colostomy: an Updated Systematic Review and Meta-Analysis of Randomized Controlled Trials. *J Gastrointest Surg* 2022; 26(2): 486-502.
  53. Liedberg F, Kollberg P, Allerbo M, Baseckas G, Brändstedt J, Gudjonsson S et al. Preventing Parastomal Hernia After Ileal Conduit by the Use of a Prophylactic Mesh: A Randomised Study. *Eur Urol* 2020; 78(5): 757-63.
  54. Donahue T, Cha E, Bochner B. Rationale and Early Experience with Prophylactic Placement of Mesh to Prevent Parastomal Hernia Formation after Ileal Conduit Urinary Diversion and Cystectomy for Bladder Cancer. *Curr Urol Rep* 2016; 17(2): 9.

55. Styrke J, Johansson M, Granåsen G, Israelsson L. Parastomal hernia after ileal conduit with a prophylactic mesh: a 10 year consecutive case series. *Scand J Urol* 2015; 49(4): 308-12.
56. Tenzel P, Williams Z, McCarthy R, Hope W. Prophylactic mesh used in ileal conduit formation following radical cystectomy: a retrospective cohort. *Hernia* 2018; 22(5): 781-4.
57. Jiang D, Softness K, Chakiryan N, Levy A, Poylin V et al Prophylactic mesh placement at time of ileal conduit creation: A simple sublay technique. *J Urol* 2021; 206. Epub ahead of print.
58. Role of Mesh Stoma Reinforcement Technique (MSRT) in Prevention of Parastomal Hernia After Ileal Conduit Urinary Diversion. <https://clinicaltrials.gov/show/NCT02387333> 2015.
59. Biologic Mesh in Preventing Hernia in Patients With Bladder Cancer Undergoing Radical Cystectomy With Ileal Conduit Diversion. <https://clinicaltrials.gov/show/NCT02439060> 2015.





# Chapter 5

## How-I-do-it: minimally invasive repair of ileal conduit parastomal hernias Technical note and preliminary results

Maxime Dewulf  
Pieter Pletinckx  
Femke Nachtergaele  
Filip Ameye  
Peter Dekuyper  
Nicole D. Hildebrand  
Filip Muysoms

*Langenbecks Archives of Surgery* 2022 January 28. Epub ahead of print.  
doi: 10.1007/s00423-021-02393-5.

## Abstract

**Background.** Parastomal hernia after radical cystectomy and ileal conduit urinary diversion is an underestimated and undertreated condition with significant impact on quality of life. However, its surgical treatment is challenging and prone to complications and the optimal surgical treatment of this condition remains to be determined.

**Methods.** In this article we describe our surgical techniques in the minimally invasive treatment of ileal conduit parastomal hernia and present our preliminary results. In a retrospective single-center design, a prospectively maintained database was screened. Data from all patients undergoing surgical treatment for a parastomal hernia after cystectomy and ileal conduit urinary diversion in our center were collected.

**Results.** Between May 2016 and June 2020, 15 patients underwent minimally invasive repair of a parastomal hernia of an ileal conduit. Details on the surgical approach are provided, along with a flow chart to standardize the choice of surgical technique, depending on the presence of a concomitant midline incisional hernia and perioperative findings. The majority of patients were treated with robotic-assisted laparoscopic surgery (10/15; 66.7%). Median postoperative hospital stay was 5 days. One third of patients developed a postoperative urinary infection. Median follow-up was 366 days. One patient developed a local recurrence of her parastomal hernia on day 66 postoperatively, treated with intraperitoneal mesh.

**Conclusion.** The minimally invasive surgical treatment of a parastomal hernia after ileal conduit urinary diversion poses specific perioperative challenges that require a broad surgical armamentarium and a tailored approach. Preliminary results confirm a significant morbidity after this type of surgery.

**Keywords.** Parastomal hernia - Cystectomy - Ileal conduit - Bricker urostomy

## Introduction

Radical cystectomy remains the cornerstone of the curative treatment of bladder neoplasms<sup>1</sup>. The use of an ileal conduit (IC) is the most commonly used technique for external urinary diversion after this type of surgery, and was first reported around the 1950s<sup>2</sup>. Recently, various alternative techniques of urinary diversion, such as orthotopic bladder substitution, have gained popularity in the current surgical field<sup>3,4</sup>. However, due to the relatively low complexity and long surgical tradition, it is estimated that around 5000 ileal conduits are still being constructed in the United States annually<sup>5</sup>.

In 2014, the European Hernia Society published a classification of parastomal hernias, and defined a parastomal hernia (PH) as abnormal protrusion of the contents of the abdominal cavity through the abdominal wall defect created during placement of a colostomy, ileostomy or ileal conduit stoma<sup>6</sup>. In an attempt to estimate the incidence of a PH after creation of an IC stoma (ICPH), Narang et al. published a systematic review in 2017<sup>4</sup>. After pooling results of 3170 patients, the incidence of a PH was estimated around 17.1%, based on either clinical examination or cross-sectional imaging, and was found to be highly dependent on the duration of follow-up. More recently, a retrospective patient series from the Cleveland Clinic reported on an incidence of 30% after 2 years of follow-up<sup>3</sup>. Data from a Canadian center even reported an incidence of PH of 68.2%, of which 3 out of 4 were diagnosed within 2 years after surgery<sup>7</sup>. Both studies used cross-sectional imaging to detect an ICPH. All authors identified obesity as an independent risk factor for the development of a PH<sup>3,4,7</sup>, while advanced bladder cancer stage and tobacco use have variably been identified as independent risk factors for the development of a ICPH<sup>3,7</sup>.

Generally, there is consensus that the majority of patients with a PH after IC urinary diversion remain asymptomatic and do not require (surgical) treatment<sup>3,4,7</sup>. In the retrospective series from Rezaee et al, 40% of patients with a PH reported symptoms related to the hernia, while only 12.5% underwent surgical treatment<sup>7</sup>. Other authors report on a broad range of patients with an ICPH that undergo surgery, varying from 4 to 75%<sup>4,8</sup>. Most frequently reported symptoms are local discomfort, difficulties in stoma bag application, skin problems and cosmetic dissatisfaction<sup>4</sup>. These numbers suggest that this condition is generally undertreated, despite significant impairment of quality of life.

The surgical treatment of an ICPH is complex, making surgeons reluctant to perform surgery. First, patients who underwent surgery for bladder cancer generally have significant morbidity and they remain at risk for recurrent or metastatic disease. Moreover, parastomal hernia surgery after radical cystectomy and ileal conduit urinary diversion poses some specific challenges, making this type of surgery technically difficult and prone to recurrence and complications. Finally, it is estimated that around 50% of patients who underwent radical cystectomy by laparotomy and who are diagnosed with a ICPH have a concomitant incisional hernia at the midline, further complicating its repair<sup>4,8,9</sup>.

## **Objectives**

With this retrospective study we aim to report on outcomes and technical aspects of minimally invasive surgical treatment of parastomal hernia after radical cystectomy and ileal conduit urinary diversion. Furthermore, it is our objective to discuss specific technical challenges in this type of surgery and propose a treatment algorithm, depending on the perioperative findings and the presence of a concomitant midline incisional hernia.

## **Methods**

### **Setting**

In a single center observational design, data from a prospectively maintained database was retrospectively analyzed. Included patients were treated between May 2016 and June 2020. Surgery was performed by one surgeon with extensive experience in both open and minimally invasive abdominal wall surgery. The study protocol has been approved by the local ethics committee with reference number MMS.2021.028. All patient and surgical data were prospectively and pseudonymously entered in the EuraHS (European registry for abdominal wall hernias, for the period 2016-2019) database and the AWSOME (Abdominal Wall Surgery Online Mesh Evaluation, for the period 2020-2021) database at the time of surgery and during a 4-weeks and one-year postoperative outpatient clinic visit<sup>10</sup>. For analysis, data were extracted in an anonymized manner.

## ***Patients***

All patients who underwent minimally invasive surgical treatment of a ICPH were considered eligible for inclusion. No specific exclusion criteria were defined. All patients were scheduled for a standard clinical outpatient follow-up visit with the surgeon at 4 weeks and one year postoperatively. Additional data on clinical evaluation or cross-sectional imaging (for scheduled oncological follow-up) were collected before the closure of the database.

## ***Endpoints and variables***

The incidence of local recurrence (based on clinical evaluation or cross-sectional imaging in the supine position at rest) was defined as primary endpoint. The rate of in-hospital complications (according to the Clavien-Dindo classification) was defined as secondary endpoint<sup>11</sup>. Furthermore, the following surgical data were collected: duration of surgery, surgical approach, surgical technique, type of mesh, mesh position, mesh fixation and mesh dimensions. Regarding postoperative data hospital stay, 30-day reoperation and readmission rates, length of follow-up and reoperations during the follow-up period were reported.

## ***Statistical analysis***

For descriptive data on patient demographics and outcomes, median values and interquartile ranges (IQR) or proportions (%N) were calculated. Data analysis was carried out using Microsoft Excel (Redmond, WE, USA).

## **Results**

### ***Patient characteristics***

During the study period, 15 patients underwent minimally invasive surgical treatment of a PH of an IC ostomy at our center. Patient characteristics are listed in Table 1. The majority of patients were male. Median Body-Mass Index was 28.7 kg/m<sup>2</sup>, with an interquartile range (IQR) from 25.7 to 34.2 kg/m<sup>2</sup>. Median age of included patients was 75 years, with an IQR of 73-77 years. Almost half of the patients had a concomitant midline incisional hernia, and 3 out of 15 patients were treated for a recurrent parastomal hernia. Reported symptoms of the PH were the following: local discomfort (12/15;

80.0%), stoma bag application problems (7/15; 46.7%), skin irritation (3/15; 20.0%) and aesthetic complaints (2/15; 13.3%).

### ***Surgical data***

Technical details of the surgical technique, mesh used and perioperative variables are presented in Table 2. Median duration of surgery was 197 minutes, with an IQR of 132-260 minutes. The majority of patients were treated with robotic-assisted laparoscopic surgery (10/15; 66.7%). One conversion from minimally invasive to open surgery was noted, due to mesh erosion of previously placed mesh requiring small bowel resection. In 33.3% of patients (5/15) the mesh was positioned in the retromuscular plane, while the remaining patients underwent surgical treatment with an intraperitoneal mesh. Illustrations on the various surgical techniques in ICPH repair are shown in Figure 1-4 in Chapter 1 of this thesis.

**Table I - Patient characteristics and symptoms of parastomal hernia after ileal conduit urinary diversion**

	BMI (kg/m <sup>2</sup> )	DM (13.3%)	Age (years)	Concomitant incisional ventral hernia (53.5%)	Previous parastomal hernia repair (20.0%)	Discomfort (80.0%)	Stoma bag application problems (46.7%)	Skin irritation (20.0%)	Aesthetic complaints (13.3%)	Incarceration (6.7%)
1	36.1	N	72	Y	Y	X	X	X		
2	24.5	N	76	N	N	X				
3	28.7	N	77	Y	N	X				
4	25.0	N	74	Y	N		X			
5	25.5	N	66	Y	N	X				
6	26.1	N	89	Y	N	X				X
7	28.1	Y	73	Y	N	X				
8	35.2	N	72	N	Y	X	X			
9	36.1	N	76	Y	N	X				
10	28.7	N	83	N	N		X	X		
11	29.8	N	75	N	N	X			X	
12	31.3	N	74	Y	N	X	X			
13	24.7	Y	74	N	N		X	X		
14	20.0	N	75	N	Y	X			X	
15	28.0	N	77	N	N	X	X			

BMI=body mass index; DM=diabetes mellitus; M=male; F=female; N=no; Y=yes



**Table 2 - Surgical data**

	Length x width of parastomal hernia (mm)	Hernia type*	Duration of surgery (min)	Surgical approach	Mesh position	Surgical technique	Type of mesh (size in mm)
1	48 x 56	IV	160	Laparoscopy	Intraperitoneal	Modified Sugarbaker	Parietex composite parastomal (20 x 20)
2	25 x 42	I	87	Laparoscopy	Intraperitoneal	Modified Sugarbaker	Parietex composite parastomal (20 x 20)
3	58 x 42	IV	405	Robotic-assisted	Retromuscular	TAR Pauli	Versatex (30 x 36)
4	30 x 30	II	197	Robotic-assisted	Retromuscular	TAR Pauli	Versatex (35 x 30)
5	40 x 50	IV	425	Robotic-assisted	Retromuscular	TAR Pauli	Versatex (30 x 35) Progrip (15 x 15)
6	55 x 56	IV	372	Robotic-assisted	Retromuscular	TAR Pauli	Versatex (50 x 50) Progrip (15 x 15)
7	38 x 55	IV	202	Robotic-assisted	Intraperitoneal	Modified Sugarbaker	Parietex composite parastomal (20 x 20)
8	58 x 61	III	245	Laparoscopy	Intraperitoneal	Modified Sugarbaker	Symbotex composite (20 x 34)
9	Missing	II or IV	260	Robotic-assisted	Retromuscular	TAR Pauli	Versatex (34 x 35)
10	59 x 56	III	102	Laparoscopy	Intraperitoneal	Modified Sugarbaker	Parietex composite parastomal (20 x 20)
11	40 x 45	I	155	Laparoscopy	Intraperitoneal	Modified Sugarbaker	Symbotex composite (25 x 12)
12	23 x 32	II	224	Robotic-assisted	Intraperitoneal	Modified Sugarbaker	Symbotex composite (25 x 15)
13	50 x 44	IV	132	Robotic-assisted	Intraperitoneal	Modified Sugarbaker	Symbotex composite (25 x 15)
14	63 x 40	III	173	Robotic-assisted	Intraperitoneal	Keyhole	Dynamesh IPST (15 x 15)
15	58 x 44	III	117	Robotic-assisted	Intraperitoneal	Keyhole	Dynamesh IPST (15 x 15)

\*According to the European Hernia Society classification of parastomal hernias<sup>6</sup>

N=no; Y=yes; TAR=transversus abdominis release

**Table 3 - Postoperative outcomes**

	Hospital stay (days)	In-hospital complications	C-D	Reoperation within 30 days	Readmission within 30 days	Length of follow-up (days)	Recurrence of parastomal hernia	Complications during follow-up	Reoperation during follow-up	Reoperation
1	6	/	/	N	N	LTFU	N	LTFU	LTFU	/
2	4	Urinary infection Hydronefrosis CVA	IVa	N	Y	1537	N	N	N	/
3	3	Urinary infection	II	N	Y	1544	N	N	N	/
4	8	/	/	N	N	1184	N	N	N	/
5	2	Urinary infection	II	N	N	66	Y	N	Y	Sugar-baker
6	25	Perforation ileal conduit	IIIb	Y	N	1387	N	Y (Mesh infection)	Y	Abscess drainage
7	5	/	/	N	N	1134	N	N	N	/
8	5	/	/	N	N	366	N	N	N	/
9	10	Pulmonary edema	IVa	N	N	LTFU	N	LTFU	LTFU	/
10	15	Urinary infection	II	N	N	342	N	N	N	/
11	9	Urinary infection	II	N	N	362	N	N	N	/
12	1	/	/	N	N	360	N	N	N	/
13	3	/	/	N	N	139	N	Y (Urinary infection)	Y	Local repair
14	2	/	/	N	N	367	N	N	N	/
15	3	/	/	N	N	27	N	N	N	/

C-D=Clavien-Dindo; N=no; Y=yes; LTFU=lost to follow-up; CVA=cerebrovascular accident

## **Postoperative outcomes**

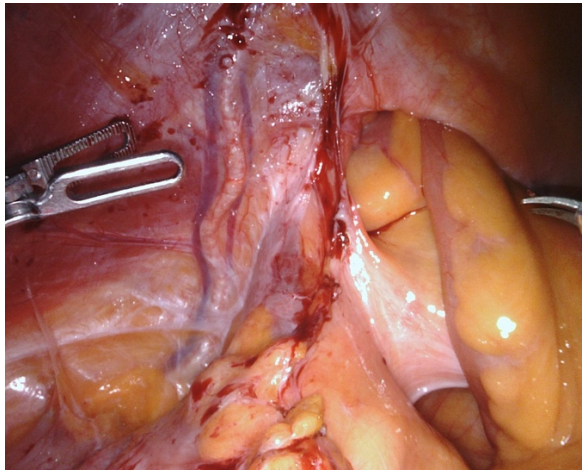
Outcome data are listed in Table 3. Median postoperative hospital stay was 5 days, with an IQR of 3-9 days. One third of patients developed a postoperative clinically relevant urinary infection and 2 patients were admitted to the intensive care unit during their hospitalization (due to neurologic disorder and acute pulmonary edema). One patient was reoperated within 30 days because of perforation of the ileal conduit, requiring abdominal drainage. She eventually developed a chronic mesh infection. Median follow-up was 366 days (IQR 241-1286 days). One patient developed a local recurrence of her parastomal hernia after 66 days, that was treated with intraperitoneal mesh.

## **Discussion**

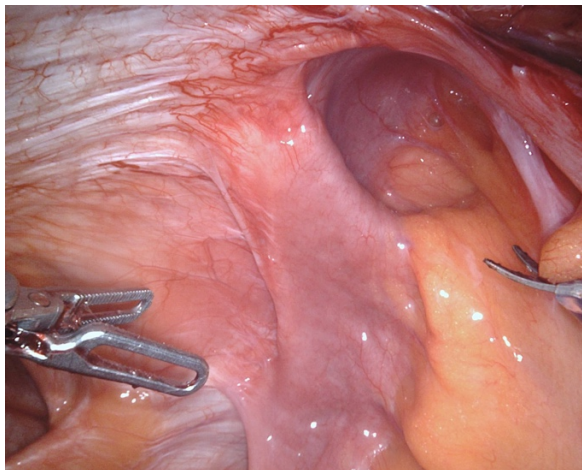
### ***How I do it***

The surgical treatment of ileal conduit parastomal hernias is technically challenging, due to some specific elements of this condition, which are listed in Table 4. First, a radical cystectomy for oncological conditions often involves stripping of the peritoneum below the arcuate line. Figure 1 illustrates the absence of peritoneum after radical cystectomy, in proximity to the ileal conduit loop. This complicates extraperitoneal mesh placement, and therefore, intraperitoneal techniques (such as intraperitoneal modified Sugarbaker or intraperitoneal keyhole repair) are often used. This absence of peritoneum below the arcuate line also complicates closure of the posterior layer in case of transversus abdominis release (TAR). In our experience, this is a common problem in case of TAR after radical cystectomy. Bridging techniques using omentum or absorbable mesh can help to protect the abdominal cavity from synthetic mesh. Second, ileal conduit urinary diversion often results in a complete collapse of the small bowel loop (Figure 2). This makes the perioperative identification difficult. This problem can be addressed by a catheterization and instillation of the IC during surgery, making its identification (and identification of a possible perioperative injury) easier. Third, the ureteric anastomoses on the ileal conduit, along with the longstanding collapse of the ileal conduit loop, complicate techniques that require further exteriorization of the stomal loop (such as onlay keyhole repair). This is another argument to propose intraperitoneal techniques in the minimally invasive treatment of this condition. Figure 3 illustrates the postoperative image of an intraperitoneal modified Sugarbaker repair of an ileal conduit PH. Another frequent observation is a difficult lateralization of the stoma loop, due to often short mesentery (Figure 2). This is a specific observation that is far less frequently seen in case of an ileo- or colostomy. In that case an intraperitoneal or retromuscular Sugarbaker

repair offers insufficient overlap of the hernia and a keyhole technique can be a better alternative. In case of difficult lateralization of the stoma loop during TAR and retromuscular Sugarbaker repair (as described by Pauli et al<sup>27</sup>), we add a second retromuscular keyhole mesh around the ileal conduit after partial closure of the defect, besides the large retromuscular mesh covering the midline. In that case, the inadequate lateralization of the stoma loop requires a slit in the large retromuscular mesh (Figure 4).

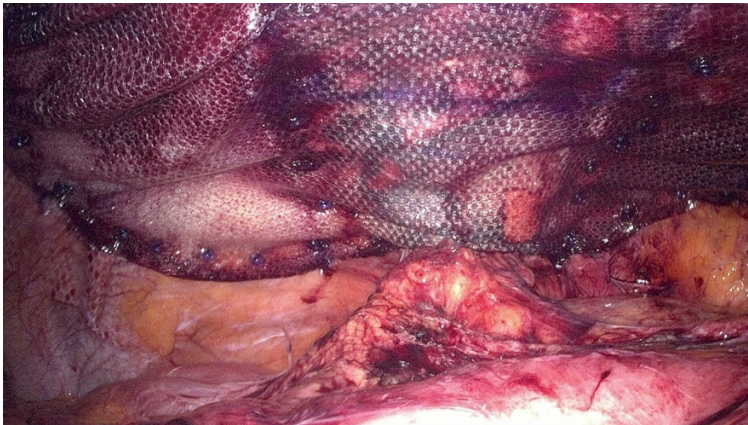


**Figure 1** - Absence of peritoneum below the arcuate line after radical cystectomy and ileal conduit urinary diversion



**Figure 2** - Collapse of ileal conduit complicating its identification, short mesentery complicating its lateralization

For intraperitoneal Sugarbaker repairs, it is obvious that a coated composite mesh should be used to prevent adhesions at the intraperitoneal surface. We do not have a habit of adding a second biological mesh to cover the interface between mesh and ileal conduit loop, as we believe that the area in contact with the mesh is mainly mesentery. In case of concomitant repair of large midline incisional hernias and extraperitoneal parastomal hernia repair, we recommend large-pore mesh to facilitate ingrowth. In case of an intraperitoneal keyhole repair a coated funnel-shaped mesh (Dynamesh IPST, Dynamesh, Aachen, Germany) was used in our series. Besides the composition, both the size and commercial availability of meshes may influence mesh choice in different countries. Regarding mesh fixation, a link between fixation methods and mesh shrinkage has not been identified in current literature. Nonetheless, some techniques require mesh fixation to secure the correct position of the mesh until ingrowth can occur. This is why we use mesh fixation in Sugarbaker and intraperitoneal keyhole repairs. After open transversus abdominis release, we use mesh fixation to allow for a proper mesh positioning during surgery. In case of robotic-assisted transversus abdominis release and concomitant retromuscular Sugarbaker repair of a parastomal hernia, this is not required as the mesh fills the entire dissected space, and the mesh cannot shift from the dissected space after deflation.



**Figure 3** - Perioperative image of intraperitoneal modified Sugarbaker repair


The extent of closure of the parastomal hernia should allow just enough space to allow for an adequate drainage of the stoma, without introducing any outflow obstruction of the urinary tract. By routinely performing a perioperative catheterization of the ileal conduit loop, extensive closure resulting in obstructive outflow can be avoided. However, the extent of closure should be tailored to the intraoperative findings, patient

characteristics and natural size of the ileal loop. Figure 5 depicts a flow chart of our current practice in the treatment of PH at the IC site depending on the presence of a concomitant midline incisional hernia and the possibility to lateralize the IC loop.

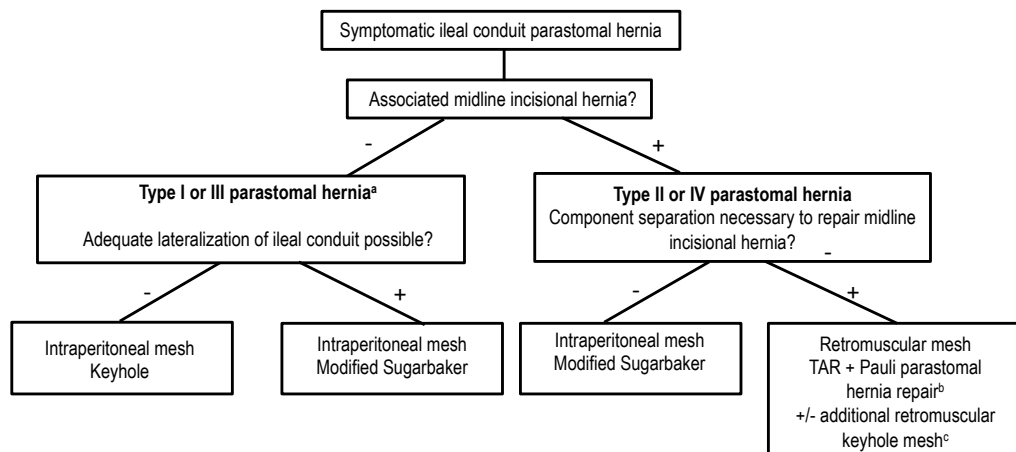
**Table 4 - Challenges and solutions in ileal conduit parastomal hernia repair**

Challenges	Solutions
Absence of peritoneum caudal from arcuate line	Intraperitoneal techniques
Difficult closure of posterior layer in case of bilateral TAR (due to absence of peritoneum)	Bridging techniques to protect abdominal cavity from synthetic mesh (absorbable mesh, omentum)
Collapse of ileal conduit complicating its identification	Perioperative catheterization and instillation
Difficult lateralization of ileal conduit due to short mesentery	Use of keyhole technique instead of Sugarbaker

TAR=transversus abdominis release



**Figure 4** - In case of inadequate lateralization of the stoma loop after TAR, an additional keyhole mesh was used in the retromuscular plane (left), and a slit was made in the big mesh covering the retromuscular plane (right).



**Figure 5** - Flow chart of different surgical techniques in ileal conduit parastomal hernia repair

<sup>a</sup> According to the European Hernia Society classification of parastomal hernias<sup>6</sup>

<sup>b</sup> Retromuscular sugarbaker repair, as described by Pauli et al.<sup>27</sup>

<sup>c</sup> In case of inadequate lateralization of the stomal loop, additional keyhole mesh was used in the retromuscular plane, and a slit was made in the big mesh covering the retromuscular plane

TAR=transversus abdominis release

## Main results

With a concomitant midline incisional hernia in almost half of our patients, and a recurrence after previous parastomal hernia in 20% of them, the patient group of this small retrospective series illustrates the complexity of an ileal conduit PH repair. A median age of 75 years at time of surgery suggests a patient population with significant comorbidities. Eventually, 46.7% of patients developed a postoperative complication during hospitalization, with a urinary infection being the most frequent. This high amount of urinary infection (despite the administration of perioperative antibiotics) can probably be addressed to the systematic perioperative catheterization of the ileal conduit loop, and possibly to the fact that keyhole or lateralization techniques of the parastomal hernia repair will increase resistance in the urinary outflow. However, this observation was not seen in studies that introduced the use of a prophylactic mesh into their practice<sup>8,9</sup>. This, along with the observation that urinary infection was seen in both patients that underwent Sugarbaker and keyhole repair, we believe that it is mainly attributable to catheterization, rather than lateralization of the stoma or outflow obstruction. A

significant portion of our patients (3/15) had a severe postoperative complication (defined as Clavien-Dindo  $\geq$ IIIb)<sup>11</sup>. No mortality was noted. Regarding the primary endpoint, only one recurrence was seen during a median follow-up of 366 days. These numbers illustrate significant morbidity after this type of surgery and show the need for specific perioperative management and postoperative care by dedicated and proficient surgical teams. These concerns were also noted in the treatment of parastomal hernias in proximity of ileo- or colostomies, making surgeons reluctant to treat this type of hernias in any type of ostomy<sup>12,13</sup>.

### **Interpretation**

Generally, data on the surgical treatment of PH at the site of an IC is scarce and available evidence is of poor quality. Only 6 retrospective patient series that included at least 5 patients have been published on the topic, with a sample size varying between 5 and 40 patients<sup>14-19</sup>. Only one of them reported on outcomes after laparoscopic surgery, using a keyhole technique<sup>17</sup>. The others reported on results after open surgery, with recurrence rates varying between 0 and 80% and inconsistently reporting on other postoperative outcomes<sup>14-16,18-19</sup>. Several case reports and conference abstracts have been published on the subject, introducing numerous surgical techniques, while some authors included ileal conduit patients to their general population of patients with parastomal hernias<sup>13,20-22</sup>. However, none of them focused on a minimally invasive approach or on simultaneous repair of a midline incisional hernia in patients with ICPH, despite the fact that this condition occurs in about half of this patient population<sup>4</sup>. There is growing evidence that minimally invasive (often robotic-assisted) techniques significantly improve outcomes in abdominal wall surgery and several component separation techniques have recently been introduced to this field of surgery<sup>23-26</sup>. With this patient series, we aim to add some unique data on the state-of-the-art minimally invasive surgical treatment of ileal conduit parastomal hernias, with a focus on the concomitant treatment of midline incisional hernias.

### **Limitations**

Besides the retrospective design, this study has several limitations. First, like other studies on the subject, the number of included patients is small. Second, the surgical technique was not randomized and highly dependent on surgeon's preference and perioperative observations. Third, minimally invasive techniques used in this patient series are mostly robotic-assisted. Although the use of a robotic platform in abdominal wall surgery is on the rise, and evidence is growing<sup>23-26</sup>, these techniques are not yet



generally adopted and readily available in most countries. These limitations make extrapolation of these results difficult, and make recommendations on the optimal surgical technique not readily applicable to all surgical centers.

## **Conclusion**

The minimally invasive surgical treatment of a parastomal hernia after ileal conduit urinary diversion poses specific perioperative challenges that require a broad surgical armamentarium and a tailored approach. This paper confirms the significant morbidity after this type of surgery stressing the need for dedicated and proficient surgical teams. Furthermore it proposes a flow chart to standardize the choice of surgical technique, depending on the presence of a concomitant midline incisional hernia and perioperative findings.

## References

1. Gakis G, Efstathiou J, Lerner S, Cookson M, Keegan K, Guru K et al. International Consultation on Urologic Disease-European Association of Urology Consultation on Bladder Cancer 2012. ICUD-EAU International Consultation on Bladder Cancer 2012: Radical cystectomy and bladder preservation for muscle-invasive urothelial carcinoma of the bladder. *Eur Urol* 2013; 63(1): 45-57.
2. Bricker EM. Bladder substitution after pelvic evisceration. *Surg Clin North Am* 1950; 30(5): 1511-21.
3. Su J, Hoy N, Fafaj A, Tastaldi L, Strong A, Rosen M et al. The European Hernia Society classification applied to the rare cases of parastomal hernia after ileal conduit urinary diversion: a retrospective cohort of 96 patients. *Hernia* 2021; 25(1): 125-31.
4. Narang S, Alam N, Campain N, Pathak S, McGrath J, Daniels I et al. Parastomal hernia following cystectomy and ileal conduit urinary diversion: a systematic review. *Hernia* 2017; 21(2): 163-75.
5. Gore J, Litwin M. Urologic Diseases in America Project. Quality of care in bladder cancer: trends in urinary diversion following radical cystectomy. *World J Urol* 2009; 27(1): 45-50.
6. Śmietański M, Szczepkowski M, Alexandre J, Berger D, Bury K, Conze J et al. European Hernia Society classification of parastomal hernias. *Hernia* 2014; 18(1): 1-6.
7. Rezaee M, Goldwag J, Goddard B, Bihrlle W, Viazmenski A, Wilson M et al. Parastomal hernia development after cystectomy and ileal conduit for bladder cancer: results from the Dartmouth ileal conduit enhancement (DICE) project. *Can J Urol* 2020; 27(5): 10369-77.
8. Liedberg F, Kollberg P, Allerbo M, Baseckas G, Brändstedt J, Gudjonsson S et al. Preventing Parastomal Hernia After Ileal Conduit by the Use of a Prophylactic Mesh: A Randomised Study. *Eur Urol* 2020; 78(5): 757-63.
9. Tenzel P, Williams Z, McCarthy R, Hope W. Prophylactic mesh used in ileal conduit formation following radical cystectomy: a retrospective cohort. *Hernia* 2018; 22(5): 781-4.
10. Muysoms F, Campanelli G, Champault G, DeBeaux A, Dietz U, Jeekel J et al. EuraHS: the development of an international online platform for registration and

- outcome measurement of ventral abdominal wall hernia repair. *Hernia* 2012; 16: 39-50.
11. Dindo D, Demartines N, Clavien P. Classification of surgical complications. A new proposal with evaluation in a cohort of 6336 patients and results of a survey. *Ann Surg* 2004; 240(2): 205-13.
  12. Hansson B, Slater N, van der Velden A, Groenewoud H, Buyne O, de Hingh I et al. Surgical techniques for parastomal hernia repair: a systematic review of the literature. *Ann Surg* 2012; 255(4): 685-95.
  13. De Robles M, Young C. Parastomal hernia repair with onlay mesh remains a safe and effective approach. *BMC Surg* 2020; 20(1): 296.
  14. Faba O, Rosales A, Breda A, Palou J, Gaya J, Esquena S et al. Simplified Technique for Parastomal Hernia Repair After Radical Cystectomy and Ileal Conduit Creation. *Urology* 2011; 77(6): 1491-4.
  15. Franks M, Hrebinko R. Technique of parastomal hernia repair using synthetic mesh. *Urology* 2001; 57(3): 551-3.
  16. Helal M, Austin P, Spyropoulos E, Pow-Sang J, Persky L, Lockhart J. Evaluation and management of parastomal hernia in association with continent urinary diversion. *J Urol* 1997; 157(5): 1630-2.
  17. Safadi B. Laparoscopic repair of parastomal hernias: early results. *Surg Endosc* 2004; 18(4): 676-80.
  18. Ho K, Fawcett D. Parastomal hernia repair using the lateral approach. *BJU Int* 2004; 94(4): 598-602.
  19. Tully K, Roghmann F, Pastor J, Noldus J, von Bodman C. Parastomal Hernia Repair With 3-D Mesh Implants After Radical Cystectomy and Ileal Conduit Urinary Diversion - A Single-center Experience Using a Purpose Made Alloplastic Mesh Implant. *Urology* 2019; 131: 245-9.
  20. Ayuso S, Shao J, Deerenberg E, Elhage S, George M, Heniford B et al. Robotic Sugarbaker parastomal hernia repair: technique and outcomes. *Hernia* 2020. doi: 10.1007/s10029-020-02328-x. Epub ahead of print.
  21. Fitzgerald M, Ullrich S, Singh K, Misholy O, Kingham P, Brady M. Parastomal hernia repair using the "top hat" technique - An initial experience in 30 patients at Memorial Sloan Kettering Cancer Center. *Am J Surg* 2018; 216(3): 465-70.

22. Olmi S, Oldani A, Uccelli M, Scotto B, Cesana G, Ciccarese F et al. Laparoscopic Modified Keyhole Technique with Coated Polyester Mesh for Treatment of Parastomal Hernia: Measures for Improving the Outcome. *J Laparoendosc Adv Surg Tech A*. 2019; 29(5): 681-4.
23. Dewulf M, Aspeslagh L, Nachtergaele F, Pletinckx P, Muysoms F. Robotic-assisted laparoscopic inguinal hernia repair after previous transabdominal prostatectomy. *Surg Endosc* 2021. doi: 10.1007/s00464-021-08497-9. Epub ahead of print.
24. Grossi J, Lee B, Belyansky I, Carbonell A, Cavazzola L, Novitsky Y et al. Critical view of robotic-assisted transverse abdominal release (r-TAR). *Hernia* 2021. doi: 10.1007/s10029-021-02391-y. Epub ahead of print.
25. Christopher A, Fowler C, Patel V, Mellia J, Morris M, Broach R et al. Bilateral transversus abdominis release: Complex hernia repair without sacrificing quality of life. *Am J Surg* 2021. doi: 10.1016/j.amjsurg.2021.03.020. Epub ahead of print.
26. Sadava E, Peña M, Bras Harriott C, Casas M, Schlottmann F, Laxague F. Long-term outcomes and quality of life assessment after posterior component separation with transversus abdominis muscle release (TAR). *Surg Endosc* 2021 Mar 4. doi: 10.1007/s00464-021-08402-4. Epub ahead of print.
27. Pauli E, Juza R, Winder J. How I do it: novel parastomal herniorrhaphy utilizing transversus abdominis release. *Hernia* 2016; 20(4): 547-52.



# **Part III**

## Ventral hernia



# Chapter 6

Three years of adopting robotic abdominal wall  
surgery in a European hospital  
The ROBUST hernia project

Filip Muysoms  
Femke Nachtergaele  
Pieter Pletinckx  
Maxime Dewulf

*Cirugía Española (English Edition) 2021; 99(9): 629-34.*



## Abstract

We describe the evolution in hernia repair approaches in our practice during the first 3 years of adopting robotic-assisted laparoscopic surgery. For inguinal hernia repair, we began using the robotic platform for complex hernias, and the use of open repair decreased from 17% to 6%. For primary ventral hernias, open procedures decreased from 59% to 10% and for incisional ventral hernias, from 48% to 11%. Moreover, a large shift in mesh position for ventral hernias was seen, with an increase of the retromuscular position from 20% to 82% and a decrease of intraperitoneal mesh position from 48% to 10%.

The robotic platform seems to hold a significant potential for complex inguinal hernias, in addition to ventral and incisional hernias which require component separation. A shorter hospital stay and less postoperative complications might make the adoption of the robotic platform for abdominal wall surgery a valuable proposition.

**Keywords.** Laparoscopic surgery - Robotic surgery - Hernia repair - Abdominal wall surgery

## Introduction

In the United States, robotic-assisted general surgery has witnessed a formidable growth over the last few years. It has overtaken urological and gynecological surgery in number of cases being performed using the robotic platform. Abdominal wall surgery has contributed significantly to this growth, both for the treatment of ventral and inguinal hernias<sup>1</sup>. This study investigates the utility of using the robotic platform to treat abdominal wall hernias and identifies treatment patterns that have changed during the initial 3 years of adopting robotic surgery in our practice.

## Methods

### *Study design*

This is a retrospective single center study of robotic-assisted laparoscopic abdominal wall surgery during the initial 3 years of its adoption.

### *Setting*

The study was performed at the Department of Surgery of Maria Middelaers Hospital in Gent, Belgium. All operations were performed by one surgeon with extensive experience in open and laparoscopic abdominal wall surgery prior to the adoption of robotic-assisted surgery. The robotic program commenced in September 2016.

### *Data extraction*

We record all our abdominal wall surgery procedures prospectively in the EuraHS database (European Registry of Abdominal Wall hernias), which allowed us to examine patterns of change in surgical practice during the years before and after adopting robotic abdominal wall surgery<sup>2</sup>. Data extracted include: type of access (open surgery, conventional laparoscopy or robotic-assisted laparoscopy) and type of mesh position (intraperitoneal, preperitoneal, retromuscular or onlay repair).

### *Descriptive data*

The EuraHS database prospectively captures data for all consecutive ventral hernia repairs since January 2012 and of inguinal hernia repairs since March 2015. Until the end of 2019, a total of 938 ventral hernias and 864 inguinal hernias have been repaired.

Ventral hernias included primary ventral hernias (n=438), incisional ventral hernias (n=451) and parastomal ventral hernias (n=49).

## **The ROBUST hernia project**

Robotic-assisted surgery first noted widespread adoption in urology with minimal invasive prostatectomy<sup>3</sup>. Gynecologic and colorectal surgery were also relatively early adopters. It was at the 17th Annual America Hernia Society meeting in Washington DC, March 2016, that we became aware of the increasing interest by surgeons to adopt the robotic platform for repair of abdominal wall hernias. Healthy skepticism caused us to question the use of the robot for general surgery and for hernia surgery specifically. We had the same objections as many: firstly, "*It takes too long*"; secondly, "*It is too expensive*" and thirdly, "*What is the clinical benefit for the patient?*". On the other hand, the early adopters of robotic-assisted laparoscopic hernia surgery presented inspiring videos. Some face-to-face discussions with those pioneers, like Conrad Ballecer from Phoenix, Arizona, triggered our interest and curiosity. In the hospital Maria Middelaers Gent, Belgium we had at that time a new latest generation robotic platform daVinci Xi (Intuitive Surgical, Sunnyvale, CA, USA) which was used two days a week by the urologist. Within the department of general surgery, we had discussions with hospital management regarding indications within general surgery where the robotic platform might be useful. We then decided in our department to develop a program investigating the adoption of the robotic platform for the treatment of abdominal wall hernias. In the ROBUST hernia project, (*ROBotic Utility for the Surgical Treatment of hernias*) we planned to perform a pilot assessment of 50 groin hernias, 40 smaller ventral hernias and 10 wider ventral hernias requiring component separation. Dividing abdominal wall hernias in those 3 indications and posing the 3 questions about robotic assisted hernia surgery mentioned higher, left us with 9 research questions (Q1-Q9) to investigate (Figure 1).

### ***Starting robotic assisted laparoscopic surgery***

The robotic platform requires a teaching pathway to safely implement it into clinical practice<sup>4</sup>. It is essential that the surgeon who is first starting robotic surgery follows the educational training modules online and commits to practice on the simulator. Once acquainted with the robotic platform, a clinical case observation of robotic surgery performed by an expert followed by hands-on training on cadavers, are obligatory steps towards clinical adoption. When performing the first cases using the robotic platform, the presence of an experienced proctor in the operating room is essential to overcome the initial insecurities a surgeon might experience when working with new robotic

technology. The importance of a comprehensive training pathway cannot be overestimated for safe introduction of robotic-assisted surgery. Also, selecting easy and straightforward procedures in the beginning is recommended. For abdominal wall surgery, 25 uncomplicated inguinal hernia repairs as part of the initial case series will create the skill set and proficiency to continue with more complex ventral hernia cases.

<b>A</b>	<b>Groin</b>	<b>Ventral</b>	<b>roboTAR</b>
<b>1 It takes too long !</b>	<b>Q1</b>	<b>Q4</b>	<b>Q7</b>
<b>2 It is too expensive !</b>	<b>Q2</b>	<b>Q5</b>	<b>Q8</b>
<b>3 Is there a clinical benefit !</b>	<b>Q3</b>	<b>Q6</b>	<b>Q9</b>

<b>B</b>	<b>Groin</b>	<b>Ventral</b>	<b>roboTAR</b>
<b>1 It takes too long !</b>	<b>no</b>	<b>no</b>	<b>no</b>
<b>2 It is too expensive !</b>	<b>yes</b>	<b>no</b>	<b>no</b>
<b>3 Is there a clinical benefit !</b>	<b>no</b>	<b>yes</b>	<b>yes</b>

**Figure 1**

- A. Nine research questions identified for the adoption of robotic hernia repair
- B. Personal current opinion on the 9 research questions after 3 years of adopting robotic-assisted hernia repair with experience from 798 procedures  
roboTAR=robotic-assisted transversus abdominis release

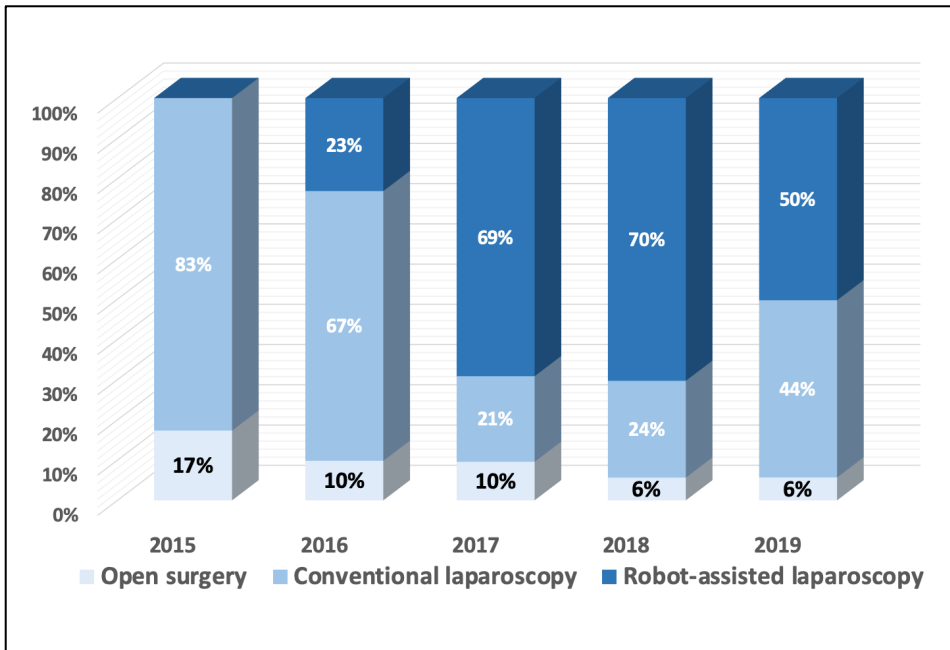
### ***Robotic-assisted laparoscopic groin hernia repair***

Most studies describing robotic-assisted inguinal hernia repair (rTAPP - robotic TransAbdominal PrePeritoneal) report longer operative times compared with conventional laparoscopic repair<sup>5</sup>. However, some reported similar operating times for rTAPP once the learning curve of the surgeon has been surpassed<sup>6,7</sup>. We prospectively analyzed the operating time of rTAPP groin hernia repair in our initial 50 cases<sup>7</sup>. We found that after a series of about 20 cases, the skin-to-skin operating time was similar both for unilateral and bilateral rTAPP. Also, in a larger study where we compared 272 conventional TAPP versus 404 rTAPP inguinal hernia repairs, the median operating time was comparable, with 47 min versus 45 min for unilateral repairs and 62 min versus 60 min for bilateral repairs respectively<sup>8</sup>.

Most studies have found rTAPP to be significantly more expensive than conventional laparoscopic surgery. In a study on the economic assessment of adopting robotic-assisted inguinal hernia repair we found that the robotic approach had an extra mean cost of €649 in our hospital<sup>8</sup>. This higher cost will limit the potential for adopting a robotic approach for all uncomplicated inguinal hernias. Nevertheless, we do think that rTAPP inguinal hernia repair is probably the best index operation for surgeons to learn how to handle the robotic platform and acquire essential skills needed for more complex abdominal wall hernia repairs. The surgeon is able to obtain the necessary experience with docking, robotic instrumentation, dissection, suturing and mesh handling during a well standardized and common surgical indication. We recommend that any surgeon and operating room team who are commencing a robotic hernia program follow the pathway of completing 25 inguinal hernia repairs before moving on to more complex ventral hernia repairs.

Is there a clinical benefit for inguinal hernia patients operated with the robotic platform compared with conventional laparoscopy? Conclusions in literature are heterogeneous. A systematic literature review from 2018 noted lower postoperative complications in rTAPP compared with open inguinal hernia repair, but did not find a difference between rTAPP and conventional TAPP<sup>5</sup>. Also, the only RCT currently published on the topic did not find any significant clinical benefit at 30 days postoperatively<sup>9</sup>. Clinical outcomes for laparoscopic inguinal hernia repair, both with and without the robotic platform, proved to be excellent in our patients<sup>8</sup>. Figure 2 depicts the evolution in our approach for inguinal hernia treatment and shows an increase in minimal invasive approaches and a decrease in the utilization of the open approach from 17% in 2015 to 6% in 2019. A group of complex inguinal hernias that we initially addressed consistently with an open

approach before adoption of the robotic platform, is now being treated minimally invasive due to enhanced visualization, availability of wristed instruments and a more stable operating field. Others have seen a similar shift towards a robotic approach for these complex inguinal hernias such as: inguinal hernias after previous abdominal prostatectomy, large non-reducible inguinoscrotal hernias and recurrences after previous preperitoneal meshes<sup>6</sup>. More specifically, patients who need removal of a previous preperitoneal mesh seem to benefit greatly from the technological advantages that the robotic platform offers.

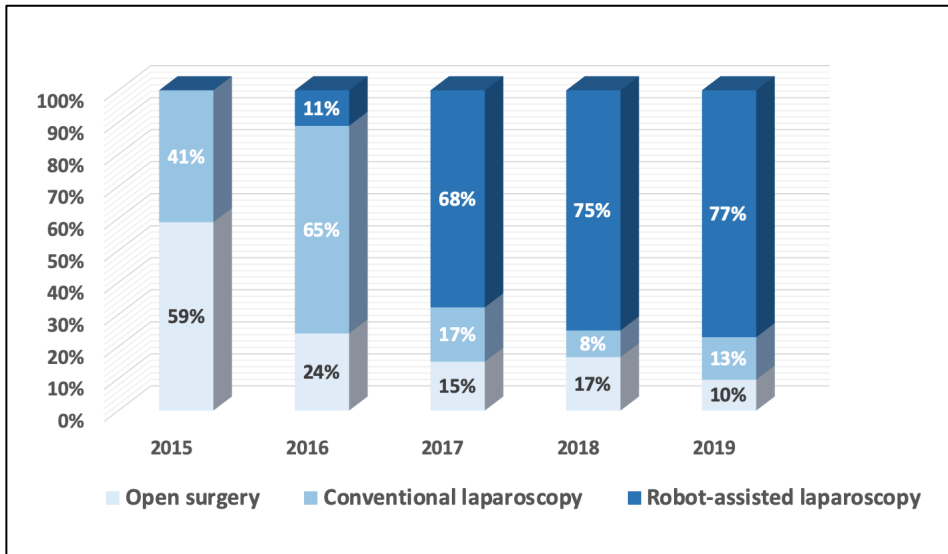


**Figure 2** - Evolution in surgical approach for groin hernias in a single center experience in 864 patients

### ***Robotic-assisted laparoscopic ventral hernia repair***

For many years we have used small round mesh devices to treat small and medium sized ventral hernias. This is often a quick and straightforward procedure, but already early in our experience we reported some severe adverse events related to the use of these intraperitoneal mesh devices<sup>10</sup>. Moreover, we reported a high recurrence rate for ventral hernias larger than 2 cm<sup>11</sup>. This is probably due to the fact that these mesh devices are limited in size and thus have a restricted amount of overlap beyond the hernia defect.

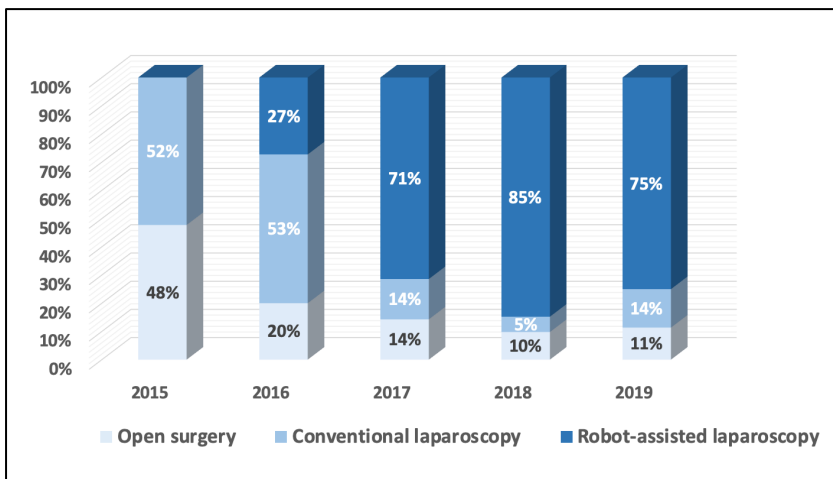
Therefore, we now prefer larger flat meshes for the repair of medium and large ventral hernias. There are several anatomical planes one can use to place mesh. Laparoscopic surgery has shown an advantage with less wound morbidity and traditionally is performed with an intraperitoneal mesh fixed with sutures and/or tackers. However, there is increasing evidence that subsequent abdominal surgery after previous intraperitoneal mesh placement has an increased risk of morbidity related to adhesions<sup>12-13</sup>. Other options are now increasingly used to avoid intraperitoneal mesh placement. In ventral TAPP, a mesh is placed in the preperitoneal plane. This allows the use of a cheaper, uncoated mesh, while the peritoneal layer functions as antiadhesive barrier between the mesh and the viscera. Another option is utilization of the retromuscular plane. In minimally invasive retromuscular ventral hernia repair, the technique as described by Rives<sup>14</sup> and Stoppa<sup>15</sup> to repair ventral hernias with a retrorectus mesh placement within the rectus sheath, can be performed via an endoscopic approach. The retrorectus plane is approached either through a limited incision on the midline (MILOS approach: Minimal Invasive or Less Open Sublay repair), via a transabdominal approach (TARUP: Trans Abdominal Retromuscular Umbilical Prosthesis) or via an extraperitoneal approach (eTEP access: extended Totally Extra Peritoneal access).



**Figure 3** - Evolution of surgical approach for primary ventral hernias in a single center experience in 438 patients

In our practice, the TARUP technique is the preferred approach to access the retrorectus plane for repair of ventral hernias. It was previously described by Chowbey et al in 2003

and by Schroeder et al in 2013 using conventional laparoscopy<sup>16-17</sup>. They found the technique to be safe and effective, but technically demanding. Using the robotic platform, the TARUP technique has been facilitated and is more reproducible. We reported on operative times comparable with open retromuscular repairs using similar sized meshes once the learning curve had been surpassed<sup>18</sup>. The robotic TARUP technique allows placement of a mesh with enough overlap beyond the hernia defect to establish a durable repair. Moreover, the extraperitoneal positioning of the mesh avoids the life-long presence of an intraperitoneal mesh, and avoids the need for penetrating mesh fixation with sutures or tackers. Therefore, a decrease in postoperative pain related to this penetrating fixation is anticipated. Although the cost for instrumentation of a robotic approach is higher, it allows the avoidance of a more expensive composite intraperitoneal mesh and tackers, which makes this treatment change cost neutral. Figure 3 depicts our transition from open surgery towards minimal invasive robotic-assisted repair of primary ventral hernias and figure 4 demonstrates a similar trend for incisional hernias. The changes in our preferential anatomical plane for mesh repair are illustrated in Figure 5, with a large increase in retrorectus repairs and a decrease in intraperitoneal mesh placement. We believe that the adoption of the robotic approach for ventral hernias has allowed us to perform more durable repairs, with less postoperative pain from penetrating mesh fixation and a decreased the risk of potential adverse events from adhesions to the intraperitoneal mesh.

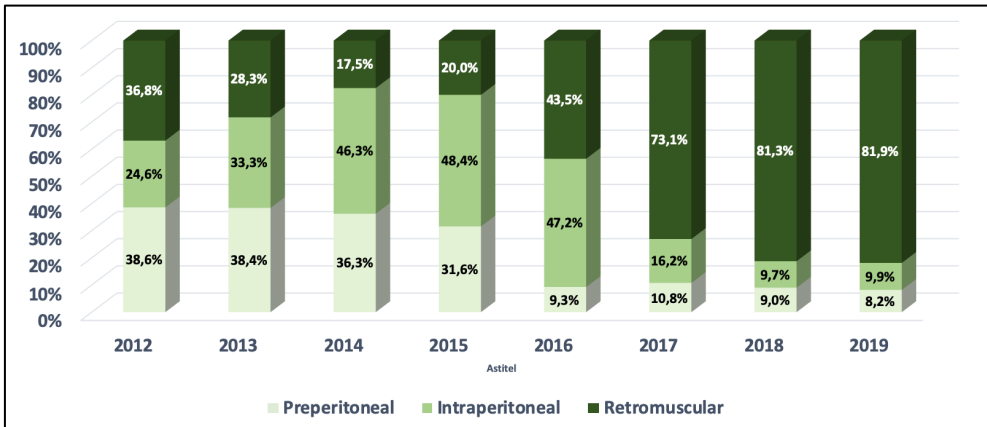


**Figure 4** - Evolution of surgical approach for incisional ventral hernias in a single center experience in 451 patients



**Robotic-assisted component separation technique**

We are confident that the main clinical value in adopting the robotic platform for hernia repair lies in the treatment of wide incisional hernias where a component separation technique is needed to close the hernia defect and place a large mesh. Traditionally, we performed a posterior component separation by TAR (Transversus Abdominus Release) using an open approach in those patients. These procedures have a significant risk of wound morbidity, a prolonged hospital stay and a prolonged interval to return to normal mobility and oral intake. We found that performing a minimal invasive approach for these complex abdominal wall reconstructions resulted in a significant decrease in hospital stay. This is in line with other case series describing a remarkable reduction in hospital stay for robotic-assisted surgery for incisional hernia<sup>19-22</sup>. This is likely related to earlier mobilization due to decreased postoperative pain and less postoperative ileus, which is often seen in the early postoperative period following open extensive abdominal wall reconstruction. Although evidence from high quality prospective studies is still lacking, we are convinced by our clinical experience that it is only a matter of time before this evidence will emerge.



**Figure 5** - Evolution of mesh position for surgical repair of ventral hernias in a single center experience in 938 patients

## References

1. Sheetz K, Claflin J, Dimick J. Trends in the Adoption of Robotic Surgery for Common Surgical Procedures. *JAMA Netw Open* 2020; 3: e1918911.
2. Muysoms F, Campanelli G, Champault G, DeBeaux A, Dietz U, Jeekel J et al. EuraHS: the development of an international online platform for registration and outcome measurement of ventral abdominal wall hernia repair. *Hernia* 2012; 16: 239–50.
3. Menon M, Tewari A, Peabody J et al. Vattikuti Institute prostatectomy, a technique of robotic radical prostatectomy for management of localized carcinoma of the prostate: experience of over 1100 cases. *Urol Clin North Am* 2004; 31: 701-17.
4. Soomro N, Hashimoto D, Porteous A et al. Systematic review of learning curves in robot-assisted surgery. *BJS Open* 2020; 4: 27-44.
5. Henriksen N, Jensen K, Muysoms F. Robot-assisted Abdominal Wall Surgery: A Systematic Review of the Literature and Meta-Analysis. *Hernia* 2019; 23: 17-27.
6. Kudsi O, McCarty J, Paluvoi N, Mabardy A. Transition From Laparoscopic Totally Extraperitoneal Inguinal Hernia Repair to Robotic Transabdominal Preperitoneal Inguinal Hernia Repair: A Retrospective Review of a Single Surgeon's Experience. *World J Surg* 2017; 41: 2251-7.
7. Muysoms F, Van Cleven S, Kyle-Leinhase I, Ballecer C, Ramaswamy A. Robotic-assisted Laparoscopic Groin Hernia Repair: Observational Case-Control Study on the Operative Time During the Learning Curve. *Surg Endosc* 2018; 32: 4850-9.
8. Muysoms F, Vierstraete M, Nachtergaele F, Van Garsse S, Pletinckx P, Ramaswamy A. Economic assessment of starting robotic assisted laparoscopic inguinal hernia repair in a single centre retrospective comparative study, the EASTER study. *BJS Open* 2021 Jan 8. doi: 10.1093/bjsopen/zraa046. Epub ahead of print.
9. Prabhu A, Carbonell A, Hope W, Warren J, Higgins R, Jacob B et al. Robotic Inguinal vs Transabdominal Laparoscopic Inguinal Hernia Repair: The RIVAL Randomized Clinical Trial. *JAMA Surg* 2020; 155: 380-7.
10. Muysoms F, Bontinck J, Pletinckx P. Complications of mesh devices for intraperitoneal umbilical hernia repair: a word of caution. *Hernia* 2011; 15: 463–8.

11. Bontinck J, Kyle-Leinhase I, Pletinckx P, Vergucht V, Beckers R, Muysoms F. Single centre observational study to evaluate the safety and efficacy of the Proceed Ventral Patch to repair small ventral hernias. *Hernia* 2014; 18: 671–80.
12. Patel P, Love M, Ewing J, Warren J, Cobb W, Carbonell A. Risks of subsequent abdominal operations after laparoscopic ventral hernia repair. *Surg Endosc* 2017; 31: 823-8.
13. Sharma A, Chowbey P, Kantharia N, Baijal M, Soni V, Khullar R. Previously implanted intra-peritoneal mesh increases morbidity during re-laparoscopy: a retrospective, case-matched cohort study. *Hernia* 2018; 22: 343-51.
14. Rives J, Pire J, Flament J, Convers G. Treatment of large eventrations (apropos of 133 cases). *Minerva Chir* 1977; 32: 749–56.
15. Stoppa R. The treatment of complicated groin and incisional hernias. *World J Surg* 1989; 13: 545–54.
16. Chowbey P, Sharma A, Khullar R, Soni V, Baijal M. Laparoscopic ventral hernia repair with extraperitoneal mesh: surgical technique and early results. *Surg Laparosc Endosc Percutan Tech* 2003; 13: 101-5.
17. Schroeder A, Debus E, Schroeder M, Reinpold W. Laparoscopic transperitoneal sublay mesh repair: a new technique for the cure of ventral and incisional hernias. *Surg Endosc* 2013; 27: 648-54.
18. Muysoms F, Van Cleven S, Pletinckx P, Ballecer C, Ramaswamy A. Robotic transabdominal retromuscular umbilical prosthetic hernia repair (TARUP): observational study on the operative time during the learning curve. *Hernia* 2018; 22: 1101-11.
19. Warren J, Cobb W, Ewing J, Carbonell A. Standard laparoscopic versus robotic retromuscular ventral hernia repair. *Surg Endosc* 2017; 31: 324-32.
20. Martin-Del-Campo L, Weltz A, Belyansky I, Novitsky Y. Comparative analysis of perioperative outcomes of robotic versus open transversus abdominis release. *Surg Endosc* 2018; 32: 840-5.
21. Bittner J, Alrefai S, Vy M, Mabe M, Del Prado P, Clingempeel N. Comparative analysis of open and robotic transversus abdominis release for ventral hernia repair. *Surg Endosc* 2018; 32: 727-34.
22. Carbonell A, Warren J, Prabhu A, Ballecer C, Janczyk R, Herrera J et al. Reducing Length of Stay Using a Robotic-assisted Approach for Retromuscular Ventral

Hernia Repair: A Comparative Analysis From the Americas Hernia Society Quality Collaborative. *Ann Surg* 2018; 267: 210-17.



# Chapter 7

## Too limited use of prophylactic mesh after open AAA repair in Belgium and The Netherlands?

Maxime Dewulf  
Nick De Wever  
Isabelle Van Herzeele  
Barend M.E. Mees  
Filip Muysoms  
Nicole D. Bouvy

*European Journal of Vascular and Endovascular Surgery* 2022 February 24. Epub ahead of print.

doi: 10.1016/j.ejvs.2022.02.031.



The incidence of incisional hernias after open repair of an abdominal aortic aneurysm (AAA) varies between 21-38% during the first two years of follow-up, and up to 69% five years after surgery<sup>1,2</sup>. To date, there have been five randomized controlled trials (RCT) on the use of a prophylactic mesh after open AAA repair<sup>1,3</sup>. Four of them have demonstrated a significant reduction in incisional hernias at two to three years follow-up, without increasing postoperative or mesh-related complications. A fifth RCT did not report on favorable effects of an onlay prophylactic mesh, but is subject to several limitations<sup>4</sup>. The most recent guidelines by the European Hernia Society (EHS) suggest the use of a prophylactic mesh in high-risk patients (level of evidence: moderate, strength of recommendation: weak), and the use of a 4 to 1 suture to wound length ratio (4:1 SL/WL) for suture closure of the abdominal wall (level of evidence: low, strength of recommendation: weak)<sup>5</sup>. The European Society of Vascular and Endovascular Surgery (ESVS) guidelines (2019) state that prophylactic mesh augmentation of the midline may be considered after open AAA repair in high-risk patients for incisional hernia<sup>6</sup>. With this survey we aim to monitor current practice among Belgian and Dutch vascular surgeons regarding techniques to prevent incisional hernias after midline laparotomy in AAA repair.

An online survey was sent to all members of the Belgian Society for Vascular Surgery (BSVS) and the Dutch Society for Vascular Surgery (Nederlandse Vereniging voor Vaatchirurgie - NVvV) between January and May 2021, including an electronic reminder after one month. Practicing vascular surgeons, fellows in vascular surgery and general surgeons commonly performing open AAA repair were asked to complete the survey. Using a 35-question survey, the current practice, knowledge and concerns regarding prophylactic mesh placement after open AAA repair were assessed. The survey was designed and distributed using Google Forms (Google, California, US). Analysis of the anonymized data was performed using Microsoft Excel (Redmond, WE, US). Primary endpoint of the survey was the percentage of vascular surgeons in Belgium and The Netherlands using a 4:1 SL/WL and/or prophylactic mesh in the closure of the abdominal wall after open AAA repair.

We received 101 responses from vascular surgeons (48 from Belgium and 53 from The Netherlands). This implies that we received at least one answer from 62% of the Dutch and 43% of the Belgian hospitals performing open aortic surgery. Approximately two thirds of the respondents (67.3%) work at a general hospital, while 25.7% work in a university medical center.



Details on the practice patterns regarding techniques to prevent incisional hernias after open AAA repair are listed in Table 1. Two thirds (66.1%) of surgeons prefer the use of lightweight mesh and 21.4% use a composite mesh. A minority of respondents (19.8%) believes prophylactic mesh reinforcement should be done by a hernia surgeon. The width of the mesh used varied between 5 and 10 centimeters in 43.5%, while 21.0% of surgeons uses a mesh that is more than 15 cm wide. A retromuscular mesh position is preferred by 40.0% of respondents, preperitoneal mesh placement by 28.3%. An onlay mesh is used by 26.7% of surgeons, 5.0% uses an intraperitoneal mesh.

Both the use of a 4:1 SL/WL and the use of prophylactic mesh after open AAA repair remain an uncommon practice among vascular surgeons in Belgium and The Netherlands, despite currently available evidence supporting both the use of a 4:1 SL/WL and of a prophylactic mesh after open AAA repair in preventing incisional hernias. RCTs did not show an increase in mesh-related complications, which has been reported as the main reason not to use mesh in this survey<sup>1,3</sup>. By relying on voluntary response, this survey may be subject to response bias. Surgeons that have strong opinions on the topic or great interest in ongoing literature were probably more likely to respond. This may have led to an overestimation of the use of prophylactic mesh. As these number were low among respondents, it is unlikely that this would significantly change overall conclusions of this research letter. Due to privacy reasons, we were not able to objectively report on response rates. This was addressed by reporting on the proportion of centers from which we received at least one answer, but limits the interpretation of our findings. Whether placement of a prophylactic mesh after AAA repair should be done by a dedicated abdominal wall surgeon is debatable. However, in most of the available studies supporting its use, hernia surgeons placed the prophylactic mesh. A clear recommendation in future guidelines - supported by well-designed trials with longer follow-up - could lead to a more widespread adoption of a 4:1 SL/WL and the use of prophylactic mesh among vascular surgeons.

**Table 1 - Practice patterns of respondents**

Statement	Number of respondents <i>n</i> (%)
<b>What suture-to-wound-length ratio do you aim for when closing the abdominal wall?</b>	
None	3 (3.0%)
1:1	11 (10.9%)
2:1	12 (11.9%)
3:1	29 (28.7%)
4:1	45 (44.6%)
<b>What is your common practice for the use of prophylactic mesh covering the midline after AAA repair?</b>	
I never use prophylactic mesh	47 (46.5%)
I am considering using prophylactic mesh, but have not done so yet	24 (23.8%)
I have used prophylactic mesh, but I no longer do so	4 (4.0%)
I use prophylactic mesh, but only in selected patients	19 (18.8%)
I use prophylactic mesh in every patient	7 (6.9%)
<b>Do you think there is sufficient high-quality evidence supporting the use of prophylactic mesh in the prevention of incisional hernia after open abdominal aortic aneurysm repair?</b>	
Yes	33 (32.7%)
No	68 (67.3%)
<b>Why have you decided to not use prophylactic mesh in your current practice?*</b>	
Lack of evidence supporting the use of prophylactic mesh	27 (16.1%)
Technical challenge in mesh placement	11 (6.6%)
Increased operating time	51 (30.5%)
Risk for mesh-related complications	43 (42.6%)
Negative experiences in the past	3 (3.0%)
Costs of mesh	15 (14.9%)
Other	17 (16.8%)
<b>What would make you consider using a prophylactic mesh in the future?*</b>	
Nothing, I won't consider prophylactic mesh placement	6 (4.6%)
Better evidence supporting the use of prophylactic mesh	63 (48.1%)
More training in the use of prophylactic mesh	25 (19.1%)
Reduced cost of mesh	12 (9.2%)
Easy handling of mesh	15 (11.5%)
Other	10 (7.6%)

\*Respondents were allowed to choose multiple answers, percentages calculated based on total number of responses  
AAA=abdominal aortic aneurysm

## References

1. Indrakusuma R, Jalalzadeh H, van der Meij J, Balm R, Koelemay M. Prophylactic Mesh Reinforcement versus Sutured Closure to Prevent Incisional Hernias after Open Abdominal Aortic Aneurysm Repair via Midline Laparotomy: A Systematic Review and Meta-Analysis. *Eur J Vasc Endovasc Surg* 2018; 56: 120-28.
2. Alnassar S, Bawahab M, Abdoh A, Guzman R, Al Tuwajiri T, Louridas G. Incisional hernia postrepair of abdominal aortic occlusive and aneurysmal disease: five-year incidence. *Vascular* 2012; 20: 273-7.
3. Nicolajsen C, Eldrup N. Abdominal Closure and the Risk of Incisional Hernia in Aneurysm Surgery - A Systematic Review and Meta-analysis. *Eur J Vasc Endovasc Surg* 2020; 59: 227-36.
4. Honig S, Diener H, Kölbl T, Reinpold W, Zapf A, Bibiza-Freiwald E et al. Abdominal incision defect following AAA-surgery (AIDA): 2-year results of prophylactic onlay-mesh augmentation in a multicentre, double-blind, randomised controlled trial. *Updates Surg* 2021 Jul 21. doi: 10.1007/s13304-021-01125-0. Epub ahead of print.
5. Muysoms F, Antoniou S, Bury K, Campanelli G, Conze J, Cuccurullo D et al. European Hernia Society guidelines on the closure of abdominal wall incisions. *Hernia* 2015; 19: 1-24.
6. Wanhainen A, Verzini F, Van Herzele I, Allaire I, Bown M, Cohnert T et al. Editor's Choice - European Society for Vascular Surgery (ESVS) 2019 Clinical Practice Guidelines on the Management of Abdominal Aorto-iliac Artery Aneurysms. *Eur J Vasc Endovasc Surg* 2019; 57: 8-93.





# Chapter 8

Prevention of incisional hernias by prophylactic mesh-augmented reinforcement of midline laparotomies for abdominal aortic aneurysm treatment  
5-year follow-up of a randomized controlled trial

Maxime Dewulf

Filip Muysoms

Tijl Vierendeels

Marc Huyghe

Marc Miserez

Martin Ruppert

Tim Tollens

Liesbeth van Bergen

Frederik Berrevoet

Olivier Detry

*Annals of Surgery* 2022 Jun 28. Epub ahead of print.

doi: 10.1097/SLA.0000000000005545.

## Abstract

**Introduction.** The incidence of incisional hernias (IHs) after open repair of an abdominal aortic aneurysm (AAA) is high. Several randomized controlled trials have reported favorable results with the use of prophylactic mesh to prevent IHs, without increasing complications. In this analysis we report on the results of the 60-month follow-up of the PRIMAAT trial (Ann Surg 2016; 263(4): 638-45).

**Methods.** In a prospective, multicenter, open label, randomized design, patients were randomized between prophylactic retrorectus mesh reinforcement (MESH group), and primary closure of their midline laparotomy after open AAA repair (NOMESH group). This article reports on the results of clinical follow-up after 60 months. If performed, ultrasonography or computed tomography were used for the diagnosis of IHs.

**Results.** Of the 120 randomized patients, 114 were included in the intention-to-treat analysis. Thirty-three patients in the NOMESH group (33/58 - 56.9%) and 34 patients in the MESH group (34/56 - 60.7%) were evaluated after 5 years. The cumulative incidence of IHs in the NOMESH group was 32.9% after 24 months and 49.2% after 60 months. No incisional hernias were diagnosed in the MESH group. In the NOMESH group, 21.7% (5/23) underwent reoperation within 5 years due to an IH.

**Conclusion.** Prophylactic retrorectus mesh reinforcement after midline laparotomy for the treatment of AAAs safely and effectively decreases the rate of IHs. The cumulative incidence of IHs after open AAA repair, when no mesh is used, continues to increase during the first 5 years after surgery, which leads to a substantial rate of hernia repairs.

**Keywords.** Incisional hernia - Prophylactic mesh - Abdominal aortic aneurysm - Randomized controlled trial

## Introduction

The incidence of incisional hernias (IHs) after open surgery for an abdominal aortic aneurysm (AAA) is high<sup>1-6</sup>. Observational studies have reported on an incidence of up to 69.1% of IHs within 5 years after surgery<sup>2,3</sup>. In a randomized controlled trial (RCT) comparing open to endovascular treatment of AAAs with 6 years of follow-up, IH was the main reason for reintervention in the group that underwent open surgery<sup>4</sup>. Several studies have been able to identify AAA as an independent risk factor for the development of an IH<sup>2,3,5</sup>. Despite the lack of a well-identified mechanism in the majority of cases, authors currently acknowledge the association of AAA and abdominal wall hernias as part of a connective tissue disorder<sup>6</sup>.

Several preventive measures have been proposed to decrease the risk of an IH after open abdominal surgery. For the primary closure of laparotomies, current guidelines advise the use of a slowly absorbable running suture, 'small bites' technique, and adherence to a 4 to 1 suture to wound length ratio (4:1 SL/WL)<sup>7,8</sup>. Furthermore, there is increasing evidence that the use of a prophylactic mesh diminishes the rate of IHs after laparotomy in high-risk patients, including those with AAAs<sup>1,9-13</sup>. To date, 5 RCTs have investigated the use of prophylactic mesh reinforcement (PMR) in patients undergoing open AAA repair<sup>9-13</sup>. Four of these have reported a significant decrease in IHs during a mid-term follow-up of 2 to 3 years, without an increase in overall or mesh-related complications<sup>9-12</sup>. One randomized trial, the AIDA-trial (abdominal incision defect following AAA-surgery), failed to demonstrate this benefit, and reported similar rates of IHs when comparing primary closure and the use of an onlay PMR<sup>13,14</sup>. However, inclusion numbers in this study were not met, and a significant lack of power limits the interpretation of these results. A recent pooled analysis confirmed the significant decrease in the incidence of IHs when PMR was used in patients undergoing open AAA repair. Surprisingly, this did not result in a significant reduction in the reoperation rates for IHs<sup>1,15</sup>. Whether this is because these IHs do not pose a clinically relevant problem, or because surgeons are reluctant to operate on patients with significant comorbidities remains grossly unknown and underreported<sup>1,9-13,15</sup>.

The most recent guidelines issued by the European Hernia Society (EHS) on the closure of midline laparotomies (2015) state that the use of prophylactic mesh in high-risk patients (including patients with an AAA) is suggested in elective cases<sup>7</sup>. At that point in time, evidence on this topic was considered weak, as only a single RCT in AAA patients had been published<sup>11</sup>. The European Society of Vascular and Endovascular



Surgery (ESVS) guidelines, published in 2019, state that prophylactic mesh augmentation of the midline may be considered after open AAA repair in patients at high-risk of IHs<sup>16</sup>. In 2019 a survey among hernia surgeons was conducted on the use of PMR in a general population of high-risk patients, illustrating that its use remains controversial, even among abdominal wall surgeons<sup>17</sup>.

## **Objectives**

This article reports on the long-term results of the PRIMAAT trial (Prevention of incisional hernias by prophylactic mesh augmented reinforcement of midline laparotomies for abdominal aortic aneurysm treatment), a randomized controlled trial comparing primary closure and PMR of the abdominal wall after midline laparotomy for open AAA repair<sup>9</sup>. By publishing the 5-year follow-up results, we aim to monitor if the protective effect of a prophylactic mesh regarding IHs continues beyond 2 years of follow-up, and report on the number of IH repairs in this patient group.

## **Methods**

The study was designed as a prospective, multicenter, open label, randomized trial. The study protocol was approved by the central Ethics Committee of the Gent University Hospital on November 6<sup>th</sup>, 2008 with the Belgian Trial Registration number B67080084346. Approval was obtained from the local ethics committees of each participating center prior to patient inclusions. No adjustments to the study protocol were made after the start of inclusions. Eight Belgian hospitals participated in the study. All patients who had a planned elective treatment of an AAA through a midline laparotomy were considered eligible for inclusion. Details on inclusion and exclusion criteria, and sample size calculation can be found in the publication reporting on the 24-month follow-up of the PRIMAAT trial<sup>9</sup>. The study was registered online on September 18<sup>th</sup>, 2008, with the Clinicaltrials.gov identifier NCT00757133. A signed informed consent was obtained from each included patient before randomization. Computer-generated block randomization per 6 patients was performed in a 1:1 allocation ratio.

Patients were randomized either to a conventional laparotomy closure (NOMESH group) or a closure of the abdominal wall with PMR (MESH group). After completion of the AAA repair, closure of the midline laparotomy was performed by an abdominal wall surgeon. In the NOMESH group, the abdominal wall was closed with a slowly absorbable running suture (polydioxanone) with a SL/WL ratio of 4 to 1. In patients randomized to the MESH group, the midline laparotomy was closed using a

prophylactic large pore, partially absorbable and lightweight polypropylene mesh of 7.5 cm in width (Ultrapro, Ethicon Inc; Johnson & Johnson, Somerville, NJ). The mesh was placed in the retrorectus position, and both anterior and posterior rectus fascia were closed using a slowly absorbable running suture (polydioxanone). Additional details on the surgical technique can be found in the original publication of the PRIMAAT trial<sup>9</sup>.

A clinical follow-up by the abdominal wall surgeon was scheduled at 1 month, 12 months, 24 months and 60 months after surgery. A radiological evaluation of the abdominal wall was not routinely performed. Ultrasonography (US) or computed tomography (CT), performed in case of dubious clinical evaluation or for other indications (e.g. follow-up) was used for the diagnosis of IHs. Patients and vascular surgeons were blinded for the allocated treatment arm.

The primary endpoint of the study was the incidence of IHs 24 months after surgery. IH was defined as 'any abdominal wall gap, with or without bulge, in the area of the midline scar perceptible or palpable by clinical examination or imaging'. For this long-term evaluation 60 months after surgery, the same follow-up methods and definitions were used. All data regarding the 60-month follow-up was gathered by the study secretariat of Maria Middelaers Hospital, Gent, and double-checked by the first author (MD). The database was closed at the end of November 2021 and sent for analysis by an independent statistician.

### **Data analysis**

Descriptive statistics used were mean, standard deviation (SD), median, interquartile range (P25-P75) and proportions in % (n/N). Baseline characteristics of patients in the mesh and non-mesh study arms were compared according to the Mann-Whitney U test for continuous variables and Fisher's exact test for proportions. The cumulative incidences of IHs across the 5-year follow-up were computed using the Kaplan-Meier product limit estimator method. Since death or loss to follow-up were unrelated to the allocated treatment (Figure 1), competing risks are independent and Kaplan-Meier estimates of cumulative incidences can hence be assumed to be unbiased. The Log-rank test was used to compare the estimated cumulative incidence functions across study arms. Hazard ratios were not estimated as no IHs were observed in the MESH arm. Likewise, the rule-of-three method was used to obtain the 95% confidence interval for the zero cumulative incidence in this MESH arm. An alpha value of 0.05 was chosen to indicate statistical significance. All reported P-values are 2-tailed.

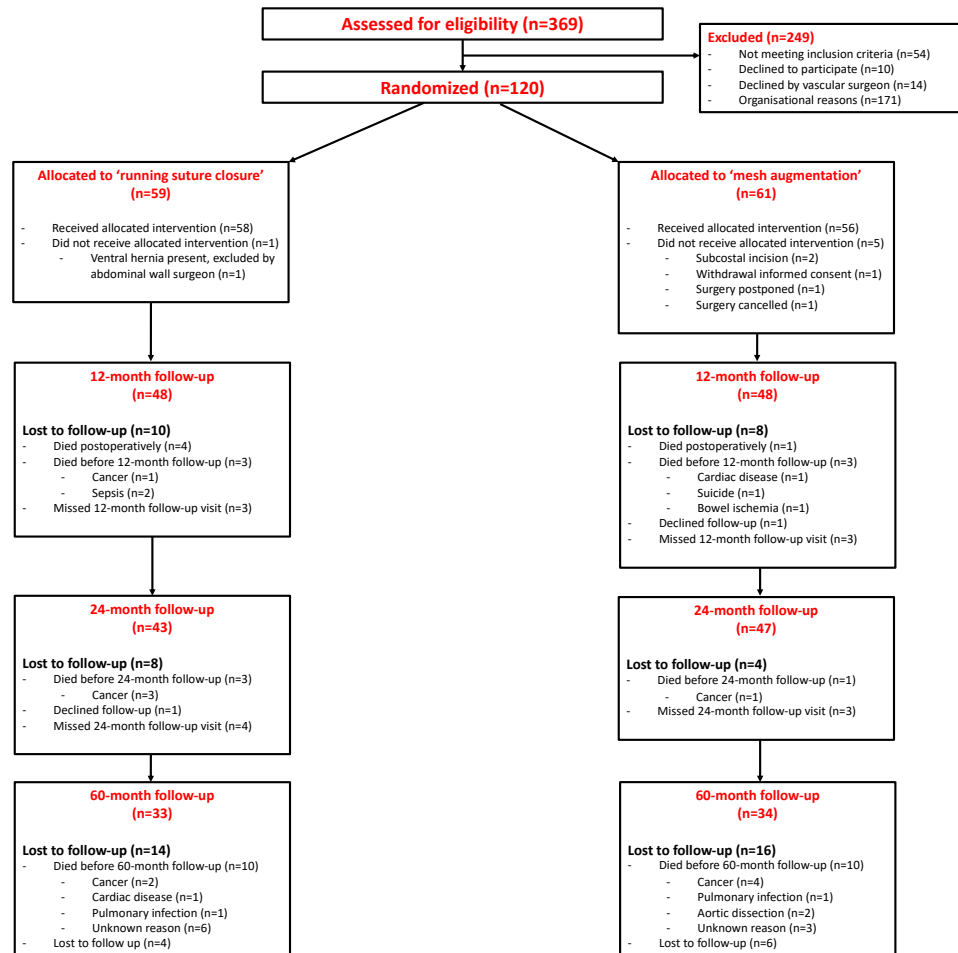
## Results

### ***Patients***

A CONSORT flow diagram of the study is shown in Figure 1. Of the 120 included patients, 114 received the allocated treatment and were included in the intention-to-treat analysis. Eventually, 33 patients in the NOMESH group and 34 patients in the MESH group were evaluated 60 months after the index surgery. In both study arms, 10 patients deceased between 24 and 60 months after surgery. Patients were enrolled in the study between February 2009 and January 2013. Follow-up visits for the 60-month follow-up were performed between February 2014 and October 2018.

Relevant patient characteristics at baseline and intraoperative details are listed in Table 1. A more detailed description of patient demographics and comorbidities, intraoperative details and short-term outcomes can be found in the paper reporting on the 24-month follow-up<sup>9</sup>. Regarding patient demographics, no statistically significant differences between groups were seen. Although not significant, there were more women in the NOMESH group. In 30.9% of the patients in the NOMESH group a SL/WL ratio  $\geq 4$  was measured, compared to 28.3% in the MESH group ( $p > 0.05$ ). Both skin-to-skin operative time (189.7 vs 211.5 min;  $p < 0.05$ ) and time to close the abdominal wall (29.6 vs 46.2 min;  $p < 0.001$ ) were significantly longer in the MESH group. In 4 patients in the MESH group, a seroma or hematoma was diagnosed 30 days after surgery. No other mesh-related complications were seen.

**Figure 1 - CONSORT flow diagram of 60-month follow-up**



**Table I - Demographics and intraoperative characteristics at baseline**

	<b>NOMESH N=58</b>	<b>MESH N=56</b>
<b>Patient characteristics at baseline</b>		
Age at the time of surgery (years)	71.9 (8.5)	72.3 (7.4)
Women	12.1% (7/58)	3.6% (2/56)
Body Mass Index (kg/m <sup>2</sup> )	26.5 (3.7)	25.5 (3.6)
ASA score:		
I - Normal health	8.8% (5/57)	9.1% (5/55)
II - Mild to moderate systemic disease	61.4% (35/57)	61.8% (34/55)
III - Serious systemic disease	29.8% (17/57)	29.1% (16/55)
IV - Life threatening systemic disease	0.0% (0/57)	0.0% (0/55)
<b>Intraoperative characteristics</b>		
SL/WL ratio	3.93 (1.61)	3.50 (0.98)
SL/WL ratio ≥ 4	30.9% (17/55)	28.3% (13/46)
Length of the mesh used (cm)	--	32.3 (3.7)
Mesh overlap beyond the incision (cm)	--	3.26 (0.81)
Skin-to-skin operative time (min)	189.7 (83.1)	211.5 (61.9)*
Time to close the abdominal wall (min)	29.6 (18.5)	46.2 (18.6)**

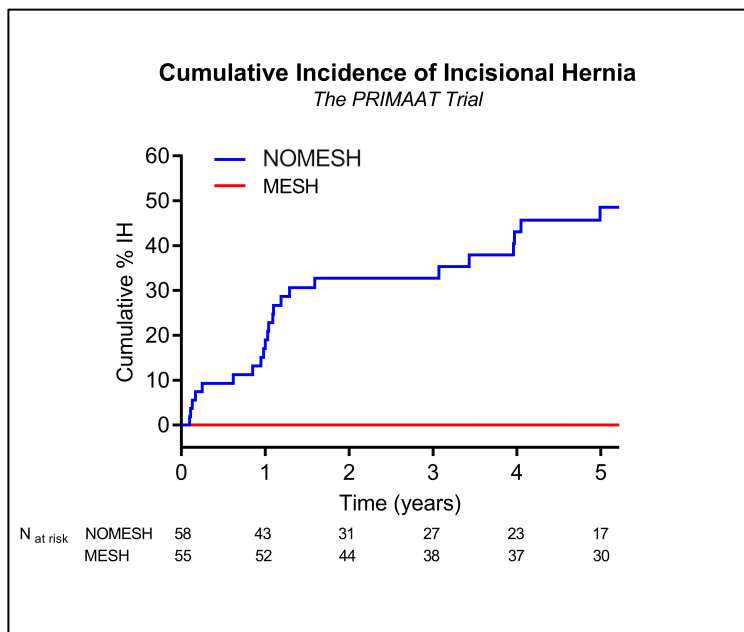
Data are reported as mean (standard deviation) or percentages (n/N)

\*P<0.05; \*\*P<0.001

ASA=American Society of Anesthesiology; SL/WL ratio=suture length to wound length ratio

## Outcome data

Outcome data of the 60-month follow-up is summarized in Table 2. Follow-up time in patients free of IH was comparable between groups, with a mean of 3.8 years in the NOMESH group, and 3.5 years in the MESH group. By the end of the studied period, 23 patients had been diagnosed with an incisional hernia in the NOMESH group, compared to 0 patients in the MESH group. The IH incidence rate per 100 person-years, indicating the number of IHS that would occur during a 1-year follow-up of 100 patients, was 14.5 in the NOMESH group, and 0.0 in the MESH group (Log-rank test:  $p < 0.0001$ ). The use of diagnostic imaging 5 years after surgery was equally distributed between the patient groups. A CT scan was performed in 39.4% of the patients in the NOMESH group and 41.2% in the MESH group. No radiological evaluation was performed in 39.4% of patients in the NOMESH group and 35.3% of patients in the MESH group. The estimated cumulative incidence of IHS during the first 60 months after surgery is depicted in Figure 2. Although less prominent than during the first 2 years, a further increase in the cumulative incidence of IHS was seen in the period between 2 and 5 years post-surgery. The cumulative incidence of patients developing an IH in the NOMESH group during the first 24 months following the index surgery was 32.9%. During the first 60 months, this was 49.2%.



**Figure 2** - Estimated cumulative incidence of incisional hernia

**Table 2 - Outcome data of 60-month follow-up in the PRIMAAT trial**

	NOMESH N=58	MESH N=56
<b>Follow-up time in patients free of IH (years)</b>		
Mean (SD)	3.8 (1.7)	3.5 (2.1)
Median (P25-P75)	5.0 (1.4-5.0)	5.0 (2.0-5.0)
<b>Number of IHs at 60-month follow-up</b>	23	0
<b>Diagnostic imaging at 60-month follow-up, % (n/N)</b>		
CT	39.4% (13/33)	41.2% (14/34)
Ultrasound	21.2% (7/33)	23.5% (8/34)
None	39.4% (13/33)	35.3% (12/34)
<b>IH incidence rate (per 100 person-years)</b>	14.5	0.0%*
<b>Cumulative incidence of IHs, % (95% CI)</b>		
at 1 year	16.4% (6.6%-26.1%)	0.0% (0.0%-5.6%)
at 2 years	32.9% (20.0%-45.8%)	0.0% (0.0%-6.4%)
at 5 years	49.2% (34.1%-64.2%)	0.0% (0.0%-10.3%)
<b>Characteristics of IH, % (n/N)</b>		
Symptomatic	17.4% (4/23)	--
Surgical repair during 60-month follow-up	21.7% (5/23)	--
Symptomatic patients that did not have hernia repair	4.3% (1/23)	--
Asymptomatic patients that underwent hernia repair	8.7% (2/23)	--

\*Log-rank test:  $\chi^2=18.93$ ,  $P<0.0001$

SD=standard deviation; IH=incisional hernia; CT=computed tomography;  
CI=confidence interval

In this study, 17.4% (4/23) of patients with an IH reported symptoms related to this hernia, and 21.7% (5/23) underwent IH surgical repair. Only 1 patient had a symptomatic IH that was not surgically treated.

## Discussion

### Results

The long-term results of this randomized trial confirm that the use of PMR after open AAA repair significantly decreases the IH incidence during the first 5 years after surgery. This is in concordance with currently available evidence that supports prophylactic mesh placement in patients undergoing AAA repair. Two meta-analyses have been published on PMR after open AAA repair, which evaluate the same 4 RCTs comparing primary fascial closure with PMR, including the 24-month follow-up of this trial<sup>1,9-12,15</sup>. Both the meta-analysis of Indrakusuma et al.<sup>1</sup> and the pooled analysis by Nicolajsen et al.<sup>15</sup> concluded that PMR significantly reduces the risk of IH after midline laparotomy for open AAA repair during a follow-up period of up to 3 years. This present trial is the first to report on long-term results. More recently, results of a fifth study, the AIDA-trial, have been published<sup>13</sup>. In this study, authors were not able to confirm a significant reduction in the rate of IHs with the use of PMR after open AAA repair, when compared to a suture closure using a 4:1 SL/WL with a slowly absorbable running suture. However, major methodological flaws and statistical limitations (e.g. insufficient power and the use of a large bites technique in the primary closure group) limit the interpretation of these findings<sup>14</sup>.

Reported studies on IH prevention vary regarding type of mesh and mesh position. Four of the published RCTs used a synthetic polypropylene mesh<sup>9-11</sup>, and one reported using a bovine pericardium mesh<sup>12</sup>. Both onlay and retrorectus mesh positions have been proposed and investigated, with no clear benefit shown for either of these approaches<sup>9-13</sup>. When an onlay mesh was used an increase in seroma formation was seen, although this did not lead to an increase in reinterventions, and generally did not pose a clinically relevant problem<sup>10,12,13</sup>. However, in a recent publication reporting on infectious complications during a 2-year follow-up of the PRIMA trial, a greater number of infectious complications were seen in the group that had an onlay mesh position, when compared to a retrorectus mesh position<sup>18</sup>. In the PRIMAAT trial, a retrorectus mesh placement was used. This is considered technically more challenging when compared to onlay mesh reinforcement. This fact may pose an additional threshold in performing PMR, especially in a population of vascular surgeons that have not been trained to perform IH repair.



During a 5-year follow-up period, 21.7% (5/23) of the patients in the NOMESH group underwent reoperation due to IHs. Even though surgeons may be reluctant to operate on IHs in AAA patients (who generally have significant comorbidities), reported reoperation rates for IH in the literature after open AAA repair vary between 9.3% and 10.4% during a follow-up period between 2 and 6 years<sup>1,15,19,20</sup>. Despite the fact that only 17.4% of patients with an IH reported hernia-related symptoms, these long-term results confirm the substantial rates of reoperation due to IHs when no PMR was performed. Several authors have shown that IHs do pose a clinically relevant problem, and are associated with a major economic burden on healthcare systems<sup>19-21</sup>.

### **Limitations**

This study is subject to several limitations that complicate the interpretation of these long-term results.

Firstly, closure of the abdominal wall was carried out by dedicated abdominal wall surgeons. As illustrated by the delay in inclusions and high levels of non-included eligible patients, this poses significant logistical problems<sup>9</sup>. Outside the study setting it is usually vascular surgeons who perform the closure of the abdominal wall. This may lead to other outcomes regarding adherence to a 4:1 SL/WL, incidence of IHs after primary closure of the abdominal wall, and possibly higher reluctance in using PMR after open AAA repair.

Secondly, only elective cases were included in this study. This limits the extrapolation of these results to all cases of open AAA repair, which are often performed as emergency surgery. Besides the fact that this study is underpowered to detect complications with low incidence rates (like mesh-related complications) it is uncertain if these beneficial outcomes are equally applicable to a population of patients that undergo emergency surgery. Increased operative times that were seen in the MESH group may add an additional threshold in case of emergency surgery.

Thirdly, no routine imaging was performed during follow-up. Current evidence and guidelines support the use of radiological evaluation to detect IHs within the setting of clinical studies<sup>7,13,22</sup>. Probably this has led to an underestimation of the incidence of IHs in the MESH group, which is illustrated by the absence of any IHs within this study arm. However, given the highly significant difference between groups regarding the primary endpoint, it is unlikely that routine imaging would have changed the overall conclusion of this paper.

To conclude, in only 30.9% of patients in the NOMESH group a SL/WL of more than 4 was achieved, despite the study protocol. Furthermore, this study did not report on the use of the small bites technique, which has proven to be superior to the use of larger bites in the suture closure of laparotomies<sup>8</sup>. A state-of-the-art closure of the abdominal wall, using a SL/WL of more than 4 in a small bites technique would probably have led to a lower incidence of IHs in the NOMESH group.

### **Future recommendations**

These long-term results illustrate that extending the follow-up period to a minimum of 5 years in studies that have IHs as a primary outcome adds highly relevant information. Traditionally, studies report on a follow-up period of 24 to 36 months, as recommended by the latest EHS guidelines<sup>7</sup>. However, observational studies in AAA patients have reported an increasing cumulative incidence of IHs after AAA repair up to 7 years after surgery, which is consistent with our findings<sup>23</sup>. Future studies with IHs as an endpoint should extend their follow-up period to a minimum of 5 years, and should use routine medical imaging by CT or dynamic US to detect abdominal wall hernias.

All currently available randomized trials comparing primary fascial closure with PMR in AAA patients aim for a 4:1 SL/WL in their study protocol. However, not a single one of them has reported on the small bites technique, and some have explicitly used a large bites technique in the primary fascial closure of the abdominal wall<sup>13</sup>. Future studies comparing primary fascial closure to PMR of the abdominal wall should use a small bites technique and a 4:1 SL/WL.

Current guidelines strongly advise the use of a 4:1 SL/WL following open AAA repair, but lack a strong recommendation for the use of PMR. The latest guidelines of the EHS (2015) require an update, as evidence on PMR has accumulated<sup>7,9,10,12,13</sup>. The 2019 ESVS AAA guidelines state that PMR 'may be considered' in high-risk patients, and that long-term results are awaited<sup>16</sup>. A clear recommendation in future guidelines - supported by this data with a longer follow-up period - could lead to a more widespread adoption of PMR among surgeons.

### **Conclusion**

Long-term results illustrate that a prophylactic retrorectus mesh reinforcement of the abdominal wall after midline laparotomy for the treatment of an AAAs safely and effectively decreases the rate of IHs. The cumulative incidence of IHs after open AAA

repair, when no mesh is used, continues to increase during the first 5 years after surgery, which leads to a substantial rate of hernia repairs.

## Funding

This trial was funded by research grants from Johnson & Johnson and the Belgian Section for Abdominal Wall Surgery. Surgeons received a fee for the administration related to the study per included patient. All meshes used in the study were provided by a material grant from Ethicon, Johnson & Johnson. The company was not involved in the design, conduct, follow-up or analysis of the trial.

## References

1. Indrakusuma R, Jalalzadeh H, van der Meij J, Balm R, Koelemay M. Prophylactic Mesh Reinforcement versus Sutured Closure to Prevent Incisional Hernias after Open Abdominal Aortic Aneurysm Repair via Midline Laparotomy: A Systematic Review and Meta-Analysis. *Eur J Vasc Endovasc Surg* 2018; 56(1): 120-28.
2. Alnassar S, Bawahab M, Abdoh A, Guzman R, Al Tuwajiri T, Louridas G. Incisional hernia postrepair of abdominal aortic occlusive and aneurysmal disease: five-year incidence. *Vascular* 2012; 20(5): 273-7.
3. Pannu R, McPhail IR. Prevalence of abdominal wall hernia in participants with abdominal aortic aneurysm versus peripheral arterial disease--a population-based study. *Angiology* 2012; 63(2):146-9.
4. De Bruin J, Baas A, Buth J, Prinssen M, Verhoeven EL, Cuypers P et al; DREAM Study Group. Long-term outcome of open or endovascular repair of abdominal aortic aneurysm. *N Engl J Med* 2010; 362(20): 1881-9.
5. Altieri M, Yang J, Jones T, Voronina A, Zhang M, Kokkosis A et al. Incidence of Ventral Hernia Repair after Open Abdominal Aortic Aneurysm and Open Aortofemoral or Aortoiliac Bypass Surgery: An Analysis of 17,594 Patients in the State of New York. *Am Surg* 2018; 84(8): 1388-93.
6. Antoniou G, Georgiadis G, Antoniou S, Granderath F, Giannoukas A, Lazarides M. Abdominal aortic aneurysm and abdominal wall hernia as manifestations of a connective tissue disorder. *J Vasc Surg* 2011; 54(4): 1175-81.
7. Muysoms F, Antoniou S, Bury K et al. European Hernia Society guidelines on the closure of abdominal wall incisions. *Hernia* 2015; 19: 1–24.
8. Deerenberg E, Harlaar J, Steyerberg E, Lont H, van Doorn H, Heisterkamp J et al. Small bites versus large bites for closure of abdominal midline incisions (STITCH):

- a double-blind, multicentre, randomised controlled trial. *Lancet* 2015; 386(10000): 1254-60.
9. Muysoms F, Detry O, Vierendeels T, Huyghe M, Miserez M, Ruppert M et al. Prevention of Incisional Hernias by Prophylactic Mesh-augmented Reinforcement of Midline Laparotomies for Abdominal Aortic Aneurysm Treatment: A Randomized Controlled Trial. *Ann Surg* 2016; 263(4): 638-45.
  10. Jairam A, Timmermans L, Eker H, Pierik R, van Klaveren D, Steyerberg EW et al; PRIMA Trialist Group. Prevention of incisional hernia with prophylactic onlay and sublay mesh reinforcement versus primary suture only in midline laparotomies (PRIMA): 2-year follow-up of a multicentre, double-blind, randomised controlled trial. *Lancet* 2017; 390(10094): 567-576. Erratum in: *Lancet*. 2017; 390(10094): 554.
  11. Bevis P, Windhaber R, Lear P, Poskitt K, Earnshaw J, Mitchell D. Randomized clinical trial of mesh versus sutured wound closure after open abdominal aortic aneurysm surgery. *Br J Surg* 2010; 97(10): 1497-502.
  12. Bali C, Papakostas J, Georgiou G, Kouvelos G, Avgos S, Arnaoutoglou E et al. A comparative study of sutured versus bovine pericardium mesh abdominal closure after open abdominal aortic aneurysm repair. *Hernia* 2015; 19(2): 267-71.
  13. Honig S, Diener H, Kölbel T, Reinpold W, Zapf A, Bibiza-Freiwald E; for AIDA study group. Abdominal incision defect following AAA-surgery (AIDA): 2-year results of prophylactic onlay-mesh augmentation in a multicentre, double-blind, randomised controlled trial. *Updates Surg* 2021 Jul 21. doi: 10.1007/s13304-021-01125-0. Epub ahead of print.
  14. Detry O, Berrevoet F, Muysoms F. Prevention of incisional hernia after midline laparotomy for abdominal aortic aneurysm repair. *Updates Surg* 2021 Sep 4. doi: 10.1007/s13304-021-01164-7. Epub ahead of print.
  15. Nicolajsen C, Eldrup N. Abdominal Closure and the Risk of Incisional Hernia in Aneurysm Surgery - A Systematic Review and Meta-analysis. *Eur J Vasc Endovasc Surg* 2020; 59(2): 227-36.
  16. Wanhainen A, Verzini F, Van Herzelee I, Allaire I, Bown M, Cohnert T et al. Editor's Choice - European Society for Vascular Surgery (ESVS) 2019 Clinical Practice Guidelines on the Management of Abdominal Aorto-iliac Artery Aneurysms. *Eur J Vasc Endovasc Surg* 2019; 57: 8-93.

17. Fischer J, Harris H, López-Cano M, Hope W. Hernia prevention: practice patterns and surgeons' attitudes about abdominal wall closure and the use of prophylactic mesh. *Hernia* 2019; 23(2): 329-34.
18. Van den Dop L, Sneider D, Kleinrensink G, Jeekel H, Lange J, Timmermans L. Infectious Complication in Relation to the Prophylactic Mesh Position: The PRIMA Trial Revisited. *J Am Coll Surg* 2021; 232(5): 738-45.
19. Gillion J, Sanders D, Miserez M, Muysoms F. The economic burden of incisional ventral hernia repair: a multicentric cost analysis. *Hernia* 2016; 20(6): 819-30.
20. Fischer J, Basta M, Wink J, Krishnan N, Kovach S. Cost-utility analysis of the use of prophylactic mesh augmentation compared with primary fascial suture repair in patients at high risk for incisional hernia. *Surgery* 2015; 158(3): 700-11.
21. Alli V, Zhang J, Telem D. Impact of incisional hernia development following abdominal operations on total healthcare cost. *Surg Endosc* 2018; 32: 2381–86.
22. den Hartog D, Dur A, Kamphuis A, Tuinebreijer W, Kreis R. Comparison of ultrasonography with computed tomography in the diagnosis of incisional hernias. *Hernia* 2009; 13(1): 45-8.
23. Gruppo M, Mazzalai F, Lorenzetti R, Piatto G, Toniato A, Ballotta E. Midline abdominal wall incisional hernia after aortic reconstructive surgery: a prospective study. *Surgery* 2012; 151(6): 882-8.



# Chapter 9

## Open versus robotic-assisted laparoscopic posterior component separation in complex abdominal wall repair

Maxime Dewulf\*

Juha M. Hiekkaranta\*

Elisa Mäkäräinen

Juha Saarnio

Maaïke Vierstraete

Pasi Ohtonen

Filip Muysoms

Tero Rautio

\*Shared first authorship

*BJS Open* 2022 May 2; 6(3): zrac057. Epub ahead of print.

doi:10.1093/bjsopen/zrac057.



## Abstract

**Background.** Transversus abdominis release (TAR) is a surgical technique used in the treatment of complex ventral hernias. The aim of this study was to compare outcomes of open (oTAR) versus robotic-assisted (rTAR) posterior component separation by TAR.

**Methods.** Consecutive patients at two European hernia centres who underwent bilateral TAR were included. Primary endpoint was the length of postoperative hospital stay.

**Results.** Data from 90 rTAR and 79 oTAR operations were evaluated. Patient demographics were similar between groups in terms of age, sex, body mass index and comorbidities. There were more smokers and hernias were larger in the oTAR group (width 8.7 cm vs 10.0 cm;  $p=0.031$ , length 11.6 cm vs 14.1 cm;  $p=0.005$ ). Length of postoperative hospital stay was significantly shorter in the rTAR group (3.4 days vs 6.9 days;  $p<0.001$ ). Short-term serious complications (Clavien-Dindo  $\geq$  grade III) were more frequent (20.3 % vs 7.8%;  $p=0.018$ ), and there were more surgical site infections (12.7% vs 3.3%;  $p=0.010$ ) in the oTAR group. During a median follow-up of 19 months in the rTAR group and 43 months in the oTAR group, reoperation (4.4% vs 8.9%;  $p=0.245$ ) and recurrence rates (5.6% vs 5.1%;  $p>0.9$ ) were similar.

**Conclusion.** Patients with ventral incisional hernias who undergo bilateral rTAR had significantly shorter postoperative hospital stays and less short-term complications compared to patients undergoing bilateral oTAR.

**Keywords.** Incisional hernia - Component separation - Robotic surgery - Transversus abdominis release

## Introduction

The retrorectus position is often considered the most favorable plane for abdominal wall reconstruction<sup>1,2</sup>. Closure of the hernia defect is important<sup>3</sup>, although some incisional hernias are too wide to perform a closure of the defect without additional surgical techniques. Component separation techniques (CST) of the lateral abdominal wall muscles increase the likelihood of medializing the edges of a midline hernia defect and achieving a tension free defect closure<sup>4</sup>. When compared to open anterior component separation techniques (ACST), posterior component separation techniques (PCST) have the advantage that there is no need to create large subcutaneous skin flaps, minimizing additional morbidity<sup>5</sup>. In 2012, Novitsky et al. described the open technique of transversus abdominis release (TAR), that allows mesh placement in the retrorectus and retromuscular position behind all three lateral abdominal wall muscles, after creation of a large retromuscular and preperitoneal space<sup>6</sup>. More recently, TAR has been performed using minimally invasive laparoscopic techniques<sup>7,8</sup>, but these complex abdominal wall reconstructions requiring TAR are technically challenging to perform with laparoscopic instruments, because of the limited workspace and restricted angulation of instruments. These limitations have been overcome by the introduction of robotic-assisted surgery<sup>9</sup>. Robotic-assisted TAR (rTAR) is similar to open TAR (oTAR) in terms of defect closure and retromuscular mesh position, but adds the benefits of minimally invasive surgery. Detailed descriptions of the surgical technique of rTAR have been published<sup>10,11</sup>. rTAR has rapidly gained popularity in recent years. Short-term results have been described and a recent meta-analysis comparing early outcomes after rTAR and oTAR demonstrated fewer complications and shorter length of postoperative hospital stay (LOS) in favour of the robotic approach<sup>12</sup>.

The aim of this study was to compare outcomes after oTAR and rTAR at 2 European hernia centres. The primary endpoint of the study was LOS. Secondary endpoints were intraoperative complications, in-hospital complications, overall and surgical site related complications during the first 30 postoperative days, overall and surgical site related complications during the follow-up period, including hernia recurrence.

## Methods

### **Study design**

This was a 2-centre case-control study using a prospectively developed database (European Registry for Abdominal Wall Hernias (EuraHS)<sup>13</sup>) based on electronic clinical files from patients undergoing bilateral PCST (either open or robotic-assisted). The study protocol was sent for notification to the local ethics committee at Maria Middelaes hospital, Gent, on December 21<sup>st</sup> 2021, with reference number MMS.2021.068. The study protocol was published online on January 19<sup>th</sup> 2022, with clinicaltrials.gov identifier NCT05195957.

The study was performed at the departments of surgery at Oulu University Hospital, Oulu, Finland (OUH) and Maria Middelaes Hospital, Gent, Belgium (MMH). Patients were operated by a single surgeon in MMH and by two surgeons at OUH. An additional search of surgical logbooks was conducted at OUH to identify bilateral TAR patients not included in the database. The study included all consecutive patients undergoing bilateral PCST between December 2011 and October 2019 at MMH hospital where the rTAR technique was introduced in October 2016, and consecutive patients undergoing bilateral PCST between August 2017 and May 2021 at OUH. After the introduction of the rTAR technique at OUH, the choice between a robotic-assisted or open approach was mainly guided by the availability of the robotic platform. All patients had a follow-up visit during the first 3 months after surgery. At MMH, a routine clinical follow-up visit 1 year after surgery was performed. Hernia recurrence was based on clinical evaluation, with supplementary computed tomography (CT) if there was clinical uncertainty.

### **Study population**

All patients undergoing bilateral PCST for the treatment of their ventral incisional hernia, either open or robotic assisted, were considered eligible. Patients undergoing only unilateral PCST and patients with a stoma or parastomal hernia were excluded. The technique of rTAR was similar in both centres, since both surgeons at OUH were trained and proctored for their first cases by the participating surgeon from MMH. The robotic-assisted surgical procedures were performed using the DaVinci Xi or Si system (Intuitive Surgical, Sunnyvale, CA, USA).

## **Statistical analysis**

Data analysis was carried out using Microsoft Excel (Redmond, WE, US) and SPSS Statistics (Northcastle, NY, US). Continuous variables are presented as mean  $\pm$  standard deviation (SD). Categorical data are presented as percentages and proportions. Statistical analysis was performed according to the intention-to-treat principle. For normally distributed continuous variables, the Independent Samples t-test was used. When a normal distribution could not be assumed, the Mann-Whitney U test was used. The Chi-Squared or Fisher's exact test were used to compare categorical data. Additionally, a logistic regression and linear regression analyses were performed for the outcome parameters "serious postoperative complications" (Clavien-Dindo  $\geq$  III) within 30 days after surgery, and "length of postoperative hospital stay". In both models smoking and hernia width were used as adjusting factors. Results of the logistic regression analysis are presented as odds ratio (OR) with a 95% confidence interval (95% CI), and as regression coefficient with a 95% CI for the linear regression analysis. A two tailed p-value of less than 0.05 was considered statistically significant.

## **Results**

A total of 90 patients in the rTAR group and 79 patients in the oTAR group were included. Patient demographics are summarized in Table 1. No differences between patient groups were noted regarding age, sex, body-mass index (BMI) or comorbidities. There were significantly more smokers in the oTAR group. Hernias were larger in the oTAR group in both width and length of fascial defect (width 8.7 cm vs 10.0 cm;  $p=0.031$ , length 11.6 cm vs 14.1 cm;  $p=0.005$ ).

**Table I - Description of patient characteristics at baseline**

	rTAR (N= 90)	oTAR (N= 79)	p-value*
Age (years)	66 (11)	63 (14)	0.075
Women	63.3% (57/90)	53.2% (42/79)	0.181
Body Mass Index (kg/m <sup>2</sup> )	31 (8.5)	30 (5.3)	0.350
Current smoker	16.7% (15/90)	30.3% (23/76)	0.038
<b>Comorbidities</b>			
Cardiac disease	23.3% (21/90)	24.1% (19/79)	>0.9
Diabetes mellitus	18.9% (17/90)	16.5% (13/79)	0.680
Hepatic disease	1.1% (1/90)	0.0% (0/79)	0.261
Previous malignancy	25.6% (23/90)	29.1% (23/79)	0.604
Pulmonary disease	11.1% (10/90)	7.6% (6/79)	0.582
Renal disease	11.1% (10/90)	5.1% (4/79)	0.229
<b>Hernia characteristics</b>			
Recurrent incisional hernia	23.3% (21/90)	17.7% (14/79)	0.369
Hernia width (cm)	8.7 (3.2)	10.0 (4.4)	0.031
Hernia length (cm)	11.6 (5.3)	14.1 (6.2)	0.005

Continuous variables are reported as mean and standard deviation (in parentheses)  
Categorical variables are reported as percentages and proportions (in parentheses)

\*For normally distributed continuous variables, the Independent Samples t-test was used. When a normal distribution could not be assumed, the Mann-Whitney U test was used. The chi-squared and Fisher's test were used to compare categorical data. A p-value of less than 0.05 was considered statistically significant.

rTAR=robotic-assisted transversus abdominis release; oTAR=open transversus abdominis release

Intraoperative data are shown in Table 2. Skin-to-skin operative time was longer in the rTAR group (242 vs 188 minutes;  $p < 0.001$ ). In case of oTAR, all patients received prophylactic antibiotics prior to surgery, compared to 71.1% in the rTAR cases. Several large pore synthetic non-absorbable meshes were used (Table 2). The mean size of the mesh used was significantly larger in the oTAR group. Hernia defect closure rates were comparable between groups. Patients of the oTAR group underwent simultaneous operations more frequently (19.0% vs 1.1%;  $p < 0.001$ ). These included panniculectomy ( $n=9$ ), colostomy closure ( $n=2$ ), oncological colorectal resections ( $n=2$ ), lymph node removal ( $n=1$ ) and adrenalectomy ( $n=1$ ). One patient in the rTAR group underwent simultaneous scar removal.

**Table 2 - Description of intraoperative variables**

	rTAR (N= 90)	oTAR (N= 79)	p-value*
<b>Skin-to-skin operative time (minutes)</b>	242 (82)	188 (90)	<0.001
<b>Wound contamination class<sup>o</sup></b>			0.465
Clean	96.7% (87/90)	92.4% (73/79)	
Clean contaminated	2.2% (2/90)	5.1% (4/79)	
Contaminated	1.1% (1/90)	2.5% (2/79)	
Dirty	0.0% (0/90)	0.0% (0/79)	
<b>Antibiotic prophylaxis</b>	71.1% (64/90)	100.0% (79/79)	<0.001
<b>Mesh type used</b>			0.526
Polyester	75.6% (68/90)	77.2% (61/79)	
Polyvinylidene	18.9% (17/90)	21.5% (17/79)	
Polypropylene	2.2% (2/90)	1.3% (1/79)	
Unknown	3.3% (3/90)	0.0% (0/79)	
<b>Mesh size (cm<sup>2</sup>)</b>	980 (354)	1344 (460)	<0.001
<b>Hernia defect closure</b>	98.9% (89/90)	93.7% (74/79)	0.119
<b>Combined surgical procedure</b>	1.1% (1/90)	19.0% (15/79)	<0.001
<b>Intraoperative complications</b>	8.9% (8/90)	16.5% (13/79)	0.137

Continuous variables are reported as mean and standard deviation (in parentheses) Categorical variables are reported as percentages and proportions (in parentheses) \*For normally distributed continuous variables, the Independent Samples t-test was used. When a normal distribution could not be assumed, the Mann-Whitney U test was used. The chi-squared and Fisher's test were used to compare categorical data. A p-value of less than 0.05 was considered statistically significant.

<sup>o</sup>according to the center for disease control and prevention (CDC) classification<sup>15</sup>  
rTAR=robotic-assisted transversus abdominis release; oTAR=open transversus abdominis release

There were 8 intraoperative complications in the rTAR group and 13 in the oTAR group ( $p=0.137$ ), the most frequent being bowel injury (16). Four of these were full thickness injuries, with one requiring bowel resection with anastomosis. Three severe bleeding complications occurred: one from the liver, one from the abdominal wall and one from the femoral vein. One patient had a small pleural injury.

There were 8 conversions from rTAR to oTAR (8/90; 8.9%) related to adhesions (8), severe bleeding (2), small bowel injury (1) and full thickness stomach injury (1).

Outcome data on primary and secondary endpoints can be found in Table 3. LOS was significantly longer in the oTAR group (3.4 days vs 6.9 days;  $p<0.001$ ). Since there were significantly more patients in the oTAR group that underwent simultaneous surgery, an additional analysis after exclusion of these patients still showed a significantly shorter LOS in the rTAR group (3.4 days vs 7.1 days;  $p <0.001$ ). In a linear regression analysis adjusting for the possible confounding factors "smoking" and "hernia width", the oTAR group had a 3.4 days (95% CI 1.8-5.0,  $p<0.001$ ) longer postoperative hospital stay.

In-hospital complications, overall complication rates and surgical site infections (SSI) during the first 30 postoperative days were significantly lower in the rTAR group, while surgical site occurrences (SSO), surgical site occurrences requiring percutaneous intervention (SSOPI), and readmission rates were similar.

Major postoperative complications (Clavien-Dindo  $\geq$  grade III) were significantly higher in the oTAR group (7.8% vs 20.3%;  $p=0.018$ ). After adjusting for smoking and hernia width, the oTAR group had an OR of 2.4 (95% CI 0.88-6.4,  $p=0.087$ ) for major postoperative complications. Two deaths occurred in each group within 30 days after surgery.

Follow-up was significantly longer in the oTAR group (43 vs 19 months;  $p<0.001$ ) and revealed a reoperation rate of 4.4% in the rTAR group and 8.9% in the oTAR group ( $p=0.246$ ). Hernia recurrence was similar between groups (5.6% vs 5.1%).

**Table 3 - Description of outcome variables**

	rTAR (N= 90)	oTAR (N= 79)	p-value*
<b>Length of postoperative hospital stay (days)</b>	3.4 (0.4)	6.9 (1.6)	<0.001
<b>In-hospital complications</b>			
Overall complications	8.9% (8/90)	26.6% (21/79)	0.002
Surgical site related complications	6.7% (6/90)	7.6% (6/79)	0.815
<b>30-day complications<sup>o</sup></b>			
No complications	70.0% (63/90)	49.4% (39/79)	0.003
Grade I	11.1% (10/90)	8.9% (7/79)	
Grade II	11.1% (10/90)	20.3% (16/79)	
Grade III	4.4% (4/90)	8.9% (7/79)	
Grade IV	1.1% (1/90)	8.9% (7/79)	
Grade V (mortality)	2.2% (2/90)	2.5% (2/79)	
<b>30-day surgical site related complications</b>			
SSI	3.3% (3/90)	12.7% (10/79)	0.010
Superficial infection	1	3	
Deep infection	-	6	
Mesh infection	2	1	
SSO	20.0% (18/90)	24.1% (19/79)	0.512
SSOPI	6.7% (6/90)	15.2% (12/79)	0.071
<b>30-day readmission rate</b>	4.4% (4/90)	7.6% (6/79)	0.386
<b>Follow-up time (months)</b>	19 (14)	43 (32)	< 0.001
<b>Reoperation rate during follow-up</b>	4.4% (4/90)	8.9% (7/79)	0.246
<b>Hernia recurrence during follow-up</b>	5.6% (5/90)	5.1% (4/79)	> 0.9

Continuous variables are reported as mean and standard deviation (in parentheses) Categorical variables are reported as percentages and proportions (in parentheses) \*For normally distributed continuous variables, the Independent Samples t-test was used. When a normal distribution could not be assumed, the Mann-Whitney U test was used. The chi-squared and Fisher's test were used to compare categorical data. A p-value of less than 0.05 was considered statistically significant.

<sup>o</sup>According to the Clavien-Dindo classification<sup>16</sup>

rTAR=robotic-assisted transversus abdominis release; oTAR=open transversus abdominis release; SSI=surgical site infection; SSO=surgical site occurrence; SSOPI=surgical site occurrence requiring procedural intervention

## Discussion

In this series rTAR was associated with significantly shorter postoperative hospital stay and fewer short-term postoperative complications compared to oTAR, at the expense of longer operative times. Hernia recurrence rates between groups were comparable, although the rTAR group had shorter follow-up.



Six cohort studies have reported outcomes of rTAR compared to oTAR<sup>14-19</sup>. Of these, two focused on hybrid robotic-assisted TAR<sup>14,17</sup>, the remaining four had sample sizes varying between 26 and 114 patients<sup>15-18</sup>. All demonstrated a significant decrease in LOS after rTAR, consistent with the present results. Regarding overall complications, only two studies reported a significant decrease in overall complications after rTAR<sup>14,16</sup>, although a recent meta-analysis identified a decrease in overall complications after pooling of results<sup>12</sup>. The significantly longer operative times when performing robotic-assisted TAR have been reported in all studies. With regards to short-term outcomes, only one study has reported outcomes beyond 30 days<sup>15</sup>.

While the current study looked at late outcomes, follow-up periods were markedly different with 19 months in the rTAR group, and 43 months in the oTAR group. This is an important limitation to this study, reflecting its observational nature and the later introduction of rTAR. The comparable recurrence rates should be therefore viewed with caution. The choice of the surgical technique varied between centres. At MMH, the implementation of the robotic platform into practice led to a shift from open to robotic-assisted surgery. After the introduction of the robot, only 9 open TARs were performed. This induced a potential selection bias, as patient and hernia characteristics may have influenced the surgeon's choice. At OUH, the choice of surgical technique was mainly dependent on the availability of the robot, which again could have led to a selection bias. More complex patients, prone to intra- and postoperative complications and longer operative times, may also have made up a larger proportion of the oTAR patients. Hernias and meshes used were significantly larger in the oTAR group, although it is worth noting that after adjusting for smoking and hernia width, LOS was still shorter in the rTAR group. A learning curve may have been included, with a possible influence on final outcomes, although no clear reduction in either operative times or complication rates seemed apparent with time. Current recommendations advocate the use of CT scan to detect hernia recurrence<sup>20</sup>. In this study, hernia recurrence was evaluated principally by clinical examination with CT scans used to resolve clinical uncertainty. The true recurrence rate may have been underestimated. This cohort study reports on data from two European high-volume hernia centres, so there remain questions about generalizability of these results.

Future investigations on this topic should have a prospective design and randomization between oTAR and rTAR. Recently, a proposal for a European multicentre randomized controlled trial has been presented at the 4th annual symposium on robotic abdominal wall surgery (Gent, Belgium). On the basis of the current results, such a study seems both ethically safe and timely.

## References

1. Parker S, Halligan S, Liang M, Muysoms F, Adrales G, Boutall A et al. International classification of abdominal wall planes (ICAP) to describe mesh insertion for ventral hernia repair. *Br J Surg* 2020; 107(3): 209-17.
2. Rives J, Pire J, Flament J, Convers G. Le traitement des grandes éventrations a propos de 133 cas) [Treatment of large eventrations (apropos of 133 cases)]. *Minerva Chir* 1977; 32(11): 749-56.
3. Tandon A, Pathak S, Lyons N, Nunes Q, Daniels I, Smart N. Meta-analysis of closure of the fascial defect during laparoscopic incisional and ventral hernia repair. *Br J Surg* 2016; 103(12): 1598-607.
4. Sneiders D, Yurtkap Y, Kroese L, Jeekel J, Muysoms F, Kleinrensink G et al. Anatomical study comparing medialization after Rives-Stoppa, anterior component separation, and posterior component separation. *Surgery* 2019; 165(5): 996-1002.
5. Balla A, Alarcón I, Morales-Conde S. Minimally invasive component separation technique for large ventral hernia: which is the best choice? A systematic literature review. *Surg Endosc* 2020; 34(1): 14-30.
6. Novitsky Y, Elliott H, Orenstein S, Rosen M. Transversus abdominis muscle release: a novel approach to posterior component separation during complex abdominal wall reconstruction. *Am J Surg* 2012; 204(5): 709-16.
7. Belyansky I, Daes J, Radu V, Balasubramanian R, Reza Zahiri H, Weltz A et al. A novel approach using the enhanced-view totally extraperitoneal (eTEP) technique for laparoscopic retromuscular hernia repair. *Surg Endosc* 2018; 32(3): 1525-32.
8. Radu V, Lica M. The endoscopic retromuscular repair of ventral hernia: the eTEP technique and early results. *Hernia* 2019; 23(5): 945-55.
9. Gokcal F, Morrison S, Kudsi O. Robotic retromuscular ventral hernia repair and transversus abdominis release: short-term outcomes and risk factors associated with perioperative complications. *Hernia* 2019; 23(2): 375-85.
10. Grossi J, Lee B, Belyansky I, Carbonell A, Cavazzola L, Novitsky Y et al. Critical view of robotic-assisted transverse abdominal release (r-TAR). *Hernia* 2021; 25(6): 1715-25.
11. Dietz U, Kudsi O, Garcia-Ureña M, Baur J, Ramser M, Maksimovic S et al. Robotic hernia repair III. English version: Robotic incisional hernia repair with transversus

- abdominis release (r-TAR). Video report and results of a cohort study. *Chirurg* 2021; 92(1): 28-39.
12. Bracale U, Corcione F, Neola D, Castiglioni S, Cavallaro G, Stabilini C et al. Transversus abdominis release (TAR) for ventral hernia repair: open or robotic? Short-term outcomes from a systematic review with meta-analysis. *Hernia* 2021; 25(6): 1471-80.
  13. Muysoms F, Campanelli G, Champault G, DeBeaux A, Dietz U, Jeekel J et al. EuraHS: the development of an international online platform for registration and outcome measurement of ventral abdominal wall hernia repair. *Hernia* 2012; 16(3): 239-50.
  14. Abdu R, Vasyluk A, Reddy N et al. Hybrid robotic transversus abdominis release versus open: propensity-matched analysis of 30-day outcomes. *Hernia* 2021; 25: 1491-7.
  15. Bittner J, Alrefai S, Vy M, Mabe M, Del Prado P, Clingempeel N. Comparative analysis of open and robotic transversus abdominis release for ventral hernia repair. *Surg Endosc* 2018; 32(2): 727-34.
  16. Dauser B, Hartig N, Vedadinejad M, Kirchner E, Trummer F, Herbst F. Robotic-assisted repair of complex ventral hernia: can it pay off? *J Robot Surg* 2021; 15: 45-52.
  17. Halka J, Vasyluk A, Demare A, Iacco A, Janczyk R. Hybrid robotic-assisted transversus abdominis release versus open transversus abdominis release: a comparison of short-term outcomes. *Hernia* 2019; 23(1): 37-42.
  18. Martin-Del-Campo L, Weltz A, Belyansky I, Novitsky Y. Comparative analysis of perioperative outcomes of robotic versus open transversus abdominis release. *Surg Endosc* 2018; 32(2): 840-45.
  19. Reeves J, Mehta S, Prabha R, Salama Y, Mittal A. Robotic versus open transversus abdominis release and incisional hernia repair: a case-control study. *Laparoscop Endoscop Robot Surg* 2020; 3(3): 59-62.
  20. Holihan J, Karanjawala B, Ko A, Askenasy E, Matta E, Gharbaoui L et al. Use of Computed Tomography in Diagnosing Ventral Hernia Recurrence: A Blinded, Prospective, Multispecialty Evaluation. *JAMA Surg* 2016; 151(1): 7-13.





# Chapter 10

Comment to:  
Transversus abdominis release (TAR) for ventral  
hernia repair: open or robotic? Short term outcomes  
from a systematic review with meta-analysis

Maxime Dewulf  
Dirk De Bacquer  
Filip Muysoms

*Hernia* 2022 January 19. Epub ahead of print.  
doi: 10.1007/s10029-022-02568-z.



Dear Editor,

It is with great interest that we read the article '*Transversus abdominis release (TAR) for ventral hernia repair: open or robotic? Short-term outcomes from a systematic review with meta-analysis*' that was recently published in *Hernia*<sup>1</sup>. The authors present a systematic review and meta-analysis on currently available evidence regarding robotic-assisted transversus abdominis release (rTAR), a novel technique that has gained rapid adoption in the treatment of complex ventral abdominal wall hernias. However, current evidence consists merely of observational retrospective data that all report on a statistically significant reduction in length of postoperative hospital stay after rTAR, when compared to open transversus abdominis release (oTAR). Regarding postoperative complications, most of the published patient series fail to demonstrate a significant benefit. Therefore, pooling of these data is indeed highly clinically relevant, and may add information on this technique that is rapidly gaining popularity. However, with this communication we would like to highlight two observations that drew our attention when reading this paper.

Eventually, 6 retrospective cohort studies were included in the pooled analysis of data. However, the two largest available patient series on hybrid rTAR (hrTAR) included in the meta-analysis, report on at least partially overlapping populations. Both articles originate from the same affiliation, the William Beaumont Hospital, Royal Oak, USA, and 5 co-authors of the second paper are the authors of the first paper. In the paper by Abdu et al., data on hrTAR operations were extracted from the Americas Hernia Society Quality Collaborative (AHSQC) for the period 2016-2018<sup>2</sup>. Data on hrTAR operations in the paper by Halka et al. were extracted from the same database (AHSQC), covering the period from August 2015 until July 2017<sup>3</sup>. This implies a possibly substantial, and certainly partial overlap of included patients. This observation was confirmed by the first author of the first article by Halka et al. and co-author of the second paper. When performing a pooled analysis, efforts should be made to avoid these type of duplications, or at least include this observation as a limitation when reporting or discussing the results.

Furthermore, the authors seem to have misinterpreted the results of their meta-analysis of continuous outcomes, i.e. differences between rTAR and oTAR patients in both operative time and length of hospital stay (LOS), as standardized mean differences (SMD). Pooling study-specific mean differences by means of a random effects model generates an estimated overall mean difference rather than a SMD, which has an entirely different meaning. Finally, the LOS data related to the study of Bittner et al. as depicted



in Figure 3G, are incorrect. Bittner et al. report means of 3.5 days and 6.7 days in rTAR patients and oTAR respectively, corresponding to a mean LOS difference of 3.2 days instead of the 7.5 days used in the meta-analysis<sup>4</sup>. Hence, the pooled mean LOS difference of 4.409 days is very likely to be an overestimation.

## References

1. Bracale U, Corcione F, Neola D, Castiglioni S, Cavallaro G, Stabilini C et al. Transversus abdominis release (TAR) for ventral hernia repair: open or robotic? Short-term outcomes from a systematic review with meta-analysis. *Hernia* 2021; 25(6): 1471-80.
2. Abdu R, Vasyluk A, Reddy N et al. Hybrid robotic transversus abdominis release versus open: propensity-matched analysis of 30-day outcomes. *Hernia* 2021; 25: 1491-7.
3. Halka J, Vasyluk A, Demare A, Iacco A, Janczyk R Hybrid robotic-assisted transversus abdominis release versus open transversus abdominis release: a comparison of short-term outcomes. *Hernia* 2019; 23(1): 37-42.
4. Bittner J, Alrefai S, Vy M, Mabe M, Del Prado P, Clingempeel N. Comparative analysis of open and robotic transversus abdominis release for ventral hernia repair. *Surg Endosc* 2018; 32(2): 727-34.





# Chapter 11

Robotic versus open component separation by transversus abdominis release in the treatment of ventral incisional hernia

Study protocol for an open-label multicenter international randomized controlled trial  
The ROCSTAR trial

Maxime Dewulf  
Maaïke Vierstraete  
Steffi Ryckaert  
Femke Nachtergaele  
Nicky Van Der Vekens  
Filip Muysoms

*Clinicaltrials.gov*

## Summary

### **Title**

Robotic versus open component separation by transversus abdominis release in the treatment of ventral incisional hernia: an open-label multicenter international randomized controlled trial

### **Short title**

ROCSTAR trial

### **Rationale**

In the treatment of ventral incisional hernias, a mesh repair in the retromuscular plane is considered as the golden standard. To allow for adequate medialization of the fascial borders and a complete closure of the defect in case of large incisional hernias, component separation techniques are increasingly being used. When compared to anterior component separation, posterior component separation by transversus abdominis release (TAR) seems to decrease postoperative wound problems. While laparoscopic techniques pose significant difficulties to perform TAR minimally invasively (mainly due to ergonomic and technical reasons), these limitations seem to be overcome by robotic platforms. Initial retrospective patient series report on significantly shorter postoperative hospital stay and fewer complications after robotic-assisted transversus abdominis release (rTAR), when compared to open transversus abdominis release (oTAR). High-quality prospective evidence on rTAR is currently lacking.

### **Main objective**

The main objective of this study is to compare the short-term outcomes after rTAR and oTAR in the treatment of ventral incisional hernias.

### **Endpoints**

#### *Primary endpoint*

Length of postoperative hospital stay (hours)

## *Secondary endpoints*

- Skin-to-skin operative time (minutes)
- Conversion rate
- Postoperative complications (Clavien-Dindo) - 30 days
- Surgical site infection (SSI) - 30 days
- Surgical site occurrence (SSO) - 30 days
- Surgical site occurrence requiring procedural interventions (SSOPI) - 30 days
- Readmission rate - 30 days
- Reoperation rate - 30 days
- Postoperative PADSS (post-anesthetic discharge scoring system - measured 3 times a day until discharge)
- Postoperative VAS pain score (measured 3 times a day until discharge)
- Use of pain medication postoperative (paracetamol/NSAID/milligram morphine equivalents/epidural analgesia)
- PROM monitoring using the EuraHS QoL score and body image scale (preoperatively, 30 days, 3 months, 12 months, 24 months, 60 months)
- Hernia recurrence (3 months, 12 months, 24 months, 60 months)
- Reoperation for hernia recurrence (3 months, 12 months, 24 months, 60 months)
- Abdominal surgery not for hernia recurrence (3 months, 12 months, 24 months, 60 months)
- Monitoring of total cost (direct + indirect)

## ***Inclusion criteria***

### *Patients*

All patients with a ventral incisional hernia of more than 8 centimeters in width, requiring bilateral component separation

### *Centers*

- Surgical centers located in Europe
- Proficiency in using the DaVinci robotic system by having completed at least 85 abdominal wall procedures, including 10 robotic TAR surgeries.
- Proficiency in performing both rTAR and oTAR, illustrated by two unedited video submissions of rTAR and picture documentation of two oTAR procedures from the first 2 procedures performed in each study arm for each participating center
- Adequate access to a DaVinci robotic platform

### **Exclusion criteria**

#### *Patients*

- Emergency surgery
- Pregnancy
- Age under 18
- Incisional hernia repair after open abdomen or enterocutaneous fistula
- Active wound infection
- Unilateral TAR
- Previous anterior or posterior component separation
- Absence of a signed informed consent
- Patients unable to give informed consent or complete the quality-of-life assessment (due to language barriers or intellectual capacity)
- Primary ventral hernias

### **Study design**

Open-label multicenter international randomized controlled trial

### **Planned interventions**

A 1:1 randomization will be performed between rTAR and oTAR

## **Administrative information**

### ***Trial registration (2a - 2b)***

ROCSTAR trial - The study protocol will be registered online on [clinicaltrials.gov](https://clinicaltrials.gov)

### ***Research protocol (3)***

Version 2.1, April 2022

This protocol was written in accordance to the standard protocol items: recommendations for interventional trials (SPIRIT) statement<sup>1</sup>

### ***Funding (4)***

This trial received research funding from:

- FEG Textiltechnik, Aachen, Germany
- Intuitive Surgical, Sunnyvale, CA, US

The funding sources have no involvement in the study design, and will have no involvement in the collection, management, analysis or interpretation of data, writing of reports or decision to submit results for publication.

### ***Principal investigator (5a)***

Dr. Filip Muysoms, MD PhD  
Department of Surgery  
AZ Maria Middelaers

Buitenring Sint-Denijs 30  
9000 Gent  
Belgium  
[filip.muysoms@azmmsj.be](mailto:filip.muysoms@azmmsj.be)



**Coordinating investigators**

Dr. Maxime Dewulf, MD  
Department of Surgery  
Maastricht University Medical Center +

P. Debyelaan 25  
6229 HX Maastricht  
The Netherlands

Dr. Maaïke Vierstraete, MD  
Surgical resident

**Names and contact information for the trial sponsor (5b-5c)**

Maria Middelaers Hospital  
Buitenring Sint-Denijs 30  
9000 Gent  
BELGIUM

**Advisory committee (5d)**

Dr. Conrad Ballecer, MD - Phoenix, Arizona, US  
Prof. Archana Ramaswamy, MD MBA - Minneapolis, Minnesota, US  
Prof. Ulrich Dietz, MD PhD - Olten, Switzerland  
Prof. Miguel Garcia Urena, MD PhD - Madrid, Spain

**Data safety monitoring committee**

Prof. Nicole Bouvy, MD PhD - Maastricht, The Netherlands  
Prof. Christophe Van Steenkiste, MD PhD - Gent, Belgium  
Prof. Dirk De Bacquer, MD PhD - Gent, Belgium

**Independent statistician**

Prof Dirk De Bacquer, MD PhD - Gent, Belgium

***Trial secretariat***

Clinical Research Center  
Department of Surgery  
AZ Maria Middelaes  
Buitenring Sint-Denijs 30  
9000 Gent  
Belgium

## Introduction

### **Background (6a-6b)**

Following abdominal surgery, the incidence of incisional hernia at 2 years is estimated to be around 13%, making the surgical treatment of incisional hernia one of the most performed surgical procedures by general surgeons. The Rives-Stoppa technique, consisting of a mesh-based repair in the retrorectus space, is now considered as the gold standard in the treatment of ventral incisional hernia<sup>2,3</sup>. However, in case of large hernia defects or long-lasting incisional hernias with significant laterally retracted rectus muscles, component separation techniques might be necessary to approximate fascial borders without significant tension<sup>4,5</sup>. Anterior component separation techniques implicate the creation of a large subcutaneous flap, and seem to increase postoperative wound morbidity when compared to posterior component separation<sup>6</sup>. Posterior component separation by TAR has been introduced by Novitsky et al. in 2012, and has rapidly gained popularity in the treatment of large incisional hernias<sup>7</sup>. Besides component separation, other techniques like peritoneal flap hernioplasty or preoperative botulinum toxin infiltration have been proposed to bridge or close large defects in incisional hernia repair, although they did not have similar widespread adoption as TAR, or are only being used in case of loss-of-domain<sup>8,9</sup>.

While TAR performed by traditional laparoscopy seems feasible in experienced hands, it does pose significant challenges - mainly due to ergonomic and technical reasons - that limit its widespread adoption. Robotic surgical platforms seem to overcome these difficulties, and rTAR is increasingly being performed. This minimally invasive approach seems to pose significant advantages over open surgery. Similar to other fields of general surgery (like colorectal or hepatobiliary surgery), a minimally invasive approach could allow for an enhanced recovery after surgery, and a decrease in complications (both in general and surgical site-related complications). However, high-quality evidence on rTAR is currently lacking. A recent systematic review identified only 6 retrospective series comparing rTAR with oTAR<sup>2,10-15</sup>. They reported on a significant shorter hospital stay and a decrease in complications in the group that underwent rTAR, when compared to oTAR. Significantly longer operative times were seen in the rTAR group.

The aim of this study is to compare short-term outcomes after rTAR, compared to oTAR. Due to the availability of robotic platforms and the development of minimally invasive techniques, there has been a major shift in the treatment strategies in abdominal wall

surgery and mesh position seems to shift from intraperitoneal to extraperitoneal. Increasing numbers of surgeons are adopting these robotic-assisted techniques for the treatment of incisional hernias. However, evidence is still lacking, and consists merely of retrospective patient series.

With this prospective randomized controlled trial comparing rTAR with oTAR we aim to undeniably illustrate the safety and feasibility of rTAR, and confirm initial promising results regarding short-term outcomes and complications. Our hypothesis is that rTAR significantly decreases postoperative length of stay, overall and surgical-site related complications, but comes at a price of a significantly longer operative time.

## **Objectives (7)**

### *Primary objectives*

The main objective of this study is to compare the short-term outcomes after rTAR and oTAR in the treatment of ventral incisional hernia. With this randomized controlled trial, we aim to collect high-quality evidence that confirms a significant decrease in length of hospital stay and general and surgical site-related complications, when comparing rTAR to oTAR.

### *Secondary objectives*

- Confirm the safety and feasibility of rTAR in a general population that requires bilateral TAR in the treatment of a ventral incisional hernia
- Compare postoperative pain after rTAR, compared to oTAR
- Compare quality-of-life scores after rTAR, compared to oTAR
- Compare outcomes in cosmesis after rTAR, compared to oTAR
- Compare recurrence rates after rTAR, compared to oTAR
- Compare total costs of rTAR versus oTAR

## **Trial design (8)**

The ROCSTAR trial is the first European multicenter trial to compare rTAR with oTAR, in a prospective, parallel-group, superiority, randomized, open-label, controlled, multicenter design. All patients requiring bilateral component separation for the treatment of their ventral incisional hernia will be considered eligible for inclusion. The

need for component separation will be based on a preoperative measurement of hernia dimensions. Patients with a hernia width of more than 8 centimeters will be considered eligible for inclusion. A web-based online central randomization method for the two study groups will be applied in a 1:1 ratio. Randomization will be performed two weeks preoperatively. Preoperative optimization using botulinum toxin infiltration, progressive pneumoperitoneum or weight loss will be left upon the surgeon's preference. Randomization will be performed after the decision to use preoperative optimization in order not to influence this decision according to the treatment arm. Included patients will be invited to the outpatient clinic 30 days, 3 months, 1 year, 2 years and 5 years after surgery for an assessment of outcomes. At 24 months additional imaging with Magnetic Resonance Imaging (MRI) will be included to evaluate hernia recurrence. In patients with a contra-indication for MRI, a computed tomography (CT) scan will be performed.

## **Methods: participants, interventions and outcomes**

### **Study setting (9)**

Participating centers are surgical centers with a special interest in hernia repair who have obtained adequate proficiency in performing both rTAR and oTAR. The following centers and site investigators will be invited to participate in the study:

1. Maria Middelaers Hospital, Gent, Belgium – Filip Muysoms
2. Oulu University Hospital, Oulu, Finland – Tero Rautio
3. OLVG Amsterdam, The Netherlands – Maarten Simons
4. Reinier de Graafziekenhuis, Delft, The Netherlands – Bob Bloemendaal
5. Rijnstate ziekenhuis, Arnhem, The Netherlands – Theo Aufenacker
6. Sint-Franciscus Gasthuis en Vlietland groep, Rotterdam, The Netherlands – Marijn Poelman
7. Klinikum Kempten, Kempten, Germany – Bjorn Muck
8. Städtische Klinikum Mönchengladbach, Mönchengladbach, Germany - Ulrich Pontenagel
9. Universidad Autónoma de Barcelona, Barcelona, Spain – Manuel Lopez-Cano
10. Universitat de Lleida, Lleida, Spain – Rafael Villalobos
11. Aristotle University of Thessaloniki, Greece – Pericles Chrysoheris
12. Bispebjerg Hospital, Copenhagen, Denmark – Kristian Kiim Jensen
13. Antwerp University Hospital, Antwerp, Belgium – Anthony Beunis

## **Eligibility criteria (10)**

### *Inclusion criteria*

#### Patients

All patients requiring bilateral component separation for the treatment of their ventral incisional hernia will be considered eligible for inclusion. Patients with a ventral incisional hernia of more than 8 centimeters in width will be included. In order to minimize selection bias, participating centers will be asked to keep a logbook of all patients that were treated for a ventral incisional hernia of more than 8 centimeters in width during the inclusion period, and reasons not to include patients will be noted.

#### Centers

- Surgical centers located in Europe
- Proficiency in using the DaVinci robotic system by having completed at least 85 abdominal wall procedures, including 10 robotic TAR surgeries.
- Proficiency in performing both rTAR and oTAR, illustrated by two unedited video submissions of rTAR and picture documentation of two oTAR procedures of the first two procedures in each study arm per center. These submissions will be evaluated by four members of the advisory committee to evaluate proficiency of participating surgeons. Based on the photographic documentation of oTAR and video submissions of rTAR, steps of the 'critical view of r-TAR' will be scored and evaluated<sup>16</sup>. This review of proficiency will be performed in a double-blinded manner. Feedback (and when applicable: remediation) will be provided to the participating surgeons after evaluation by the advisory committee.
- Adequate access to a DaVinci robotic platform

### *Exclusion criteria*

#### Patients

- Emergency surgery
- Pregnancy
- Age under 18

- Incisional hernia repair after open abdomen or enterocutaneous fistula
- Active wound infection
- Unilateral TAR
- Previous anterior or posterior component separation
- Absence of a signed informed consent
- Patients unable to give informed consent or complete the quality-of-life assessment (due to language barriers or intellectual capacity)
- Primary ventral hernias

## **Interventions**

### *Intervention description (11a)*

All participating surgeons are trained and proctored by the principal investigator, and have a similar and proven step-wise introduction of rTAR into their clinical practice. According to the surgeon's preference, preoperative optimization using botulinum toxin or progressive pneumoperitoneum will be allowed within the study. Randomization will be performed two weeks preoperatively (to avoid any influence on this decision). Patients where the need for a bilateral TAR is considered no longer required during surgery will not be excluded from the study.

Used mesh and suture material will be standardized across centers. A light-weight non-absorbable polyvinylidene fluoride (PVDF) mesh (Dynamesh CICAT Visible, FEG Textiltechnik, Aachen, Germany) will be used during all surgeries, closure of fascial layers and hernia defects will be done using barbed sutures in case of rTAR, and using slowly absorbable running sutures in case of oTAR. In open surgery, adherence to a 4-to-1 suture-to-wound length ratio and small bites technique will be monitored, and measurements of both suture and wound length will be evaluated. Drain management and mesh fixation will be left to the surgeon's preference.

### *Criteria for discontinuing or modifying allocated interventions (11b)*

There are no specific criteria for discontinuing or modifying allocated interventions. In case of conversion from rTAR to oTAR, patient data will be analyzed according to the intention-to-treat principles. In case of withdrawal of informed consent prior to surgery, this will not affect a patient's right to receive treatment. The treatment of choice in that case will be discussed between the patient and the surgeon. If component separation is

considered no longer required during surgery (e.g. after administration of botulinum toxin or major weight loss), these patients will not be excluded from the study. Obviously, TAR will not be performed if the treating surgeon estimates this is no longer required for the optimal treatment of the incisional hernia.

*Strategies to improve adherence to interventions (11c)*

Besides regular updates on the progression of inclusions in the study, notifications will be given to individual centers every 3 months on the expected follow-up moments over the coming six months in their center to promote participant retention and complete follow-up.

*Relevant concomitant care permitted or prohibited during the trial (11d)*

None.

**Outcomes (12)**

*Primary endpoint*

Length of postoperative hospital stay (defined as hours from the end of surgery until discharge)

*Secondary endpoints*

During hospitalization and the first 30 postoperative days, data on the following endpoints will be collected:

- Skin-to-skin operative time (minutes)
- Conversion from rTAR to oTAR
- Postoperative complications (Clavien-Dindo) during the first 30 days postoperative
- Surgical site infections (SSI) during the first 30 days postoperative
- Surgical site occurrence (SSO) during the first 30 days postoperative
- Surgical site occurrence requiring procedural interventions (SSOPI) during the first 30 days postoperative



- Readmission rate during the first 30 days postoperative
- Reoperation rate during the first 30 days postoperative
- Postoperative PADSS (post-anesthetic discharge scoring system - measured 3 times a day until discharge)
- Postoperative VAS pain score (measured 3 times a day until discharge)
- Use of pain medication postoperative (paracetamol/NSAID/milligram morphine equivalents/epidural analgesia) until discharge
- PROM monitoring using the EuraHS QoL score (preoperatively, 30 days, 3 months, 12 months, 24 months and 60 months postoperatively)
- PROM monitoring using the body image scale (preoperatively, 30 days, 3 months, 12 months, 24 months and 60 months postoperatively)
- Total cost, both direct (material cost, disposables, mesh, mesh fixation, personnel and length of hospital stay) and indirect (costs related to readmission, reoperation and complications)

Standard clinical follow-up will be scheduled 30 days, 3 months, 12 months, 24 months and 60 months postoperatively. During this visit the following data will be collected:

- Complications
- PROM monitoring using the EuraHS QoL score
- PROM monitoring using the body image scale
- Hernia recurrence based on a clinical examination and imaging at 24 months after surgery. If a CT scan or MRI was performed within a window of +/- 3 months (thus between 21 months and 27 months) for another indication, no new imaging will be proposed. First choice will be an MRI of the abdomen, in case of contraindication for MRI a CT scan of the abdomen will be performed. In case of doubt upon clinical evaluation, additional CT scan will be performed (with and without Valsalva manoeuvre)
- Reoperation for hernia recurrence
- Abdominal surgery not for hernia recurrence

To define surgical site-related complications, SSI, SSO and SSOPI were chosen as endpoints. This terminology was recently proposed to standardize outcome in hernia surgery<sup>17</sup>. The PADSS score was chosen as an objective tool to evaluate patient's ability to go home after surgery. It has proven to be a validated scoring system to objectively predict a safe discharge from hospital<sup>18</sup>. The EuraHS QoL-tool will be used to evaluate PROM both pre- and postoperatively. This has been proven to be a validated and widely

adopted tool in reporting on patient-reported outcomes in hernia surgery<sup>19</sup>. To evaluate outcomes on cosmesis, the body image scale will be used<sup>20</sup>.

### ***Participant timeline (13)***

The participant timeline is presented in Figure 1. After obtaining informed consent, patients will be enrolled in the study. Randomization will be performed 2 weeks prior to surgery, in order not to make a decision to use preoperative botulinum toxin or progressive pneumoperitoneum in relation to the treatment arm.

Patients will be invited for a clinical follow-up 30 days, 3 months, 12 months, 24 months and 60 months postoperatively. These visits will be free of charge for patients. A clinical evaluation for recurrence will be performed in a standing and supine position, including Valsalva manoeuvre. At 24 months an MRI of the abdomen for detection of a recurrent ventral hernia will be performed. In case of a contra-indication for MRI imaging, a CT scan of the abdominal wall will be performed.

During each follow-up visit, the patients will be asked to complete the EuraHS QoL questionnaire and body image scale.

### ***Sample size calculation and power analysis (14)***

Sample size calculation is based on studies comparing rTAR with oTAR included in the recent meta-analysis by Bracale et al<sup>2</sup>. To demonstrate a mean difference of 2 days of hospital stay between oTAR and rTAR ( $\alpha=0.05$ , 90% power), N=33 patients per arm are required. To account for potential clustering within centers as well as possible drop-out, a total number of N=100 will be randomized. These numbers are in concordance with retrospective data from two of the participating centers, as described in Chapter 9 of this thesis.

### ***Recruitment (15)***

For each participating center, a dedicated site investigator will be asked to keep a logbook of all patients that underwent surgical treatment of their ventral incisional hernia of more than 8 cm in width, and reasons not to include patients will be noted. By selecting dedicated participating surgical centers with high volumes of hernia surgery we are confident that inclusion numbers will be met within the study period. During the

inclusion period, the coordinating investigators will give regular updates on inclusion numbers and study progression.

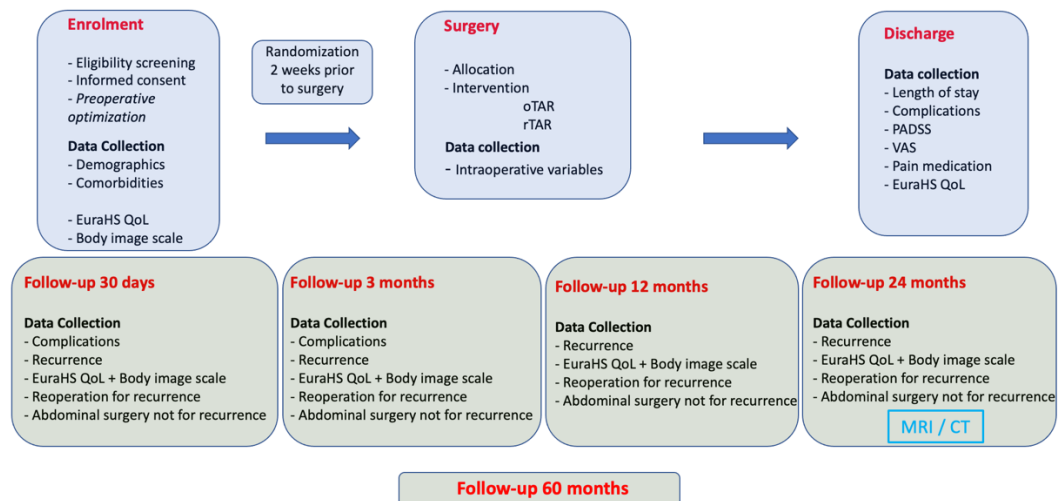


Figure 1 - Patient timeline

## Methods: assignment of interventions

### Allocation

#### Sequence generation (16a)

Randomization will take place after a written informed consent of patients was obtained, two weeks before surgery. A web-based online central randomization method for the two study groups will be applied in a 1:1 ratio using the REDCAP online database software. Randomization will be conducted using block randomization, using the center as a stratification factor. Varying block randomization will be used to avoid any predictability on the treatment arm.

#### Allocation concealment mechanism (16b)

A web-based online central randomization will be used. Further concealment of allocations will be achieved by applying block random sequence generation. This is an

open-label RCT, thus after preoperative randomization, the patient, the surgeon, research coordinators, planners and hospital staff will be aware of the treatment arm. Evaluation of the imaging of the abdominal wall at 24 months (MRI or CT scan) will be done by radiologists blinded for the randomized treatment arm.

#### *Implementation (16c)*

Patients will be included in the study by the participating surgeons. After assessment of inclusion and exclusion criteria, and written informed consent has been obtained, patients will be randomized using the online data capture software REDCAP.

#### **Blinding (17a)**

Open TAR is performed using a large midline incision, whereas rTAR is performed using 6 or 7 small incisions. Therefore, blinding of patients and physicians who perform the follow-up visits is difficult. Blinding of the surgical field by surgical drapes during hospitalization will not be performed in order not to blur the 'real-life' recovery after both oTAR and rTAR.

Evaluation of the imaging of the abdominal wall at 24 months (MRI or CT scan) will be done by radiologists blinded to the randomized treatment arm. This blinded evaluation for the presence or absence of hernia recurrence will be done centrally at the coordinating study center (Maria Middelaers hospital Gent) by at least two independent radiologists and additionally by the principal investigator (surgeon). Data analysis will be performed in a blinded manner by an independent statistician.

#### *Procedure for unblinding if needed (17b)*

Not applicable, as both patient and treating physician are not blinded for the surgical procedure that was performed.

## **Methods: data collection, management, and analysis**

#### **Data collection methods (18a-18b)**

Data will be collected using the online data capture software REDCAP. Data on baseline characteristics and comorbidities will be collected after inclusion of patients in the study.

Data on postoperative outcomes during hospitalization and follow-up will be collected upon discharge from the hospital, and following the postoperative outpatient clinic visits 30 days, 3 months, 12 months, 24 months and 60 months after surgery. At each of these moments, participating surgeons will be asked to complete an eCRF using the online data capture software REDCAP.

### ***Data management (19)***

After inclusion, trial participants will be given a trial code that will be used for randomization and completion of eCRF during the further conduction of the trial. The trial code will be a combination of 3 letters and 2 numbers. The first letter for the country of the center, second letter for the city of the center and third for the surgeons' name. Example: BGM01: Belgium/Gent/Muysoms/01. After inclusion of participating centers, the site-specific study coordinator will be granted access to the REDCAP online database for inclusion, web-based randomization and completion of eCRF.

### ***Confidentiality (27)***

Patient-identifying data will not be collected in the REDCAP database. Only treating surgeons will have knowledge of this patient-identifying data related to the trial code. All patient identifying data will be kept strictly confidential and will be treated in accordance with the European General Data Protection Regulations both during and after the trial. Only the coordinating investigators and the data analysts will have access to the full database. Site-specific study coordinators will only have access to the patient data that were included from their own center.

### ***Statistical methods (20a-20b-20c)***

Statistical analysis will be performed by an independent statistician, blinded to the allocated treatment. Data will be described according to common statistics (mean, standard deviation, median, quartiles, range, proportions). Parametric and non-parametric methods will be used to evaluate differences in primary and secondary outcomes between study arms. All analyses will be done according to the intention-to-treat principle. A per-protocol analysis will be added to the statistical evaluation, as in some patients that underwent preoperative optimization the need for bilateral TAR may be estimated no longer required. If relevant, multiple imputation methods will be applied to replace missing data. Hypotheses will be tested at the  $\alpha=0.05$  significance level.

## **Methods: monitoring**

### ***Data monitoring (21a-21b-23)***

Data monitoring will be performed by an independent institute during the first 2 years after surgery. Both physical and online evaluations will be performed to secure data monitoring. Study data and trial progression can be monitored at all time by using the web-based data capture software REDCAP. The coordinating investigators will regularly provide updates to the participating centers regarding study and inclusion progression. Participating surgeons will be asked to complete eCRF within 48 hours after inclusion, surgery, hospital discharge and follow-up visits, and will not be able to make any changes to the data afterwards. No interim analysis is planned during the inclusion period.

### ***Adverse event reporting and harms (22)***

In the treatment of large incisional ventral hernias requiring component separation, both oTAR and rTAR are techniques that are well established, and are considered standard of care in proficient centers. Early complications related to the surgery will be monitored, documented and registered after discharge and during a follow-up visit 30 days after surgery.

Site investigators will be asked to report all serious adverse events to the trial secretariat within 24 hours. Each serious adverse event and unexpected accumulations of complications observed by a site investigator, will be discussed by the principal investigator with the data safety monitoring committee. The definition of an adverse event and a serious adverse event is added as Addendum 1 to the full study protocol. All members of the data safety monitoring committee will be asked to sign a non-competing interest form prior to the start of inclusions. When applicable, a premature termination of the trial will be discussed. Predefined reasons for discontinuation of patients, participating centers or the trial are added to the full study protocol as Addendum 2. Any mortality within this trial will be reported to the leading ethics committee.

## **Ethics and dissemination**

### ***Research ethics approval (24)***

The study protocol will be submitted to the ethics committee of Maria Middelaers hospital (Gent, Belgium) for approval. For each participating center, approval by the local committee will be obtained prior to any inclusion. Site investigators are responsible to obtain both oral and written informed consent before inclusion of patients. Amendments to the study protocol will be submitted to both the local and coordinating ethics committee prior to implementation.

### ***Protocol amendments (25)***

Any relevant changes to the study protocol will be sent to the ethics committee for approval prior to their implementation. After approval, protocol amendments will be communicated to site investigators, participating centers, trial participants, and [clinicaltrials.gov](http://clinicaltrials.gov).

### ***Consent (26a-26b)***

Participating surgeons will obtain both oral and written informed consent of trial participants prior to inclusion.

### ***Confidentiality (27)***

Patient-identifying data will not be collected in the REDCAP database. Only treating surgeons will have knowledge of this patient-identifying data related to the trial code. All patient identifying data will be kept strictly confidential and will be treated in accordance with the European General Data Protection Regulations both during and after the trial. Only the coordinating investigators and the data analysts will have access to the full database. Site-specific study coordinators will only have access to the patient data that were included from their own surgical center. Photographic and video material from the procedures will be transferred through an online platform in an anonymized manner for proficiency evaluation. These images will not allow for any identification of patients (or surgeons). For evaluation of the imaging at 24 months after surgery, anonymized image files will be transferred through the same online platform.

### ***Declaration of interests (28)***

Statements on conflicts of interest from coordinating investigators, members of the advisory committee, independent experts and participating surgeons will be explicitly noted upon any communication regarding this trial (study protocol, report of results).

### ***Access to data (29)***

After statistical analysis, trial data will be uncoded, and kept for 15 years after closure of the trial through the web-based data capture system REDCAP. Upon request, data can be made available for review or meta-analysis.

### ***Ancillary and post-trial care (30)***

Not applicable.

### ***Dissemination policy (31a)***

Results will be submitted to a peer-reviewed journal, regardless of the outcomes. The 3 principal and coordinating investigators will be granted senior and shared first authorship. Co-authors will follow the ICMJE recommendations and will be listed based on inclusion numbers. One authorship will be granted for each participating center and 2 authorships in case of 15 included patients or more.



## References

1. Chan A, Tetzlaff J, Gatzsche P, Altman D, Mann H, Berlin J et al. SPIRIT 2013 explanation and elaboration: guidance for protocols of clinical trials *BMJ* 2013; 346: e7586.
2. Bracale U, Corcione F, Neola D, Castiglioni S, Cavallaro G, Stabilini C et al. Transversus abdominis release (TAR) for ventral hernia repair: open or robotic? Short-term outcomes from a systematic review with meta-analysis. *Hernia* 2021 Sep 7. doi: 10.1007/s10029-021-02487-5. Epub ahead of print.
3. Temudom T, Siadati M, Sarr M. Repair of complex giant or recurrent ventral hernias by using tension-free intraparietal prosthetic mesh (Stoppa technique): lessons learned from our initial experience (fifty patients). *Surgery* 1996; 120(4): 738-43.
4. Zolin S, Fafaj A, Krpata D. Transversus abdominis release (TAR): what are the real indications and where is the limit? *Hernia* 2020; 24(2): 333-40.
5. Love M, Warren J, Davis S, Ewing J, Hall A, Cobb W et al. Computed tomography imaging in ventral hernia repair: can we predict the need for myofascial release? *Hernia* 2021; 25(2): 471-77.
6. Krpata D, Blatnik J, Novitsky Y, Rosen M. Posterior and open anterior components separations: a comparative analysis. *Am J Surg* 2012; 203(3): 318-22.
7. Novitsky Y, Elliott H, Orenstein S, Rosen M. Transversus abdominis muscle release: a novel approach to posterior component separation during complex abdominal wall reconstruction. *Am J Surg* 2012; 204(5): 709-16.
8. Malik A, Macdonald A, de Beaux A, Tulloh B. The peritoneal flap hernioplasty for repair of large ventral and incisional hernias. *Hernia* 2014; 18(1): 39-45.
9. van Rooijen M, Yurtkap Y, Allaeyns M, Ibrahim N, Berrevoet F, Lange J. Fascial closure in giant ventral hernias after preoperative botulinum toxin a and progressive pneumoperitoneum: A systematic review and meta-analysis. *Surgery* 2021; 170(3): 769-76.
10. Abdu R, Vasyluk A, Reddy N, Huang L, Halka J, DeMare A et al. Hybrid robotic transversus abdominis release versus open: propensity-matched analysis of 30-day outcomes. *Hernia* 2020. doi: 10.1007/s10029-020-02249-9. Epub ahead of print.

11. Bittner J, Alrefai S, Vy M, Mabe M, Del Prado P, Clingempeel N. Comparative analysis of open and robotic transversus abdominis release for ventral hernia repair. *Surg Endosc* 2018; 32(2): 727-34.
12. Martin-Del-Campo L, Weltz A, Belyansky I, Novitsky Y. Comparative analysis of perioperative outcomes of robotic versus open transversus abdominis release. *Surg Endosc* 2018; 32(2): 840-45.
13. Reeves J, Metha S, Prabha R, Salama Y, Mittal A. Robotic versus open transversus abdominis release and incisional hernia repair: A case-control study. *Laparoscop Endoscop Robot Surg* 2020; 3(3): 59-62.
14. Dauser B, Hartig N, Vedadinejad M, Kirchner E, Trummer F, Herbst F. Robotic-assisted repair of complex ventral hernia: can it pay off? *J Robot Surg* 2021; 15(1): 45-52.
15. Halka J, Vasyluk A, Demare A, Iacco A, Janczyk R. Hybrid robotic-assisted transversus abdominis release versus open transversus abdominis release: a comparison of short-term outcomes. *Hernia* 2019; 23(1): 37-42.
16. Grossi J, Lee B, Belyansky I, Carbonell A, Cavazzola L, Novitsky Y, Ballecer C. Critical view of robotic-assisted transverse abdominal release (r-TAR). *Hernia* 2021 Apr 2. doi: 10.1007/s10029-021-02391-y. Epub ahead of print.
17. DeBord J, Novitsky Y, Fitzgibbons R et al. SSI, SSO, SSE, SSOPI: the elusive language of complications in hernia surgery. *Hernia* 2018; 22, 737–38.
18. Palumbo P, Tellan G, Perotti B, Pacilè MA, Vietri F, Illuminati G. Modified PADSS (Post Anaesthetic Discharge Scoring System) for monitoring outpatients discharge. *Ann Ital Chir* 2013; 84(6): 661-5.
19. Muysoms F, Dewulf M, Kyle-Leinhase I, Baumgartner R, Ameye F, Defoort B et al. Laparoscopic bilateral groin hernia repair with one large self-fixating mesh: prospective observational study with patient-reported outcome of urological symptoms and EuraHS-QoL scores. *Surg Endosc* 2020; 34(2): 920-29.
20. Melissant H, Neijenhuijs K, Jansen F, Aaronson N, Groenvold M, Holzner B et al. A systematic review of the measurement properties of the Body Image Scale (BIS) in cancer patients. *Support Care Cancer* 2018; 26: 1715-26.



# Chapter 12

General discussion and future perspectives



## Introduction

Throughout this thesis, several recent developments in the relatively new specialty of abdominal wall surgery were evaluated. With an emphasis on both prevention and treatment of inguinal, parastomal and ventral (incisional) hernias, technical aspects and clinical outcomes were evaluated. In this chapter we aim to discuss our main findings, check them against existing literature, and identify future perspectives that can help to further improve outcomes in (minimally invasive) hernia surgery.

### Inguinal hernia repair: common as dirt, yet possibly life-defining

During minimally invasive inguinal hernia repair (IHR), achieving a critical view on the myopectineal orifice (MPO) involves an extensive dissection of the retropubic Retzius space, and close contact between a mesh and the bladder<sup>1</sup>. Both in open and minimally invasive IHR, chronic pain and urinary retention are among the most feared complications<sup>2</sup>. It is estimated that around 6% develop chronic pain after laparoscopic IHR, after open surgery these numbers vary between 7 and 18%<sup>3</sup>. In a prospective cohort study evaluating our standardized technique of laparoscopic IHR in case of bilateral disease, using one large self-gripping mesh covering both groins, outcomes in QoL<sup>4</sup> and lower urinary tract symptoms (LUTS)<sup>5</sup> were studied (**Chapter 2**). In 100 male patients, QoL and LUTS scores significantly improved after surgery during a one-year follow-up. Besides illustrating satisfactory results on LUTS after IHR, this study adds evidence to the fact that IHR significantly improves quality of life, by actually reducing pain complaints, restrictions of activity and cosmetic concerns<sup>6</sup>. The use of self-gripping mesh has the advantage that it omits any other (often penetrating) fixation. This was confirmed by a recent meta-analysis that reported on a significant reduction in postoperative pain when self-gripping mesh is used in laparoscopic IHR, when compared to conventional mesh<sup>7</sup>.

In current guidelines, recommendations are given regarding mesh size during IHR<sup>8</sup>. The optimal mesh configuration however, remains to be determined. Mesh configuration seems to matter, as some authors have reported on high recurrence rates when a slit-mesh or rectangular mesh was used during bilateral laparoscopic IHR<sup>9,10</sup>. **Chapter 2** illustrates that the use of one large self-gripping mesh, in a configuration that allows optimal coverage of the MPO can be performed with very low recurrence rates and satisfying results regarding QoL and LUTS. Thereby, this technique provides a

pragmatic solution to the problem of large medial hernias. In their latest guidelines, the European Hernia Society (EHS) suggest an adaptation in technique based on patient- and hernia-related factors<sup>8</sup>. Several modifications to the surgical technique have been proposed to tackle the problem of large medial hernias, like closure of the defect or fixation of the transversalis fascia and/or hernia sac to the pubic bone<sup>11,12</sup>. By using one large mesh covering both groins, a large overlap of the hernia defect is obtained, even on the medial side.

## **Expanding indications for minimally invasive inguinal hernia repair**

Previous transabdominal prostatectomy is considered a relative contra-indication for minimally invasive IHR, and guidelines advise an open anterior approach in this specific setting<sup>8</sup>. Indeed, evidence on the safety, feasibility and outcomes of these techniques for this indication is very limited. Currently, only 5 cohort studies report on outcomes of minimally invasive IHR after transabdominal prostatectomy, who have either an uncontrolled design<sup>13,14</sup> or compare with a population that did not undergo prostatectomy<sup>15-17</sup>. Our retrospective cohort study was the first comparative analysis of open and minimally invasive IHR after previous prostatectomy (**Chapter 3**). Despite obvious limitations (mainly due to study design and patient numbers), outcomes in patients that were treated with robotic-assisted surgery had comparable outcomes than the group that underwent Lichtenstein repair, and no conversions were noted. Increased operative times in the minimally invasive group were no longer statistically significantly longer in case of bilateral disease. Besides well-established advantages of laparoscopic IHR, the true benefit of a minimally invasive approach in this specific setting probably lies in the group of patients with a bilateral inguinal hernia. A transabdominal laparoscopic approach after prostatectomy allows for a systematic evaluation of the contralateral side. The higher proportion of patients that underwent bilateral IHR in the robotic group illustrates this, as occult hernias were systematically diagnosed and treated within the same surgery. A transabdominal prostatectomy has been identified as a risk factor for the development of an inguinal hernia<sup>18,19</sup>. This indicates that this specific clinical entity is highly relevant, and strengthens the potential of a laparoscopic approach in diagnosing and treating contralateral occult hernias. In our practice, a shift towards minimally invasive surgery for these patients was seen with the introduction of a robotic platform. The enhanced visualization and improved dexterity in robotic-assisted surgery compared to conventional laparoscopic surgery has lowered the threshold to use minimally invasive techniques after prostatectomy, at least in our experience. Obviously,

this is merely an observation and the added value of the robot in these cases is difficult to objectify<sup>20</sup>. Therefore, conclusions on this matter should be drawn with caution.

## **Ileal conduit parastomal hernia: possibly the most complex of all hernias**

In **Part II** of this thesis, the (minimally invasive) surgical treatment of ileal conduit parastomal hernias (PHs) is studied. In our systematic review (**Chapter 4**) evaluating currently available evidence on the topic, a large variety of open, conventional laparoscopic and robotic-assisted techniques have been identified in 8 full-text articles and 5 conference abstracts<sup>21-28</sup>. All included studies had a retrospective design, and report on relatively small patient numbers (between 5 and 40 included patients). The majority of studies report outcomes after open surgery. Therefore, our review did not allow identification of the optimal treatment for this specific condition. It did however stress the need for further prospective research on the topic, including larger patient numbers. These observations, along with the complexity of this clinical entity and high complication rates after PH treatment<sup>29</sup>, do stress the need to further centralize surgical treatment of this clinical entity.

In **Chapter 5**, technical considerations regarding the minimally invasive (mainly robotic-assisted) treatment of ileal conduit PH are described, and preliminary outcomes from our single center experience are presented. These outcomes confirm the relatively high morbidity after treating this type of hernias. In our patient series, the overall complication rate was 46.7%, and 3/15 patients had a severe complication (Clavien-Dindo  $\geq 3$ )<sup>30</sup>. In a recent nation-wide cohort study from Finland, equally high complication numbers were seen<sup>27</sup>. By presenting our systematic approach to this clinical entity the complex nature and the large armamentarium required to treat this type of hernias is illustrated. Several elements complicate surgery to treat ileal conduit PH. These patients present with significant comorbidity and are prone to metastatic or recurrent disease, and in more than half of them a concomitant midline incisional hernia is present<sup>29</sup>. Thereby, several local elements complicate the surgical approach. The absence of peritoneum and preperitoneal fat after radical cystectomy, a longstanding collapse of the stomal loop, the presence of ureteric anastomoses and a difficult lateralization of the stomal loop due to an often short mesentery demand a highly tailored approach. In our experience, depending on the type of PH intraperitoneal Sugarbaker<sup>31</sup>, intraperitoneal keyhole or a modified Pauli technique<sup>32</sup> (with or without



an additional keyhole mesh, depending on the presence of a midline incisional hernia) is used.

## **Prophylactic mesh reinforcement after open abdominal aortic aneurysm repair**

In the prevention of incisional hernias (IHs) after midline laparotomies, both the optimal technique to close the abdominal wall and the use of a prophylactic mesh have extensively been studied. The use of a slowly absorbable running suture, in a 4 to 1 suture to wound length ratio (4:1 SL/WL)<sup>33</sup>, using a small bites technique<sup>34</sup>, are currently widely accepted principles in the primary closure of laparotomies<sup>35</sup>. The use of a prophylactic mesh is far less established in daily practice. However, its use has been evaluated in several clinical trials, both in the prevention of parastomal and midline incisional hernias. Especially in high-risk patients, e.g. in patients with an abdominal aortic aneurysm (AAA), there are several randomized controlled trials (RCTs) that have shown favorable results<sup>36,37</sup>. Despite this evidence, that is generally of good quality, guidelines online cautiously advise that the use of a prophylactic mesh after open AAA repair 'may be considered', or is 'suggested'<sup>35,38</sup>. The most recent guidelines from the European Society of Vascular and Endovascular Surgery (ESVS) explicitly state that long-term follow-up is awaited to possibly change this recommendation<sup>38</sup>. In **Chapter 8**, we report on the 60-month follow-up of one of these RCTs. Our results illustrate that the use of a prophylactic retrorectus mesh safely and effectively decreases the rate of IHs after open AAA repair, even on the long term, and that the cumulative incidence of IHs continues to increase during the first 5 years after surgery. The perception that these IHs in this specific patient population do not pose a clinically relevant problem - and thus not lead to a substantial number of incisional hernia repairs - was not confirmed by our results. This was confirmed by other authors, who have shown that incisional hernia repair is the most common reintervention after open AAA repair<sup>39</sup>. The most important limitation of our study was the lack of systematic radiological examination during follow-up<sup>40</sup>. However, in less than half of the patients follow-up consisted merely of clinical evaluation. In the setting of clinical trials, closure of the abdominal wall and placement of a prophylactic mesh was usually done by a hernia surgeon<sup>36,37</sup>. In daily practice this is generally not the case. In a brief report on a survey among 101 vascular surgeons in Belgium and The Netherlands, we report on current practices and concerns regarding the use of a prophylactic mesh (**Chapter 7**). Results of this questionnaire illustrate that vascular surgeons remain reluctant to use a prophylactic mesh after open AAA repair, with only 6.9% systematically using it, and 18.8% placing it in selected cases.

Main reasons not to use mesh were increased operative times and concerns on mesh-related complications. The latter has not been reported in the literature<sup>36,37,41</sup>.

## **Robotic-assisted transversus abdominis release: the true advantage of robotic surgery?**

When compared to conventional laparoscopy, robotic-assisted surgery offers some specific advantages. The enhanced visualization, improved dexterity due to tremor filtration and motion scaling, availability of wristed instruments and improved ergonomics make it an attractive platform<sup>42</sup>. This has led to a widespread adoption of robotic surgery in the field of urological, gynaecological, colorectal and hepatobiliary surgery<sup>43,44</sup>. Despite these advantages, it is difficult to demonstrate a true benefit of robotic-assisted surgery over conventional laparoscopy regarding patient outcomes. However, in abdominal wall surgery, the introduction of robotic-assisted techniques has caused a major shift in techniques and seems to significantly ameliorate patient outcomes (**Chapter 6**). For some indications in hernia surgery, it probably has the potential of being true 'disruptive technology'.

While transversus abdominis release (TAR) performed by traditional laparoscopy seems feasible in experienced hands<sup>45</sup>, it does pose significant technical limitations. Robotic surgical platforms seem to overcome these difficulties, and facilitate a minimally invasive approach of these posterior component separation techniques. Until now, 6 retrospective patient series have been published reporting on short-term outcomes of robotic-assisted TAR (rTAR) compared to open TAR (oTAR)<sup>46-51</sup>. They all report a significantly shorter postoperative hospital stay in the rTAR group, and a pooled analysis showed a reduction in short-term overall and surgical-site related complications after rTAR<sup>52</sup>. This meta-analysis, that was recently published in *Hernia*, is however subject to a few methodological and statistical shortcomings, that were commented in a brief communication in **Chapter 10**. These consist mainly of a duplication and incorrect input of data, and a misinterpretation of outcome measures.

In **Chapter 9**, outcomes of a comparative analysis of rTAR versus oTAR in a retrospective multicenter design are reported. In concordance with available literature, a highly significant reduction in length of postoperative hospital stay (3.4 vs 6.9 days;  $p < 0.001$ ) and a significant reduction in overall and serious complications after 30 days was seen in the rTAR group. Due to these forementioned promising results, robotic-assisted surgery in the treatment of ventral hernias is rapidly gaining popularity. However, after

a critical appraisal of available literature<sup>52</sup>, evidence is still scarce, and prospective randomized data are lacking. For this reason, we aim to conduct a prospective randomized controlled trial in several centers across Europe. A detailed study protocol for this trial is written down in **Chapter 11**.

## Future perspectives

As mentioned, abdominal wall surgery should be considered as a relatively new subspecialty. It is a field in full expansion, and novel techniques are rapidly being adopted. However, there is a growing discrepancy between the number of procedures performed using these (often minimally invasive) techniques, and evidence supporting them. With this thesis, our aim was to add evidence on these recent developments, in an attempt to (at least partially) close this gap. Throughout the chapters, several flaws of currently available evidence and essential shortcomings in the literature have been identified.

In **chapter 2** and **3**, outcomes of minimally invasive IHR have been investigated. Despite extensive dissection of the Retzius space and close contact of a mesh with the bladder, the influence of these techniques on LUTS have not been thoroughly studied. With the introduction of the ICIQ-LUTS score (International Consultation on Incontinence modular Questionnaire - Lower Urinary Tract Symptoms), a tool to evaluate patient-related outcome measures regarding LUTS was introduced to the field of hernia surgery<sup>53</sup>. Obviously, further validation of this score after IHR is warranted, yet we believe that future research on outcomes after IHR should include evaluation of LUTS. Furthermore, additional evidence is warranted on the role of minimally invasive IHR after transabdominal prostatectomy. Our patient series stresses the need for prospective studies, including randomization between open and minimally invasive techniques, to further clarify its role in this specific (but clinically relevant) setting.

Similarly, a huge gap in the evidence on the surgical treatment of ileal conduit PHs was identified after systematic review of the literature (**Chapter 4**). In the reported patient series<sup>21-28</sup> (**Chapter 5**), significant technical challenges in the treatment of this condition were identified, and high complication rates were reported. This stresses the need for a further centralization of the treatment of this specific condition. Due to a relatively low incidence, single center trials will unlikely be able to include adequate patient numbers. Hence, future research on this topic should focus on a systematic prospective registration of data, and multicenter trials.

Regarding the use of a prophylactic mesh after open AAA repair, available evidence is of acceptable quality. However, by evaluating the long-term results of our RCT (**Chapter 8**), a few recommendations for the future can be made. First, future studies with IH as an endpoint should extend their follow-up period to a minimum of 5 years<sup>54</sup>. This is in contrast to the latest recommendations of the EHS, who advise a follow-up period of 24 to 36 months<sup>35</sup>. Second, to detect abdominal wall hernias in the setting of a clinical trial, routine use of medical imaging by computed tomography or dynamic ultrasound is warranted<sup>35,40</sup>. This is illustrated by the absence of any IH within the control arm of our study, and recommended by current guidelines<sup>35</sup>. Third, RCTs investigating the use of a prophylactic mesh in AAA patients aim for a 4:1 SL/WL in their study protocol. However, none of them report on the use of the small bites technique, and some explicitly used a large bites technique<sup>40</sup>. Future studies should use a small bites technique and a 4:1 SL/WL for the closure of laparotomies to allow comparison with the a 'state-of-the-art' closure of the abdominal wall. To conclude, the optimal mesh position of a prophylactic mesh after midline laparotomy remains to be determined. Both onlay and retrorectus (often referred to as 'sublay') meshes have been studied, and both have their advantages. Placement of an onlay mesh is technically less demanding than a retrorectus mesh. This could lower the threshold for its use in a population of vascular surgeons, who are not trained to place retromuscular meshes. On the other hand, a recent analysis of the Dutch PRIMA-trial has illustrated a higher incidence of mesh-related complications with onlay meshes, when compared to a retrorectus mesh<sup>41</sup>.

In **Chapter 7**, a great restraint among vascular surgeons in the use of a prophylactic mesh after open AAA repair was documented. Available guidelines only cautiously state that its use could be considered, despite available evidence<sup>35,38</sup>. A clear recommendation in future guidelines - supported by our data with longer follow-up - could lead to a more widespread adoption among surgeons.

Shortcomings in the evidence supporting minimally invasive treatment of complex ventral incisional hernias are extensively discussed in **Chapter 9** and **10**. The need for prospective data on rTAR is addressed in **Chapter 11**, in which we describe the study protocol for a multicenter randomized controlled trial.

## References

1. Daes J, Felix E. Critical View of the Myopectineal Orifice. *Ann Surg* 2017; 266(1): e1-e2.
2. Broderick R, Li J, Blitzer R, Ahuja P, Race A, Yang G et al. A steady stream of knowledge: decreased urinary retention after implementation of ERAS protocols in ambulatory minimally invasive inguinal hernia repair. *Surg Endosc* 2022 Jan 4. doi: 10.1007/s00464-021-08950-9. Epub ahead of print
3. Alabi A, Haladu N, Scott N, Imamura M, Ahmed I, Ramsay G et al. Mesh fixation techniques for inguinal hernia repair: an overview of systematic reviews of randomised controlled trials. *Hernia* 2021 Dec 14. doi: 10.1007/s10029-021-02546-x. Epub ahead of print.
4. Muysoms F, Campanelli G, Champault G, DeBeaux A, Dietz U, Jeekel J et al. EuraHS: the development of an international online platform for registration and outcome measurement of ventral abdominal wall hernia repair. *Hernia* 2012; 16(3): 239-50.
5. Tran M, Yip J, Uveili K, Biers S, Thiruchelvam N. Patient reported outcome measures in male incontinence surgery. *Ann R Coll Surg Engl* 2014; 96(7): 521-5.
6. Muysoms F, Vanlander A, Ceulemans R, Kyle-Leinhase I, Michiels M, Jacobs I et al. A prospective, multicenter, observational study on quality of life after laparoscopic inguinal hernia repair with ProGrip laparoscopic, self-fixating mesh according to the European Registry for Abdominal Wall Hernias Quality of Life Instrument. *Surgery* 2016; 160(5): 1344-57.
7. Wang D, Jiang J, Fu Y, Qu P. The comparison of self-gripping mesh and conventional mesh in laparoscopic inguinal hernia repair: the results of meta-analysis. *Updates Surg* 2022 Jan 16. doi: 10.1007/s13304-021-01218-w. Epub ahead of print.
8. The HerniaSurge Group. International guidelines for groin hernia management. *Hernia* 2018; 22(1): 1-165.
9. Knook M, Weidema W, Stassen L, van Steensel C. Laparoscopic repair of recurrent inguinal hernias after endoscopic herniorrhaphy. *Surg Endosc* 1999; 13(11): 1145-7.
10. Köhler G, Fischer I, Kaltenböck R, Mitteregger M, Seitinger G, Szyszkowitz A. Critical evaluation of an innovative mesh for bilateral transabdominal preperitoneal (TAPP) repair of inguinal hernias. *Hernia* 2018; 22(5): 857- 62.

11. Ng A, Lin J, Ching S, Lee J, Wong A. Does primary closure of direct inguinal hernia defect during laparoscopic mesh repair reduce the risk of early recurrence? *Hernia* 2020; 24(5): 1093-8.
12. Pini R, Mongelli F, Proietti F, Cianfarani A, Garofalo F, Di Giuseppe M et al. Suture and Fixation of the Transversalis Fascia during Robotic-Assisted Transabdominal Preperitoneal Hernia Repair to Prevent Seroma Formation after Direct Inguinal Hernia Repair. *Surg Innov* 2021; 28(3): 284-9.
13. Claus C, Coelho J, Campos A, Filho A, Loureiro M, Dimbarre D et al. Laparoscopic inguinal hernioplasty after radical prostatectomy: is it safe? Prospective clinical trial. *Hernia* 2014; 18(2): 255-9.
14. Sakon M, Sekino Y, Okada M, Seki H, Munakata Y. Laparoscopic inguinal hernioplasty after robot-assisted laparoscopic radical prostatectomy. *Hernia* 2017; 21: 745-8.
15. Wauschkuhn C, Schwarz J, Bittner R. Laparoscopic transperitoneal inguinal hernia repair (TAPP) after radical prostatectomy: is it safe? Results of prospectively collected data of more than 200 cases. *Surg Endosc* 2009; 23(5): 973-7.
16. Dulucq J-L, Wintringer P, Mahajna. Totally extraperitoneal (TEP) hernia repair after radical prostatectomy or previous lower abdominal surgery: is it safe? A prospective study. *Surg Endosc* 2006; 20(3): 473-6.
17. Le Page P, Smialkowski A, Morton J, Fenton-Lee D. Totally extraperitoneal inguinal hernia repair in patients previously having prostatectomy is feasible, safe, and effective. *Surg Endosc* 2013; 27(12): 4485-90.
18. Liu L, Xu H, Qi F, Wang S, Shadhu K, Ramlagun-Mungur D, Wang S. Incidence and risk factors of inguinal hernia occurred after radical prostatectomy – comparisons of different approaches. *BMC Surgery* 2020; 20: 218-25.
19. Zhu S, Zhang H, Xie L, Chen J, Niu Y. Risk factors and prevention of inguinal hernia after radical prostatectomy: a systematic review and meta-analysis. *J Urol* 2013; 189: 884-90.
20. Kudsi O, Bou-Ayash N, Gokcal F, Crawford A, Chung S, Chudner A et al. Learning curve of robot-assisted transabdominal preperitoneal (rTAPP) inguinal hernia repair: a cumulative sum (CUSUM) analysis. *Surg Endosc* 2021 Apr 6. doi: 10.1007/s00464-021-08462-6. Epub ahead of print.

21. Faba O, Rosales A, Breda A, Palou J, Gaya J, Esquena S, et al. Simplified Technique for Parastomal Hernia Repair After Radical Cystectomy and Ileal Conduit Creation. *Urology* 2011; 77(6): 1491-4.
22. Tully K, Roghmann F, Pastor J, Noldus J, von Bodman C. Parastomal Hernia Repair With 3-D Mesh Implants After Radical Cystectomy and Ileal Conduit Urinary Diversion - A Single-center Experience Using a Purpose Made Alloplastic Mesh Implant. *Urology* 2019; 131: 245-9.
23. Ho K, Fawcett D. Parastomal hernia repair using the lateral approach. *BJU Int* 2004; 94(4): 598-602.
24. Franks M, Hrebinko R. Technique of parastomal hernia repair using synthetic mesh. *Urology* 2001; 57(3): 551-3.
25. Helal M, Austin P, Spyropoulos E, Pow-Sang J, Persky L, Lockhart J. Evaluation and management of parastomal hernia in association with continent urinary diversion. *J Urol* 1997; 157(5): 1630-2.
26. Safadi B. Laparoscopic repair of parastomal hernias: early results. *Surg Endosc* 2004; 18(4): 676-80.
27. Makarainen-Uhlback E, Vironen J, Vaarala M, Nordstrom P, Valikoski A, Kossi J et al. Keyhole versus Sugarbaker techniques in parastomal hernia repair following ileal conduit urinary diversion: a retrospective nationwide cohort study. *BMC Surg* 2021; 21(1): 231.
28. López-Cano M, Pereira J, Rodrigues-Gonçalves V, Verdaguer-Tremolosa M, Hernández-Granados P, Bravo-Salvá A. Parastomal hernia repair. Prospective observational study based on the Spanish Registry of Incisional Hernia (EVEREG). *Cir Esp (Engl Ed)* 2021; 99(7): 527-34.
29. Narang S, Alam N, Campain N, Pathak S, McGrath J, Daniels I et al. Parastomal hernia following cystectomy and ileal conduit urinary diversion: a systematic review. *Hernia* 2017; 21(2): 163-75.
30. Dindo D, Demartines N, Clavien P-A. Classification of surgical complications. A new proposal with evaluation in a cohort of 6336 patients and results of a survey. *Ann Surg* 2004; 240 (2): 205-13.

31. Stelzner S, Hellmich G, Ludwig K. Repair of paracolostomy hernias with a prosthetic mesh in the intraperitoneal onlay position: modified Sugarbaker technique. *Dis Colon Rectum* 2004; 47(2): 185-91.
32. Pauli E, Juza R, Winder J. How I do it: novel parastomal herniorrhaphy utilizing transversus abdominis release. *Hernia* 2016; 20(4): 547-52.
33. Henriksen N, Deerenberg E, Venclauskas L, Fortelny R, Miserez M, Muysoms F. Meta-analysis on Materials and Techniques for Laparotomy Closure: The MATCH Review. *World J Surg* 2018; 42(6): 1666-78.
34. Deerenberg E, Harlaar J, Steyerberg E, Lont H, van Doorn H, Heisterkamp J et al. Small bites versus large bites for closure of abdominal midline incisions (STITCH): a double-blind, multicentre, randomised controlled trial. *Lancet* 2015; 386(10000): 1254-60.
35. Muysoms F, Antoniou S, Bury K et al. European Hernia Society guidelines on the closure of abdominal wall incisions. *Hernia* 2015; 19: 1–24.
36. Indrakusuma R, Jalalzadeh H, van der Meij J, Balm R, Koelemay M. Prophylactic Mesh Reinforcement versus Sutured Closure to Prevent Incisional Hernias after Open Abdominal Aortic Aneurysm Repair via Midline Laparotomy: A Systematic Review and Meta-Analysis. *Eur J Vasc Endovasc Surg* 2018; 56(1): 120-28.
37. Nicolajsen C, Eldrup N. Abdominal Closure and the Risk of Incisional Hernia in Aneurysm Surgery - A Systematic Review and Meta-analysis. *Eur J Vasc Endovasc Surg* 2020; 59(2): 227-36.
38. Wanhainen A, Verzini F, Van Herzelee I, Allaire I, Bown M, Cohnert T et al. Editor's Choice - European Society for Vascular Surgery (ESVS) 2019 Clinical Practice Guidelines on the Management of Abdominal Aorto-iliac Artery Aneurysms. *Eur J Vasc Endovasc Surg* 2019; 57: 8-93.
39. Krishnamoorthi H, Jeon-Slaughter H, Wall A, Banerjee S, Ramanan B, Timaran C, et al. Rate of Secondary Intervention After Open Versus Endovascular Abdominal Aortic Aneurysm Repair. *J Surg Res* 2018; 232: 99-106.
40. Honig S, Diener H, Kölbel T, Reinpold W, Zapf A, Bibiza-Freiwald E et al; for the AIDA study group. Abdominal incision defect following AAA-surgery (AIDA): 2-year results of prophylactic onlay-mesh augmentation in a multicentre, double-blind, randomised controlled trial. *Updates Surg* 2021 Jul 21. doi: 10.1007/s13304-021-01125-0. Epub ahead of print.



41. Arora A, Kumar M, Kumar M, Jha A. Infectious Complication in Relation to the Prophylactic Mesh Position: The PRIMA Trial Revisited. *J Am Coll Surg* 2021; 233(5): 654
42. Prasad S, Prasad S, Maniar H, Chu C, Schuessler R, Damiano R. Surgical robotics: impact of motion scaling on task performance. *J Am Coll Surg* 2004; 199(6): 863-8.
43. Cuk P, Kjær M, Mogensen C, Nielsen M, Pedersen A, Ellebæk M. Short-term outcomes in robot-assisted compared to laparoscopic colon cancer resections: a systematic review and meta-analysis. *Surg Endosc* 2022; 36(1): 32-46.
44. Duong L, Cai H, Shrubsole M, Bailey C, Idrees K, Shu X. Outcomes of robotic-assisted liver surgery versus laparoscopic liver surgery for treatment of stage I hepatocellular carcinoma. *Cancer* 2022; 128(4): 762-69.
45. Belyansky I, Daes J, Radu V, Balasubramanian R, Reza Zahiri H, Weltz A et al. A novel approach using the enhanced-view totally extraperitoneal (eTEP) technique for laparoscopic retromuscular hernia repair. *Surg Endosc* 2018; 32(3): 1525-32.
46. Abdu R, Vasylyuk A, Reddy N, Huang L, Halka J, DeMare A et al. Hybrid robotic transversus abdominis release versus open: propensity-matched analysis of 30-day outcomes. *Hernia* 2020. doi: 10.1007/s10029-020-02249-9. Epub ahead of print.
47. Bittner J, Alrefai S, Vy M, Mabe M, Del Prado P, Clingempeel N. Comparative analysis of open and robotic transversus abdominis release for ventral hernia repair. *Surg Endosc* 2018; 32(2): 727-34.
48. Martin-Del-Campo L, Weltz A, Belyansky I, Novitsky Y. Comparative analysis of perioperative outcomes of robotic versus open transversus abdominis release. *Surg Endosc* 2018; 32(2): 840-45.
49. Reeves J, Metha S, Prabha R, Salama Y, Mittal A. Robotic versus open transversus abdominis release and incisional hernia repair: A case-control study. *Laparoscop Endoscop Robot Surg* 2020; 3(3): 59-62.
50. Dauser B, Hartig N, Vedadinejad M, Kirchner E, Trummer F, Herbst F. Robotic-assisted repair of complex ventral hernia: can it pay off? *J Robot Surg* 2021; 15(1): 45-52.
51. Halka J, Vasylyuk A, Demare A, Iacco A, Janczyk R. Hybrid robotic-assisted transversus abdominis release versus open transversus abdominis release: a comparison of short-term outcomes. *Hernia* 2019; 23(1): 37-42.

52. Bracale U, Corcione F, Neola D, Castiglioni S, Cavallaro G, Stabilini C et al. Transversus abdominis release (TAR) for ventral hernia repair: open or robotic? Short-term outcomes from a systematic review with meta-analysis. *Hernia* 2021 Sep 7. doi: 10.1007/s10029-021-02487-5. Epub ahead of print.
53. Coyne K, Kelleher C. Patient reported outcomes: the ICIQ and the state of the art. *Neurourol Urodyn* 2010; 29: 645–51.
54. Gruppo M, Mazzalai F, Lorenzetti R, Piatto G, Toniato A, Ballotta E. Midline abdominal wall incisional hernia after aortic reconstructive surgery: a prospective study. *Surgery* 2012; 151(6): 882-8.



# Chapter 13

Summary



Abdominal wall surgery accounts for a large proportion of surgical procedures worldwide. Nowadays, these surgeries are increasingly being performed by dedicated abdominal wall surgeons that more and more use extraperitoneal mesh and minimally invasive techniques. Since the introduction of robotic-assisted surgery, a major shift in current practice has been observed (**Chapter 1**). This thesis reports on several recent developments in the field of hernia surgery. With an emphasis on both technical aspects and outcomes, interventions in the prevention and treatment of inguinal, parastomal and ventral hernias are discussed.

In **Part I**, outcomes of two minimally invasive techniques in inguinal hernia repair are reported. In a prospective cohort study in 100 male patients that were treated for a bilateral inguinal hernia, a standardized laparoscopic technique using one large self-gripping mesh was validated (**Chapter 2**). By reporting on patient-related outcome measures on quality of life and lower urinary tract symptoms during a 1-year follow-up, favorable results were seen. The use of a large self-gripping mesh covering both groins did not induce urological complaints or significant chronic pain. In **Chapter 3**, a single center experience of robotic-assisted inguinal hernia repair after previous transabdominal prostatectomy was described. In a group of 45 patients, this minimally invasive approach has proven to be safe and feasible, and has shown similar short-term outcomes when compared to open surgery. In case of bilateral disease and in the diagnosis of an occult contralateral inguinal hernia this approach might offer specific advantages.

In **Part II** of this thesis, we elaborate on the treatment of ileal conduit parastomal hernias. A systematic review has identified a major lack of evidence, and fails to identify the optimal treatment of this specific problem (**Chapter 4**). Difficulties to overcome during minimally invasive surgery for this complex hernia, and the need for a tailored approach are described in **Chapter 5**. In our patient cohort, a significant amount of complications were reported during a median follow-up of 366 days. The overall complication rate of 46.7%, and 3 out of 15 patients presenting with a severe complication illustrate the challenges in treating this condition. Depending on the presence of a concomitant midline incisional hernia (IH) and intraoperative findings, we present a flowchart to standardize the choice of surgical technique.

The stepwise introduction of robotic-assisted techniques in the treatment of inguinal and ventral hernias in Maria Middelaers hospital (Gent, Belgium) is presented in **Chapter 6**. Regarding ventral hernia repair, this has led to a major shift in mesh position. Robotic

surgery allows techniques that use extraperitoneal mesh, and intraperitoneal meshes were largely abandoned.

Furthermore, two topics regarding midline IHs are discussed in **Part III**. First, current practice and long-term outcomes regarding prophylactic mesh after open abdominal aortic aneurysm (AAA) treatment were investigated. Second, outcomes, shortcomings in current literature and future perspectives in robotic-assisted transversus abdominis release (rTAR) are reported.

In a survey among vascular surgeons in Belgium and The Netherlands, current practice in the use of a prophylactic mesh after open AAA repair was monitored (**Chapter 7**). Of the 101 respondents, only 6.9% systematically use a prophylactic mesh, and 18.8% use it in selected cases. Furthermore, only 44.6% of vascular surgeons report using the recommended 4 to 1 suture to wound length ratio in the primary closure of the abdominal wall. Increased operative times and concerns on mesh-related complications were identified as the main reasons not to use mesh. In **Chapter 8**, we report on the 5-year follow-up of a randomized controlled trial (RCT) comparing the use of a prophylactic retrorectus mesh and primary closure of midline laparotomies after open AAA repair. The cumulative incidence of IHs after open AAA repair when no mesh is used continues to increase during the first 5 years after surgery (up to 49.2%), which leads to a substantial rate of hernia repairs (21.7%). On the contrary, when a mesh was used, no IHs were observed during follow-up.

Results of a retrospective multicenter study, including 90 patients that underwent rTAR and 79 patients that were treated by open transversus abdominis release (oTAR) are presented in **Chapter 9**. The length of postoperative hospital stay was significantly shorter in the rTAR group (3.4 days vs 6.9 days;  $p < 0.001$ ) and during the first 30 days after surgery, there were significantly more overall and serious complications in the oTAR group (7.8% vs 20.3%;  $p = 0.018$ ). On the longer term, reoperation and recurrence rates were similar. These findings are in concordance with available observational data in literature. In a comment to a recently published pooled analysis of these data (**Chapter 10**), some shortcomings in the methodology of this meta-analysis were highlighted. To conclude, in **Chapter 11**, we present a study protocol for a multicenter RCT to undeniably illustrate the possible advantages of rTAR over rTAR in the treatment of complex ventral IHs.







## Samenvatting



Een aanzienlijk deel van alle heilkundige ingrepen die wereldwijd worden uitgevoerd betreft ingrepen ter hoogte van de buikwand. Deze operaties worden tegenwoordig meer en meer uitgevoerd door gespecialiseerde en toegewijde herniachirurgen, die meer en meer minimaal invasieve technieken toepassen en steeds minder intraperitoneale meshes gebruiken. Sinds de introductie van robotgeassisteerde technieken binnen dit subdiscipline is de huidige praktijk aanzienlijk veranderd en mee geëvolueerd (**Hoofdstuk 1**). Binnen dit proefschrift worden enkele van deze recente ontwikkelingen binnen de buikwandchirurgie nader onderzocht. Zowel de technische aspecten als uitkomsten van enkele nieuwe technieken voor de preventie en behandeling van lies-, parastomale en ventrale hernias worden nader toegelicht.

In **Deel 1** worden resultaten van twee specifieke minimaal invasieve technieken voor liesbreukherstel beschreven. In een prospectieve cohort studie bij 100 mannelijke patiënten werd een gestandaardiseerde techniek middels 1 grote zelf-fixerende mesh voor de behandeling van een bilaterale liesbreuk gevalideerd (**Hoofdstuk 2**). Gedurende een follow-up van 1 jaar werden gunstige resultaten gezien wat betreft levenskwaliteit en urinaire symptomen. In onze patientencohorte werden geen urologische of chronische pijnklachten geïnduceerd door het gebruik van de grote zelf-fixerende mesh die beide liesopeningen overlapt. In **Hoofdstuk 3** worden resultaten beschreven van een groep patiënten die een robot-geassisteerd liesbreukherstel hebben ondergaan, na eerdere transabdominale prostatectomie. Deze minimaal invasieve approach is in een groep van 45 patiënten veilig en haalbaar gebleken, met gelijkaardige uitkomsten als na open chirurgie. Bovendien kan deze techniek bijkomende voordelen bieden ingeval van een bilaterale inguinale hernia, of bij de diagnostiek (en behandeling) van een contralaterale occulte liesbreuk.

In **Deel 2** van dit proefschrift gaan we dieper in op de behandeling van een parastomale hernia ter hoogte van een ileale lis urinaire derivatie. Na een systematisch nazicht van de beschikbare literatuur blijkt dat er nog steeds een belangrijk hiaat bestaat in de evidence omtrent dit ziektebeeld. Door de schaarste in beschikbare data is het op dit moment niet mogelijk één optimale behandeling voor deze aandoening te identificeren (**Hoofdstuk 4**). De moeilijkheden en obstakels die een minimaal invasieve behandeling van deze complexe hernia met zich meebrengt worden beschreven in **Hoofdstuk 5**, evenals de noodzaak tot een gepersonaliseerde behandeling van dit ziektebeeld. Binnen een patientencohort werd een aanzienlijke hoeveelheid complicaties gezien gedurende een mediane follow-up van 366 dagen. De hoge complicatieratio van 46.7%, en het feit dat 3 van de 15 patiënten zich hebben gepresenteerd met een ernstige complicatie illustreren de uitdagingen die een chirurgische behandeling met zich meebrengt. Naast

een beschrijving van de resultaten wordt in **Hoofdstuk 5** ook een stroomdiagram voorgesteld om de optimale chirurgische techniek te selecteren, afhankelijk van de aanwezigheid van een littekenbreuk ter hoogte van de linea alba en de peroperatieve bevindingen ter hoogte van de parastomale hernia.

In **Hoofdstuk 6** wordt de stapsgewijze introductie van robotgeassisteerde technieken voor de behandeling van lies- en ventrale hernias in het Maria Middelaars ziekenhuis (Gent, België) voorgesteld. Vooral voor de behandeling van ventrale buikwandbreuken heeft dit een belangrijke verschuiving in de chirurgische techniek teweeggebracht. De robot heeft ervoor gezorgd dat het gebruik van een intraperitoneale mesh grotendeels werd verlaten, en meshes voor het overgrote deel tegenwoordig buiten de buikholtte worden geplaatst (zowel preperitoneaal als retromusculair).

In **Deel 3** van dit proefschrift worden twee onderwerpen aangaande littekenbreuken ter hoogte van de middellijn nader onderzocht. Vooreerst worden de huidige praktijk en langetermijnsresultaten van profylactische mesh na een open herstel van een abdominaal aorta aneurysma (AAA) beschreven. Daarnaast worden uitkomsten, tekortkomingen in de huidige literatuur en toekomstige perspectieven wat betreft robotgeassisteerde transversus abdominis release (rTAR) beschreven.

Het gebruik van een profylactische mesh na open AAA herstel in de huidige praktijk werd onderzocht in een survey onder vaatchirurgen in België en Nederland (**Hoofdstuk 7**). Van de 101 respondenten zegt slechts 6.9% systematisch een profylactische mesh te gebruiken, en 18.8% gebruikt het in geselecteerde gevallen. Slechts 44.6% van de vaatchirurgen geeft aan de aangewezen 4-1 verhouding tussen de lengte van de hechting en de lengte van de wonde te respecteren bij het sluiten van de buikwand. Langere operatieduur en bezorgdheden omtrent mesh-gerelateerde complicaties werden in onze enquête geïdentificeerd als de voornaamste redenen om geen profylactische mesh te gebruiken. In **Hoofdstuk 8** beschrijven we de 5-jaars resultaten van een gerandomizeerde gecontroleerde studie waarin het gebruik van een retromusculaire profylactische mesh en het primair sluiten van de buikwand werden vergeleken na open AAA herstel. De cumulatieve incidentie van littekenbreuken wanneer geen profylactische mesh wordt gebruikt neemt verder toe gedurende de eerste 5 jaar na chirurgie (tot 49.2%). Dit leidt tot een substantiële hoeveelheid operaties voor het herstel van een littekenbreuk (21.7%). Binnen de groep patiënten bij wie wel een profylactische mesh werd geplaatst werden binnen deze studie geen littekenbreuken gediagnosticeerd.

In **Hoofdstuk 9** worden de resultaten van een retrospectieve multicentrische studie voorgesteld, waarbij uitkomsten van 90 patiënten die een rTAR hebben ondergaan werden vergeleken met die van 79 patiënten waarbij een open transversus abdominis release (oTAR) werd verricht. De postoperatieve hospitalisatieduur was significant korter in de rTAR groep (3.4 vs 6.9 dagen;  $p < 0.001$ ). Binnen de eerste 30 dagen na chirurgie was het aantal complicaties en het aantal ernstige complicaties significant hoger in de oTAR groep (7.8% vs 20.3%;  $p = 0.018$ ). Op langere termijn waren het aantal heroperaties en recidief hernias gelijklopend tussen de beide groepen. Deze bevindingen zijn in overeenstemming met beschikbare observationale data in de huidige literatuur. Recent werd van deze data een meta-analyse verricht en gepubliceerd. Enkele tekortkomingen in de methodologie van deze gepoolde analyse worden beschreven in **Hoofdstuk 10**. Tot slot wordt in **Hoofdstuk 11** een studieprotocol voorgesteld voor een prospectieve, multicentrische, gerandomizeerde studie die uitkomsten na rTAR en oTAR op een objectieve manier gaat vergelijken in de behandeling van complexe ventrale hernias.



Impact





In this paragraph, we aim to delineate the impact on daily practice of the recent advances in abdominal wall surgery that were discussed in this thesis. The economic burden that these techniques pose on healthcare systems necessitate an identification of the true clinical benefit of novelties, and a careful selection of patients that benefit the most from these developments. In general, two relatively new evolutions in hernia surgery were evaluated throughout the chapters, that warrant an evaluation of the true added value in daily practice:

1. Robotic-assisted techniques in inguinal, parastomal and ventral hernias
2. The use of a prophylactic mesh after open abdominal aortic aneurysm (AAA) surgery

## **Robotic-assisted techniques in hernia surgery: where is the true benefit?**

For the treatment of uncomplicated inguinal hernias, the robot probably does not add sufficient value to justify its routine use. Economic analyses have shown that the costs for robotic-assisted inguinal hernia repair were significantly higher compared to conventional laparoscopy, and probably the potential benefits do not outweigh this. In case of complex inguinal hernias (e.g. after transabdominal prostatectomy, large inguinoscrotal hernias, after previous preperitoneal repairs), these robotic techniques could be superior to conventional laparoscopy. However, there is currently insufficient evidence to support this opinion.

In the treatment of ventral hernias, the introduction of the robot has led to a shift in mesh position. Using conventional laparoscopic techniques mostly intraperitoneal repairs with penetrating fixations are performed. The robotic platform facilitates extraperitoneal mesh placement, in both preperitoneal and retromuscular planes. The wristed instruments facilitate suturing the abdominal wall, which is highly beneficial in closing hernia defects and fixating mesh. On the short term, this implies a reduction in postoperative pain, use of pain medication and length of hospital stay. Thereby, this allows the use of a less expensive (uncoated) mesh. On the long term, avoiding intraperitoneal mesh placement decreases the risk of adhesions and/or mesh erosions. These advantages could compensate for the increased cost of robotic-assisted surgery, and undeniably influence quality of life of patients.

Probably the biggest potential of robotic-assisted surgery lies within a patient group that needs component separation techniques to treat an incisional hernia. Our data suggest a highly significant reduction in length of postoperative hospital stay, due to a substantial decrease in postoperative pain and complications. Besides improving quality of life, this big reduction in length of hospital stay could (at least partially) compensate for higher procedure-related costs. It should be mentioned that these techniques are still in an early adoption phase, and do not represent common practice in Europe.

## **Prophylactic mesh after open AAA repair: should routine use be recommended?**

By reporting on the long-term results of the PRIMAAT-trial (**Chapter 8**), we illustrated a high cumulative incidence of incisional hernias when no prophylactic mesh was used after open AAA repair. This number continues to increase during the first 5 years after surgery, and leads to a substantial number of incisional hernia repairs. The use of a prophylactic mesh did not lead to an increase in mesh-related complications. Despite these observations, surgeons remain reluctant to use it, and guidelines only cautiously state that its use may be considered after open AAA repair. The most recent guidelines for vascular surgeons on the topic explicitly state that long-term results are awaited to recommend a change in practice. By reporting on the 60-month follow-up of the PRIMAAT-trial, we believe that this evidence has now been provided, supported by similar results (although with shorter follow-up) from other randomized controlled trials. The latest guidelines of the European Hernia Society on abdominal wall closure, published in 2015, require an update. Since then, evidence has piled up. This offers an opportunity to include a stronger recommendation on the use of a prophylactic mesh in patients at high risk for the development of an incisional hernia, like patients with an AAA.





Dankwoord



Graag wil ik enkele mensen in het bijzonder bedanken die hebben bijgedragen aan dit proefschrift.

**Prof. dr. C.H.C. Dejong**, beste Kees, het is best lastig om mijn dank voor jou in enkele zinnestjes neer te schrijven. Tot twee maal toe heb je mij een kans gegeven, en dat is helemaal niet vanzelfsprekend. Een eerste keer als fellow, en toen kenden we elkaar niet. Een tweede keer, toen kenden we elkaar al iets beter, in onnoemelijk lastige omstandigheden. Ik ben je heel erg dankbaar voor de kansen die jij me hebt geboden. Ik heb eindeloos goeie herinneringen aan de vele vrijdagen die we samen aan de operatietafel hebben doorgebracht. Wir schneiden es ruhig durch, de bloeding luusterde na een beetje zuugge beter na dich dan na mich, maar together we're strong. Ik leerde er ook vissen, want 'if you go where no one goes, and you throw where no one throws, you'll catch them'. Oprechte dank voor alles wat je voor mij hebt gedaan, en voor alles wat je mij hebt geleerd. My kingdom for a deurbeweging.

**Prof. dr. N.D. Bouvy**, beste Nicole, van harte bedankt om mij als promovendus onder de vleugels te nemen. Je gaf me onderweg ook nog mee wat echt belangrijk is in het leven, en - toegegeven - dat was ook af en toe nodig.

**Dr. F. Muysoms**, beste Filip, dit proefschrift is veel meer jouw verdienste dan die van mij. Wetenschap bedrijven aan de snelheid en kwaliteit waarmee jij het doet is niet iedereen gegeven. Wat je hebt bereikt als niet-academisch chirurg is uitzonderlijk. Bovendien toont dit proefschrift ook jouw generositeit. Dankjewel voor de vele kansen.

**Dr. S.A.W. Bouwense**, beste Stefan, we hebben het Maastrichtse avontuur samen aangevat. Alleen had ik geen idee, en jij wel. Ik hoop dat we mooie jaren tegemoet gaan in Maastricht, en we er samen iets moois kunnen van maken. Ik ken in elk geval geen dokter met een groter hart voor zijn patiënten dan jij. Je zorgt ervoor dat ik geen beren op de weg zie, dat is al veel meer dan vele anderen voor me kunnen doen.

Geachte leden van de beoordelingscommissie en overige opponenten, bedankt voor uw kritische beoordeling van dit proefschrift. Ik kijk uit naar een boeiende discussie tijdens de verdediging.

**Prof. dr. S.W.M. Olde Damink**, beste Steven. Ik heb op korte tijd heel veel van jou geleerd. Jouw drive werkt telkens weer inspirerend. Jouw daadkracht is fenomenaal, maar je hebt daarbij heel veel aandacht voor de personen rondom jou, en dat is hoogst



uitzonderlijk. Ik wil je oprecht danken voor de unieke kans die je mij hebt geboden en het vertrouwen. Dat is niet evident, en dat besef ik.

**Prof. dr. U. Neumann**, beste Ulf, van harte bedankt voor de vele kansen die je mij hebt gegeven, en me nog elke dag gunt. Ik hoop nog veel van jou te leren, en ik kijk daar oprecht naar uit.

**Dr. M. Coolsen, Mevr. Baade-Corpelijn, Dr. M. Bemelmans, Dr. R. Van Dam, Dr. M. Den Dulk**, beste Marielle, Lieke, Marc, Ronald en Marcel. Lieve HPB-vrienden, jullie hebben mij in jullie armen gesloten, als broekje van de hele club. Groot is mijn dank voor alle kansen die ik dag in dag uit van jullie krijg. We maken er samen een mooie toekomst van.

**Dr. P. Pletinckx**, beste Pieter, ik vind het heel jammer dat we niet meer dagelijks samenwerken. Wat je doet als chirurg, collega en diensthoofd is bewonderenswaardig. Je hebt me heel veel geleerd, zowel in het operatiekwartier als daarbuiten.

Alle collega-stafleden, fellows, assistenten, verpleegkundigen en secretariaatsmedewerkers van de dienst heelkunde in het MUMC+ wil ik van harte bedanken voor het warme welkom. Het voelt altijd weer een beetje als thuiskomen.

Velen worden hier niet vernoemd, en voor sommige onder hen is dat helemaal onterecht. Ik moet hen dankbaar zijn om doorgaans andere redenen dan een bijdrage aan dit proefschrift, en ik hoop dat ik mijn dankbaarheid dan ook voldoende laat blijken buiten dit dankwoord om. Dat heb ik zeker verwaarloosd, maar ik beloof plechtig beter mijn best te doen.

Nost, groot is mijn dank. Jouw steun is niet-aflatend en onvoorwaardelijk.

Lieve Sarah, mogelijk zijn oprechte excuses hier meer op hun plek dan een woord van dank. Toch wil ik je bedanken voor wie je bent. Ik besef dat alle kansen die ik heb gekregen er niet zouden geweest zijn zonder jou. Jouw talenten zijn zoveel waardevoller dan die van mij, ik sta elke dag vol bewondering te kijken hoe je het allemaal doet. Dat laat ik veel te weinig zien. Marielou en Lize, jullie brengen vreugde en vrolijkheid in ons leven, dag in dag uit. Ondanks jullie jonge leeftijd hebben jullie allebei al laten zien heel erg dappere krijgers te zijn, en daar ben ik ontzettend trots op. We gaan een mooie tijd tegemoet samen.





# Curriculum vitae



Maxime Dewulf was born in Roeselare, Belgium on May 18, 1987. After graduating from high school in 2005, he started medical school. He obtained his degree as a medical doctor in 2012, and graduated *summa cum laude* from the University of Gent, Belgium. During the 6 following years, he completed his specialty training in surgery and worked as a resident in the Gent University Hospital, Maria Middelaes hospital in Gent and AZ Sint-Lucas hospital in Gent, Belgium. He became a certified surgeon in 2018. Afterwards, his fellowship training consisted of a one-year additional training in robotic and colorectal surgery in Maria Middelaes hospital (Gent, Belgium) where he was trained by Dr. Filip Muysoms and Dr. Pieter Pletinckx. As a fellow of the European Hernia Society he visited Prof. Andrew Debeaux in Edinburgh, Scotland. Under the supervision of Prof. Kees Dejong and Prof. Ulf Neumann, he completed a two-year fellowship training in hepatobiliary surgery in Maastricht University Medical Center, The Netherlands, between 2019 and 2021.

In January 2021 Maxime became a staff member in Maria Middelaes hospital in Gent, Belgium, with a particular interest in colorectal and minimally invasive liver surgery. In December 2021 he became a staff member at the department of hepatobiliary surgery at the Maastricht University Medical Center in The Netherlands. As a resident and fellow, he participated in several research projects in the field of robotic-assisted abdominal wall surgery under the supervision of Dr. Filip Muysoms, which eventually led to this PhD thesis. To date, he authored several peer-reviewed articles in the fields of colorectal, hepatobiliary and abdominal wall surgery, gave over 25 oral presentations and was an invited speaker and moderator in several international conferences.

Together with his wife Sarah, and his daughters Marielou and Lize he lives in Gellik, Belgium. Besides his professional activities, he is a passionate cycling fan, and a very moderate amateur cyclist.



## List of publications





Conservative treatment of left ventricular free wall rupture

**Dewulf M**, Cathenis K, Goossens D

Acta Chir Belg 2015; 115(6): 433-5.

Fecal impaction causing bilateral pelvic venous thrombosis

**Dewulf M**, Blomme Y, Coucke C

Acta Chir Belg 2018; 118(2): 110-2.

Right hemicolectomy in a patient with Heterotaxy Syndrome

**Dewulf M**, Beckers R, Pletinckx P

World J Colorectal Surg 2019; 8: 30-3.

‘Full prosthetic jacket’: external stenting of the renal vein

**Dewulf M**, Van Herzeele I, Decaestecker K, Vermassen F

Acta Chir Belg 2019; 120(5): 357-60.

Complete mesocolic excision does not increase short-term complications in laparoscopic left-sided colectomies. A comparative retrospective single center study

**Dewulf M**, Kalmar A, Vandenberg B, Muysoms F, Defoort B, Claeys D, Pletinckx P

Langenbecks Arch Surg 2019; 404: 557-64.

Laparoscopic bilateral groin hernia repair with one large self-fixating mesh: prospective observational study with patient related outcome of urological symptoms.

Muysoms F, **Dewulf M**, Kyle-Leinhase I, Baumgartner R, Ameye F, Defoort B, Pletinckx P

Surg Endosc 2020; 34(2): 920-29.

The effect of prehabilitation on postoperative complications and postoperative hospital stay in hepatopancreatobiliary surgery

**Dewulf M**, Verrips M, Coolsen MME, Den Dulk M, Bongers BC, Olde Damink SWM, Dejong CHC, Bouwense SAW

HPB 2021; 23(9): 1299-310.

Short-term outcomes of laparoscopic versus open hepatectomy in the elderly patient: systematic review and meta-analysis

Hildebrand N, Verkoulen K, **Dewulf M**, Van Dam R, Heise D, Ulmer F, Coolsen M

HPB 2021; 23(7): 984-93.

Osteoclast-like giant cells in hepatocellular carcinoma: case description and review of the literature

Gielen AHC, Samarska I, Den Dulk M, Beckervordersantvorth J, Dejong CHC, Bouwense SAW, **Dewulf M**

Acta Chir Belg 2021 June 21. Epub ahead of print.

doi: 10.1080/00015458.2021.1940443.

Robotic-assisted laparoscopic inguinal hernia repair after previous abdominal prostatectomy

**Dewulf M**, Aspeslagh L, Nachtergaele F, Pletinckx P, Muysoms F

Surg Endosc 2022; 36(3): 2105-12.

Three years of adopting robotic abdominal wall surgery in a European hospital: the ROBUST hernia project.

Muysoms F, Nachtergaele F, Pletinckx P, **Dewulf M**

Cir Esp (Engl Ed) 2021; 99(9): 629-34.

Comment to: Transversus abdominis release (TAR) for ventral hernia repair: open or robotic? Short-term outcomes from a systematic review with meta-analysis

**Dewulf M**, De Bacquer D, Muysoms F

Hernia 2022 Jan 19. Epub ahead of print.

doi: 10.1007/s10029-022-02568.

How-I-do-it: Minimally invasive repair of ileal conduit parastomal hernias. Technical note and preliminary results.

**Dewulf M**, Pletinckx P, Nachtergaele F, Ameye F, Dekuyper P, Hildebrand ND, Muysoms F

Langenbecks Arch Surg 2022 Jan 28. Epub ahead of print.

doi: 10.1007/s00423-021-02393-5.

Incidental finding of a congenital unilateral absence of the vas deferens during robotic inguinal hernia repair: missing a crucial landmark

Pauwaert K, Muysoms F, **Dewulf M**

Acta Chir Belg 2022 Feb 2. Epub ahead of print.

doi: 10.1080/00015458.2022.2035920.

Parastomal hernias after cystectomy and ileal conduit urinary diversion: surgical treatment and the use of prophylactic mesh: a systematic review

**Dewulf M**, Hildebrand ND, Bouwense SAW, Bouvy ND, Muysoms F

BMC Surg 2022 Mar 29; 22(1): 118. Epub ahead of print.

doi: 10.1186/s12893-022-01509-y.

Too limited use of prophylactic mesh of prophylactic mesh after open AAA repair in Belgium and The Netherlands?

**Dewulf M**, De Wever N, Van Herzele I, Mees BME, Muysoms FE, Bouvy ND

Eur J Vasc Endovasc Surg 2022 Feb 24: S1078-5884(22)00139-3. Epub ahead of print.

doi:10.1016/j.ejvs2022.02.031.

Open versus robotic-assisted laparoscopic posterior component separation in complex abdominal wall repair

**Dewulf M**, Hiekkaranta J, Mäkäräinen E, Saarnio J, Vierstraete M, Ohtonen P,

Muysoms F, Rautio T

BJS Open 2022 May 2;6(3): zrac057. Epub ahead of print.

doi:10.1093/bjsopen/zrac057.

Reply to: Incisional hernias after open abdominal aortic aneurysm repair: more attention needed at start and finish

**Dewulf M**, Bouvy N, Van Herzele I

Eur J Vasc Endovasc Surg 2022 June 11; S1078-5884(22)00353-7. Epub ahead of print.

doi: 10.1016/j.ejvs2022.06.003.

Prevention of incisional hernias by prophylactic mesh-augmented reinforcement of midline laparotomies for abdominal aortic aneurysm treatment: 5-year follow-up of a randomized controlled trial

**Dewulf M**, Muysoms F, Vierendeels T, Huyghe M, Miserez M, Ruppert M, Tollens T, van Bergen L, Berrevoet F, Detry O

Ann Surg 2022 Jun 28. Epub ahead of print.

doi: 10.1097/SLA.0000000000005545.

Robotic parastomal hernia repair: video report and preliminary results (Robotic-assisted hernia surgery: part IV)

**Dewulf M**, Dietz U, Montgomery A, Pauli E, Ayuso S, Marturano M, Augenstein V, Lambrecht J, Köhler G, Keller N, Wiegering A, Muysoms F

Chirurg 2022 - Accepted for publication

Addendum

Robotic versus open component separation by transversus abdominis release in the treatment of ventral incisional hernia: study protocol for an open-label multicenter international randomized controlled trial

**Dewulf M**, Vierstraete M, Nachtergaele F, Van Der Vekens N, Muysoms F

Clinicaltrials.gov



